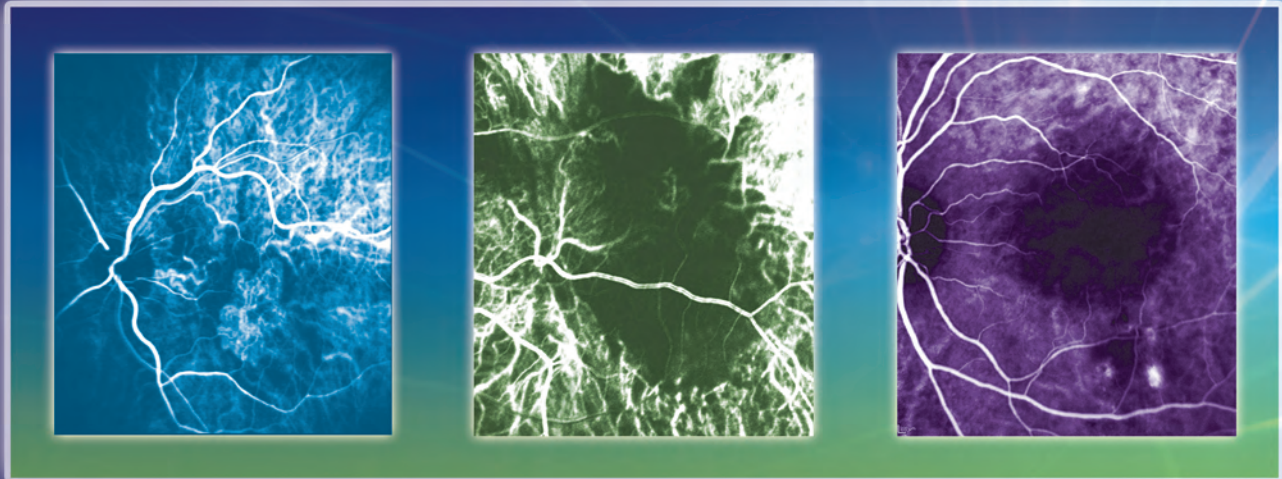


- Online testing and instant certificate at <http://tinyurl.com/PDTCME>
- Fax or Mail form at end of monograph

# PHOTODYNAMIC THERAPY

What Your Mentor May Not Have Taught You –  
Helpful Answers for Challenging Patients



## Highlights of a CME Roundtable

### Faculty Participants

Scott W. Cousins, MD, *Chair and Moderator*

Gregg T. Kokame, MD

Priyatham S. Mettu, MD

Gaurav K. Shah, MD

**Original Release Date:** April 1, 2015 | **Last Review Date:** March 2, 2015 | **Expiration Date:** April 30, 2016

Jointly provided by New York Eye and Ear Infirmary of Mount Sinai and MedEdicus LLC



MedEdicus  
LLC

This continuing medical education activity is supported through an unrestricted educational grant from Bausch + Lomb Incorporated.

Distributed with **EyeNet**  
MAGAZINE  
AMERICAN ACADEMY  
OF OPHTHALMOLOGY  
The Eye World's Authority

## Learning Method and Medium

This educational activity consists of a supplement and ten (10) study questions. The participant should, in order, read the learning objectives contained at the beginning of this supplement, read the supplement, answer all questions in the post test, and complete the Activity Evaluation/Credit Request form. To receive credit for this activity, please follow the instructions provided on the post test and Activity Evaluation/Credit Request form. This educational activity should take a maximum of 1.5 hours to complete.

## Content Source

This continuing medical education (CME) activity captures content from a roundtable discussion held on October 18, 2014, in Chicago, Illinois.

## Activity Description

Today's newly minted retina specialists might not have adequate exposure to the clinical utility of photodynamic therapy (PDT) with verteporfin. PDT with verteporfin was first introduced in 2001. At that time, PDT represented a significant advance over thermal laser therapy in the management of neovascular age-related macular degeneration (AMD). Soon thereafter, in 2004, the advent of intravitreal anti-vascular endothelial growth factor therapy produced a paradigm shift in the treatment of neovascular AMD. Nevertheless, PDT offers substantial benefit for a subset of patients with neovascular AMD and other choroidal vascular diseases, many of whom represent the more challenging patients seen in clinical practice. The goal of this activity is to help retina specialists provide better outcomes for their patients by addressing practice gaps related to PDT.

## Target Audience

This activity is intended for retina specialists as well as fellows and third-year residents.

## Learning Objectives

Upon completion of this activity, participants will be better able to:

- Demonstrate when photodynamic therapy (PDT) may be appropriate for patients with wet age-related macular degeneration that is resistant to anti-vascular endothelial growth factor therapy
- Describe the role of indocyanine green angiography in differentiating and diagnosing various forms of neovascularization and exudative diseases
- Discuss use of PDT in the management of appropriate patients with diagnoses of polypoidal choroidal vasculopathy, central serous retinopathy, and other diseases

## Accreditation Statement

This activity has been planned and implemented in accordance with the accreditation requirements and policies of the Accreditation Council for Continuing Medical Education (ACCME) through the joint providership of **New York Eye and Ear Infirmary of Mount Sinai** and MedEdicus LLC. The **New York Eye and Ear Infirmary of Mount Sinai** is accredited by the ACCME to provide continuing medical education for physicians.



In July 2013, the Accreditation Council for Continuing Medical Education (ACCME) awarded New York Eye and Ear Infirmary of Mount Sinai "Accreditation with Commendation," for six years as a provider of continuing medical education for physicians, the highest accreditation status awarded by the ACCME.

## AMA Credit Designation Statement

The **New York Eye and Ear Infirmary of Mount Sinai** designates this enduring material for a maximum of 1.5 AMA PRA Category 1 Credits™. Physicians should claim only the credit commensurate with the extent of their participation in the activity.

## Grantor Statement

This continuing medical education activity is supported through an unrestricted educational grant from Bausch + Lomb Incorporated.

## Disclosure Policy Statement

It is the policy of **New York Eye and Ear Infirmary of Mount Sinai** that the faculty and anyone in a position to control activity content disclose any real or apparent conflicts of interest relating to the topics of this educational activity, and also disclose discussions of unlabeled/unapproved uses of drugs or devices during their presentation(s). **New York Eye and Ear Infirmary of Mount Sinai** has established policies in place that will identify and resolve all conflicts of interest prior to this educational activity. Full disclosure of faculty/planners and their commercial relationships, if any, follows.

## Disclosures

**Scott W. Cousins, MD**, had a financial agreement or affiliation during the past year with the following commercial interest in the form of *Contracted Research*: Bausch + Lomb Incorporated.

**Gregg T. Kokame, MD**, had a financial agreement or affiliation during the past year with the following commercial interests in the form of *Consultant Fees*

(Advisory Board): Allergan, Inc; Bausch + Lomb Incorporated; Bayer HealthCare; Regeneron Pharmaceuticals, Inc; and Santen Pharmaceutical Co, Ltd; *Contracted Research*: Genentech, Inc; and Regeneron Pharmaceuticals, Inc; *Honoraria from promotional, advertising or non-CME services received directly from commercial interests or their Agents (eg, Speakers Bureaus)*: Regeneron Pharmaceuticals, Inc; and ThromboGenics NV.

**Priyatham S. Mettu, MD**, had a financial agreement or affiliation during the past year with the following commercial interest in the form of *Contracted Research*: Bausch + Lomb Incorporated.

**Gaurav K. Shah, MD**, had a financial agreement or affiliation during the past year with the following commercial interests in the form of *Consultant Fees (Advisory Board)*: Alcon, Inc; Allergan, Inc; QLT Inc; and Regeneron Pharmaceuticals, Inc.

## New York Eye and Ear Infirmary of Mount Sinai Peer Review Disclosure

**John A. Sorenson, MD**, has no relevant commercial relationships to disclose.

## Editorial Support Disclosures

**Cynthia Tornallyay, RD, MBA, CCMEP**; **Diane McArdle, PhD**; **Kimberly Corbin, CCMEP**; **Barbara Auel**; and **Laura Herold** have no relevant commercial relationships to disclose.

**Tony Realini, MD (Writer)**, had a financial agreement or affiliation during the past year with the following commercial interests in the form of *Consultant Fees (Advisory Board)*: Alcon, Inc; *Contracted Research*: Alcon, Inc; and Aerie Pharmaceuticals, Inc; *Research Equipment*: Lumenis Ltd.

## Disclosure Attestation

The contributing physicians and instructors listed above have attested to the following:

- 1) that the relationships/affiliations noted will not bias or otherwise influence their involvement in this activity;
- 2) that practice recommendations given relevant to the companies with whom they have relationships/affiliations will be supported by the best available evidence or, absent evidence, will be consistent with generally accepted medical practice; and
- 3) that all reasonable clinical alternatives will be discussed when making practice recommendations.

## For Digital Editions

### System Requirements:

If you are viewing this activity online, please ensure the computer you are using meets the following requirements:

- **Operating System:** Windows or Macintosh
- **Media Viewing Requirements:** Flash Player or Adobe Reader
- **Supported Browsers:** Microsoft Internet Explorer, Firefox, Google Chrome, Safari, and Opera
- **A good Internet connection**

## New York Eye and Ear Infirmary of Mount Sinai Privacy & Confidentiality Policies

CME policies: <http://www.nyee.edu/cme-enduring.html>

Hospital policies: <http://www.nyee.edu/websiteprivacy.html>

## CME Provider Contact Information

For questions about this activity, call 212-979-4383.

## To Obtain AMA PRA Category 1 Credit™

To obtain AMA PRA Category 1 Credit™ for this activity, read the material in its entirety and consult referenced sources as necessary. Complete the evaluation form along with the post test answer box within this supplement. Remove the Activity Evaluation/Credit Request page from the printed supplement or print the Activity Evaluation/Credit Request page from the Digital Edition. Return via mail to Kim Corbin, Director, ICME, **New York Eye and Ear Infirmary of Mount Sinai**, 310 East 14th Street, New York, NY 10003 or fax to (212) 353-5703. Your certificate will be mailed to the address you provide on the Activity Evaluation/Credit Request form. Please allow 3 weeks for Activity Evaluation/Credit Request forms to be processed. There are no fees for participating in and receiving CME credit for this activity.

Alternatively, we offer instant certificate processing and support Green CME. Please take this post test and evaluation online by going to <http://tinyurl.com/PDTCME>. Upon passing, you will receive your certificate immediately. You must score 70% or higher to receive credit for this activity, and may take the test up to 2 times. Upon registering and successfully completing the post test, your certificate will be made available online and you can print it or file it.

## Disclaimer

The views and opinions expressed in this educational activity are those of the faculty and do not necessarily represent the views of **New York Eye and Ear Infirmary of Mount Sinai**, MedEdicus LLC, Bausch + Lomb Incorporated, or EyeNet Magazine.

This CME activity is copyrighted to MedEdicus LLC ©2015. All rights reserved.



## Program Chair and Moderator

### Scott W. Cousins, MD

Robert Machemer, MD, Professor of Ophthalmology and Immunology  
Vice Chair for Research and Director  
Duke Center for Macular Diseases  
Duke Eye Center  
Durham, North Carolina

## Faculty

### Gregg T. Kokame, MD

Clinical Professor  
University of Hawaii John A. Burns School of Medicine  
Honolulu, Hawaii  
Medical Director  
The Retina Center at Pali Momi  
Pali Momi Medical Center  
Aiea, Hawaii

### Priyatham S. Mettu, MD

Assistant Professor of Ophthalmology  
Duke University School of Medicine  
Duke Eye Center  
Durham, North Carolina

### Gaurav K. Shah, MD

Co-Director, Fellowship Program  
The Retina Institute  
St. Louis, Missouri

## CME Reviewer for

## New York Eye and Ear Infirmary of Mount Sinai

### John A. Sorenson, MD

Clinical Assistant Professor  
Department of Ophthalmology  
New York University School of Medicine  
Surgical Staff  
New York Eye and Ear Infirmary of Mount Sinai  
New York, New York

## Introduction

**Scott W. Cousins, MD:** *Photodynamic therapy (PDT) with verteporfin was first introduced in 2001.<sup>1</sup> At that time, PDT represented a significant advance over thermal laser therapy in the management of neovascular age-related macular degeneration (AMD). Soon thereafter, in 2004, the advent of intravitreal anti-vascular endothelial growth factor (VEGF) therapy produced a paradigm shift in the treatment of neovascular AMD. Nevertheless, PDT continues to offer substantial benefit for a subset of patients with neovascular AMD and other choroidal vascular diseases, many of whom represent the more challenging patients we face in clinical practice. The goal of this monograph is to provide expert perspectives on the use of PDT in 7 clinically relevant scenarios.*

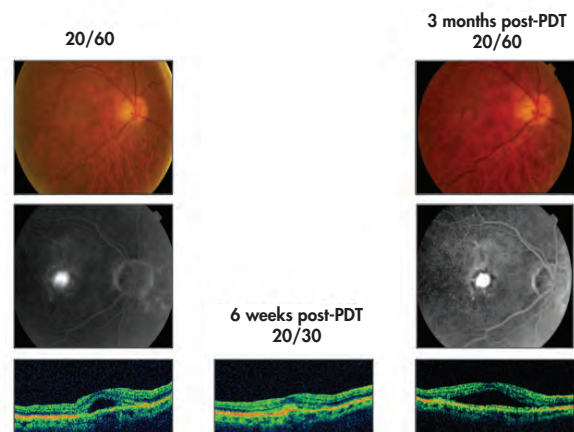
## Case 1. Photodynamic Therapy With Verteporfin: Historical Review

**Dr Cousins:** The first case, which is from the pre-anti-VEGF era, involves a 68-year-old patient who presented with neovascular AMD of the classic lesion subtype with subretinal fluid evident on optical coherence tomography (OCT) (Figure 1). The patient underwent PDT with verteporfin, and within 6 weeks had improved visual acuity and a dry macula on OCT. By 3 months post-PDT, there was recurrence of neovascular activity on both fluorescein angiography and OCT. This represents the typical response we obtained with PDT.

Dr Shah, what is the mechanism of action of PDT with verteporfin?

**Gaurav K. Shah, MD:** Verteporfin is injected into the systemic circulation, much as we do with fluorescein. As it circulates through the retinal vasculature, we activate the

### Case 1: Classic Leakage Treated With PDT Monotherapy



**Figure 1.** This case demonstrates a classic lesion by fluorescein angiography, and associated subretinal fluid by OCT (left column). Despite a good initial response to PDT with resolution of subretinal fluid (middle column), reactivation of the classic lesion with recurrence of subretinal fluid occurred 3 months later (right column).

molecule by directing a nonthermal red laser at a wavelength of 693 nm at the macular lesion. Once photoactivated, verteporfin triggers production of reactive oxygen species, which causes damage that is confined to the vascular endothelium of the lesion targeted by the laser. This locally induced phototoxicity causes platelet aggregation, thrombosis, and, ultimately, targeted occlusion of choroidal neovascularization, which remains inactive until there is reperfusion.

**Dr Cousins:** Dr Kokame, please summarize the major clinical trials that supported the use of PDT with verteporfin.

**Gregg T. Kokame, MD:** The Treatment of AMD with Photodynamic Therapy (TAP) study compared PDT with sham therapy in patients with subfoveal AMD lesions that contained a classic component.<sup>1</sup> Overall, the PDT group had better visual outcomes at 12 and 24 months compared with the sham group. Subgroup analysis showed that the benefit of PDT over sham was in patients with predominantly classic lesions, and the benefit was particularly great in patients with no occult component.

The Verteporfin in PDT (VIP) study was of similar design but enrolled patients with occult lesions.<sup>2</sup> The 12-month results for that study were disappointing, but at 24 months there was a small benefit favoring PDT over sham. Again, subgroup analysis revealed that the greatest benefit of PDT was in patients with small lesions (<4 disc diameters) and with visual acuity worse than 20/50. In terms of safety, there was a low risk (1%–2%) of a sudden decrease in vision that was thought to be due to choroidal ischemia or subretinal hemorrhage.

**Dr Cousins:** Once the anti-VEGF drugs were introduced, the use of PDT rapidly decreased. A few years ago, there was a resurgence of its use as part of a combination therapy to reduce the treatment burden of patients with AMD.

Dr Shah, please describe the evidence supporting the use of PDT in combination with anti-VEGF therapy.

**Dr Shah:** The MONT BLANC study compared PDT and ranibizumab to ranibizumab alone in eyes with neovascular AMD, using an as-needed dosing strategy following 3 monthly loading doses of ranibizumab 0.5 mg.<sup>3</sup> The study failed to show an added benefit of combination therapy over ranibizumab alone in terms of visual acuity outcomes or the number of retreatments necessary at 12 months. The DENALI study had 3 arms: monthly ranibizumab 0.5 mg monotherapy, standard-fluence PDT combined with ranibizumab 0.5 mg, and reduced-fluence PDT combined with ranibizumab 0.5 mg. In both PDT groups, ranibizumab was administered as needed after 3 monthly loading doses.<sup>4</sup> The ranibizumab monotherapy group had significantly better visual acuity outcomes than either of the 2 combination groups (ie, 3–4 Early Treatment Diabetic Retinopathy Study letters or approximately 1 line of Snellen vision), but the combination therapy groups required approximately half as many ranibizumab injections over the 12-month study. The RADICAL (Reduced Fluence Visudyne Anti-VEGF-Dexamethasone In Combination for AMD Lesions) study took combination therapy one step further by comparing 4 groups: ranibizumab alone, ranibizumab plus PDT at

half-fluence, or ranibizumab plus dexamethasone plus PDT at either half- or quarter-fluence.<sup>5</sup> All 3 combination groups required significantly fewer overall ranibizumab injections compared with the monotherapy group, with the triple combination at half-fluence providing the greatest reduction in treatment burden and minimal reduction in visual acuity compared with ranibizumab monotherapy.

**Dr Cousins:** Based on these studies, do you use combination therapy in your practices? If so, describe how you do so.

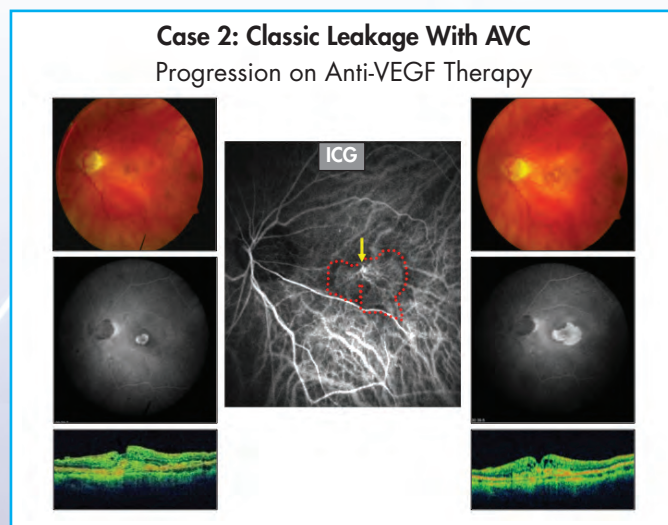
**Dr Kokame:** Whenever I use PDT for any condition characterized by choroidal neovascularization, I combine it with both anti-VEGF and steroid therapy. I perform PDT at our local hospital, and then on the same day I have the patient come to our office for the anti-VEGF and dexamethasone injection afterward.

**Dr Shah:** We see many patients at our satellite offices, where we will start with anti-VEGF therapy and have them follow up at one of the main offices soon thereafter—typically within a week—for PDT and dexamethasone. There are many ways to administer combination therapy, and each has its pros and cons. In the end, I think it usually comes down to the logistics of individual practices.

**Priyatham S. Mettu, MD:** The order may be less important than the timing. I strive to make sure the anti-VEGF injection is given within a week or 2 of PDT, and I usually administer an intravitreal steroid at the time of PDT. This is because there may be increased levels of VEGF and inflammatory mediators that drive exudation post-PDT.

## Case 2. Neovascular Age-Related Macular Degeneration With Persistent Disease Activity

**Dr Cousins:** Next, we will consider a patient with a classic subfoveal lesion (Figure 2). After 2 monthly anti-VEGF



**Figure 2.** Neovascular age-related macular degeneration with a small classic leakage pattern on fluorescein angiography (left column). Despite anti-VEGF therapy, the lesion persisted and progressed (right column). Indocyanine green angiography (middle image) demonstrated a feeder artery (yellow arrow) with many branching arterioles and minimal capillaries, also known as an arteriolarized vascular complex (AVC) (outlined in red).



treatments, the lesion has tripled in size. This represents a manifestation of persistent disease activity (PDA) despite anti-VEGF therapy.

**Dr Mettu:** please explain the difference between anti-VEGF-responsive and anti-VEGF-resistant neovascular AMD, and please explain PDA.

**Dr Mettu:** Responsive disease is typically characterized as quiescence of disease with treatment over time, which is defined as resolution of leakage and stable lesion size without growth. In contrast, resistant disease typically fails to achieve quiescence despite an adequate course of anti-VEGF therapy.

Broadly, PDA can be recognized as an incomplete response to anti-VEGF monotherapy. This may occur early, after a 3-dose loading period, or it can appear later in the treatment course, after 6 to 12 months of anti-VEGF therapy. On OCT, we may see intraretinal fluid, subretinal fluid, and a new serous pigment epithelial detachment (PED). Often you also will see prominent spongiform PED, with heterogenous reflectivity on OCT, suggesting the presence of a perfused vessel. Fluorescein angiography may reveal persistent leakage and lesion growth. On clinical examination, we can often appreciate both progressive fibrosis and either a persistent or breakthrough hemorrhage while on treatment.

**Dr Cousins:** How common is PDA?

**Dr Mettu:** PDA is surprisingly frequent. In the Comparison of AMD Treatments Trial (CATT), 50% to 80% of subjects had PDA at 12 months, with the higher frequencies occurring in as-needed treatment groups compared with the monthly treatment groups.<sup>6</sup> By the second year of CATT, lesion size increase was also evident, with the most marked effect apparent in the bevacizumab as-needed treatment group.<sup>7</sup>

**Dr Shah:** I would like to add that there are frequently cases of PDA that may not be evident by OCT, but will be evident on fluorescein angiography. OCT does not always reveal activity within the choroid. As retina specialists, we may not be doing enough angiograms to observe this phenomenon.

**Dr Cousins:** Once PDA is established, should we routinely obtain fluorescein angiography on all new patients with neovascular AMD?

**Dr Shah:** I do. I feel it is important to document our baseline status.

**Dr Mettu:** I do, as well.

**Dr Kokame:** I obtain both fluorescein and indocyanine green (ICG) angiography on all neovascular AMD patients at presentation.

**Dr Cousins:** Once PDA is established, should we initiate anti-VEGF therapy with a series of loading doses?

**Dr Kokame:** Regardless of which anti-VEGF agent I select, I start with a series of 3 monthly loading doses.

**Dr Shah:** I also start with 3 loading doses, and repeat the fluorescein angiography after 3 to 4 months of therapy.

**Dr Cousins:** If the angiogram looks inactive by your criteria at the 3-month visit, when will you repeat it?

**Dr Shah:** If the lesion appears inactive and the patient is clinically stable, I may not repeat it. If I plan to stop therapy or switch to a different treatment plan for any reason, I will repeat the fluorescein.

**Dr Mettu:** If the lesion appears inactive following the loading-dose therapy, I will typically repeat the angiography sometime between 6 and 9 months later to determine whether I can continue to extend the interval between treatments. This approach is based on data from the PIER study suggesting that the fluorescein angiogram can help identify those patients who can sustain visual acuity gains with less frequent therapy.<sup>8</sup>

**Dr Cousins:** Does PDA matter?

**Dr Shah:** As Dr Mettu has noted, the PIER study demonstrated that the level of disease activity at 3 months was predictive of visual acuity outcomes at 1 year. Those patients with a dry macula by fluorescein angiography at 3 months had better 1-year vision than those with a wet macula at 3 months.<sup>8</sup> Having said that, I do not routinely treat a nearly dry macula with continued aggressive anti-VEGF therapy; I consider extending the interval between treatments. It is important to make sure that we are treating the patient and not the test. If the patient is doing well, I take that into account.

**Dr Cousins:** Are other characteristics of PDA associated with worse vision outcomes?

**Dr Mettu:** The CATT study demonstrated that fibrosis and intraretinal fluid were associated with worse long-term vision.<sup>9</sup> Increased lesion size was predictive of vision loss in the MARINA and ANCHOR studies.<sup>10</sup>

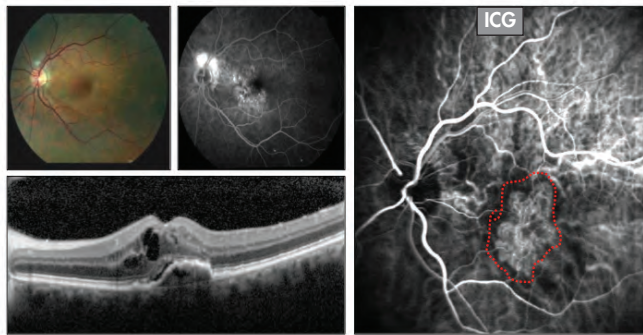
**Dr Cousins:** Why is ICG angiography useful in these patients?

**Dr Mettu:** ICG can reveal subtypes, such as arteriolarized vascular complex (AVC) or polypoidal choroidal vasculopathy (PCV), which may follow a different natural history than typical choroidal neovascularization and which may more commonly manifest PDA. These subtypes may require alternative treatment strategies, and ICG can identify them early in the course of the disease. For example, I may consider switching anti-VEGF agents sooner. If I started with bevacizumab, I might have a lower threshold for switching to ranibizumab or aflibercept. Alternately, the presence of these lesion subtypes might prompt me to consider the role of adjunctive PDT.

### Case 3. Persistent Disease Activity Associated With Arteriolarized Vascular Complex

**Dr Cousins:** A 70-year-old patient with neovascular AMD has received 5 anti-VEGF injections and has 20/70 visual acuity. The fluorescein angiogram shows an occult leakage pattern (**Figure 3**). The OCT shows cystic intraretinal fluid, subretinal fluid, and a mixed reflectivity spongiform PED. The ICG shows a blood vessel complex characterized by large-caliber branching arterioles and almost no capillary component, which is typically called an AVC.

### Case 3: PDA in Occult Leakage With AVC



**Figure 3.** An occult AMD lesion persisted despite 5 anti-VEGF treatments (top left images). OCT revealed cystic intraretinal fluid, subretinal fluid, and mixed reflectivity spongiform pigment epithelial detachment. (bottom left). The indocyanine green angiography (right image) demonstrated an arteriolarized vascular complex (AVC) (outlined in red).

What are these arteriolarized vessels? How are they related to what we once called feeder vessels?

**Dr Mettu:** Arteriolarized vessels are, in fact, large-caliber, high-flow arteries from the choroid that give rise to multiple branching arterioles. They typically have a minimal capillary component and are often accompanied by perivascular fibrosis within Bruch membrane or under the retinal pigment epithelium (RPE). These lesions are quite commonly accompanied by persistent activity, in spite of anti-VEGF therapy. Historically, we have believed that feeder vessels are present only with more severe cases of fibrotic choroidal neovessels; however, with ICG, we have learned that AVCs are more common than we might have otherwise thought.

**Dr Cousins:** We assume that anti-VEGF therapy acts on the capillary component of the lesion, of which there is very little in these lesions. When we back off with anti-VEGF therapy, the capillaries regrow, and the lesion is reperfused. Thus, these cases require intensive treatment.

**Dr Kokame:** This is a great example of a lesion that is best imaged with ICG to determine its size. In addition, because the capillary component is minimal, I would opt for an anti-VEGF agent combined with PDT and a steroid.

**Dr Cousins:** Would you aim the PDT at the entire lesion or just at the feeder artery? What parameters would you use?

**Dr Kokame:** I would treat the lesion itself. As for parameters, I use visual acuity as my guide. If a patient's vision is relatively good, I use reduced fluence (25 J/m<sup>2</sup>). For acuity of 20/80 or worse, I use standard fluence (50 J/m<sup>2</sup>).

**Dr Mettu:** I would focus PDT at the base of the branch point. For subfoveal lesions, I start with reduced fluence and then retreat at standard fluence if I get a suboptimal response.

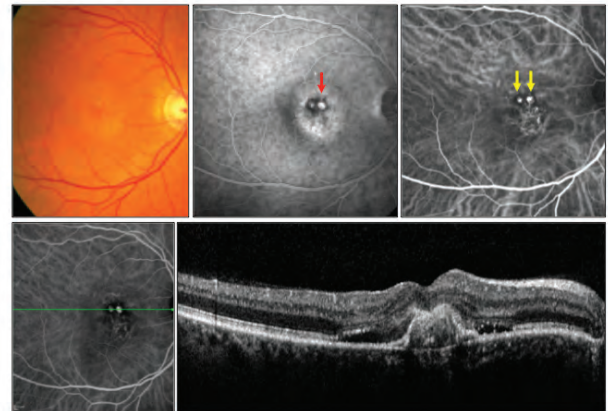
**Dr Cousins:** When do you repeat imaging after PDT?

**Dr Shah:** Typically, I will repeat fluorescein or ICG angiography 4 to 6 weeks after PDT to see if the lesion has been shut down. If I see residual subretinal or intraretinal fluid, I will repeat the anti-VEGF injection at that time.

## Case 4. Persistent Disease Activity Associated With Polypoidal Choroidal Vasculopathy

**Dr Cousins:** Figure 4 shows the imaging results of a 54-year-old white male with neovascular AMD that manifests persistent subretinal fluid and a pointed PED despite 3 doses of anti-VEGF therapy. The ICG showed several large polyps fed by a branching vascular complex. This is a typical case of PCV, which I believe is one of the most underdiagnosed subsets of PDA in AMD.

### Case 4: Minimally Classic Leakage With PCV Persistent Disease Activity



**Figure 4.** A minimally classic lesion by fluorescein angiography (top middle image) with persistent subretinal fluid and pointed PED (red arrow) by OCT (bottom middle), despite anti-VEGF treatments. The indocyanine green angiography (top right image) demonstrated several large polyps (yellow arrows) fed by a branching vascular complex.

Dr Kokame, as one of the world's experts on PCV, please describe PCV in a historical context.

**Dr Kokame:** Lawrence Yannuzzi initially described PCV at the 1982 Macula Society Annual Meeting and later reported on 11 patients with serosanguinous bleeding in the macula, PED, and peculiar orange subretinal lesions.<sup>11</sup> PCV was subsequently described in black females and in Asians with neovascular AMD. PCV is a very common cause of macular hemorrhage, exudation, and pointed or "peaked" PEDs among elderly Asians.<sup>12</sup>

**Dr Shah:** PCV represents approximately 10% to 15% of my practice in a typical Midwestern demographic, including many white patients. Some patients manifest PCV upon presentation, while in other patients, lesions evolve into a PCV configuration over time. PCV is particularly common among my patients who require consistent monthly anti-VEGF therapy. I think PCV is significantly underdiagnosed, perhaps in part because of the reluctance of retinal specialists to obtain ICG angiography routinely.

**Dr Cousins:** ICG is the gold-standard technology for the diagnosis of PCV. What role does OCT play?

**Dr Kokame:** ICG is the current gold standard, but some of the new OCT technologies show promise as an alternative diagnostic method. The next evolution will be en face OCT



imaging, and we are working on methods to correlate OCT and ICG findings. This technique reconstructs B scans into an en face image, visualizing the surface of the choroid and showing vascular contours. Interestingly, the vast majority of the time, the polypoidal lesions lie between Bruch membrane and the RPE, not in the choroid. The polyps appear as U-shaped lesions that are elevated significantly above the branching vascular network. With en face imaging, the lesion size is often larger on the OCT than on the ICG. The branching vascular network actually looks like a double line, a slight elevation of the RPE above Bruch membrane.

**Dr Cousins:** If this patient with PCV presented to your office, what would be your treatment considerations?

**Dr Kokame:** I would consider a number of factors. The first of these is visual acuity. If visual acuity remains relatively good, I would start with anti-VEGF therapy, just because there is that rare 1% to 2% risk of sudden vision loss with PDT.<sup>2</sup> If vision is 20/60 or worse, then I often discuss PDT as an option with patients. PDT can be very helpful in reducing anti-VEGF treatment burden in these eyes. The EVEREST study demonstrated that PDT alone or in combination with ranibizumab was far more effective than ranibizumab monotherapy in effecting polyp regression.<sup>13</sup>

**Dr Cousins:** How do you use PDT in these cases? Do you treat the whole lesion or target the polyps?

**Dr Kokame:** We measure the lesion size by ICG and add 300 microns as the basis for our PDT treatment area. We combine PDT therapy with same-day intravitreal anti-VEGF and dexamethasone.

**Dr Shah:** When I review the ICG, I prefer to review the video rather than just single images. This can reveal the dynamic nature of lesions, and it can reveal a pulsatile polyp.

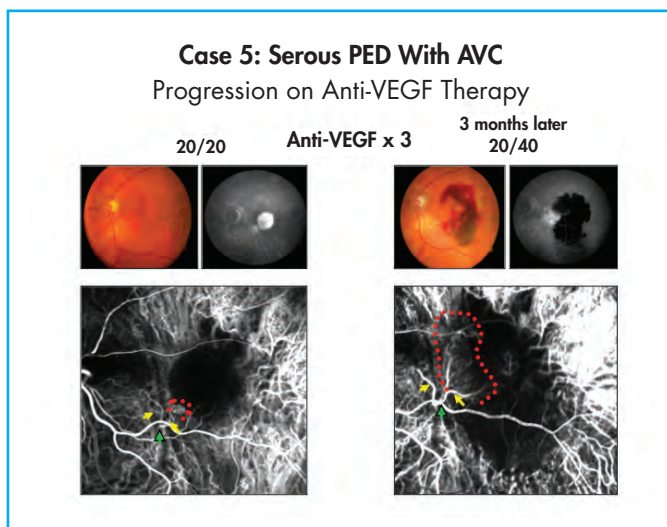
**Dr Kokame:** One additional imaging pearl is to focus on the early images or video. The first 3 to 5 minutes are more important than the later images.

**Dr Cousins:** What is the significance of pulsatile polyps, and do you modify your treatment plan to address them?

**Dr Shah:** Pulsatile polyps may be evidence of increased perfusion pressure. If the patient has elevated blood pressure in the setting of pulsatile polyps, I may defer PDT until the patient has better blood pressure control, in order to reduce the risk for submacular hemorrhage following PDT.

## Case 5. Persistent Disease Activity Associated With Serous Pigment Epithelial Detachment

**Dr Cousins:** Next, let us consider the patient whose imaging studies are shown in **Figure 5**. This patient with neovascular AMD presented with a typical serous PED. The fluorescein angiogram revealed some hyperfluorescence at 7 o'clock, which the ICG angiography clarified was a large-caliber feeding artery with a small cluster of arterioles and a second branch vessel. This patient underwent anti-VEGF therapy, and after the third injection there was a hemorrhage along the



**Figure 5.** Serous PED with small focus of hyperfluorescence at 7 o'clock on fluorescein angiography (top left images) with OCT findings (bottom left) of a feeder vessel (green arrow) with two branches (yellow arrows) and a small cluster of arterioles (red outline). A hemorrhage developed along the temporal edge of the macula (top right images) after 3 anti-VEGF treatments, with dramatic enlargement of the arteriolarized vascular complex (AVC) (red outline) on ICG (bottom right image).

temporal edge of the macula. The ICG at that time showed a dramatic enlargement of this AVC despite monthly anti-VEGF therapy.

Dr Mettu, tell us about the different kinds of PEDs, and tell us whether they are a manifestation of neovascular AMD.

**Dr Mettu:** There are several different types of PED that can be associated with neovascular AMD, including serous, spongiform, and hemorrhagic PED, as well as an additional type, drusenoid PED, which is actually a manifestation of dry AMD. Serous PEDs, in particular, have been both a diagnostic and treatment challenge because there has always been a question of whether they are truly neovascular. This issue has become more relevant in the anti-VEGF era, because we have observed that many of these cases do not respond well to anti-VEGF therapy, as this case illustrates. I believe these lesions respond poorly because many of these serous PEDs are associated with complex lesions like AVCs, as in this case, or PCV.

**Dr Cousins:** These vascular complexes cannot always be appreciated on fluorescein angiogram or OCT. Do you routinely obtain ICG upon presentation with serous PEDs?

**Dr Mettu:** Yes, I do, in order to determine the presence and location of the associated neovascular lesion.

**Dr Kokame:** For an isolated serous PED, I may not, but if I suspect there is any serous detachment, macular edema, or subretinal fluid, I would definitely get an ICG.

**Dr Shah:** I am less likely to get an ICG if the patient is asymptomatic.

**Dr Cousins:** How do you approach treating a patient with a serous PED and an AVC that is not responding to anti-VEGF therapy?

**Dr Kokame:** I prefer a localized PDT approach, not to the whole PED, but rather to the area of the vascular lesion.

Many times, I have seen the PED regress following treatment isolated to just the localized vessels.

**Dr Mettu:** I agree. I would target the base of the new vessel, striving for vascular occlusion or at least decreased perfusion.

**Dr Cousins:** We have discussed AVCs with PED. How common is PCV in association with nonhemorrhagic serous PED?

**Dr Kokame:** PED is very common in PCV. It is one of the primary manifestations of PCV.

**Dr Shah:** This discussion makes it clear that we need more than 1 imaging technique to see the whole picture. Without the ICG, it would be very difficult to detect the aspects of these lesions that are relevant for selecting appropriate therapy.

**Dr Cousins:** In the case I presented, I reassessed 1 month after PDT. The serous PED persisted, although there was partial closure of the polyps.

In a case with incomplete closure, what is the next therapeutic step?

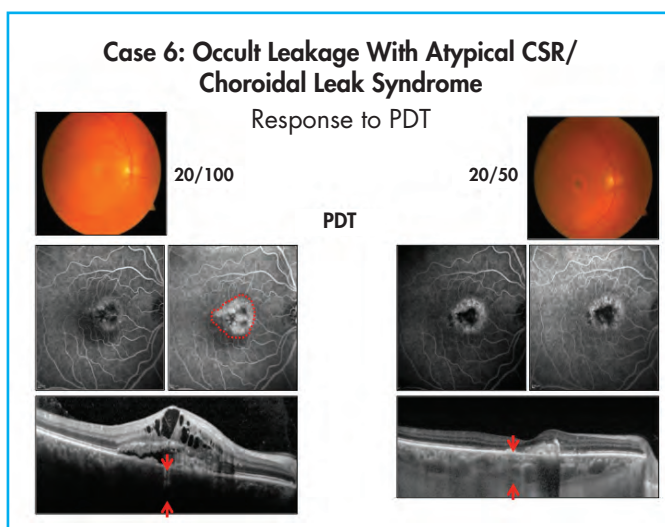
**Dr Kokame:** In my experience, the anatomic findings on ICG often do not correlate with the fundus appearance or the patient's visual status. For this reason, I often base my decision on the appearance of the fundus and the OCT. If the PED has regressed and there is no fluid or leakage, I will often observe without treatment. If there is any residual fluid or any residual leakage, I will use anti-VEGF therapy. If there are new polyps, reperfusion of existing polyps, new bleeding, or recurrence/worsening of PED, I will repeat the ICG and then consider repeat PDT at that point.

## Case 6. Persistent Disease Activity Associated With Atypical Central Serous Retinopathy

**Dr Cousins:** Consider the patient whose clinical imaging results are depicted in **Figure 6**. The patient's visual acuity is 20/100. The fluorescein angiogram reveals an occult lesion. The OCT demonstrates a complex lesion with cystic intraretinal fluid, subretinal fluid, fibrovascular PED, and a very thick choroid by enhanced depth imaging OCT (not shown). ICG angiography shows a few transient hot spots, but does not show a well-formed vascular complex, polypoidal, or retinal angiomatous proliferation type lesion. This patient had not responded to a year of monthly aflibercept. She underwent PDT to the area demarcated on the fluorescein and showed resolution of the intraretinal fluid and subretinal fluid but persistence of the thick choroid. I consider this a case of atypical central serous retinopathy (CSR).

Please describe how atypical cases of CSR deviate from the classic picture.

**Dr Mettu:** Classic and atypical CSR both feature a thick choroid and often have detachment of the neurosensory retina at the macula. Distinctive characteristics of atypical CSR include the presence of an occult leakage pattern on



**Figure 6.** Occult leakage pattern (outlined in red) by fluorescein angiography (FA) (top left and middle left images) and intraretinal fluid, subretinal fluid, subretinal hyperreflective material and a thickened choroid (red arrows) by OCT (bottom left) despite a year of anti-VEGF therapy. Following PDT there was diminished leakage by FA (right middle images), and resolution of intraretinal and subretinal fluid, but persistence of the thick choroid (red arrows) by OCT (bottom right).

fluorescein angiogram as opposed to the well-described leakage patterns (eg, smokestack, hot spot, pooling) found in classic CSR. The OCT is usually different as well, with a shaggy appearance at the detached ellipsoid zone of the outer retina and subretinal hyperreflective material often seen in atypical cases. Occasionally spongiform PED is present, and on clinical examination you may see coarse pigment mottling, which often is not seen in classic CSR.

**Dr Cousins:** How common is this as a cause of PDA?

**Dr Mettu:** In our practice, these cases may represent only 10% to 15% of the population of neovascular AMD patients, but may represent as much as 35% to 40% of PDA cases. These are cases that will manifest persistent subretinal fluid and yet maintain good acuity, often in the 20/40 to 20/60 range.

**Dr Cousins:** There are several potential treatments for this condition.

How do you decide between anti-VEGF therapy, use of a mineralocorticoid receptor antagonist, such as eplerenone<sup>14</sup> or spironolactone,<sup>15</sup> or application of PDT?

**Dr Kokame:** In cases that are clearly CSR with chronic leakage, PDT is my first choice. I will use reduced-fluence PDT.

**Dr Shah:** I suspect that these atypical CSR cases are evolved from lesions that were once classic CSR but now have the features of an occult-type lesion. Anti-VEGF therapy can be ineffective in these patients, as this case illustrates, and PDT can work exquisitely well. One clue to differentiate this from routine AMD is age: these patients are often in the 50 to 54 years age range, which is young for AMD.

**Dr Cousins:** Several small studies have shown that mineralocorticoid receptor antagonism can be effective in reducing fluid in some cases of CSR.<sup>14,15</sup>



Do any of the panelists have experience using this approach for atypical CSR?

**Dr Shah:** It may be effective, but I have not tried it. One concern is the potential for hyperkalemia, so knowledge of the patient's renal function is important.<sup>14</sup> I prefer PDT.

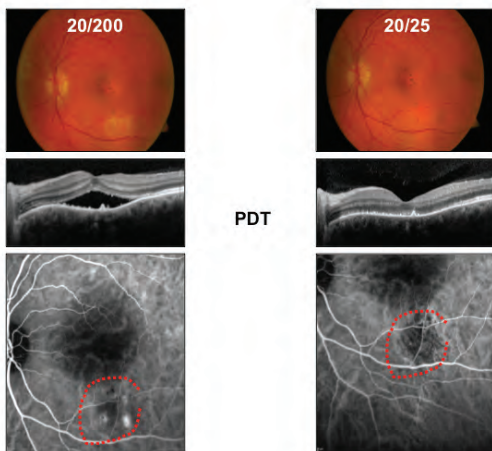
**Dr Mettu:** We have tried eplerenone as an alternative to PDT in several cases. We have seen some success in classic CSR cases but have not seen efficacy in atypical CSR cases. As Dr Shah pointed out, the risk of hyperkalemia is real. I recall 1 patient who had a significant burden of systemic medications and became profoundly hyperkalemic on spironolactone. It may be less of a concern in younger, healthier patients without comorbid systemic disease.

**Dr Cousins:** I do not use these drugs in atypical CSR cases. My approach to these patients is a short trial of anti-VEGF therapy, with a rapid transition to PDT if I see a suboptimal response.

## Case 7. Classic Central Serous Retinopathy

**Dr Cousins:** I recently saw a textbook case of CSR. The patient was a high-strung engineer who came to me for a second opinion. Previously, he had received monthly aflibercept x 12, although he never actually had a fluorescein angiogram. He demonstrated serous macular detachment by OCT. Fluorescein angiogram showed 3 classic enlarging hot spots (Figure 7). ICG angiography confirmed late plaques of choroidal stain. Given that he was frustrated with the monthly injections, which were not making much difference, we immediately performed PDT to the areas of leak identified on the fluorescein angiogram. He had a good response and has not recurred in approximately 2 years.

Case 7: CSR With Serous Macular Detachment



**Figure 7.** A patient with focal pigment mottling (top left), serous macular detachment by OCT (middle left), and choroidal hot spots in the inferior macula by ICG (bottom left). Following PDT, there was resolution of the serous macular detachment (middle right) and vaso-occlusion of the choroidal hot spots (bottom right).

Is there a role for anti-VEGF therapy in classic CSR?

**Dr Kokame:** There would not be a role for this in my practice, because anti-VEGF therapy probably has limited

utility for classic CSR. Classic CSR with an extrafoveal leak can be treated with PDT. In the event that third-party payers do not approve PDT, thermal laser is an established alternative.

**Dr Shah:** The patients I see with classic CSR often already have undergone anti-VEGF therapy—with little effect—before being referred to me. I typically proceed straight to PDT and have not had an issue with approval from insurance companies, but in extrafoveal cases, thermal laser is certainly a reasonable alternative.

**Dr Cousins:** Dr Mettu, when do you consider eplerenone in classic CSR?

**Dr Mettu:** I consider using eplerenone in bilateral or recurrent cases and in younger, healthier patients.

**Dr Cousins:** My approach is to present 3 options—observation, PDT, or eplerenone—and let the patient help me make the decision according to the benefits and risks. If we choose eplerenone, I try to use it for no longer than 3 months.

**Dr Shah:** Not uncommonly, the disease recurs upon discontinuing eplerenone, in which case I proceed to PDT.

## Practical Issues for Using Photodynamic Therapy in Clinical Practice

**Dr Cousins:** We have had a very informative discussion about the various clinical scenarios in which PDT is useful. Let us now consider the nuts and bolts of PDT in clinical practice. We can start with a common scenario.

At an initial visit, you and your patient have decided to proceed with PDT therapy. What happens at that initial visit?

**Dr Mettu:** I prefer to schedule PDT for a subsequent visit. If, however, the patient has traveled a long way, I will try to do the PDT the same day.

**Dr Cousins:** Once you have scheduled the PDT, do you wait and give triple therapy with PDT, anti-VEGF, and steroids all on the same day?

**Dr Shah:** I will give an anti-VEGF injection that day and schedule the PDT and steroid injection for 1 week later.

**Dr Kokame:** We do the opposite. We give the PDT first and then the injections. This is to make sure we have the best visualization possible for delivering the PDT.

**Dr Cousins:** Which steroid do you use?

**Dr Shah:** I use dexamethasone. The goal is to provide short-term anti-inflammatory activity to reduce the risk for serous fluid detachment that occurs post-PDT. A longer-acting steroid, such as triamcinolone, is probably not necessary.

**Dr Mettu:** I tend to use triamcinolone and give it immediately after PDT.

**Dr Cousins:** How long do you tell the patient to stay out of the sun after PDT?

**Dr Kokame:** I tell patients 5 days; the laser day is the first day. The first 3 days are the most important.

**Dr Cousins:** What is your procedure for mapping the area of retina that you will treat with PDT?

**Dr Kokame:** I identify the greatest linear dimension of the lesion on ICG angiography, add 300 microns to this length, and then draw a circle with that diameter around the lesion. That is my treatment strategy.

**Dr Mettu:** I also use the ICG to identify the spot size. Then I map this to the color image, which I use as my treatment guide.

**Dr Cousins:** Who mixes your medicine infusion?

**Dr Kokame:** We do PDT in the hospital, so the same nurses who prepare the oncologic injections also prepare our verteporfin injections.

**Dr Shah:** We use a technician.

**Dr Cousins:** When doing PDT, what kind of lens do you use?

**Dr Kokame:** We use a lens with a 1.5x magnification factor. That is our most common lens. It is very rare that we have to use the lens with a 1.9x magnification factor, which allows you to treat a larger lesion.

**Dr Cousins:** What kind of laser do you use?

**Dr Kokame:** We have the Coherent laser. It has been with us for 15 years now and is still working well. Service is still available for it as well.

**Dr Shah:** Even though these lasers are older, they remain functional, probably because we do not use them as often as we use our thermal lasers.

**Dr Cousins:** What would you recommend to physicians who are reading this and do not have a laser in their practice?

**Dr Kokame:** The first step would be to see if they can get access to a laser in their community, such as a hospital-based laser. A related issue is repairing an existing laser when it goes down—getting parts and finding qualified service technicians can be challenging.

**Dr Cousins:** Would anyone like to share any additional pearls for PDT?

**Dr Shah:** It has been 10 years since PDT was our primary therapy, before the anti-VEGF era. The procedure takes a long time compared with an injection. It can be disruptive to your clinic schedule to do PDT during the day. Therefore, I recommend that we remind our staff just how effective this procedure is for the scenarios we have discussed today. It will be less burdensome to the staff if they understand how beneficial this is for the patient.

**Dr Kokame:** Even in the anti-VEGF area, PDT is an important resource. We tend to reach for anti-VEGF therapy for most of our patients, but it is worth remembering that numerous clinical trials have affirmed the benefit of PDT in these scenarios.

## Conclusion

**Dr Cousins:** The treatment of retinal and choroidal vasculopathies has evolved dramatically over the past 15 years. There is a tendency to abandon older therapies in favor of newer ones. Each treatment, however, has its place. Anti-VEGF therapy has not made our thermal lasers obsolete for retinal diseases such as diabetic macular edema, but it has limited their use to specific clinical situations in which the laser is superior. The same is true for PDT in neovascular AMD and other choroidal diseases. Although it is not typically the preferred therapy, there are some clinical scenarios in which PDT is the superior treatment. We have discussed examples of such scenarios and lesions in this monograph, and we have provided both data from clinical trials and the real-world experiences of a panel of experts. We hope that this educational activity clarifies the specific role of PDT in the modern management of retinal and choroidal vasculopathies, especially neovascular AMD.

## References

1. Bressler NM; Treatment of Age-Related Macular Degeneration with Photodynamic Therapy (TAP) Study Group. Photodynamic therapy of subfoveal choroidal neovascularization in age-related macular degeneration with verteporfin: two-year results of 2 randomized clinical trials—TAP report 2. *Arch Ophthalmol*. 2001;119(2):198-207.
2. Verteporfin In Photodynamic Therapy Study Group. Verteporfin therapy of subfoveal choroidal neovascularization in age-related macular degeneration: two-year results of a randomized clinical trial including lesions with occult with no classic choroidal neovascularization—verteporfin in photodynamic therapy report 2. *Am J Ophthalmol*. 2001;131(5):541-560.
3. Larsen M, Schmidt-Erfurth U, Lanzetta P, et al; MONT BLANC Study Group. Verteporfin plus ranibizumab for choroidal neovascularization in age-related macular degeneration: twelve-month MONT BLANC study results. *Ophthalmology*. 2012;119(5):992-1000.
4. Kaiser PK, Boyer DS, Cruess AF, Slakter JS, Pilz S, Weisberger A; DENALI Study Group. Verteporfin plus ranibizumab for choroidal neovascularization in age-related macular degeneration: twelve-month results of the DENALI study. *Ophthalmology*. 2012;119(5):1001-1110.
5. Ohana E, Blumenkranz MS. Treatment of reopened macular hole after vitrectomy by laser and outpatient fluid-gas exchange. *Ophthalmology*. 1998;105(8):1398-1403.
6. CATT Research Group, Martin DF, Maguire MG, Ying GS, Grunwald JE, Fine SL, Jaffe GJ. Ranibizumab and bevacizumab for neovascular age-related macular degeneration. *N Engl J Med*. 2011;364(20):1897-1908.
7. Comparison of Age-related Macular Degeneration Treatments Trials (CATT) Research Group, Martin DF, Maguire MG, Fine SL, et al. Ranibizumab and bevacizumab for treatment of neovascular age-related macular degeneration: two-year results. *Ophthalmology*. 2012;119(7):1388-1398.
8. Brown DM, Tuomi L, Shapiro H; Pier Study Group. Anatomical measures as predictors of visual outcomes in ranibizumab-treated eyes with neovascular age-related macular degeneration. *Retina*. 2013;33(1):23-34.
9. Ying GS, Kim BJ, Maguire MG, et al; CATT Research Group. Sustained visual acuity loss in the Comparison of Age-Related Macular Degeneration Treatments Trials. *JAMA Ophthalmol*. 2014;132(8):915-921.
10. Rosenfeld PJ, Shapiro H, Tuomi L, Webster M, Elledge J, Blodi B; MARINA and ANCHOR Study Groups. Characteristics of patients losing vision after 2 years of monthly dosing in the phase III ranibizumab clinical trials. *Ophthalmology*. 2011;118(3):523-530.
11. Yannuzzi LA, Sorenson J, Spaide RF, Lipson B. Idiopathic polypoidal choroidal vasculopathy (IPCV). *Retina*. 1990;10(1):1-8.
12. Coppens G, Spielberg L, Leys A. Polypoidal choroidal vasculopathy, diagnosis and management. *Bull Soc Belge Ophthalmol*. 2011;317:39-44.
13. Koh A, Lee WK, Chen LJ, et al. EVEREST study: efficacy and safety of verteporfin photodynamic therapy in combination with ranibizumab or alone versus ranibizumab monotherapy in patients with symptomatic macular polypoidal choroidal vasculopathy. *Retina*. 2012;32(8):1453-1464.
14. Bousquet E, Beydoun T, Zhao M, Hassan L, Offret O, Behar-Cohen F. Mineralocorticoid receptor antagonism in the treatment of chronic central serous chorioretinopathy: a pilot study. *Retina*. 2013;33(10):2096-2102.
15. Herold TR, Prause K, Wolf A, Mayer WJ, Ullbig MW. Spironolactone in the treatment of central serous chorioretinopathy—a case series. *Graefes Arch Clin Exp Ophthalmol*. 2014;252(12):1985-1991.



To obtain *AMA PRA Category 1 Credit™* for this activity, complete the CME Post Test by writing the best answer to each question in the Answer Box located on the Activity Evaluation/Credit Request form on the following page. Alternatively, you can complete the CME Post Test at <http://tinyurl.com/PDTCME>.

See detailed instructions at **To Obtain AMA PRA Category 1 Credit™** on page 2.

1. The mechanism of action of PDT with verteporfin in the treatment of macular lesions includes:
  - A. Photoactivation
  - B. Nitric oxide liberation from tissues
  - C. Focal vascular occlusion within the lesion
  - D. Both A and C
2. Based on the results of several clinical trials and long-term clinical experience, what is the current role of PDT with verteporfin in the management of typical cases of neovascular AMD?
  - A. First-line monotherapy
  - B. First-line therapy in combination with VEGF inhibition
  - C. Adjunctive therapy when first-line VEGF inhibition is inadequate
  - D. Usually avoided because of the risk for acute reduction in visual acuity
3. What percentage of patients with neovascular AMD will show PDA by OCT after 12 months of treatment with anti-VEGF therapy?
  - A. 5% to 10%
  - B. 20% to 30%
  - C. 30% to 50%
  - D. 50% to 80%
4. Which of the following is an important consequence of PDA?
  - A. PDA reduces the responsiveness of the lesion to PDT therapy
  - B. PDA promotes conversion of the lesion from classic to occult
  - C. PDA is associated with worse long-term visual outcomes
  - D. PDA requires imaging with ICG angiography because it cannot be seen on OCT
5. Which of the following is not typically associated with PDA?
  - A. A capillary-type lesion
  - B. An AVC
  - C. PCV
  - D. A serous PED
6. What is the best way to image AVCs?
  - A. OCT
  - B. ICG angiography
  - C. Fluorescein angiography
  - D. Red-free fundus photography
7. Clinical features of PCV include:
  - A. An occult leakage pattern on fluorescein angiography
  - B. "Peaked" PED on OCT
  - C. RPE atrophy
  - D. Both A and B
8. The optimal approach to PDT therapy for serous PED in combination with an AVC is:
  - A. Diffuse therapy to the entire area of the PED
  - B. Targeted therapy to the center of the PED lesion
  - C. Targeted therapy to the base of the new vessel(s)
  - D. PDT should be avoided in serous PED
9. The least effective therapy for chronic classic CSR is:
  - A. Mineralocorticoid receptor antagonism
  - B. Anti-VEGF therapy
  - C. PDT
  - D. Thermal laser
10. All of the following are more common in atypical compared with typical CSR, except:
  - A. Occult lesion morphology
  - B. A shaggy appearance to the ellipsoid zone of the outer retina
  - C. Better presenting visual acuity
  - D. Coarse pigment mottling

Photodynamic Therapy (PDT): What Your Mentor May Not Have Taught You – Helpful Answers for Challenging Patients: Highlights of a CME Roundtable

Original Release Date: April 1, 2015 | Last Review Date: March 2, 2015 | Expiration Date: April 30, 2016

To receive AMA PRA Category 1 Credit™, you must complete this Evaluation form and the Post Test. Record your answers to the Post Test in the Answer Box located below. Mail or Fax this completed page to New York Eye and Ear Infirmary of Mount Sinai–ICME, 310 East 14th Street, New York, NY 10003 (Fax: 212-353-5703). Your comments help us to determine the extent to which this educational activity has met its stated objectives, assess future educational needs, and create timely and pertinent future activities. Please provide all the requested information below. This ensures that your certificate is filled out correctly and is mailed to the proper address. It also enables us to contact you about future CME activities. Please print clearly or type. Illegible submissions cannot be processed.

PARTICIPANT INFORMATION (Please Print) ☐ Home ☐ Office

Last Name \_\_\_\_\_ First Name \_\_\_\_\_  
Specialty \_\_\_\_\_ Degree ☐ MD ☐ DO ☐ OD ☐ PharmD ☐ RPh ☐ NP ☐ RN ☐ PA ☐ Other \_\_\_\_\_  
Years in Practice ☐ ≤5 ☐ 6-15 ☐ 16-25 ☐ Over 25 Institution \_\_\_\_\_  
Street Address \_\_\_\_\_  
City \_\_\_\_\_ State \_\_\_\_\_ ZIP Code \_\_\_\_\_ Country \_\_\_\_\_  
E-mail \_\_\_\_\_ Phone \_\_\_\_\_ Fax \_\_\_\_\_

Please note: We do not sell or share e-mail addresses. They are used strictly for conducting post-activity follow-up surveys to assess the impact of this educational activity on your practice.

Learner Disclosure: To ensure compliance with the US Centers for Medicare and Medicaid Services regarding gifts to physicians, New York Eye and Ear Infirmary of Mount Sinai Institute for CME requires that you disclose whether or not you have any financial, referral, and/or other relationship with our institution. CME certificates cannot be awarded unless you answer this question. For additional information, please call NYEE ICME at 212-979-4383. Thank you.

☐ Yes ☐ No I and/or my family member have a financial relationship with New York Eye and Ear Infirmary of Mount Sinai and/or refer Medicare/Medicaid patients to it.  
☐ I certify that I have participated in the entire activity and claim 1.5 AMA PRA Category 1 Credits™.

Signature Required \_\_\_\_\_ Date Completed \_\_\_\_\_

OUTCOMES MEASUREMENT

☐ Yes ☐ No Did you perceive any commercial bias in any part of this activity? IMPORTANT! If you answered “Yes,” we urge you to be specific about where the bias occurred so we can address the perceived bias with the contributor and/or in the subject matter in future activities.

Circle the number that best reflects your opinion on the degree to which the following learning objectives were met:  
5 = Strongly Agree 4 = Agree 3 = Neutral 2 = Disagree 1 = Strongly Disagree

Upon completion of this activity, I am better able to:

• Demonstrate when photodynamic therapy (PDT) may be appropriate for patients with wet age-related macular degeneration that is resistant to anti-vascular endothelial growth factor therapy	5	4	3	2	1
• Describe the role of indocyanine green angiography in differentiating and diagnosing various forms of neovascularization and exudative diseases	5	4	3	2	1
• Discuss use of PDT in the management of appropriate patients with diagnoses of polypoidal choroidal vasculopathy, central serous retinopathy, and other diseases	5	4	3	2	1

1. Please list one or more things, if any, you learned from participating in this educational activity that you did not already know. \_\_\_\_\_

2. As a result of the knowledge gained in this educational activity, how likely are you to implement changes in your practice?  
4=definitely will implement changes 3=likely will implement changes 2=likely will not implement any changes 1=definitely will not make any changes  
4 3 2 1

Please describe the change(s) you plan to make: \_\_\_\_\_

3. Related to what you learned in this activity, what barriers to implementing these changes or achieving better patient outcomes do you face? \_\_\_\_\_

4. Please check the Core Competencies (as defined by the Accreditation Council for Graduate Medical Education) that were enhanced for you through participation in this activity. ☐ Patient Care ☐ Practice-Based Learning and Improvement ☐ Professionalism  
☐ Medical Knowledge ☐ Interpersonal and Communication Skills ☐ Systems-Based Practice

5. What other topics would you like to see covered in future CME programs? \_\_\_\_\_

ADDITIONAL COMMENTS \_\_\_\_\_

POST TEST ANSWER BOX

1	2	3	4	5	6	7	8	9	10

