

# News in Review

COMMENTARY AND PERSPECTIVE

## Ziv-Aflibercept: Déjà Vu in Retinal Therapy?

**BEFORE INTRAVITREAL RANIBIZUMAB** (Lucentis) was commercially available, U.S. ophthalmologists found a way to use anti-VEGF therapy in the eye: off-label repurposing of its cancer-fighting cousin, bevacizumab (Avastin), to treat choroidal neovascularization.

Now, a similar story is unfolding overseas with the VEGF-blocking intravitreal drug aflibercept (Eylea) and the related cancer chemotherapy agent, ziv-aflibercept (Zaltrap). In countries where aflibercept is unavailable or financially prohibitive, researchers have found early evidence that intravitreal ziv-aflibercept might be a safe and effective alternative to the approved drug.<sup>1-4</sup>

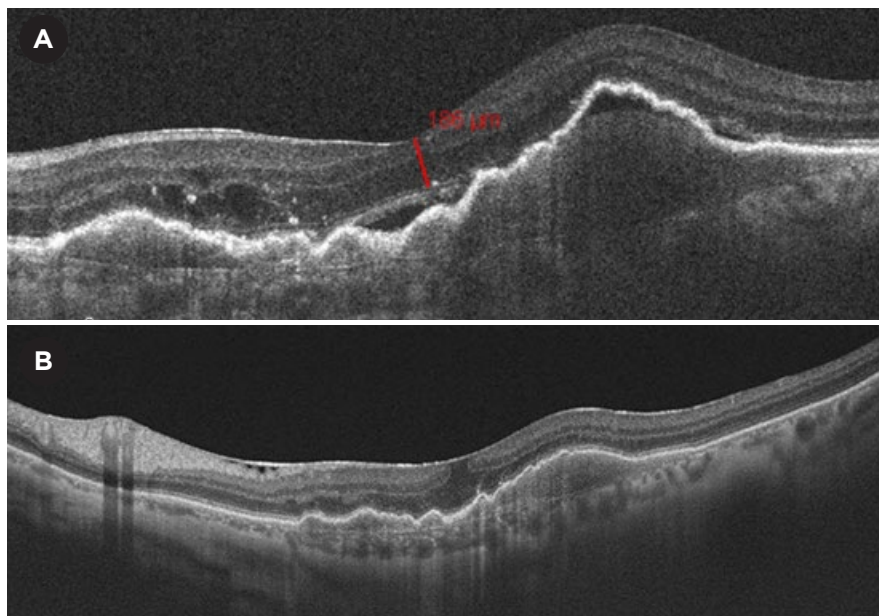
**Clinical experience with ziv-aflibercept.** In Hyderabad, India, researchers at the Smt. Kanuri Santhamma Retina Vitreous Centre of the L.V. Prasad Eye Institute have done hundreds of these off-label injections during the last 2 years, with good clinical outcomes and

without retinal toxicity, inflammation, or other adverse events, said Jay Chhablani, MS, consulting ophthalmologist.

The primary motivation for investigating this option was to help patients who otherwise could

### FURTHER READING.

For a complete list of references, see this article at [www.aao.org/eyenet](http://www.aao.org/eyenet).



**BEFORE AND AFTER.** (A) Spectral-domain optical coherence tomography scans of an eye with polypoidal choroidal vasculopathy showing presence of subretinal fluid and PED. (B) After 2 monthly intravitreal injections of ziv-aflibercept (1.25 mg/0.08 mL), visual acuity improved from 20/125 to 20/60, with resolution of subretinal fluid and decrease in height of PED.

not afford therapy with the approved medication, Dr. Chhablani said.

“In our country, patients generally have to pay out of their pocket for anti-VEGF injections, and Eylea is very expensive, even compared with Lucentis. It is almost double the cost of Lucentis,” he said.

In Brazil, researchers are studying ziv-aflibercept for treating refractory age-related macular degeneration and diabetic macular edema. They reported positive outcomes at the Academy’s 2015 Retina Subspecialty Day<sup>5</sup> and in papers published over the last 2 years.

**How it’s used.** For off-label intravitreal administration, standard ziv-aflibercept vials can be divided into 1.25 mg/0.05 mL aliquots without further mixing or dilution, thus avoiding risks associated with those processes, as reported by Dr. Chhablani and col-

leagues in case studies published since mid-2015.<sup>1-4</sup>

As Zaltrap, ziv-aflibercept is approved for intravenous use in the United States and Europe to treat patients with metastatic colorectal cancer. The prepackaged vials of Eylea and Zaltrap contain identical concentrations of the same active drug, a fusion protein that inhibits 3 molecules in the angiogenic VEGF family. However, the Eylea formulation is iso-osmolar, and the Zaltrap solution is hyperosmolar (1,000 mOsm/L), relative to the vitreous.

**Safety concerns.** Critics commonly express concern about the potential impact of the higher osmolarity, Dr. Chhablani said. “Everybody has been worried about the osmolarity issue, but we have extensive experience with this now, and we did not find any problems. We reported the safety of 1.25 mg/0.05 mL

in human eyes with no retinal toxicity after a single injection. We have given more than 350, perhaps as many as 500, injections, and we have never seen a problem,” he said.

**Looking ahead.** Larger, longer-term studies are necessary to confirm the safety and effectiveness of intravitreal ziv-aflibercept therapy, especially with multiple injections, Dr. Chhablani said. Furthermore, this off-label use is not likely to spread beyond poorer countries like India, where the lack of government insurance coverage puts the approved drug beyond the reach of most patients who need it, he said.

“There are definitely some patients, such as those with large pigmented epithelial detachments [PED] or polypoidal choroidal vasculopathy [PCV], and patients who are not responding to Avastin or Lucentis, who would benefit from this alternative therapy,” he said. “These are the types of patients whom we now are injecting with ziv-aflibercept, equally with aflibercept.”

—Linda Roach

1 Mansour AM et al. *Br J Ophthalmol*. Published online March 30, 2016. doi:10.1136/bjophthalmol-2015-308319.

2 Mansour AM et al. *Br J Ophthalmol*. Published online May 17, 2016. doi:10.1136/bjophthalmol-2016-308679.

3 Chhablani J et al. *Retina*. 2016;36(6):1126-1131.

4 Mansour AM et al. *Br J Ophthalmol*. 2015;99(8):1055-1059.

5 Farah ME. Intravitreal Ziv-Aflibercept. Presented at: AAO Retina Subspecialty Day; Nov. 13, 2015; Las Vegas.

**Relevant financial disclosures:** Dr. Chhablani—None.

## CATARACT CONUNDRUM

# IOL Errors Persist Despite Checklists

### A REVIEW OF NATIONAL HEALTH

Service (NHS) data in the United Kingdom shows that wrong intraocular lens (IOL) implantation still occurs, despite the introduction of surgical checklists designed to prevent this mistake.<sup>1</sup>

Human factors are mostly to blame, according to the British researchers who studied patient safety incidents (PSIs) involving IOLs.

“In the U.K., cataract surgery carries a greater risk of inserting a wrong implant than any other procedure requiring an implant,” said lead author Laura R. Steeples, MBChB Hons, FRCOphth, consultant ophthalmic surgeon, at Manchester Royal Eye Hospital.

Although this retrospective review involved PSIs reported in England and Wales, Dr. Steeples said, “Wrong IOL implants are a global problem.” An analysis of errors at the Veterans Health Administration confirms a similar problem in the United States.<sup>2</sup>

**A closer look at IOL errors.** The authors considered 178 wrong IOL incidents reported between 2010 and 2014. They compared these incidents with previously analyzed occurrences from 2003 through 2010. They wanted to assess whether causation of errors had changed following significant patient safety initiatives and the implementa-

## REFRACTIVE PATIENT OUTCOMES

# LASIK Satisfaction vs. Contact Lenses

Three years after undergoing LASIK, patients were substantially happier with this choice of surgical correction than a comparative group of patients who opted for contact lenses (CL) during the same time period, a large longitudinal study has found.<sup>1</sup>

Surveys of 1,800 patients at 20 sites across the United States revealed that 88% of former CL wearers and 77% of former glasses wearers were strongly satisfied with LASIK at year 3. In a control group of continued CL wearers, 54% expressed strong satisfaction with their current vision correction method after 3 years.

The data not only supported LASIK surgeons' clinical impressions about their patients' satisfaction rates but also unearthed 2 surprises, said coauthor Francis W. Price Jr., MD, who heads the Price Vision Group in Indianapolis.

**Surprise findings.** “I was surprised to see that LASIK dramatically improved the ease of night driving not only for [former] contact lens wearers but also for those who wore glasses,” Dr. Price said. “I think too often we assume that glasses prescriptions provide

perfect vision. However, anyone who wears glasses knows that there are visual disturbances and inconveniences with wearing them.

“The other welcome surprise was that for those who had worn contact lenses, dry eye symptoms were no worse 1 year after LASIK and improved over the 3-year follow-up period,” he said.

**Compared against CL correction—not against a perfect eye.** Dr. Price pointed to the study's unique design—with contact lens wearers as the control group—as one of its key strengths.

“At the time we put this study together, LASIK was being criticized by a small group of people who, rightfully or not, blamed LASIK for any visual problems they had or depression they felt. LASIK was being compared to perfection instead of to alternative treatments for visual errors,” he said. “Therefore, we felt it was important to see how LASIK patients compared with a control group using another popular form of visual correction, such as contact lenses.” —Linda Roach

1 Price MO et al. *Ophthalmology*. 2016;123(8):1659-1666.

**Relevant financial disclosures:** Dr. Price—Calhoun Vision: O; Haag-Streit: C; Interactive Medical Publishing: O; Revital-Vision: O; Staar Surgical: C; Strathspay Crown: O; TearLab: O; Transcend Medical: C.

tion of surgical checklists in 2010.

At a minimum, the authors expected to see a reduction in mistakes involving matching data with the correct patient or eye. They also anticipated seeing fewer team communication errors. “We were surprised by how many mistakes [n = 26] involved incorrect transcription of the selected IOL to other sources and subsequent failure to refer to original source documents,” Dr. Steeples said.

**Complex causation.** Errors occurred at every stage, from preoperative (biometry or transcription error) to intraoperative (changes in planned procedure) to perioperative (handwriting misinterpretations and wrong IOL brought into the operating room).

The NHS considers these incidents to be “never events,” defined by the U.K. National Patient Safety Agency as “serious, largely preventable patient safety incidents that should not occur if the available preventative measures have been implemented.” Yet they are difficult to eliminate. “The selection and implantation of the correct IOL is a complex process involving multiple team members, with numerous potential sources of error,” Dr. Steeples said. “The current safety processes do not protect against mistakes cascading through the pathway, resulting in wrong IOL implantation.”

Among other findings:

- Misfiling of the biometric data in the wrong patient notes was reported in far more incidents after 2010 (21/178) than in the earlier period analyzed (4/164).
- Changes in planned procedure created a vulnerable stage for mistakes.
- Mistakes involving electronic medical records were a new source of error (n = 17).
- The cause of 44 PSIs was unknown, leading the authors to recommend more thorough error reporting.
- IOL exchange surgery was reported in 45 cases.

**Better preparation is key.** To minimize error, the authors recommend simulation training to better prepare medical teams for real patient en-

counters. “The actions, behaviors, and communication skills of the surgical team are key to the success of surgical checklists and safety processes to ensure correct IOL implantation,” Dr. Steeples said. “Simulation training is important for teams to train together to enhance communication and build more robust systems.” —*Miriam Karmel*

1 Steeples LR et al. *Eye*. Published online May 13, 2016. doi:10.1038/eye.2016.87.

2 Neily J et al. *J Patient Saf*. Published online March 16, 2015.

Relevant financial disclosures: Dr. Steeples—None.

## CORNEA ADVANCES

# Fewer Keratoplasties After CXL Adoption

**LAST SPRING, THE FDA GRANTED** approval of corneal cross-linking (CXL) for progressive keratoconus (KC), which affects 1 in every 2,000 Americans.<sup>1</sup> Will this new treatment decrease the number of corneal transplants (keratoplasties), which have been needed in up to 20% of patients whose disease progresses to advanced stages?<sup>1</sup> Data from the Dutch National Organ Transplant registry suggest that there may be good news on the American horizon.<sup>2</sup>

**Marked decrease in transplants.** A nationwide study in the Netherlands found a 25% reduction in keratoplasties performed for KC during the 3-year period after implementation of CXL (2012 through 2014) compared with a 3-year period before its introduction (2005 through 2007)—results that were consistent with an earlier local study by Sandvik et al.<sup>3</sup> In the Netherlands, there were 269 corneal transplants in eyes with KC in the 3-year study period before introduction of CXL, but in the later study period, the number declined to 201.

“Given the observational nature of the study, we cannot be absolutely certain about the causal relationship

between the number of cross-linking treatments and the reduction in transplants,” said lead author Daniel A. Godefrooij, MD, at the University Medical Center Utrecht, the Netherlands. “However, we did everything possible to test our assumptions,” he said. These were the 3 assumptions: that the lower number of keratoplasties was unlikely to be explained simply by a decrease in the prevalence of KC, that the indication for performing keratoplasty did not change between the 2 study periods, and that the preventive effect of CXL would be detectable within several years.

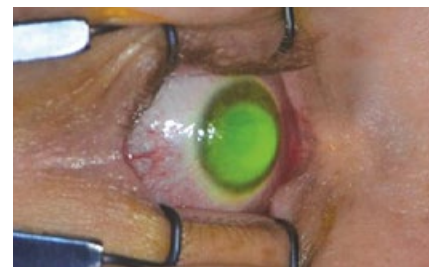**Better for patients.** In fact, with a greater number of cross-linking procedures performed and more time to observe patients following these procedures, said Dr. Godefrooij, it is possible that the reduction in keratoplasties could be even greater than that found in this study. Regardless, he said, the ability to avoid the more invasive procedure of corneal transplantation—or to simply arrest the progression of corneal ectasia—is incredibly valuable for patients. And it’s accomplished using a procedure shown to be safe, minimally invasive, and effective. —*Annie Stuart*

1 National Keratoconus Foundation. [www.nkcf.org/about-keratoconus/](http://www.nkcf.org/about-keratoconus/). Accessed June 28, 2016.

2 Godefrooij DA et al. *Acta Ophthalmol*. Published online May 23, 2016. doi:10.1111/aos.13095.

3 Sandvik GF et al. *Cornea*. 2015;34(9):991-995.

Relevant financial disclosures: Dr. Godefrooij—None.



**CROSS-LINKING.** New data from the Netherlands show a substantial reduction in the number of keratoplasties for KC after adoption of CXL.

See the financial disclosure key, page 8. For full disclosures, including category descriptions, view this News in Review at [www.aao.org/eyenet](http://www.aao.org/eyenet).