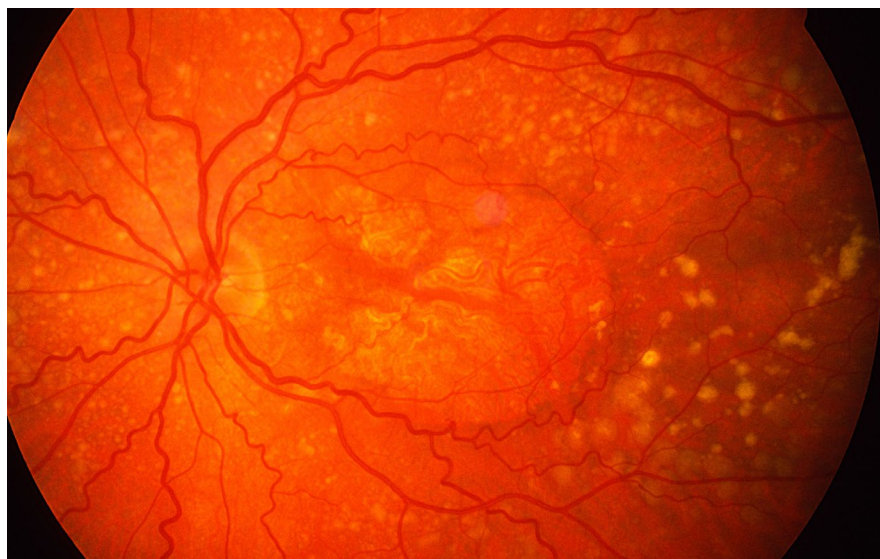

# News in Review

COMMENTARY AND PERSPECTIVE

*THIS MONTH, NEWS IN REVIEW highlights selected papers from the original papers sessions at AAO 2020 Virtual. Each was chosen by the session chairs because it presents important news or illustrates a trend in the field. For details of presentation times, check the Virtual Meeting Guide at either [aao.org/2020](http://aao.org/2020) or in the virtual meeting platform.*



## RETINA

### RPE Cell Transplants for Dry AMD

**IN A PHASE 1/2A CLINICAL TRIAL,** cultured retinal pigment epithelial (RPE) cells were successfully transplanted into patients with advanced dry age-related macular degeneration (AMD).<sup>1</sup>

Implanted subretinally, the human embryonic stem cell–derived RPE cells (OpRegen, Lineage Cell Therapeutics) were well tolerated. The initial cohorts showed evidence of improved structural changes during up to four years of follow-up, said Christopher D. Riemann, MD, at the University of Cincinnati and the Cincinnati Eye Institute.

“We’ve done 18 patients so far, and the OpRegen cells have a clear safety signal. We’ve also got anatomic [evidence of] slower progression of the geographic atrophy, resolution of drusen, and restoration of outer retinal and RPE anatomy,” Dr. Riemann said. “Both structural and functional data suggest a substantive and important potential signal of efficacy.”

**Initial safety trial.** In the first 15 eyes treated, pars plana vitrectomy and retinotomy were performed in order to inject a suspension of 50,000 to 200,000 cells subretinally, Dr. Riemann said. The stem cells used in the trial came from an ethically sourced, federally approved, 20-year-old cell line derived from embryos that were abandoned following in vitro fertilization.

With regard to adverse events, 13 of the 15 eyes developed macular fibrosis or macular pucker. Serious ocular adverse events included one severe epiretinal membrane (ERM) and one retinal detachment, both of which required surgical repair, Dr. Riemann said.

Persistent subretinal pigmentation was visible in most of these eyes in the area where the cells were implanted. “We think this actually represents the sustained cells that have survived,” he said.

**Next steps.** In the ongoing trial’s latest study cohort, which comprises 12 patients, those with better visual acuity (20/64 to 20/200) are being enrolled, Dr. Riemann said. “We’re looking at eyes that have better vision [than did those in the safety trial], in hopes of

**DRY AMD.** Multiple drusen, RPE changes, and geographic atrophy are evident in this patient with dry AMD.

picking up on some sort of improved visual acuity signal after treatment,” he said. Patients in the safety trial had advanced AMD and were legally blind.

The investigators also are testing the use of a new flexible cannula infuser—Orbit SDS (Gyroscope Therapeutics)—that they hope will reduce the risk of procedural complications by eliminating the need for vitrectomy and retinotomy. Dr. Riemann said the researchers have already performed three OpRegen transplants using the Orbit SDS with excellent results and no ERM formation.

He added that the group is excited by initial indications that the nonvitrectomy approach may have solved the ERM issue seen in the initial cohort. The group hopes to have completed several procedures with the device by the time of AAO 2020 Virtual to corroborate this finding.

“The first thing we have to figure out is whether implanting these RPE cells really works as well as the early data

may suggest,” he said. “Then we would want to ask, ‘If one bleb is good, are two or more blebs better?’ Because one of the exciting things is that, in animals, I’ve personally been able to create up to nine blebs in one eye with a single incision and a single Orbit SDS device.”

—Linda Roach

1 Riemann CD et al. Phase 1/2a study of sub-retinally transplanted human embryonic stem cell–derived RPE cells in advanced dry-form AMD patients. Presented at: AAO 2020 Virtual; Nov. 13-15, 2020.

**Relevant financial disclosures**—Dr. Riemann: BioTime/Lineage: C,S; Gyroscope Therapeutics: C,S; Janssen/Johnson & Johnson: C; Orbit Biomedical: C.

## CORNEA

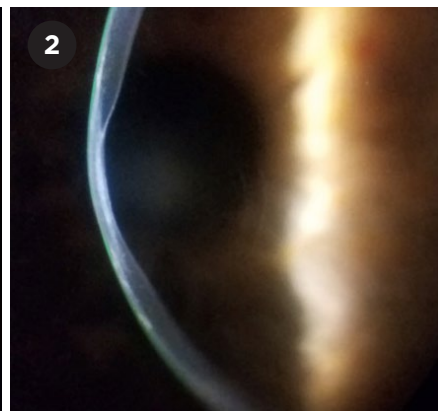
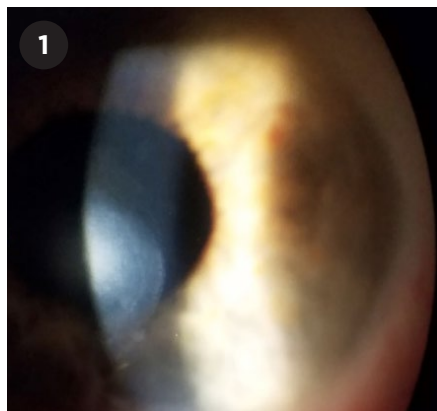
# AI Meets Cornea Diseases

**ARTIFICIAL INTELLIGENCE CAN NOW** be used to help detect the most common cornea diseases. A deep learning algorithm, which uses anterior segment optical coherence tomography (AS-OCT), has been developed to simultaneously screen for keratoconus (KC), dry eye syndrome (DES), and Fuchs endothelial dystrophy (FED). In a study at Bascom Palmer Eye Institute in Miami, it performed nearly as well as cornea specialists.<sup>1</sup>

“This is the first deep learning multi-disease algorithm for the autonomous diagnosis of common cornea diseases with significant morbidity and economic burden,” said Mohamed Abou Shousha, MD, PhD, at Bascom Palmer in Miami.

**Teaching the machine to classify.** For this prospective study, the researchers created a dataset of 158,220 AS-OCT images. The researchers then trained the algorithm using 134,460 of those images; the images were obtained from 747 eyes that were either healthy or diagnosed with KC, DES, or FED. In addition, they tested the model in a second clinical study, using 23,760 images of 132 eyes that had not been diagnosed by the study’s cornea specialists.

**High specificity and sensitivity.** Overall, the algorithm was able to both



**POSTERIOR KERATOCONUS.** (1) Stromal opacity associated with (2) posterior excavation of the cornea in the visual axis.

accurately diagnose KC, DES, and FED and confirm the lack of cornea disease in healthy eyes. It had sensitivity values ranging from 93% to 100% and specificity values  $\geq 96\%$ .

However, while the algorithm was able to distinguish between diseased and healthy corneas, it didn’t always agree with the experts’ clinical diagnoses. It made seven diagnostic errors in the independent clinical study. Those included five diagnoses that confused dry eye and healthy eyes; one in which dry eye was misclassified as keratoconus; and one in which an eye with keratoconus was misclassified as healthy. This misclassification of keratoconus was the only error considered to be serious, said Dr. Shousha. However, the algorithm correctly diagnosed keratoconus in the other eye of the same patient, so the diagnostic error presumably would have been caught on referral.

**A win-win.** “These autonomous diagnostic algorithms can allow non-specialists to detect disease with a sensitivity approximating that of a specialist,” said Dr. Shousha, who plans to file for FDA approval of the algorithm. “Using such algorithms translates into patients who will be diagnosed and referred early enough for care to prevent irreversible vision loss.”

—Miriam Karmel

1 Shousha MA et al. Multidisease deep learning neural network for the diagnosis of corneal diseases. Presented at: AAO 2020 Virtual; Nov. 13-15, 2020.

**Relevant financial disclosures**—Dr. Shousha:

NEI; S; Research to Prevent Blindness; S; Resolve Ophthalmics; O. Related patents and PCT are owned by the University of Miami and licensed to Resolve Ophthalmics.

## GLAUCOMA

# Omidenepag Eye-drops Lower IOP in Real-World Setting

**A JAPANESE MANDATORY POST-**marketing observational study has confirmed the safety and efficacy of omidenepag isopropyl ophthalmic solution 0.002% (OMDI), a topical drug used to treat elevated intraocular pressure (IOP) in patients with glaucoma or ocular hypertension.<sup>1</sup>

Two years ago, OMDI (Eyebelis, Santen) received the first global approval in Japan, based on results from phase 3 clinical trials.<sup>2</sup> In this observational study, conducted in a real-world setting, researchers report significant IOP lowering effects and no significant safety concerns. “These results will enhance the proper use of this drug for glaucoma patients,” said Toru Nakazawa, MD, PhD, at Tohoku University School of Medicine in Sendai City, Japan.

**Mechanism of action.** Although OMDI is not a prostaglandin, it binds selectively to the prostaglandin EP2 receptors, and it increases the pathway of aqueous humor outflow through both the trabecular and uveoscleral outflow pathways.

“In the clinical trials, OMDI showed noninferior IOP reduction compared

to latanoprost and timolol,” Dr. Nakazawa said. “And it showed no specific adverse reactions commonly found in prostaglandin analogs, like eyelid/iris pigmentation or deepening of upper eyelid sulcus.”<sup>2</sup>

The earlier clinical trials also found OMDI to be safe and effective as an adjunct to beta blockers; in addition, it was shown to be safe and effective for patients who do not respond well to latanoprost ( $\leq 15\%$  IOP reduction).

**Observational study.** The latest findings are based on a review of the medical records of 981 patients at hospitals and clinics throughout Japan. Of the patients evaluated, 32.8% had primary open-angle glaucoma, 59.1% had normal tension glaucoma, and 5.2% had ocular hypertension naive to treatment.

On average, the patients experienced a reduction in IOP from a baseline of 16.6 mm Hg to 13.8 mm Hg at seven months. They will continue to be observed for 12 months, Dr. Nakazawa said.

A total of 167 patients (17.0%) experienced adverse reactions. Although most adverse effects were not serious, one case of macular edema was observed. (In the clinical trials of the drug, aphakic or pseudophakic patients had an increased risk of developing macular edema.)

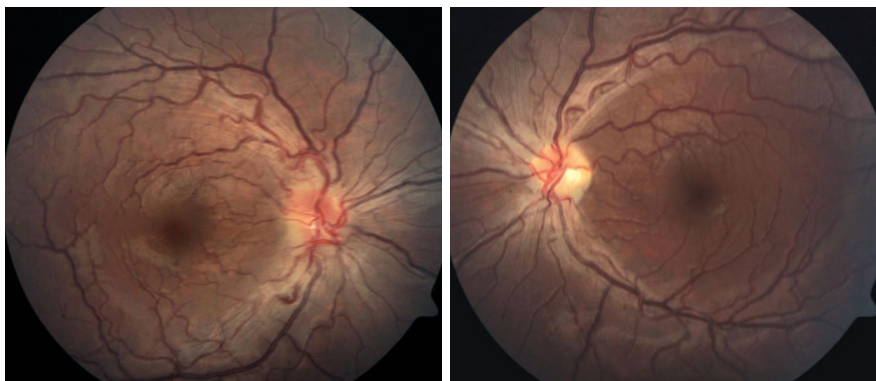
**What’s next.** This postmarketing study will run to 2022, with a target of 3,900 patients. “In the near future, we will be able to analyze this study data with a larger patient population,” Dr. Nakazawa said. “This may possibly reveal more detailed safety information, including risk factors for both identified safety concerns and unexpected adverse reactions, which might not have been detected earlier.”

—Miriam Karmel

1 Nakazawa T et al. Safety and efficacy of omide-nepag isopropyl in multicenter observational study in Japan—interim result. Presented at: AAO 2020 Virtual; Nov. 13-15, 2020.

2 Duggan S. *Drugs*. 2018;78(18):1925-1929.

**Relevant financial disclosures**—Dr. Nakazawa: Canon; S; Daiichi-Sankyo; S; Kowa; S; Nidek; S;



**YOUNG PATIENT WITH LHON.** Fundus photographs in this 17-year-old patient show hyperemic optic discs with blurred margins and moderately tortuous vasculature. The left optic disc shows mild temporal pallor.

Rhoto Pharmaceutical; S; Santen; C,L,S; Senju Pharmaceutical; C,L,S; Tomey; S; Topcon; S; Wakamoto Pharmaceutical; S.

## NEURO-OPHTHALMOLOGY

# Promising Results for Gene Therapy in LHON

**TWO YEARS AFTER A SINGLE GENE** therapy injection, patients with Leber hereditary optic neuropathy (LHON) have experienced significant visual improvement.<sup>1</sup>

**Two clinical trials.** In the two randomized sham-controlled phase 3 trials known as RESCUE and REVERSE, 76 patients with LHON received a single unilateral, intravitreal injection of an adeno-associated viral vector, rAAV2/2-ND4 (Lumevoq, GenSight Biologics). They also received a simulated sham injection in their fellow eyes, said Patrick Yu-Wai-Man, MD, PhD, at the University of Cambridge, Moorfields Eye Hospital, and the University College London Institute of Ophthalmology.

The RESCUE trial evaluated patients who had onset of vision loss up to six months before treatment; the REVERSE trial evaluated those who experienced vision loss six to 12 months before treatment. The viral vector carries a replacement for the mitochondrial ND4 gene. When defective, this gene leads to rapid loss of retinal ganglion cells because of mitochondrial dysfunction;

this is followed by degeneration of the optic nerves with visual failure.

**VA outcomes.** Visual acuity (VA) in the treated eyes improved by 26 EDTRS letters from the worst measured vision in the early-treatment group and by 28 letters in the late-treatment group, Dr. Yu-Wai-Man said. “The improvement that we observed is more than what would be expected based on the natural history of untreated patients,” he said.<sup>2</sup>

However, both the RESCUE and REVERSE trials produced an unexpected finding: The untreated contralateral eyes had VA gains comparable to those of the treated eyes.<sup>3</sup> Two other LHON gene therapy research groups, in Miami and in Wuhan, China, have also reported this bilateral effect in their studies. Dr. Yu-Wai-Man will discuss possible reasons for this bilateral improvement in his AAO 2020 Virtual presentation.

**European marketing.** In September, GenSight Biologics submitted a marketing application for Lumevoq to the European Medicines Agency. To date, nearly 200 patients have been treated with the viral vector through trials and compassionate-use exceptions.

—Linda Roach

1 Yu-Wai-Man P et al. Efficacy of gene therapy for Leber hereditary optic neuropathy: Final results of the phase 3 RESCUE and REVERSE trials. Presented at: AAO 2020 Virtual; Nov. 13-15, 2020.

2 Newman NJ et al. *J Neuroophthalmol*. In press.

3 Yu-Wai-Man P et al. *Sci Transl Med*. In press.

**Relevant financial disclosures**—Dr. Yu-Wai-Man: GenSight Biologics; C.