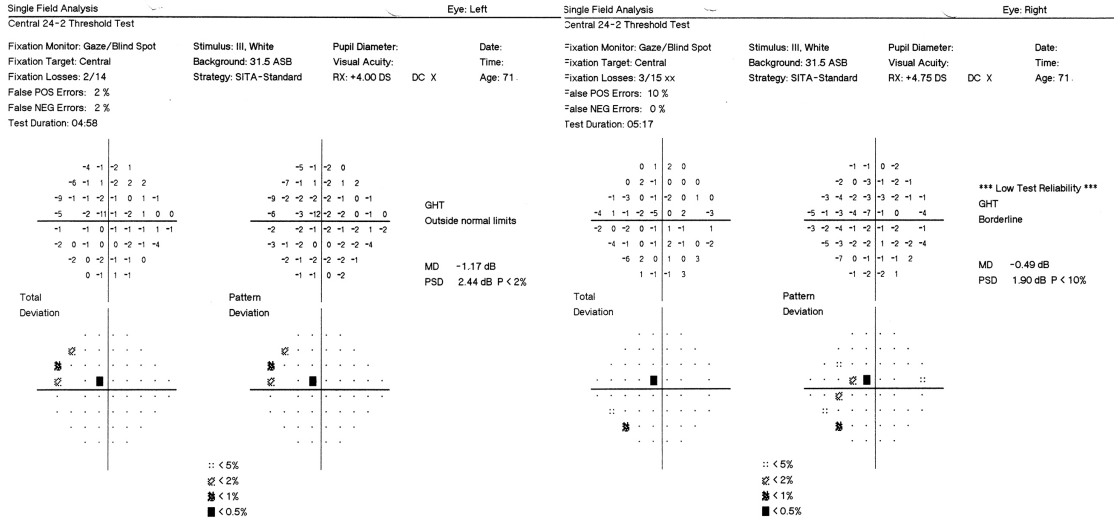


MYSTERY IMAGE  
BLINK



WHAT IS THIS MONTH'S MYSTERY CONDITION? Visit [aoa.org/eyenet](http://aoa.org/eyenet) to make your diagnosis in the comments.

LAST MONTH'S BLINK

# Occult Foreign Body of the Conjunctival Fornix

**A** 3-year-old boy with neurofibromatosis type I presented with a one-year history of right upper lid edema, ptosis, and a small nodule located superonasally. The nodule, which was nontender, soft, and mobile, had been treated as a presumed chalazion. Because of persistence of the nodule and higher location than expected for chalazion, an MRI of the brain and orbits was obtained; this demonstrated a 6- × 7- × 10-mm hypointense mass with sharply defined angles concerning for a man-made foreign body.

Examination under anesthesia revealed a dark-colored foreign body. This was gently removed with forceps and found to extend deep into the fornix. The underlying conjunctiva was thickened but without lacerations. The identity of the foreign body remains unknown.

An occult foreign body should be considered in young children presenting with atypical eyelid masses.

WRITTEN BY MELANIE DAULTON, MD, SAMEERA NADIMPALLI, MD, PRAVEEN JEYASEELAN, MD, JANICE LASKY ZEID, MD, AND BAHRAM RAHMANI, MD. PHOTOS BY MELANIE DAULTON, MD. ALL ARE AT NORTHWESTERN UNIVERSITY, FEINBERG SCHOOL OF MEDICINE, CHICAGO.

