



AMERICAN ACADEMY
OF OPHTHALMOLOGY®

Protecting Sight. Empowering Lives.®

Corneal Ectasia Preferred Practice Pattern®

Secretary for Quality of Care
Roy S. Chuck, MD, PhD

Academy Staff
Andre Ambrus, MLIS
Meghan Daly
Flora C. Lum, MD

Medical Editor: Susan Garratt

Approved by: Board of Trustees
September 22, 2023

© 2023 American Academy of Ophthalmology®
All rights reserved

AMERICAN ACADEMY OF OPHTHALMOLOGY and PREFERRED PRACTICE PATTERN are registered trademarks of the American Academy of Ophthalmology. All other trademarks are the property of their respective owners.

Preferred Practice Pattern® guidelines are developed by the Academy's H. Dunbar Hoskins Jr., MD Center for Quality Eye Care without any external financial support. Authors and reviewers of the guidelines are volunteers and do not receive any financial compensation for their contributions to the documents. The guidelines are externally reviewed by experts and stakeholders before publication.

Correspondence:
Andre Ambrus, MLIS, American Academy of Ophthalmology, P. O. Box 7424, San Francisco, CA 94120-7424. E-mail: aambrus@ao.org.

CORNEA/EXTERNAL DISEASE PREFERRED PRACTICE PATTERN® DEVELOPMENT PROCESS AND PARTICIPANTS

The **Cornea/External Disease Preferred Practice Pattern Panel** members wrote the Corneal Ectasia Preferred Practice Pattern guidelines (PPP). The PPP Panel members discussed and reviewed successive drafts of the document, meeting in person twice and conducting other review by e-mail discussion, to develop a consensus over the final version of the document.

Cornea/External Disease Preferred Practice Pattern Panel 2022–2023

Vishal Jhanji, MD, FRCS, FRCOphth
 Sumayya Ahmad, MD, Methodologist
 Guillermo Amescua, MD
 Albert Y. Cheung, MD
 Daniel S. Choi, MD
 Amy Lin, MD
 Shahzad I. Mian, MD
 Michelle K. Rhee, MD
 Elizabeth T. Viriya, MD
 Francis S. Mah, MD, Co-chair
 Divya M. Varu, MD, Co-chair

The **Preferred Practice Patterns Committee** members reviewed and discussed the document during a meeting in June 2023. The document was edited in response to the discussion and comments.

Preferred Practice Patterns Committee 2023

David K. Wallace, MD, MPH, Chair
 Christina J. Flaxel, MD
 Steven J. Gedde, MD
 Deborah S. Jacobs, MD
 Francis S. Mah, MD
 Kevin M. Miller, MD
 Thomas A. Oetting, MD
 Divya M. Varu, MD
 David C. Musch, PhD, MPH, Methodologist

The Corneal Ectasia PPP was sent for review in July 2023 to improve the quality of the guideline, to gather feedback on the draft recommendations, and to assess feasibility for and applicability to the target audience, including assessing the facilitators and barriers to implementing recommendations (e.g., U.S. ophthalmologists and other important groups, including patients, other physicians, international ophthalmologists, research organizations, ophthalmological organizations, and experts in the field). The PPP was sent for review to the following patient organizations to solicit the views and preferences of patients and the public: Consumers United for Evidence-Based Healthcare, American Foundation for the Blind, Foundation Fighting Blindness, Lighthouse Guild, National Federation of the Blind, and Prevent Blindness. All those who were returning comments were required to provide disclosure of relevant relationships with industry to have their comments considered (indicated with an asterisk below). Members of the Cornea/External Disease Preferred Practice Pattern Panel reviewed these comments and determined revisions to the document.

Academy Reviewers

Board of Trustees and Committee of Secretaries*
 Council
 General Counsel*
 Ophthalmic Technology Assessment Committee
 Cornea/External Disease Panel

Basic and Clinical Science Course Section 8

Subcommittee*

Practicing Ophthalmologists Advisory Committee for Education*

Invited Reviewers

American College of Surgeons, Advisory Council for Ophthalmic Surgery*
American Foundation for the Blind
American Ophthalmological Society*
American Society of Cataract & Refractive Surgery
American Uveitis Society*
Asia Cornea Society*
Association for Research in Vision and Ophthalmology
Association of University Professors of Ophthalmology
Canadian Ophthalmological Society
Consumers United for Evidence-Based Health Care
Cornea Society*

Foundation Fighting Blindness
International Council of Ophthalmology
International Society of Refractive Surgery
Lighthouse Guild
National Eye Institute
National Federation of the Blind
National Medical Association, Ophthalmology Section
Ocular Microbiology and Immunology Group
Prevent Blindness
Women in Ophthalmology
Robert S. Feder, MD*
Jeanine Baqai, MD

This guideline will be formally re-evaluated and updated on a 5-year cycle in 2028. A Summary Benchmark is a resource to facilitate application of the guideline and to provide criteria that could be used to measure the application of recommendations, which will be available to all at www.aao.org/ppp.

FINANCIAL DISCLOSURES

There is no external funding, including industry/commercial support, for the development of this PPP or for the distribution of the guidelines. The Academy has fully funded the development of this PPP, and the views or interests of the Academy have not influenced the final recommendations, which are based on evidence from systematic reviews. All those individuals significantly involved in the guideline development process, including guideline panel members, PPP Committee members, Secretary for Quality of Care, and Academy Staff, have declared competing/financial interests through a financial interest disclosure process as well as an assessment of the Open Payments website (available at <https://openpaymentsdata.cms.gov/>). The interests of the guideline panel members are provided at the beginning of each meeting and those with competing interests in a guideline topic do not participate in voting on areas of disagreement. In compliance with the Council of Medical Specialty Societies' Code for Interactions with Companies (available at <https://cmss.org/code-for-interactions-with-companies/>), relevant relationships with industry are listed. As per CMSS code, direct financial relationships with companies do not include food and beverages, research funds paid to the institution, and relationships outside of the topic of the PPP. The Academy has Relationship with Industry Procedures to comply with the Code (available at www.aao.org/about-preferred-practice-patterns). A majority (82%) of the members of the Cornea/External Disease Preferred Practice Pattern Panel 2022–2023 had no direct financial relationships to disclose.

Cornea/External Disease Preferred Practice Pattern Panel 2022–2023

Vishal Jhanji, MD, FRCS, FRCOphth: No financial relationships to disclose

Sumayya Ahmad, MD: No financial relationships to disclose

Guillermo Amescua, MD: No financial relationships to disclose

Albert Y. Cheung, MD: No financial relationships to disclose

Daniel S. Choi, MD: Glaukos Corporation—Lecture Fees

Amy Lin, MD: No financial relationships to disclose

Shahzad I. Mian, MD: No financial relationships to disclose

Michelle K. Rhee, MD: No financial relationships to disclose

Elizabeth T. Viriya, MD: No financial relationships to disclose

Francis S. Mah, MD: Alcon Laboratories, Avellino Labs, Bausch + Lomb, Carl Zeiss Meditec, Johnson & Johnson Vision—Consultant/Advisor; Bausch + Lomb—Lecture Fees

Divya M. Varu, MD: No financial relationships to disclose

Preferred Practice Patterns Committee 2023

David K. Wallace, MD, MPH: No financial relationships to disclose

Christina J. Flaxel, MD: No financial relationships to disclose

Steven J. Gedde, MD: No financial relationships to disclose

Deborah S. Jacobs, MD: TECLens—Consultant/Advisor, Owner

Francis S. Mah, MD: Alcon Laboratories, Bausch + Lomb, Carl Zeiss Meditec, Johnson & Johnson Vision—Consultant/Advisor; Bausch + Lomb—Lecture Fees

Kevin M. Miller, MD: Alcon Laboratories, Johnson & Johnson Vision, Oculus, Inc.—Consultant/Advisor

Thomas A. Oetting, MD: No financial relationships to disclose

Divya M. Varu, MD: No financial relationships to disclose

David C. Musch, PhD, MPH: Glaukos Corporation—Consultant/Advisor

Secretary for Quality of Care

Roy S. Chuck, MD, PhD: No financial relationships to disclose

Academy Staff

Andre Ambrus, MLIS: No financial relationships to disclose

Meghan Daly: No financial relationships to disclose

Susan Garratt: No financial relationships to disclose

Flora C. Lum, MD: No financial relationships to disclose

The disclosures of relevant relationships to industry of other reviewers of the document from January to October 2023 are available online at www.aao.org/ppp.

TABLE OF CONTENTS

OBJECTIVES OF PREFERRED PRACTICE PATTERN GUIDELINES	P209
METHODS AND KEY TO RATINGS	P210
HIGHLIGHTED FINDINGS AND RECOMMENDATIONS FOR CARE	P212
INTRODUCTION	P213
Disease Definition	P213
Patient Population	P213
Clinical Objectives	P213
BACKGROUND	P213
Prevalence and Risk Factors	P213
Natural History	P214
Rationale for Treatment	P214
CARE PROCESS	P215
Patient Outcome Criteria	P215
Diagnosis	P215
History	P215
Examination	P216
Diagnostic Tests	P217
Management	P218
Prevention and Early Detection	P218
Choice of Therapy	P219
Follow-up Evaluation	P227
Provider and Setting	P227
Counseling and Referral	P228
Socioeconomic Considerations	P228
Quality of Life	P229
Economics	P229
APPENDIX 1. QUALITY OF OPHTHALMIC CARE CORE CRITERIA	P230
APPENDIX 2. DETERMINATION OF INTRAOCULAR PRESSURE IN DISEASED OR POSTSURGICAL CORNEAS	P232
LITERATURE SEARCHES FOR THIS PPP	P233
RELATED ACADEMY MATERIALS	P235
REFERENCES	P236

OBJECTIVES OF PREFERRED PRACTICE PATTERN® GUIDELINES

As a service to its members and the public, the American Academy of Ophthalmology has developed a series of Preferred Practice Pattern guidelines that **identify characteristics and components of quality eye care**. Appendix 1 describes the core criteria of quality eye care.

The Preferred Practice Pattern guidelines are based on the best available scientific data as interpreted by panels of knowledgeable health professionals. In some instances, such as when results of carefully conducted clinical trials are available, the data are particularly persuasive and provide clear guidance. In other instances, the panels have to rely on their collective judgment and evaluation of available evidence.

These documents provide guidance for the pattern of practice, not for the care of a particular individual. While they should generally meet the needs of most patients, they cannot possibly best meet the needs of all patients. Adherence to these PPPs will not ensure a successful outcome in every situation. These practice patterns should not be deemed inclusive of all proper methods of care or exclusive of other methods of care reasonably directed at obtaining the best results. It may be necessary to approach different patients' needs in different ways. The physician must make the ultimate judgment about the propriety of the care of a particular patient in light of all of the circumstances presented by that patient. The American Academy of Ophthalmology is available to assist members in resolving ethical dilemmas that arise in the course of ophthalmic practice.

Preferred Practice Pattern guidelines are not medical standards to be adhered to in all individual situations. The Academy specifically disclaims any and all liability for injury or other damages of any kind, from negligence or otherwise, for any and all claims that may arise out of the use of any recommendations or other information contained herein.

References to certain drugs, instruments, and other products are made for illustrative purposes only and are not intended to constitute an endorsement of such. Such material may include information on applications that are not considered community standard, that reflect indications not included in approved US Food and Drug Administration (FDA) labeling, or that are approved for use only in restricted research settings. The FDA has stated that it is the responsibility of the physician to determine the FDA status of each drug or device he or she wishes to use, and to use them with appropriate patient consent in compliance with applicable law.

Innovation in medicine is essential to ensure the future health of the American public, and the Academy encourages the development of new diagnostic and therapeutic methods that will improve eye care. It is essential to recognize that true medical excellence is achieved only when the patients' needs are the foremost consideration.

All Preferred Practice Pattern guidelines are reviewed by their parent panel annually or earlier if developments warrant and updated accordingly. To ensure that all PPPs are current, each is valid for 5 years from the "approved by" date unless superseded by a revision. Preferred Practice Pattern guidelines are funded by the Academy without commercial support. Authors and reviewers of PPPs are volunteers and do not receive any financial compensation for their contributions to the documents. The PPPs are externally reviewed by experts and stakeholders, including consumer representatives, before publication. The PPPs are developed in compliance with the Council of Medical Specialty Societies' Code for Interactions with Companies. The Academy has Relationship with Industry Procedures (available at www.aao.org/about-preferred-practice-patterns) to comply with the Code.

The intended users of the Corneal Ectasia PPP are ophthalmologists.

METHODS AND KEY TO RATINGS

Preferred Practice Pattern guidelines should be clinically relevant and specific enough to provide useful information to practitioners. Where evidence exists to support a recommendation for care, the recommendation should be given an explicit rating that shows the strength of evidence. To accomplish these aims, methods from the Scottish Intercollegiate Guideline Network¹ (SIGN) and the Grading of Recommendations Assessment, Development and Evaluation² (GRADE) group are used. GRADE is a systematic approach to grading the strength of the total body of evidence that is available to support recommendations on a specific clinical management issue. Organizations that have adopted GRADE include SIGN, the World Health Organization, the Agency for Healthcare Research and Quality, and the American College of Physicians.³

- ◆ All studies used to form a recommendation for care are graded for strength of evidence individually, and that grade is listed with the study citation.
- ◆ To rate individual studies, a scale based on SIGN¹ is used. The definitions and levels of evidence to rate individual studies are as follows:

I++	High-quality meta-analyses, systematic reviews of randomized controlled trials (RCTs), or RCTs with a very low risk of bias
I+	Well-conducted meta-analyses, systematic reviews of RCTs, or RCTs with a low risk of bias
I-	Meta-analyses, systematic reviews of RCTs, or RCTs with a high risk of bias
II++	High-quality systematic reviews of case-control or cohort studies High-quality case-control or cohort studies with a very low risk of confounding or bias and a high probability that the relationship is causal
II+	Well-conducted case-control or cohort studies with a low risk of confounding or bias and a moderate probability that the relationship is causal
II-	Case-control or cohort studies with a high risk of confounding or bias and a significant risk that the relationship is not causal
III	Nonanalytic studies (e.g., case reports, case series)

- ◆ Recommendations for care are formed based on the body of the evidence. The body of evidence quality ratings are defined by GRADE² as follows:

Good quality	Further research is very unlikely to change our confidence in the estimate of effect
Moderate quality	Further research is likely to have an important impact on our confidence in the estimate of effect and may change the estimate
Insufficient quality	Further research is very likely to have an important impact on our confidence in the estimate of effect and is likely to change the estimate Any estimate of effect is very uncertain

- ◆ Key recommendations for care are defined by GRADE² as follows:

Strong recommendation	Used when the desirable effects of an intervention clearly outweigh the undesirable effects or clearly do not
Discretionary recommendation	Used when the trade-offs are less certain—either because of low-quality evidence or because evidence suggests that desirable and undesirable effects are closely balanced

- ◆ The Highlighted Findings and Recommendations for Care section lists points determined by the PPP panel to be of particular importance to vision and quality of life outcomes.
- ◆ All recommendations for care in this PPP were rated using the system described above. Ratings are embedded throughout the PPP main text in italics.
- ◆ Literature searches for the PPP were undertaken on March 3, 2022 and June 7, 2023 in the PubMed database. Complete details of the literature search are available at www.ao.org/ppp.

- ◆ Recommendations are based on systematic reviews, as per the Institute of Medicine (Clinical Practice Guidelines We Can Trust, 2011). In formulating the recommendations, the health benefits, side effects/harms/risks, and the balance of benefits and risks are reviewed and considered. Final decisions are arrived at through informal consensus techniques. If there are areas of disagreement, a vote will be conducted among the members of the guideline panel. If there are individuals with direct financial relationships in the area of disagreement, these individuals will refrain from the vote.

HIGHLIGHTED FINDINGS AND RECOMMENDATIONS FOR CARE

Patients with unstable refractions should be evaluated for evidence of corneal ectasia.

Since corrected distance visual acuity (CDVA) may not completely characterize visual function in patients with corneal ectasia, the ophthalmologist needs to include other measures such as corneal topography and tomography.

Signs of corneal ectasia can include, but are not limited to, inferior steepening, superior flattening, skewing of radial axes on power topographic maps, abnormal islands of elevation anteriorly and/or posteriorly on tomography, and decentered or abnormal corneal thinning and/or abnormal rate of change of corneal thickening from the center to the periphery.

Patients being evaluated for keratorefractive surgery should be evaluated for corneal ectasia following a period of contact lens abstinence. Corneal topography and tomography should be reviewed for evidence of irregular astigmatism or abnormalities suggestive of keratoconus or other forms of corneal ectasia. Overall, the risk of corneal ectasia is lower after photorefractive keratectomy (PRK) and small-incision lenticule extraction (SMILE) compared with laser in-situ keratomileusis (LASIK). This has been attributed to higher residual stromal bed thickness and absence of the corneal flap in PRK.

Corneal cross-linking (CXL) reduces the risk of progressive ectasia in patients with keratoconus. It also stabilizes corneal ectasia occurring after keratorefractive surgery but is generally not as effective in this latter setting. Corneal cross-linking is the recommended treatment for progressive keratoconus because it stabilizes the cornea and reduces the risk of progressive ectasia. It also stabilizes corneal ectasia occurring after keratorefractive surgery but is generally less effective in this later setting.

The long-term stabilizing effect of CXL may be more cost effective than corneal transplantation.

Specialty contact lenses, including hybrid and scleral lenses, should be trialed for visual rehabilitation prior to keratoplasty and may delay and even eliminate the need for corneal transplantation.

Penetrating keratoplasty (PK) and deep anterior lamellar keratoplasty (DALK) may be used to treat corneal ectasia. The advantages of DALK include no risk for endothelial rejection and lower risk of globe rupture than with PK. The progressive endothelial cell loss following DALK may also be less than the loss following PK.

INTRODUCTION

DISEASE DEFINITION

Corneal ectasia is characterized by progressive corneal steepening and thinning. Types of corneal ectasia include keratoconus, pellucid marginal degeneration, keratoglobus, postkeratorefractive ectasia, and wound ectasia after lamellar keratoplasty or penetrating keratoplasty (PK). Corneal ectasias are associated with decreased uncorrected visual acuity (UCVA), an increase in corneal aberrations, and often a loss of best-corrected distance visual acuity. Corneal ectasia can result in significant ocular morbidity and may require surgical intervention.

PATIENT POPULATION

The patient population includes individuals of any age with corneal ectasia.

CLINICAL OBJECTIVES

- ◆ Identify corneal ectasia risk factors and associated conditions, and recognize signs of ectasia during the clinical examination
- ◆ Establish the diagnosis of corneal ectasia, including use of appropriate diagnostic technologies
- ◆ Understand appropriate nonsurgical and surgical treatment options
- ◆ Improve visual function
- ◆ Prevent loss of visual function
- ◆ Educate and involve the patient in the management of this disease

BACKGROUND

PREVALENCE AND RISK FACTORS

Corneal ectasia encompasses both naturally occurring and surgically induced thinning and protrusion. Naturally occurring keratoconus typically was thought to begin in puberty and progress until about 40 years of age. Newer imaging modalities, however, have shown the ectatic disease can occur at a much earlier age (pre-puberty), and progression past the age of 40 is not that uncommon. Keratoconus is typically bilateral but is often asymmetrical. The overall prevalence of keratoconus has been reported to be between 50 and 230 per 100,000 in the general population, with both sexes equally affected.⁴⁻⁷ However, the prevalence depends on the method of diagnosis. Using corneal topographic and tomographic values, other population-based surveys from Asia, the Middle East, and Oceania found a prevalence ranging from 0.9% to 3.3%.⁸ A meta-analysis that included more than 50 million individuals from 15 countries determined that the global prevalence of keratoconus was 138/100,000.⁹ Pellucid marginal degeneration usually has its onset later in life. Keratoglobus is rare and may be seen in children and is usually congenital. Corneal ectasia can occur after laser in-situ keratomileusis (LASIK), small incision lenticule extraction (SMILE), radial keratotomy (RK), and photorefractive keratectomy (PRK) in eyes with a pre-existing subclinical keratoconus, or even in eyes with no preoperative signs of keratoconus.^{10, 11}

The etiology of corneal ectasia may include genetic factors, biochemical, and biomechanical factors (e.g., eye rubbing).¹² Keratoconus is associated with atopic disease, including hay fever, asthma, eczema, and vernal keratoconjunctivitis or within families demonstrating these entities.¹³ In these patients, ocular inflammation should be controlled to decrease the propensity for eye rubbing, and adding a mast cell stabilizer can be considered. Corneal ectasia has also been associated with obstructive sleep apnea¹⁴ and high body mass index.¹⁵

Genetic disorders associated with keratoconus include connective tissue diseases with abnormal collagen and hyper-elasticity such as Ehlers-Danlos syndrome, osteogenesis imperfecta, congenital hip dysplasia, nail patella syndrome, pseudoxanthoma elasticum, hyper-immunoglobulin E syndrome associated with eczema and atopy, oculodentodigital dysplasia, and ichthyosis. Other genetic

syndromes associated with keratoconus include those that are associated with eye rubbing and diminished mental capacity, such as in Apert syndrome, Crouzon syndrome, Down syndrome, hyperornithinemia, Angelman syndrome, and Noonan syndrome. Keratoconus has been associated with disorders related to abnormal retinal function and oculodigital stimulation, including albinism, Bardet-Biedl syndrome, Leber congenital amaurosis, tapetoretinal degeneration, retinitis pigmentosa, and Kurz syndrome. Although there is a lack of a definitive evidence of a “keratoconic personality,” one study showed that keratoconus patients score lower on the respectful coping-style scale.¹⁶

Thinning of the cornea in keratoconus occurs as a result of the degradation of corneal collagen. Altered enzyme activities and oxidative stress have been proposed as factors related to the pathogenesis of keratoconus and related corneal ectasias. In particular, increased matrix metalloproteinase levels, along with decreased tissue inhibitor of metalloproteinase, have been demonstrated in keratoconic corneas when compared with normal corneas. The findings indicate a probable role for these enzymes in matrix degradation found in keratoconus.^{12, 17-22}

The tears of patients with keratoconus have been shown to contain increased levels of inflammatory mediators such as interleukin-6, TNF-alpha, and MMP-9.^{23, 24} These inflammatory mediators likely result in keratocyte apoptosis and the decreased keratocyte cell density associated with keratoconic corneas. It is therefore likely that this form of corneal thinning, classified as noninflammatory, may have an inflammatory component that is either directly or indirectly related to the pathogenesis and progression of the disease.²⁵ Postkeratorefractive surgical ectasia has been postulated to occur as a result of insufficient corneal thickness, exacerbation of pre-existing subclinical or clinical keratoconus by further weakening of the corneal structure, and/or the development of genetically predetermined ectasia occurring years after refractive surgery.^{11, 26, 27} A genetic predisposition to keratoconus may exist in patients who undergo a second environmental insult, such as eye rubbing and/or the iatrogenic corneal thinning that occurs after laser vision correction.^{4, 12}

Findings in corneal ectasia that occurs after keratorefractive surgery include the following: the residual stromal bed following surgery was thinner than expected; the flap was thicker than intended; the degree of myopia treated was large; or the patient had unrecognized preoperative signs of a pre-existing subclinical keratoconus, particularly in a young patient. However, corneal ectasia can develop in the absence of these situations.¹⁰ Postrefractive ectasia occurs at lower rates in eyes undergoing PRK than LASIK. A meta-analysis reported incidence of postrefractive ectasia in eyes without preoperative identifiable risk factors. Without adjustment for treatment depth or length of follow up, ectasia occurred in 20 per 100,000 eyes in PRK, 90 per 100,000 eyes in LASIK, and 11 per 100,000 eyes in SMILE. The rate of ectasia in LASIK was found to be 4.5 times higher than the rate in PRK.²⁸ Of note, the rate of ectasia in SMILE may be underestimated due to the much shorter follow-up period since its regulatory approval.

NATURAL HISTORY

Corneal ectasia is usually bilateral, and it varies in severity from clinically undetectable, or “subclinical,” to advanced disease. The most common ectasia is keratoconus, which is a progressive disorder that results in corneal thinning, irregular astigmatism, and decreased vision. Eye rubbing, family history, and younger age of onset may result in greater progression of disease, resulting in more severe loss of vision due to greater irregular astigmatism, thinning, and scarring. Less than 20% of keratoconus cases historically required PK. Improved imaging technologies allow for early identification of keratoconus. Consequently, the true incidence of keratoconus is much higher than previously thought, making the true incidence of progression to keratoplasty much lower.^{4, 5, 29, 30} Overall, the rate of keratoplasty in keratoconus is decreasing in the United States.³¹ Corneal hydrops, caused by the acute disruption of Descemet’s membrane in the setting of corneal ectasia, occurs in approximately 3% of patients with keratoconus.³² A history of eye rubbing and seasonal allergies is associated with hydrops development.³³ (Management of acute corneal hydrops is addressed in the Corneal Edema and Opacification PPP.³⁴)

RATIONALE FOR TREATMENT

Patients with corneal ectasia suffer from varying degrees of disability, including reduced visual acuity and quality, glare, halos, multiple images, ghosting, and intolerance to eyeglasses and contact lenses. The loss of visual function may result in lost productivity, a reduced self-esteem, and difficulties when performing high-skill visual tasks (e.g., driving). The rationale for treatment depends on the

severity of disease and the amount of vision loss. Because keratoconus usually presents in late childhood or adolescence, early diagnosis is very important. Once progression is observed, prompt treatment with corneal cross-linking (CXL) can reduce or stop keratoconus progression and preserve visual acuity with eyeglasses and/or contact lenses.^{4, 5, 35} The greater the delay of diagnosis, the higher the risk of greater vision loss and of the patient requiring a cornea transplant.³⁶

CARE PROCESS

PATIENT OUTCOME CRITERIA

- ◆ Preventing visual loss
- ◆ Preventing progressive disease
- ◆ Reducing the signs and symptoms of corneal ectasia
- ◆ Maintaining, restoring, or improving visual function according to the needs of the patient

DIAGNOSIS

Initial evaluation of the patient who has symptoms and signs of corneal ectasia should include the relevant aspects of the comprehensive medical eye evaluation.³⁷ The diagnosis of corneal ectasia is usually based on a typical patient history and characteristic findings on topography and tomography. Ideally, the ophthalmologist would like to make the diagnosis early, before a patient becomes symptomatic; however, there currently is no simple, cost-effective screening test available to do this. An FDA-approved test is available (Avellino Lab USA, Inc.) that evaluates more than 2,000 variants in the 75 genes associated with keratoconus and any transforming growth factor beta induced (TGFB1) gene-related corneal dystrophy variants. The test uses a weighted scoring model that integrates diagnostic tests and environmental factors to calculate the degree of keratoconic risk for a patient.³⁸ However, its relevance in clinical practice is unknown. It is important to properly identify the presence of potentially progressive corneal ectatic conditions, including subclinical disease (also known as forme-fruste keratoconus), in patients considering keratorefractive surgery who are more likely to progress to a symptomatic stage of ectasia.

History

- ◆ Onset and course
The onset of corneal ectasia varies with the type and degree of the thinning disorder. Keratoconus usually appears in the second or third decade of life. Pellucid marginal degeneration occurs between the third and the fifth decade of life,^{39, 40} whereas keratoglobus can be present in early life. Postkeratorefractive surgery ectasia can occur any time after LASIK, SMILE, RK, and/or PRK. The onset of postkeratorefractive surgery ectasia can be months to years following the original refractive procedure.
- ◆ Vision (degree of impairment)
The degree of impairment from corneal ectasias varies widely from little to no visual impairment or loss of corrected distance visual acuity (CDVA) in eyes with minimal findings on topography and tomography to significant loss of visual function in eyes with severe corneal thinning, irregularity, and scarring.
- ◆ Ocular history
A typical history of a patient with keratoconus is a frequent change of glasses prescription that initially corrects vision but later does not. Often, one eye is affected much more than the fellow eye, and the poor vision is detected when the better seeing eye is covered.

Obtaining a history of the type and duration of contact lens wear is important, noting the stability and comfort of the contact lens. If the contact lens corrects the vision to an acceptable level but decenters, causes discomfort, or even pops out frequently, it will not provide acceptable visual function. If there is a history of keratorefractive surgery, it is helpful to collect as much information as available about the surgery and the condition of the eyes before and after the procedure.

Eyes with topographic and tomographic abnormalities that suggest subclinical keratoconus can progress to clinically significant ectasia following keratorefractive surgery. One of the commonly used indices is the Belin-Ambrósio enhanced ectasia total deviation (BAD-D) value. It is a multivariate index that integrates anterior elevation, posterior elevation, and the pachymetric data.⁴¹ Other risk factors potentially associated with ectasia after keratorefractive surgery may include a younger age, a high manifest refractive spherical equivalent, reduced corneal thickness, and the prediction of a thin residual stromal bed thickness.²⁶ Risk-scoring systems have been developed to attempt to predict the likelihood of ectasia. However, these systems have demonstrated variable accuracy in clinical use with both false-positive and false-negative results.^{26, 42, 43}

- ◆ Medical history

A history of atopy associated with eye rubbing, asthma, and hay fever has also been reported to be associated with keratoconus in many studies.^{12, 13, 44} Down syndrome and other genetic disorders can also be associated with keratoconus (see genetic disorders referred to in the Prevalence and Risk Factors section).

- ◆ Family history

Keratoconus has been associated with other genetic syndromes such as Down syndrome, Leber congenital amaurosis, Ehlers-Danlos syndrome, and Noonan syndrome. Multiple reports of twins with keratoconus have been documented in the literature.⁴⁵ In addition, first-degree relatives of patients with keratoconus have an increased risk for the development of keratoconus as well as an increased prevalence of corneal topographic abnormalities.⁴⁵⁻⁴⁷ The Collaborative Longitudinal Evaluation of Keratoconus (CLEK) study showed that 14% of 1209 patients with keratoconus had a family history of the disease.⁴⁸ The CLEK study did not include corneal topography or tomography in the diagnosis of ectasia. New studies using more advanced screening and diagnostic techniques developed since CLEK are likely to show an even higher incidence. Recent developments in the field of keratoconus genetics have identified polymorphism in the enzyme lysyl oxidase gene and CAST gene (encoding calpastatin, inhibitor of calpains, which are inhibitors of intracellular proteases), among others.⁴⁹ A single keratoconus locus (5q21.2) has been replicated across multiple linkage studies.⁵⁰

Examination

- ◆ Assessment of visual function

Corneal ectasia typically presents with unstable refractive error, a progressive increase in irregular astigmatism on manifest refraction, and a scissors reflex on retinoscopy, and it ultimately results in the inability to correct the patient to 20/20. Checking visual acuity by presenting several Snellen lines and asking the patient to read the letters as quickly as possible suggests that the visual acuity is far worse than suspected when an unlimited time to read the chart is permitted. Visual compromise is a late finding in many patients.

- ◆ External examination of the ectasia patient:

- ◆ Eyelid skin is examined for evidence of thickening and scaling (atopic disease) or eyelid ptosis and a rubbery, floppy eyelid with accompanying papillary conjunctivitis on upper eyelid eversion.
- ◆ Outward bowing of the lower eyelid on downgaze (Munson sign) is a nonspecific finding seen in severe ectasia.

- ◆ Slit-lamp biomicroscopy findings of corneal ectasia:

- ◆ The presence, extent, and location of corneal thinning and protrusion, which is important. In keratoconus, the cornea usually protrudes in the area of maximal thinning.⁴² In contrast, patients with pellucid marginal degeneration typically have an area of maximal protrusion that is superior to the band of thinning. The inferior band of corneal thinning is often separated by an uninvolved area 1 to 2 mm from the inferior limbus.⁴² The area of thinning and protrusion can occasionally be seen superiorly.
- ◆ Evidence of previous corneal surgery, especially LASIK flap, and incisions from SMILE and RK.

- ◆ Vogt striae, which are vertical (rarely horizontal) fine folds, in the mid and deep stroma that clear with external pressure. These may dissipate on gentle globe pressure, suggesting wrinkles in Descemet's membrane.
- ◆ Prominent corneal nerves.
- ◆ Fleischer ring (i.e., epithelial iron deposition at the base of the cone seen in keratoconus).
- ◆ Evidence of corneal scarring, noting location of scarring in relation to corneal thinning/protrusion; evidence of apical scarring at Bowman's layer; mid or deep stromal scarring and/or evidence of previous hydrops.
- ◆ Intraocular pressure measurement

The measurement of intraocular pressure (IOP) by applanation tonometry (e.g., Goldmann) is artifactually reduced as a consequence of tissue thinning and biomechanical weakening in ectatic disease and following refractive surgery (PRK, SMILE, and LASIK).⁵¹⁻⁵³ Use of an alternative device that is less dependent on a smooth and regular corneal surface to obtain an accurate measurement is suggested (such as with the pneumotonometer, corneal thickness-compensated IOP, dynamic contour tonometer, or rebound tonometer⁵⁴). It is important to consider loss of corneal resistance as an additional factor that can affect IOP measurement in corneal ectasia.
- ◆ Fundus assessment

The red reflex should be assessed by examining the fundus to look for a dark area caused by total internal refraction (oil droplet), and the retina should be assessed for signs of tapetoretinal degenerations, as these can be associated with keratoconus.

Diagnostic Tests

- ◆ Keratometry

Corneal ectasia is usually associated with irregular astigmatism and an increase in steepening in the paracentral or mid peripheral area of the cornea. Because primary and secondary corneal ectasia can result in an inferiorly displaced area of protrusion, keratometry can show increased steepening in patient upgaze or rarely downgaze.
- ◆ Corneal topography and tomography

A comprehensive evaluation of both the anterior and posterior surfaces (topographically and tomographically) as well as full pachymetric mapping of the cornea is important in establishing the diagnosis of corneal ectatic disease and following its course. Slit-scanning corneal tomography and Scheimpflug imaging systems can evaluate these parameters and have expanded diagnostic criteria for keratoconus, subclinical keratoconus, pellucid marginal degeneration, and postkeratorefractive corneal ectasias. Their use is necessary to properly screen potential refractive surgery patients.^{55, 56}

 - ◆ Topographic power map

There is no corneal power value that defines ectasia. However, ectasia is usually associated with higher/steeper corneal power measurements (i.e., greater than 46.0 diopters [D]). Inferior steepening, superior flattening with an I/S (inferior to superior) ratio of 1.2 or greater and skewing of the radial axes more than 21° are typical of keratoconus. Curvature maps, especially those from Placido-based systems, are limited to approximately 60% of the corneal surface and lack important data for peripheral or paracentral corneal pathologies, particularly pellucid marginal degeneration.^{53, 57}
 - ◆ Tomographic elevation mapping

Isolated islands of elevation (anteriorly, posteriorly, or both) are often seen in ectatic corneas and can be a helpful sign of keratoconus and postkeratorefractive ectasia when generated by slit-scanning systems or Scheimpflug imaging. Posterior elevation mapping and tomography generated by these devices has been shown to have a relatively high sensitivity and specificity for the detection of keratoconus, but less so with subclinical keratoconus.^{58, 59}
- ◆ Optical coherence tomography

Anterior segment optical coherence tomography (AS-OCT) provides high-definition, cross-sectional images of the cornea, angle, anterior chamber, and anterior lens. Measurement tools to document and follow changes in the corneal

thickness, angle recess opening, and anterior chamber depth and size are standard with all models. Pachymetry mapping is available, and software is available that can use AS-OCT measurements for keratoconus detection.⁶⁰⁻⁶² In corneal ectasia, the corneal epithelium is known to remodel because of underlying stromal irregularities.⁶³ Epithelial thickness maps can be used as an adjunct to the existing criteria for detection of keratoconus.⁶⁴ High axial resolution AS-OCT-based devices and high-frequency ultrasound enable accurate corneal epithelial thickness mapping. Typically, the epithelial thickness profile in keratoconus is donut shaped, which corroborates with stromal thinning at the cone surrounded by a rim of thickened epithelium. Anterior segment optical coherence tomography also has the advantage of imaging retrocorneal structures. A large Descemet's break and central stromal cleft may exist in cases of corneal edema associated with keratoconic hydrops or trauma. Anterior segment optical coherence tomography can also be used to assess LASIK flap thickness and residual bed in cases of postrefractive ectasia.

◆ Other considerations

The ability to detect corneal ectasia at the subclinical or “biomechanical stage” prior to the development of secondary changes in thickness or curvature is being evaluated.⁶⁵ Parameters used to assess corneal biomechanics in clinical practice, including corneal hysteresis and corneal resistance factor, are assumed to be altered in these conditions. Commercially available devices used to characterize corneal biomechanical properties, including a dynamic bidirectional applanation device and a dynamic Scheimpflug analyzer, are being evaluated in order to develop additional parameters for early keratoconus detection.⁶⁶ The first *in vivo* biomechanical biometer uses an infrared beam to measure the deformation of the eye caused by a variable pressurized column of air that indents the central 3 to 6 mm of the apical cornea. A Scheimpflug biometer captures the effects of a standardized air puff with a camera and generates upward of 12 biomechanical parameters.⁶⁷ Studies have shown that biomechanical changes in a keratoconus cornea happen before the morphological changes.⁶⁸ It has been proposed that identification of corneal biomechanical properties might be useful in the diagnosis of early keratoconus.⁶⁹

Higher-order aberrations of the anterior and posterior corneal surfaces are altered in keratoconus and have been evaluated as a means of detecting both clinical and subclinical disease.⁶⁵ The dominant higher-order aberration found in keratoconus is vertical coma, which is of greater magnitude in patients with keratoconus compared with normal patients; however, the diagnostic value of coma alone, particularly for subclinical keratoconus, is limited.^{57, 70-74}

MANAGEMENT

Prevention and Early Detection

Early detection and treatment of corneal ectasia attempt to preserve or improve vision and prevent loss of functional vision. Preventing disease progression has been an elusive goal. Patients should be advised to refrain from eye rubbing, which has been associated with progression. Adding a mast cell stabilizer to control ocular allergy should be considered to reduce eye rubbing. Corneal cross-linking (CXL) can slow or arrest progression of the disease,^{75, 76} which works best early in the disease process (for prevention prior to keratorefractive surgery, see the Refractive Surgery PPP⁷⁷).

Ectasia should be suspected in a young patient whose refractive error keeps changing, and these patients should be carefully evaluated and followed. Closer follow-up is recommended in patients younger than 17 and with steeper than 55 D Kmax.⁷⁸ The natural progression of corneal steepening is shown to decelerate after the age of 30.⁷⁹ However, progression in patients older than 30 can occur if the baseline keratometry values are high.⁸⁰ Additionally, all patients seeking refractive surgery must be carefully screened for ectasia. Corneal topography and tomography following a period of contact lens abstinence is an essential part of this evaluation. Evidence of irregular astigmatism or abnormalities of the posterior cornea suggestive of keratoconus or other

corneal ectasias may be associated with unpredictable refractive outcomes and with ectasia progression following keratorefractive surgery.^{42, 81-83}

Several methods have been described to evaluate and document progression in keratoconus. Although serial topographic analysis can be used to document disease progression, a few newly proposed systems use complex keratometric indices to describe progression. A 2015 consensus document defined the minimal requirement for documented progression as at least 2 of the following: steepening of the anterior corneal surface, steepening of the posterior corneal surface, or thinning and/or an increase in the rate of corneal thickness change from the periphery to the thinnest point.⁸⁴ The ABCD classification system has been integrated into a Scheimpflug imaging device. It creates a composite score of four different parameters: Anterior radius of curvature (A), posterior radius of curvature (B), minimum corneal (C) thickness, and, and best spectacle-corrected distance (D) acuity. A change in ABCD score can be used to document progression. Each parameter is individually staged between 0 and 4. Overall, keratoconus is known to progress at a faster rate in younger patients. Early detection and treatment are therefore crucial in this age group.⁸⁵ Although it has been proposed that CXL in children and adolescents should be performed as soon as the diagnosis has been made without awaiting documentation of progression,⁸⁶ it is reasonable for clinicians to confirm progression prior to treatment so as to avoid unnecessary treatment of false positive cases and many insurance companies still require evidence of progression in ectasia.

Choice of Therapy

The choice of therapy, medical or surgical, is tailored to the individual patient and depends on both the degree of visual impairment and a risk/benefit analysis for each particular treatment option.

Medical

Eyeglasses

In early keratoconus, vision can be corrected with eyeglasses, but as keratoconus and the resultant corneal aberrations progress, contact lenses may be required to correct vision and reduce distortion. In one study, 71% of patients could be corrected to 20/40 with their eyeglasses, and 47% of patients reported wearing their eyeglasses full time or on occasion.²⁹ Another study reported that 58% of patients achieved 20/40 or better with best eyeglass correction.⁸⁷

Contact Lenses

Soft Contact Lenses

In mild forms of keratoconus, spherical soft contact lenses or toric soft contact lenses may give patients acceptable vision with perhaps more comfort than a hard contact lens. Since soft contact lenses conform to the irregular corneal shape of the keratoconic cornea, they are designed with a thicker center. Other lens designs for keratoconus include aberration-controlled soft contact lenses to correct vertical coma aberrations and reverse geometry soft contact lenses.

Gas-Permeable Contact Lenses

Long-term studies (the CLEK and the Dundee University Scottish Keratoconus Study [DUSKS]) have found that most patients are fitted with contact lenses when vision can no longer be corrected to at least 20/30 in eyeglasses.^{29, 48} Rigid corneal gas-permeable contact lenses have the advantage of masking corneal irregularities, thus providing a regular anterior refractive surface.⁸⁸ Flat-fitting contact lenses provided worse visual acuity than steep-fitting contact lenses.⁸⁸ In general, three strategies have been used for rigid corneal contact lens fitting in keratoconus: apical clearance, apical touch, and three-point touch. In DUSKS, contact lens wear was the mainstay of treatment; 76% of the 200 patients (mean age: 30.9 ± 10.4 years) were fitted with a contact lens. The majority of these patients wore their contact lenses for more than 12 hours per day, 7 days per week, and 93% achieved a CDVA of 20/30 or better.²⁹ In addition, 91% of these contact lens patients wore gas-

permeable contact lenses, 6% wore hybrid contact lenses, and 2% wore scleral contact lenses. Only 1% wore soft contact lenses. Seventy-one percent of contact lens wearers reported some discomfort and 18% reported severe discomfort. With advances in contact lens design and an increasing number of hybrid and scleral lenses now available, it is likely that updated studies would show better results.⁸⁹⁻⁹² Hyperemia was reported in 63%, and 18% described the hyperemia as severe.^{29, 88} In the CLEK study, 65% of the 1,209 patients wore rigid contact lenses on entry,⁹³ and 29% developed corneal scarring over 8 years.⁸⁸ (At baseline, 53% of study patients had corneal scarring in one or both eyes.⁴⁸)

Hybrid Contact Lenses

Hybrid contact lenses contain a rigid gas-permeable (RGP) center with a soft skirt.^{88, 94} New-generation hybrid contact lenses provide higher oxygen permeability and greater strength of the RGP/hydrogel junction. In studies of RGP contact lens intolerance, 87% achieved success with hybrid contact lenses.⁹⁴ Unlike RGP contact lenses, the optical center of the hybrid contact lenses remains in the center of the cornea, which may not be coincident with the center of the cone. Disadvantages of hybrid contact lenses include late lens tightening, a tendency toward a tight fit, and the need for high molecular-weight fluorescein to evaluate the fit.^{88, 94}

Piggyback Contact Lenses

Use of piggyback contact lenses involves fitting an RGP contact lens on top of a soft contact lens to provide for greater comfort and less epithelial disruption. A mild negative-powered soft contact lens facilitates the fitting of a flatter and less minus-powered rigid corneal contact lens, resulting in improved centration and movement and reduction in aberrations. Disadvantages include the need for more than one lens care system, the increased potential for loss of the RGP contact lens, damage to the soft contact lens, and difficulty fitting the soft contact lens on the misshapen cornea.⁸⁸

Scleral Lenses

Scleral lenses have the advantages of completely vaulting over the corneal surface to provide centration, less apical touch, stability, and improved central visual acuity. A study found that all patients referred for scleral lens fitting owing to failed RGP wear could be successfully fitted either with a conventional lens or a custom-designed scleral lens, thus avoiding keratoplasty.⁹⁵ Custom-made lenses are now widely available and allow for scleral lenses to be custom designed for patients with scleral irregularities, such as patients with pterygia or glaucoma blebs. Scleral lenses are particularly useful in advanced keratoconus when other lens modalities fail to achieve a good fit due to lens decentration. These commercially available lenses are made to order like other specialty RGP lenses and may delay or eliminate the need for keratoplasty. Disadvantages include decreased tear exchange and difficulty with insertion and removal of the lenses.^{88, 96} Custom-made lenses are considerably more expensive than larger-diameter or mini lenses and may be cost prohibitive for patients with inadequate insurance coverage.

Surgical

Corneal Cross-Linking

None of the above medical treatments impact the disease process, and the ectasia can progress despite good corrected visual acuity. It is important to consider CXL in the early stages of progressive keratoconus rather than wait until corrected visual acuity has declined and the benefits of CXL are more limited or when patients have progressed (thinned) to the point where they may no longer be a CXL candidate.

Indications

Corneal cross-linking is a procedure designed to increase the biomechanical rigidity of the cornea and is thought to achieve this by increasing the biochemical bonds in the corneal stroma. This is achieved by local photo-polymerization using ultraviolet-A (365 nm UV-A) light and topical riboflavin as a photosensitizing agent.⁹⁷ The aim of CXL is to arrest or slow the progression of corneal ectasia. The U.S. Food and Drug Administration (FDA)

keratoconus or corneal ectasia following keratorefractive surgery. No consistent or clear definition of ectasia progression has been identified,⁸⁴ yet several tomography-derived values (alone or in combination) have been evaluated as progression determinants.^{98, 99} These include maximum keratometry, steepening of the anterior or posterior corneal surface, and thinning and/or an increase in the rate of corneal thickness change from the periphery to the thinnest point. Refractive changes such as increasing myopia and astigmatism are also considered to be evidence of ectasia progression.

Technique Options

The original Dresden protocol for CXL (“conventional” CXL) involved removal of the corneal epithelial layer, application of topical riboflavin every 2 minutes for 30 minutes to saturate the cornea, followed by 30 minutes of UV-A light treatment with continued instillation of riboflavin (again, every 2 minutes) until UV-A treatment is completed.¹⁰⁰ Although this is the FDA-approved protocol, the optimal treatment parameters have yet to be determined. Because the Dresden protocol requires a long treatment time of at least 60 minutes, accelerated protocols have been proposed to shorten the treatment time.¹⁰¹⁻¹⁰⁴

Recent studies include evaluations of pulsed or fractionated UV-A protocols in order to improve the effectiveness of accelerated protocols.¹⁰⁵ Current treatment protocols require either the removal of the epithelium or exposure of the intact epithelium to agents that increase the permeability of the cell layer, followed by the application of topical riboflavin and UV-A treatment. The transepithelial or “epithelium on” technique allows for passage of the riboflavin through an essentially intact epithelium. This may decrease the risk of complications associated with epithelial removal, but it may also decrease CXL efficacy.^{75, 106} Both techniques and the relative importance of the benefits of one approach over another continue to be studied.

Outcomes

Corneal cross-linking was introduced in 2003 to stabilize progressive keratoconus,⁷⁵ and it has been reported by others to arrest progression in early⁷⁶ as well as advanced cases of the disease.^{75, 107-110} In addition to stabilizing the cornea, CXL has been reported to induce flattening of the cornea by 1.0 to 2.5 D, thereby potentially improving corneal optics and vision. In addition to a plethora of international clinical data supporting the use of CXL,¹¹¹ other studies have contributed additional direct^{112, 113} (*I-, Insufficient, Strong*) and indirect evidence to support the efficacy of it.^{114, 115} Two European studies have reported significant reductions in the number of penetrating keratoplasties performed for keratoconus since the introduction of CXL; however, these findings were concurrent with advances in contact lens technology, which has also decreased keratoplasty rates.^{116, 117}

The phase III study data that supported the FDA approval of CXL for progressive keratoconus included 205 patients at multiple U.S. centers who had documented progressive keratoconus and who were randomized into treatment (using the Dresden protocol) and a sham control group. In the treatment group, the topography-derived maximum keratometry value decreased by 1.6 ± 4.2 D from baseline to 1 year, whereas keratoconus continued to progress in the control group. The cross-linked eyes also showed improved CDVA compared with the sham control eyes.¹¹⁸

The phase III study that evaluated CXL for corneal ectasia after refractive surgery randomized 179 patients with postkeratorefractive surgery ectasia into treatment and sham groups. The treatment group received CXL per the Dresden protocol. In the treatment group, the mean maximum keratometry value decreased by 0.7 ± 2.1 D compared with an increase in the mean maximum keratometry value in the control group of 0.6 ± 2.1 D.¹¹⁹

Long-term studies confirm that standard Dresden CXL stops the deterioration and progression of keratoconus (the principal goal of treatment). Meta-analysis of 75 publications with more than 36 months of follow-up also showed more improvement in uncorrected vision than in corrected distance vision and that there is a late reduction in keratometry (corneal topography) values. Some reduction in astigmatism was seen, but spherical equivalent did not materially change. A transient reduction in the endothelial cell count has been noted, but this typically returns to normal by 6 months. Although certain biomechanical parameters such as corneal resistance factor and corneal hysteresis are minimally affected by CXL, some custom variables derived from the same instrument are

changed in ways that suggest stiffer behavior after cross-linking.^{120, 121}

In pediatric patients, where keratoconus can present at an advanced stage and progress more aggressively than in adult counterparts, standard CXL is effective in attenuating progression (1-year and 3-year data). The KERALINK study from the United Kingdom is a randomized clinical trial that examined the efficacy and safety of corneal CXL for stabilization of progressive keratoconus in participants 10 to 16 years of age. Corneal cross-linking stopped progression of keratoconus in the majority of young patients when measured at 18 months. The study recommended that CXL be considered as a first-line treatment in progressive disease.¹²² Longer-term studies are needed to evaluate the persistence of treatment effect.¹²³

The majority of international clinical data supports the use of CXL in the early management of keratoconus. Its long-term safety and stability combined with data indicating a reduction in the need for corneal transplantation are significant. Corneal cross-linking helps to prevent vision loss that impacts an individual's personal and professional life due to insufficient correction with eyeglasses and difficulties of properly fitting contact lenses, and that necessitates patients to undergo corneal transplantation with its lifelong risks of rejection and rupture.

Contraindications

A contraindication to CXL is corneal stromal thickness below 400 μm at the time of UV light exposure to prevent endothelial damage. There are various modifications to the conventional CXL method to circumvent this. Hypotonic riboflavin can be used to transiently thicken a cornea to the 400 μm threshold in some cases that fall below this value. Other methods such as iontophoresis-assisted CXL, transepithelial CXL, and contact lens-assisted CXL have been described but are not FDA approved in the United States. Hafezi et al published the results of CXL in patients with stromal thicknesses of 400 μm or less who were treated with the sub400 protocol, in which the UV irradiation time was customized for each patient based in the corneal thickness.¹²⁴ This sub400 protocol outlines treatments for corneal thickness between 200 and 400 μm using UV exposure between 1 and 29 minutes.¹²⁴

Since exposure to UV light may cause reactivation of herpes simplex virus infection, so caution should be taken when performing CXL in patients with prior herpes simplex virus keratitis. Other contraindications include corneal stromal scarring, severe ocular surface disease, and autoimmune disorders associated with corneal thinning.

Complications

Complications of CXL include punctate keratitis, corneal striae, photophobia, dry eye, eye pain, infectious keratitis, sterile infiltrates, corneal haze, corneal scarring, nonhealing epithelial defects, and corneal edema. With the exception of corneal edema, which is the likely result of endothelial damage, it has been suggested that other complications are related to the removal of the epithelial layer.^{75, 108} However, deep stromal haze may not be related to endothelial damage or epithelial removal. Complications seem to occur more frequently in patients over 35, when cornea thickness is less than 400 μm , and with worse preoperative corrected visual acuity.

Corneal cross-linking failure is defined as progression of keratoconus after treatment. Risk factors for failure included a preoperative patient age of 35 or older, preoperative corrected visual acuity less than 20/25, and preoperative maximum steepening greater than 58 D.^{125, 126} However, more recent studies have shown that CXL is safe and that it stabilized both the visual acuity and tomographic parameters at the 2-year follow-up in eyes with advanced (>58 D) progressive keratoconus.¹²⁷

Combined Cross-Linking and Photorefractive Keratectomy

Combining CXL and PRK has been proposed to stabilize the cornea while providing greater improvement in visual function. It was postulated that simultaneous topography-guided PRK with CXL might be an alternative option for optimizing refractive outcomes of keratoconus with a single treatment. However, a major concern with simultaneous procedures is that CXL alone has been shown to gradually induce changes in anterior corneal curvature that do not stabilize until 6 to 12 months postoperatively. Additionally,

increased risk of stromal haze after simultaneous combined procedures remains a substantial concern with generalized adoption of this treatment method. The exact sequence of these procedures, whether simultaneous or sequential, and the long-term safety of surface ablation in the setting of ectasia, have yet to be determined.¹²⁸⁻¹³⁰

Intrastromal Corneal Ring Segments

Indications

Intrastromal corneal ring segments (ICRS) help to create a more uniform corneal contour (i.e., a more central cone) in ectatic corneas that are clear centrally and have a corneal thickness of 400 μm or greater. Intrastromal corneal ring segments have been shown to improve UCVA and corrected visual acuity, reduce high-order corneal aberrations, and facilitate the fitting of contact lenses. They are not indicated in subclinical disease and do not alter the progression of the disease process. Visual acuity improvements are usually the result of reduction in astigmatism, central flattening, and better contact lens tolerance.¹³¹

The main types of ICRS used for corneal ectasia are Intacs, Ferrara rings, and Kerarings. Intacs segments are approved for use in the United States. They consist of a pair of semicircular pieces of polymethyl methacrylate, each one having a circumference arc length of 150° and a hexagonal transverse shape. The optical zone in Intacs is approximately 7 mm, whereas the Ferrara and Kerarings have an optical zone of approximately 4.5 to 5 mm. The smaller optical zone allows for more efficacy in corneal flattening at the expense of increased visual aberrations. The other kinds of available rings include Intacs SK, which have an optical zone of 6 mm and a round design to minimize glare. The surgical planning is based on the location of the steepest axis, the extent of ectatic area, and the refraction. Arc length and distance from the visual axis determine the amount of flattening. Implant manufacturers usually suggest a nomogram to be followed for the implantation of the ICRS.

An alternative to intracorneal rings, Corneal Allogenic Intrastromal Ring Segments (CAIRS) was first described in 2017.¹³² The procedure involves harvesting a ring of corneal tissue from a donor graft. Long-term results on CAIRS with or without CXL are awaited.

Technique Options

Mechanical channel dissection for placement of an ICRS utilizes a suction ring with a specially designed stainless steel keratome for creating channels at 70% to 80% depth in the cornea.

The femtosecond laser creates channels of a specifically set diameter and depth (80% of thinnest local pachymetry). Either Scheimpflug or OCT-generated pachymetry maps are required to measure thickness along the entire course of the corneal channel dissection to avoid intraoperative perforation. The rings are then used to dissect the channels, leaving them entirely within the stroma. The wound is sutured.

Outcomes

Intrastromal corneal ring segments have been shown to provide similar visual and refractive outcomes for keratoconus patients when either mechanical or femtosecond methods of channel creation were used.^{4, 133-136} Ring segment insertion can improve UCVA and CDVA as well as contact lens tolerance.^{131, 134-151} Most studies have suggested that ICRS may be most effective in patients with moderate keratoconus (<58.0 D).^{131, 137, 148} However, the change in astigmatism can be unpredictable.¹⁵² Loss of CDVA in both types of ICRS may be due to induced irregular astigmatism.¹³⁷

Contraindications

As per the FDA, Intacs implantation is contraindicated in keratoconus patients who can achieve functional vision using contact lenses, are younger than 21, do not have clear central corneas, and have a corneal thickness less than 450 μm at the proposed incision site. Additionally, ICRS implantation is contraindicated in pellucid marginal degeneration with extreme corneal thinning.^{55, 153}

Complications

Complications with both forms of channel creation and with both types of FDA-approved ICRS include infection, decreased vision, intraoperative perforation, postoperative segment

extrusion now seen later in the course, epithelial defects, corneal scarring, and corneal melting. The presence of postoperative lamellar intrastromal channel creamy-white deposits has also been documented and is found in up to 74% of cases.^{4, 154} These deposits consist of lipids and keratocytes and are thought to arise in response to corneal injury and activation of keratocytes, but they do not appear to alter the functional outcomes of the ICRS.^{4, 154, 155}

Complications of mechanical channel creation include anterior corneal perforation, superficial segment implantation, and postoperative segment migration.¹⁴⁵

Complications attributed to femtosecond channel creation include incomplete channel creation, intraoperative perforation, postoperative segment migration,¹⁵⁶ and decentration due to misalignment of the cornea and pupil during applanation.¹⁵⁷ In some cases, the ring segments may need to be removed owing to complications. If keratoplasty becomes necessary in the future, the rings should be removed prior in a separate procedure.

Combined Cross-Linking and Intrastromal Corneal Ring Segments

Implantation of ICRS combined with CXL has been shown to be effective in stopping progression of keratoconus and improving visual function. The combination of these treatments may result in a greater improvement than when these individual treatment modalities are used alone.¹³⁵ There is a lack of consensus as to whether CXL should be performed before or after ICRS. Some studies have suggested that the greatest improvement in keratoconus occurs when ICRS and CXL are performed in the same session.¹³⁸ Other studies have demonstrated the greatest improvements when implantation of ICRS was followed by CXL treatment.^{135, 158} Additional studies described the need for modification of laser power settings with femtosecond channel creation when attempting ICRS following CXL because it is difficult to create channels for ICRS using the laser in corneas that have undergone CXL.¹⁵⁹ Many of these studies were performed with ICRS products not available in the United States. A meta-analysis on six studies that reported 12-month follow-up outcomes showed no significant differences in uncorrected and best-corrected visual acuity and cylindrical refractive error between same day ICRS and CXL, ICRS first, and CXL first. However, results with simultaneous surgery were superior to the CXL-first technique in terms of spherical refractive errors and flat-K, and to both CXL first and ICRS first in terms of steep-K.¹⁶⁰

Partial-Thickness/Lamellar Keratoplasty

Indications

Lamellar keratoplasty using deep anterior lamellar keratoplasty (DALK) techniques can be considered for contact lens-intolerant patients or patients with inadequate visual function. The DALK technique removes all or nearly all the corneal stroma down to Descemet's membrane. The benefit of DALK is that it preserves the host endothelial layer, thereby eliminating the risk of endothelial rejection and avoiding the higher chronic endothelial cell loss associated with PK.^{5, 161, 162} Deep anterior lamellar keratoplasty also has the advantage of requiring less stringent tissue requirements than PK (i.e., tissue with low endothelial cell count is acceptable, making more tissue available for surgery).

Crescentic lamellar keratoplasty is a less commonly performed surgery but can be used when the area of maximal thinning is in the periphery, such as in cases of pellucid marginal degeneration. The crescentic recipient bed is achieved by using a smaller trephine on the central edge. Special surgical techniques such as tuck-in lamellar keratoplasty (TILK), are designed to provide adequate tectonic support to the central and peripheral cornea in patients with advanced keratoconus extending to the corneal periphery. The donor lenticule has a peripheral partial thickness flange of posterior stromal tissue that integrates into the host to provide tectonic support at the peripheral cornea.¹⁶³ Peripheral thinning and ectasia can also be managed in two stages by performing a standard decentered lamellar procedure for tectonic support, followed 4 to 6 months later by a central PK. In cases of keratoglobus in which thinning is diffuse, particularly in the periphery, lamellar keratoplasty may lend tectonic support and flatten the cornea. However, prominent folds may result.

DALK Technique Options

Procedure options for DALK include the Melles technique, the Anwar big-bubble technique, and variations on the big-bubble and manual dissection technique.^{5, 164} The Melles technique involves injecting air into the anterior chamber to better assess the depth of the lamellar resection.^{5, 161, 165} The Anwar big-bubble technique involves trephining the cornea, followed by injecting air to achieve baring of Descemet's membrane.^{5, 161} The large-bubble modification of the big-bubble technique utilizes a shallower trephination with a larger expansion of the bubble to the periphery.^{166, 167} Manual dissection techniques are recommended in patients with deep corneal scars or scars involving the Descemet's membrane. Appropriate depth of the corneal lamella to be dissected is judged clinically or with an AS-OCT. The superficial lamella of the cornea is taken off using a crescent blade and the deeper layers are dissected slowly until the pre-Descemetic layers are reached. The femtosecond-assisted big-bubble technique utilizes a femtosecond laser program to trephine the cornea. Subsequently, a big bubble is created using a needle or cannula to bare the Descemet's membrane, and a femtosecond-laser trephined cornea is sutured on to the recipient bed.¹⁶⁸⁻¹⁷⁰

Outcomes

There are conflicting reports on the data comparing DALK and PK. The thickness of the host residual stromal bed after dissection³⁴ has been correlated with variation in postoperative visual acuity and contrast sensitivity following DALK. When baring of Descemet's membrane was achieved, visual results were reported to be comparable to PK.^{161, 171-177} A study from the United Kingdom reported that eyes with a recipient corneal bed thickness of less than 20 μm had spectacle-corrected visual acuities similar to eyes with PK. The spectacle-corrected visual acuity of DALK eyes decreased significantly with increasing thickness of recipient stroma. Deep anterior lamellar keratoplasty eyes with a recipient tissue of 80 μm or more tended to show a reduction in photopic contrast sensitivity.¹⁷¹ Similar CDVA outcomes have been reached with the two procedures, but more studies have found a higher percentage of patients achieving 20/20 visual acuity with PK compared with DALK,^{5, 161, 178, 179} although this difference was not always statistically significant.¹⁸⁰ The difference may be associated with the surgeon's learning curve and may decrease with increased surgeon experience with the DALK technique.^{161, 181} One study found that DALK resulted in significantly higher myopia compared with PK.¹⁸² Endothelial cell loss was significantly lower with DALK that was performed without perforation of Descemet's membrane compared with full-thickness keratoplasty.¹⁸³⁻¹⁸⁷ High IOP and corneal infection were more common findings in the PK groups compared with the DALK groups. A 2014 Cochrane review reported no difference in best-corrected visual acuity, graft survival, or keratometric outcomes between patients undergoing DALK or PK.¹⁸⁸ They did report some evidence that rejection is more likely in the PK group compared with the DALK group. The review authors concluded that there was insufficient evidence to determine which technique offers better overall outcomes.

Contraindications and Complications

Relative contraindications to DALK include severe corneal scarring associated with hydrops, in which corneal perforation is more likely. Other potential contraindications include deep stromal vascularization and severe thinning. Complications include infection, suture-related complications, stromal graft rejection, and graft failure due to interface opacity. Complications unique to DALK include perforation of the cornea during surgery leading to conversion to PK.¹⁶¹ The incidence of stromal rejection is reported to be between 2% and 12%. This variation prompted the authors to suggest that postoperative corticosteroid treatment regimens may play an important role in the postoperative management of DALK.¹⁸⁹ Deep anterior lamellar keratoplasty carries no risk of endothelial rejection; thus the overall rejection rate is lower than with PK. Deep anterior lamellar keratoplasty is believed to be associated with lower risk of globe rupture compared with PK because it leaves the Descemet's membrane and endothelial layer intact, which may help preserve globe integrity.¹⁹⁰

Full-Thickness Keratoplasty/Penetrating Keratoplasty

Penetrating keratoplasty was the mainstay of incisional surgical treatment for keratoconus prior to the introduction of DALK, and long-term graft survival has been reported at 95% at 5 years and 89% at 10 years according to the Australian Corneal Graft registry.⁵ Recent data from the Eye Bank Association of America¹⁹¹ reported a continuing trend of declining keratoplasty procedures for keratoconus from 2011 to 2022. Improvement in contact lens design and availability of cross-linking are likely responsible for the decreasing number of keratoplasty procedures for corneal ectasia. Penetrating keratoplasty was the preferred surgical procedure for the treatment of corneal ectasia compared with anterior lamellar keratoplasty (91.2% vs. 8.8%).

Indications

Keratoplasty is indicated when a patient can no longer achieve functional vision with eyeglasses and contact lenses. Persistent corneal edema following hydrops is also an indication for full-thickness keratoplasty. Penetrating keratoplasty may be preferred over DALK in cases of deep stromal scarring, in which perforation is more likely to occur during deep lamellar resection. When ectasia occurs in the far periphery of the cornea, a lamellar graft can be performed for tectonic support as a primary procedure, and additional PK can be performed later for visual rehabilitation. Large-diameter PK has been used successfully in patients with pellucid marginal degeneration.¹⁹²

Technique Options

- ◆ Mechanical: Trephination for PK includes the use of oversize and same-size trephines for donors and recipients. Axial length and graft-host disparity may have an impact on postoperative refractive error. Same-size grafts for PK in short eyes can result in postoperative hyperopia, whereas myopia will likely result when an oversized graft is used in eyes with long axial lengths.
- ◆ Femtosecond laser surgery: Femtosecond laser-assisted keratoplasty (FLAK) is a technique that utilizes the femtosecond laser for trephining both the donor and recipient corneas. With this technique, the same pattern of laser trephination is used for both donor and recipient, designated as top-hat, mushroom, or zigzag. Theoretical advantages of FLAK over standard PK are increased wound strength, earlier removal of sutures, faster visual rehabilitation,¹⁹³⁻¹⁹⁶ and potentially decreased astigmatism.¹⁹⁴⁻¹⁹⁸ However, studies have shown no long-term benefit when compared with mechanical trephination.

Outcomes

- ◆ Mechanical: PK has been shown to be a safe and effective procedure with good visual acuity outcomes for all levels of severity in keratoconus.¹⁹⁹⁻²⁰¹ Suturing techniques have not been demonstrated to affect outcomes. Less graft/host-size disparity seems to induce less myopic shift.^{200, 201} Repeat PK has also been performed with success for cases of recurrent ectasia following corneal grafts and is related either to incomplete excision of the cone or to progression of the disease. These cases occurred, on average, many years after the original PK and were often bilateral, suggesting that the etiology of recurrence may relate to host cellular and/or biochemical factors.^{199, 202} There have also been case reports of keratoconus following PK in patients with no pre-existing keratoconus, suggesting that donor tissue may have had undiagnosed corneal pathology.²⁰³
- ◆ Femtosecond laser surgery: Earlier suture removal is possible with FLAK owing to greater mechanical stability and wound-healing advantages.¹⁹⁵ Studies have shown that the FLAK procedure resulted in significant improvement in astigmatism up to 6 months following the procedure; but this improvement did not persist beyond 6 months following surgery.¹⁹⁴

Contraindications and Complications

- ◆ Penetrating keratoplasty may be contraindicated if many prior full-thickness corneal transplants have failed or if extensive anterior segment scarring is present. When corneal thinning extends near the limbus, PK is more challenging and carries a greater

risk of failure. The complications of PK in ectasia include infection, rejection, failure, glaucoma, cataract, and poor refractive outcomes (including anisometropia or high corneal astigmatism). A meta-analysis showed that the rate of graft rejection in DALK is significantly lower than that after PK (odds ratio [OR] = 0.28; 95% confidence interval, 0.15–0.50; $P < 0.001$), but the rate of graft failure is similar (OR = 1.05; 95% confidence interval, 0.81–1.36).²⁰⁴ In cases of PK failure without ectasia or significant astigmatism, endothelial keratoplasty can be performed as a treatment for endothelial failure.

FOLLOW-UP EVALUATION

Follow-up evaluation and visit intervals for patients with corneal ectasia are dictated by the age of the patient, the choice of treatment, and the severity and/or progression of the disease. Follow-up visits should include measurement of visual acuity, external examination, slit-lamp biomicroscopy, and assessment of corneal contour and thickness by both topography and tomography. Typically, annual follow-up was recommended for cases of ectasia; however, with the advent of CXL, more frequent follow-up (i.e., every 3–6 months) to look for progression is now warranted. Younger patients may need to be followed even more frequently. Ideally, progression would be identified before it starts to affect vision. Patients who see well with contact lenses yet experience an unstable fit should be examined to assess contact lens stability.

Postsurgical visits should include the above as well as additional measurements specific to the type of surgical follow-up care indicated. After keratoplasty, slit-lamp biomicroscopic examinations should be performed to assess the clarity and health of the cornea and to check for suture erosion and rejection. After DALK, additional investigations such as AS-OCT are warranted, especially in nonresolving corneal edema to look for Descemet's membrane detachment and double anterior chamber. Selective suture removal can be initiated in accordance with topographic findings to manage astigmatism that then improves visual function. Depending on the method of closure, suture removal typically begins after 3 to 6 months to ensure corneal wound stability and to minimize the risk of wound dehiscence. In the case of loose sutures, suture erosion, or vascularization, sutures may be removed earlier to prevent infection or rejection.

Post-PK patients should be made aware of the warning signs of rejection, including redness, sensitivity to light, vision change, and/or pain, and they should be advised to seek medical attention promptly if these signs or symptoms occur. The practitioner should be aware of the slit-lamp biomicroscopic findings of epithelial, stromal, and endothelial rejection. An epithelial rejection line/ridge may appear alone or with subepithelial infiltrates. Stromal and endothelial rejection may include stromal edema, and endothelial rejection may include pigmented keratic precipitates on the endothelium as well as an endothelial rejection line and possible anterior chamber reaction. Therapeutic modalities for treating graft rejection include topical and oral corticosteroids as well as subconjunctival or sub-Tenon corticosteroid injections, and occasionally systemic corticosteroids. The intensity of steroid treatment will depend on the severity of the rejection. Patients at high risk for rejection may be candidates for systemic immunosuppression to reduce this risk.

Corneal pachymetry may be useful in evaluating endothelial function, particularly if baseline thickness data are available. Serial corneal tomography may be used to manage postoperative astigmatism as well as track corneal thickness over time. The potential diurnal variation in corneal thickness should always be considered when comparing measurements. Patients using long-term topical corticosteroids should also have their IOP checked at regular intervals to rule out corticosteroid-induced IOP elevation.²⁰⁵ Other assessments that should be considered include pupil dilation to estimate the cup-to-disc ratio, visual field testing, and stereo disc photography or OCT imaging of the retinal nerve fiber layer to look for early signs of optic nerve damage associated with elevated IOP. (See Appendix 2 for additional information on how IOP is determined in diseased or postsurgical corneas.)

PROVIDER AND SETTING

The diagnosis and management of corneal ectasia requires broad ophthalmic medical and surgical skills. Patients with corneal ectasias should be promptly referred to an ophthalmologist with expertise in the management of corneal disorders if any of the following occurs:

- ◆ Visual loss

- ◆ Loss of functional vision
- ◆ Acute hydrops
- ◆ Progression of the disease
- ◆ Onset in childhood or young adulthood

COUNSELING AND REFERRAL

Patients with corneal ectasia have many medical and surgical treatment options. When ectasia is diagnosed early, tomographic evaluation to determine the extent of the disease and to establish a baseline to determine when and if progression occurs is crucial. A discussion of the benefits and potential risks of early CXL in patients at high risk for progression (e.g., pre-puberty) or who historically have noted progressive loss of vision should be undertaken. Waiting for additional loss of best corrected vision or progression in patients with ectasia should be avoided whenever possible. Referral is appropriate in this situation. In families with a history of keratoconus it may be advisable to screen youngsters for subclinical keratoconus. Eyeglasses and contact lens are the mainstay of treatment for the majority of patients with ectasia. When these approaches cannot improve vision, or when there is loss of visual function, referral to an ophthalmologist trained in surgical treatments for corneal ectasia is indicated. All patients should be counseled to avoid eye rubbing whether they have a history of allergies or not. Also, patients with a history of allergy and/or atopy may also need referral to an allergist and/or dermatologist. Patients with floppy eyelid disease may be best managed by an oculoplastics specialist. If there is evidence of newly diagnosed asthma, or in the case of obstructive sleep apnea or heart valve disease associated with floppy eyelid syndrome, referral to primary care and/or other medical specialists may also be indicated.

Many patients ask if lifestyle change can alter the course of the disease. To date, only eye rubbing has been linked to progression. This should be discussed with all patients, since many may not be fully aware to what extent they do rub their eyes and inadvertently worsen their disease. A behavior modification approach for controlling chronic habits of abnormal rubbing has been suggested to prevent progression of keratoconus. Patients with keratoconus who had vernal keratoconjunctivitis may need corneal transplant surgery earlier compared with those who did not have it. In addition, patients with atopy have higher risk for developing corneal hydrops.²⁰⁶

SOCIOECONOMIC CONSIDERATIONS

Epidemiological studies have reported global variation in the prevalence and incidence of keratoconus. A review estimated keratoconus prevalence between 0.2 and 4,790 per 100,000 persons and its incidence between 1.5 and 25 per 100,000 persons/year.²⁰⁷ Some of these figures date back to the pre-tomography era. In contrast to other chronic eye diseases such as glaucoma and age-related macular degeneration, ectasia, particularly keratoconus and postkeratorefractive ectasias, is more commonly seen in younger people 20 to 40 years old. The average estimated age of onset of keratoconus ranges from 9 to 28 years.^{7, 48, 208}

Corneal ectasias rarely lead to blindness, so these conditions are thought by some to have limited socioeconomic and public health significance. However, because ectasias such as keratoconus occur in younger individuals who are considerably more active and in or entering their prime earning and child-rearing years, modest deficits in visual function can result in a disproportionate impact on quality of life and social burden. A retrospective cohort study showed that socioeconomic factors were important predictors of keratoconus severity and need for corneal transplantation. Compared with commercially insured patients, Medicaid recipients were more likely to have severe keratoconus, independent of social and clinical confounders. Male sex was independently associated with progression.²⁰⁹ Medicare and Medicaid recipients were more likely to require transplantation compared with commercially insured patients.²¹⁰

Quality of Life

Keratoconus is associated with a significant decrease in optical quality resulting from increases in ocular aberrations and a loss of corneal transparency which can affect quality of life. The CLEK Study Group utilized the National Eye Institute Visual Function Questionnaire (NEI-VFQ) to assess vision-related quality of life (V-QoL) in their cohort. The NEI-VFQ is a V-QoL instrument designed to assess a patient's perception of visual function and quality of life in 12 different domains. It was administered to 1,166 CLEK study patients at their first annual follow-

up evaluation.²¹¹ The questionnaire revealed that binocular-entrance visual acuity worse than 20/40 was associated with lower quality of life scores on each of the 12 scales except General Health and Ocular Pain. A keratometric reading averaging over 52.0 D (average of both eyes) was associated with lower scores on the Mental Health, Role Difficulty, Driving, Dependency, and Ocular Pain scales. A follow-up study demonstrated that keratoconus is associated with a significantly impaired V-QoL that continues to decline over time.²¹²

Economics

Because of the significantly reduced vision-related quality of life and the relatively young onset of this disease, the economic burden of caring for keratoconus patients is a significant public health problem. One study used a Markov decision model to estimate the incremental lifetime cost for treatment of keratoconus compared with the lifetime expected cost of treating myopia. This study looked at costs for clinic visits, contact lenses, fitting fees, surgical procedures, and complications. The expected increment in the lifetime cost of treating keratoconus compared with treating myopia was determined to be \$25,168.²¹³ The factors that most influenced the lifetime cost were the probability of corneal transplantation and subsequent re-raft. This study found that the cost of routine care likely has relatively little influence on the lifetime cost of care, although for keratoconus the cost of routine care is not trivial. This study concluded that the expected lifetime cost for treatment of keratoconus presents a significant cost to both patient and payers.

Individuals with keratoconus have a higher utilization of eye care services than the general population. A study evaluated the cost-effectiveness of corneal collagen cross-linking for progressive keratoconus using a Markov-type model.²¹⁴ The authors compared two cohorts, one receiving CXL treatment and the other no treatment, and followed both groups over a lifetime, taking into account the probability of need for corneal transplantation and associated complications and costs. Assuming a 10-year stabilizing effect of CXL, this treatment would be cost-effective relative to what treatments and associated costs were predicted to occur over 10 years within the no-treatment cohort. Corneal cross-linking halts disease progression in keratoconus. It is expected that this would reduce the long-term costs associated with the disease, mainly associated with a reduction in the need for changes in spectacle or contact lens prescriptions, clinic visits to optometrists and ophthalmologists, rates of corneal transplantation, and loss of productivity for patients and their family while attending appointments. A 6-year study evaluated the association of scleral contact lens use on the risk for keratoplasty for people with keratoconus. Scleral (HR = 0.19, 95% confidence interval, 0.09–0.39) or RGP (HR = 0.30, 95% confidence interval, 0.17–0.52) contact lens use significantly lowered the hazard of undergoing keratoplasty when compared with no contact lens use.²¹⁵ Another study attempted to quantify the conferred patient value (improvement in quality of life and/or length of life), comparative effectiveness, and cost-effectiveness of PK for keratoconus compared with other interventions across different medical specialties.²¹⁶ These parameters were assessed using cost-utility analysis with value-based medicine criteria. This study concluded that PK for patients with severe keratoconus was very cost-effective compared with other health care interventions. It should be noted that FLAK is not fully covered by insurance and CXL may not be covered unless progression can be demonstrated.

APPENDIX 1. QUALITY OF OPHTHALMIC CARE CORE CRITERIA

*Providing quality care
is the physician's foremost ethical obligation, and is
the basis of public trust in physicians.
AMA Board of Trustees, 1986*

Quality ophthalmic care is provided in a manner and with the skill that is consistent with the best interests of the patient. The discussion that follows characterizes the core elements of such care.

The ophthalmologist is first and foremost a physician. As such, the ophthalmologist demonstrates compassion and concern for the individual, and utilizes the science and art of medicine to help alleviate patient fear and suffering. The ophthalmologist strives to develop and maintain clinical skills at the highest feasible level, consistent with the needs of patients, through training and continuing education. The ophthalmologist evaluates those skills and medical knowledge in relation to the needs of the patient and responds accordingly. The ophthalmologist also ensures that needy patients receive necessary care directly or through referral to appropriate persons and facilities that will provide such care, and he or she supports activities that promote health and prevent disease and disability.

The ophthalmologist recognizes that disease places patients in a disadvantaged, dependent state. The ophthalmologist respects the dignity and integrity of his or her patients and does not exploit their vulnerability.

Quality ophthalmic care has the following optimal attributes, among others.

- ◆ The essence of quality care is a meaningful partnership relationship between patient and physician. The ophthalmologist strives to communicate effectively with his or her patients, listening carefully to their needs and concerns. In turn, the ophthalmologist educates his or her patients about the nature and prognosis of their condition and about proper and appropriate therapeutic modalities. This is to ensure their meaningful participation (appropriate to their unique physical, intellectual and emotional state) in decisions affecting their management and care, to improve their motivation and compliance with the agreed plan of treatment, and to help alleviate their fears and concerns.
- ◆ The ophthalmologist uses his or her best judgment in choosing and timing appropriate diagnostic and therapeutic modalities as well as the frequency of evaluation and follow-up, with due regard to the urgency and nature of the patient's condition and unique needs and desires.
- ◆ The ophthalmologist carries out only those procedures for which he or she is adequately trained, experienced and competent, or, when necessary, is assisted by someone who is, depending on the urgency of the problem and availability and accessibility of alternative providers.
- ◆ Patients are assured access to, and continuity of, needed and appropriate ophthalmic care, which can be described as follows.
 - The ophthalmologist treats patients with due regard to timeliness, appropriateness, and his or her own ability to provide such care.
 - The operating ophthalmologist makes adequate provision for appropriate pre- and postoperative patient care.
 - When the ophthalmologist is unavailable for his or her patient, he or she provides appropriate alternate ophthalmic care, with adequate mechanisms for informing patients of the existence of such care and procedures for obtaining it.
 - The ophthalmologist refers patients to other ophthalmologists and eye care providers based on the timeliness and appropriateness of such referral, the patient's needs, the competence and qualifications of the person to whom the referral is made, and access and availability.
 - The ophthalmologist seeks appropriate consultation with due regard to the nature of the ocular or other medical or surgical problem. Consultants are suggested for their skill, competence, and accessibility. They receive as complete and accurate an accounting of the problem as necessary to provide efficient and effective advice or intervention, and in turn respond in an adequate and timely manner.

- The ophthalmologist maintains complete and accurate medical records.
- ◆ On appropriate request, the ophthalmologist provides a full and accurate rendering of the patient's records in his or her possession.
- ◆ The ophthalmologist reviews the results of consultations and laboratory tests in a timely and effective manner and takes appropriate actions.
- ◆ The ophthalmologist and those who assist in providing care identify themselves and their profession.
- ◆ For patients whose conditions fail to respond to treatment and for whom further treatment is unavailable, the ophthalmologist provides proper professional support, counseling, rehabilitative and social services, and referral as appropriate and accessible.
- ◆ Prior to therapeutic or invasive diagnostic procedures, the ophthalmologist becomes appropriately conversant with the patient's condition by collecting pertinent historical information and performing relevant preoperative examinations. Additionally, he or she enables the patient to reach a fully informed decision by providing an accurate and truthful explanation of the diagnosis; the nature, purpose, risks, benefits, and probability of success of the proposed treatment and of alternative treatment; and the risks and benefits of no treatment.
- ◆ The ophthalmologist adopts new technology (e.g., drugs, devices, surgical techniques) in judicious fashion, appropriate to the cost and potential benefit relative to existing alternatives and to its demonstrated safety and efficacy.
- ◆ The ophthalmologist enhances the quality of care he or she provides by periodically reviewing and assessing his or her personal performance in relation to established standards, and by revising or altering his or her practices and techniques appropriately.
- ◆ The ophthalmologist improves ophthalmic care by communicating to colleagues, through appropriate professional channels, knowledge gained through clinical research and practice. This includes alerting colleagues of instances of unusual or unexpected rates of complications and problems related to new drugs, devices or procedures.
- ◆ The ophthalmologist provides care in suitably staffed and equipped facilities adequate to deal with potential ocular and systemic complications requiring immediate attention.
- ◆ The ophthalmologist also provides ophthalmic care in a manner that is cost effective without unacceptably compromising accepted standards of quality.

Reviewed by: Council
Approved by: Board of Trustees
October 12, 1988

2nd Printing: January 1991
3rd Printing: August 2001
4th Printing: July 2005

APPENDIX 2. DETERMINATION OF INTRAOCULAR PRESSURE IN DISEASED OR POSTSURGICAL CORNEAS

Intraocular pressure (IOP) assessment in diseased corneas may be very inaccurate when measured only by Goldmann applanation tonometry (GAT). This is due to a host of reasons, including disease-induced and treatment-induced alterations in corneal thickness, hydration, corneal curvature/astigmatism, an irregular corneal epithelial surface, and corneal stromal scarring. All these factors can affect the estimation of the inherently subjective endpoint of GAT (i.e., the “just-touching” inside edges of the semicircular mires viewed through the Goldmann applanation prism tip). Therefore, use of alternative techniques to determine IOP in these diseased, abnormal, or surgically altered corneas is strongly advised. Such techniques are described below.

- ◆ Applanation techniques use various devices to measure IOP.
 - ◆ Pneumotonometer: This technology uses a pneumatic sensor (consisting of a piston floating on an air bearing) with a 5-mm fenestrated silicone tip that conforms to the cornea. The balance between the flow of air from the machine and the resistance to flow from the cornea affects the movement of the piston, and this movement is used to calculate the IOP. This device generates 40 readings per second and also measures ocular pulse amplitude. Topical anesthesia is required.
 - ◆ Non-Goldmann applanation tonometer: This technology utilizes a free-floating 1-mm microstrain gauge transducer to detect transmitted IOP. The transducer is surrounded by an outer ring that flattens the adjacent cornea, reducing its influence on measurement. These devices measure 500 samples per second and average eight or ten readings for each IOP determination within confidence limits. Topical anesthesia is required.
 - ◆ Ocular response analyzer: This technology uses a collimated air pulse to cause the cornea to move inward and then outward in a bidirectional applanation process to measure the biomechanical properties of the cornea (i.e., hysteresis) and calculate a “corneal-compensated” and GAT-equivalent IOP. This technology also measures ocular pulse amplitude and does not require topical anesthesia.
- ◆ The contour-matching Pascal technique (dynamic contour tonometer) utilizes a piezoresistive sensor embedded into the tonometer tip to digitally sample IOP 100 times per second. The concave tip shape causes a relaxation of the cornea to conform to the dynamic contour tonometer tip and minimizes any influence of corneal properties on IOP measurements. An internal microprocessor then analyzes this direct proportional signal and extracts IOP and ocular pulse amplitude. The device calculates an IOP independent of corneal properties. It requires 6 seconds or six ocular pulse cycles to determine the IOP, and it requires topical anesthesia. This is mounted to the slit lamp.
- ◆ The rebound tonometry deceleration technique utilizes an induction coil to magnetize a small plastic-tipped metal probe that is rapidly fired against the cornea (0.25 m/sec). Software analyzes the rate of deceleration and the contact time of the probe against the cornea (approximately 0.05 sec), the relative magnitude of which is proportional to IOP and from which the IOP is calculated. Six measurements are required for accuracy. This technology does not require topical anesthesia.
- ◆ The Mackay-Marg tonometer combines mechanisms of both applanation and indentation. It is available as a small, handheld, battery-powered device that requires topical anesthesia. The tonometer has a small applanating plunger from which the IOP is read electronically. Multiple readings are averaged.

Although applanation and rebound tonometers are more influenced by corneal properties compared with other devices, they may more accurately and reproducibly estimate “true IOP” (relative to GAT) over the course of a patient’s corneal disease state. Nevertheless, it is very important to use the same valid technique consistently, from visit to visit, to detect clinically significant and meaningful IOP elevations. Early detection of elevated IOP will allow timely initiation of IOP-lowering therapy before irreversible optic nerve damage occurs. These eyes are frequently subject to either disease- or treatment-induced secondary IOP elevation, which often goes undetected when relying on GAT alone to determine IOP.

LITERATURE SEARCHES FOR THIS PPP

Literature searches of the PubMed database were conducted on March 3, 2022; the search strategies are listed below. Specific limited update searches were conducted on June 7, 2023. The searches had added filters for human, English-language randomized controlled trials and systematic reviews and date limiters to capture literature published since June 27, 2018. The panel analyzed 199 studies of which 23 were included in the PPP. The literature searches with the disease condition and the search terms patient values and preferences didn't yield results. The literature searches for economic evaluation and treatment cost did not yield relevant studies.

All: Corneal ectasia[tiab]

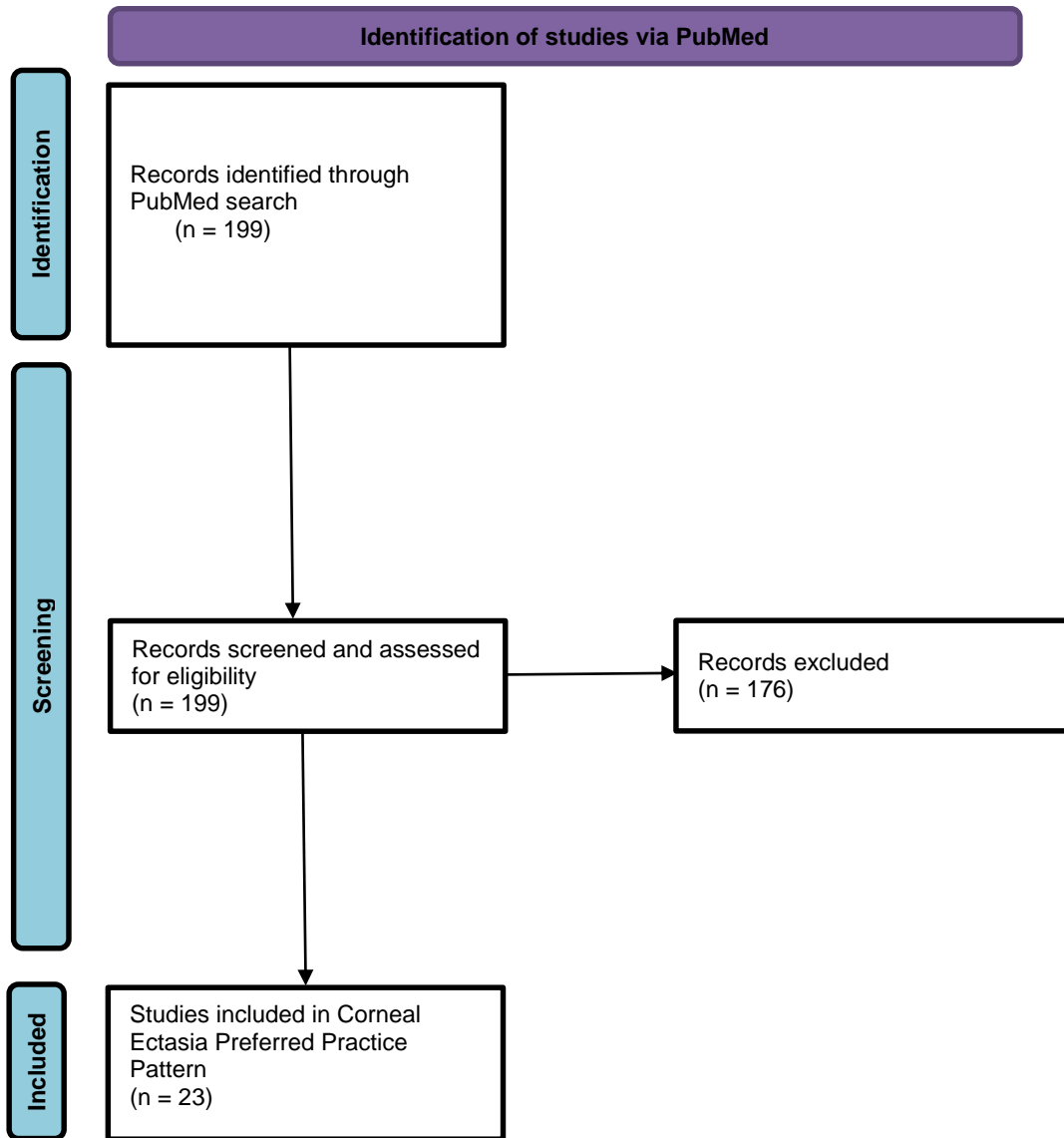
Treatment: (cornea*[tiab] AND ectasia[tiab]) OR keratectasia[tiab] OR "corneal ectasia"[tiab] OR keratoectasia[tiab] OR (dilatation, pathologic[mh] AND cornea[tiab]) AND (Corneal Diseases/surgery[mh] OR Corneal Diseases/therapy[mh] OR "Keratoconus/surgery"[Mesh] OR Keratoconus/therapy[mh] OR intrastromal[tiab] OR ring*[tiab] OR collagen cross*[tiab] OR keratectomy[tw] OR lamellar keratoplasty[tiab] OR Keratoplasty, Penetrating[mh] OR Contact Lenses[mh] OR Eyeglasses[mh] OR manage[tiab] OR management[tiab] OR treat[tiab] OR treatment*[tiab])

Diagnostic: ((cornea*[tiab] AND ectasia[tiab]) OR keratectasia[tiab] OR "corneal ectasia"[tiab] OR keratoectasia[tiab] OR (dilatation, pathologic[mh] AND cornea[tiab])) AND ((Corneal Diseases/diagnosis[mh]) AND (Corneal Topography[mh] OR keratometry[tiab] OR pachometr*[tiab] OR ultra-structur*[tiab] OR ultrastructure*[tiab] OR pachymetr*[tiab] Diagnostic Techniques, Ophthalmological[mh]))

Physiopathology: ((cornea*[tiab] AND ectasia[tiab]) OR keratectasia[tiab] OR "corneal ectasia"[tiab] OR keratoectasia[tiab] OR (dilatation, pathologic[mh] AND cornea[tiab])) AND (Corneal Diseases/pathology[MAJR] OR Corneal Diseases/physiology[MAJR] OR Corneal Diseases/physiopathology[MAJR])

Cost of Illness: ("cornea[tiab] AND ectasia"[tiab]) AND (economics[All Fields] OR economics[MeSH Terms] OR cost[All Fields] OR cost[MeSH Terms])

Patient Values: corneal ectasia[tiab] AND (patient values[tiab] OR patient preferences[tiab])



From: Page MJ, McKenzie JE, Bossuyt PM, Boutron I, Hoffmann TC, Mulrow CD, et al. The PRISMA 2020 statement: an updated guideline for reporting systematic reviews. *BMJ* 2021;372:n71. doi: 10.1136/bmj.n71

For more information, visit: <http://www.prisma-statement.org/>

RELATED ACADEMY MATERIALS

Basic and Clinical Science Course

External Disease and Cornea (Section 8, 2023-2024)

Focal Points

Diagnosis and Management of Noninfectious Corneal Ulceration and Melting (2015)

Risk Factors for Post-LASIK Ectasia (2015)

Preferred Practice Pattern® Guidelines – Free download available at www.aao.org/ppp

Comprehensive Adult Medical Eye Evaluation (2020)

Pediatric Eye Evaluations (2022)

REFERENCES

1. Scottish Intercollegiate Guidelines Network (SIGN). *SIGN 50: A guideline developer's handbook*. Edinburgh: SIGN; 2015. (SIGN publication no. 50). [November 2015]. Available from URL: <http://www.sign.ac.uk>. Accessed November 1, 2023.
2. Guyatt GH, Oxman AD, Vist GE, et al. GRADE: An emerging consensus on rating quality of evidence and strength of recommendations. *BMJ*. 2008;336:924-926.
3. GRADE Working Group. Organizations that have endorsed or that are using GRADE. <http://www.gradeworkinggroup.org/>. Accessed November 1, 2023.
4. Espandar L, Meyer J. Keratoconus: Overview and update on treatment. *Middle East Afr J Ophthalmol*. 2010;17:15-20.
5. Jhanji V, Sharma N, Vajpayee RB. Management of keratoconus: Current scenario. *Br J Ophthalmol*. 2011;95:1044-1050.
6. Pinero DP, Nieto JC, Lopez-Miguel A. Characterization of corneal structure in keratoconus. *J Cataract Refract Surg*. 2012;38:2167-2183.
7. Krachmer JH, Feder RS, Belin MW. Keratoconus and related noninflammatory corneal thinning disorders. *Surv Ophthalmol*. 1984;28:293-322.
8. Gordon-Shaag A, Millodot M, Kaiserman I, et al. Risk factors for keratoconus in Israel: A case-control study. *Ophthalmic Physiol Opt*. 2015;35:673-681.
9. Lucas SEM, Burdon KP. Genetic and environmental risk factors for keratoconus. *Annu Rev Vis Sci*. 2020;6:25-46.
10. Binder PS. Analysis of ectasia after laser in situ keratomileusis: Risk factors. *J Cataract Refract Surg*. 2007;33:1530-1538.
11. Moshirfar M, Albarracin JC, Desautels JD, et al. Ectasia following small-incision lenticule extraction (SMILE): A review of the literature. *Clin Ophthalmol*. 2017;11:1683-1688.
12. Sugar J, Macsai MS. What causes keratoconus? *Cornea*. 2012;31:716-719.
13. Bawazeer AM, Hodge WG, Lorimer B. Atopy and keratoconus: A multivariate analysis. *Br J Ophthalmol*. 2000;84:834-836.
14. Pellegrini M, Bernabei F, Friehmann A, Giannaccare G. Obstructive sleep apnea and keratoconus: A systematic review and meta-analysis. *Optom Vis Sci*. 2020;97:9-14.
15. Eliasi E, Bez M, Megreli J, et al. The association between keratoconus and body mass index: A population-based cross-sectional study among half a million adolescents. *Am J Ophthalmol*. 2021;224:200-206.
16. Giedd KK, Mannis MJ, Mitchell GL, Zadnik K. Personality in keratoconus in a sample of patients derived from the internet. *Cornea*. 2005;24:301-307.
17. Atilano SR, Coskun P, Chwa M, et al. Accumulation of mitochondrial DNA damage in keratoconus corneas. *Invest Ophthalmol Vis Sci*. 2005;46:1256-1263.
18. Arnal E, Peris-Martinez C, Menezo JL, et al. Oxidative stress in keratoconus? *Invest Ophthalmol Vis Sci*. 2011;52:8592-8597.
19. Balasubramanian SA, Pye DC, Willcox MD. Are proteinases the reason for keratoconus? *Curr Eye Res*. 2010;35:185-191.
20. Chwa M, Atilano SR, Hertzog D, et al. Hypersensitive response to oxidative stress in keratoconus corneal fibroblasts. *Invest Ophthalmol Vis Sci*. 2008;49:4361-4369.
21. Kenney MC, Chwa M, Atilano SR, et al. Increased levels of catalase and cathepsin V/L2 but decreased TIMP-1 in keratoconus corneas: Evidence that oxidative stress plays a role in this disorder. *Invest Ophthalmol Vis Sci*. 2005;46:823-832.
22. Smith VA, Matthews FJ, Majid MA, Cook SD. Keratoconus: Matrix metalloproteinase-2 activation and timp modulation. *Biochim Biophys Acta*. 2006;1762:431-439.
23. Lema I, Duran JA. Inflammatory molecules in the tears of patients with keratoconus. *Ophthalmology*. 2005;112:654-659.
24. Lema I, Sobrino T, Duran JA, et al. Subclinical keratoconus and inflammatory molecules from tears. *Br J Ophthalmol*. 2009;93:820-824.
25. Matthews FJ, Cook SD, Majid MA, et al. Changes in the balance of the tissue inhibitor of matrix metalloproteinases (TIMPs)-1 and -3 may promote keratocyte apoptosis in keratoconus. *Exp Eye Res*. 2007;84:1125-1134.

26. Randleman JB, Trattler WB, Stulting RD. Validation of the ectasia risk score system for preoperative laser in situ keratomileusis screening. *Am J Ophthalmol.* 2008;145:813-818.
27. Binder PS, Trattler WB. Evaluation of a risk factor scoring system for corneal ectasia after lasik in eyes with normal topography. *J Refract Surg.* 2010;26:241-250.
28. Moshirfar M, Tukan AN, Bundogji N, et al. Ectasia after corneal refractive surgery: A systematic review. *Ophthalmol Ther.* 2021;10:753-776.
29. Weed KH, MacEwen CJ, McGhee CN. The Dundee University Scottish keratoconus study II: A prospective study of optical and surgical correction. *Ophthalmic Physiol Opt.* 2007;27:561-567.
30. Gordon MO, Steger-May K, Szczotka-Flynn L, et al. Baseline factors predictive of incident penetrating keratoplasty in keratoconus. *Am J Ophthalmol.* 2006;142:923-930.
31. Sarezky D, Orlin SE, Pan W, VanderBeek BL. Trends in corneal transplantation in keratoconus. *Cornea.* 2017;36:131-137.
32. Barsam A, Petrushkin H, Brennan N, et al. Acute corneal hydrops in keratoconus: A national prospective study of incidence and management. *Eye (Lond).* 2015;29:469-474.
33. Fan Gaskin JC, Good WR, Jordan CA, et al. The Auckland keratoconus study: Identifying predictors of acute corneal hydrops in keratoconus. *Clin Exp Optom.* 2013;96:208-213.
34. American Academy of Ophthalmology Cornea/External Disease Panel. Preferred practice pattern guidelines. Corneal edema and opacification. San Francisco, CA: American Academy of Ophthalmology; 2023. www.aao.org/ppp. Accessed November 1, 2023.
35. Mannis MJ. Keratoconus: Why and when do we turn to surgical therapy? *Am J Ophthalmol.* 2006;142:1044-1045.
36. Reeves SW, Stinnett S, Adelman RA, Afshari NA. Risk factors for progression to penetrating keratoplasty in patients with keratoconus. *Am J Ophthalmol.* 2005;140:607-611.
37. Chuck RS, Dunn SP, Flaxel CJ, et al. Comprehensive adult medical eye evaluation preferred practice pattern. *Ophthalmology.* 2021;128:P1-P29.
38. Cusumano A, Roshanravan H, Chao-Shern C, et al. Genetic prescreening of a candidate for laser refractive surgery identifies risk for inadequate tissue response: A case report. *J Med Case Rep.* 2022;16:207.
39. Jinabhai A, Radhakrishnan H, O'Donnell C. Pellucid corneal marginal degeneration: A review. *Cont Lens Anterior Eye.* 2011;34:56-63.
40. Feder RS, Gan TG. Non-inflammatory ectatic disorders. In: Krachmer JH, Mannis MJ, eds. *Cornea: Fundamentals, diagnosis, and management*, 3rd ed. London: Elsevier, Inc., 2011:879; v. 1.
41. Ambrosio R, Jr., Nogueira LP, Caldas DL, et al. Evaluation of corneal shape and biomechanics before LASIK. *Int Ophthalmol Clin.* 2011;51:11-38.
42. Randleman JB, Woodward M, Lynn MJ, Stulting RD. Risk assessment for ectasia after corneal refractive surgery. *Ophthalmology.* 2008;115:37-50.
43. Sedaghat MR, Momeni-Moghaddam H, Ambrosio R, Jr., et al. Diagnostic ability of corneal shape and biomechanical parameters for detecting frank keratoconus. *Cornea.* 2018;37:1025-1034.
44. Weed KH, MacEwen CJ, Giles T, et al. The Dundee University Scottish keratoconus study: Demographics, corneal signs, associated diseases, and eye rubbing. *Eye (Lond).* 2008;22:534-541.
45. McMahon TT, Shin JA, Newlin A, et al. Discordance for keratoconus in two pairs of monozygotic twins. *Cornea.* 1999;18:444-451.
46. Steele TM, Fabinyi DC, Couper TA, Loughnan MS. Prevalence of Orbscan II corneal abnormalities in relatives of patients with keratoconus. *Clin Experiment Ophthalmol.* 2008;36:824-830.
47. Kaya V, Utine CA, Altunsoy M, et al. Evaluation of corneal topography with Orbscan II in first-degree relatives of patients with keratoconus. *Cornea.* 2008;27:531-534.
48. Zadnik K, Barr JT, Edrington TB, et al. Baseline findings in the collaborative longitudinal evaluation of keratoconus (CLEK) study. *Invest Ophthalmol Vis Sci.* 1998;39:2537-2546.
49. Bykhovskaya Y, Margines B, Rabinowitz YS. Genetics in keratoconus: Where are we? *Eye Vis (Lond).* 2016;3:16.
50. Bisceglia L, De Bonis P, Pizzicoli C, et al. Linkage analysis in keratoconus: Replication of locus 5q21.2 and identification of other suggestive Loci. *Invest Ophthalmol Vis Sci.* 2009;50:1081-1086.
51. Montes-Mico R, Charman WN. Intraocular pressure after excimer laser myopic refractive surgery. *Ophthalmic Physiol Opt.* 2001;21:228-235.
52. Rashad KM, Bahnassy AA. Changes in intraocular pressure after laser in situ keratomileusis. *J Refract Surg.* 2001;17:420-427.
53. Kirwan C, O'Keefe M. Measurement of intraocular pressure in LASIK and LASEK patients using the Reichert ocular response analyzer and Goldmann applanation tonometry. *J Refract Surg.* 2008;24:366-370.

54. Altinkaynak H, Kocasarac C, Dundar H, et al. Which tonometry in eyes with keratoconus? *Eye (Lond)*. 2016;30:431-437.
55. Belin MW, Asota IM, Ambrosio R, Jr., Khachikian SS. What's in a name: Keratoconus, pellucid marginal degeneration, and related thinning disorders. *Am J Ophthalmol*. 2011;152:157-162.
56. Ucakhan OO, Cetinkor V, Ozkan M, Kanpolat A. Evaluation of scheimpflug imaging parameters in subclinical keratoconus, keratoconus, and normal eyes. *J Cataract Refract Surg*. 2011;37:1116-1124.
57. Alio JL, Shabayek MH. Corneal higher order aberrations: A method to grade keratoconus. *J Refract Surg*. 2006;22:539-545.
58. de Sanctis U, Loiacono C, Richiardi L, et al. Sensitivity and specificity of posterior corneal elevation measured by Pentacam in discriminating keratoconus/subclinical keratoconus. *Ophthalmology*. 2008;115:1534-1539.
59. Schlegel Z, Hoang-Xuan T, Gatinel D. Comparison of and correlation between anterior and posterior corneal elevation maps in normal eyes and keratoconus-suspect eyes. *J Cataract Refract Surg*. 2008;34:789-795.
60. Li Y, Meisler DM, Tang M, et al. Keratoconus diagnosis with optical coherence tomography pachymetry mapping. *Ophthalmology*. 2008;115:2159-2166.
61. Ambrosio R, Jr., Caiado AL, Guerra FP, et al. Novel pachymetric parameters based on corneal tomography for diagnosing keratoconus. *J Refract Surg*. 2011;27:753-758.
62. Belin MW, Ambrosio R. Scheimpflug imaging for keratoconus and ectatic disease. *Indian J Ophthalmol*. 2013;61:401-406.
63. Silverman RH, Urs R, Roychoudhury A, et al. Epithelial remodeling as basis for machine-based identification of keratoconus. *Invest Ophthalmol Vis Sci*. 2014;55:1580-1587.
64. Serrao S, Lombardo G, Cali C, Lombardo M. Role of corneal epithelial thickness mapping in the evaluation of keratoconus. *Cont Lens Anterior Eye*. 2019;42:662-665.
65. Ambrosio R, Jr., Lopes B, Faria-Correia F, et al. Ectasia detection by the assessment of corneal biomechanics. *Cornea*. 2016;35:e18-20.
66. Martinez-Abad A, Pinero DP. New perspectives on the detection and progression of keratoconus. *J Cataract Refract Surg*. 2017;43:1213-1227.
67. Esporcatte LPG, Salomao MQ, Lopes BT, et al. Biomechanical diagnostics of the cornea. *Eye Vis (Lond)*. 2020;7:9.
68. Vinciguerra R, Ambrosio R, Jr., Elsheikh A, et al. Detection of keratoconus with a new biomechanical index. *J Refract Surg*. 2016;32:803-810.
69. Wang YM, Chan TCY, Yu M, Jhanji V. Comparison of corneal dynamic and tomographic analysis in normal, forme fruste keratoconic, and keratoconic eyes. *J Refract Surg*. 2017;33:632-638.
70. Atchison DA, Mathur A, Read SA, et al. Peripheral ocular aberrations in mild and moderate keratoconus. *Invest Ophthalmol Vis Sci*. 2010;51:6850-6857.
71. Bühren J, Kuhne C, Kohnen T. Defining subclinical keratoconus using corneal first-surface higher-order aberrations. *Am J Ophthalmol*. 2007;143:381-389.
72. Kosaki R, Maeda N, Bessho K, et al. Magnitude and orientation of Zernike terms in patients with keratoconus. *Invest Ophthalmol Vis Sci*. 2007;48:3062-3068.
73. Mihaltz K, Kranitz K, Kovacs I, et al. Shifting of the line of sight in keratoconus measured by a hartmann-shack sensor. *Ophthalmology*. 2010;117:41-48.
74. Pantanelli S, MacRae S, Jeong TM, Yoon G. Characterizing the wave aberration in eyes with keratoconus or penetrating keratoplasty using a high-dynamic range wavefront sensor. *Ophthalmology*. 2007;114:2013-2021.
75. Stulting RD. Corneal collagen cross-linking. *Am J Ophthalmol*. 2012;154:423-424.
76. Derakhshan A, Shandiz JH, Ahadi M, et al. Short-term outcomes of collagen crosslinking for early keratoconus. *J Ophthalmic Vis Res*. 2011;6:155-159.
77. Jacobs DS, Lee JK, Shen TT, et al. Refractive surgery preferred practice pattern. *Ophthalmology*. 2023;130:P61-P135.
78. Ferdi AC, Nguyen V, Gore DM, et al. Keratoconus natural progression: A systematic review and meta-analysis of 11,529 eyes. *Ophthalmology*. 2019;126:935-945.
79. Fujimoto H, Maeda N, Shintani A, et al. Quantitative evaluation of the natural progression of keratoconus using three-dimensional optical coherence tomography. *Invest Ophthalmol Vis Sci*. 2016;57:OCT169-175.
80. Gokul A, Patel DV, Watters GA, McGhee CNJ. The natural history of corneal topographic progression of keratoconus after age 30 years in non-contact lens wearers. *Br J Ophthalmol*. 2017;101:839-844.

81. Pallikaris IG, Kymionis GD, Astyrakakis NI. Corneal ectasia induced by laser in situ keratomileusis. *J Cataract Refract Surg.* 2001;27:1796-1802.
82. Argento C, Cosentino MJ, Tytiun A, et al. Corneal ectasia after laser in situ keratomileusis. *J Cataract Refract Surg.* 2001;27:1440-1448.
83. Binder PS, Lindstrom RL, Stulting RD, et al. Keratoconus and corneal ectasia after LASIK. *J Cataract Refract Surg.* 2005;31:2035-2038.
84. Gomes JA, Tan D, Rapuano CJ, et al. Global consensus on keratoconus and ectatic diseases. *Cornea.* 2015;34:359-369.
85. Leoni-Mesplie S, Mortemousque B, Touboul D, et al. Scalability and severity of keratoconus in children. *Am J Ophthalmol.* 2012;154:56-62 e51.
86. Chatzis N, Hafezi F. Progression of keratoconus and efficacy of pediatric [corrected] corneal collagen cross-linking in children and adolescents. *J Refract Surg.* 2012;28:753-758.
87. Zadnik K, Barr JT, Steger-May K, et al. Comparison of flat and steep rigid contact lens fitting methods in keratoconus. *Optom Vis Sci.* 2005;82:1014-1021.
88. Barnett M, Mannis MJ. Contact lenses in the management of keratoconus. *Cornea.* 2011;30:1510-1516.
89. Papas EB, Tilia D, Tomlinson D, et al. Consequences of wear interruption for discomfort with contact lenses. *Optom Vis Sci.* 2014;91:24-31.
90. Sulley A, Young G, Hunt C. Factors in the success of new contact lens wearers. *Cont Lens Anterior Eye.* 2017;40:15-24.
91. Sulley A, Young G, Hunt C, et al. Retention rates in new contact lens wearers. *Eye Contact Lens.* 2018;44 Suppl 1:S273-S282.
92. Young G, Veys J, Pritchard N, Coleman S. A multi-centre study of lapsed contact lens wearers. *Ophthalmic Physiol Opt.* 2002;22:516-527.
93. Wagner H, Barr JT, Zadnik K. Collaborative longitudinal evaluation of keratoconus (CLEK) study: Methods and findings to date. *Cont Lens Anterior Eye.* 2007;30:223-232.
94. Abdalla YF, Elsahn AF, Hammersmith KM, Cohen EJ. Synergeyes lenses for keratoconus. *Cornea.* 2010;29:5-8.
95. Baran I, Bradley JA, Alipour F, et al. Prose treatment of corneal ectasia. *Cont Lens Anterior Eye.* 2012;35:222-227.
96. Schornack MM, Patel SV. Scleral lenses in the management of keratoconus. *Eye Contact Lens.* 2010;36:39-44.
97. Klyce SD. UVA-riboflavin collagen cross-linking: A misnomer perhaps, but it works! *Invest Ophthalmol Vis Sci.* 2013;54:1635.
98. Belin MW MJ, Duncan JK, Gelman R, Borgstrom M, Ambrosio R. Assessing progression of keratoconus & crosslinking efficacy: The Belin ABCD progression display. *Int J Kerat Ect Cor Dis.* 2017;6:1-10.
99. Duncan JK, Belin MW, Borgstrom M. Assessing progression of keratoconus: Novel tomographic determinants. *Eye Vis (Lond).* 2016;3:6.
100. Raiskup-Wolf F, Hoyer A, Spoerl E, Pillunat LE. Collagen crosslinking with riboflavin and ultraviolet-A light in keratoconus: Long-term results. *J Cataract Refract Surg.* 2008;34:796-801.
101. Elbaz U, Shen C, Lichtinger A, et al. Accelerated (9-mw/cm²) corneal collagen crosslinking for keratoconus-a 1-year follow-up. *Cornea.* 2014;33:769-773.
102. Medeiros CS, Giacomini NT, Bueno RL, et al. Accelerated corneal collagen crosslinking: Technique, efficacy, safety, and applications. *J Cataract Refract Surg.* 2016;42:1826-1835.
103. Shetty R, Pahuja NK, Nuijts RM, et al. Current protocols of corneal collagen cross-linking: Visual, refractive, and tomographic outcomes. *Am J Ophthalmol.* 2015;160:243-249.
104. Marino GK, Torricelli AA, Giacomini N, et al. Accelerated corneal collagen cross-linking for postoperative LASIK ectasia: Two-year outcomes. *J Refract Surg.* 2015;31:380-384.
105. Mazzotta C, Baiocchi S, Bagaglia SA, et al. Accelerated 15 mW pulsed-light crosslinking to treat progressive keratoconus: Two-year clinical results. *J Cataract Refract Surg.* 2017;43:1081-1088.
106. Filippello M, Stagni E, O'Brart D. Transepithelial corneal collagen crosslinking: Bilateral study. *J Cataract Refract Surg.* 2012;38:283-291.
107. Vinciguerra P, Albe E, Frueh BE, et al. Two-year corneal cross-linking results in patients younger than 18 years with documented progressive keratoconus. *Am J Ophthalmol.* 2012;154:520-526.
108. Hovakimyan M, Guthoff RF, Stachs O. Collagen cross-linking: Current status and future directions. *J Ophthalmol.* 2012;2012:Article ID 406850.
109. Arbelaez MC, Sekito MB, Vidal C, Choudhury SR. Collagen cross-linking with riboflavin and ultraviolet-A light in keratoconus: One-year results. *Oman J Ophthalmol.* 2009;2:33-38.

110. Asri D, Touboul D, Fournie P, et al. Corneal collagen crosslinking in progressive keratoconus: Multicenter results from the French National Reference Center for Keratoconus. *J Cataract Refract Surg*. 2011;37:2137-2143.
111. Pron G, Ieraci L, Kaulback K, Medical Advisory Secretariat Health Quality Ontario. Collagen cross-linking using riboflavin and ultraviolet-A for corneal thinning disorders: An evidence-based analysis. *Ont Health Technol Assess Ser*. 2011;11:1-89.
112. Meiri Z, Keren S, Rosenblatt A, et al. Efficacy of corneal collagen cross-linking for the treatment of keratoconus: A systematic review and meta-analysis. *Cornea*. 2016;35:417-428.
113. Kobashi H, Rong SS. Corneal collagen cross-linking for keratoconus: Systematic review. *Biomed Res Int*. 2017;2017:8145651.
114. Salmon HA, Chalk D, Stein K, Frost NA. Cost effectiveness of collagen crosslinking for progressive keratoconus in the UK NHS. *Eye (Lond)*. 2015;29:1504-1511.
115. Sykakis E, Karim R, Evans JR, et al. Corneal collagen cross-linking for treating keratoconus. *Cochrane Database Syst Rev*. 2015:CD010621.
116. Sandvik GF, Thorsrud A, Raen M, et al. Does corneal collagen cross-linking reduce the need for keratoplasties in patients with keratoconus? *Cornea*. 2015;34:991-995.
117. Godefrooij DA, Gans R, Imhof SM, Wisse RP. Nationwide reduction in the number of corneal transplantations for keratoconus following the implementation of cross-linking. *Acta Ophthalmol*. 2016;94:675-678.
118. Hersh PS, Stulting RD, Muller D, et al. United States multicenter clinical trial of corneal collagen crosslinking for keratoconus treatment. *Ophthalmology*. 2017;124:1259-1270.
119. Hersh PS, Stulting RD, Muller D, et al. U.S. multicenter clinical trial of corneal collagen crosslinking for treatment of corneal ectasia after refractive surgery. *Ophthalmology*. 2017;124:1475-1484.
120. Hallahan KM, Rocha K, Roy AS, et al. Effects of corneal cross-linking on ocular response analyzer waveform-derived variables in keratoconus and postrefractive surgery ectasia. *Eye Contact Lens*. 2014;40:339-344.
121. Spoerl E, Terai N, Scholz F, et al. Detection of biomechanical changes after corneal cross-linking using ocular response analyzer software. *J Refract Surg*. 2011;27:452-457.
122. Larkin DFP, Chowdhury K, Burr JM, et al. Effect of corneal cross-linking versus standard care on keratoconus progression in young patients: The Keralink randomized controlled trial. *Ophthalmology*. 2021;128:1516-1526.
123. McAnena L, Doyle F, O'Keefe M. Cross-linking in children with keratoconus: A systematic review and meta-analysis. *Acta Ophthalmol*. 2017;95:229-239.
124. Hafezi F, Kling S, Gilardoni F, et al. Individualized corneal cross-linking with riboflavin and UV-A in ultrathin corneas: The sub400 protocol. *Am J Ophthalmol*. 2021;224:133-142.
125. Koller T, Mrochen M, Seiler T. Complication and failure rates after corneal crosslinking. *J Cataract Refract Surg*. 2009;35:1358-1362.
126. Kuechler SJ, Tappeiner C, Epstein D, Frueh BE. Keratoconus progression after corneal cross-linking in eyes with preoperative maximum keratometry values of 58 diopters and steeper. *Cornea*. 2018;37:1444-1448.
127. Moghadam RS, Akbari M, Alizadeh Y, et al. The outcome of corneal collagen cross-linking in patients with advanced progressive keratoconus: A 2-year follow-up study. *Middle East Afr J Ophthalmol*. 2019;26:11-16.
128. Kymionis GD, Kontadakis GA, Kounis GA, et al. Simultaneous topography-guided PRK followed by corneal collagen cross-linking for keratoconus. *J Refract Surg*. 2009;25:S807-811.
129. Kymionis GD, Portaliou DM, Kounis GA, et al. Simultaneous topography-guided photorefractive keratectomy followed by corneal collagen cross-linking for keratoconus. *Am J Ophthalmol*. 2011;152:748-755.
130. Stojanovic A, Zhang J, Chen X, et al. Topography-guided transepithelial surface ablation followed by corneal collagen cross-linking performed in a single combined procedure for the treatment of keratoconus and pellucid marginal degeneration. *J Refract Surg*. 2010;26:145-152.
131. Alfonso JF, Lisa C, Fernandez-Vega L, et al. Intrastromal corneal ring segment implantation in 219 keratoconic eyes at different stages. *Graefes Arch Clin Exp Ophthalmol*. 2011;249:1705-1712.
132. Jacob S, Patel SR, Agarwal A, et al. Corneal allogenic intrastromal ring segments (CAIRS) combined with corneal cross-linking for keratoconus. *J Refract Surg*. 2018;34:296-303.

133. Pinero DP, Alio JL, El Kady B, et al. Refractive and aberrometric outcomes of intracorneal ring segments for keratoconus: Mechanical versus femtosecond-assisted procedures. *Ophthalmology*. 2009;116:1675-1687.
134. Colin J, Malet FJ. Intacs for the correction of keratoconus: Two-year follow-up. *J Cataract Refract Surg*. 2007;33:69-74.
135. Coskunseven E, Jankov MR, 2nd, Hafezi F, et al. Effect of treatment sequence in combined intrastromal corneal rings and corneal collagen crosslinking for keratoconus. *J Cataract Refract Surg*. 2009;35:2084-2091.
136. Coskunseven E, Kymionis GD, Tsiklis NS, et al. One-year results of intrastromal corneal ring segment implantation (KeraRing) using femtosecond laser in patients with keratoconus. *Am J Ophthalmol*. 2008;145:775-779.
137. Ertan A, Kamburoglu G. Intacs implantation using a femtosecond laser for management of keratoconus: Comparison of 306 cases in different stages. *J Cataract Refract Surg*. 2008;34:1521-1526.
138. El-Raggal TM. Sequential versus concurrent kerarings insertion and corneal collagen cross-linking for keratoconus. *Br J Ophthalmol*. 2011;95:37-41.
139. Ferrara G, Torquetti L, Ferrara P, Merayo-Llodes J. Intrastromal corneal ring segments: Visual outcomes from a large case series. *Clin Experiment Ophthalmol*. 2012;40:433-439.
140. Ferrara P, Torquetti L. Clinical outcomes after implantation of a new intrastromal corneal ring with a 210-degree arc length. *J Cataract Refract Surg*. 2009;35:1604-1608.
141. Gharaibeh AM, Muhsen SM, AbuKhader IB, et al. Keraring intrastromal corneal ring segments for correction of keratoconus. *Cornea*. 2012;31:115-120.
142. Hamdi IM. Optical and topographic changes in keratoconus after implantation of Ferrara intracorneal ring segments. *J Refract Surg*. 2010;26:871-880.
143. Khan MI, Injarie A, Muhtaseb M. Intrastromal corneal ring segments for advanced keratoconus and cases with high keratometric asymmetry. *J Cataract Refract Surg*. 2012;38:129-136.
144. Kaya V, Utine CA, Karakus SH, et al. Refractive and visual outcomes after Intacs vs Ferrara intrastromal corneal ring segment implantation for keratoconus: A comparative study. *J Refract Surg*. 2011;27:907-912.
145. Kubaloglu A, Sari ES, Cinar Y, et al. Comparison of mechanical and femtosecond laser tunnel creation for intrastromal corneal ring segment implantation in keratoconus: Prospective randomized clinical trial. *J Cataract Refract Surg*. 2010;36:1556-1561.
146. Kubaloglu A, Sari ES, Cinar Y, et al. Intrastromal corneal ring segment implantation for the treatment of keratoconus. *Cornea*. 2011;30:11-17.
147. Pesando PM, Ghiringhello MP, Di Meglio G, Romeo S. Treatment of keratoconus with Ferrara ICRS and consideration of the efficacy of the Ferrara nomogram in a 5-year follow-up. *Eur J Ophthalmol*. 2010;20:865-873.
148. Pinero DP, Alio JL, Teus MA, et al. Modification and refinement of astigmatism in keratoconic eyes with intrastromal corneal ring segments. *J Cataract Refract Surg*. 2010;36:1562-1572.
149. Renesto Ada C, Melo LA, Jr., Sartori Mde F, Campos M. Sequential topical riboflavin with or without ultraviolet A radiation with delayed intracorneal ring segment insertion for keratoconus. *Am J Ophthalmol*. 2012;153:982-993.
150. Shabayek MH, Alio JL. Intrastromal corneal ring segment implantation by femtosecond laser for keratoconus correction. *Ophthalmology*. 2007;114:1643-1652.
151. Torquetti L, Berbel RF, Ferrara P. Long-term follow-up of intrastromal corneal ring segments in keratoconus. *J Cataract Refract Surg*. 2009;35:1768-1773.
152. Hellstedt T, Mäkelä J, Uusitalo R, Emre S. Treating keratoconus with Intacs corneal ring segments. *J Refract Surg*. 2005;21:236-246.
153. Walker RN, Khachikian SS, Belin MW. Scheimpflug photographic diagnosis of pellucid marginal degeneration. *Cornea*. 2008;27:963-966.
154. Ruckhofer J, Twa MD, Schanzlin DJ. Clinical characteristics of lamellar channel deposits after implantation of Intacs. *J Cataract Refract Surg*. 2000;26:1473-1479.
155. Twa MD, Kash RL, Costello M, Schanzlin DJ. Morphologic characteristics of lamellar channel deposits in the human eye: A case report. *Cornea*. 2004;23:412-420.
156. Coskunseven E, Kymionis GD, Tsiklis NS, et al. Complications of intrastromal corneal ring segment implantation using a femtosecond laser for channel creation: A survey of 850 eyes with keratoconus. *Acta Ophthalmol*. 2011;89:54-57.

157. Ertan A, Kamburoglu G. Analysis of centration of intacs segments implanted with a femtosecond laser. *J Cataract Refract Surg.* 2007;33:484-487.
158. Ertan A, Karacal H, Kamburoglu G. Refractive and topographic results of transepithelial cross-linking treatment in eyes with intacs. *Cornea.* 2009;28:719-723.
159. El-Raggal TM. Effect of corneal collagen crosslinking on femtosecond laser channel creation for intrastromal corneal ring segment implantation in keratoconus. *J Cataract Refract Surg.* 2011;37:701-705.
160. Hashemi H, Alvani A, Seyedian MA, et al. Appropriate sequence of combined intracorneal ring implantation and corneal collagen cross-linking in keratoconus: A systematic review and meta-analysis. *Cornea.* 2018;37:1601-1607.
161. Jones MN, Armitage WJ, Ayliffe W, et al. Penetrating and deep anterior lamellar keratoplasty for keratoconus: A comparison of graft outcomes in the United Kingdom. *Invest Ophthalmol Vis Sci.* 2009;50:5625-5629.
162. Reinhart WJ, Musch DC, Jacobs DS, et al. Deep anterior lamellar keratoplasty as an alternative to penetrating keratoplasty a report by the American Academy of Ophthalmology. *Ophthalmology.* 2011;118:209-218.
163. Kaushal S, Jhanji V, Sharma N, et al. "Tuck in" lamellar keratoplasty (TILK) for corneal ectasias involving corneal periphery. *Br J Ophthalmol.* 2008;92:286-290.
164. Feizi S, Javadi MA, Jamali H, Mirbabae F. Deep anterior lamellar keratoplasty in patients with keratoconus: Big-bubble technique. *Cornea.* 2010;29:177-182.
165. Caporossi A, Balestrazzi A, Simi C, et al. Manual deep lamellar keratoplasty: Alternative methods and air-guided technique. *Transplant Proc.* 2005;37:2697-2701.
166. Behrooz MJ, Daneshgar F. "Large-bubble" modification of the "big-bubble" technique for performing maximum-depth anterior lamellar keratoplasty. *Cornea.* 2010;29:820-824.
167. Daneshgar F, Fallahtafti M. 'Expanding bubble' modification of 'big-bubble' technique for performing maximum-depth anterior lamellar keratoplasty. *Eye (Lond).* 2011;25:803-808.
168. Buzzonetti L, Laborante A, Petrocelli G. Refractive outcome of keratoconus treated by combined femtosecond laser and big-bubble deep anterior lamellar keratoplasty. *J Refract Surg.* 2011;27:189-194.
169. Farid M, Steinert RF. Deep anterior lamellar keratoplasty performed with the femtosecond laser zigzag incision for the treatment of stromal corneal pathology and ectatic disease. *J Cataract Refract Surg.* 2009;35:809-813.
170. Price FW, Jr., Price MO, Grandin JC, Kwon R. Deep anterior lamellar keratoplasty with femtosecond-laser zigzag incisions. *J Cataract Refract Surg.* 2009;35:804-808.
171. Ardjomand N, Hau S, McAlister JC, et al. Quality of vision and graft thickness in deep anterior lamellar and penetrating corneal allografts. *Am J Ophthalmol.* 2007;143:228-235.
172. Al-Torbak AA, Al-Motowa S, Al-Assiri A, et al. Deep anterior lamellar keratoplasty for keratoconus. *Cornea.* 2006;25:408-412.
173. Feizi S, Javadi MA, Rastegarpour A. Visual acuity and refraction after deep anterior lamellar keratoplasty with and without successful big-bubble formation. *Cornea.* 2010;29:1252-1255.
174. Fontana L, Parente G, Sincich A, Tassinari G. Influence of graft-host interface on the quality of vision after deep anterior lamellar keratoplasty in patients with keratoconus. *Cornea.* 2011;30:497-502.
175. Fontana L, Parente G, Tassinari G. Clinical outcomes after deep anterior lamellar keratoplasty using the big-bubble technique in patients with keratoconus. *Am J Ophthalmol.* 2007;143:117-124.
176. Han DC, Mehta JS, Por YM, et al. Comparison of outcomes of lamellar keratoplasty and penetrating keratoplasty in keratoconus. *Am J Ophthalmol.* 2009;148:744-751.
177. Javadi MA, Feizi S, Yazdani S, Mirbabae F. Deep anterior lamellar keratoplasty versus penetrating keratoplasty for keratoconus: A clinical trial. *Cornea.* 2010;29:365-371.
178. Bahar I, Kaiserman I, Srinivasan S, et al. Comparison of three different techniques of corneal transplantation for keratoconus. *Am J Ophthalmol.* 2008;146:905-912.
179. Chen G, Tzekov R, Li W, et al. Deep anterior lamellar keratoplasty versus penetrating keratoplasty: A meta-analysis of randomized controlled trials. *Cornea.* 2016;35:169-174.
180. Cohen AW, Goins KM, Sutphin JE, et al. Penetrating keratoplasty versus deep anterior lamellar keratoplasty for the treatment of keratoconus. *Int Ophthalmol.* 2010;30:675-681.
181. Smadja D, Colin J, Krueger RR, et al. Outcomes of deep anterior lamellar keratoplasty for keratoconus: Learning curve and advantages of the big bubble technique. *Cornea.* 2012;31:859-863.
182. Kim KH, Choi SH, Ahn K, et al. Comparison of refractive changes after deep anterior lamellar keratoplasty and penetrating keratoplasty for keratoconus. *Jpn J Ophthalmol.* 2011;55:93-97.

183. Cheng YY, Visser N, Schouten JS, et al. Endothelial cell loss and visual outcome of deep anterior lamellar keratoplasty versus penetrating keratoplasty: A randomized multicenter clinical trial. *Ophthalmology*. 2011;118:302-309.
184. Fogla R, Padmanabhan P. Results of deep lamellar keratoplasty using the big-bubble technique in patients with keratoconus. *Am J Ophthalmol*. 2006;141:254-259.
185. Kubaloglu A, Koytak A, Sari ES, et al. Corneal endothelium after deep anterior lamellar keratoplasty and penetrating keratoplasty for keratoconus: A four-year comparative study. *Indian J Ophthalmol*. 2012;60:35-40.
186. Kubaloglu A, Sari ES, Unal M, et al. Long-term results of deep anterior lamellar keratoplasty for the treatment of keratoconus. *Am J Ophthalmol*. 2011;151:760-767.
187. Sarnicola V, Toro P, Sarnicola C, et al. Long-term graft survival in deep anterior lamellar keratoplasty. *Cornea*. 2012;31:621-626.
188. Keane M, Coster D, Ziaei M, Williams K. Deep anterior lamellar keratoplasty versus penetrating keratoplasty for treating keratoconus. *Cochrane Database Syst Rev*. 2014:CD009700.
189. Olson EA, Tu EY, Basti S. Stromal rejection following deep anterior lamellar keratoplasty: Implications for postoperative care. *Cornea*. 2012;31:969-973.
190. Kawashima M, Kawakita T, Shimmura S, et al. Characteristics of traumatic globe rupture after keratoplasty. *Ophthalmology*. 2009;116:2072-2076.
191. Mathews P, Benbow A, Corcoran K, et al. 2022 Eye Banking Statistical Report--executive summary. *Eye Banking and Corneal Transplantation*. 2023;2:e1-e12.
192. Skeens HM, Holland EJ. Large-diameter penetrating keratoplasty: Indications and outcomes. *Cornea*. 2010;29:296-301.
193. Mashor RS, Rootman DB, Bahar I, et al. Outcomes of deep anterior lamellar keratoplasty versus intralase enabled penetrating keratoplasty in keratoconus. *Can J Ophthalmol*. 2011;46:403-407.
194. Chamberlain WD, Rush SW, Mathers WD, et al. Comparison of femtosecond laser-assisted keratoplasty versus conventional penetrating keratoplasty. *Ophthalmology*. 2011;118:486-491.
195. Chan CC, Ritenour RJ, Kumar NL, et al. Femtosecond laser-assisted mushroom configuration deep anterior lamellar keratoplasty. *Cornea*. 2010;29:290-295.
196. Farid M, Kim M, Steinert RF. Results of penetrating keratoplasty performed with a femtosecond laser zigzag incision initial report. *Ophthalmology*. 2007;114:2208-2212.
197. Farid M, Steinert RF. Femtosecond laser-assisted corneal surgery. *Curr Opin Ophthalmol*. 2010;21:288-292.
198. Cheng YY, Tahzib NG, van Rij G, et al. Femtosecond laser-assisted inverted mushroom keratoplasty. *Cornea*. 2008;27:679-685.
199. Pramanik S, Musch DC, Sutphin JE, Farjo AA. Extended long-term outcomes of penetrating keratoplasty for keratoconus. *Ophthalmology*. 2006;113:1633-1638.
200. Javadi MA, Motlagh BF, Jafarinasab MR, et al. Outcomes of penetrating keratoplasty in keratoconus. *Cornea*. 2005;24:941-946.
201. Javadi MA, Naderi M, Zare M, et al. Comparison of the effect of three suturing techniques on postkeratoplasty astigmatism in keratoconus. *Cornea*. 2006;25:1029-1033.
202. Patel SV, Malta JB, Banitt MR, et al. Recurrent ectasia in corneal grafts and outcomes of repeat keratoplasty for keratoconus. *Br J Ophthalmol*. 2009;93:191-197.
203. Unal M, Yucel I, Akar Y, et al. Recurrence of keratoconus in two corneal grafts after penetrating keratoplasty. *Cornea*. 2007;26:362-364.
204. Liu H, Chen Y, Wang P, et al. Efficacy and safety of deep anterior lamellar keratoplasty vs. penetrating keratoplasty for keratoconus: A meta-analysis. *PLoS One*. 2015;10:e0113332.
205. Gedde SJ, Vinod K, Wright MM, et al. Primary open-angle glaucoma preferred practice pattern. *Ophthalmology*. 2021;128:P71-P150.
206. Sharma R, Titiyal JS, Prakash G, et al. Clinical profile and risk factors for keratoplasty and development of hydrops in North Indian patients with keratoconus. *Cornea*. 2009;28:367-370.
207. Santodomingo-Rubido J, Carracedo G, Suzaki A, et al. Keratoconus: An updated review. *Cont Lens Anterior Eye*. 2022;45:101559.
208. Gordon MO, Schechtman KB, Davis LJ, et al. Visual acuity repeatability in keratoconus: Impact on sample size. Collaborative longitudinal evaluation of keratoconus (CLEK) study group. *Optom Vis Sci*. 1998;75:249-257.
209. Lin KK, Chen YW, Yeh CT, et al. Comparing the natural progression and clinical features of keratoconus between pediatric and adult patients. *Sci Rep*. 2022;12:8278.

210. Ahmad TR, Kong AW, Turner ML, et al. Socioeconomic correlates of keratoconus severity and progression. *Cornea*. 2023;42:60-65.
211. Kymes SM, Walline JJ, Zadnik K, Gordon MO. Quality of life in keratoconus. *Am J Ophthalmol*. 2004;138:527-535.
212. Kymes SM, Walline JJ, Zadnik K, et al. Changes in the quality-of-life of people with keratoconus. *Am J Ophthalmol*. 2008;145:611-617.
213. Rebenitsch RL, Kymes SM, Walline JJ, Gordon MO. The lifetime economic burden of keratoconus: A decision analysis using a Markov model. *Am J Ophthalmol*. 2011;151:768-773.
214. Godefrooij DA, Mangen MJ, Chan E, et al. Cost-effectiveness analysis of corneal collagen crosslinking for progressive keratoconus. *Ophthalmology*. 124:1485-1495.
215. Ling JJ, Mian SI, Stein JD, et al. Impact of scleral contact lens use on the rate of corneal transplantation for keratoconus. *Cornea*. 2021;40:39-42.
216. Roe RH, Lass JH, Brown GC, Brown MM. The value-based medicine comparative effectiveness and cost-effectiveness of penetrating keratoplasty for keratoconus. *Cornea*. 2008;27:1001-1007.