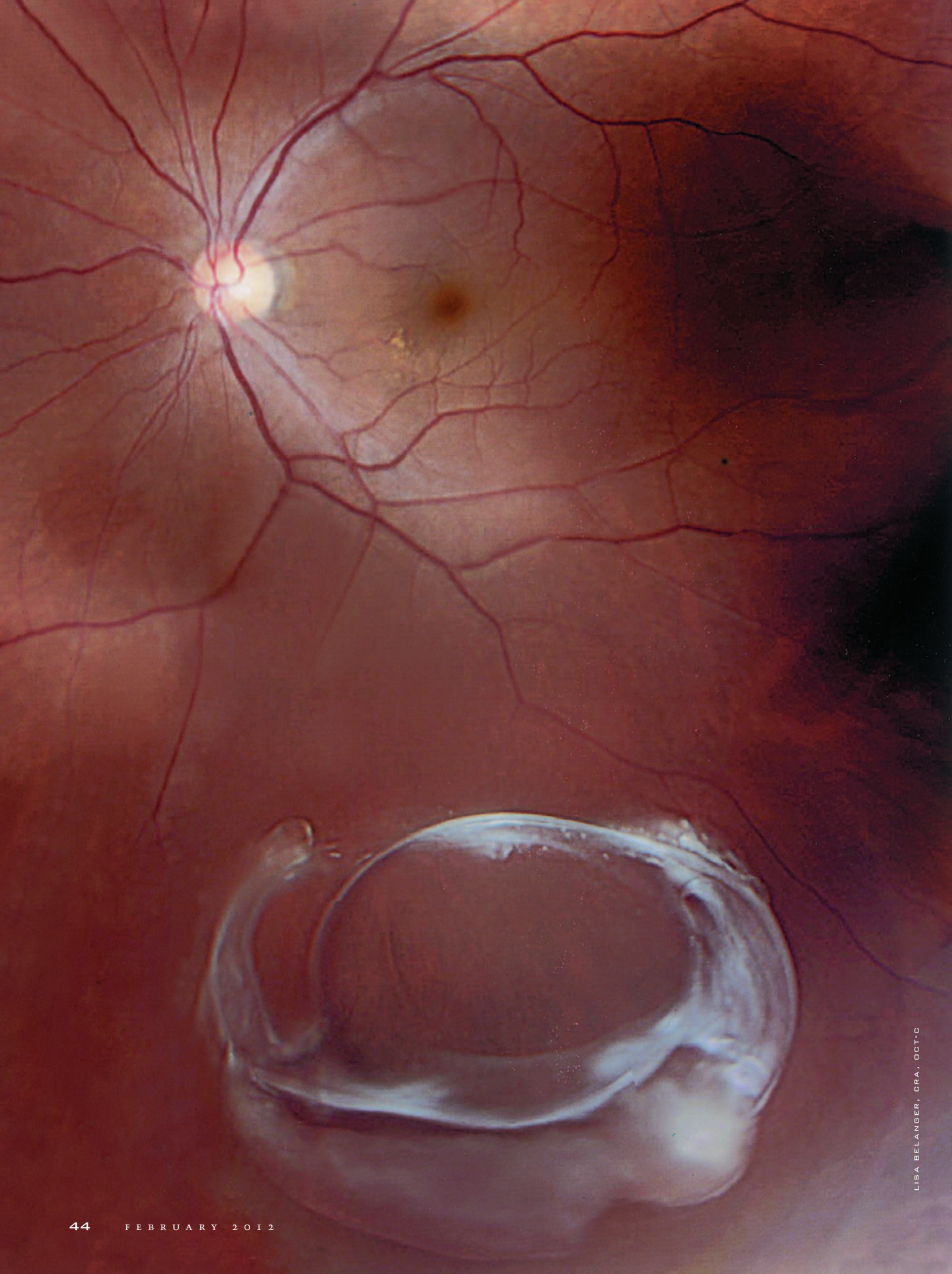

LISA BELANGER, DRA, DCT-C

CATARACT
EXPERTS
SHARE
THEIR

Surgical Mishaps

Every cataract surgeon makes mistakes and suffers complications, but it is what we learn from these mistakes that makes us better ophthalmologists.

With this in mind, Bruce Wallace and I cochaired last October's 10th annual Spotlight on Cataract Surgery Session at the Academy's Annual Meeting. The four-hour case-based video symposium entitled "M&M Rounds: Learning From My Mistakes" was focused on cataract surgical complications.

Eighteen cataract experts presented video cases in which something had gone wrong, resulting in a complication that taught them valuable lessons. At critical points during each case, the video was paused and the attendees made clinical decisions using their electronic audience response pads. Next, two discussants (who had not previously seen the case) gave their own management recommendation and commented on the audience responses before the video of the outcome was shown. The audience also voted on the best teaching cases and the surgeons who demonstrated the most courage—both in the OR and on the podium.

The 18 video cases covered the spectrum of surgical complications—from the common to the rare and from the spectacular save to the horrifying outcome. For years, Bob Osher has used this approach of courageously showing a serious complication of his own to educate the audience. This year's complications included iris prolapse, incision burn, Descemet's membrane detachment, suprachoroidal hemorrhage, globe perforation, descending nuclei

Experts recounted their worst OR experiences during this year's Spotlight on Cataract Complications Session. *EyeNet* presents audience poll results and expert opinion on management of these troubling cases.

and IOLs, and capsules or zonules ruptured at virtually every stage of surgery.

This *EyeNet* article reports the audience poll results, followed by the presenter's description of the case as well as a second comment, from another expert, discussing his or her own thoughts about the case.

I concluded the Spotlight Session

by delivering the seventh annual Academy Charles Kelman Lecture, entitled "Conquering Complicated Cataracts," in which I presented a 1998 surgical video of my most technically and emotionally challenging case ever. I then showed video examples of newer strategies that I would use today to approach this particular eye. The Kelman Lecture can be viewed on the ONE website as part of my Master Class on Weak Zonules (www.aao.org/masterclass). And the entire symposium, with videos and PowerPoint presentations, is available for purchase at www.cmeoncall.com/aao/index.html.

Fittingly, the 10th anniversary of the Academy's Spotlight on Cataract Surgery was celebrated in Orlando, where the Cataract Spotlight Session was born in 2002. And the Academy's Annual Meeting continues to feature a daylong, continuous series of cataract symposia that constitute "Cataract Monday."

—David F. Chang, MD

Cataract Spotlight Program Cochairman

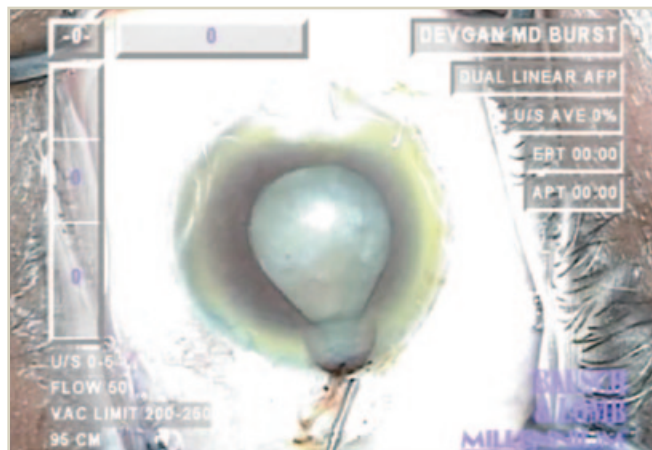
Case 1: Not the Usual Beverly Hills Cataract

Uday Devgan's patient had a short eye with a mature white cataract and a crowded anterior chamber. Iris prolapse occurred suddenly following hydrodissection.

Q At this point, assuming that you cannot reposition the iris in the small eye, what is your very next step?

- Administer an osmotic agent (e.g., IV mannitol) . . . 31%
- Perform a pars plana vitreous tap 38%
- Burp the anterior chamber (AC)
 - via another incision 18%
- Create a new phaco incision 5%
- Abort surgery (in case of a suprachoroidal hemorrhage) 9%

Uday Devgan This is a tricky question because the primary issue is the sudden pressure gradient, which could be at least partially addressed by more than one of these answers. In this case, the 80-year-old patient has a short eye (axial length, 20 mm) with a dense white cataract and moderate dilation. The principal surgical error was excessive hydrodissection because the fluid wave behind the lens could not be visualized. Balanced salt solution became trapped behind the nucleus, which was then unable to prolapse out of the bag because of the smaller-than-desired 4-mm anterior capsulorrhexis. This created a pressure gradient with high pressure in the posterior chamber and lower pressure in the anterior chamber, leading to the resultant iris prolapse out of the clear corneal phaco incision. This challenge was resolved by releasing the trapped balanced salt solution from behind the cataract by using a blunt cannula to rock the nucleus. Once the pressure gradient was equalized, the iris prolapse resolved, and the surgery could be continued. The take-home message is that the cause of the pressure gradient must be addressed in order to resolve iris prolapse.



CASE 1. Iris prolapse.

Steve Lane A patient with a short axial length and a white lens that prevents visualization of the retina and does not even allow a red reflex during surgery poses special challenges. In this case, the IOP increased suddenly during hydrodissection and was accompanied by iris prolapse. Without a red reflex, the cause and treatment are not obvious. A suprachoroidal hemorrhage (SCH) due to nanophthalmos must be considered because of its dire consequences. Administration of an osmotic agent is a reasonable treatment if an SCH is suspected, but the pressure-lowering effect may take 30 minutes or longer. Performing a pars plana vitreous tap would be risky without knowing whether an SCH is present because a more severe hemorrhage might ensue. In the absence of a red reflex, a B-scan ultrasound is the only way to know whether an SCH is present. This specialized instrumentation is not readily available but would have been helpful to rule an SCH in or out.

Burping the anterior chamber or creating another incision are similar alternatives. Given that the pressure is greater in the posterior chamber than in the anterior chamber, these actions would be of little value and would create more prolapse. Aborting the case is a possibility, but the rhexis has been completed, and delay in nuclear removal can lead



FULL HOUSE. The October Spotlight on Cataract Complications Session drew more than 2,000 audience members.

UDAY DEVGAN, MD; OSCAR EINZIG

to significant inflammation. An SCH, if present, might take several days to resolve. Equalizing the posterior and anterior pressure is the key to solving the problem. Decompression of the pressure inside the capsular bag is an important goal in every cataract procedure. Compressing the lens during hydrodissection and allowing the trapped balanced salt solution within the capsular bag to escape are important maneuvers that should be performed routinely. In this case, it solved the problem and ruled out SCH.

Case 2: Pearls for Posterior Capsulorrhexis

Mark Packer had a refractive lens exchange patient for whom a multifocal intraocular lens had been planned. During phacoemulsification with biaxial microincisional instrumentation, the posterior capsule tore.

Q What should your next step be?

- Withdraw the irrigating chopper to avoid hydrating the vitreous. 8%
- Inject viscoelastic while maintaining irrigation through the irrigating chopper 91%
- Perform a pars plana vitrectomy while maintaining irrigation via the irrigating chopper 2%
- Close the eye and refer the patient. 0%

Mark Packer Ninety-one percent of the audience correctly identified the conventional management wisdom. Withdrawing irrigation is precisely what should not be done. Doing so would allow the vitreous to prolapse anteriorly and the lens fragments to dislocate posteriorly. Vitrectomy is not indicated unless one or both of these untoward events occurs.

Converting the posterior capsular tear into a continuous posterior capsulorrhexis under irrigation or viscoelastic prevents further extension of the tear and will allow in-the-bag implantation of the multifocal IOL as planned. One of the advantages of biaxial phacoemulsification is the ability to maintain irrigation while removing the phacoemulsification needle, performing the posterior rhexis and injecting viscoelastic. The patient in this example demonstrated uncorrected distance visual acuity of 20/20 and uncorrected near visual acuity of J1 on postop day 1.

Abhay Vasavada The audience recommendation is very logical. I would also recommend lowering the irrigating bottle height and foot pedal position and injecting dispersive viscoelastic anterior to the rupture area and then withdrawing the irrigating chopper. If the surgeon is very patient and the surgical team is very efficient, preservative-free triamcinolone can be injected before the viscoelastic. This would allow the surgeon to recognize the presence of vitreous in the event that it had prolapsed into the anterior chamber.

Case 3: When Did It Tear? Keep Your Eye on the Ball!

In this case from Barry Seibel, his patient had undergone prior pneumatic retinopexy during which the needle shaft might have contacted the posterior lens capsule. During cortical cleanup with coaxial irrigation and aspiration (I&A) instrumentation, a posterior capsular tear is noted.

Q During which step do you think the posterior capsular tear occurred?

- A posterior capsular defect or weakness
 - was preexisting 14%
 - Hydrodissection 11%
 - Nuclear emulsification. 6%
 - Cortical I&A 47%
 - Not sure 23%

Barry Seibel Because of the posterior subcapsular cataract's unusual appearance and traumatic etiology, posterior capsular fragility or discontinuity was anticipated. Therefore, many appropriate prophylactic steps had been taken, such as refraining from significant hydrodissection in favor of a complete hydrodelineation, and using viscodissection of the epinucleus so that if a posterior capsular rent were present, the ophthalmic viscosurgical device (OVD) would tamponade the vitreous. However, attention was diverted from the eye during the switch from phaco to I&A as the surgeon looked at the handpieces, tubing, etc. During this time, the unblinking eye of the camcorder revealed the presence of an obvious fusiform red reflex rent progressively opening up in the posterior capsule.

However, the surgeon's mindset was frozen on the last image seen through the operating microscope—an intact capsule. This mindset likely obscured the brief visualization of this break before it was obliterated by the repressurization of the anterior chamber upon insertion of the I&A tip. Vitreous was soon evident during I&A, but it might have been appreciated even sooner had there been less complacency about the posterior capsular integrity. Conceivably, the surgeon could have maintained constant observation through the microscope even during handpiece switching. However, I find direct visualization of this step useful in properly draping tubing over my forearm to relieve traction, adjust irrigating sleeves as needed, etc. The moral of this case is one we already know: We must maintain constant, unrelenting vigilance during surgery; always be open to the possibility of complications, particularly in high-risk cases; and suppress our natural tendency to believe that everything is fine even if there are hints to the contrary.

Steve Dewey The audience's response is appropriate, as the tear in the posterior capsule could not be visualized until after the I&A was performed. But this is the perfect example of a teaching case that would have remained a mystery if it had not been caught on videotape. The tear

corresponds exceptionally well to the posterior subcapsular cataract. During the video, the only manipulation Dr. Seibel performed in the area of the tear was his hydrodissection. The tear might have been made worse during this step, but it is much more likely that the tear was preexisting. The softer nature of the cataract and the solid chamber stability prevented the capsule from being challenged during phacoemulsification and allowed the case to proceed as it did.

During my informed consent for cataract surgery, I explain that the greatest barrier to achieving a good outcome is something the patient has brought with him or her into the operating room, such as macular degeneration or diabetic retinopathy. This simplifies the concept of a preexisting comorbidity to a basic level of understanding and allows the discussion to continue. In this challenging case, I would counsel the patient that the previous ocular surgery may present unknowns that could potentially affect the outcome. A focal cataract, or one that has progressed exuberantly over a shorter period following pars plana vitrectomy, certainly raises the question of preexisting capsular damage. As with a patient with potential zonular laxity, the first step is to reduce the infusion pressure prior to beginning phaco. A larger capsulorrhexis (5.5 mm) is useful, and gentle hydrodelineation will allow the nucleus to be brought into the anterior chamber. A smaller-gauge phaco needle will act as a flow restrictor and will further maintain a stable anterior chamber during phacoemulsification. Size and location of the capsular defect will determine whether the IOL can then be placed in the bag or captured in the capsulorrhexis. Although it is unusual to have vitreous presenting at this point, a touch of triamcinolone in the anterior chamber after IOL placement will identify any unexpected vitreous strands for excision if the posterior capsule was indeed compromised.

CASES 1 TO 3. “Grand Rounds Award” voted for the surgeon who presented the best teaching case:

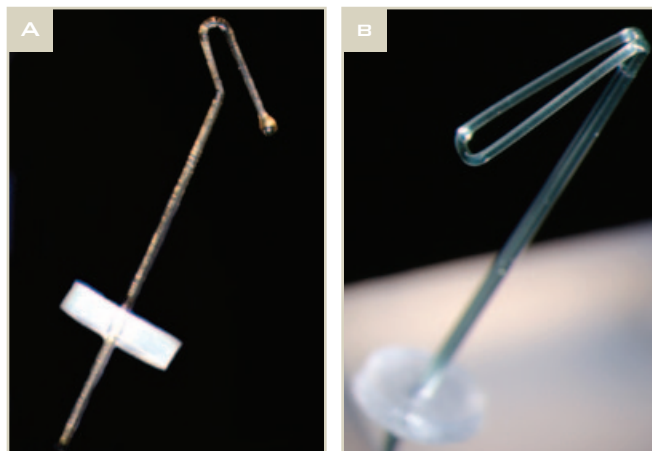
- Uday Devgan: Iris prolapse 66%
- Mark Packer: PC rupture 25%
- Barry Seibel: PC rupture 9%

Case 4: Fun With Zonules (Not)

In Alan Crandall's case, the nucleus abruptly tilted posteriorly during an attempt at prechopping, indicating the presence of a sizable zonular dialysis.

Q The entire lens appears to be loose. What now?

- Insert a capsular tension ring (CTR) and carefully continue phaco. 49%
- Elevate the nucleus with a posterior-assisted levitation (PAL) technique, and phaco it in the anterior chamber 20%



CASE 4. (A) Mackool capsule retractor. (B) MST capsule retractor.

- Convert to a manual extracapsular cataract extraction (ECCE) 21%
- Close the eye and refer the patient. 3%
- Other 6%

Alan Crandall This case reminds us that in phacoemulsification cataract extraction no steps are inconsequential. In this case of pseudoexfoliation (PXF), poor wound construction led to a small capsulorrhexis after the hydrodissection; the prechopper movement was too rapid; and the tip tore more than 180 degrees of the already weakened zonules. However, capsular support systems (in this case, Mackool hooks, FCI Ophthalmics) can allow the surgeon to safely proceed with phaco using a low-flow technique; and, finally, a CTR or Cionni-Modified CTR (Morcher) can allow for in-the-bag implantation of the IOL. To use any of the capsular support systems (I now prefer the MST capsule retractors [MicroSurgical Technology]), a stab incision is made. Then viscoelastic is used to create space in the capsule for easier insertion of the support. Usually two or three capsule hooks will be enough to stabilize the lens. Low flow indicates that the bottle height is lowered to reduce posterior pressure. It is also important to reduce the aspiration flow rate on a peristaltic system to 25 mm/minute, and I use linear vacuum with a maximum of 350 mmHg. Another important decision involves lens placement and the use of CTRs. If the bag is intact and the rhexis is continuous, a CTR can be used. Assuming that the remaining zonules are intact and the dehiscence is less than 120 degrees, a standard CTR can be used. Larger zonular defects need a Cionni-Modified CTR or an Ahmed Capsular Tension Segment (FCI Ophthalmics) sewn to the sclera with 9-0 Prolene or 8-0 Gore-Tex sutures (off-label use). Other options would be iris fixation or an anterior chamber lens.

Walter Stark Zonular dehiscence or dialysis has many causes, the most likely being pseudoexfoliation of the lens capsule. This should be recognized or suspected preoperatively so that measures can be taken to prevent further

detachment of the zonules. Often, the first evidence of weak zonules is movement of the entire lens at the start of the capsulotomy. In these cases, I perform a wider capsulotomy, which enables me to make a more complete hydrodissection. This separates the lens nucleus away from the capsular bag so that the chopping or manipulation of the nucleus no longer exerts traction on the capsule or, in turn, on the zonules. A wider capsulotomy also reduces the chances of later phimosis of the anterior capsule. With good hydrodissection and separation of the nucleus from the capsule, phacoemulsification can usually be performed safely within the iris plane.

In the presence of extensive zonular weakness, as in cases of Marfan syndrome or traumatic weakness of the zonules, iris retractors can be used to hold the anterior capsular leaf peripherally, thereby stabilizing the capsular bag. I do not use CTRs because I do not believe they offer any better support than a three-piece lens. My preference for these complicated cases is the MA50BM acrylic lens made by Alcon with a 13.5-mm loop. The MA50BM lens is 6.5 mm in diameter, which is 18 percent larger than a 6-mm optic. This exerts peripheral tension on the capsular bag and, in my opinion, provides essentially the same support as would be provided by a CTR. If necessary, with the three-piece lens or the CTR, scleral fixation can be created with a 10-0 Prolene suture with a CIF4 or CT6 needle, both of which are made by Ethicon.

The audience poll indicates that 49 percent of respon-

dents would place a CTR and then continue with careful phacoemulsification. I suspect that insertion of a CTR without good hydrodissection might lead to further weakness of the zonules and/or a capsular tear. Some people routinely use CTRs in patients with PXF, and I wonder how often this causes a complication. Twenty percent of the audience would use the PAL technique. If the injection of a dispersive viscoelastic behind the lens did not elevate the nucleus to the pupillary plane, the PAL technique could be used in these more complex cases.

With the nucleus dropping posteriorly, it is very difficult to do a manual extracapsular cataract extraction; 21 percent of the audience suggested this as an option. To do an extracapsular cataract extraction, one would need to increase the size of the incision to 11 to 13 mm and be able to exert enough vitreous pressure to push the lens forward. I would not choose this approach out of concern that it would only further sublux the nucleus.

With a preoperative suspicion of weak zonules, the surgeon can properly handle these cases with a wider capsulotomy, good hydrodissection to bring the nucleus forward and then very careful phacoemulsification. Iris retractors are sometimes needed to stabilize the capsular bag. The intraocular lens can then be placed in the ciliary sulcus. If support for the IOL appears inadequate, pupillary capture of the optic can be accomplished; and iris fixation of the haptic can be performed at least superiorly and, if necessary, inferiorly.

Case 5: Got Burned: So You Say You Won't Wear Glasses?

In Lisa Arbisser's case, a significant wound burn occurred, and the surgeon was faced with the problem of how to close the incision. The wound burn also resulted in an initial large degree of induced astigmatism in a patient who did not want to wear eyeglasses.

Q How many serious wound burns have you experienced?

None	48%
1	26%
2-3	15%
>3	11%

Lisa Arbisser A burn can occur anytime absent flow coexists with ultrasound. I learned that my usual technique with a brunescient lens—vertical chop, 2.2-mm incision, dispersive OVD and burst-mode high power—could create a burn if OVD was not adequately cleared before embedding the tip in the nucleus. The situation was perhaps aggravated by the absence of an ABS port, which might have given an extra margin of safety. This, my first burn, coincided with my first use of a reusable phaco tip featuring no hole in the shaft. Burns are biphasic, progressing from transient tissue shrinkage with remodeling to permanent destruction.

Happily, after the first chop I fully established flow, clearing OVD along with nucleus as always before the second chop. I realized intraoperatively that interrupted anterior-to-posterior lip sutures repair coagulated tissue poorly. Instead, I closed the tunnel floor and roof in their native position with three interrupted horizontal sutures (two from normal tissue to the middle of the burn and one within the tunnel). A fornix-based conjunctival flap sutured tightly over the limbus provided further protection. A more severe burn would have required a split scleral flap to gain tissue without having banked sclera, or a substitute, to secure the anterior chamber. Stable at four months and after suture removal, this toric lens—implanted eye's 2.5 D residual cylinder diminished with astigmatic keratotomy. My patient's final outcome: uncorrected 20/30 and best-corrected 20/20+ with 1.25 D cylinder residual manifest refraction. She still refuses to wear glasses, but I count myself lucky.

Elizabeth Davis Fortunately, according to the audience, the incidence of serious wound burns is low, with nearly half of respondents reporting never having experienced even one. This is good news, as a severe wound burn can induce considerable astigmatism, require a patch graft to close, or even necessitate a corneal transplant. I believe this complication is uncommon because of major advances in



SEVENTH ANNUAL KELMAN LECTURE. After his Kelman Lecture, titled “Conquering Complicated Cataracts (Featuring My Most Challenging Case Ever),” Dr. Chang (left) received the 2011 Kelman Award from Ann Kelman and symposium cochairman, R. Bruce Wallace, MD.

technology. Today’s phaco machines have enhanced designs that reduce the risk of blockage or loss of the cooling inflow of irrigating fluid, as well as advanced power modulations that reduce phaco energy and thus thermal increases. I would also suspect that most cataract surgeons are well versed in ways to avoid wound burns (although rarely they may be unavoidable), such as minimizing continuous ultrasound and using techniques of mechanical disassembly.

Case 6: Splitting Headache (Phaco After RK)

Sonia Yoo’s case involved difficulty in closing the clear corneal incision in an eye with many prior radial keratotomy (RK) scars. The incision was not completely watertight at the conclusion of surgery.

Q For cataract surgery in an eye with multiple RK scars, I prefer:

- Coaxial phaco with a scleral pocket incision . . . 41%
- Coaxial phaco with a clear corneal incision . . . 46%
- Biaxial microphaco 4%
- Manual ECCE 1%
- I would refer this patient. 8%

Sonia Yoo This case of radial keratotomy wound dehiscence during phacoemulsification cataract extraction highlights one of the intraoperative challenges of performing cataract surgery in an eye with previous RK. Apart from the problem with biometry and intraocular lens calculations in post-RK patients, RK wound dehiscence is always a risk during cataract surgery because RK incisions typically run almost

the full thickness of the cornea and extend to the corneal limbus circumferentially. Even in cases in which the RK was performed many years prior to the cataract surgery, these wounds can open up. This patient had undergone his RK more than 15 years earlier.

I try to construct my primary cataract wound and paracentesis so as not to transect the RK incisions. This can be difficult for cases in which the RK incisions are close together (eight-incision RK or more). In cases in which it is impossible to avoid transecting the RK incisions with a clear corneal cataract wound, I consider a scleral tunnel approach, which allows for a slightly more posterior entry into the anterior chamber, or a uniplanar limbal approach, which requires suturing for closure at the end of the case.

It is noteworthy that in this case, it was not until the infusion pressure was high that the RK incision dehiscid. “Low-flow, slow-mo, small-incision phaco,” which would keep the infusion pressure relatively low, should be considered for such cases to reduce the risk of RK wound dehiscence. Finally, when facing the need to suture corneal wounds that transect dehiscid RK wounds, I prefer to use an X or a figure-of-eight suture to close these. Interrupted radial or horizontal sutures tend to make the incisions gape and may be ineffective or even exacerbate the dehiscence in this situation.

Kerry Solomon Cataract surgery in an eye that has undergone RK presents many challenges. I always review these with the patient as part of the informed consent. Certainly, cataract surgery involves a risk of these incisions opening. I inform patients that if this occurs, sutures or glue/tissue adhesive might be necessary to close the incision(s). Visual recovery can be delayed due to induced astigmatism from the wound closure. My rule of thumb is that if my primary clear corneal incision can readily fit between the RK incisions, I can proceed with clear corneal surgery. If my primary incision cannot fit between the RK scars (because of a larger incision or multiple [16+] RK incisions), I prefer a scleral tunnel approach with a more posterior entry into the cornea. The presence of the scleral flap and a sutured conjunctival closure often facilitates wound closure if the RK incisions split open. These patients are also informed about the challenges regarding the IOL calculation and the delayed visual recovery (with early postoperative hyperopia), which is a normal occurrence in the setting of preexisting RK incisions. Refractive options are considered once things stabilize, typically three to four months postoperatively or more. The options are typically photorefractive keratectomy with mitomycin C or an IOL exchange.

CASES 4 TO 6. “Chinese Water Torture Award” voted for the surgeon who endured the most pain during his or her case:

- Alan Crandall: Large zonular dialysis. 13%
- Lisa Arbisser: Incision burn 66%
- Sonia Yoo: Clear corneal incisions intersecting with RK incisions 21%

Case 7: Now What? I Tore the Capsule and Can't Implant an Artificial Iris

In Kevin Miller's patient with a traumatic mydriasis, the posterior capsule tore, making it impossible to implant the Morcher artificial iris segment rings as planned. Instead, a three-piece PC IOL was implanted into the ciliary sulcus.

Q Apart from sunglasses, how could this patient's severe glare be managed?

- Prescribe a colored contact lens 54%
- Consider corneal tattooing 15%
- Exchange the PC IOL with an artificial iris IOL (Morcher, Ophtec) 21%
- Choose another option 7%
- Refer the patient 3%

Kevin Miller Eyes that experience blunt trauma severe enough to produce a permanent 11-mm mydriasis probably have concomitant zonular instability, no matter how subtle it appears at a slit-lamp biomicroscope. That was certainly the situation with this patient. I was expecting some trampoline of the lens-iris diaphragm, and I had dialed down the aspiration flow rate and vacuum limit in anticipation. Despite these efforts, I managed to pop a hole in the peripheral posterior capsule at the end of quadrant removal, which was precipitated by an occlusion break surge. At the moment it happened, I did not have a backup or alternative aniridia device to implant in the sulcus.

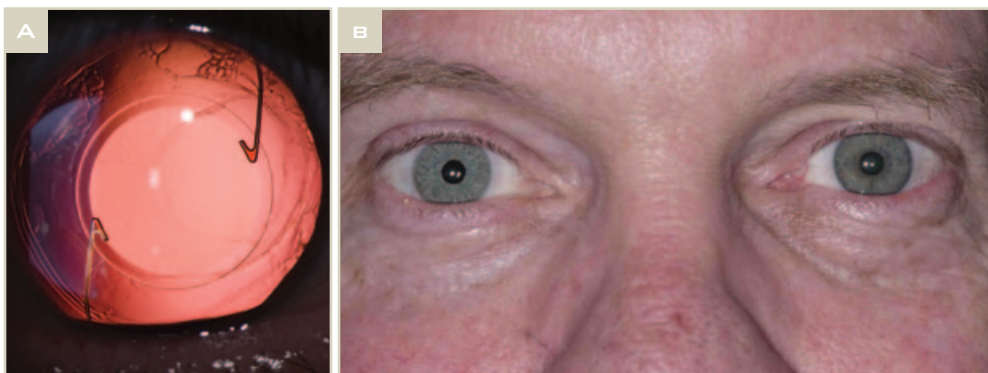I had gone to the operating room with two Morcher 50F modified CTRs that had to be placed inside an intact capsular bag. I had a "Plan A" only. A backup iris reconstruction lens would have required a second set of FDA and IRB approvals, and implantation of such a device would have required opening an 11-mm incision. I finished the procedure by performing a limited anterior vitrectomy and implanting a Staar Surgical AQ2010V lens in the ciliary sulcus (Fig. A).

Fortunately, several months later I became aware of a

beautiful new foldable artificial iris device that is being manufactured by Dr. Schmidt Intraocularlinsen, a subsidiary of HumanOptics AG. After extensive discussion, the patient consented to implantation of this device, and the results were spectacular (Fig. B). One year after this surgery, his vision was 20/20 uncorrected, and at a typical conversational distance, it was impossible to tell which eye had experienced the problem.

Ken Rosenthal In this case, the old adage "to fail to prepare is to prepare to fail" is somewhat overstated. As it turns out, the delay in the repair of the iris afforded the surgeon the opportunity to use a newer, more esthetically pleasing and less invasive method of iris repair. However, I learned early on, in the 15 years since I performed the first modern iris implantation surgery, that one should always have a sulcus fixation device available as a backup. When I request compassionate use for these non-FDA-approved devices, the alternative device is included in our IRB-submitted protocol, and we obtain a single-piece IOL/iris prosthesis (such as the Ophtec Model 311) as a backup. I have since determined, however, that in cases of incomplete bag tears, the iris prosthesis (especially the Ophtec Iris Prosthetic System) can be placed in a stable fashion. In addition, the Rasch-Rosenthal modified iris prosthesis (Morcher), such as the one Dr. Miller intended to use, can be placed in the ciliary sulcus and fixated to the sclera or, when present, to the iris remnants.

The audience response is interesting in that a majority would favor a contact lens rather than additional surgery. Although I always present this option to the patient when discussing solutions to remaining photosensitivity, only a handful of the hundreds of patients with iris defects I have treated have been successful contact lens wearers. This is due in part to the imperfect optical properties of an iris-painted contact lens, which is at the corneal plane (and in which the pupil position moves with each blink), as well as to the fact that many patients with iris defects (both congenital and traumatic) have significant ocular surface disease. These lenses are also less comfortable than normal cosmetic contact lenses because they are thicker and contain a texturized layer of pigment on the surface. If the surgical risk is appropriate, implantation of an iris prosthesis is a much better option.



CASE 7. (A) This slit-lamp biomicroscope photograph, which was taken without the instillation of dilating drops, shows a rent in the posterior capsule of the right eye and a Staar Surgical AQ2010V IOL in the ciliary sulcus. (B) This photograph shows both eyes after artificial iris implantation into the ciliary sulcus of the right eye.

Some audience participants suggested an IOL exchange. I would not recommend this in any instance because the iris prosthesis designed for sulcus/sutured fixation can be obtained without an IOL and implanted over the existing, stable IOL. It is important to take a careful history: A significant minority (perhaps 10 percent) of patients with iris defects do not have visual symptoms such as glare, photophobia and starbursts. These patients, of course, require no additional treatment.

The excellent result that Dr. Miller's patient enjoyed shows how amazing the HumanOptics iris prosthetic implants are. I have been very gratified to have implanted these devices, through a compassionate protocol, in patients who otherwise might not have been candidates for the older devices. By virtue of their superior cosmesis, versatility and minimally invasive implantation, these devices are life changers.

Case 8: Weak Zonules: Taking a Ride on the Gravitron

In Bonnie Henderson's patient with very weak zonules, the capsular bag and lens appear to be descending during phaco.

Q With the capsular bag seeming to drop more posteriorly, what would you do?

Continue to phaco carefully.	19%
Insert capsule retractors and continue phaco . . .	40%
Insert a CTR and continue phaco	10%
Insert capsule retractors and a CTR and continue phaco	23%
Convert to a manual ECCE	8%

Bonnie Henderson This 68-year-old woman had no preoperative signs of or risk factors for weak zonules. The procedure began with routine phacoemulsification with no obvious signs of zonular weakness during the capsulorrhexis or hydrodissection. During lens removal, however, attempts at chopping the lens were futile because of the posterior displacement of the lens. When it became apparent that the difficulty was due to weak zonules, capsule hooks were placed to bolster capsular support, and lens removal was successful. Before the epinucleus and cortex were removed, a modified CTR was placed for additional support. A three-piece IOL was implanted in the bag with the haptics positioned against the areas of zonular weakness.

Zonular dialysis is often associated with a horizontal displacement of the lens and prolapse of vitreous from behind the area of zonular loss. However, zonular weakness can be more subtle. Struggling to place a chopper and to cut the lens can be signs that zonular weakness is causing posterior displacement of the lens diaphragm. When confronted with

this situation, it's important to lower the fluidic parameters and inject viscoelastics before exiting the anterior chamber in order to maintain a stable chamber depth. Capsular hooks and rings can be useful adjuncts in these situations.

Garry Condon In this rather unexpected scenario in which there appeared to be long and lax zonular support, the entire lens/capsular bag complex descended posteriorly when an infusion was started. An attempt to phaco the lens immediately revealed the loose zonules' lack of support. The inadequate support allowed the lens and bag to continually "roll" away from the phaco tip when any pressure was applied to the lens. The first question to be answered was how we could be confident that there were, in fact, intact zonules in light of this most disconcerting lens behavior. In the absence of preexisting zonulopathy, these cases typically do not demonstrate any unusual preoperative slit-lamp findings that would alert us to this intraoperative challenge. One paradoxical slit-lamp/biometric finding that I have learned to appreciate, however, is an eye with an unusually shallow anterior chamber that has a normal axial length.

Recognizing that there is no coexisting PXF and that the lens rebounds to a central and anterior position upon returning to foot position zero are essential to feeling confident that one can continue with the case once zonular support is augmented with a device. The necessary counter-pressure against the phaco tip can be safely and effectively supplied with disposable capsular support devices that not only grasp the edge of the rhexis but also extend support out to the lens equator. I would recommend either the Mackool hooks or the new capsule retractors by MST for these cases. I would not be inclined to implant a CTR prior to lens removal unless zonular loss was evident at the outset. Using only the retractors would likely solve the support problem with the lax zonules and avoid the risk of damaging the bag and zonules unnecessarily by attempting to implant a ring. Once the lens is removed, implanting a CTR while the bag is fully inflated with viscoelastic and still supported with retractors is certainly reasonable, as the bag in these cases is extremely redundant and floppy. Loose but intact zonules usually do not require conversion to ECCE as long as the challenge is recognized and support is available.

Case 9: Frugality Leads to Frustration: A Needless Capsular Rupture

In Skip Nichamin's case, the posterior capsule was torn during IOL implantation.

Q What is your preferred (most common) incision for performing an anterior vitrectomy?

Use the phaco incision	56%
Create a new limbal incision	23%

- Perform pars plana sclerotomy 10%
- Place pars plana or limbal incisions,
depending on the case 11%

Skip Nichamin In this case, the posterior capsule was torn as a three-piece silicone IOL was being dialed into the capsular bag. The mishap occurred because of inadequate OVD inflation. Two issues led to this elementary technical error: First, our ambulatory surgical center had recently switched from a 0.8-mL OVD syringe to a 0.5-mL OVD syringe at the juncture of the case. Second, my attention to the status of the intraocular milieu had temporarily waned, and I did not notice the shallow state of the capsular fill.

This case offers two important take-away lessons. First, ongoing attempts to reduce costs can indeed have a direct and negative effect upon our clinical outcomes; and, second, a state of vigilant attention is essential, even during a routine case that is seemingly progressing in an expected manner. This complication occurred during a day in which everything was flowing in a perfectly smooth and effortless way, allowing me to drift into a relaxed “zone.” I had let my guard down and did not notice the shallowed capsular bag. Fortunately, closed chamber maneuvers and performance of a proper (pars approach) anterior vitrectomy resulted in a very good visual and anatomic result for this patient.

Nick Mamalis This case demonstrates the rare instance in which posterior capsular rupture occurs during IOL insertion. In this instance, the lens capsule was not adequately opened with OVD, allowing the IOL to catch on the capsule and cause a capsular bag rupture. Once such a rupture has occurred, and if any vitreous has entered the anterior chamber, it is important to remove all the vitreous via a vitrectomy in a closed system within the anterior chamber if possible. The preferred incision for performing an anterior vitrectomy depends upon the surgeon’s experience and preferences. One advantage of performing the vitrectomy through the pars plana is that the vitreous is drawn posteriorly to its normal anatomic position. This may decrease traction on the retina and help limit the amount of vitreous that is pulled into the anterior chamber using an anterior approach. However, this approach involves a pars plana incision and requires that the surgeon be comfortable with and very well versed in working from the pars plana. This approach was preferred by only 10 percent of the audience respondents. However, an additional 11 percent stated that they use both pars plana and limbal incisions, depending on the particular case. The pars plana incision can be performed with a vitrectomy probe placed into the anterior vitreous and the irrigation placed through a clear corneal stab incision anteriorly.

The majority of respondents preferred an anterior approach, with 56 percent using the phaco incision and 23 percent creating a new limbal incision. Regardless of which incision is chosen, the irrigation must be split from the vitrectomy probe so as not to hydrate the vitreous and push it away from the vitrectomy probe. A second stab incision can

be made at the limbus in the clear cornea to insert the irrigation port. The vitrectomy probe must be placed through an incision that seals around the port and does not allow leakage around the vitrector, shallowing the anterior chamber. If this cannot be achieved through the phacoemulsification incision, a second clear corneal incision can be made and the vitrectomy probe inserted away from the phacoemulsification incision.

It is important to use as high a cutting rate as possible for the vitrectomy probe. The rate of aspiration depends on the degree of irrigation as well as on the cutting speed. The bottle height is usually set low by the default setting on the phacoemulsification machine, but it should be raised as the vitrectomy progresses or if hypotony begins to develop. Preservative-free triamcinolone may be injected into the anterior chamber through the paracentesis to help visualize any remaining strands of vitreous. With triamcinolone, the vitreous will stain with small white particles in a sheetlike pattern. Excess triamcinolone can then be washed out with balanced salt solution. Any remaining strands of vitreous can be identified and removed from the anterior chamber along with the triamcinolone. With meticulous technique, vitreous can be safely removed after a posterior capsular tear, allowing a successful outcome to the case.

CASES 7 TO 9. “Mariano Rivera Award” voted for the presenter who had the best surgical save:

- Kevin Miller: Iris defect 63%
- Bonnie Henderson: Zonular weakness 22%
- Skip Nichamin: Posterior capsular rupture 14%

Case 10: Vitreous Lost and Vitreous Found

In Eric Donnenfeld’s case, an anterior capsular tear extends into the posterior capsule during surgery. Later, the PC IOL is placed into the ciliary sulcus.

Q After noticing a posterior extension of the radial anterior capsular tear, I would:

- Carefully continue phaco 55%
- Perform an anterior vitrectomy to clear any
prolapsing vitreous prior to resuming phaco . . . 30%
- Continue phaco over a Sheets glide 13%
- Convert to a manual ECCE 3%

Eric Donnenfeld Radial anterior tears are moderately common and become more significant when they extend posteriorly because of the increased risk of vitreous loss. When a posterior tear of the capsule is noted, the surgeon should immediately stop the procedure but leave the phaco tip in the eye with enough infusion of balanced salt solution to maintain the anterior chamber. Removing the phaco tip typically causes the anterior chamber to flatten, pulling vit-

reous forward. The second instrument should be removed and a dispersive viscoelastic placed in the area of the posterior capsular tear to segment the exposed vitreous face and protect against progression of the capsular tear. Reduce the flow and vacuum and carefully remove the remaining nucleus and cortex by working as far away from the capsular tear as possible. Dispersive viscoelastic can be replaced as needed.

Warren Hill See answer under next question.

Q After initially placing a three-piece PC IOL into the sulcus, I would:

- Leave it as is 71%
- Capture the optic with the remaining anterior capsule 23%
- Rotate the IOL into the capsular bag 4%
- Iris suture fixate the haptics 3%

Eric Donnenfeld The audience got this one completely correct. Leave the three-piece PC IOL in the sulcus and rotate the haptics away from the area of the posterior capsular tear. With a small, localized posterior tear, the lens could be placed in the capsular bag; but in this case, the tear was too extensive to consider this option. Most important, do not capture the optic behind the anterior capsule unless the capsulorrhexis is intact. Pressing on the IOL will compress the vitreous face, causing vitreous to prolapse into the anterior chamber.

Warren Hill I agree with the majority of the audience who felt that phacoemulsification can be carefully continued in the presence of a posterior extension of a radial anterior capsular tear. If this is handled carefully, such an occurrence does not need to result in vitreous prolapse; but the surgeon must be mindful of what may follow if attention to detail is lost. Isolation of the area with viscoelastic and reduced fluid flow and aspiration go a long way in preventing an anterior tear from extending posteriorly, or a posterior extension from enlarging. However, any part of the procedure, if ill conceived, may initiate the complication cascade.



SHOCKING SIGHTS. The audience is aghast at seeing ruptured posterior capsules, descending nuclei and other mishaps.

If only the capsule is involved, viscoelastic can be used effectively to isolate the vitreous face, thereby reducing the risk of prolapse into the anterior chamber. A sulcus-placed three-piece IOL would follow, preferably one with a large haptic diameter and a large optic. If vitreous prolapse does occur, a 1:4 dilution of nonpreserved triamcinolone is often used for easy identification of vitreous and to aid in its removal. A very small amount of Triesence (Alcon) should also remain in the eye to minimize postoperative inflammation. In the case presented, attempting optic capture in the presence of a capsular tear was nothing less than asking for trouble ... and trouble was found.

Case 11: “Floppy Bag” Syndrome: I Left What, Where?

In Sam Masket’s case, zonular weakness was evident during surgery. Postoperatively, recurrent iridocyclitis and inflammation are present.

Q What is your differential diagnosis?

- Infectious endophthalmitis 7%
- Retained nuclear chip 48%
- Both 34%
- Neither 11%

Sam Masket This case offers several points for learning. The “floppy bag,” induced by generalized weakness of the zonules, is among the risk factors for retained nuclear remnants. Other associated risk factors include dense cataracts, small pupils and, in particular, intraoperative floppy iris syndrome. In this case, the weakened zonules required use of a CTR; but despite its use, vitreous prolapsed around the lens into the main and side-port incisions, requiring anterior vitrectomy. To my thinking, the nuclear remnant became trapped in vitreous under the iris, allowing it to “hide” at the close of surgery.

Sizable nuclear “chips” in the posterior chamber or anterior vitreous will induce inflammation that often develops after topical NSAIDs and corticosteroids have been discontinued, as noted in this case. The nuclear fragment was tolerated for several months, as long as anti-inflammatory medications were employed. When these were discontinued, the inflammation reappeared. However, despite topical medications, by four months after surgery the eye had become “hot.” Fortunately, the nuclear remnant was visualized. After its removal, the inflammation subsided and the eye attained clinically normal postoperative status. Had I not actually seen the “tip of the iceberg” of the nuclear piece in the inferior posterior chamber, anterior segment ultrasound biomicroscopy would have been indicated and likely helpful. Fortunately, neither cystoid macular edema nor

significant elevation of IOP occurred in my case, although these are frequent complications of retained nuclear fragments. Nuclear chips in the anterior chamber are often associated with corneal decompensation, not present herein.

The pattern of repeated bouts of inflammation after seemingly uneventful cataract surgery might also represent low-grade endophthalmitis, typically induced by anaerobic microbes such as *Propionibacterium acnes*. Although keratic precipitates and vitritis might be more evident in that scenario, absent the eventually obvious nuclear remnant in this case, ocular fluid samples (anterior chamber and vitreous) should have been obtained for culture and sensitivity testing, followed by administration of intraocular antibiotics.

Corrective surgery in this case was aided by the use of iris retractors, nonpreserved triamcinolone and anterior vitrectomy. In dealing with cases of “floppy bag” syndrome,

surgeons should be particularly vigilant in looking for nuclear remnants at the close of surgery.

Rosa Braga-Mele I agree with the audience poll. Given the scenario, my first inclination is that a retained nuclear fragment is causing the inflammation. However, one cannot be too cavalier and must keep the possibility of endophthalmitis on the back burner. At this point, I would begin a course of aggressive topical steroid treatment and look for a nuclear fragment, either by gonioscopy or by performing anterior segment optical coherence tomography or ultrasound biomicroscopy. I would definitely revisit the situation in 24 hours and, if a nuclear chip is suspected, take the patient back to the operating room for chip removal. If no nuclear chip is evident, the inflammation must be considered evidence of potential endophthalmitis and treated in conjunction with one of our retina colleagues.

Case 12: Vitreous Prolapse—Get Out of a Sticky Situation

In Ike Ahmed's case, with a zonular dialysis, vitreous has prolapsed into the anterior chamber during phaco.

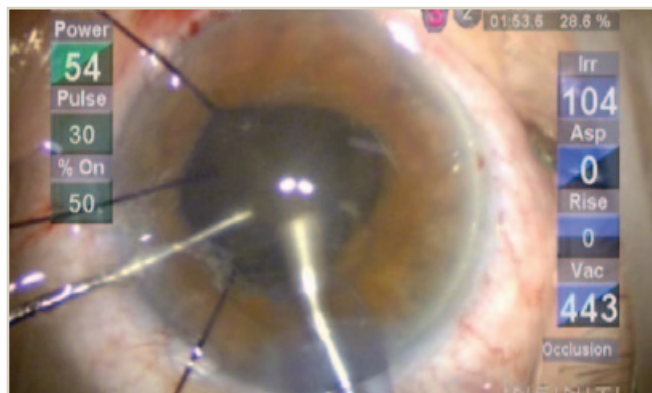
Q With a loose capsular bag and vitreous prolapse into the anterior chamber, what would you do?

- Convert to a manual ECCE 35%
- Perform an anterior vitrectomy, implant a CTR in the bag and continue phaco 13%
- Perform an anterior vitrectomy, insert capsule retractors and continue phaco 21%
- Viscopartition the vitreous and continue phaco 9%
- Viscopartition the vitreous, insert capsule retractors and continue phaco 22%

Ike Ahmed This 85-year-old patient had a dense black cataract and small pupil. The surgery began uneventfully, but after the first crack of the nucleus, it was evident that vitreous (with asteroid hyalosis) had prolapsed around the lens superiorly and toward the side-port incision. Of course, no one likes vitreous in the anterior chamber, but removing it could have caused further loss of support for the lens; coincidentally, the vitreous that had already prolapsed forward was diverted to the side port, away from the phaco tip.

Removing prolapsed vitreous acutely will not reduce existing vitreoretinal traction, but the vitreous should be removed to prevent additional traction. Fortunately, in this case, the vitreous prolapse stabilized when it was diverted to the side port (think of the side port as a hand holding the vitreous away). With the vitreous out of the way, it was unlikely to be engaged and cause further traction.

In fact, performing an anterior vitrectomy through a limbal incision probably would have caused more vitreous to move forward. Furthermore, viscopartition with a dispersive OVD sequestered the area of prolapse, enabling ma-



CASE 12. Vitreous prolapse with asteroid hyalosis present to the superior side port (left side of image). OVD has been used to partition the vitreous from the central anterior chamber and phaco tip, and iris hooks have been placed to support the capsulorrhexis and capsular bag.

nipulations to be made in the anterior chamber, away from the side port, without engaging vitreous.

Finally, three iris hooks were placed along the edge of the capsulorrhexis to support the capsular bag. The dense lens was successfully removed without engaging vitreous or capsule.

At this point—with a very mobile capsular bag in an elderly patient—removing the bag and placing an AC IOL appeared to be the most efficient and safe option. Micrograspers were used to pull out the empty (and intact) capsular bag in its entirety, while viscoelastic was used to keep the area of vitreous away from the site. Although it can be argued that pulling on zonules might cause an inadvertent retinal tear, minimal zonules were present. Those that were present were so loose that no tension was required to pull out the bag.

The vitreous prolapse was swept back behind the pupil; and, as asteroid hyalosis was present, this helped to visualize and ensure that all vitreous was repositioned. Under OVD stabilization of the anterior chamber, an AC IOL was placed; a small peripheral iridectomy was made with micro-scissors; and all wounds were sutured. It is easy to say, “Just do a vitrectomy,” but in the larger context, managing with viscopartition and sequestering of vitreous permitted the safe removal of lens material.

Converting to manual ECCE would be more traumatic and would most certainly result in greater vitreous loss. As long as the vitreous is kept isolated, with sufficient use of dispersive OVD to viscopartition the anterior chamber, and iris hooks are used to support the capsular bag, the dense nucleus can be phacoemulsified. A CTR was not used in this case because placement of an in-the-bag PC IOL was believed to be unlikely considering the degree of zonulysis, and suturing a capsular tension device was even less likely because an AC IOL would be tolerated in this patient.

Jennifer Lim First of all, it is important to remove the vitreous from the wound margins and the anterior segment before attempting any further phacoemulsification of the lens. Vitreous traction on the retina must be relieved in order to reduce the risk of causing a retinal break or subsequent retinal tear, detachment and postoperative cystoid macular edema. Attempts to viscopartition the vitreous are fraught with an increased risk of retinal tears because this maneuver exerts tractional forces on the vitreous base. If significant vitreous prolapse has occurred, and the lens is now located in the posterior segment, I would involve the retina surgeon early in the management of this patient. Ideally, a retina surgeon could perform a pars plana vitrectomy at the same surgery or on the same day. If the vitreous can be removed with anterior vitrectomy and the anterior bag is able to support an IOL, I recommend inserting an IOL. Any lens fragments in the posterior segment pose too great a risk of causing retinal tears or choroidal detachments if attempts are made to remove the lens fragments anteriorly. It is easiest for the patient if the retina surgeon can remove these

fragments on the same day. Even if lens fragments were not found posteriorly and an anterior vitrectomy was successfully performed, the patient should be referred to a retina specialist for postoperative evaluation because of the high risk of developing the posterior complications mentioned.

Q With the zonular dialysis, where would you place an IOL in this patient?

- Implant an anterior chamber IOL 76%
- Place a posterior chamber IOL in the bag following a CTR 2%
- Place a posterior chamber IOL in the bag along with a sutured Cionni ring or capsular tension segment 1%
- Place a posterior chamber IOL in the ciliary sulcus 9%
- Scleral suture a sulcus posterior chamber IOL 12%

Ike Ahmed In an 85-year-old with no history of glaucoma and an average-sized eye, an AC IOL may be the simplest approach. It has the lowest intraoperative risk and should be well tolerated. If the patient were younger than 65, an iris- or scleral-fixated PC IOL could have been considered.

Rosa Braga-Mele When evaluating the placement of an IOL, one needs to look at the patient’s age and health status and at the status of the capsular bag. In this case, the patient was quite elderly, and the capsular bag had been completely removed. As a result, I agree with the audience responses, and I would implant an AC IOL through the smallest incision possible. If the patient had been younger, I probably would have sutured a sulcus posterior chamber IOL either to the iris or to the sclera. If there had been some capsular support, suturing a CTR or CTS also would have been a viable solution.

CASES 10 TO 12. “Meet Me in Vegas Award” for the surgeon who had the luckiest outcome:

- Eric Donnenfeld: Vitreous prolapsed. 13%
- Sam Masket: Retained nucleus. 7%
- Ike Ahmed: Vitreous prolapsed. 80%

Case 13: It’s Going, Going, Gone ... or Maybe Not?

Terry Kim’s patient had previously undergone a pars plana vitrectomy. During phaco, the posterior capsule ruptured and the nucleus dropped posteriorly.

Q The lens has dropped posteriorly. Now what?

- Call a retina specialist into the OR 18%
- Attempt a PAL maneuver to elevate the nucleus. 21%
- Abandon the dropped material, implant an IOL and observe the patient 40%
- Same as previous response, but promptly refer to a retina specialist postoperatively. 16%
- Abort surgery (no IOL) and promptly refer to a retina specialist postoperatively. 5%

Terry Kim In this diabetic patient who had previously undergone pars plana vitrectomy, a white, mature cortical cataract formed quite rapidly and required cataract surgery. After staining the anterior capsule with trypan blue, I performed a continuous curvilinear capsulorrhexis (CCC) without incident. However, after hydrodissection and initiation of irrigation with the phaco tip, the posterior capsule suddenly ruptured, with subsequent loss of the nucleus into the posterior segment.

A retina specialist was called into the OR for anticipated pars plana lensectomy. In an effort to help clear the view for the retina specialist before his arrival, the I&A tip was used to remove the cortical material. After most of the cortex was

cleared, fragments of the dropped nucleus were observed floating anteriorly toward the I&A tip because of the I&A flow currents. At this point, with the consent of the retina specialist, a phaco tip was inserted through the posterior capsular opening to remove these nuclear fragments. Again, the I&A flow currents from the phaco tip helped tumble the nuclear fragments anteriorly for uneventful phacoemulsification in the posterior segment. Afterward, a three-piece acrylic IOL was implanted in the ciliary sulcus with anterior capsular capture of the optic. A dilated fundus examination at the conclusion of the procedure confirmed complete removal of all nuclear and cortical lens material and no retinal damage.

Every cataract surgeon should know that when a posterior capsular rupture results in posterior descent of the nucleus, a pars plana vitrectomy/pars plana lensectomy with a vitrectomy cutter/fragmatome is typically performed to avoid vitreous incarceration by the phaco tip and potential retinal damage. Alternatively, a PAL technique can be used through a pars plana incision with a spatula and/or dispersive viscoelastic to deliver the dropping nucleus into the anterior chamber for eventual phacoemulsification. However, this case illustrates that lens/cortex removal can be performed successfully with a phaco tip in the posterior segment as long as no vitreous is present or encountered. Subsequent sulcus IOL implantation can result in an excellent surgical outcome without requiring any pars plana procedures.

Tim Olsen Dr. Kim presents a unique case that was managed appropriately. Using the approach described in this case requires caution in some areas. This diabetic patient had previously undergone vitrectomy, presumably for proliferative diabetic retinopathy, and was left phakic. A cataract ensued. During the anterior segment approach, capsular incompetence became evident and may have been related to the prior vitrectomy. Some diabetics will require an aggressive anterior vitreous base dissection that addresses peripheral vitreoretinal pathology (traction and neovascularization). Such a procedure may lead to zonular and/or capsular weakening. From a posterior segment surgeon's point of view, addressing anterior proliferation aggressively is a sign of an appropriately thorough vitrectomy, even if it means more rapid cataract progression. Failure to address this anterior vitreous base area may lead to recurrent vitreous hemorrhages.

A key point is that Dr. Kim had a posterior segment colleague assess the case before he inserted the phaco tip into the posterior segment. If called into the OR under similar circumstances, I would carefully assess the eye for remaining vitreous and ensure that the infusion was adequately maintaining the intraocular pressure during the procedure. The technique described by Dr. Kim is very similar to the fluid dynamics that we employ in the posterior segment, using a fragmatome along with a pars plana infusion. Many times, especially with a complete vitrectomy, the crystalline lens will float on the fluid currents inside the eye and be-

come impaled on the tip of the ultrasonic device. With adequate aspiration, the lens can be fragmented and removed.

When Dr. Kim's technique is performed from the anterior segment, the surgeon should be alert to several potential complications: 1) vitreous may become incarcerated in the phaco tip, especially with a sub-complete vitrectomy; 2) some fragmented nuclear particles may remain behind, adhere to the retinal surface, and lead to postoperative inflammation and cystoid macular edema; 3) overuse of the high-flow infusion could lead to large retinal breaks or even giant retinal tears; and 4) visualizing the peripheral vitreous base region is difficult with the anterior segment approach.

The successful outcome in this case was under the supervision of a retina specialist, who was prepared to manage a peripheral retinal break, tear or even a giant retinal tear. One should be fully aware that these serious complications could arise during a case like this one. Finally, in an eye that had only had a core or a more limited posterior vitrectomy, the risk would be much higher. In these instances, the procedure described by Dr. Kim should be avoided because the remaining peripheral vitreous skirt would certainly be engaged in the phaco tip, leading to significant retinal morbidity.

Case 14: Nano Nasty (Challenges of a Tiny Globe)

Richard Packard's case is one of a nanophthalmic eye with a crowded anterior chamber. Difficulty arose in deepening the anterior chamber with viscoelastic at the outset of surgery. Following posterior capsular rupture, the entire nucleus descended. A PAL technique was unsuccessful. Postoperatively, the eye developed a retinal detachment that was not successfully repaired.

Q In this nanophthalmic eye with a persistently shallow anterior chamber, what is your next step?

- Perform digital ocular massage. 3%
- Administer an osmotic agent (e.g., IV mannitol) . . . 42%
- Perform a pars plana vitreous tap 51%
- Close the eye and refer 3%

Richard Packard Short eyes, whether nanophthalmic or those with a crowded anterior chamber, present the surgeon with a number of issues. These include getting the biometry right, having an IOL of sufficiently high power, having surgical space to carry out the cataract removal without damaging intraocular structures, and avoiding or overcoming the risks of iris prolapse. In this particular case, the anterior chamber was very shallow to begin with. After the incisions were made and while the posterior synechiae were being broken down, the iris started to prolapse through the phaco wound. Despite attempts with high-viscosity viscoelastics

and peripheral iridectomy, there was no way to proceed without some further intervention.

When asked how to proceed, 51 percent of the audience respondents chose to carry out a limited dry pars plana vitrectomy. Forty-two percent wanted to use an osmotic agent, but this would have meant stopping the case for at least 30 minutes to allow for the agent to take effect. Therefore, a vitrectomy was performed through an incision located 2.5 mm behind the limbus, and the capsulorrhexis and hydrodissection apparently proceeded normally. However, when the phaco was initiated, it became apparent that the nucleus had dropped, presumably because of capsular damage during the vitrectomy. After the anterior segment was cleared, no lens was implanted because the selected high-power lens (+45) was not suitable for sulcus placement. When the vitreoretinal procedure was completed, it became clear that the pars plana did not really exist in this eye, and both the original entry and those made by the second surgeon were through the retina. A retinal detachment ensued and was repaired with silicone oil. The patient has very poor unaided vision and is very unhappy, resulting in a medico-legal case.

Learning points include: Try to decompress these eyes before surgery, using osmotic agents and possibly ocular massage; use the smallest incisions possible to minimize the risk of iris escape; and make the tunnels as long as is feasible. If you are considering doing a vitrectomy, try to establish whether a pars plana is present; and if you do a vitrectomy, keep the cutter mouth away from the capsule.

Bob Cionni The nanophthalmic eye that is in need of cataract surgery is one of the most challenging cases we encounter in our practices today. The challenges go well

beyond the difficulty of selecting an IOL. These eyes tend to have very small and shallow anterior chambers, making surgical maneuvers difficult. In addition, nanophthalmic eyes have a higher likelihood of developing a choroidal effusion, with relentless positive pressure and the possibility of expulsive hemorrhage. However, several techniques can be considered to better ensure a successful outcome.

The two most reliable means of deepening the anterior chamber and decreasing the intraoperative pressure are the use of IV mannitol and tapping the vitreous with a small-gauge vitrector. The audience was split between these two choices as the preferred method to manage this particular patient; and, indeed, both methods would likely work. This case highlights the danger of attempting a pars plana approach for the vitreous tap in nanophthalmic eyes, as they typically demonstrate unusual anatomy. Therefore, although one would normally place a stab incision 3.5 mm posterior to the limbus, in this eye, such an incision would enter through the retina, leading to a retinal tear and probably to retinal detachment. Indeed, even though the surgeon placed the incision more anteriorly than this (2.5 mm posterior to the limbus), the retina was still damaged by the stab incision. If the incision is placed too far anteriorly, the surgeon risks damaging the lens capsule at the outset of the procedure—also an undesirable situation.

The safest method might indeed be the use of intravenous 20 percent mannitol (100 mL or 1 to 2 mg/kg). This should be given at least 30 minutes before the procedure in order to allow time for the eye to soften. Care should be taken to prevent the eye from becoming hypotonous at any time, a situation that would increase the likelihood of choroidal effusion.

Case 15: Tased by Descemet's!

Bill Fishkind had a case in which he attempted stromal hydration, and a large Descemet's detachment was created at the site of the cataract incision.

Q On postop day 1, a 4+ corneal edema had developed and Descemet's membrane had detached. How would you treat this?

- Inject an air bubble at the slit lamp 28%
- Fill the anterior chamber with OVD plus air (in the OR) 28%
- Fill the anterior chamber with SF6 (in the OR) . . . 18%
- Just observe 11%
- Refer elsewhere 15%

Bill Fishkind Although said countless times, the initial lesson of this case is that “It’s not over until it’s over.” At the closing stages of this case, a huge, unexpected Descemet’s detachment occurred, requiring intervention and triggering in the surgeon a shock akin to that of a Taser. The treatment was to fill the anterior chamber with OVD and air (air lasts

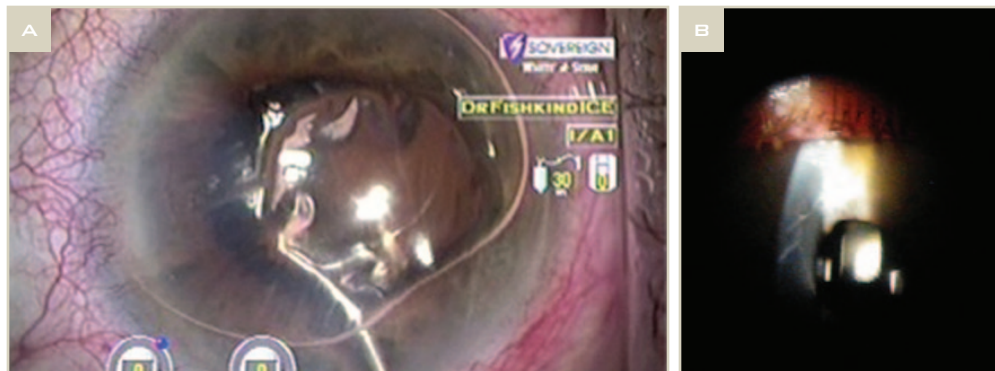
two days) or OVD and SF6 24 percent (SF6 lasts two weeks), while concurrently making a paracentesis by entering into the space between Descemet’s and the stroma and releasing the injected air. With this maneuver, Descemet’s is driven toward the stroma, allowing the endothelial cell pump to reattach.

The second lesson is that early recognition of this situation, and interrupting the air injection at the earliest sign of its occurrence, can lessen its severity. Finally, less significant Descemet’s detachments may be observed postoperatively. These usually require similar interventions on a nonemergent basis.

This patient had a second filling of the anterior chamber with OVD and air at one week postop. This halved the size of the detachment, which then gradually resolved over the next month. One year after this complication, the cornea appeared thin and clear with a few striae.

Randy Olson The audience responses show that this bad scenario has no perfect solution. With an almost complete Descemet’s detachment, air may not stick around long

CASE 15. (A) Large Descemet's detachment with OVD and air in the anterior chamber. (B) Striae are seen in the clear cornea one year postoperatively.



enough; any OVD that gets between the stroma and Descemet's membrane can be a disaster; "observation and hope" is a questionable strategy for a truly bad detachment; and SF6 is toxic (as is extant air to a lesser degree). Entire chapters have been written on this subject; but, in summary, a tear in Descemet's membrane should be sutured closed and to the stroma. If partial attachment is noted, air is a good first step and is often enough to resolve the issue because the endothelial pump wants to fix this problem if given a chance. Furthermore, the surgeon should be very leery of using any OVD because it can get into the interface so easily and then act as a barrier to reattachment; removal is very hard on the

endothelium and is difficult to do. SF6 is a good step for a complete detachment without a tear in Descemet's membrane and as a second step if air has failed.

CASES 13 TO 15. "Purple Heart Award" for the surgeon who attempted the most courageous intraoperative maneuvers:

Terry Kim: Dropped lens	36%
Richard Packard: Dropped lens	53%
Bill Fishkind: Descemet's detachment	11%

Case 16: Small-Pupil Surgery: Opening Pandora's Box

In Amar Agarwal's case, the patient had a small pupil and weak zonules, and a CTR was inserted. Subsequently, an IOL was implanted in the weakened capsular bag, and the entire bag with the IOL descended posteriorly.

Q In the absence of sufficient capsular support, what IOL do you prefer to implant?

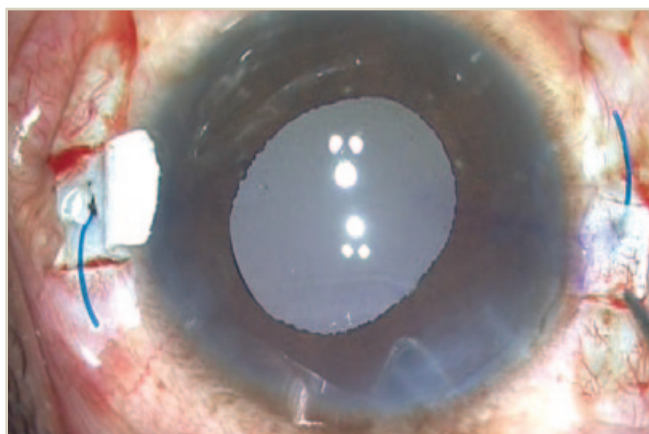
- Anterior chamber IOL 55%
- Scleral-sutured posterior chamber IOL 26%
- Iris-sutured posterior chamber IOL 12%
- Glued posterior chamber IOL (with haptics placed in scleral tunnels) 5%
- No IOL: Refer later for secondary IOL 2%

Amar Agarwal This case—a small-pupil surgery—opened a Pandora's box and turned out to be my "longest day" in surgery. Because the zonules were weak, a CTR was inserted. The phaco portion went smoothly, and the IOL was implanted. But when the viscoelastic was removed with the I&A probe, vitreous was seen protruding out of the corneal incision. Soon the endocapsular ring began to come out of the bag. Then, when bimanual vitrectomy was started, the iris was accidentally chewed up. Subsequently, the endocapsular ring was removed, but the ring snapped in half because it was grasped in the middle. The remaining piece of the CTR was then removed separately.

By this time, the PC IOL was sinking. I attempted to remove it, but the PC IOL fell into the vitreous cavity. Even-

tually, scleral flaps were prepared 180 degrees apart for the glued IOL technique. A chandelier illumination was fixed for posterior vitrectomy. A three-port vitrectomy was performed, followed by grasping the haptic of the IOL, which was lying on the retina. The IOL was explanted, and a three-piece IOL was tucked into Scharioth scleral tunnels. The haptics were then glued using Tisseel (Baxter USA). The iris was also repaired using a McCannel suture.

One year later, the patient had 20/20 vision with zero sphere and 0.75 D cylinder. A principal reason for such a good result is that with the glued IOL, no pseudophacodonesis develops (unlike a sutured IOL, which moves like



CASE 16. Glued IOL. Note that the haptics are externalized.

a hammock). Viewed with high-speed videography, which takes 200 frames per second, the glued PC IOL clearly does not move. The take-home messages are that a Malyugin Ring (MicroSurgical Technology) or iris hooks should have been used because of the small pupil; and, instead of a simple CTR, we could have used a Cionni ring, Ahmed Capsular Tension Segment or a glued endocapsular ring. When the ring was being explanted, a handshake technique would have found the eyelets easily, preventing the ring from breaking. Finally, when one has a dropped IOL, it is always better to use chandelier illumination, as it gives a better view of the retina.

Five percent of the audience voted for the glued IOL. With our four-year follow-up showing good results, we feel

this is a very good technique for implanting IOLs in eyes without a capsule.

Roger Steinert Surgeon comfort levels with AC IOLs continue to beat those of various PC IOL techniques by a 55-43 margin (2 percent abstaining). However, this year we are seeing increased interest in the scleral tunnel/glue technique pioneered by Dr. Agarwal. This technique requires careful observance of key steps in the procedure. When the technique is performed correctly, the surgeon can obtain scleral fixation without the risk of suture breakage in the years after surgery. Of course, the scleral tunnel/glue technique needs longer follow-up and more widespread use before it can be crowned as the better alternative to scleral-suture fixation of PC IOLs.

Case 17: My Worst Case Ever: An Elderly PAL With PXF

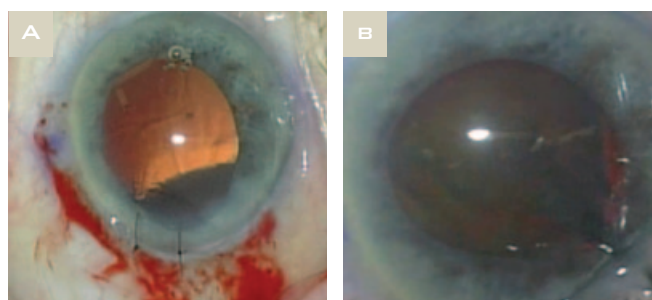
Rich Hoffman's case is one of pseudoexfoliation in an elderly patient, with a zonular dialysis, posterior capsular rupture, descending nucleus and suprachoroidal hemorrhage.

Q For an elderly PXF patient with a 4+ nuclear sclerotic cataract, I would place a CTR:

Automatically prior to starting phaco.	7%
Prior to phaco only if weak zonules were noted during the capsulorrhexis	23%
During phaco if it became apparent then that the zonules were abnormal	28%
Only after cortical I&A had been completed.	16%
I have not used/do not use CTRs	26%

Rich Hoffman This is a case of pseudoexfoliation in an elderly patient in whom an intraoperative zonular dialysis, descending nucleus and suprachoroidal hemorrhage occurred after an attempted posterior-assisted levitation. No evidence of zonular weakness was noted during creation of the capsulorrhexis, but after rotation of the lens nucleus, a severe zonular dialysis was created. Attempts to support the lens with hooks were unsuccessful because of the posterior subluxation of the inferior equator of the lens. Instead of attempting to elevate the lens into a better position, which would have allowed the hooks to be placed onto the rhexis for support, I panicked and resorted to a PAL of the lens into the anterior chamber and an intracapsular extraction through a large limbal incision.

A large amount of vitreous prolapse developed during lens removal; and instead of completely securing the incision with multiple interrupted sutures, I closed the wound with only two sutures to avoid incarcerating vitreous in the incision. After a five-minute vitrectomy, a suprachoroidal hemorrhage developed from the relative hypotony that was created from the inadequately secured incision. The patient underwent two subsequent choroidal drainages and a secondary AC IOL. The final result was quite dismal, leaving



CASE 17. (A) Hemorrhage. (B) Zonular dialysis.

the patient with a visual acuity of 20/100.

After several years of understandable procrastination, the patient proceeded with surgery in her second eye, which over time had developed a 4+ nuclear sclerosis (20/200) in addition to her PXF. After the experience with the first eye, I took certain precautions, including blocking the eye and having a retina surgeon scrubbed and sitting in the operating room during the cataract extraction. Hooks and a CTR were planned after the capsulorrhexis, but they were not used because the zonules appeared very stable. However, within a very short time after I started phacoemulsification, the lens came loose and was dangling from a few zonules. The retina surgeon stepped in, performed an immediate pars plana lensectomy/pars plana vitrectomy and placed an anterior chamber IOL, which achieved a good visual result.

This case offers many lessons, including the need to make every effort to keep the incision small until all other avenues have been exhausted. If a large wound is required, it should be closed completely in order to maintain an adequate IOP and avoid hypotony. Incarcerated vitreous can be cut free from the incision with a vitrector through a second small incision, and interrupted sutures with vitreous remnants can be removed one by one until all vitreous has been cleaned from the wound.

This case raises the question of whether we should be placing prophylactic CTRs and capsule hooks in elderly patients with PXF. The current teaching is that CTRs and hooks should be placed only at the first sign of zonular weakness, but in this case there was no evidence of zonular weakness until it was too late. I believe that in extremely elderly patients with PXF, hooks and CTRs should be placed after the capsulorrhexis but before phacoemulsification—regardless of the degree of nuclear sclerosis. This will support the zonular apparatus and prevent the development of zonular misadventures. The final lesson from this case was to prepare for similar events in second eyes.

Howard Gimbel The audience response to the question of when to place a CTR for a patient with PXF and a 4+ nuclear sclerotic cataract was quite mixed. I believe that this reflects the experience of most of us in that PXF does not necessarily mean that the zonules are going to be so weak that a CTR has to be placed before cataract extraction. Certainly, when doing the CCC we get a good indication of how loose the zonules may be; but as the dense nucleus is being removed from the lens, and the endoskeleton effect of the nucleus is gone, the bag may collapse more than was expected from its behavior during the capsulorrhexis step. The CTR may also be placed partway through phacoemulsification. Thus, I believe that all of the responses can be appropriate for different cases. We all know that placing the CTR before starting phaco poses more difficulty in removing the cortex, and that is why many surgeons resist placing it automatically unless there is sufficient evidence to justify the ring and the added technical difficulty. I think those who have not used CTRs probably have not faced the extreme zonular laxity that we see with PXF.

Case 18: A True Emergency

In Bob Osher's case, globe perforation occurred during a peribulbar block with intraocular injection of anesthetic, resulting in a patient who reported no light perception.

Q Postoperatively, a patient declares that he can see absolutely nothing. At this moment, what are you thinking?

- Sheer panic 37%
- I could relocate my practice to Bolivia 5%
- Medical ophthalmology has its plusses 13%
- Did I pay my malpractice premium? 45%

Q Do you verbally inform every cataract patient about the risk of blindness?

- Yes, I tell everyone. 65%
- I mention this risk only to one-eyed patients or if I am dealing with a more complicated case. . . 16%
- No, I only discuss this if the patient asks me. . . . 15%
- I don't do cataract surgery 4%

Bob Osher About a third of the respondents do not specifically mention the risk of blindness. Neither do I. If a patient asks me what is the worst thing that can happen during the surgery, I look him in the eye and respond “For me to die!” That invariably brings a smile to the patient’s face, and the ice is broken. Then I can mention the other horrible possibilities, including blindness. But I do not like to upset the patient during my examination and then again, when my assistant reviews the informed consent form, which contains all possible complications, including loss of vision. My obligation is to be absolutely honest but not to provoke more patient anxiety than necessary.

Dick Lindstrom I side with the majority, who discuss the possibility of blindness with every patient about to undergo cataract surgery. My standard has always been to discuss the most frequent and the worst possible complications. I advise patients in lay language that the thin, transparent membrane behind the implant may become cloudy through the natural healing process and would require a painless office laser treatment in one-third of patients. Furthermore, I explain that transient elevation of pressure, corneal swelling and inflammation are common and are the reasons we need to do the postop visits—to check for them and treat appropriately. I then tell patients that the worst thing that can happen is an unexpected infection or bleeding, which in the worst case could cause severe or total loss of vision. I also write in my own handwriting that I discussed alternatives, benefits and risks, and it is wise to say “including loss of vision and blindness.” Most juries will come to the conclusion that if the patient was willing to accept blindness as a risk to overcome their visual handicap from cataracts, they would likely have accepted less severe side effects like mild dry eye symptoms or residual astigmatism or defocus. Of course, we have a written informed consent document that is more comprehensive; but in my experience, it is the face-to-face discussion and the surgeon’s documentation of this in the chart that is the most powerful deterrent to litigation. It is simply impossible to discuss all complications in detail, but sharing the most common and most severe has served me well.

CASES 16 TO 18. “Witness Protection Program Award” for the surgeon who displayed the most courage by his or her willingness to present such a difficult case in public:

- Amar Agarwal: Dropped IOL 68%
- Richard Hoffman: Suprachoroidal hemorrhage . . 14%
- Bob Osher: Globe perforation 18%

LAST QUESTION. What was the highlight of your trip to Orlando?

- I went to Disney World 25%
- I went to Harry Potter World 12%
- I went to the Academy Cataract Spotlight Session 51%
- What happens in Orlando, stays in Orlando. . . . 12%

FINANCIAL DISCLOSURES

Financial interests are designated by C, E, L, O, P or S:

C = CONSULTANT/ADVISOR
E = EMPLOYEE
L = LECTURE FEES
O = EQUITY OWNER
P = PATENTS/ROYALTY
S = GRANT SUPPORT

DR. AGARWAL AMO: C; Bausch + Lomb Surgical: C; Dr. Agarwal's Pharma: O; Slack: P; Staar Surgical: C; Thieme Medical Publishers: P. **DR. AHMED** AMO: L; Alcon: C,L,S; Allergan: C,L,S; AqueSys: C,S; Carl Zeiss Meditec: C,L,S; Clarity: C,S; Endo Optiks: C; Glaukos: C,S; iScience: C,S; Ivantis: C,L,S; Merck: C,L,S; New World Medical: L; Pfizer: C,L,S; Alcon: C,L. **DR. BRAGA-MELE** AMO: C,L; Alcon: C,L. **DR. CHANG** AMO: C; Alcon: C; Allergan: L; Bausch + Lomb: L; Calhoun Vision: O; Carl Zeiss Meditec: L; Clarity: C,O; Eyemaginations: P; Glaukos: S; Hoya: C; Icon Bioscience: O; Ista: C; LensAR: C,O; Revital Vision: O; Slack: P; Transcend Medical: C,O. **DR. CIONNI** Alcon: C,L; Morcher: P. **DR. CONDON** Alcon: C,L; Allergan: C,L; iScience: C; NeoMedix: C. **DR. CRANDALL** Alcon: C,L; Allergan: L; AqueSys: C; ASICO: C; eSinomed: C; *Glaucoma Today*: C; Glaukos: C; iScience: C; *Journal of Cataract & Refractive Surgery*: C; Mastel Surgical: C; *Ocular Surgery News*: L; Omeros Corporation: C; Transcend Medical: C; Vimetrics: C. **DR. DAVIS** AMO: C; Allergan: S; Bausch + Lomb Surgical: C; Ista: C; Merck: C; Refractec: O. **DR. DEVGAN** AMO: C,L,O,S; Accutome: L,P; Alcon: L,O; Allergan: O; Bausch + Lomb Surgical: C,L,S; Carl Zeiss Meditec: L; Haag-Streit: L; Hoya Surgical Optics: C,L; Ista: C,L,O; Renaissance Surgical: O; Slack: L; Specialty Surgical: O; Staar Surgical: O; Storz Instruments: C. **DR. DEWEY** AMO: C; MicroSurgical Technology: P. **DR. DONNENFELD** AMO: C,L,S; AcuFocus: C; Advanced Vision Research: C,L,S; Alcon: C,L,S; Allergan: C,L,S; AqueSys: C; Bausch + Lomb Surgical: C,L,S; CRST: C; Glaukos: C; Inspire: C,P; LenSx: C; Odyssey: C; Pfizer: C; QLT: C; TLC Laser Eye Centers: L,O; TrueVision: C,O; WaveTec: C. **DR. FISHKIND** AMO: C; LensAR: C; Thieme Medical Publishers: P. **DR. GIMBEL** None. **DR. HENDERSON** Alcon: C; Ista: C; Massachusetts Eye and Ear Infirmary: P. **DR. HILL** Alcon: C,L; Bausch + Lomb Surgical: C; Carl Zeiss Meditec: C,L; Elenza: C; Haag-Streit: C; LensAR: C; Oculus: C; Santen: C. **DR. HOFFMAN** None. **DR. KIM** Alcon: C,L; Allergan: C,L; Inspire: C,L; IOP: C,L; Ista: C,L; Ocular Systems: C; Ocular Therapeutix: C,O; PowerVision: C,O. **DR. LANE** AMO: C; Alcon: C,L; Bausch + Lomb Surgical: C,L; Eyemaginations: C; Inspire: C; Ista: C; OptiMedica: C,O; Patient Education Concepts: C; SMI: C; Tear Science: C; Visiogen: C; VisionCare: C,L; WaveTec: C. **DR. LIM** Genentech: L,S; Icon Bioscience: S; Quark: C; Regeneron: C,S. **DR. LINDSTROM** 3D Vision Systems: C,O; AMO: C; Acu-

Focus: C,O; Advanced Refractive Technologies: C,O; Alcon: C; Bausch + Lomb Surgical: C,P; BioSyntrix: C,O; Bradley Scott: C,O; Calhoun Vision: C,O; Clarity: C,O; Clear Sight: C,O; CoDa Therapeutics: C,O; Confluence Acquisition Partners: O; EBV Partners: C,O; EGG Basket Ventures: C,O; Encore: C,O; Evision: C,O; Eyemaginations: C,O; Foresight Venture Fund: C,O; FzioMed: C,O; Glaukos: C,O; Healthcare Transaction Services: O; Heaven Fund: O; High Performance Optics: C,O; Hoya Surgical Optics: C; Improve Your Vision: C,O; LensAR: C,O; LenSx: C; Life Guard Health: C,O; Lumineyes: C; Minnesota Eye Consultants: C,O; NuLens: C,O; Ocular Optics: C,O; *Ocular Surgery News*: C; Ocular Therapeutix: C; Omega Eye Health: C,O; Omeros: C; Pixel Optics: C,O; Qwest: C,O,P; Refractec: C,O; Revision Optics: O; RXVP: C,O; Schroder Life Science Venture Fund: C,O; Sight Path: C,O; Surgijet/Visijet: C,O; TearLabs: C,O; TLC Laser Center: C,O; Tracey Technologies: C,O; Transcend: C,O; TrueVision: C,O. **DR. MAMMALIS** AMO: S; Alcon: S; Allergan: S; Anew Optics: C; Bausch + Lomb Surgical: S; Calhoun Vision: S; MBI: S; Medennium: C; OptiMedica: C; PowerVision: S. **DR. MASKET** Alcon: C,L,S; Bausch + Lomb Surgical: L; Haag-Streit: S; Ocular Therapeutix: C,L,O,S; PowerVision: C; Zeiss: S. **DR. MILLER** Alcon: C,L; Hoya Surgical Optics: C. **DR. NICHAMIN** 3D Vision Systems: C,O; AMO: C; Allergan: C; Bausch + Lomb Surgical: C; Eyeonics: C,O; Glaukos: C; Harvest Precision Components: O; iScience: C,O; LensAR: C,O; PowerVision: C,O; RevitalVision: C,O; SensoMotoric Instruments: C; WaveTec Vision System: C,O. **DR. OLSEN** Dobbs Foundation: S; Emtech Biotechnology Development Grant: S; Georgia Research Alliance: S; NIH/NEI: S; NIH/NIA: S; Research to Prevent Blindness: S. **DR. OLSON** AMO: C,S; Allergan: C,S; Beaver-Visitec: C. **DR. OSHER** AMO: C; Alcon: C; Bausch + Lomb Surgical: C; BD Medical-Ophthalmic Systems: C; Carl Zeiss Meditec: C; Clarity: C; Haag-Streit: C; SMI: C; TrueVision: C; *Video Journal of Cataract & Refractive Surgery*: O. **DR. PACKARD** AMO: C; Alcon: C; Bausch + Lomb: C. **DR. PACKER** AMO: C; Advanced Vision Science: C; Bausch + Lomb Surgical: C; Carl Zeiss: C; Celgene: C; Corinthian Trading: O; General Electric: L; Haag-Streit: L; Ista: C; LensAR: C,O; Rayner Intraocular Lenses: C; Surgiview: O; Transcend Medical: C,O; TrueVision Systems: C,O; WaveTec Vision Systems: C,O. **DR. ROSENTHAL** AMO: C,L,S; Alcon: C,L; Bausch + Lomb Surgical: C; Inspire: C; Ista: C; Johnson & Johnson Consumer & Personal Products: C; MicroSurgical Technologies: C; Ophtec: C,L,S. **DR. SEIBEL** Bausch + Lomb: P; Calhoun Vision: O; OptiMedica: L,O; Rhein Medical: P; Slack: P. **DR. SOLOMON** AMO: C,L,S; Advanced Vision Research: C,L,S; Alcon: C,L,S; Allergan: C,L,S; Bausch + Lomb Surgical: C,L; Glaukos: C,O; Inspire: L; QLT: C,O,S. **DR. STARK** VueCare Media: O. **DR. STEINERT** AMO: C,S; LenSx: C; OptiMedica: C; Revision Optics: C; Rhein Medical: P. **DR. VASAVADA** Alcon: L. **DR. WALLACE** AMO: L; Allergan: C; Bausch + Lomb Surgical: C; LensAR: C. **DR. YOO** Alcon: C,L; Allergan: S; Bausch + Lomb Surgical: C; Carl Zeiss Meditec: S; Genentech: S; Transcend: C.

AAO Meetings
onDemand



ORDER NOW

Attend Academy Cataract Spotlights AT HOME

With AAO Meetings on Demand, you can view session slides and synchronized audio exactly as they were presented in the room. The three convenient formats – USB flash drive, online access and downloadable MP3 files – allow you to watch anytime, anywhere.

Get more than 150 hours of content with the 2011 AAO Annual Meeting on Demand, which includes these essential Spotlight sessions:

- Spotlight on Cataract Complications: M&M Rounds – Learning From My Mistakes
- Spotlight on Premium Cataract Surgery: The Business Behind the Medicine
- Spotlight on Femtosecond-Assisted Cataract Surgery

www.cmeoncall.com/ao

2011 AAO Subspecialty Day on Demand, containing all six programs, is also available.