



Diabetes




Diabetes is epidemic in the US, with more than 100M Americans being diabetic or pre-diabetic. Of the 30M+ with full-blown diabetes, it's estimated that 25% don't know they have it. Age is a risk factor for developing diabetes, with older individuals at greater risk. While people of all ethnic backgrounds are at risk, those with Native American, Inuit, African, and Hispanic backgrounds are especially at risk. Social factors play a role as well: diabetes prevalence is twice as high among individuals with less than a high-school education.

Worldwide, a third of diabetics have retinopathy—and in a third of these individuals, the retinopathy is severe enough to pose a significant threat to their sight. The risk of retinopathy increases with disease duration; after 20 years, 60% of Type II diabetics will have retinopathy, and virtually all Type I pts will. Unfortunately, only 60% of US diabetics receive appropriate screening eye exams at recommended intervals.



- There are three fundamental histological vascular derangements in DBR:
 - 1)
 - 2)
 - 3)



- There are three fundamental histological vascular derangements in DBR:
 - 1) Pericyte loss
 - 2) BM thickening → ↓ lumen diameter
 - 3) Loss of endothelial barrier function

BM = basement membrane

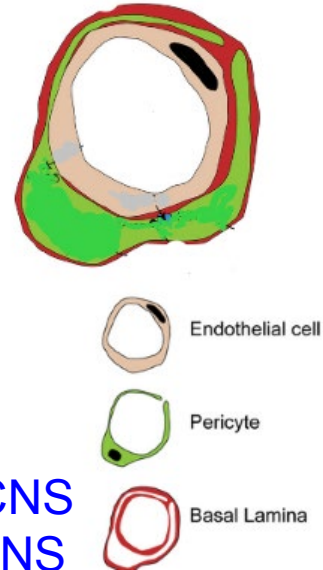
- There are three fundamental histological vascular derangements in DBR:

- 1) **Pericyte loss**

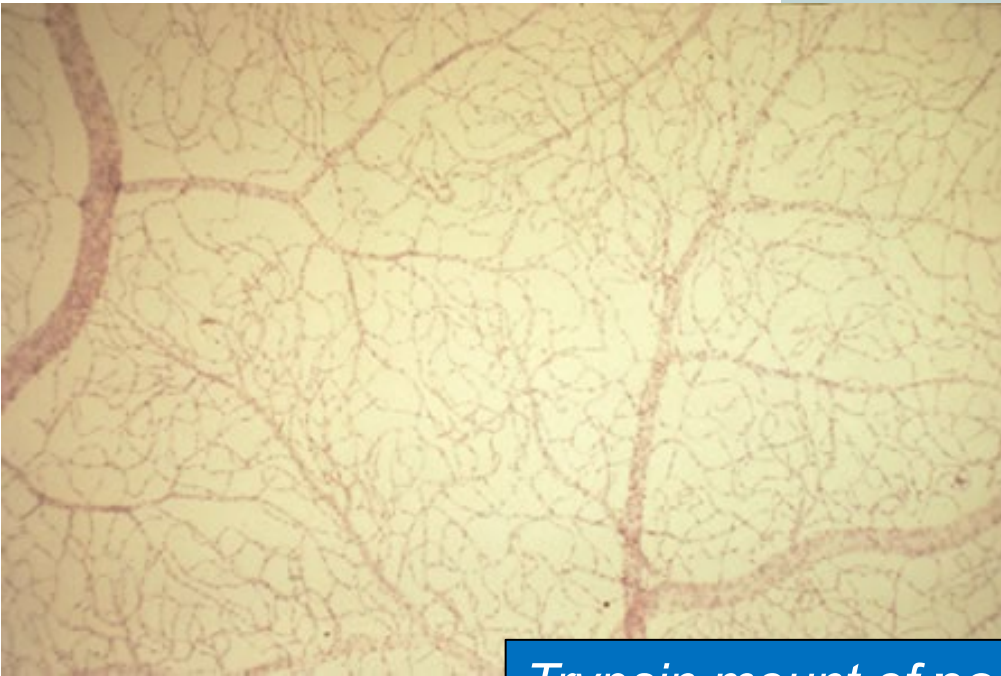

- 2) BM thickening → ↓ lumen diameter

- 3) Loss of endothelial barrier function

Pericytes are multifunctional cells that play a supportive role for the CNS vasculature, including that of the retina. (Remember, the retina is a CNS structure that happens to be located with the globes.) Pericytes are located on the external aspect of vessels (their appearance has been likened to ‘bumps on a log’), and are embedded in the BM of the endothelial cells. (Recall that endothelial cells face the *inner* aspect of vessels, and thus their basal surfaces—and thus BMs—are superficial to the endo cells themselves.)



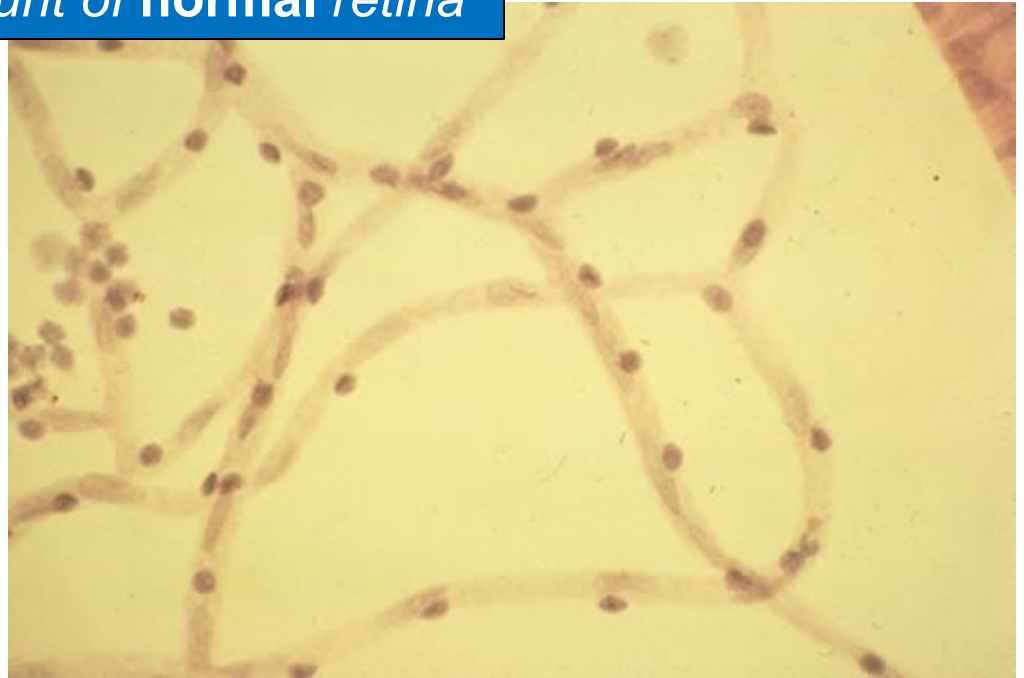In diabetic retinopathy, pericyte loss is the first vascular derangement to occur.

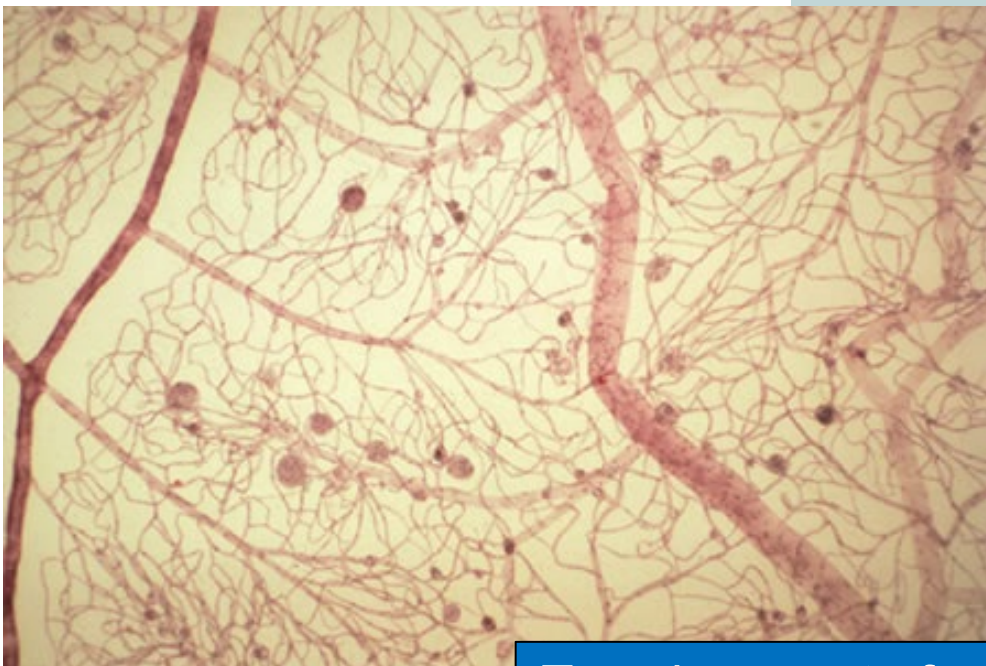


Trypsin mount of normal retina

The dark nuclei belong to pericytes;
the lighter, to endothelial cells.

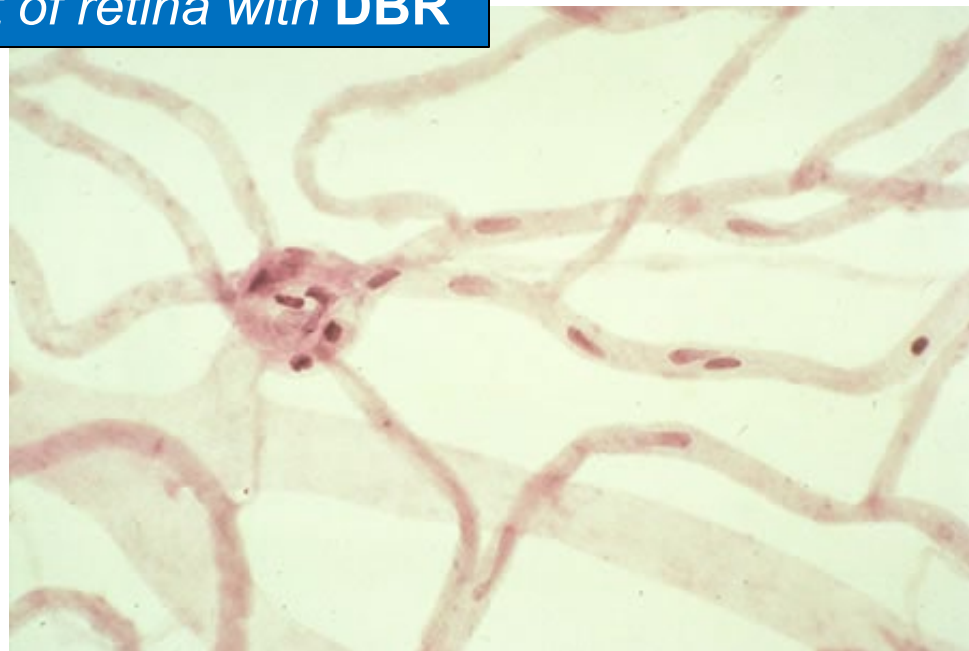
*Note that the ratio between them is
roughly 1:1.*

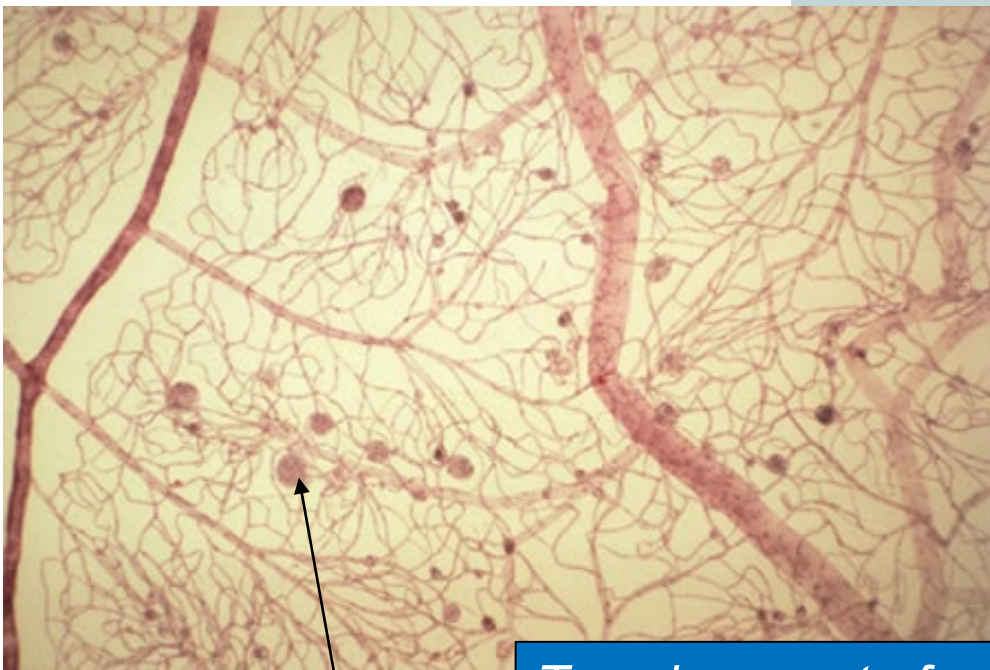





Trypsin mount of retina with DBR

In a retina with damage 2ndry to diabetes, the ratio of endothelial cells to pericytes is **many-to-one**.

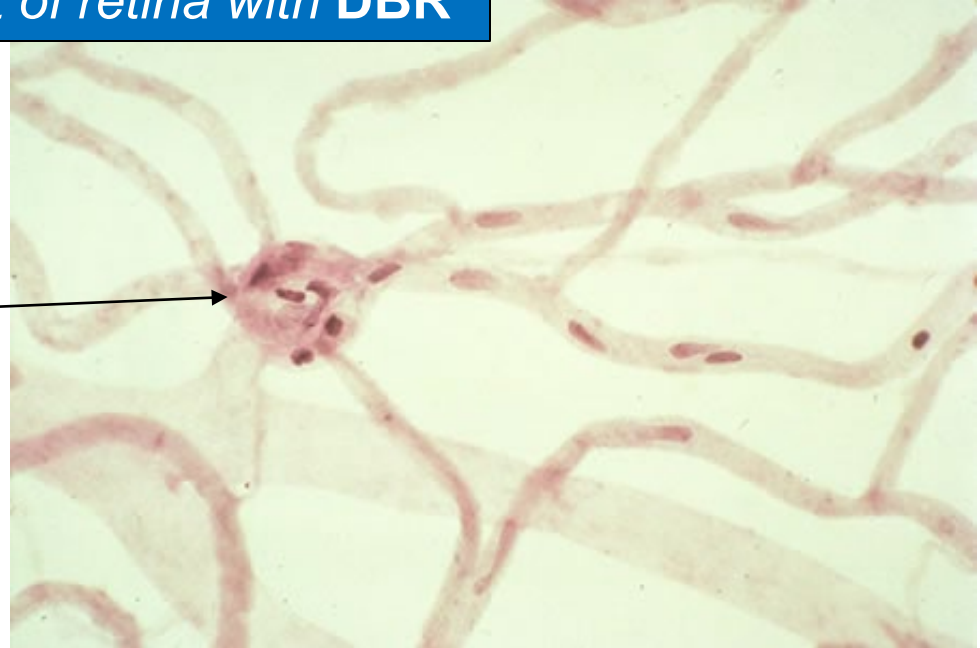


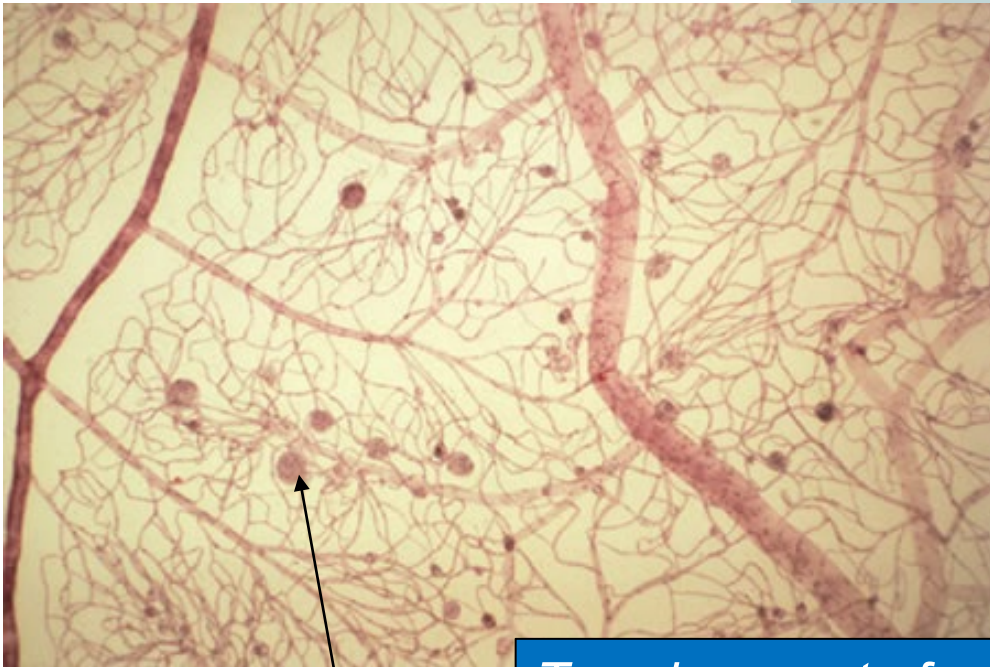



es

Trypsin mount of retina with DBR

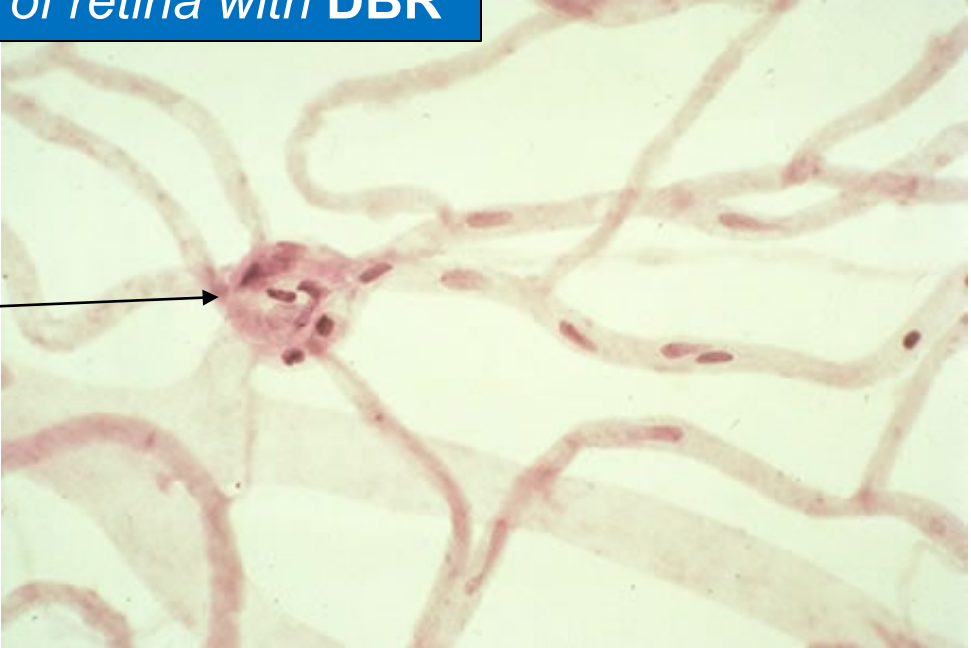What are these things?






Trypsin mount of retina with DBR

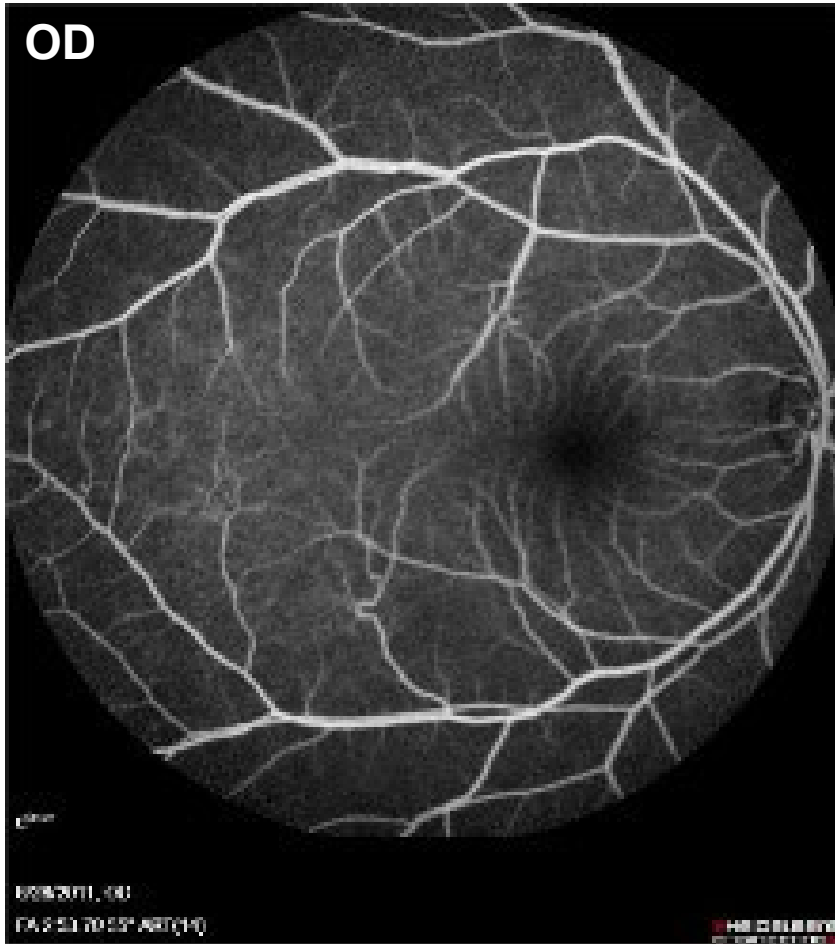

What are these things?
Microaneurysms, one of the classic manifestations of DBR



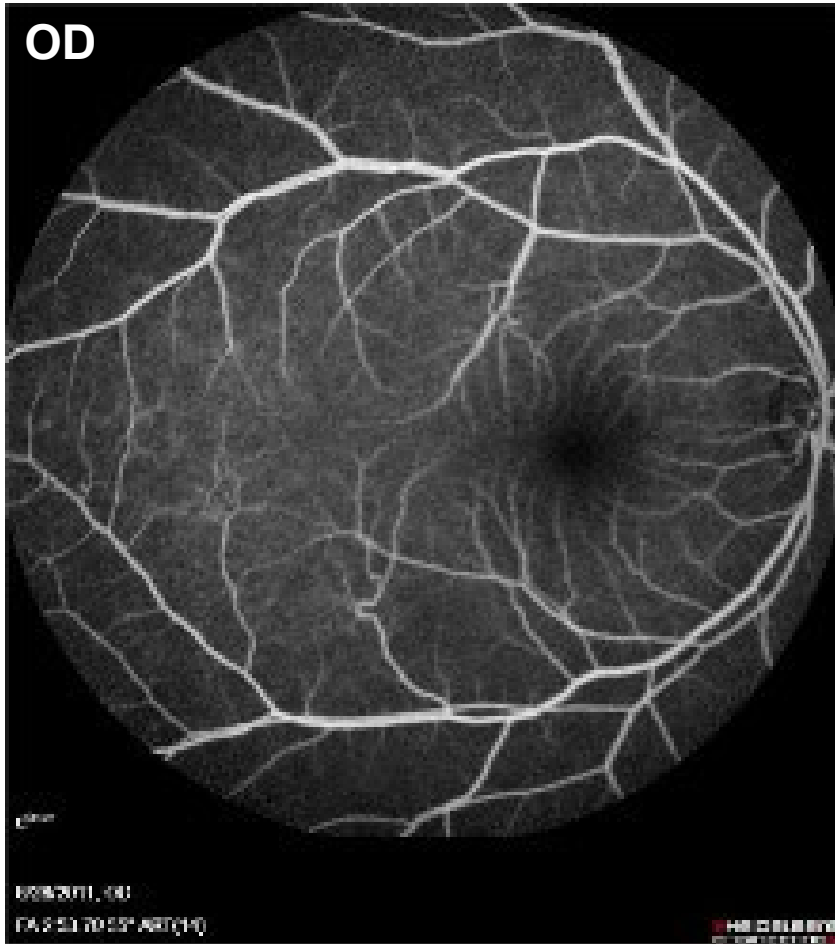



- What are the three histological vascular derangements in DBR?
 - 1) Pericyte loss
 - 2) BM thickening → ↓ lumen diameter**
 - 3) Loss of endothelial barrier function

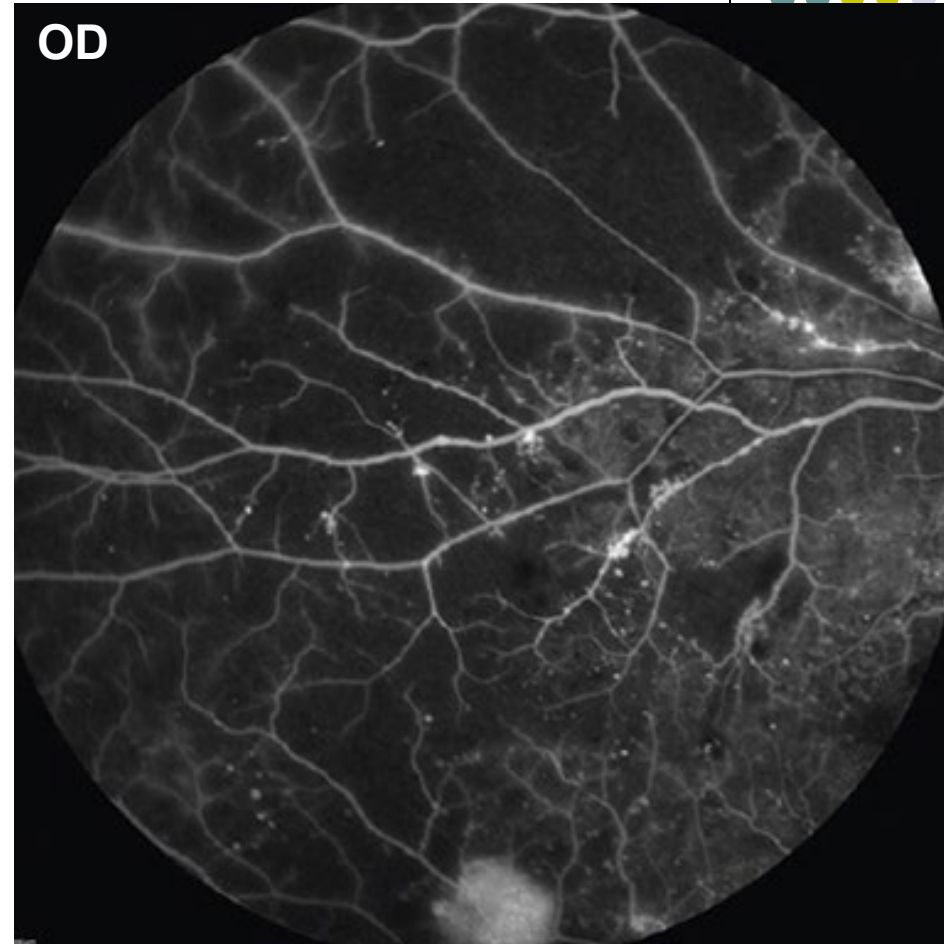
Decreases in lumen diameter leads to partial, and eventually complete, occlusion of the retinal vessel. At some point during this progressive occlusive process, blood flow through the vessel is compromised to the point that the retinal area serviced by the vessel becomes ischemic, and its cells hypoxic.




Fluorescein angiography (FA) of normal retina. Note the uniform background hyperfluorescence indicative of normal capillary fluorescein filling.



Fluorescein angiography (FA) of normal retina. Note the uniform background hyperfluorescence indicative of normal capillary fluorescein filling.




FA of diabetic retinopathy, including ischemic changes. Note the extensive areas of abnormal hypofluorescence owing to nonperfusion.



- What are the three histological vascular derangements in DBR?
 - 1) Pericyte loss
 - 2) BM thickening → ↓ lumen diameter**
 - 3) Loss of endothelial barrier function


Decreases in lumen diameter leads to partial, and eventually complete, occlusion of the retinal vessel. At some point during this progressive occlusive process, blood flow through the vessel is compromised to the point that the retinal area serviced by the vessel becomes ischemic, and its cells hypoxic.

These cells respond to the hypoxia with a cry for help—specifically, they request the development of new blood vessels to replace the occluded ones. They do this by releasing a signaling molecule called *vascular endothelial growth factor (VEGF)* that plays a central role in the pathogenesis of DBR.



VEGF-A₁₆₅


VEGF is an extracellular signaling protein involved in vascular development. Extracellular VEGF binds to VEGF receptors (VEGFR), which are transmembrane receptor tyrosine kinase (RTK) structures.



VEGF-A₁₆₅

VEGF is an extracellular signaling protein involved in vascular development. Extracellular VEGF binds to VEGF receptors (VEGFR), which are transmembrane receptor tyrosine kinase (RTK) structures.

VEGF is not a single entity—a number of similar-but-different proteins comprise the ‘VEGF family.’ These are differentiated as VEGF-A through VEGF-F. (One family member, placental growth factor [PlGF], is the exception to the naming rule.) When the term VEGF is used in the ophthalmology literature without a sub-family designation, it is understood to mean VEGF-A.




VEGF-A₁₆₅

VEGF is an extracellular signaling protein involved in vascular development. Extracellular VEGF binds to VEGF receptors (VEGFR), which are transmembrane receptor tyrosine kinase (RTK) structures.

VEGF is not a single entity—a number of similar-but-different proteins comprise the ‘VEGF family.’ These are differentiated as VEGF-A through VEGF-F. (One family member, placental growth factor [PlGF], is the exception to the naming rule.) When the term VEGF is used in the ophthalmology literature without a sub-family designation, it is understood to mean VEGF-A.

VEGF-A is not a single entity either. At least 4 isoforms exist; these differ in the number of peptides they contain, and that number is used as a subscript to identify specific isoforms. **Isoform 165** seems to be the most important with respect to pathologic angiogenesis in the human eye.



VEGF-A₁₆₅

In addition to diabetic retinopathy, VEGF plays a central role in the pathogenesis of a number of other prominent ophthalmic conditions, including (but not limited to):

- Wet ARMD
- Central retinal vein occlusion (CRVO)
- Ocular ischemic syndrome (OIS)
- Many others

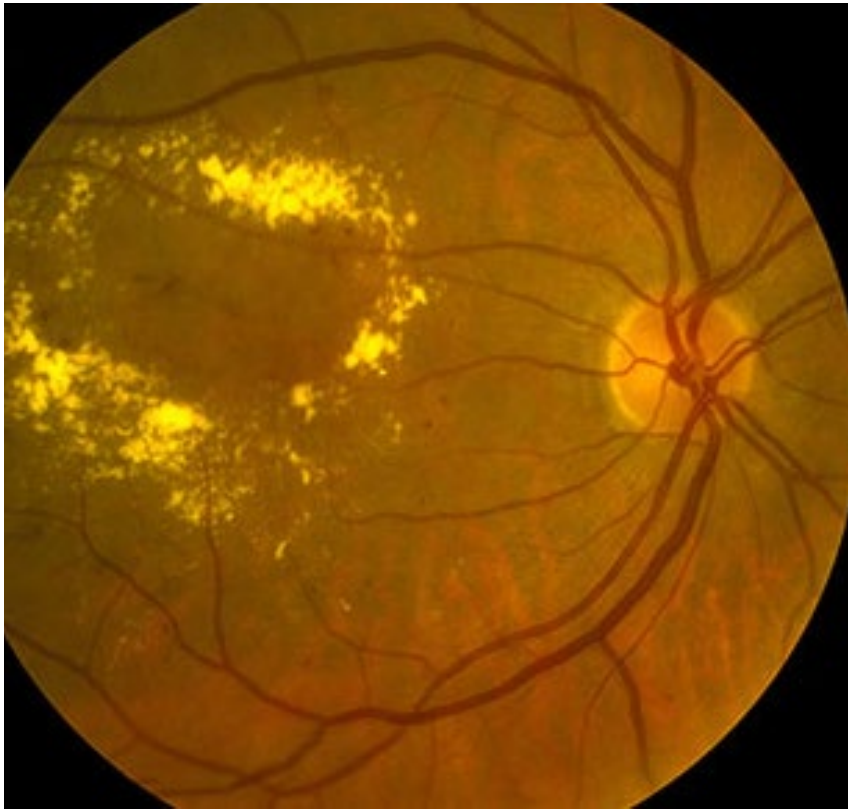
VEGF
Extra
recep
VEGF
'VEG
mem
term
is understood to mean VEGF-A.

VEGF-A is not a single entity either. At least 4 isoforms exist; these differ in the number of peptides they contain, and that number is used as a subscript to identify specific isoforms. **Isoform 165** seems to be the most important with respect to pathologic angiogenesis in the human eye.

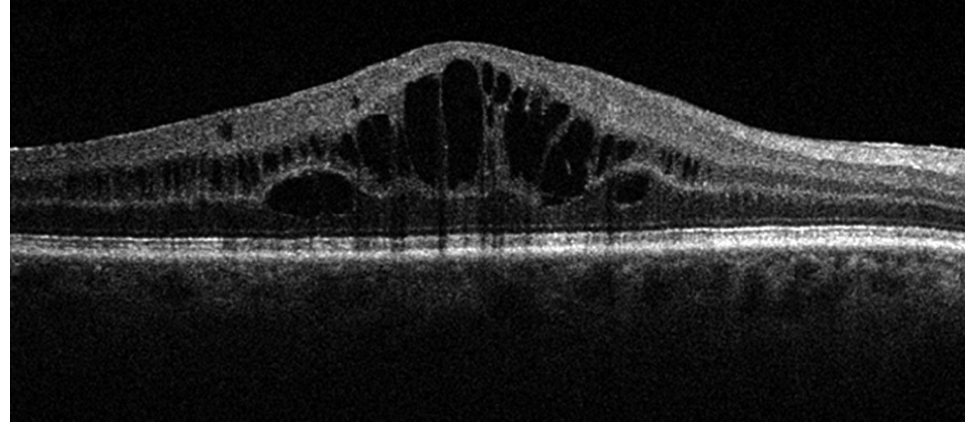


- There are three fundamental histological vascular derangements in DBR:
 - 1) Pericyte loss
 - 2) BM thickening → ↓ lumen diameter
 - 3) **Loss of endothelial barrier function**

As mentioned, the endothelial cells line the lumen of the vessel, surrounded by their BM. They are nonfenestrated, and attached to one another via tight junctions. The tight junctions between endothelial cells form the so-called *inner blood-retina barrier*. Loss of endothelial barrier function leads to the leaching of serum into the retinal space, resulting in the retinal edema that is so commonly associated with DBR.



Diabetic macular edema (DME)



DME on OCT



- *Classification of diabetic retinopathy*

- **Nonproliferative diabetic retinopathy (NPDR)**

There are two broad categories of DBR: *NPDR* and *PDR*

- **Proliferative diabetic retinopathy (PDR)**



- *Classification of diabetic retinopathy*
 - **Nonproliferative diabetic retinopathy (NPDR)**

There are two broad categories of DBR: *NPDR* and *PDR*

- **Proliferative diabetic retinopathy (PDR)**

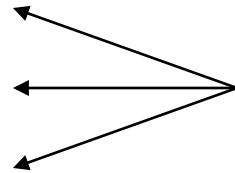
In this context, ***proliferative*** refers to the development of new retinal blood vessels (ie, retinal neovascularization) that break through the internal limiting membrane (ILM)



- *Classification of diabetic retinopathy*

- **Nonproliferative diabetic retinopathy (NPDR)**

- *Mild*
- *Moderate*
- *Severe*



There are three basic levels of NPDR:
Mild, moderate and severe

- Proliferative diabetic retinopathy (PDR)



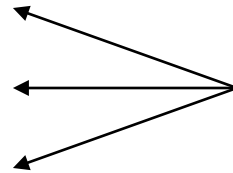
- *Classification of diabetic retinopathy*

- **Nonproliferative diabetic retinopathy (NPDR)**

- *Mild*


- *Moderate*

- *Severe*



There are three basic levels of NPDR:
Mild, moderate and severe

- *Very severe*



One more level—*very severe*—is not
employed routinely by all ophthalmologists

- **Proliferative diabetic retinopathy (PDR)**



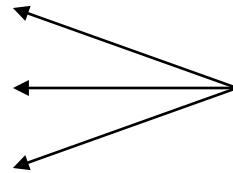
- *Classification of diabetic retinopathy*

- **Nonproliferative diabetic retinopathy (NPDR)**

- *Mild*


- *Moderate*

- *Severe*



There are three basic levels of NPDR:
Mild, moderate and severe

- *Very severe*



One more level—*very severe*—is not employed routinely by all ophthalmologists

- **Proliferative diabetic retinopathy (PDR)**

- *High-risk PDR*



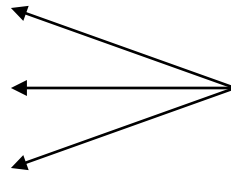
There is only one level of concern for PDR, that being so-called *high-risk PDR*



- *Classification of diabetic retinopathy*


- **Nonproliferative diabetic retinopathy (NPDR)**

- *Mild*
- *Moderate*
- *Severe*



There are three basic levels of NPDR:
Mild, moderate and severe

- *Very severe*



One more level—*very severe*—is not employed routinely by all ophthalmologists

- **Proliferative diabetic retinopathy (PDR)**

- *High-risk PDR*



There is only one level of concern for PDR, that being so-called *high-risk PDR*

(We'll unpack how all these terms are defined very shortly)



- *Classification of diabetic retinopathy*
 - **Nonproliferative diabetic retinopathy (NPDR)**
 - *Mild*
 - *Moderate*
 - *Severe*
 - *Very severe*
 - **Proliferative diabetic retinopathy (PDR)**
 - *High-risk PDR*

The landmark clinical trial that provided this system of DBR classification was the **Early Treatment of Diabetic Retinopathy Study**. Note: The ETDRS is one of the few ophthalmology clinical trials everyone is expected to be familiar with *by name*.



- *Classification of diabetic retinopathy*
 - **Nonproliferative diabetic retinopathy (NPDR)**
 - *Mild*
 - *Moderate*
 - *Severe*
 - *Very severe*
 - **Proliferative diabetic retinopathy (PDR)**
 - *High-risk PDR*

Your assessment (both in the chart and when presenting a pt to staff) of a pt with DBR will always commence with reference to this classification system; eg, *'Mr. Jones is a 58 y.o. diabetic/hypertensive with high-risk PDR OD and severe nonproliferative dz OS.'*



- *Classification of diabetic retinopathy*
 - **Nonproliferative diabetic retinopathy (NPDR)**
 - *Mild* *Mild and moderate NPDR are defined with respect to a set of standard photographs employed in the ETDRS.*
 - *Moderate*
 - *Severe*
 - *Very severe*
 - **Proliferative diabetic retinopathy (PDR)**
 - *High-risk PDR*



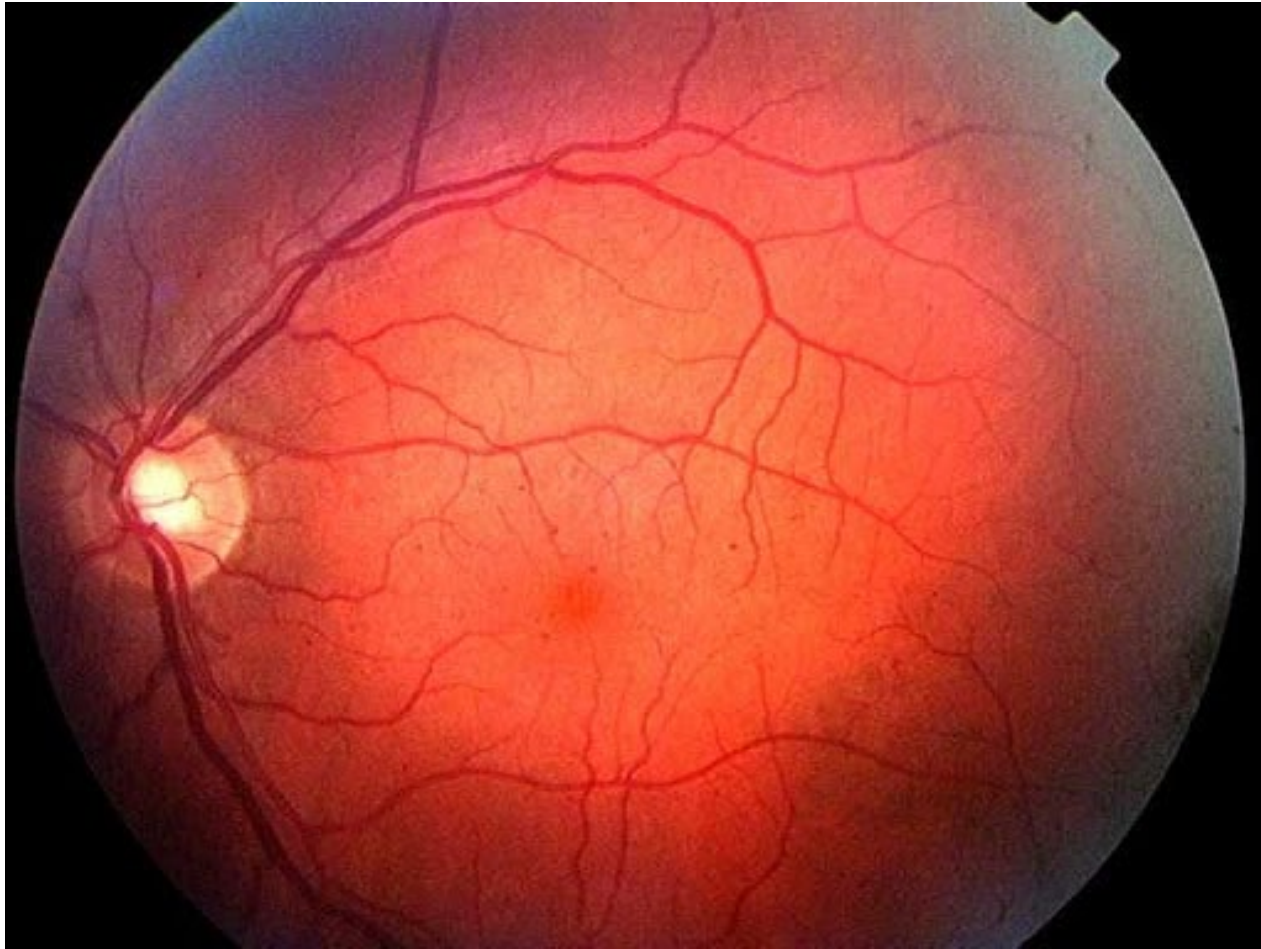
- *Classification of diabetic retinopathy*
 - **Nonproliferative diabetic retinopathy (NPDR)**
 - *Mild* *Mild and moderate NPDR are defined with respect to a set of standard photographs employed in the ETDRS.*
 - *Moderate* *In clinical practice you can think about it as follows:*
 - *Severe*
 - *Very severe*
 - **Proliferative diabetic retinopathy (PDR)**
 - *High-risk PDR*



- *Classification of diabetic retinopathy*
 - **Nonproliferative diabetic retinopathy (NPDR)**
 - ***Mild: Any DBR < moderate***
 - *Moderate*
 - *Severe*

 - *Very severe*
 - **Proliferative diabetic retinopathy (PDR)**
 - *High-risk PDR*

Diabetes

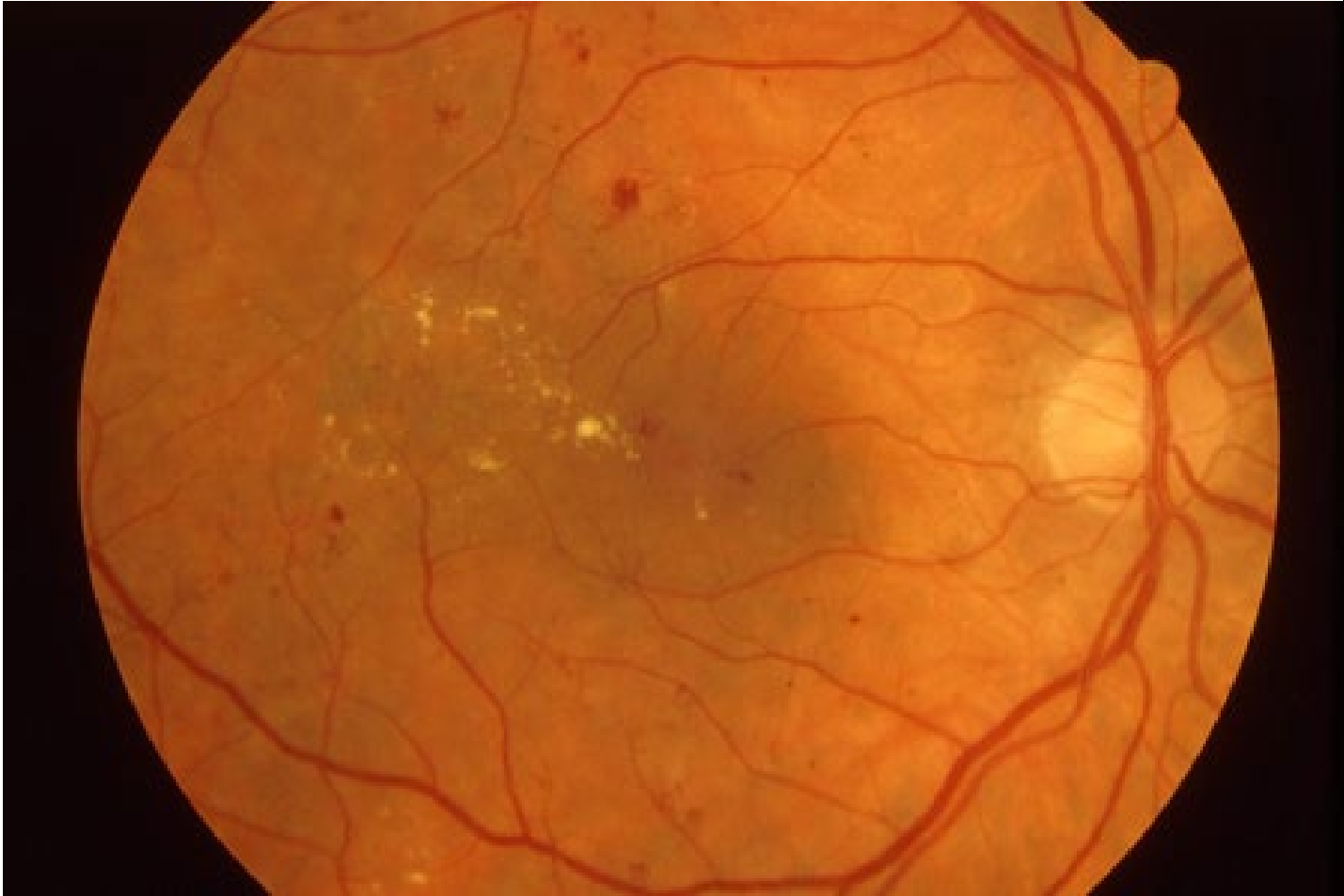


Mild NPDR—nothing more than a few MAs



- *Classification of diabetic retinopathy*
 - **Nonproliferative diabetic retinopathy (NPDR)**
 - *Mild: Any DBR < moderate*
 - *Moderate: DBR > mild but < severe*
 - *Severe*
 - *Very severe*
 - **Proliferative diabetic retinopathy (PDR)**
 - *High-risk PDR*

Diabetes



Moderate NPDR

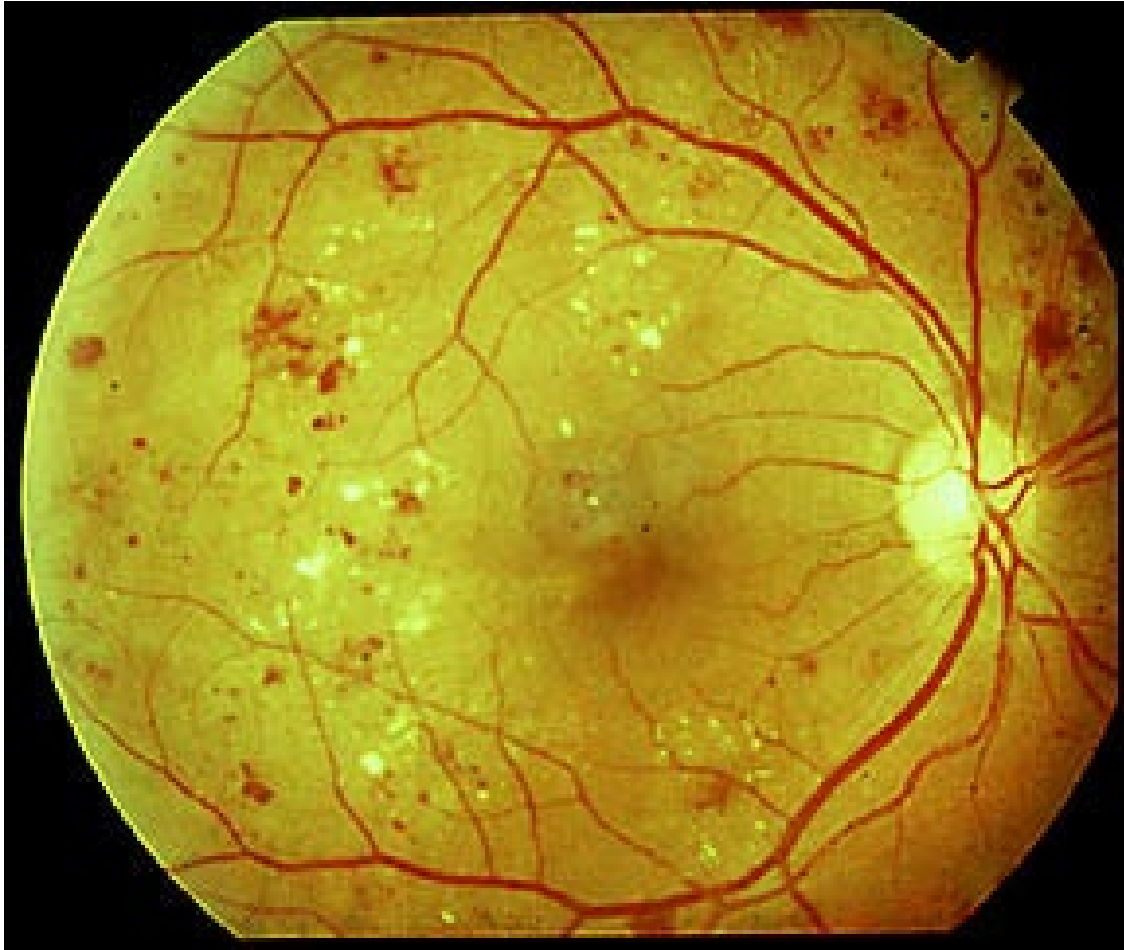

- *Classification of diabetic retinopathy*
 - **Nonproliferative diabetic retinopathy (NPDR)**
 - *Mild: Any DBR < moderate*
 - *Moderate: DBR > mild but < severe*
 - **Severe: Presence of any 1 of the 4:2:1 rule**
 - *Very severe*
 - **Proliferative diabetic retinopathy (PDR)**
 - *High-risk PDR*



- *Classification of diabetic retinopathy*
 - **Nonproliferative diabetic retinopathy (NPDR)**
 - *Mild: Any DBR < moderate*
 - *Moderate: DBR > mild but < severe*
 - **Severe: Presence of any 1 of the **4:2:1 rule****
chance of high-risk PDR within 1 year
 - *Very severe*
 - **What is the 4:2:1 rule?**
 - --4 retinal quadrants of...**extensive retinal hemorrhages**
 - --2 retinal quadrants of...
 - --1 retinal quadrant of...
 - **Proliferative diabetic retinopathy (PDR)**

Diabetes

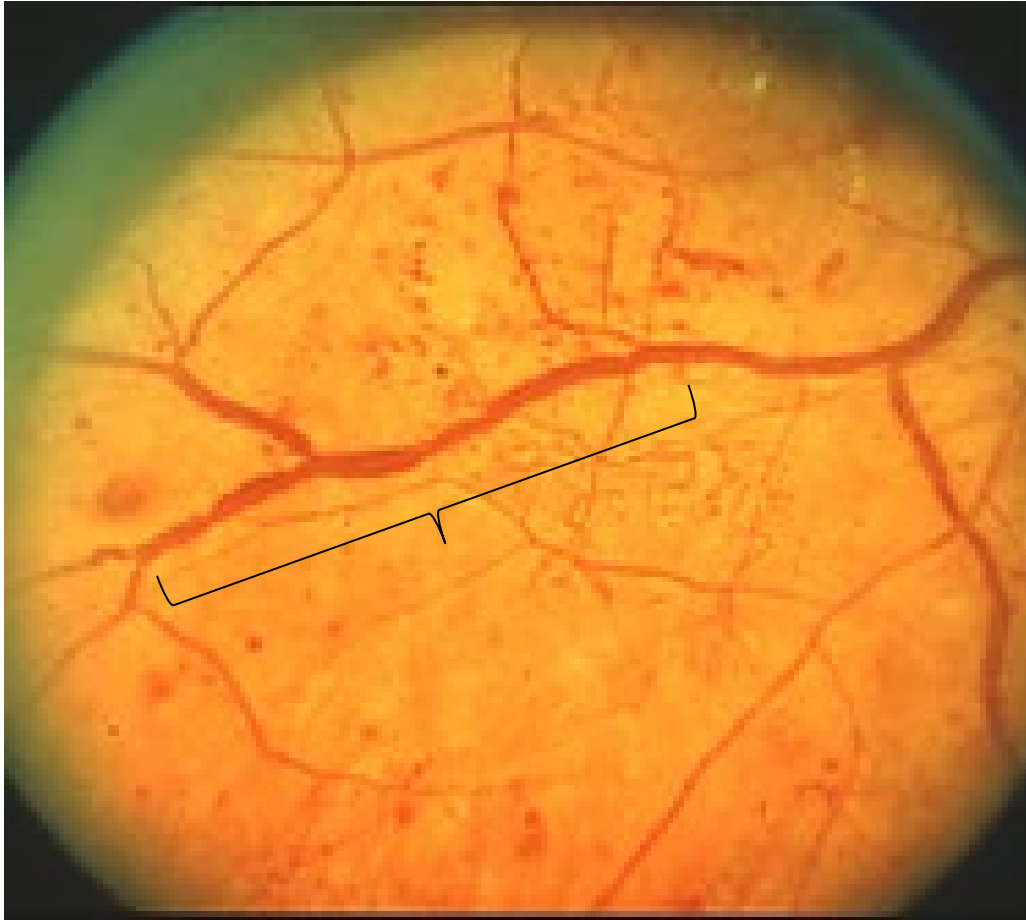


Severe NPDR: Extensive hemorrhages



- *Classification of diabetic retinopathy*
 - **Nonproliferative diabetic retinopathy (NPDR)**
 - *Mild: Any DBR < moderate*
 - *Moderate: DBR > mild but < severe*
 - **Severe: Presence of any 1 of the **4:2:1 rule****
chance of high-risk PDR within 1 year
 - *Very severe*
 - **What is the 4:2:1 rule?**
 - 4 retinal quadrants of...**extensive retinal hemorrhages**
 - 2 retinal quadrants of...**venous beading**
 - 1 retinal quadrant of...
 - **Proliferative diabetic retinopathy (PDR)**

Diabetes



Severe NPDR: Venous beading



- *Classification of diabetic retinopathy*
 - **Nonproliferative diabetic retinopathy (NPDR)**
 - *Mild: Any DBR < moderate*
 - *Moderate: DBR > mild but < severe*
 - **Severe: Presence of any 1 of the **4:2:1 rule****
chance of high-risk PDR within 1 year
 - *Very severe*
 - **What is the 4:2:1 rule?**
 - 4 retinal quadrants of...**extensive retinal hemorrhages**
 - 2 retinal quadrants of...**venous beading**
 - 1 retinal quadrant of...**IRMA**
 - **Proliferative diabetic retinopathy (PDR)**

Diabetes



- *Classification of diabetic retinopathy*
 - **Nonproliferative diabetic retinopathy (NPDR)**
 - *Mild: Any DBR < moderate*
 - *Moderate: DBR > mild but < severe*
 - **Severe: Presence of any 1 of the **4:2:1 rule****

chance of high-risk PDR within 1 year

What is the 4:2:1 rule?

IRMA stands for intraretinal microvascular anomalies. Think of it as neovascularization that has **not** broken through the ILM.

...extensive retinal hemorrhages
venous beading

IRMA

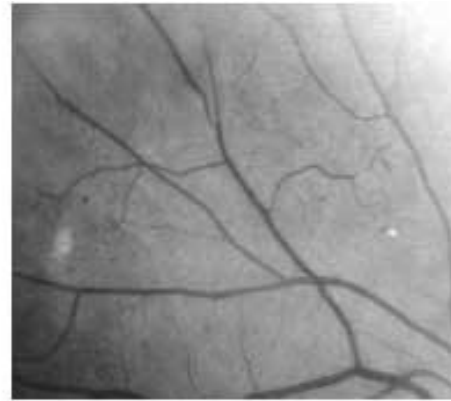
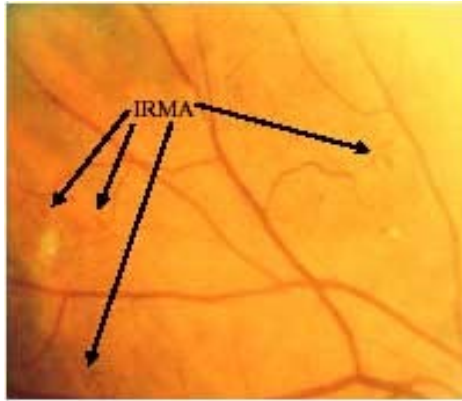
Pre-proliferative: Seve

- **Proliferative diabetic retinopathy (PDR)**

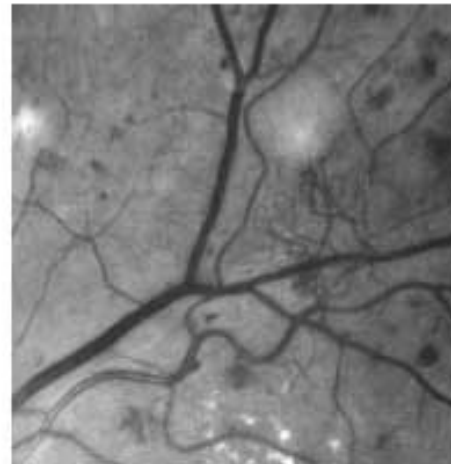
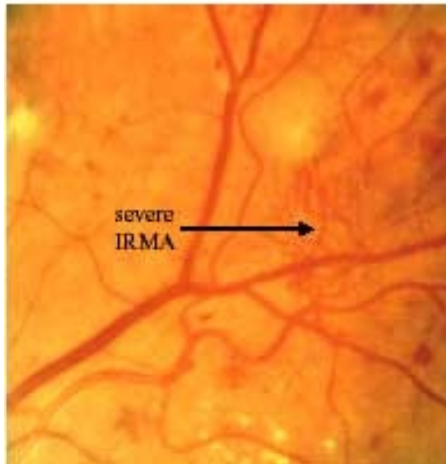
In this context, ^{IRMA}~~proliferation~~ is defined as retinal neovascularization that breaks _{through} the internal limiting membrane (ILM).

hasn't broken

Diabetes



4 patches of IRMA (Airlie House Slide 6a). Note that they are more visible in the right-hand red-free image



Severe NPDR: IRMA



- *Classification of diabetic retinopathy*
 - **Nonproliferative diabetic retinopathy (NPDR)**
 - *Mild: Any DBR < moderate*
 - *Moderate: DBR > mild but < severe*
 - *Severe: Presence of any 1 of the 4:2:1 rule*
 - *Very severe: Any 2 of the 4:2:1 rule*
 - **Proliferative diabetic retinopathy (PDR)**
 - *High-risk PDR*



- *Classification of diabetic retinopathy*
 - **Nonproliferative diabetic retinopathy (NPDR)**
 - *Mild: Any DBR < moderate*
 - *Moderate: DBR > mild but < severe*
 - **Severe: Presence of any 1 of the 4:2:1 rule**
 - Per the DRS*, **15%** of severe NPDR cases will progress to high-risk PDR in 1 year...
 - *Very severe: Any 2 of the 4:2:1 rule*
 - **Proliferative diabetic retinopathy (PDR)**
 - *High-risk PDR*

(*DRS = *Diabetic Retinopathy Study*, another landmark clinical trial. We'll address it in detail shortly)



- *Classification of diabetic retinopathy*
 - **Nonproliferative diabetic retinopathy (NPDR)**
 - *Mild: Any DBR < moderate*
 - *Moderate: DBR > mild but < severe*
 - *Severe: Presence of any 1 of the 4:2:1 rule*
 - Per the DRS, 15% of severe NPDR cases will progress to high-risk PDR in 1 year...
 - **Very severe: Any 2 of the 4:2:1 rule**
 - And 45% of **very** severe NPDR cases will progress to high-risk PDR in 1 year
 - **Proliferative diabetic retinopathy (PDR)**
 - *High-risk PDR*



- *Classification of diabetic retinopathy*

- **Nonproliferative diabetic retinopathy (NPDR)**

- *Mild: Any DBR < moderate*

NPDR is managed by controlling three systemic risk factors:

- --Blood glucose

- --Blood pressure

- --Lipid profile

In addition, there is good clinical-trial data demonstrating that two interventions can lessen the severity of NPDR:

- --Intravitreal anti-VEGF injections

- --Intravitreal steroids

However, what has yet to be determined is whether the cost/benefit ratio of these interventions is favorable enough to warrant their use.

(Trials addressing this issue are ongoing.)

- *Proliferative diabetic retinopathy (PDR)*

- *High-risk PDR*



- *Classification of diabetic retinopathy*

- Nonproliferative diabetic retinopathy (NPDR)

- *Mild: Any DBR < moderate*
- *Moderate: DBR > mild but < severe*
- *Severe: Presence of any 1 of the 4:2:1 rule*
15% chance of high-risk PDR within 1 year
- *Very severe: Any 2 of the 4:2:1 rule*
45% chance of high-risk PDR within 1 year

- **Proliferative diabetic retinopathy (PDR)**

- *High-risk PDR*

Recall that *proliferative retinopathy* is defined as neovascularization that has broken through the ILM.



- *Classification of diabetic retinopathy*
 - Nonproliferative diabetic retinopathy (NPDR)
 - *Mild: Any DBR < moderate*
 - *Moderate: DBR > mild but < severe*
 - *Severe: Presence of any 1 of the 4:2:1 rule*
 - 15% chance of high-risk PDR within 1 year
 - *Very severe: Any 2 of the 4:2:1 rule*
 - 45% chance of high-risk PDR within 1 year
 - **Proliferative diabetic retinopathy (PDR)**
 - *High-risk PDR*

Recall that *proliferative retinopathy* is defined as neovascularization that has broken through the ILM.

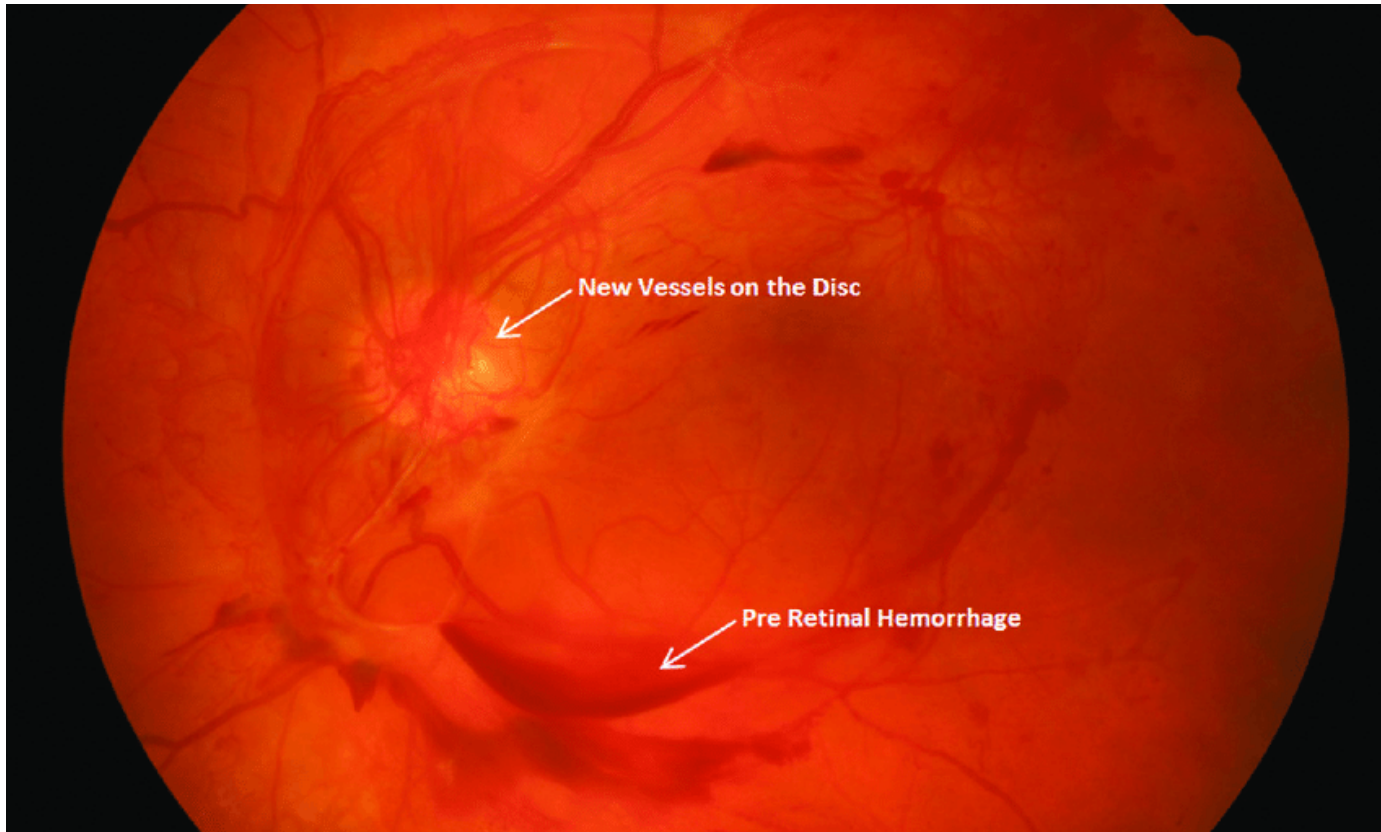
There are three findings that qualify neo as 'high-risk':



- *Classification of diabetic retinopathy*
 - **Nonproliferative diabetic retinopathy (NPDR)**
 - *Mild: Any DBR < moderate*
 - *Moderate: DBR > mild but < severe*
 - *Severe: Presence of any 1 of the 4:2:1 rule*
 - 15% chance of high-risk PDR within 1 year
 - *Very severe: Any 2 of the 4:2:1 rule*
 - 45% chance of high-risk PDR within 1 year
 - **Proliferative diabetic retinopathy (PDR)**
 - *High-risk PDR*
 - Any NVD associated with vitreous heme (VH)

NVD =
Neovascularization
of the disc

Diabetes



High-risk PDR: NVD + vitreous hemorrhage



- *Classification of diabetic retinopathy*

- Nonproliferative diabetic retinopathy (NPDR)

- *Mild: Any DBR < moderate*
- *Moderate: DBR > mild but < severe*
- *Severe: Presence of any 1 of the 4:2:1 rule*
15% chance of high-risk PDR within 1 year
- *Very severe: Any 2 of the 4:2:1 rule*
45% chance of high-risk PDR within 1 year

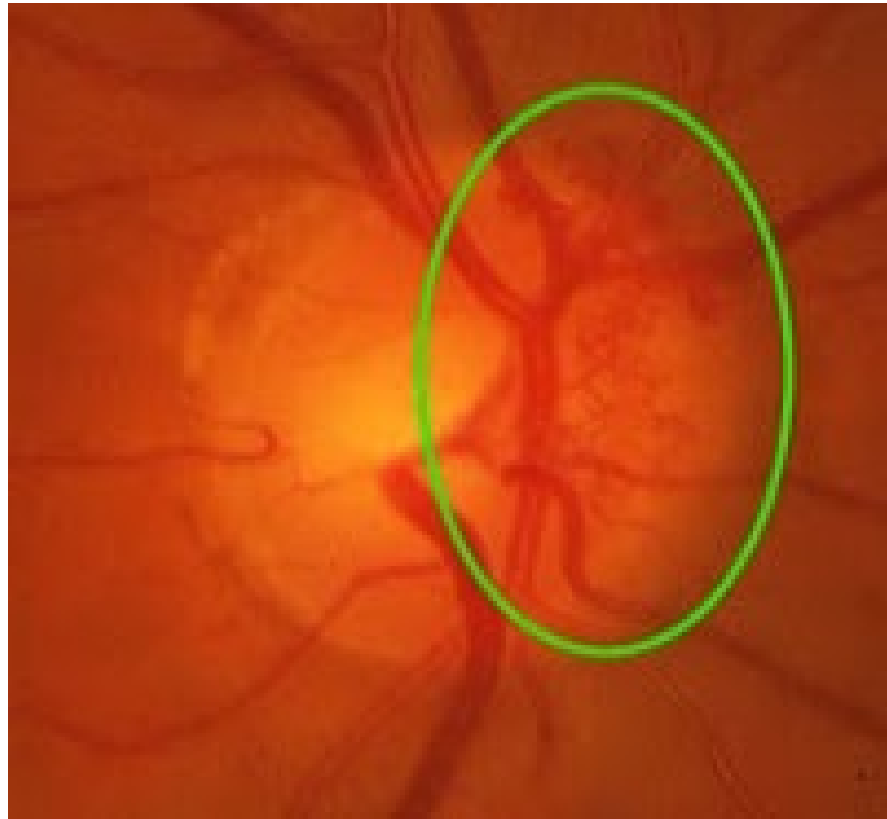
There are three exam findings that qualify as high-risk PDR:

- **Proliferative diabetic retinopathy (PDR)**

- *High-risk PDR*
 - Any NVD associated with vitreous heme (VH), **OR**
 - Large (at least $\frac{1}{4}$ DD) area of NVD with or without VH

DD = Disc diameter

Diabetes



High-risk PDR: Extensive NVD



- *Classification of diabetic retinopathy*

- Nonproliferative diabetic retinopathy (NPDR)

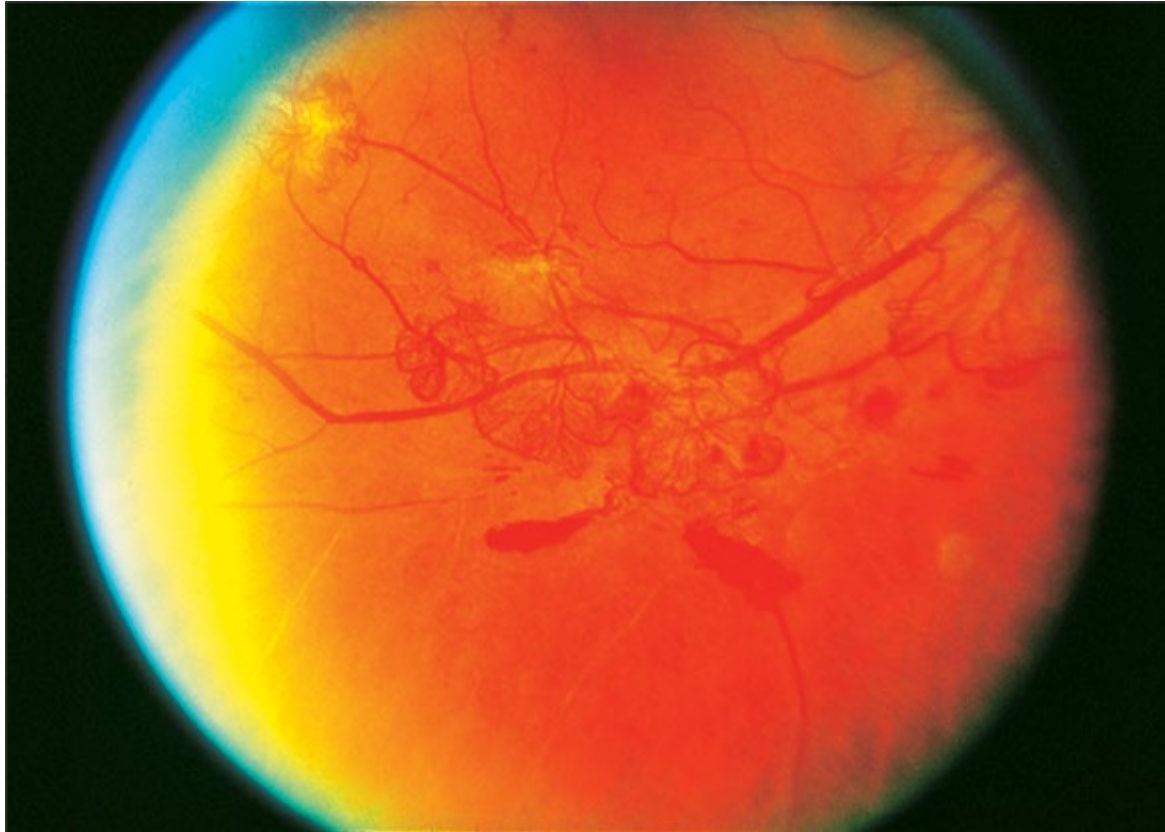
- *Mild: Any DBR < moderate*
- *Moderate: DBR > mild but < severe*
- *Severe: Presence of any 1 of the 4:2:1 rule*
15% chance of high-risk PDR within 1 year
- *Very severe: Any 2 of the 4:2:1 rule*
45% chance of high-risk PDR within 1 year

There are three exam findings that qualify as high-risk PDR:

- **Proliferative diabetic retinopathy (PDR)**

- *High-risk PDR*
 - Any NVD associated with vitreous heme (VH), **OR**
 - Large (at least $\frac{1}{4}$ DD) area of NVD with or without VH, **OR**
 - Large (at least $\frac{1}{2}$ DD) area of NVE with VH

Diabetes



High-risk PDR: Extensive NVE + VH



● *Classification of diabetic retinopathy*

● Nonproliferative diabetic retinopathy (NPDR)

- M The landmark clinical trial that provided this system of PDR classification was the **Diabetic Retinopathy Study (DRS)**—another study you need to know by name.

- S 15% chance of high-risk PDR within 1 year

- Very severe: **Any 2 of the 4:2:1 rule**
45% chance of high-risk PDR within 1 year

● **Proliferative diabetic retinopathy (PDR)**

- *High-risk PDR*

- Any NVD associated with vitreous heme (VH), **OR**
- Large (at least $\frac{1}{4}$ DD) area of NVD with or without VH, **OR**
- Large (at least $\frac{1}{2}$ DD) area of NVE with VH



● *Classification of diabetic retinopathy*

● Nonproliferative diabetic retinopathy (NPDR)

- M The landmark clinical trial that provided this system of PDR classification was the **Diabetic Retinopathy Study (DRS)**—another study you need to know by name. **The primary purpose of the DRS was to determine whether panretinal photocoagulation (PRP) is effective in treating PDR and severe NPDR. (We'll get to the answer shortly.)**

15% chance of high-risk PDR within 1 year

- S Very severe: **Any 2 of the 4:2:1 rule**

45% chance of high-risk PDR within 1 year

● **Proliferative diabetic retinopathy (PDR)**

● *High-risk PDR*

- Any NVD associated with vitreous heme (VH), **OR**
- Large (at least $\frac{1}{4}$ DD) area of NVD with or without VH, **OR**
- Large (at least $\frac{1}{2}$ DD) area of NVE with VH

Diabetes



- *Classification of diabetic retinopathy*
 - Nonproliferative diabetic retinopathy (NPDR)
 - *Mild: Any DBR < moderate*
 - *Moderate: DBR > mild but < severe*
 - *Severe: Presence of any 1 of the 4:2:1 rule*
15% chance of high-risk PDR within 1 year
 - *Very severe: Any 2 of the 4:2:1 rule*

- *Circling back for a minute... We said that PDR consists of retinal neovascularization. What sequence of events leads to retinal neovascularization? The answer can be found in a block of info from earlier in the slide-set:*

What is the histological definition of proliferation in this context?

Retinal neovascularization that breaks through the internal limiting membrane (ILM)

- Large (at least $\frac{1}{2}$ DD) area of NVE with VH



- *Classification of diabetic retinopathy*

- Nonproliferative diabetic retinopathy (NPDR)

Decreases in lumen diameter eventually results in occlusion of the retinal vessel. In turn, occlusion leads to ischemia of the retinal area serviced by the vessel. This renders those cells hypoxic. The cells react to being hypoxic by releasing a signaling molecule—VEGF—that plays a central role in the pathogenesis of DBR.

- Very severe: Any 2 of the 4:2:1 rule

Circling back for a minute... We said that PDR consists of retinal neovascularization. What sequence of events leads to retinal neovascularization?

The answer can be found in a block of info from earlier in the slide-set:

What is the histological definition of proliferation in this context?

Retinal neovascularization that breaks through the internal limiting membrane (ILM)

- Large (at least $\frac{1}{2}$ DD) area of NVE with VH



- *Classification of diabetic retinopathy*

- Nonproliferative diabetic retinopathy (NPDR)

Decreases in lumen diameter eventually results in occlusion of the retinal vessel.

To summarize: Occlusive vasculopathy secondary to diabetic derangements produces retinal ischemia.

Circling back for a minute... We said that PDR consists of retinal neovascularization. What sequence of events leads to retinal neovascularization?

The answer can be found in a block of info from earlier in the slide-set:

What is the histological definition of proliferation in this context?

Retinal neovascularization that breaks through the internal limiting membrane (ILM)

- Large (at least $\frac{1}{2}$ DD) area of NVE with VH



- *Classification of diabetic retinopathy*

- Nonproliferative diabetic retinopathy (NPDR)

Decreases in lumen diameter eventually results in occlusion of the retinal vessel.

To summarize: Occlusive vasculopathy secondary to diabetic derangements produces retinal ischemia. In a desperate attempt to recruit a blood supply, hypoxic retinal cells release **VEGF**, which diffuses throughout the vitreous cavity promoting neovascularization.

Circling back for a minute... We said that PDR consists of retinal neovascularization. What sequence of events leads to retinal neovascularization?

The answer can be found in a block of info from earlier in the slide-set:

What is the histological definition of proliferation in this context?

Retinal neovascularization that breaks through the internal limiting membrane (ILM)

- Large (at least $\frac{1}{2}$ DD) area of NVE with VH



- *Classification of diabetic retinopathy*

- Nonproliferative diabetic retinopathy (NPDR)

Decreases in lumen diameter eventually results in occlusion of the retinal vessel.

To summarize: Occlusive vasculopathy secondary to diabetic derangements produces retinal ischemia. In a desperate attempt to recruit a blood supply, hypoxic retinal cells release **VEGF**, which diffuses throughout the vitreous cavity promoting neovascularization. Unfortunately, the resulting new fibrovascular tissue is highly abnormal—it is prone to bleeding and contraction, leading to vitreous hemorrhages and/or tractional retinal detachment.

Circling back for a minute... We said that PDR consists of retinal neovascularization. What sequence of events leads to retinal neovascularization?

The answer can be found in a block of info from earlier in the slide-set:

What is the histological definition of proliferation in this context?

Retinal neovascularization that breaks through the internal limiting membrane (ILM)

- Large (at least ½ DD) area of NVE with VH



- *Classification of diabetic retinopathy*
 - Nonproliferative diabetic retinopathy (NPDR)
 - *Mild: Any DBR < moderate*

Time to expand upon what 'high risk PDR' pts are at risk of...

- **Proliferative diabetic retinopathy (PDR)**
 - ***High-risk PDR***
 - Any NVD associated with vitreous heme (VH), **OR**
 - Large (at least $\frac{1}{4}$ DD) area of NVD with or without VH, **OR**
 - Large (at least $\frac{1}{2}$ DD) area of NVE with VH



- *Classification of diabetic retinopathy*
 - Nonproliferative diabetic retinopathy (NPDR)
 - *Mild: Any DBR < moderate*

Time to expand upon what 'high risk PDR' pts are at risk of...

The term **high-risk PDR** derives from a finding in the DRS. Specifically, the DRS found that pts with neovascularization to the degree described below were found to be at high risk of suffering **severe vision loss (SVL)**, which was defined as VA \leq 5/200 (20/800).

- **Proliferative diabetic retinopathy (PDR)**
 - **High-risk PDR**
 - Any NVD associated with vitreous heme (VH), **OR**
 - Large (at least $\frac{1}{4}$ DD) area of NVD with or without VH, **OR**
 - Large (at least $\frac{1}{2}$ DD) area of NVE with VH

Diabetes



- *Classification of diabetic retinopathy*
 - Nonproliferative diabetic retinopathy (NPDR)
 - *Mild: Any DBR < moderate*

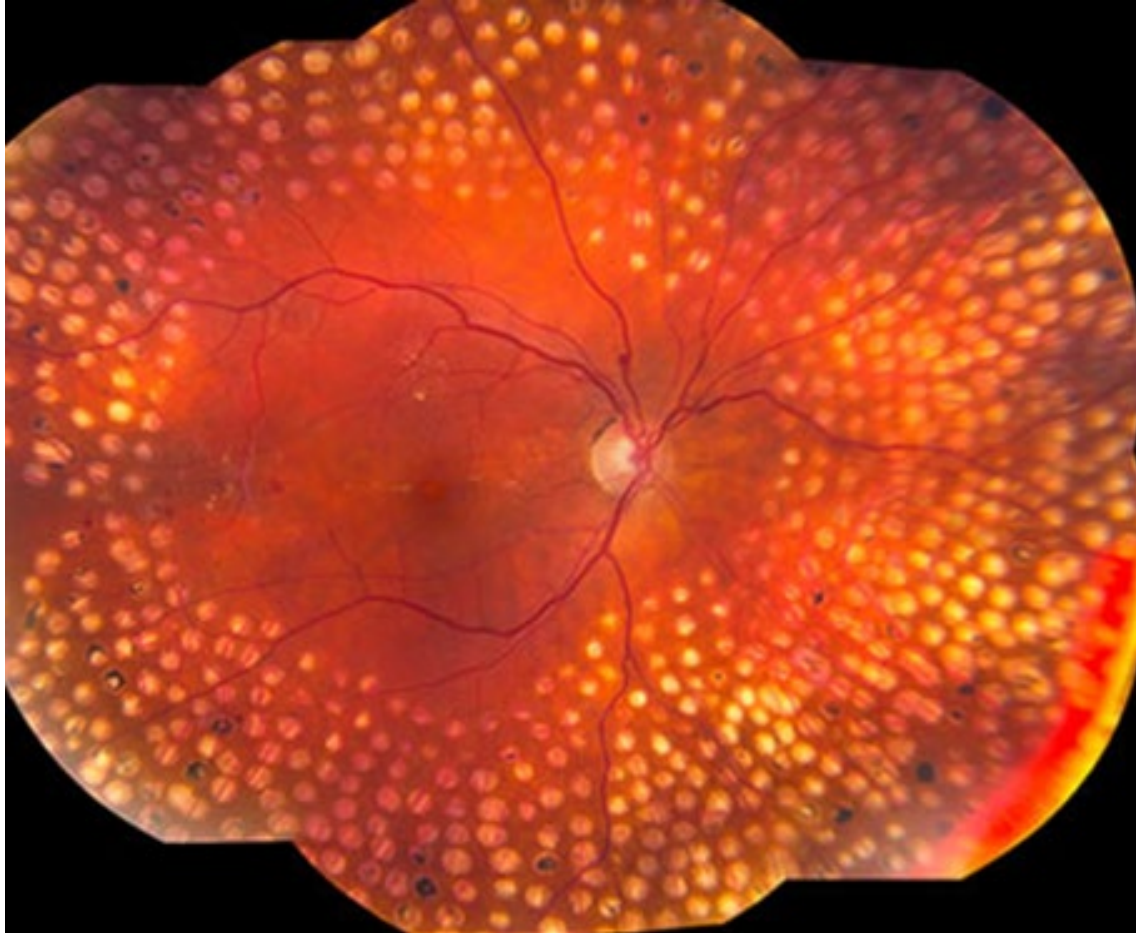
Time to expand upon what 'high risk PDR' pts are at risk of...

The term **high-risk PDR** derives from a finding in the DRS. Specifically, the DRS found that pts with neovascularization to the degree described below were found to be at high risk of suffering **severe vision loss (SVL)**, which was defined as VA \leq 5/200 (20/800).

The clinical implication of finding high-risk PDR in a patient is that it represents the formal justification for performing PRP. ***The DRS found that PRP reduces the risk of SVL by 50%.***

- **Proliferative diabetic retinopathy (PDR)**
 - ***High-risk PDR***
 - Any NVD associated with vitreous heme (VH), **OR**
 - Large (at least $\frac{1}{4}$ DD) area of NVD with or without VH, **OR**
 - Large (at least $\frac{1}{2}$ DD) area of NVE with VH

Diabetes



PRP

Diabetes



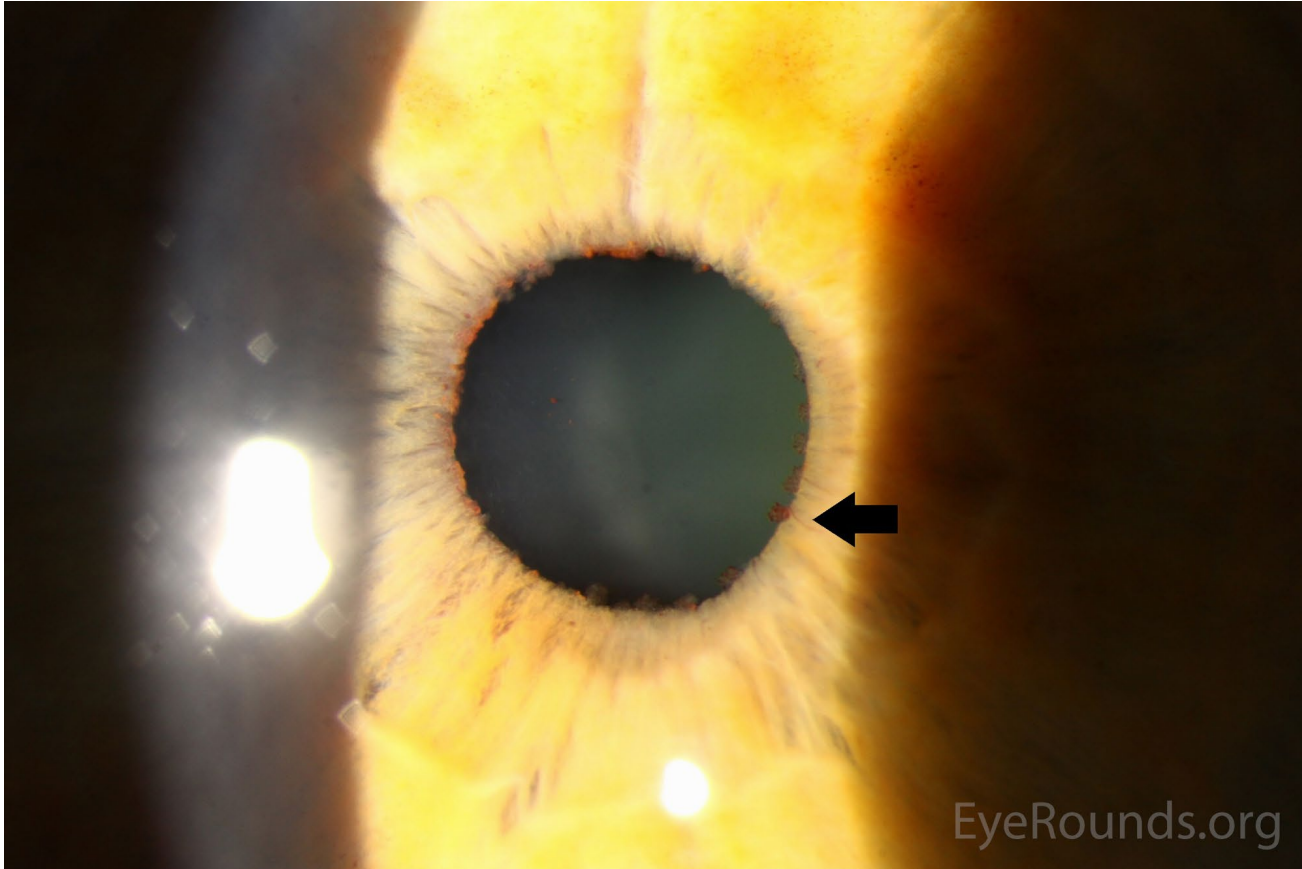

- *Classification of diabetic retinopathy*
 - Nonproliferative diabetic retinopathy (NPDR)
 - *Mild: Any DBR < moderate*

Another justification for PRP is the presence of extensive *neovascularization of the iris* (NVI). Small 'tufts' of NVI at the pupillary margin are a common occurrence in diabetics, and warrant close follow up (including frequent undilated gonioscopy to assess for the presence of *neovascularization of the angle*, NVA).

The clinical implication of finding high-risk PDR in a *NVI/NVA* represent the *informal* justification for performing PRP. *The DRS found that PRP reduces the risk of SVL by 50%.*

- Proliferative diabetic retinopathy (PDR)
 - *High-risk PDR*
 - *Any NVD associated with vitreous heme (VH), OR*
 - *Large (at least ¼ DD) area of NVD with or without VH, OR*
 - *Large (at least ½ DD) area of NVE with VH*

Diabetes



Pupillary vascular tufts

Diabetes



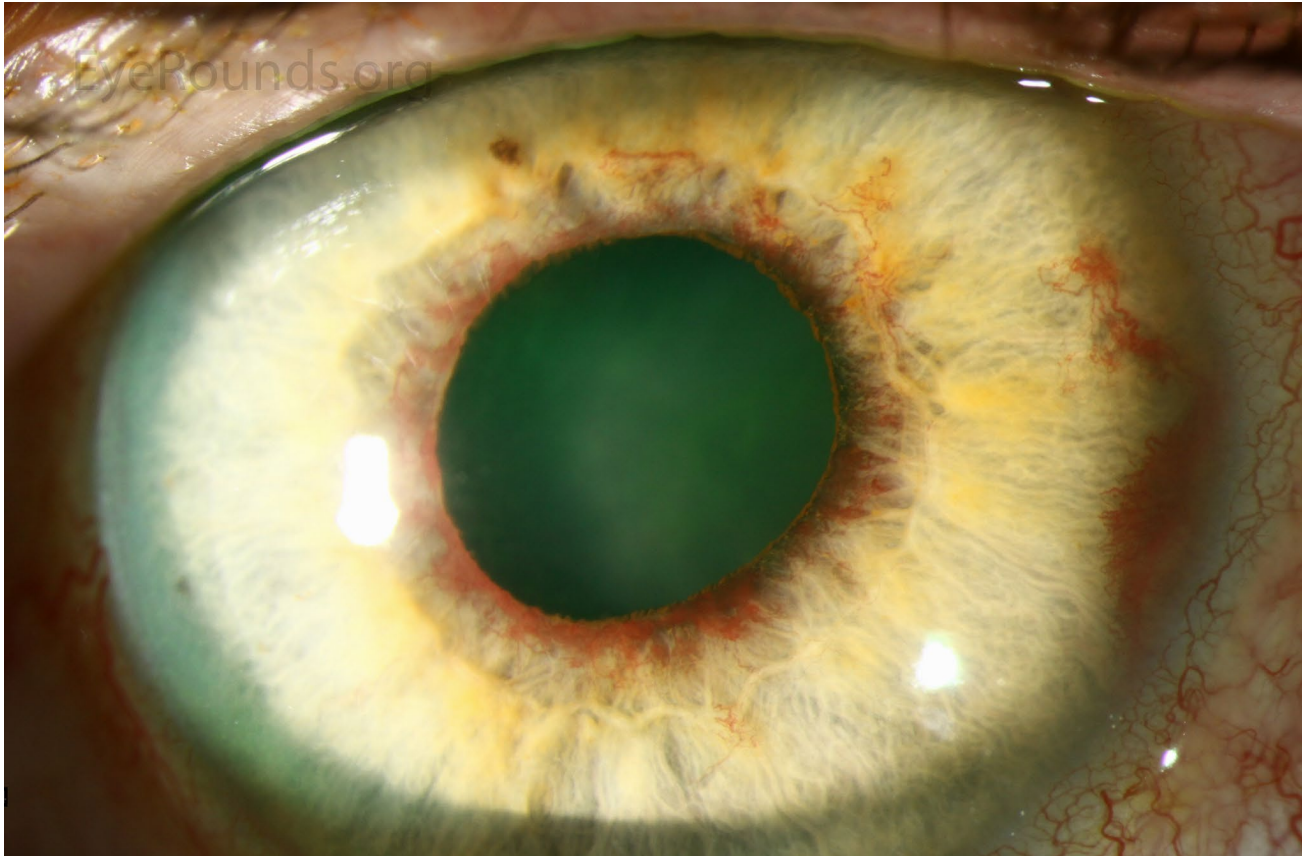
- *Classification of diabetic retinopathy*
 - Nonproliferative diabetic retinopathy (NPDR)
 - *Mild: Any DBR < moderate*

Another justification for PRP is the presence of extensive *neovascularization of the iris* (NVI). Small 'tufts' of NVI at the pupillary margin are a common occurrence in diabetics, and warrant close follow up (including frequent undilated gonioscopy to assess for the presence of *neovascularization of the angle*, NVA). However, extensive NVI, or NVA, may portend the development of *neovascular glaucoma* (NVG), and thus are an indication for PRP.

The clinical implication of finding high-risk PDR in a *NVI/NVA* represent the *informal* justification for performing PRP. *The DRS found that PRP reduces the risk of SVL by 50%.*

- Proliferative diabetic retinopathy (PDR)
 - *High-risk PDR*
 - *Any NVD associated with vitreous heme (VH), OR*
 - *Large (at least ¼ DD) area of NVD with or without VH, OR*
 - *Large (at least ½ DD) area of NVE with VH*

Diabetes



Yikes

Diabetes



- What is the purpose of PRP, ie, what are we trying to do to the retina? At first glance, the purpose will likely seem deeply counterintuitive, but it is this: *The goal is to kill most of the cells in the peripheral retina.*

Tim

The
pts
suff

The clinical implication of finding high-risk PDR in a patient is that it represents the formal justification for performing PRP.

The DRS found that PRP reduces the risk of SVL by 50%.

- Proliferative diabetic retinopathy (PDR)
 - *High-risk PDR*
 - Any NVD associated with vitreous heme (VH), *OR*
 - Large (at least $\frac{1}{4}$ DD) area of NVD with or without VH, *OR*
 - Large (at least $\frac{1}{2}$ DD) area of NVE with VH

Diabetes



- What is the purpose of PRP, ie, what are we trying to do to the retina? At first glance, the purpose will likely seem deeply counterintuitive, but it is this: *The goal is to kill most of the cells in the peripheral retina.*

How, you might ask, does killing the peripheral retina reduce the risk of SVL? The answer is actually pretty straightforward. As stated several times now: DBR renders portions of the retina hypoxic, the hypoxic cells release VEGF, and VEGF initiates a cascade of events that lead to neovascularization and, ultimately, to SVL.

The clinical implication of finding high-risk PDR in a patient is that it represents the formal justification for performing PRP. ***The DRS found that PRP reduces the risk of SVL by 50%.***

- Proliferative diabetic retinopathy (PDR)

- *High-risk PDR*

- Any NVD associated with vitreous heme (VH), *OR*
- Large (at least $\frac{1}{4}$ DD) area of NVD with or without VH, *OR*
- Large (at least $\frac{1}{2}$ DD) area of NVE with VH



- What is the purpose of PRP, ie, what are we trying to do to the retina? At first glance, the purpose will likely seem deeply counterintuitive, but it is this: *The goal is to kill most of the cells in the peripheral retina.*

How, you might ask, does killing the peripheral retina reduce the risk of SVL? The answer is actually pretty straightforward. As stated several times now: DBR renders portions of the retina hypoxic, the hypoxic cells release VEGF, and VEGF initiates a cascade of events that lead to neovascularization and, ultimately, to SVL. OTOH, **dead cells do not release VEGF**. So by euthanizing the hypoxic retina, intraocular VEGF production is reduced. This in turn halts the development and progression of neovascularization, thereby reducing the risk of SVL that neovascularization conveys.

The clinical implication of finding high-risk PDR in a patient is that it represents the formal justification for performing PRP. ***The DRS found that PRP reduces the risk of SVL by 50%.***

- Proliferative diabetic retinopathy (PDR)

- *High-risk PDR*

- Any NVD associated with vitreous heme (VH), *OR*
- Large (at least $\frac{1}{4}$ DD) area of NVD with or without VH, *OR*
- Large (at least $\frac{1}{2}$ DD) area of NVE with VH



- What is the purpose of PRP, ie, what are we trying to do to the retina? At first glance, the purpose will likely seem deeply counterintuitive, but it is this: *The goal is to kill most of the cells in the peripheral retina.*

How, you might ask, does killing the peripheral retina reduce the risk of SVL? The answer is actually pretty straightforward. As stated several times now: DBR renders portions of the retina hypoxic, the hypoxic cells release VEGF, and VEGF initiates a cascade of events that lead to neovascularization and, ultimately, to SVL. OTOH, **dead cells do not release VEGF**. So by euthanizing the hypoxic retina, intraocular VEGF production is reduced. This in turn halts the development and progression of neovascularization, thereby reducing the risk of SVL that neovascularization conveys.

The clinical implication of finding high-risk PDR in a patient is that it represents the formal justification for performing PRP.

The DRS found that PRP reduces the risk of SVL by 50%.

PRP has two other salutary effects on oxygen tension in the retina:

--By decreasing the number of living retinal cells competing for oxygen, the remaining ones receive a greater portion of the oxygen delivered to the retina

- Large (at least $\frac{1}{4}$ DD) area of NVD with or without VH, OR
- Large (at least $\frac{1}{2}$ DD) area of NVE with VH

Diabetes



- What is the purpose of PRP, ie, what are we trying to do to the retina? At first glance, the purpose will likely seem deeply counterintuitive, but it is this: *The goal is to kill most of the cells in the peripheral retina.*

How, you might ask, does killing the peripheral retina reduce the risk of SVL? The answer is actually pretty straightforward. As stated several times now: DBR renders portions of the retina hypoxic, the hypoxic cells release VEGF, and VEGF initiates a cascade of events that lead to neovascularization and, ultimately, to SVL. OTOH, **dead cells do not release VEGF**. So by euthanizing the hypoxic retina, intraocular VEGF production is reduced. This in turn halts the development and progression of neovascularization, thereby reducing the risk of SVL that neovascularization conveys.

The clinical implication of finding high-risk PDR in a patient is that it represents the formal justification for performing PRP. ***The DRS found that PRP reduces the risk of SVL by 50%.***

PRP has two other salutary effects on oxygen tension in the retina:

- By decreasing the number of living retinal cells competing for oxygen, the remaining ones receive a greater portion of the oxygen delivered to the retina; and
- The PRP scars facilitate the diffusion of oxygen from the choroidal circulation into the retinal space

- Large (at least $\frac{1}{4}$ DD) area of NVD with or without VH, OR
- Large (at least $\frac{1}{2}$ DD) area of NVE with VH

Diabetes



What is the purpose of PRP, ie, what are we trying to do to the retina? At first glance, the purpose will likely seem deeply counterintuitive, but it is this: *The goal is to kill most of the cells in the peripheral retina.*

An important aside: The **ETDRS** looked at whether PRP reduced the risk of SVL in pts with mild, moderate and/or severe NPDR. It found a modest reduction in the risk among pts with severe NPDR, but not for those with mild or moderate dz. Thus, PRP is justified in severe NPDR, but not in mild or moderate dz.

answer
of
not

reduced. This in turn halts the development and progression of neovascularization, thereby reducing the risk of SVL that neovascularization conveys.

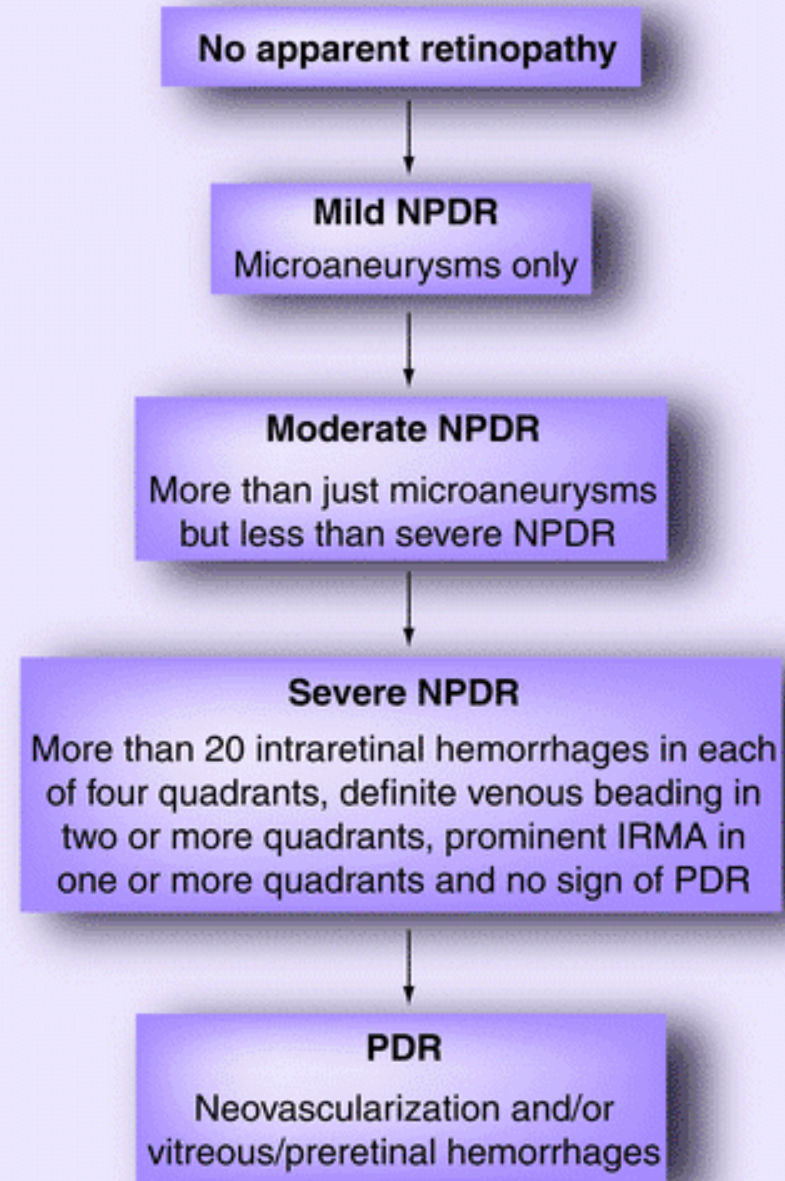
The clinical implication of finding high-risk PDR in a patient is that it represents the formal justification for performing PRP. *The DRS found that PRP reduces the risk of SVL by 50%.*

PRP has two other salutary effects on oxygen tension in the retina:

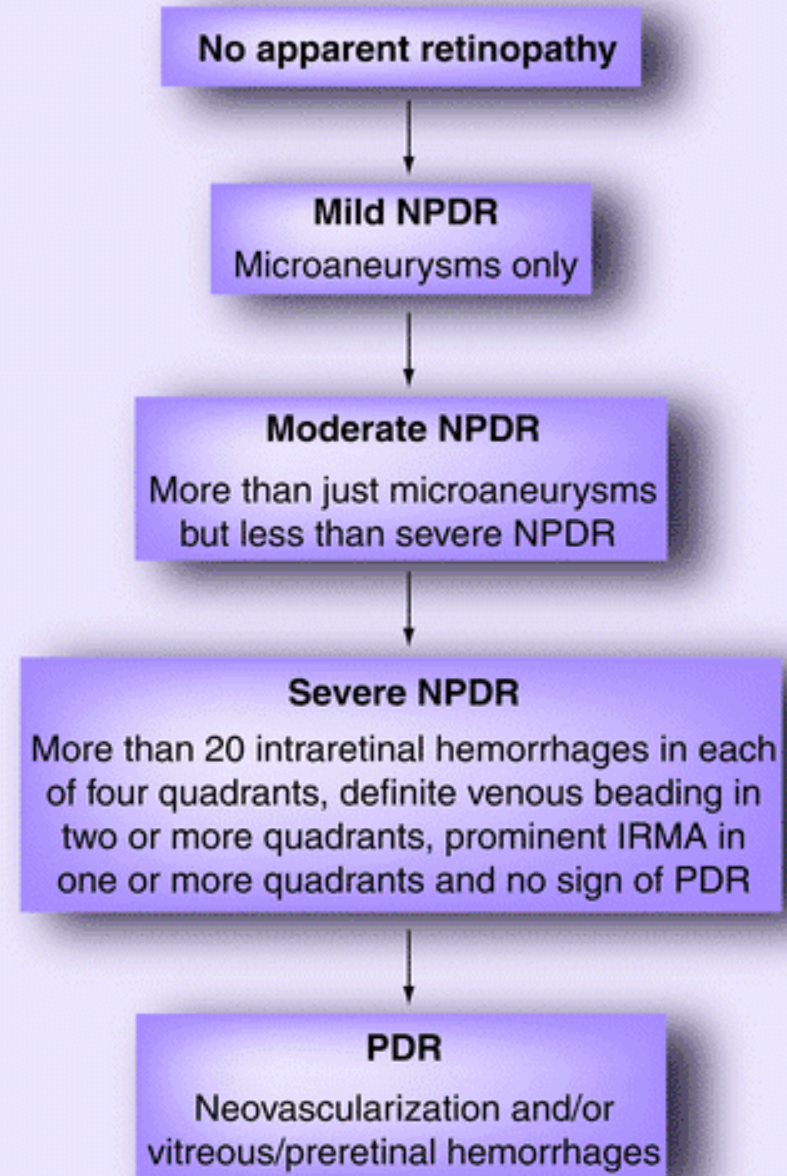
- By decreasing the number of living retinal cells competing for oxygen, the remaining ones receive a greater portion of the oxygen delivered to the retina; and
- The PRP scars facilitate the diffusion of oxygen from the choroidal circulation into the retinal space

- Large (at least $\frac{1}{4}$ DD) area of NVD with or without VH, **OR**
- Large (at least $\frac{1}{2}$ DD) area of NVE with VH

Take note: DBR is a **progressive** condition, one that passes through a well-defined series of stages on its way to blinding a pt. If DBR is identified at an early stage, the pt has a chance to enact lifestyle modifications that will lead to its resolution. If it is recognized at a later (but pre-SVL) stage, treatment can be performed that may prevent it from blinding the pt. *This is why we screen DM pts on the reg.*



Take note also of what's **not** mentioned here: **Diabetic macular edema (DME)**. This is because DME can occur at **any** stage of DBR.



Take note also of what's **not** mentioned here: *Diabetic macular edema (DME)*. This is because DME can occur at **any** stage of DBR.

Let's look at diabetic macular edema next

No apparent retinopathy

Mild NPDR

Microaneurysms only

Moderate NPDR


More than just microaneurysms

Severe NPDR

More than 20 intraretinal hemorrhages in each of four quadrants, definite venous beading in two or more quadrants, prominent IRMA in one or more quadrants and no sign of PDR

PDR

Neovascularization and/or vitreous/preretinal hemorrhages



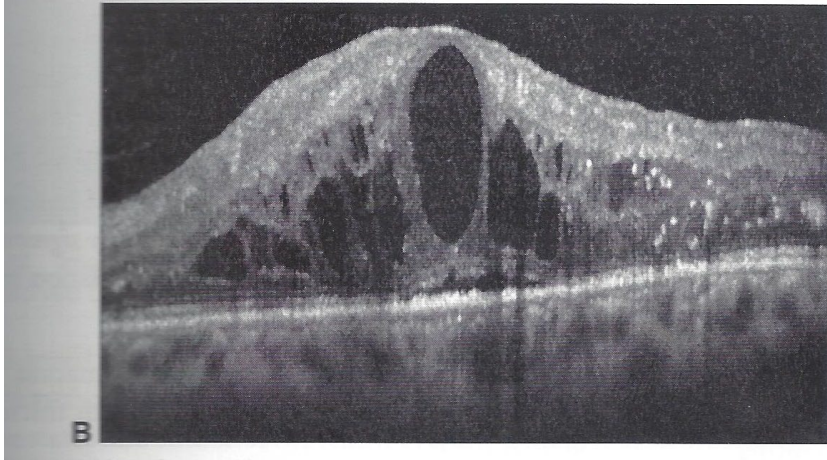
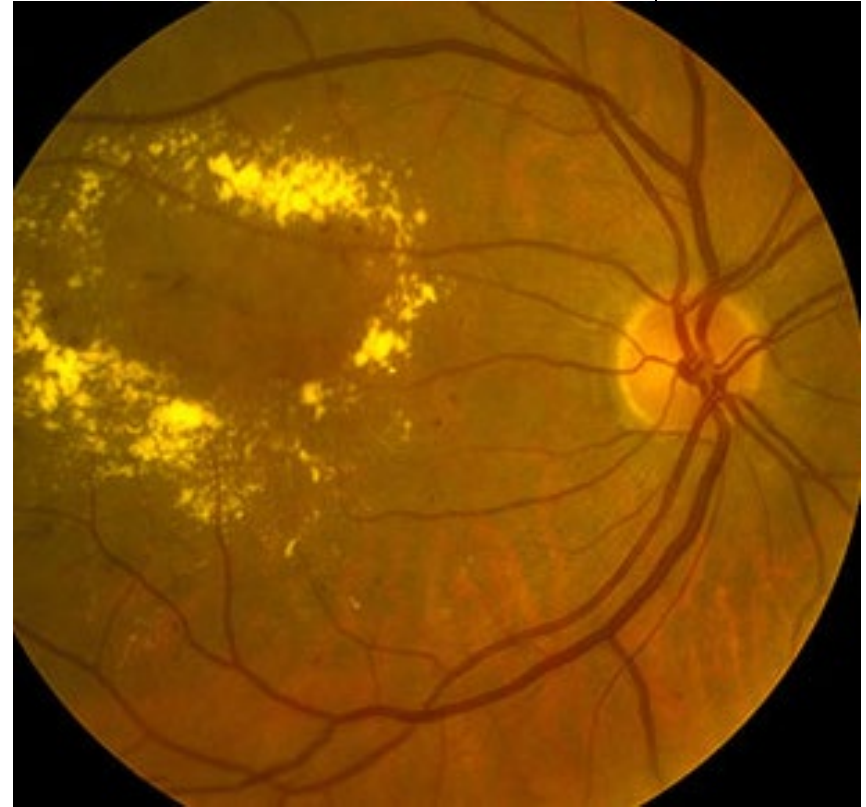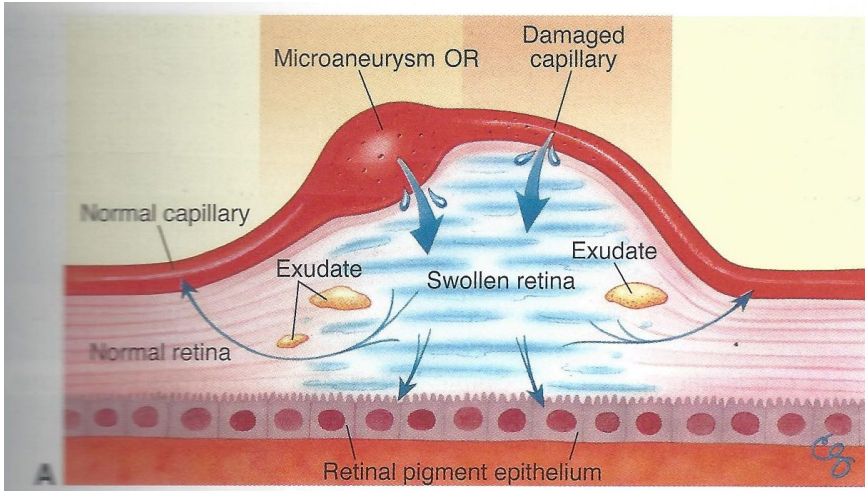

- There are three fundamental histological vascular derangements in DBR:
 - 1) Pericyte loss
 - 2) BM thickening → ↓ lumen diameter
 - 3) **Loss of endothelial barrier function**

As mentioned, the endothelial cells line the lumen of the vessel, surrounded by their BM. They are nonfenestrated, and attached to one another via tight junctions. The tight junctions between endothelial cells form the so-called *inner blood-retina barrier*. Loss of endothelial barrier function leads to the leaching of serum into the retinal space, resulting in the retinal edema that is so commonly associated with DBR.




We saw this slide early in the set. We're revisiting it as a reminder regarding the mechanism underlying the development of DME





DME




Diabetic Macular Edema

Primary intervention:
Pharmacologic

Primary intervention:
Laser surgery

There are two classes of intervention for DME: Pharmacologic, and Laser.



Diabetic Macular Edema


Primary intervention:
Pharmacologic

Primary intervention:
Laser surgery

In the present context, ***pharmacologic intervention*** refers to the intravitreal injection of a pharmacologic agent. The most commonly-employed agents work by inhibiting the action of VEGF; these include aflibercept, ranibizumab and bevacizumab. Anti-inflammatory agents (eg, triamcinolone) are also employed, but much less frequently.

and Laser.

Diabetes




Diabetic Macular Edema

Primary intervention:
Pharmacologic

Primary intervention:
Laser surgery

Laser surgery involves applying thermal energy to the microaneurysm(s) felt to be responsible for the edema (*focal macular laser, FML*), or to the area of edema broadly, in a grid pattern (*grid macular laser, GML*).

There are two classes of i



Diabetic Macular Edema

Primary intervention:
Pharmacologic

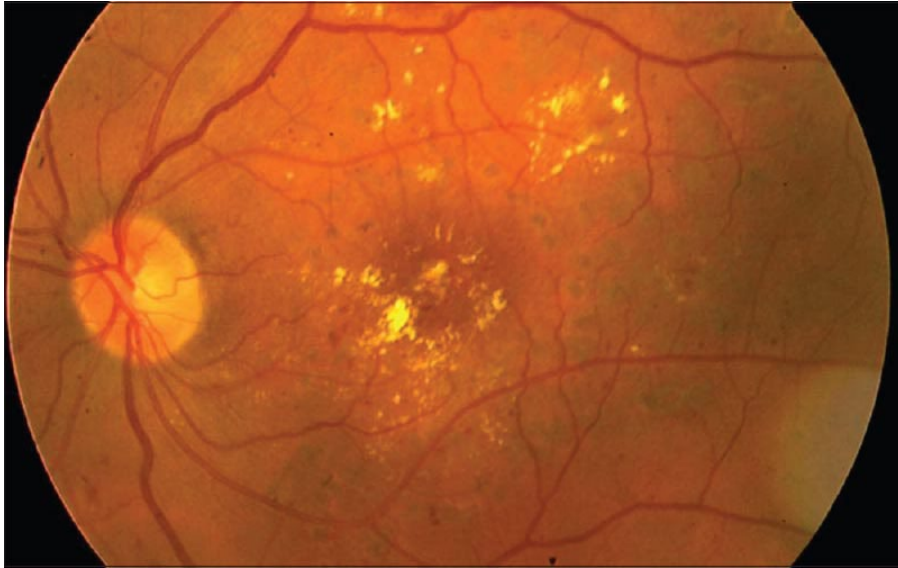

Center-
involved

Non-center-
involved

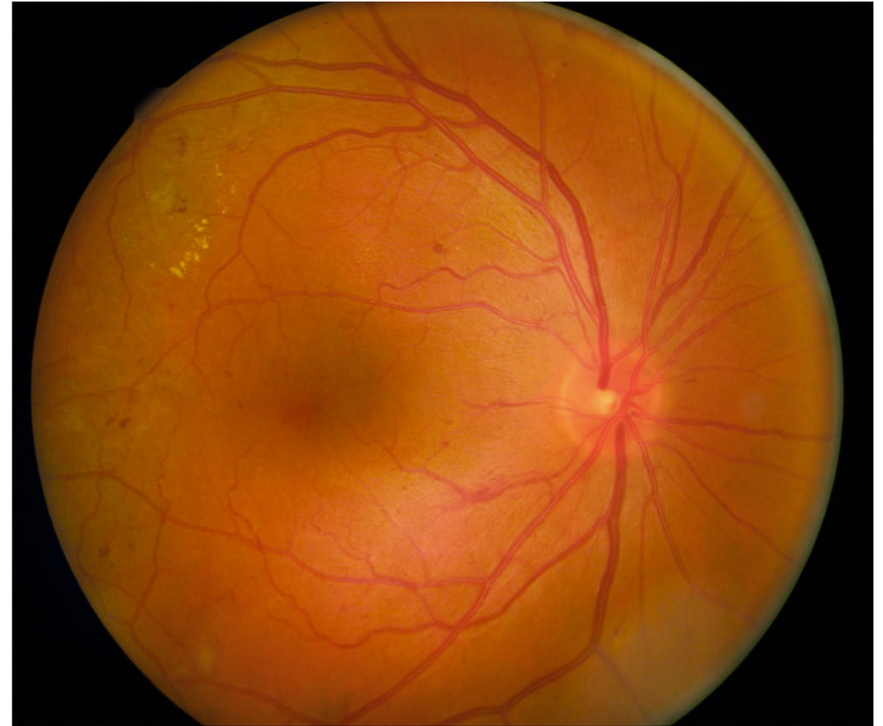Primary intervention:
Laser surgery

Two types of intervention for DME: Pharmacologic, and Laser.

When one is contemplating pharmacologic intervention, there are two types of DME: That which involves the center (foveal) region, and that which is located anywhere else. OCT is the principal means by which the presence of DME is determined.

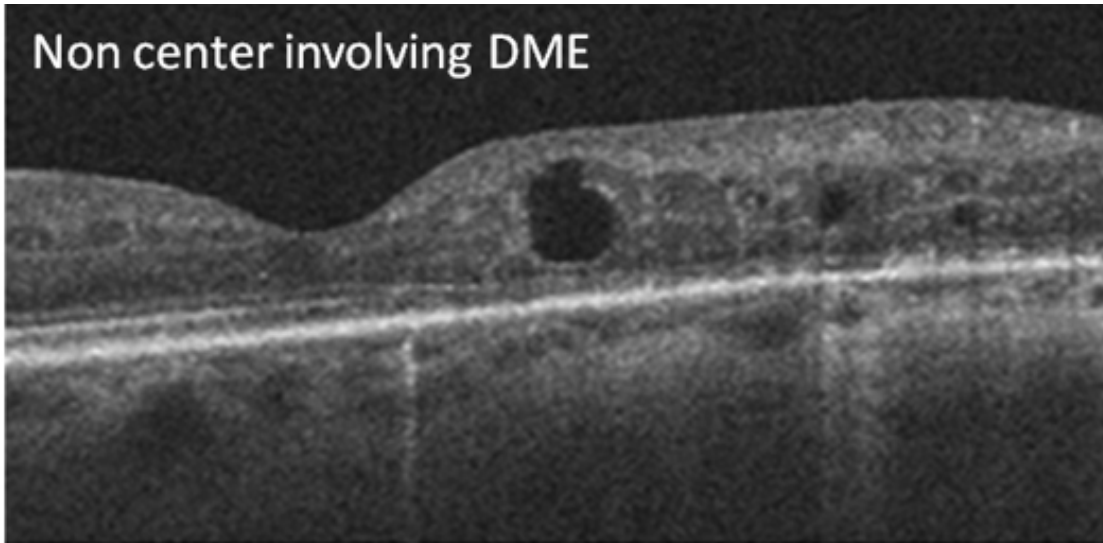
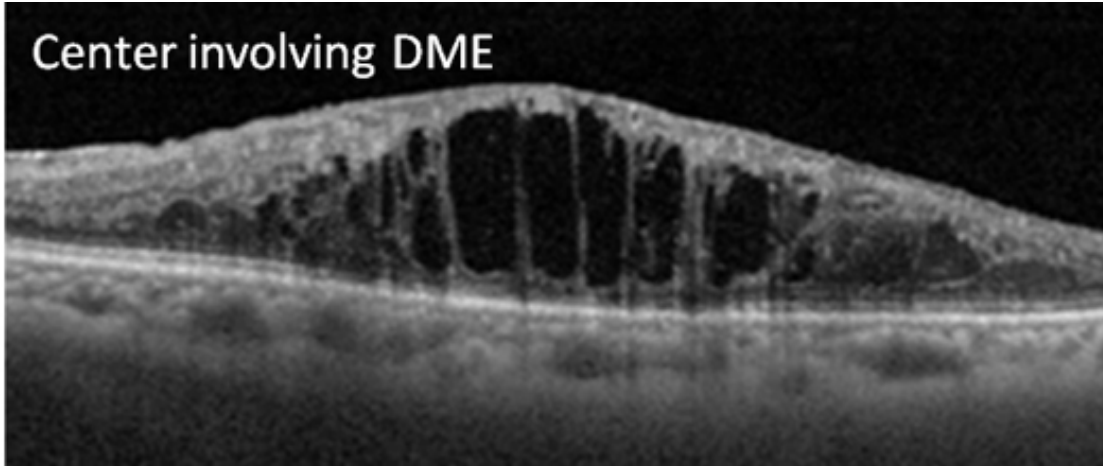



DME: Center-involved




DME: Not center-involved

Diabetes



Diabetes



Diabetic Macular Edema

Primary intervention:
Pharmacologic

Center-
involved


Non-center-
involved

Primary intervention:
Laser surgery

Two types of intervention for DME: Pharmacologic, and Laser.

When one is contemplating pharmacologic intervention, there are two types of DME: That which involves the center (foveal) region, and that which is located anywhere else. OCT is the principal means by which the presence of DME is determined. The presence of center-involving DME + decreased visual acuity is the indication that pharmacologic intervention is warranted.

Diabetes



Diabetic Macular Edema

Primary intervention:
Pharmacologic


Center-
involved

Non-center-
involved

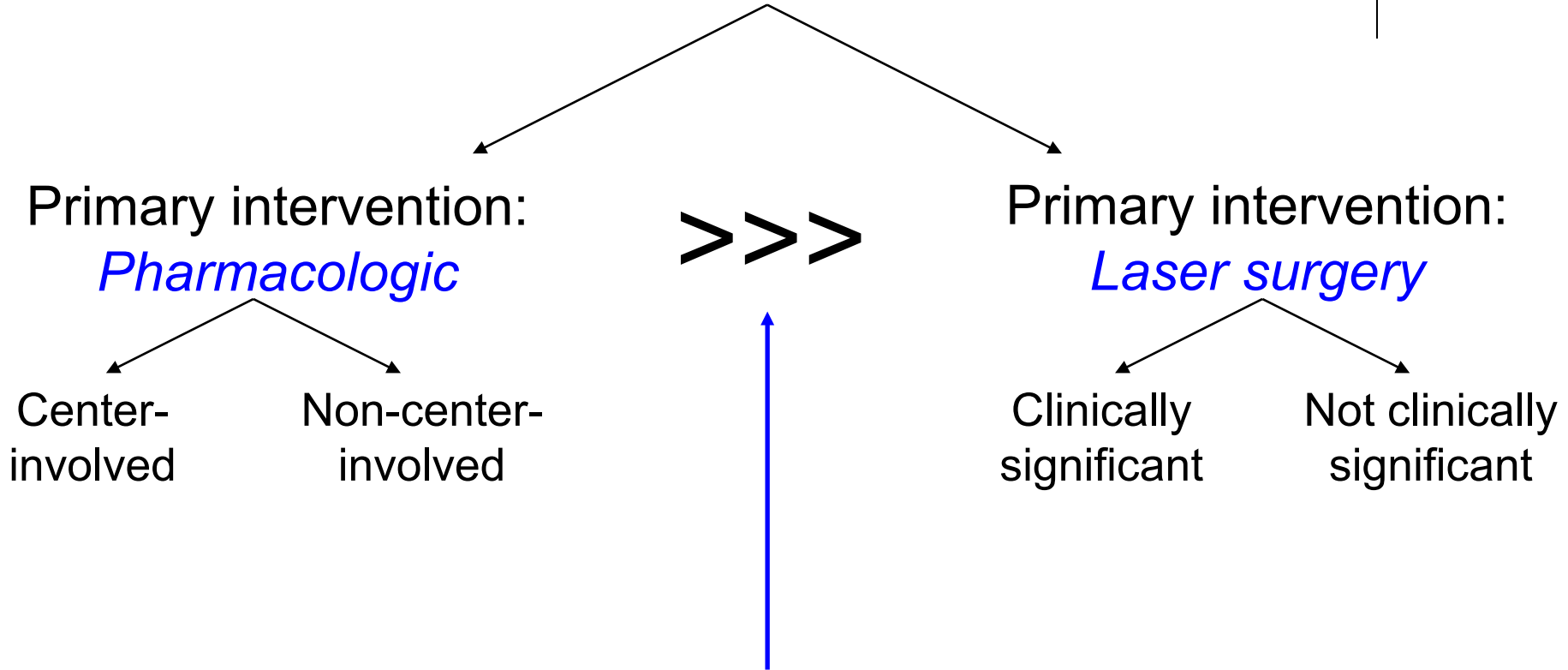
Your assessment (both in the chart and when presenting a pt to staff) of a pt with DME will commence with your assessment of their DBR, followed by your assessment of their DME; eg, *'Ms. Jones is a 58 y.o. diabetic with moderate nonproliferative dz OU. Further, she has center-involving DME OD associated with decreased visual acuity. Non-center-involved DME is present OS.'*

Three modes of intervention for DME: Pharmacologic, and Laser.

When one is contemplating pharmacologic intervention, there are two types of DME: That which involves the center (foveal) region, and that which is located anywhere else. OCT is the principal means by which the presence of DME is determined. *The presence of center-involving DME + decreased visual acuity is the indication that pharmacologic intervention is warranted.*



Diabetic Macular Edema



Of the two approaches to treating DME, *pharmacologic* is considered first-line. The reason is straightforward: With respect to visual acuity, clinical trials have found that pharmacologic yields consistently superior results.

Diabetes

Diabetic Macular Edema

Primary intervention:
Pharmacologic

>>>


Primary intervention:
Laser surgery

A study called **Protocol I*** was the first phase 3 clinical trial to demonstrate that an intravitreal anti-VEGF agent (specifically, ranibizumab) was superior to laser for the tx of center-involved DME—ranibizumab-treated eyes gained about 9 letters of acuity on average, compared to only 3 in the laser-treated eyes.

(*This is the letter *I*, not the number 1)

Of the two approaches to treating DME, *pharmacologic* is considered first-line. The reason is straightforward: With respect to visual acuity, clinical trials have found that pharmacologic yields consistently superior results.

Diabetes



Diabetic Macular Edema

Primary intervention:
Pharmacologic

>>>

Primary intervention:
Laser surgery

A study called **Protocol I*** was the first phase 3 clinical trial to demonstrate that an intravitreal anti-VEGF agent (specifically, ranibizumab) was superior to laser for the tx of center-involved DME—ranibizumab-treated eyes gained about 9 letters of acuity on average, compared to only 3 in the laser-treated eyes. Other phase 3 studies have found that bevacizumab and aflibercept are similarly superior to laser; these include the **RISE** and **RIDE**, **VIVID** and **VISTA**, and **Protocol T** studies.

(*This is the letter *I*, not the number 1)

Of the two approaches to treating DME, *pharmacologic* is considered first-line. The reason is straightforward: With respect to visual acuity, **clinical trials** have found that pharmacologic yields consistently superior results.



That's it! Go through this slide-set a couple of times (at least) until you feel like you have a handle on it. **When you're ready, do slide-sets *R31* and *R32*, which cover this material in a Q&A format (and more detail).**