
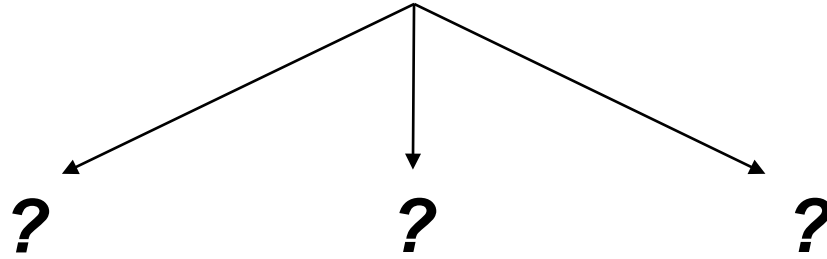

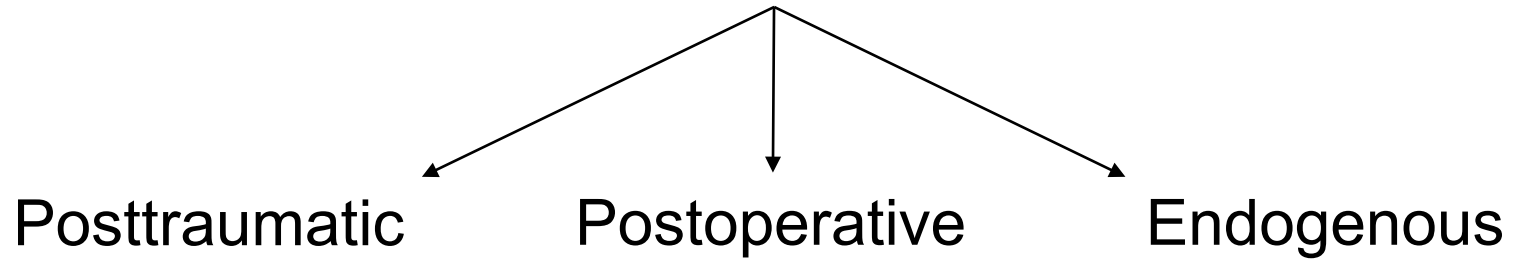


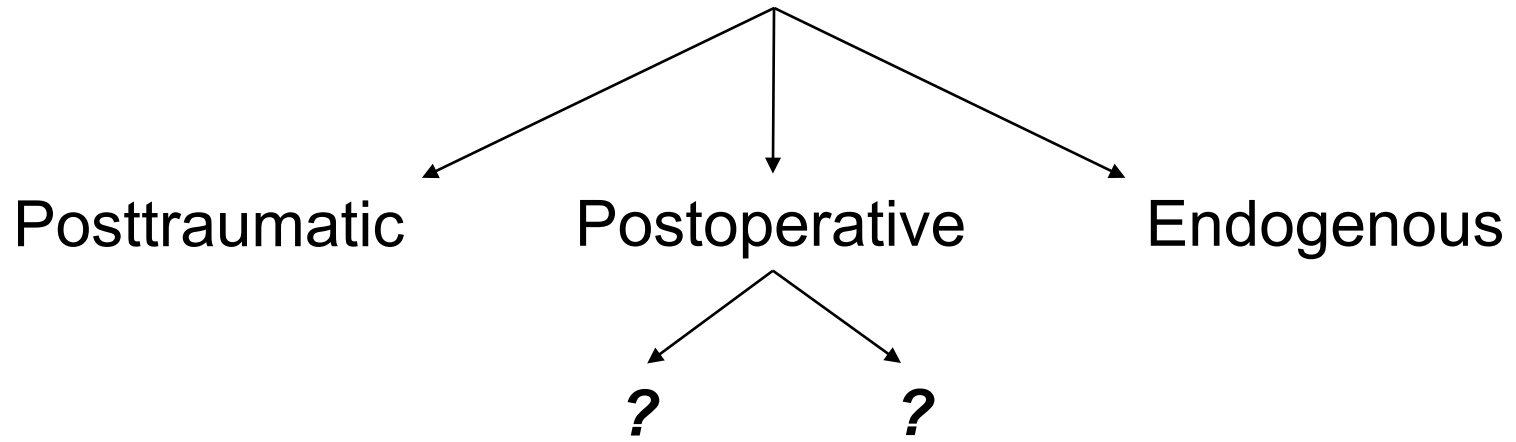
Endophthalmitis




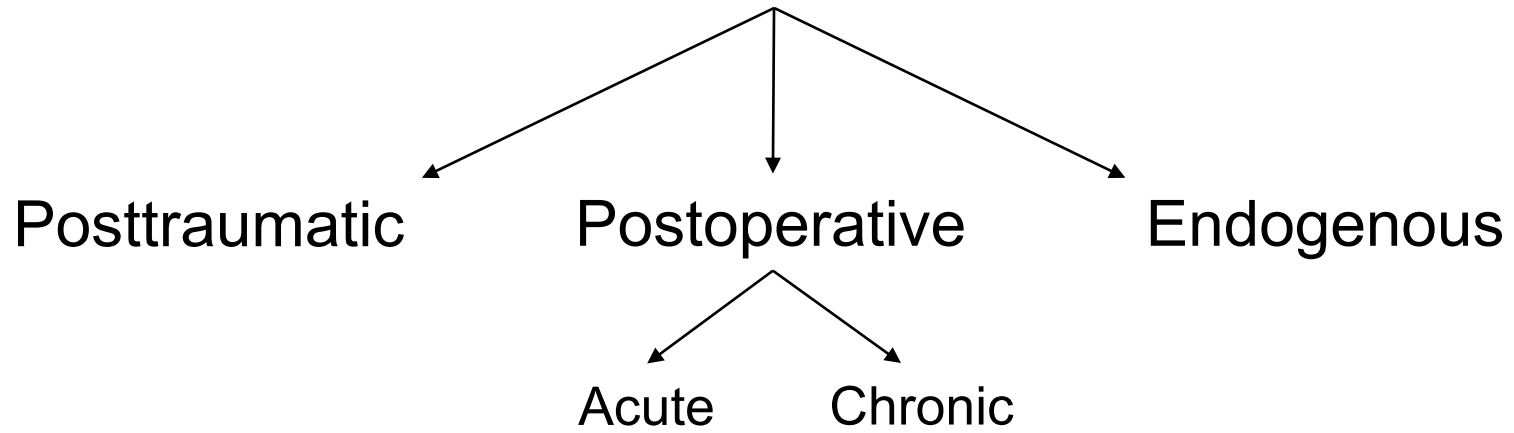
Endophthalmitis




Endophthalmitis

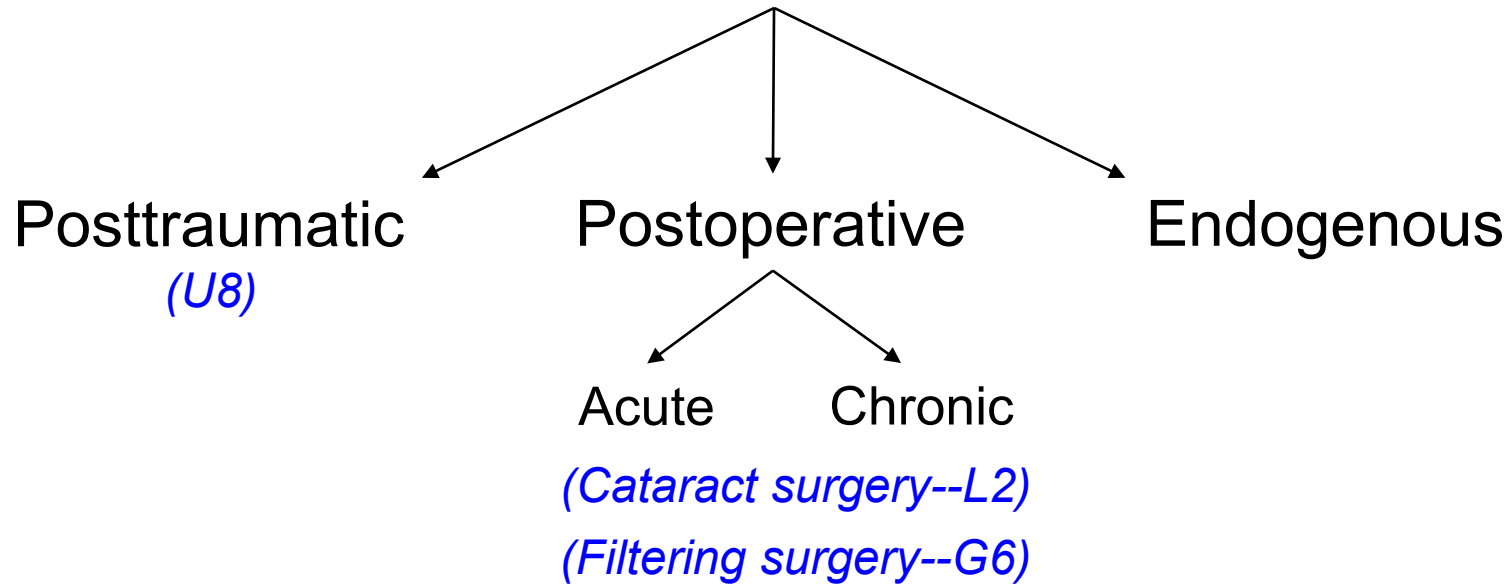


Endophthalmitis






Endophthalmitis



(Posttraumatic and postoperative endophthalmitis are discussed in the slide-sets listed above. The remainder of this slide-set will address endogenous endophthalmitis)

Endogenous Endophthalmitis

Is endogenous endophthalmitis a common entity?



Endogenous Endophthalmitis

Is endogenous endophthalmitis a common entity?


No, it is quite rare, accounting for less than % of all cases of endophthalmitis



Endogenous Endophthalmitis

Is endogenous endophthalmitis a common entity?

No, it is quite rare, accounting for less than 10% of all cases of endophthalmitis



Endogenous Endophthalmitis




Is endogenous endophthalmitis a common entity?

No, it is quite rare, accounting for less than 10% of all cases of endophthalmitis

What factors place an individual at increased risk of endogenous endophthalmitis?

Endogenous Endophthalmitis



Is endogenous endophthalmitis a common entity?


No, it is quite rare, accounting for less than 10% of all cases of endophthalmitis

What factors place an individual at increased risk of endogenous endophthalmitis?

There are many, but they can be grouped as follows:

--
--
--

Endogenous Endophthalmitis



Is endogenous endophthalmitis a common entity?

No, it is quite rare, accounting for less than 10% of all cases of endophthalmitis

What factors place an individual at increased risk of endogenous endophthalmitis?

There are many, but they can be grouped as follows:

- Impaired immune status
- Recent invasive medical procedure
- Chronic and/or repeated breaching of the body's outer barrier

Endogenous Endophthalmitis



Is endogenous endophthalmitis a common entity?

No, it is quite rare, accounting for less than 10% of all cases of endophthalmitis

What factors place an individual at risk?

There are many, but they can be categorized into:

--**Impaired immune status**

--Recent invasive medical procedures

--Chronic and/or repeated breaches of the blood-ocular barrier

What sorts of conditions are associated with impaired immune status?

--?


--?

--?

--?

--?

Endogenous Endophthalmitis



Is endogenous endophthalmitis a common entity?

No, it is quite rare, accounting for less than 10% of all cases of endophthalmitis

What factors place an individual at risk?

There are many, but they can be categorized into several groups:

--**Impaired immune status**

--Recent invasive medical procedures

--Chronic and/or repeated breaches of the blood-ocular barrier

What sorts of conditions are associated with impaired immune status?

--HIV/AIDS

--Chronic disease (eg,)

--On immunosuppressive/modulatory meds (eg, pts)

--Chemotherapy pts

--Neonates

Endogenous Endophthalmitis



Is endogenous endophthalmitis a common entity?

No, it is quite rare, accounting for less than 10% of all cases of endophthalmitis

What factors place an individual at risk?

There are many, but they can be categorized into:

--Impaired immune status

--Recent invasive medical procedures

--Chronic and/or repeated breaches of the blood-ocular barrier

What sorts of conditions are associated with impaired immune status?

--HIV/AIDS

--Chronic disease (eg, DM; malignancy; sickle-cell dz; lupus)

--On immunosuppressive/modulatory meds (eg, organ transplant pts)

--Chemotherapy pts

--Neonates

Endogenous Endophthalmitis



Is endogenous endophthalmitis a common entity?

No, it is quite rare, accounting for less than 10% of all cases of endophthalmitis

What factors place an individual at risk?

There are many, but they can be categorized into:

--**Impaired immune status**

--Recent invasive medical procedures

--Chronic and/or repeated breaches of the blood-ocular barrier

What sorts of conditions are associated with impaired immune status?

--HIV/AIDS

--Chronic disease (eg, DM; malignancy; sickle-cell dz; lupus)

--On immunosuppressive/modulatory meds (eg, organ transplant pts)

--Chemotherapy

--**Neonates**

Why are neonates on this list?

Endogenous Endophthalmitis



Is endogenous endophthalmitis a common entity?

No, it is quite rare, accounting for less than 10% of all cases of endophthalmitis

What factors place an individual at risk?

There are many, but they can be categorized into several groups:

--Impaired immune status

--Recent invasive medical procedure

--Chronic and/or repeated breaches of the blood-ocular barrier

What sorts of conditions are associated with impaired immune status?

--HIV/AIDS

--Chronic disease (eg, DM; malignancy; sickle-cell dz; lupus)

--On immunosuppressive/modulatory meds (eg, organ transplant pts)

--Chemotherapy

--Neonates

Why are neonates on this list?

The immune system does not fully mature until an infant is at least 6 months old. Until it does, they are immunocompromised to a degree.

Endogenous Endophthalmitis



Is endogenous endophthalmitis a common entity?

No, it is quite rare, accounting for less than 10% of all cases of endophthalmitis

What factors place an individual at increased risk of endogenous endophthalmitis?

There are many, but they can be grouped as follows:

--Impaired immune status

--**Recent invasive medical procedure**

--Chronic and/or repeated breaching of the body's outer barrier

Virtually any invasive medical procedure could result in endogenous endophthalmitis, but the BCSC Uveitis book mentions three by name. What are they?

--?

--?

--?

Endogenous Endophthalmitis



Is endogenous endophthalmitis a common entity?

No, it is quite rare, accounting for less than 10% of all cases of endophthalmitis

What factors place an individual at increased risk of endogenous endophthalmitis?

There are many, but they can be grouped as follows:

--Impaired immune status

--**Recent invasive medical procedure**

--Chronic and/or repeated breaching of the body's outer barrier

Virtually any invasive medical procedure could result in endogenous endophthalmitis, but the BCSC Uveitis book mentions three by name. What are they?

--Bowel surgery

--Endoscopy

--Dental work

Endogenous Endophthalmitis



Is endogenous endophthalmitis a common entity?

No, it is quite rare, accounting for less than 10% of all cases of endophthalmitis

What factors place an individual at increased risk of endogenous endophthalmitis?

There are many, but they can be grouped as follows:

- Impaired immune status
- Recent invasive medical procedure
- Chronic and/or repeated breaching of the body's outer barrier**

Important examples of chronic and/or repeated breaching of the body's outer barrier include:

- ?
- ?
- ?

Endogenous Endophthalmitis



Is endogenous endophthalmitis a common entity?

No, it is quite rare, accounting for less than 10% of all cases of endophthalmitis

What factors place an individual at increased risk of endogenous endophthalmitis?

There are many, but they can be grouped as follows:

- Impaired immune status
- Recent invasive medical procedure
- Chronic and/or repeated breaching of the body's outer barrier**

Important examples of chronic and/or repeated breaching of the body's outer barrier include:

- Indwelling catheters
- IV drug use
- Intravenous access lines

Endogenous Endophthalmitis



Is endogenous endophthalmitis a common entity?

No, it is quite rare, accounting for less than 10% of all cases of endophthalmitis

What factors place an individual at increased risk of endogenous endophthalmitis?

There are many, but they can be grouped as follows:

- Impaired immune status
- Recent invasive medical procedure
- Chronic and/or repeated breaching of the body's outer barrier

What is the mechanism of infection; ie, how do the organisms reach the interior of the globe?

Endogenous Endophthalmitis



Is endogenous endophthalmitis a common entity?

No, it is quite rare, accounting for less than 10% of all cases of endophthalmitis

What factors place an individual at increased risk of endogenous endophthalmitis?

There are many, but they can be grouped as follows:

- Impaired immune status
- Recent invasive medical procedure
- Chronic and/or repeated breaching of the body's outer barrier

What is the mechanism of infection; ie, how do the organisms reach the interior of the globe?

The route is hematogenous, with subsequent breakdown of the blood-eye barrier

Endogenous Endophthalmitis



Is endogenous endophthalmitis a common entity?

No, it is quite rare, accounting for less than 10% of all cases of endophthalmitis

What factors place an individual at increased risk of endogenous endophthalmitis?

There are many, but they can be grouped as follows:

- Impaired immune status
- Recent invasive medical procedure
- Chronic and/or repeated breaching of the body's outer barrier

What is the mechanism of infection; ie, how do the organisms reach the interior of the globe?

The route is hematogenous, with subsequent breakdown of the blood-eye barrier

The fact that the route is hematogenous suggests the organisms are traveling from a nidus elsewhere, ie, that the endophthalmitis is an ocular sequelae of an infection elsewhere. Is this usually the case?

Endogenous Endophthalmitis



Is endogenous endophthalmitis a common entity?

No, it is quite rare, accounting for less than 10% of all cases of endophthalmitis

What factors place an individual at increased risk of endogenous endophthalmitis?

There are many, but they can be grouped as follows:

- Impaired immune status
- Recent invasive medical procedure
- Chronic and/or repeated breaching of the body's outer barrier


What is the mechanism of infection; ie, how do the organisms reach the interior of the globe?

The route is hematogenous, with subsequent breakdown of the blood-eye barrier

The fact that the route is hematogenous suggests the organisms are traveling from a nidus elsewhere, ie, that the endophthalmitis is an ocular sequelae of an infection elsewhere. Is this usually the case?

Yes; it is estimated that a specific extraocular nidus is present in at least % of cases

Endogenous Endophthalmitis



Is endogenous endophthalmitis a common entity?

No, it is quite rare, accounting for less than 10% of all cases of endophthalmitis

What factors place an individual at increased risk of endogenous endophthalmitis?

There are many, but they can be grouped as follows:

- Impaired immune status
- Recent invasive medical procedure
- Chronic and/or repeated breaching of the body's outer barrier

What is the mechanism of infection; ie, how do the organisms reach the interior of the globe?

The route is hematogenous, with subsequent breakdown of the blood-eye barrier

The fact that the route is hematogenous suggests the organisms are traveling from a nidus elsewhere, ie, that the endophthalmitis is an ocular sequelae of an infection elsewhere. Is this usually the case?

Yes; it is estimated that a specific extraocular nidus is present in at least 90% of cases

Endogenous Endophthalmitis



Is endogenous endophthalmitis a common entity?

No, it is quite rare, accounting for less than 10% of all cases of endophthalmitis

What factors place an individual at increased risk of endogenous endophthalmitis?

There are many, but they can be grouped as follows:

- Impaired immune status
- Recent invasive medical procedure
- Chronic and/or repeated breaching of the body's outer barrier

What is the mechanism of infection; ie, how do the organisms reach the interior of the globe?

The route is hematogenous, with subsequent breakdown of the blood-eye barrier

The fact that the route is hematogenous suggests the organisms are traveling from a nidus elsewhere, ie, that the endophthalmitis is an ocular sequelae of an infection elsewhere. Is this usually the case?

Yes; it is estimated that a specific **extraocular nidus** is present in at least 90% of cases

Which extraocular locations are frequently implicated as the source in endogenous endophthalmitis?

- ?
- ?
- ?
- ?
- ?
- ?
- ?

Endogenous Endophthalmitis



Is endogenous endophthalmitis a common entity?

No, it is quite rare, accounting for less than 10% of all cases of endophthalmitis

What factors place an individual at increased risk of endogenous endophthalmitis?

There are many, but they can be grouped as follows:

- Impaired immune status
- Recent invasive medical procedure
- Chronic and/or repeated breaching of the body's outer barrier

What is the mechanism of infection; ie, how do the organisms reach the interior of the globe?

The route is hematogenous, with subsequent breakdown of the blood-eye barrier


The fact that the route is hematogenous suggests the organisms are traveling from a nidus elsewhere, ie, that the endophthalmitis is an ocular sequelae of an infection elsewhere. Is this usually the case?

Yes; it is estimated that a specific **extraocular nidus** is present in at least 90% of cases

Which extraocular locations are frequently implicated as the source in endogenous endophthalmitis?

- Lungs
- Bladder
- Liver
- Sinuses
- Skin
- CNS (ie, meningitis)
- Heart

Endogenous Endophthalmitis



Is endogenous endophthalmitis a common entity?

No, it is quite rare, accounting for less than 10% of all cases of endophthalmitis

What factors place an individual at increased risk of endogenous endophthalmitis?

There are many, but they can be grouped as follows:

- Impaired immune status
- Recent invasive medical procedure
- Chronic and/or repeated breaching of the body's outer barrier

What is the mechanism of infection; ie, how do the organisms reach the interior of the globe?

The route is hematogenous, with subsequent breakdown of the blood-eye barrier

The fact that the route is hematogenous suggests the organisms are traveling from a nidus elsewhere, ie, that the endophthalmitis is an ocular sequelae of an infection elsewhere. Is this usually the case?

Yes; it is estimated that a specific extraocular nidus is present in at least 90% of cases

What if no nidus can be identified?

Endogenous Endophthalmitis



Is endogenous endophthalmitis a common entity?

No, it is quite rare, accounting for less than 10% of all cases of endophthalmitis

What factors place an individual at increased risk of endogenous endophthalmitis?

There are many, but they can be grouped as follows:

- Impaired immune status
- Recent invasive medical procedure
- Chronic and/or repeated breaching of the body's outer barrier

What is the mechanism of infection; ie, how do the organisms reach the interior of the globe?

The route is hematogenous, with subsequent breakdown of the blood-eye barrier

The fact that the route is hematogenous suggests the organisms are traveling from a nidus elsewhere, ie, that the endophthalmitis is an ocular sequelae of an infection elsewhere. Is this usually the case?


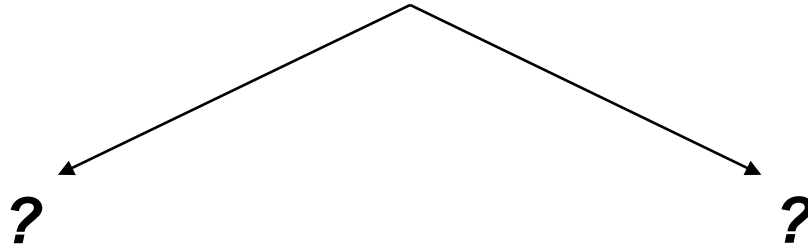
Yes; it is estimated that a specific extraocular nidus is present in at least 90% of cases

What if no nidus can be identified?

Keep looking! Don't rely on labs and/or imaging studies to find it; rather, take a more careful and detailed history and ROS, and perform a more thorough PE. (Remember the old maxim: 'When all else fails, examine the pt.')

That lower-extremity pain might actually be osteomyelitis. That 'common cold' might actually be bacterial sinusitis.

Endogenous Endophthalmitis



The organisms causing endogenous endophthalmitis come from one of two groups. What are they?

Endogenous Endophthalmitis


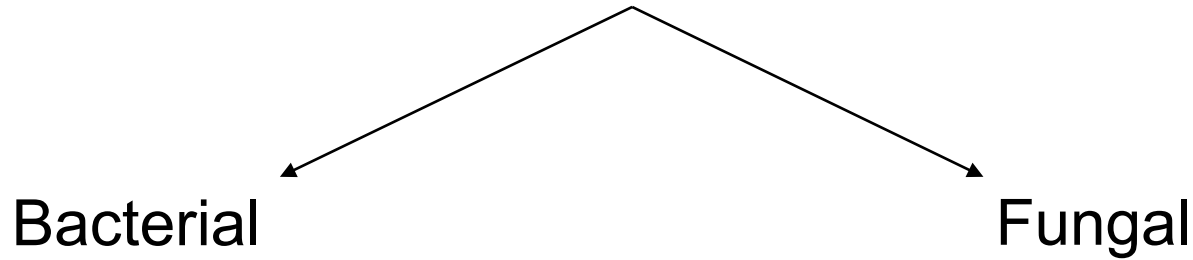
Bacterial

Fungal



The organisms causing endogenous endophthalmitis come from one of two groups. What are they?
Bacteria, and fungi

Endogenous Endophthalmitis



*The organisms causing endogenous endophthalmitis come from one of two groups. What are they?
Bacteria, and fungi*

Which is more common, bacterial or fungal endogenous endophthalmitis?

Endogenous Endophthalmitis

Bacterial

Fungal




The organisms causing endogenous endophthalmitis come from one of two groups. What are they?
Bacteria, and fungi

Which is more common, bacterial or fungal endogenous endophthalmitis?
Estimates vary, but it's probably in the ballpark of 50:50

Endogenous Endophthalmitis

Bacterial

Fungal



The organisms causing endogenous endophthalmitis come from one of two groups. What are they?
Bacteria, and fungi

Which is more common, bacterial or fungal endogenous endophthalmitis?
Estimates vary, but it's probably in the ballpark of 50:50

If the identity of the organism is in question, how should the clinician proceed?

Endogenous Endophthalmitis



Bacterial

Fungal

The organisms causing endogenous endophthalmitis come from one of two groups. What are they?
Bacteria, and fungi

Which is more common, bacterial or fungal endogenous endophthalmitis?
Estimates vary, but it's probably in the ballpark of 50:50

If the identity of the organism is in question, how should the clinician proceed?
By obtaining aqueous (and vitreous, if PPV is performed) samples for culture and stains

Endogenous Endophthalmitis



Bacterial

Fungal

The organisms causing endogenous endophthalmitis come from one of two groups. What are they?
Bacteria, and fungi

Which is more common, bacterial or fungal endogenous endophthalmitis?
Estimates vary, but it's probably in the ballpark of 50:50

If the identity of the organism is in question, how should the clinician proceed?
By obtaining aqueous (and vitreous, if PPV is performed) samples for **culture** and stains


Which three culture media should be employed?

--?

--?

--?

Endogenous Endophthalmitis



Bacterial

Fungal

The organisms causing endogenous endophthalmitis come from one of two groups. What are they?
Bacteria, and fungi

Which is more common, bacterial or fungal endogenous endophthalmitis?
Estimates vary, but it's probably in the ballpark of 50:50

If the identity of the organism is in question, how should the clinician proceed?
By obtaining aqueous (and vitreous, if PPV is performed) samples for **culture** and stains

Which three culture media should be employed?

- Aerobic
- Anaerobic
- Fungal

Endogenous Endophthalmitis



Bacterial

Fungal

The organisms causing endogenous endophthalmitis come from one of two groups. What are they?
Bacteria, and fungi

Which is more common, bacterial or fungal endogenous endophthalmitis?
Estimates vary, but it's probably in the ballpark of 50:50

If the identity of the organism is in question, how should the clinician proceed?
By obtaining aqueous (and vitreous, if PPV is performed) samples for culture and **stains**

Which two stains should be used?

--?

--?

Endogenous Endophthalmitis



Bacterial

Fungal

The organisms causing endogenous endophthalmitis come from one of two groups. What are they?
Bacteria, and fungi

Which is more common, bacterial or fungal endogenous endophthalmitis?
Estimates vary, but it's probably in the ballpark of 50:50

If the identity of the organism is in question, how should the clinician proceed?

By obtaining aqueous (and vitreous, if PPV is performed) samples for culture and **stains**

Which two stains should be used?

- Gram
- Giemsa

Endogenous Endophthalmitis



Bacterial

Fungal

The organisms causing endogenous endophthalmitis come from one of two groups. What are they?
Bacteria, and fungi

Which is more common, bacterial or fungal endogenous endophthalmitis?
Estimates vary, but it's probably in the ballpark of 50:50

If the identity of the organism is in question, how should the clinician proceed?
By obtaining aqueous (and vitreous, if PPV is performed) samples for culture and stains

Which is of greater utility--cultures, or stains?

Endogenous Endophthalmitis

Bacterial

Fungal



The organisms causing endogenous endophthalmitis come from one of two groups. What are they?
Bacteria, and fungi

Which is more common, bacterial or fungal endogenous endophthalmitis?
Estimates vary, but it's probably in the ballpark of 50:50


If the identity of the organism is in question, how should the clinician proceed?
By obtaining aqueous (and vitreous, if PPV is performed) samples for culture and stains

Which is of greater utility--cultures, or stains?
Stains, definitely. Remember, these pathogens are slow-growing and fastidious; thus, it could be weeks before they reveal themselves via culturing. On the other hand, staining has the potential to identify the culprit **instantly**.

Endogenous Endophthalmitis

Bacterial

Fungal



The organisms causing endogenous endophthalmitis come from one of two groups. What are they?
Bacteria, and fungi

Which is more common, bacterial or fungal endogenous endophthalmitis?
Estimates vary, but it's probably in the ballpark of 50:50

If the identity of the organism is in question, how should the clinician proceed?
By obtaining aqueous (and vitreous, if PPV is performed) samples for culture and stains

Which is of greater utility--cultures, or stains?
Stains, definitely. Remember, these pathogens are slow-growing and fastidious; thus, it could be weeks before they reveal themselves via culturing. On the other hand, staining has the potential to identify the culprit **instantly**.

What about the potential nidus of infection?

Endogenous Endophthalmitis



Bacterial

Fungal

The organisms causing endogenous endophthalmitis come from one of two groups. What are they?
Bacteria, and fungi

Which is more common, bacterial or fungal endogenous endophthalmitis?
Estimates vary, but it's probably in the ballpark of 50:50

If the identity of the organism is in question, how should the clinician proceed?
By obtaining aqueous (and vitreous, if PPV is performed) samples for culture and stains

Which is of greater utility--cultures, or stains?

Stains, definitely. Remember, these pathogens are slow-growing and fastidious; thus, it could be weeks before they reveal themselves via culturing. On the other hand, staining has the potential to identify the culprit **instantly**.

What about the potential nidus of infection?


The H&P should guide the obtaining of nonocular specimens for cultures and stains. If in doubt, blood, urine and sputum C&S should probably be checked. Imaging studies should be considered as well, with consideration given to percutaneous or even open biopsies as the clinical situation warrants.

Endogenous Endophthalmitis

Bacterial

Fungal

How does endogenous bacterial endophthalmitis present?



Endogenous Endophthalmitis

Bacterial

Fungal

How does endogenous bacterial endophthalmitis present?
With both systemic and ocular findings



Endogenous Endophthalmitis

Bacterial

Fungal

How does endogenous bacterial endophthalmitis present?

With both systemic and ocular findings

What systemic findings are common?



Endogenous Endophthalmitis

Bacterial


Fungal

How does endogenous bacterial endophthalmitis present?

With both systemic and ocular findings

What systemic findings are common?

Those associated with infection: fever, elevated white count, malaise



Endogenous Endophthalmitis

Bacterial

Fungal

How does endogenous bacterial endophthalmitis present?

With both systemic and ocular findings

What systemic findings are common?

Those associated with infection: fever, elevated white count, malaise

What ocular complaints are typically associated with endogenous bacterial endophthalmitis?



Endogenous Endophthalmitis

Bacterial

Fungal

How does endogenous bacterial endophthalmitis present?


With both systemic and ocular findings

What systemic findings are common?

Those associated with infection: fever, elevated white count, malaise

What ocular complaints are typically associated with endogenous bacterial endophthalmitis?

The acute onset of pain, redness and decreased vision



Endogenous Endophthalmitis



Bacterial

Fungal

How does endogenous bacterial endophthalmitis present?

With both systemic and ocular findings

What systemic findings are common?

Those associated with infection: fever, elevated white count, malaise

What ocular complaints are typically associated with endogenous bacterial endophthalmitis?

The acute onset of pain, redness and decreased vision

What ocular signs are typically found?

--

--

--

--

--

Endogenous Endophthalmitis



Bacterial

Fungal

How does endogenous bacterial endophthalmitis present?

With both systemic and ocular findings

What systemic findings are common?

Those associated with infection: fever, elevated white count, malaise

What ocular complaints are typically associated with endogenous bacterial endophthalmitis?

The acute onset of pain, redness and decreased vision

What ocular signs are typically found?

--Periorbital/lid edema

--A red, angry eye

--A fibrinous AC +/- hypopyon

--Vitreous inflammation

--Retinal microabscesses may be present, or white-centered hemorrhages (aka

two words

Endogenous Endophthalmitis



Bacterial

Fungal

How does endogenous bacterial endophthalmitis present?

With both systemic and ocular findings

What systemic findings are common?

Those associated with infection: fever, elevated white count, malaise

What ocular complaints are typically associated with endogenous bacterial endophthalmitis?

The acute onset of pain, redness and decreased vision

What ocular signs are typically found?

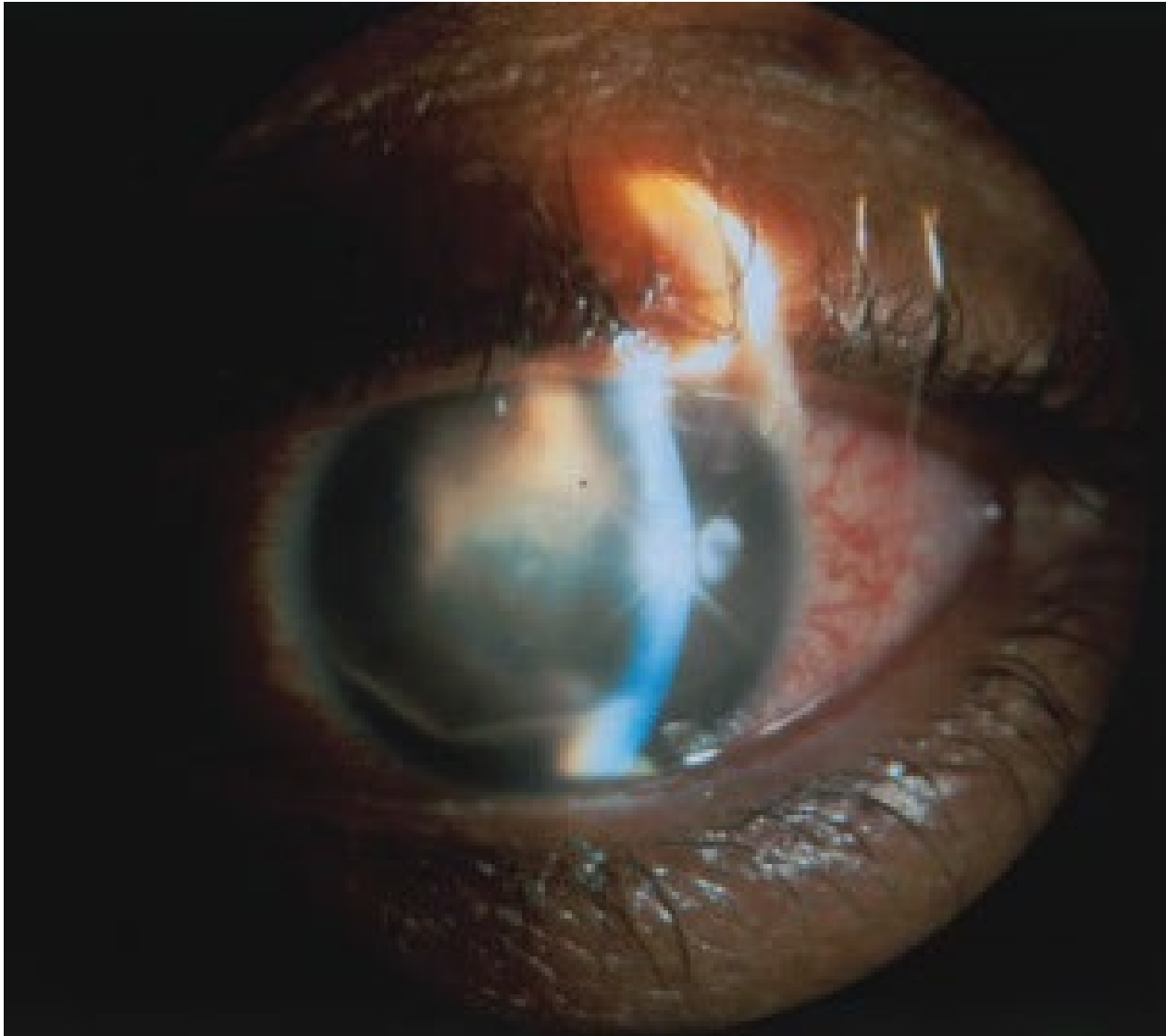--Periorbital/lid edema

--A red, angry eye

--A fibrinous AC +/- hypopyon


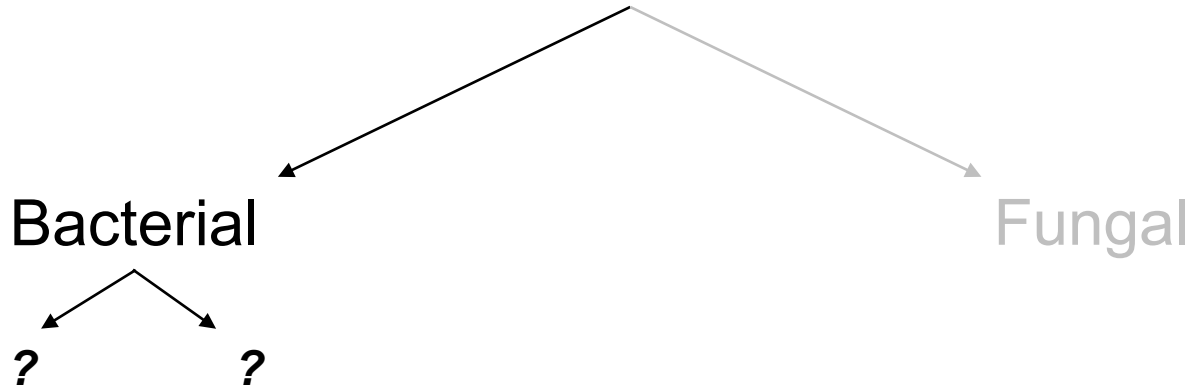
--Vitreous inflammation

--Retinal microabscesses may be present, or white-centered hemorrhages (aka **Roth spots**)




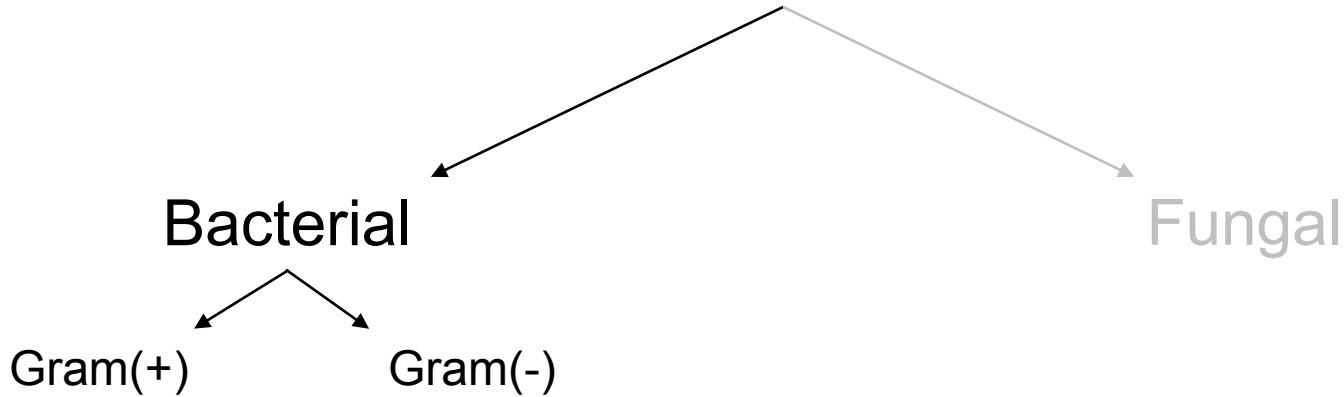
Bacterial endophthalmitis

Endogenous Endophthalmitis



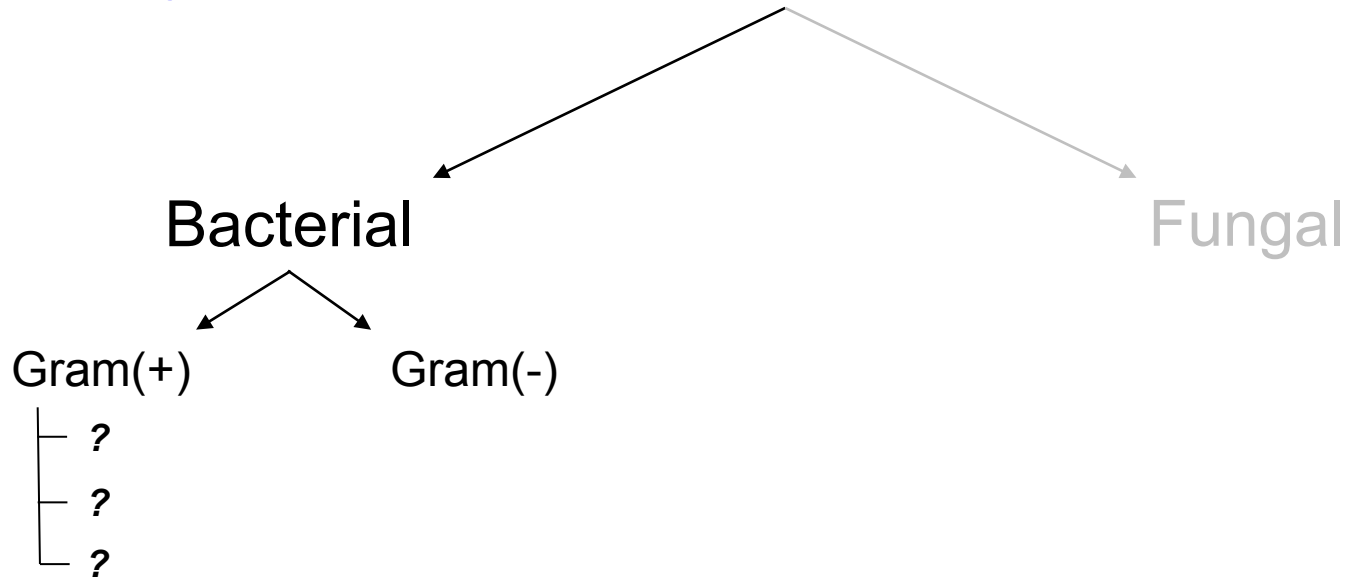

Bacteria are frequently classified with respect to a basic microbiologic property. What is it?

Endogenous Endophthalmitis



*Bacteria are frequently classified with respect to a basic microbiologic property. What is it?
Whether they are G(+) or G(-)*

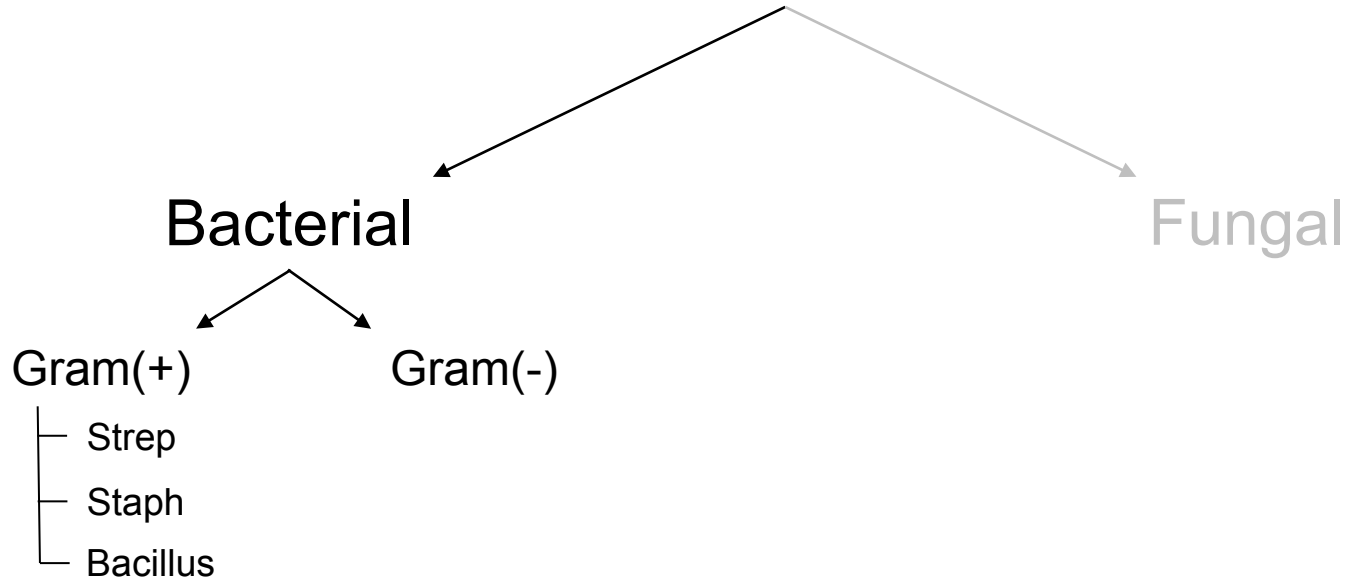
Endogenous Endophthalmitis



*Bacteria are frequently classified with respect to a basic microbiologic property. What is it?
Whether they are G(+) or G(-)*

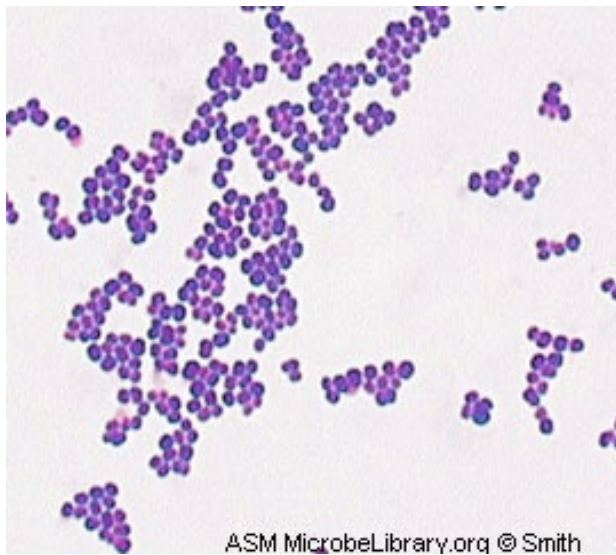
Which three G(+) bugs are most commonly implicated in endogenous bacterial endophthalmitis?

Endogenous Endophthalmitis



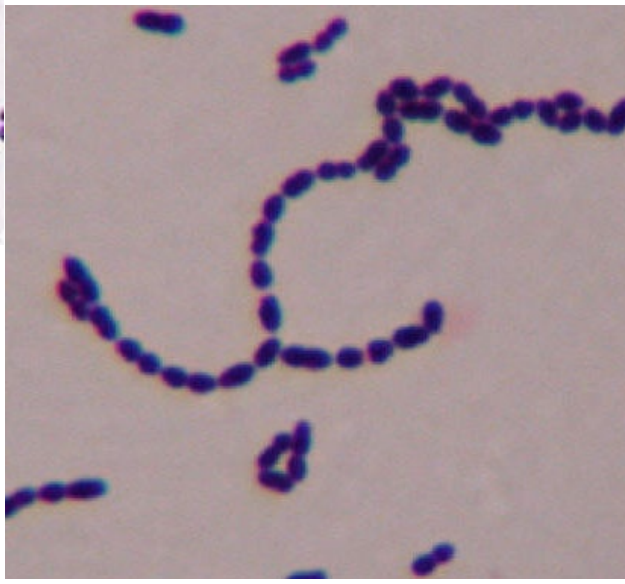*Bacteria are frequently classified with respect to a basic microbiologic property. What is it?
Whether they are G(+) or G(-)*

Which three G(+) bugs are most commonly implicated in endogenous bacterial endophthalmitis?

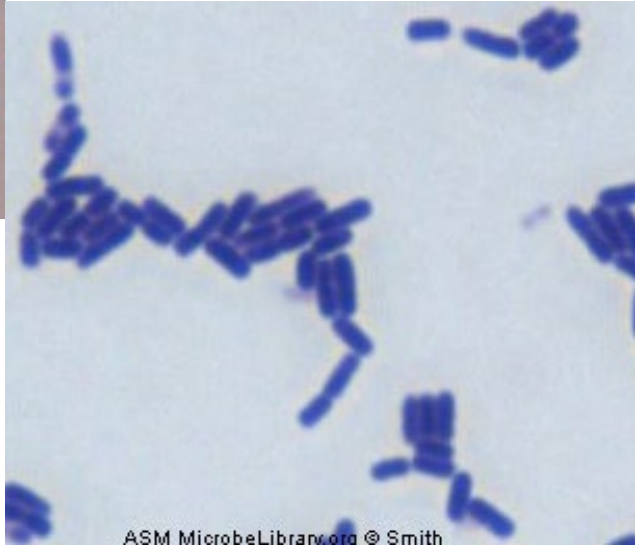


ASM MicrobeLibrary.org © Smith

Staph
'Clusters'



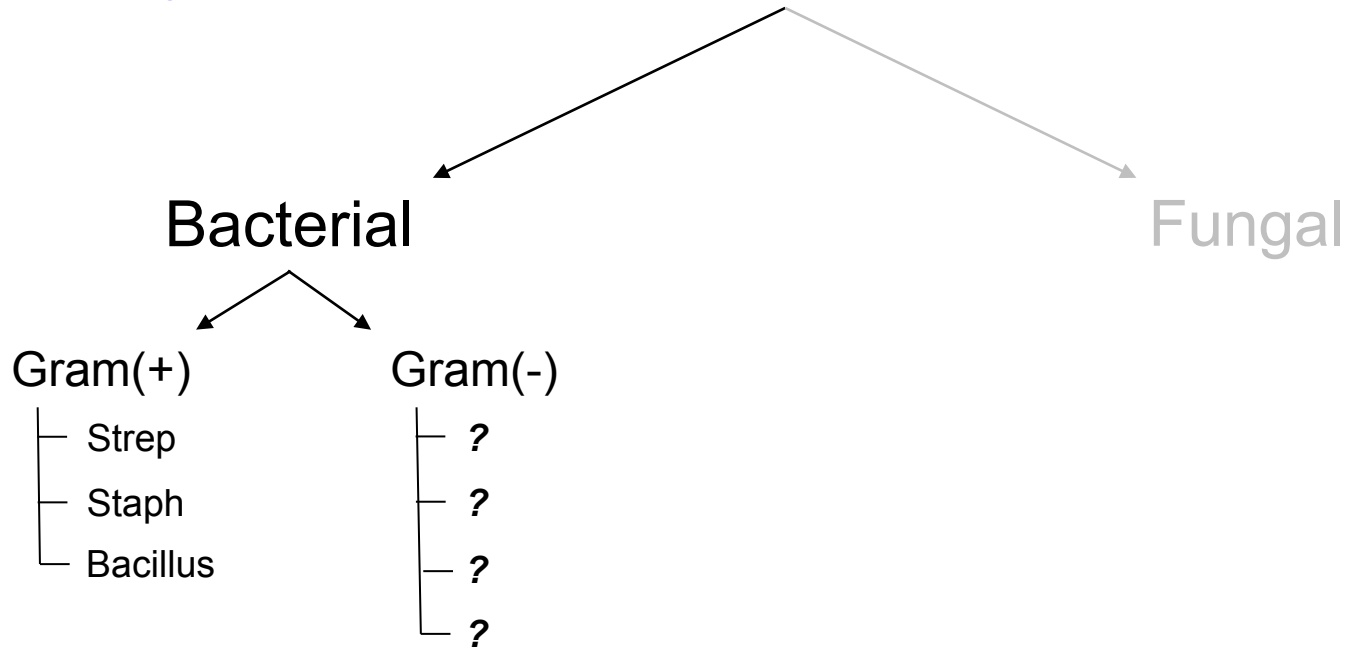
Strep
'Chains'



ASM MicrobeLibrary.org © Smith

Bacillus
'G+ rods'

Endogenous Endophthalmitis

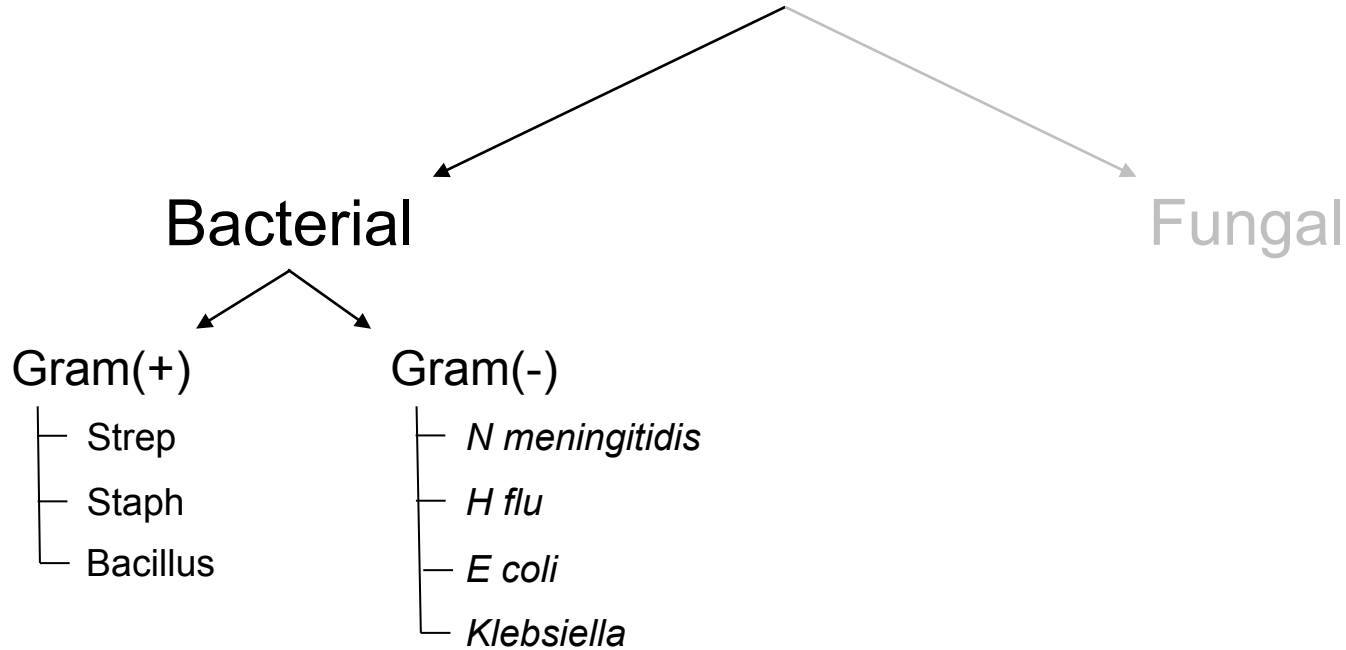


*Bacteria are frequently classified with respect to a basic microbiologic property. What is it?
Whether they are G(+) or G(-)*

Which three G(+) bugs are most commonly implicated in endogenous bacterial endophthalmitis?

Which four G(-) bugs are most commonly implicated in endogenous bacterial endophthalmitis?

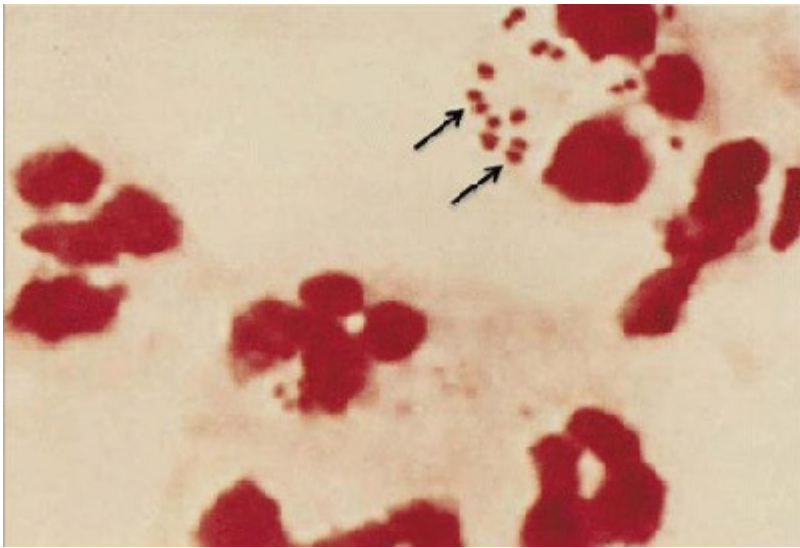
Endogenous Endophthalmitis



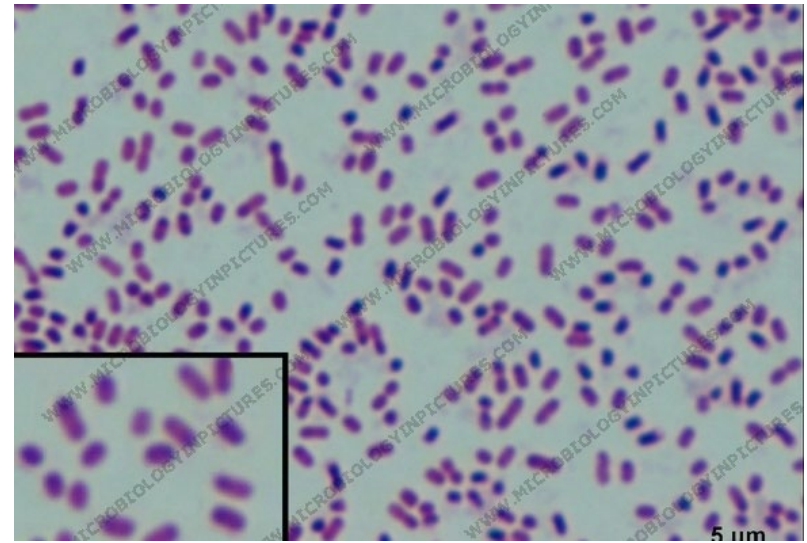
*Bacteria are frequently classified with respect to a basic microbiologic property. What is it?
Whether they are G(+) or G(-)*

Which three G(+) bugs are most commonly implicated in endogenous bacterial endophthalmitis?

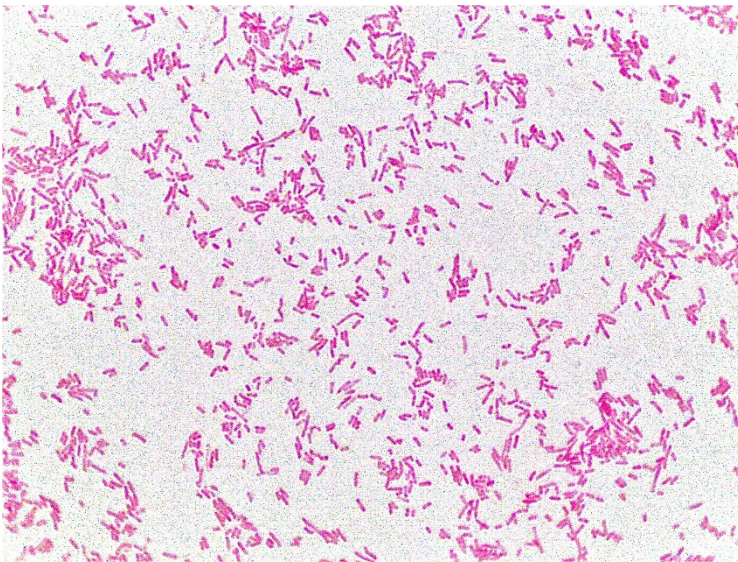
Which four G(-) bugs are most commonly implicated in endogenous bacterial endophthalmitis?



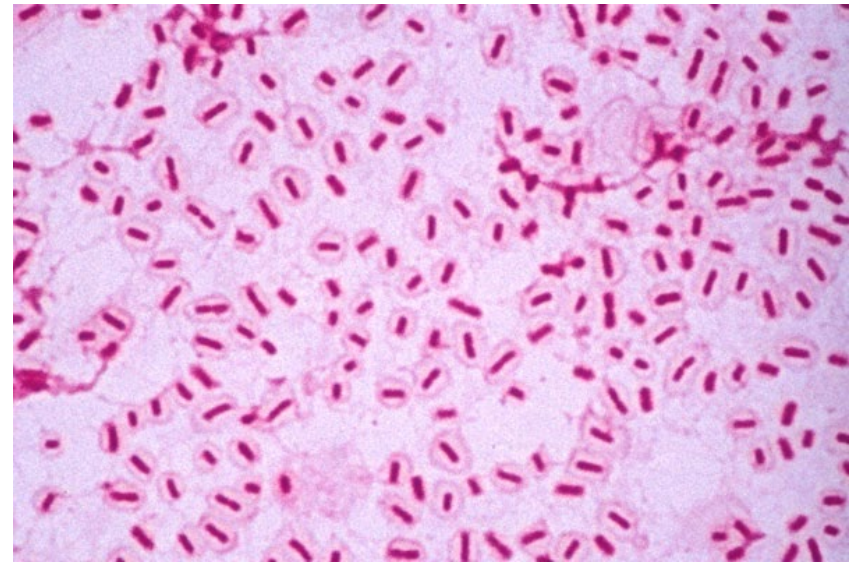
N meningitidis: 'Diplococci in PMNs'



H flu: 'Short rods'



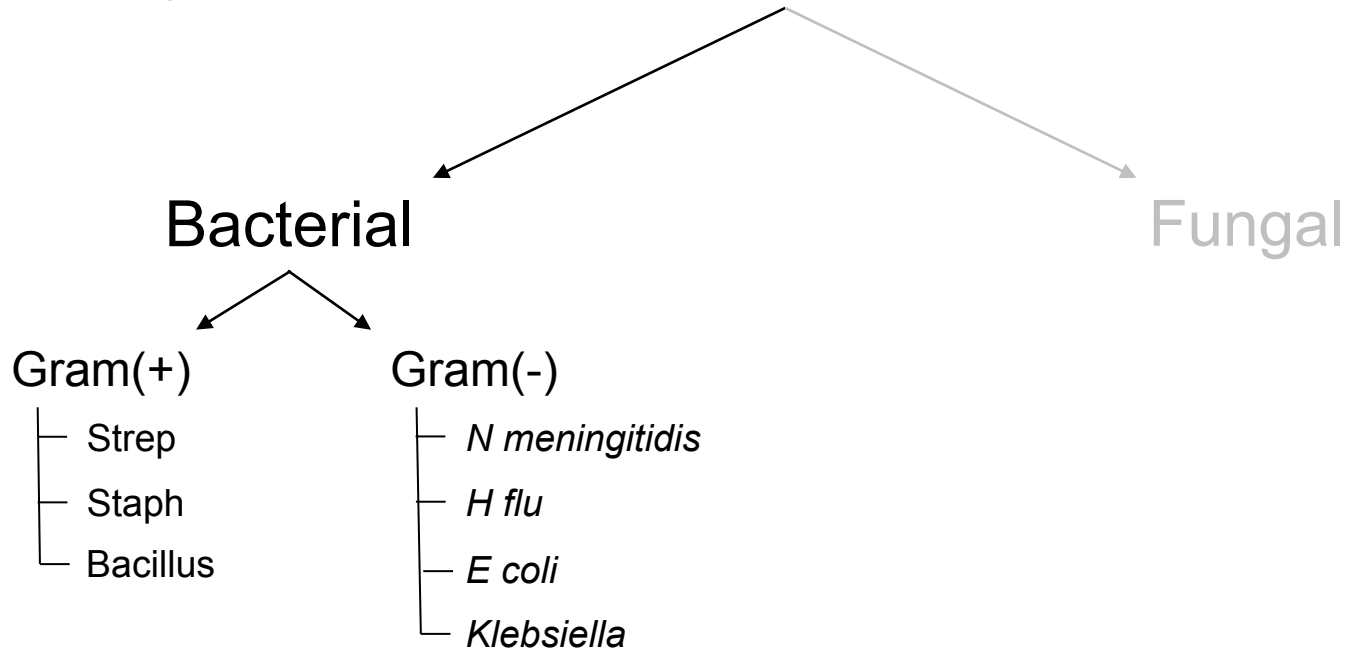
E coli: 'Nothing special'



Klebsiella: 'Very large capsule'



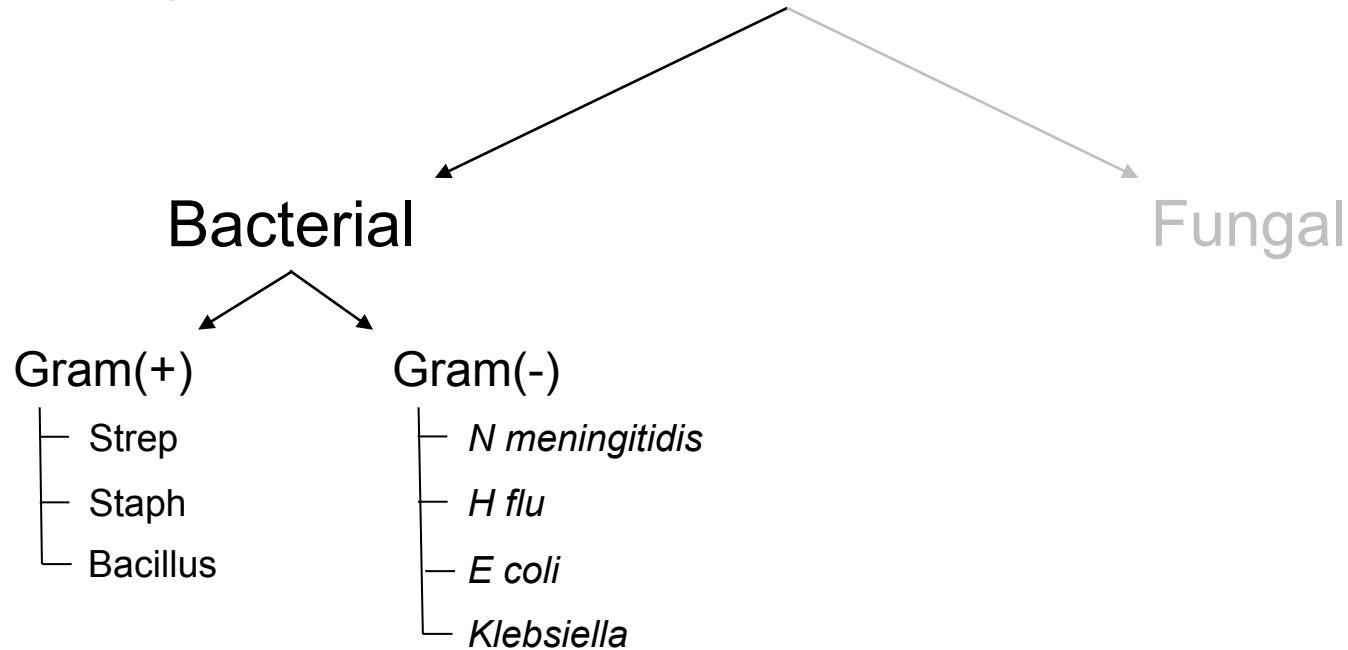

Endogenous Endophthalmitis



What are the five classic clinical scenarios associated with endogenous endophthalmitis?

- ?
- ?
- ?
- ?
- ?

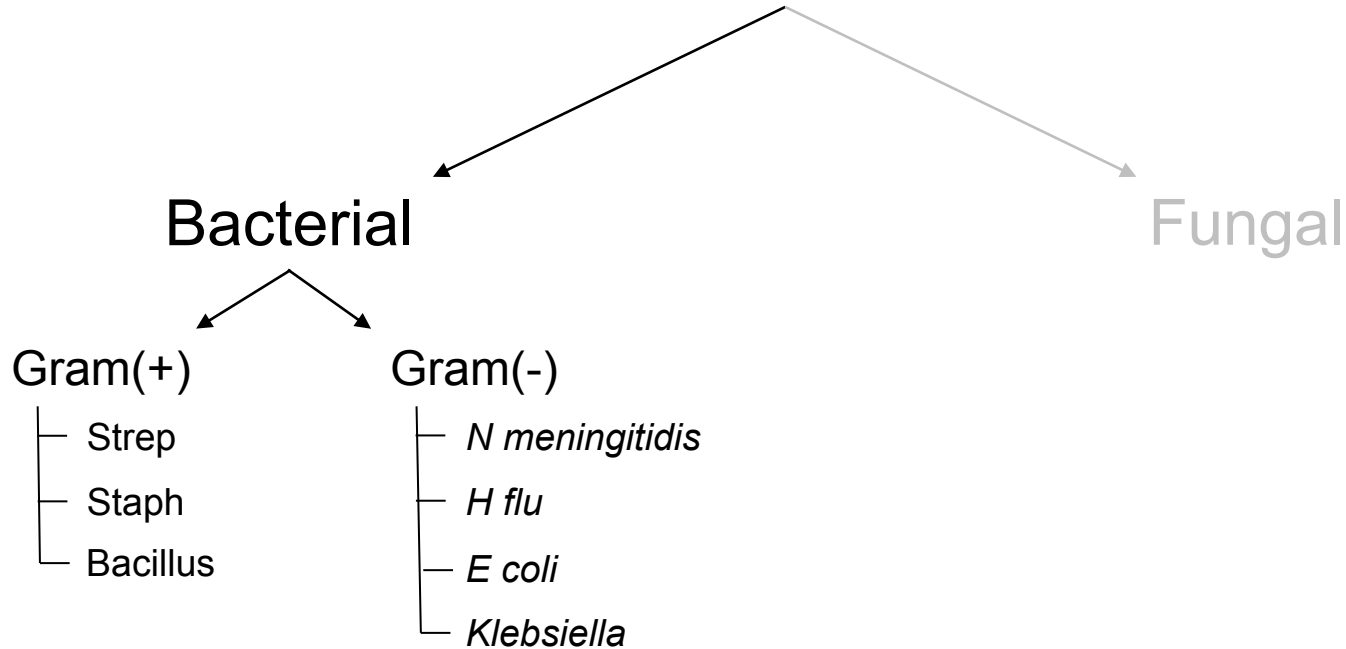
Endogenous Endophthalmitis



What are the five classic clinical scenarios associated with endogenous endophthalmitis?

- Endocarditis
- Skin infection
- IVDU
- Liver abscess
- UTI

Endogenous Endophthalmitis

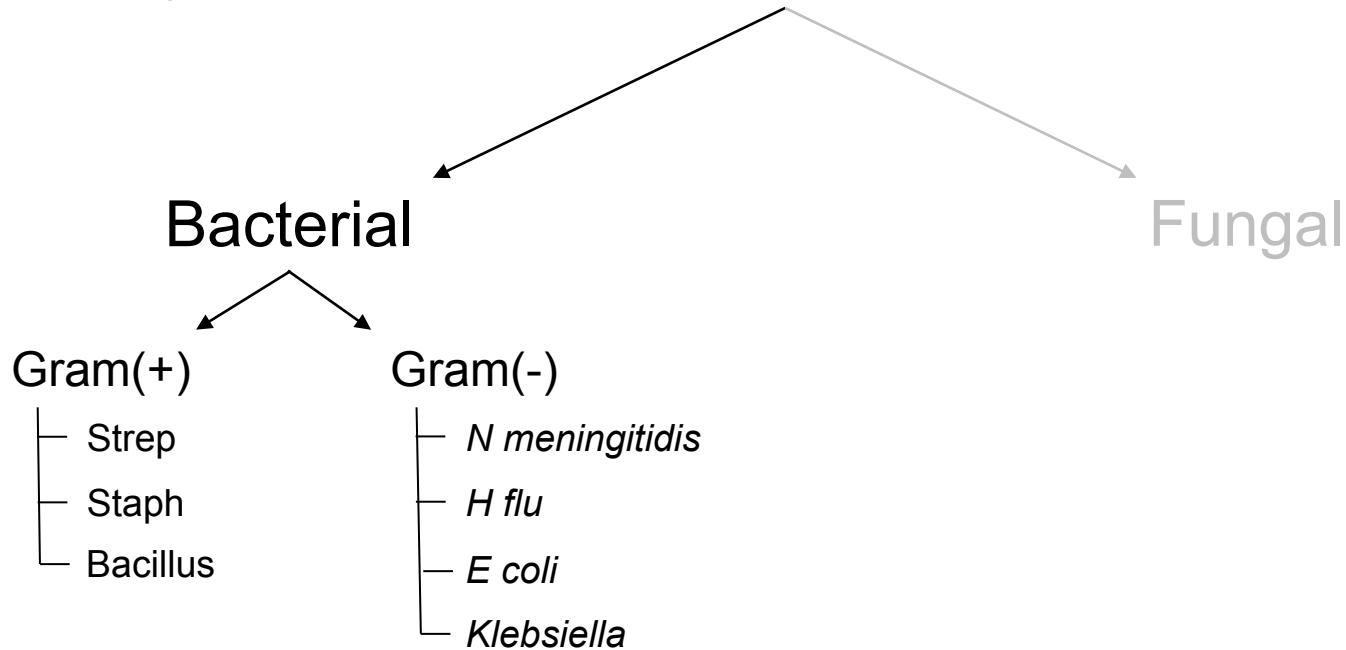


What are the five classic clinical scenarios associated with endogenous endophthalmitis?

Which bacterial cause above is classically associated with each?

- Endocarditis?
- Skin infection
- IVDU
- Liver abscess
- UTI

Endogenous Endophthalmitis



What are the five classic clinical scenarios associated with endogenous endophthalmitis?

Which bacterial cause above is classically associated with each?

--Endocarditis? *Strep*

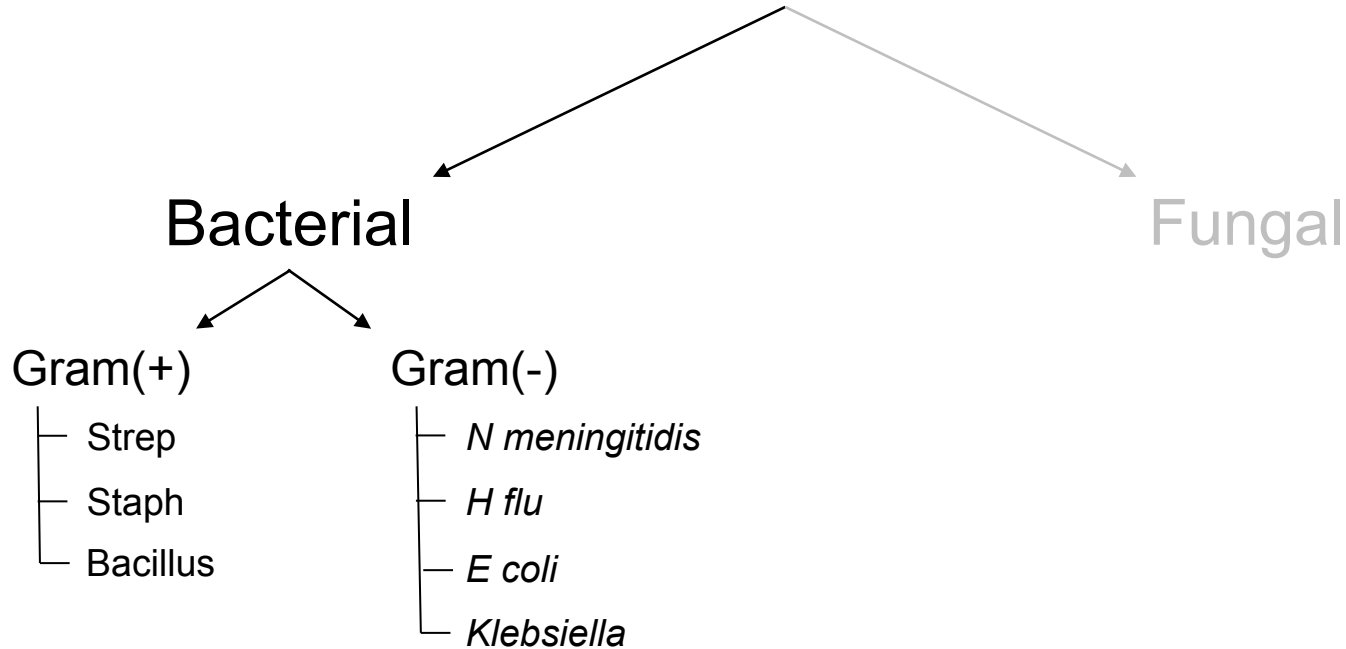
--Skin infection

--IVDU

--Liver abscess

--UTI

Endogenous Endophthalmitis



What are the five classic clinical scenarios associated with endogenous endophthalmitis?

Which bacterial cause above is classically associated with each?

--Endocarditis? *Strep*

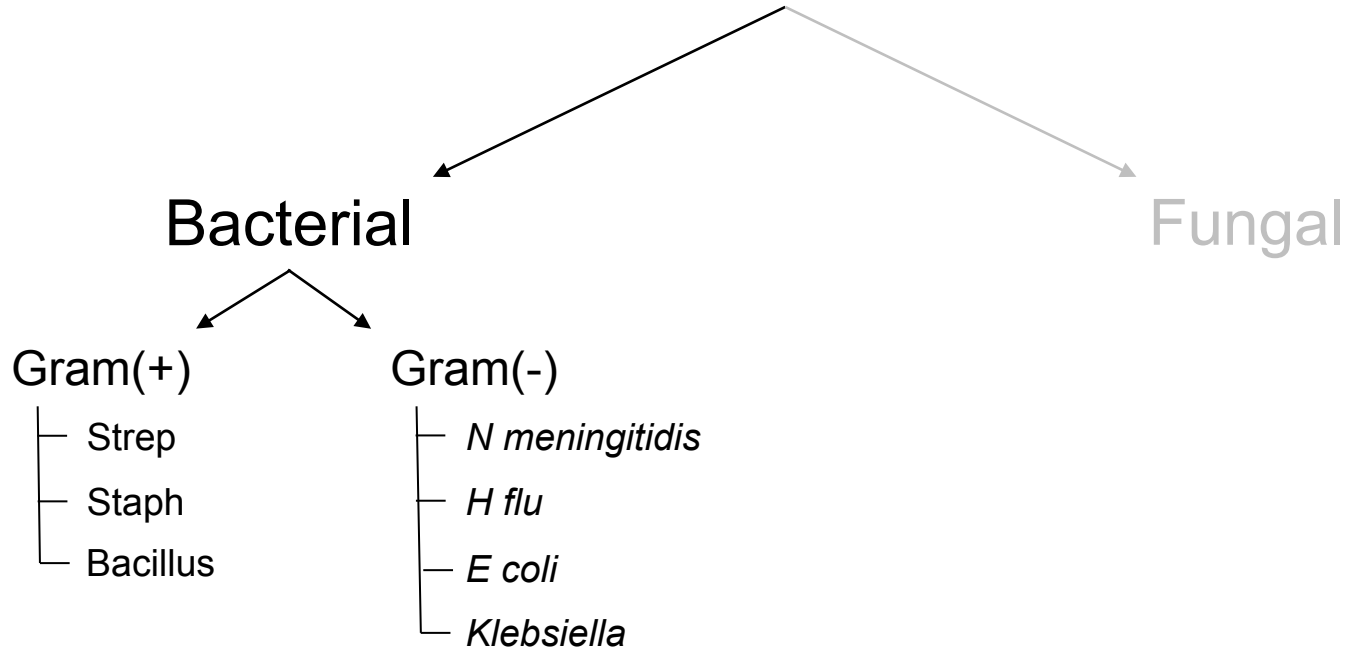
--Skin infection?

--IVDU

--Liver abscess

--UTI

Endogenous Endophthalmitis



What are the five classic clinical scenarios associated with endogenous endophthalmitis?

Which bacterial cause above is classically associated with each?

--Endocarditis? *Strep*

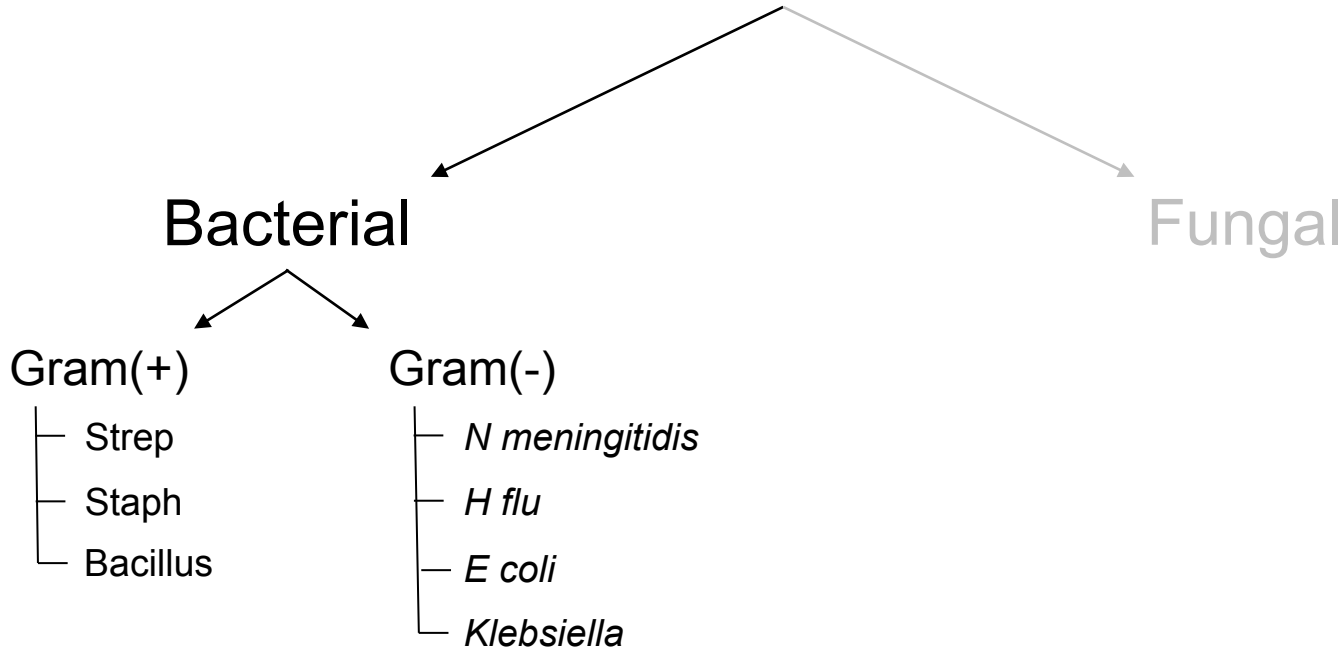

--Skin infection? *Staph*

--IVDU

--Liver abscess

--UTI

Endogenous Endophthalmitis



What are the five classic clinical scenarios associated with endogenous endophthalmitis?

Which bacterial cause above is classically associated with each?

--Endocarditis? *Strep*

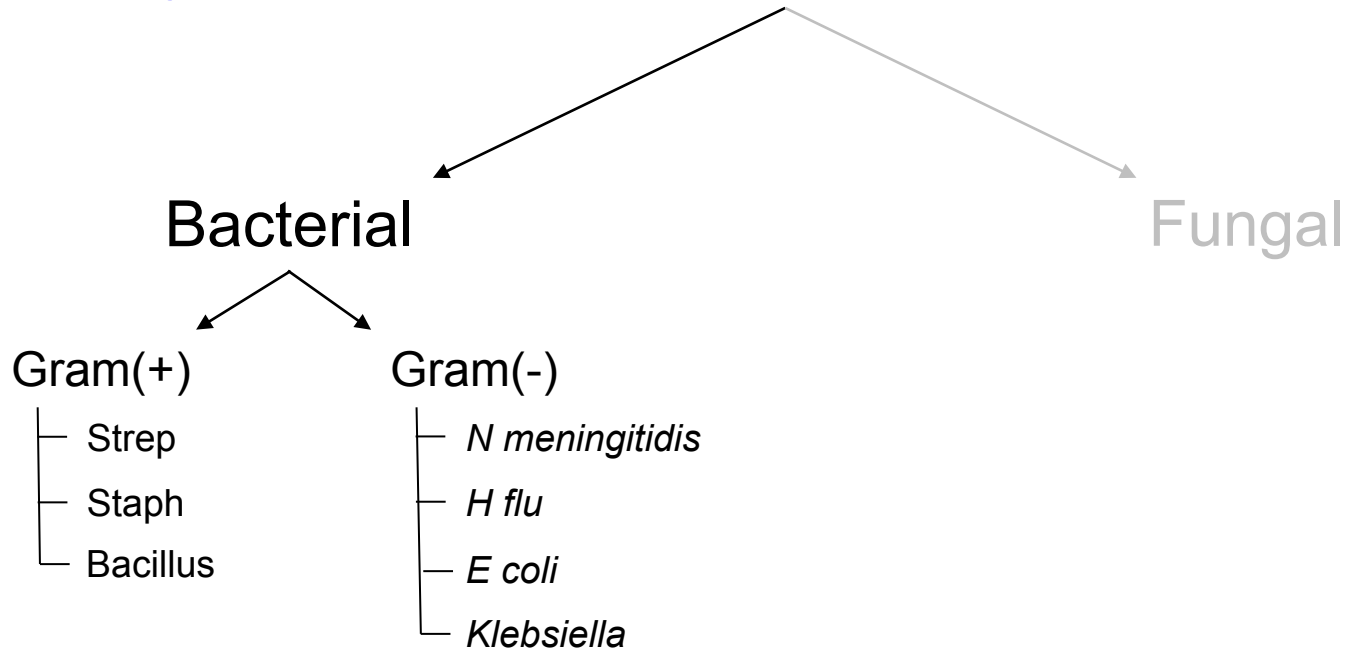

--Skin infection? *Staph*

--IVDU?

--Liver abscess

--UTI

Endogenous Endophthalmitis



What are the five classic clinical scenarios associated with endogenous endophthalmitis?

Which bacterial cause above is classically associated with each?

--Endocarditis? *Strep*

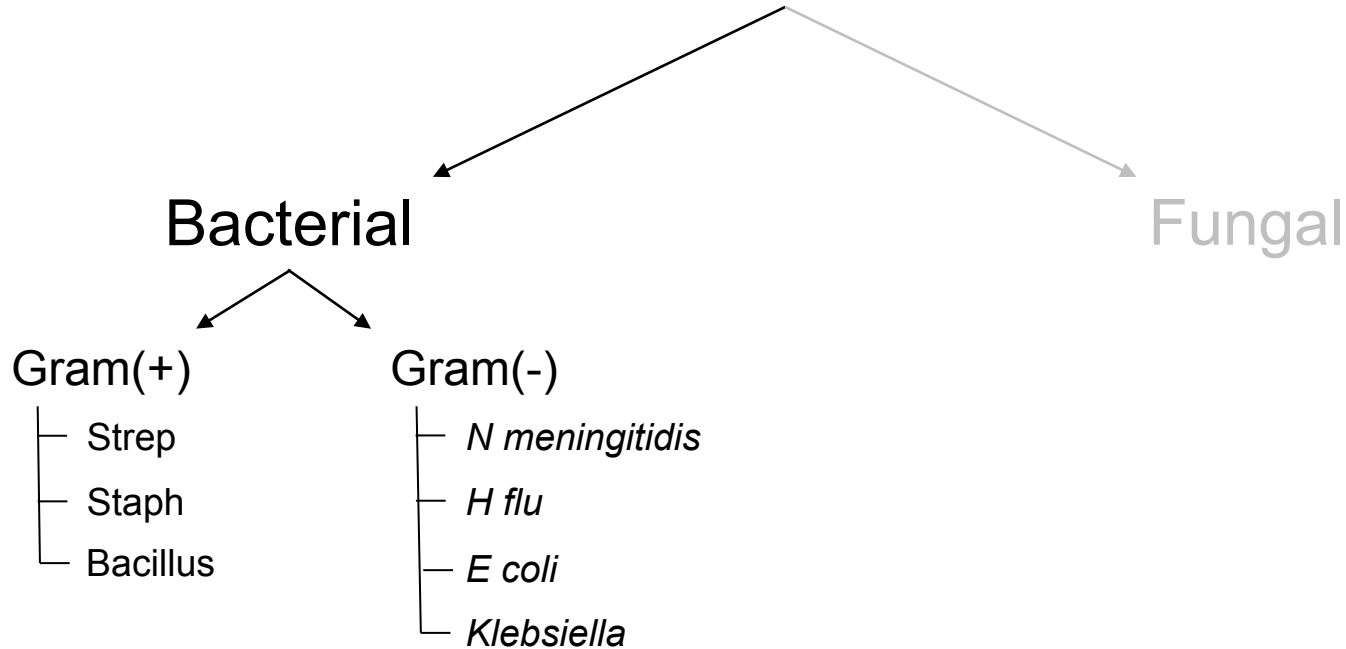
--Skin infection? *Staph*

--IVDU? *Bacillus*

--Liver abscess

--UTI

Endogenous Endophthalmitis



What are the five classic clinical scenarios associated with endogenous endophthalmitis?

Which bacterial cause above is classically associated with each?

--Endocarditis? *Strep*

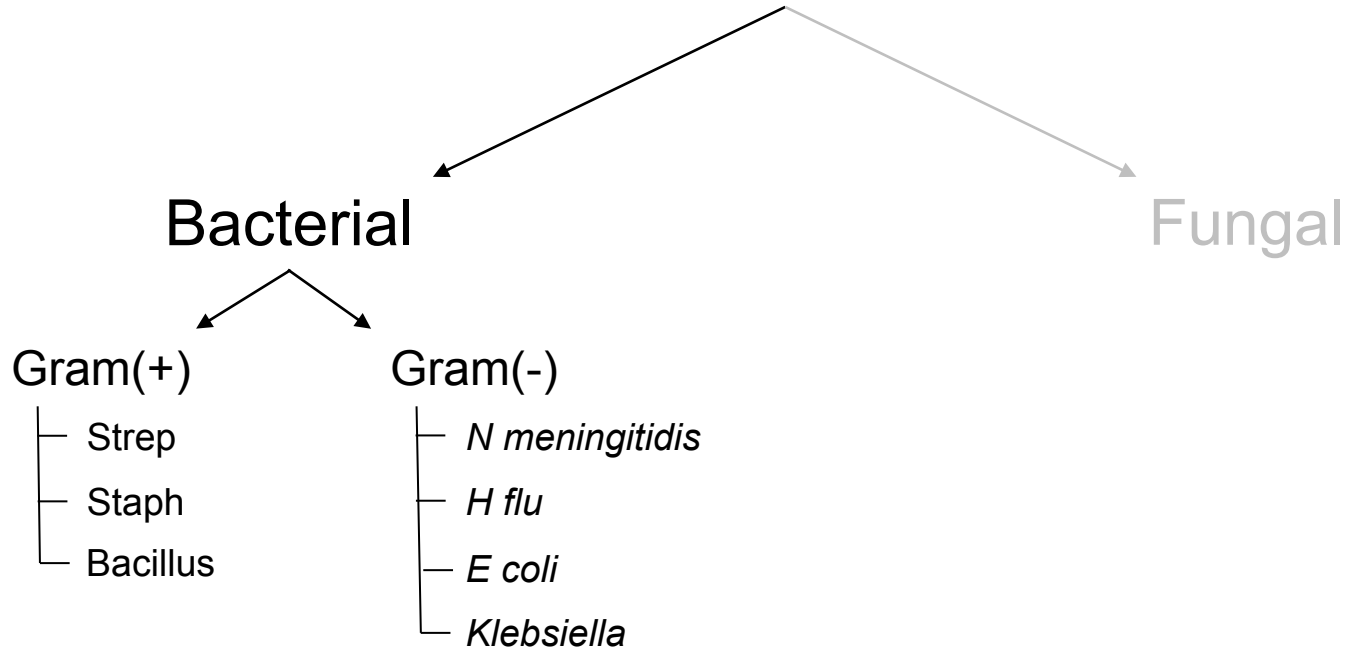
--Skin infection? *Staph*

--IVDU? *Bacillus*

--Liver abscess?

--UTI

Endogenous Endophthalmitis

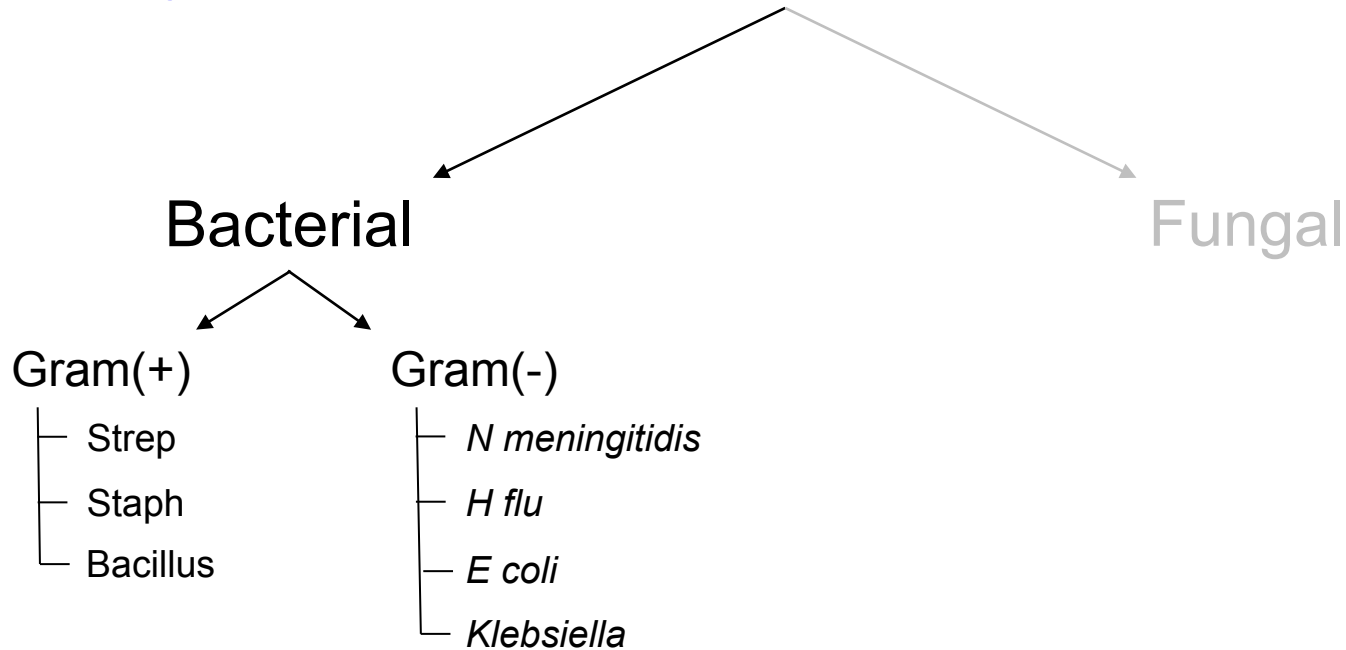



What are the five classic clinical scenarios associated with endogenous endophthalmitis?

Which bacterial cause above is classically associated with each?

- Endocarditis? *Strep*
- Skin infection? *Staph*
- IVDU? *Bacillus*
- Liver abscess? *Klebsiella*
- UTI

Endogenous Endophthalmitis

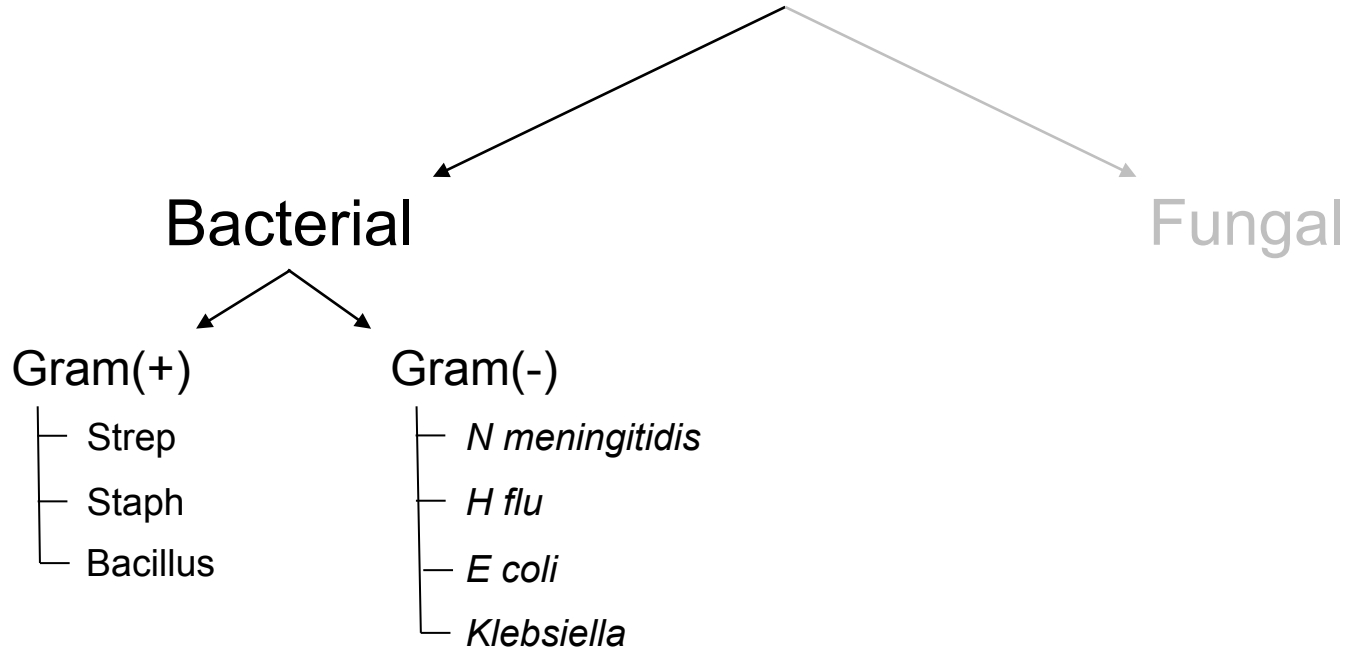


What are the five classic clinical scenarios associated with endogenous endophthalmitis?

Which bacterial cause above is classically associated with each?

- Endocarditis? *Strep*
- Skin infection? *Staph*
- IVDU? *Bacillus*
- Liver abscess? *Klebsiella*
- UTI?

Endogenous Endophthalmitis

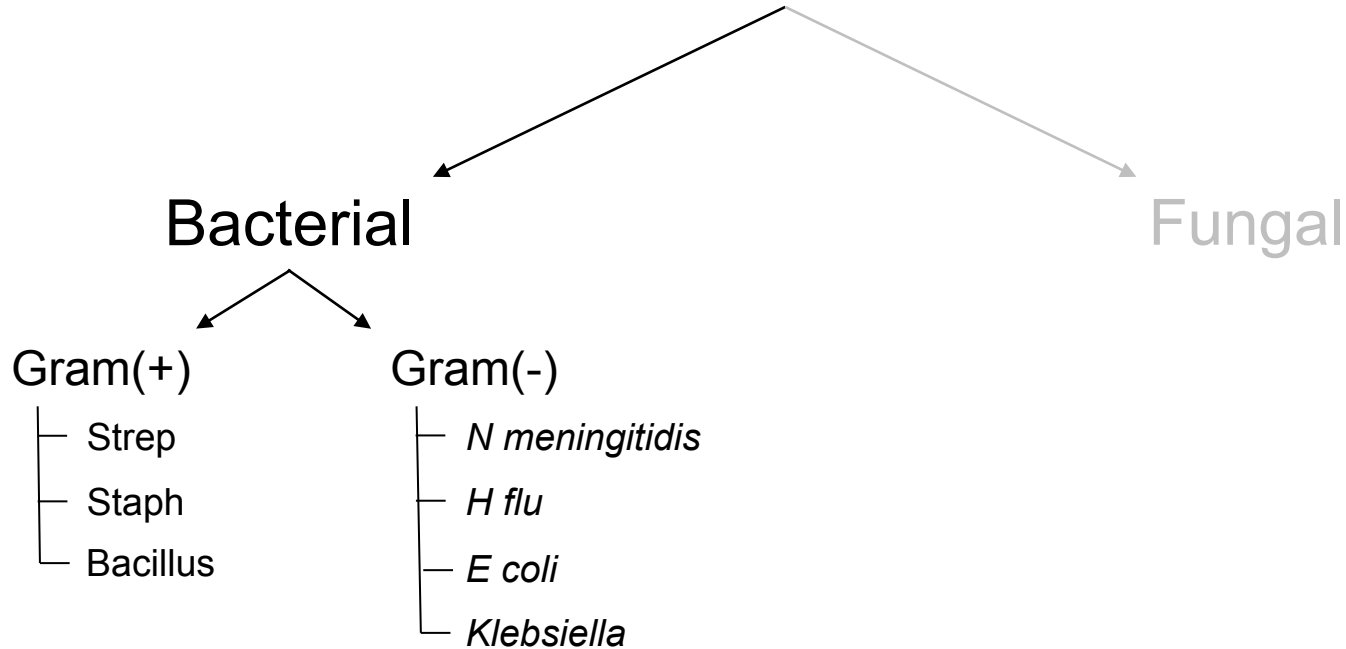


What are the five classic clinical scenarios associated with endogenous endophthalmitis?

Which bacterial cause above is classically associated with each?

- Endocarditis? *Strep*
- Skin infection? *Staph*
- IVDU? *Bacillus*
- Liver abscess? *Klebsiella*
- UTI? *E coli*

Endogenous Endophthalmitis



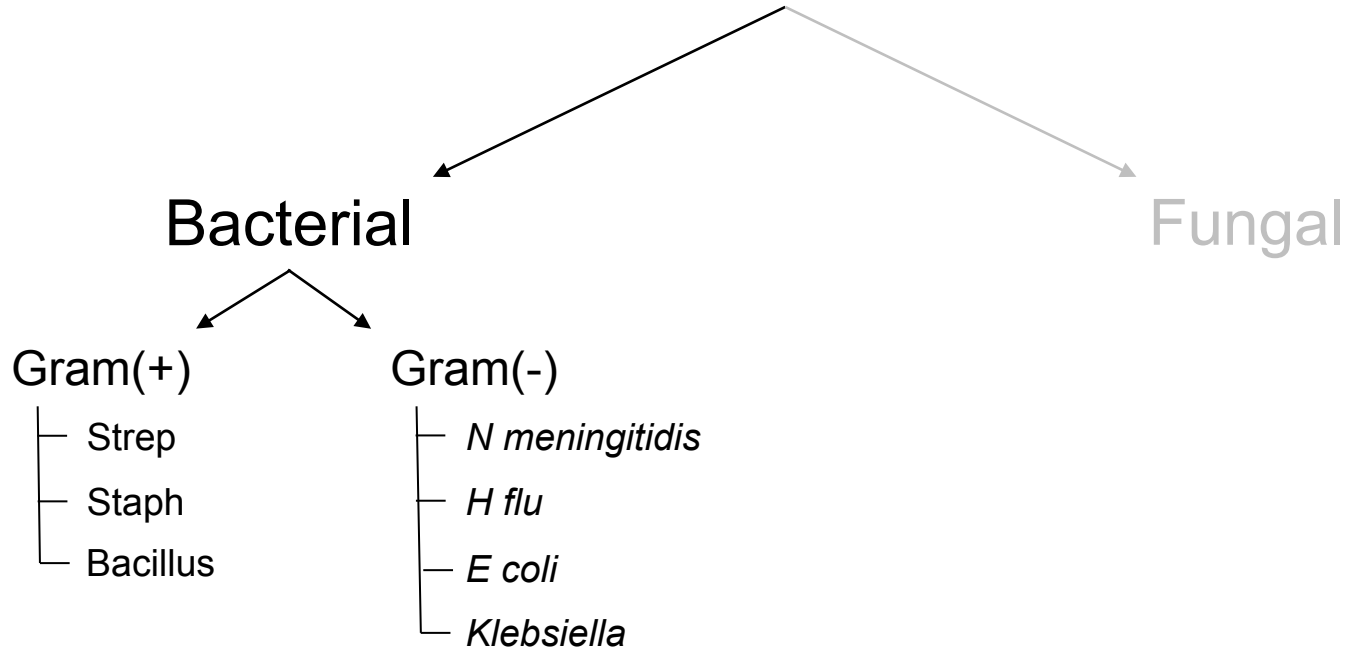
What are the five classic clinical scenarios associated with endogenous endophthalmitis?

Which bacterial cause above is classically associated with each?

- Endocarditis? *Strep*
- Skin infection? *Staph*
- IVDU? *Bacillus*
- Liver abscess? *Klebsiella*
- UTI? *E coli*

Which is the most common in North America?

Endogenous Endophthalmitis



What are the five classic clinical scenarios associated with endogenous endophthalmitis?

Which bacterial cause above is classically associated with each?

--**Endocarditis?** *Strep*

--Skin infection? *Staph*

--IVDU? *Bacillus*

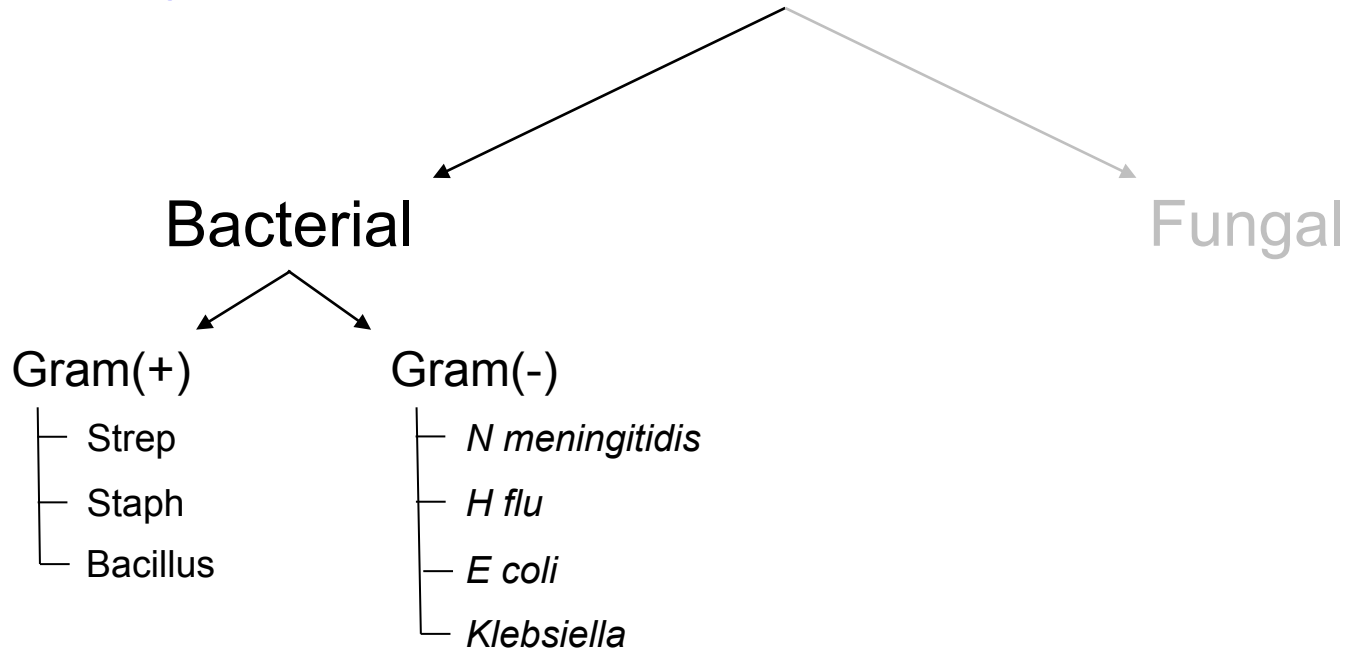

--Liver abscess? *Klebsiella*

--UTI? *E coli*

Which is the most common in North America?

Endocarditis accounts for % here

Endogenous Endophthalmitis



What are the five classic clinical scenarios associated with endogenous endophthalmitis?

Which bacterial cause above is classically associated with each?

--**Endocarditis?** *Strep*

--Skin infection? *Staph*

--IVDU? *Bacillus*

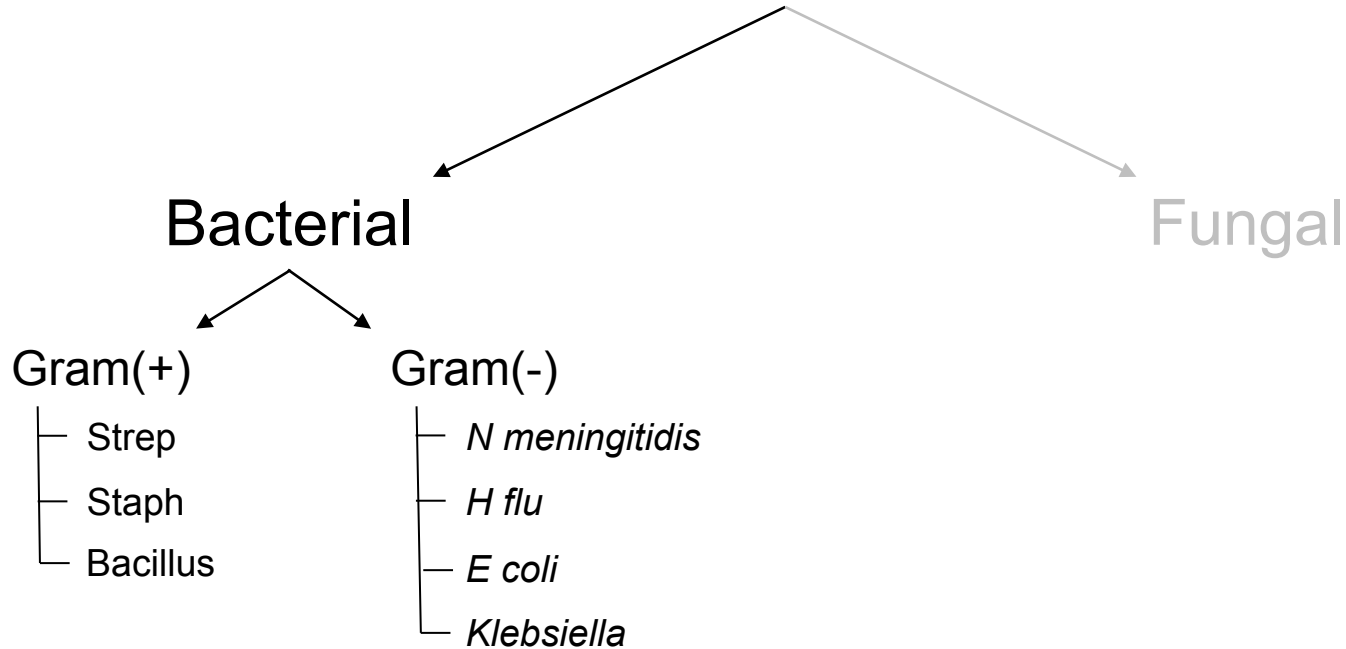
--Liver abscess? *Klebsiella*

--UTI? *E coli*

Which is the most common in North America?

Endocarditis accounts for 40% here

Endogenous Endophthalmitis



What are the five classic clinical scenarios associated with endogenous endophthalmitis?

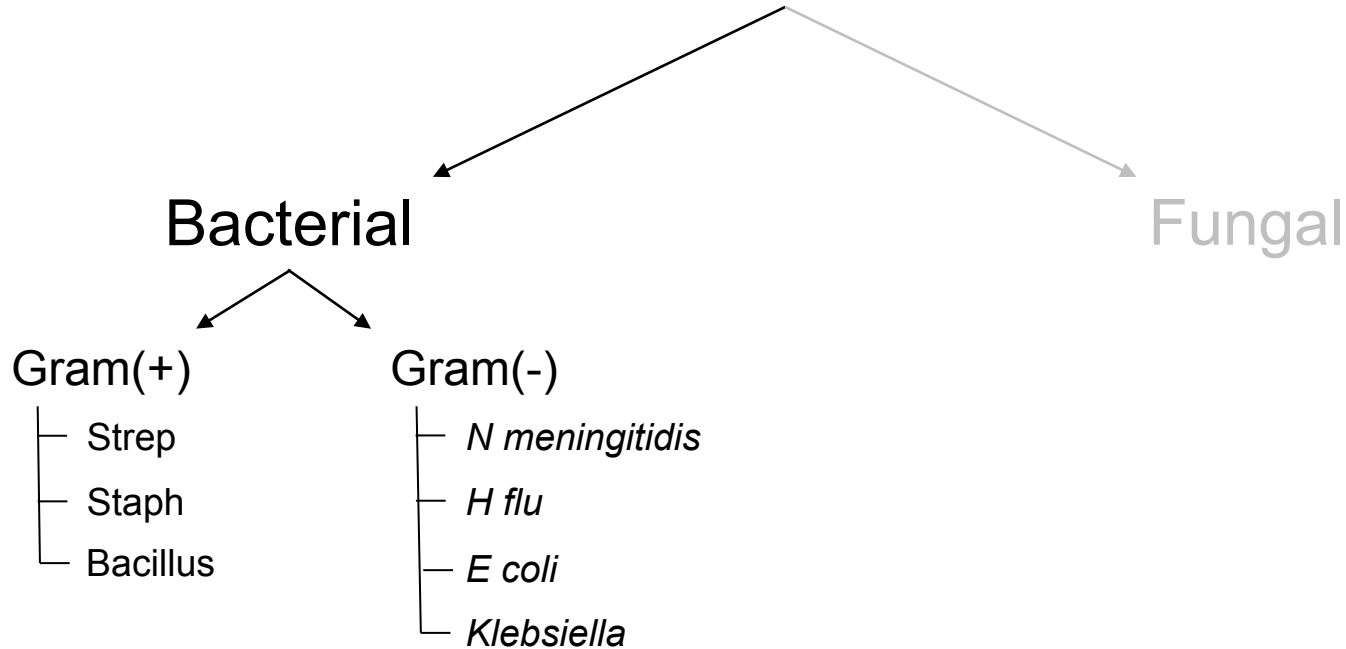
Which bacterial cause above is classically associated with each?

- Endocarditis? *Strep*
- Skin infection? *Staph*
- IVDU? *Bacillus*
- Liver abscess? *Klebsiella*
- UTI? *E coli*

*Which is the most common in North America?
Endocarditis accounts for 40% here*

Which cause is in second place here?

Endogenous Endophthalmitis



What are the five classic clinical scenarios associated with endogenous endophthalmitis?

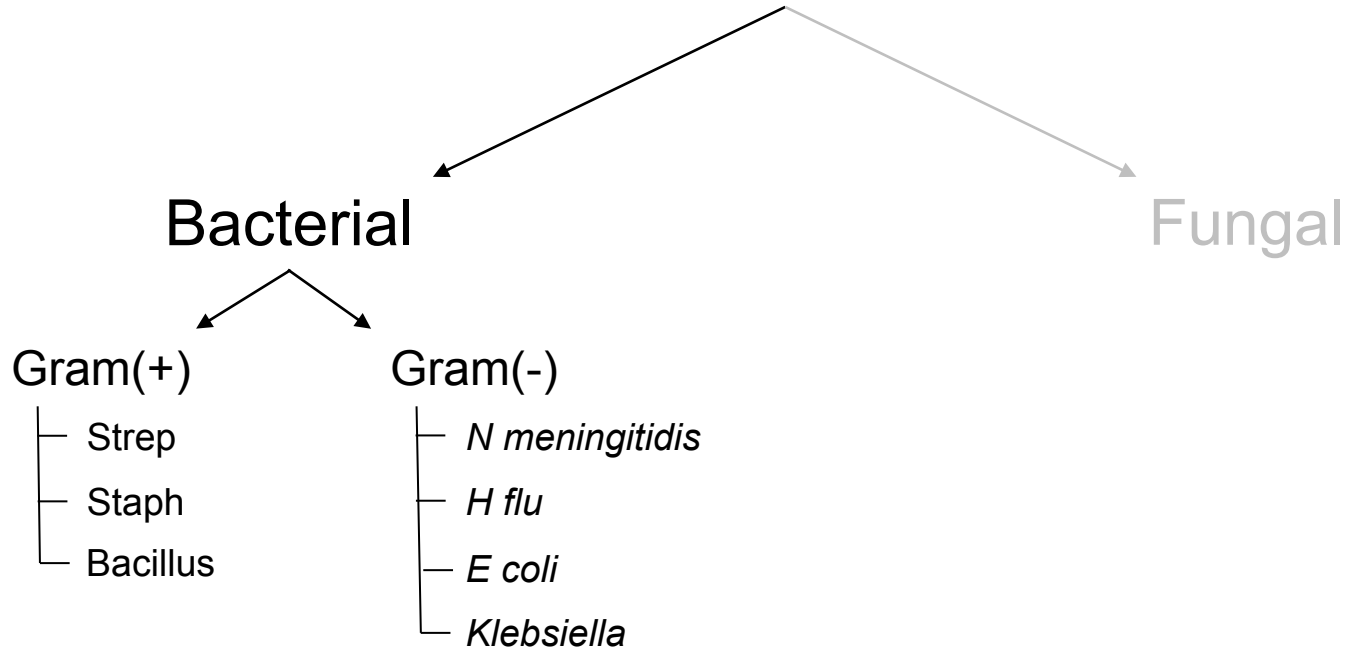
Which bacterial cause above is classically associated with each?

- Endocarditis? *Strep*
- Skin infection? *Staph*
- IVDU? *Bacillus*
- Liver abscess? *Klebsiella*
- UTI? *E coli***

Which is the most common in North America?
Endocarditis accounts for 40% here

Which cause is in second place here?
UTI, accounting for about % of cases

Endogenous Endophthalmitis



What are the five classic clinical scenarios associated with endogenous endophthalmitis?

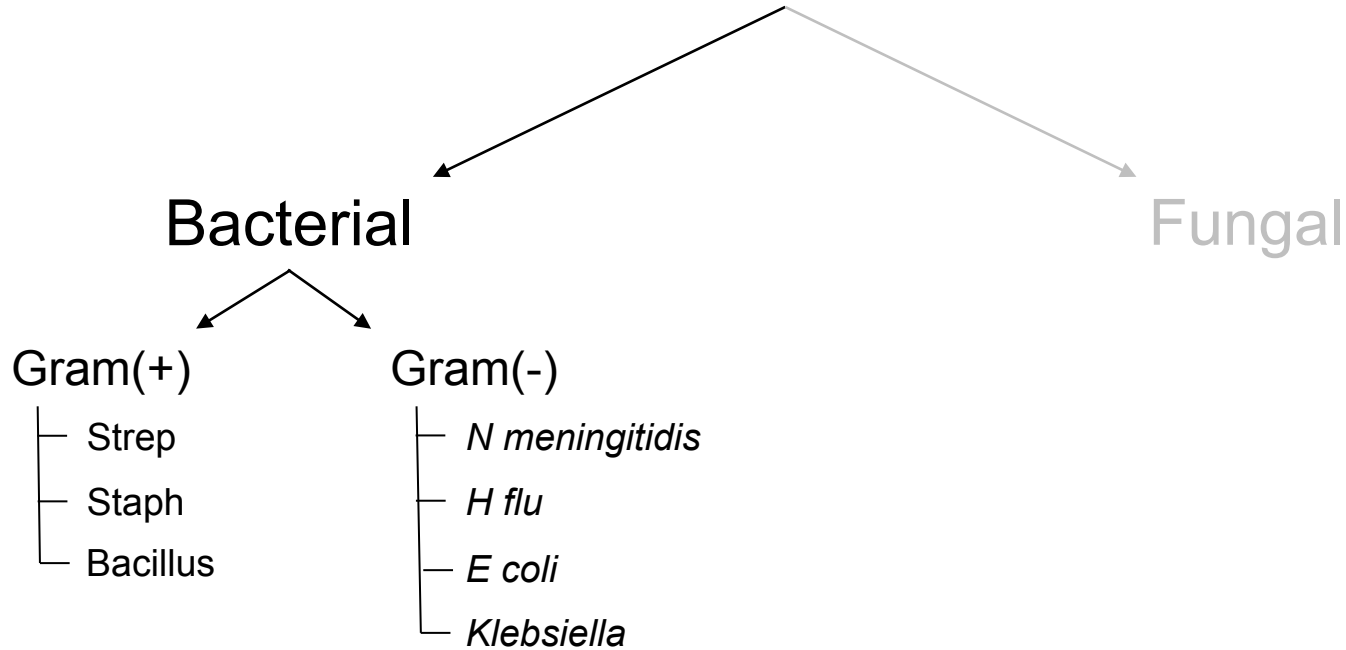
Which bacterial cause above is classically associated with each?

- Endocarditis? *Strep*
- Skin infection? *Staph*
- IVDU? *Bacillus*
- Liver abscess? *Klebsiella*
- UTI? *E coli***

Which is the most common in North America?
Endocarditis accounts for 40% here

Which cause is in second place here?
UTI, accounting for about 1/3 of cases

Endogenous Endophthalmitis



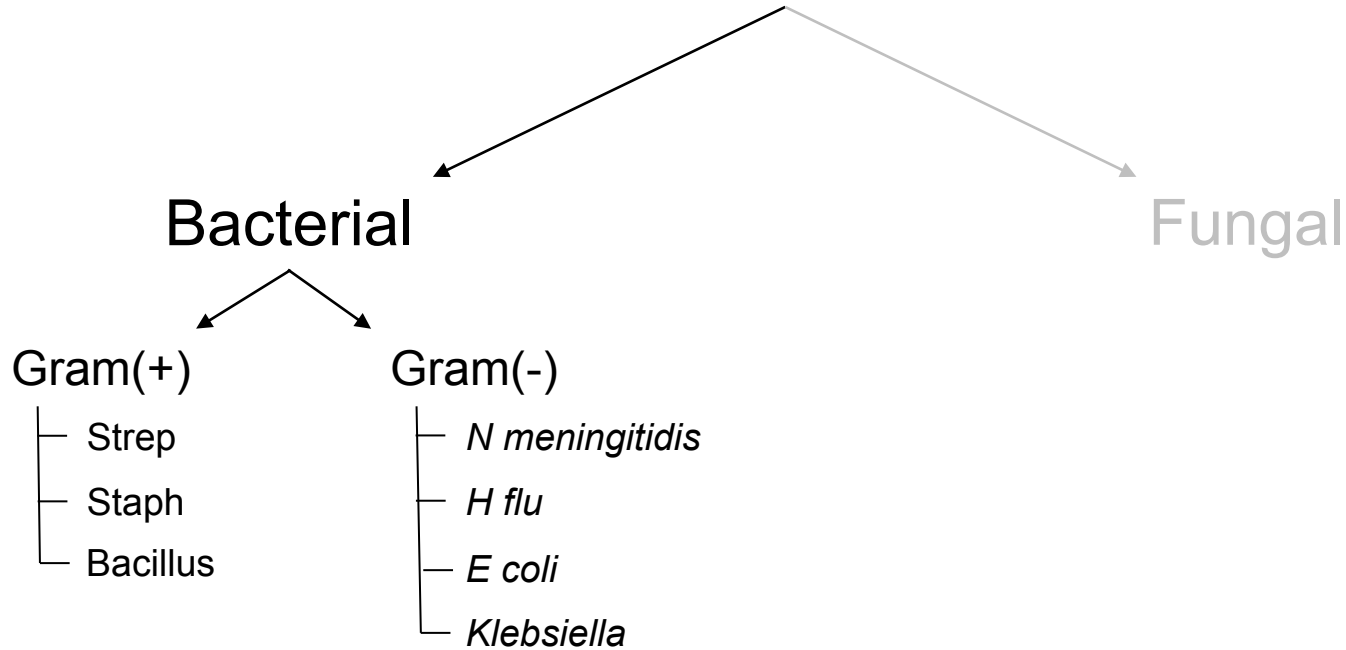
What are the five classic clinical scenarios associated with endogenous endophthalmitis?

Which bacterial cause above is classically associated with each?

- Endocarditis? *Strep*
- Skin infection? *Staph*
- IVDU? *Bacillus*
- Liver abscess? *Klebsiella*
- UTI? *E coli*

Which is the most common in **Asia**?

Endogenous Endophthalmitis



What are the five classic clinical scenarios associated with endogenous endophthalmitis?

Which bacterial cause above is classically associated with each?

--Endocarditis? *Strep*

--Skin infection? *Staph*

--IVDU? *Bacillus*

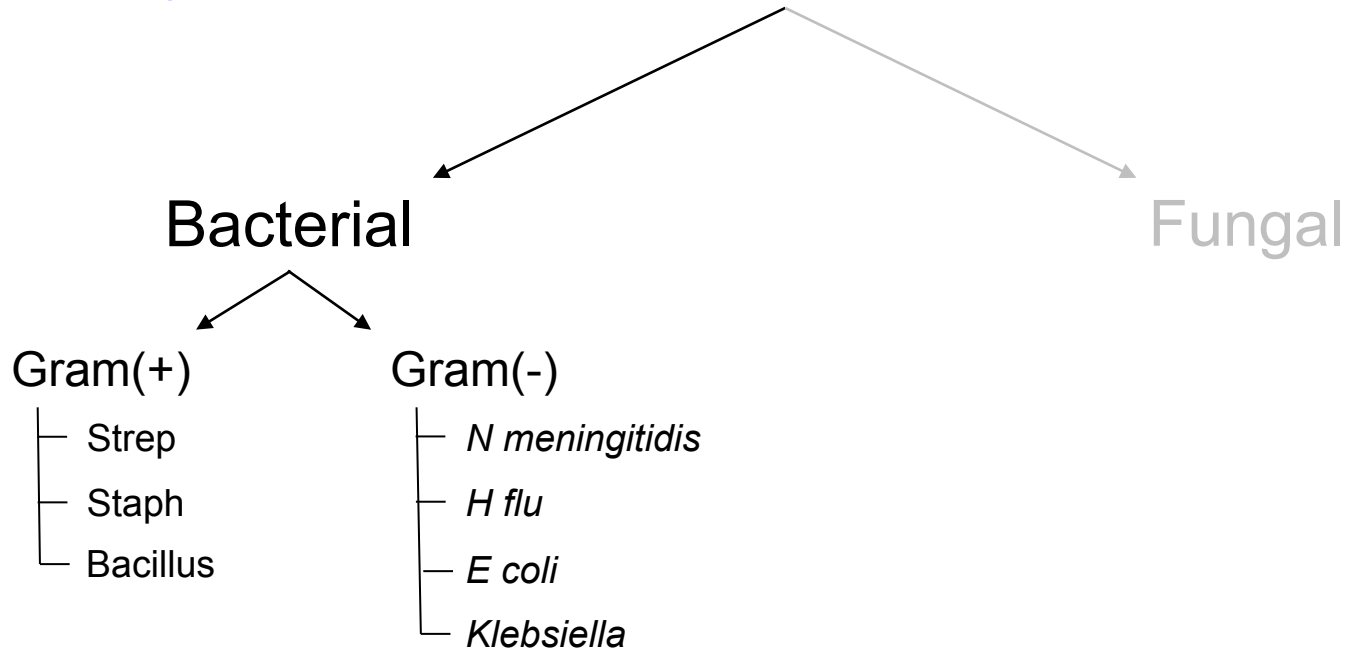
--**Liver abscess? *Klebsiella***

--UTI? *E coli*

Which is the most common in **Asia**?

% of endogenous endophthalmitis there is associated with *Klebsiella* liver abscesses!

Endogenous Endophthalmitis



What are the five classic clinical scenarios associated with endogenous endophthalmitis?

Which bacterial cause above is classically associated with each?

--Endocarditis? *Strep*

--Skin infection? *Staph*

--IVDU? *Bacillus*

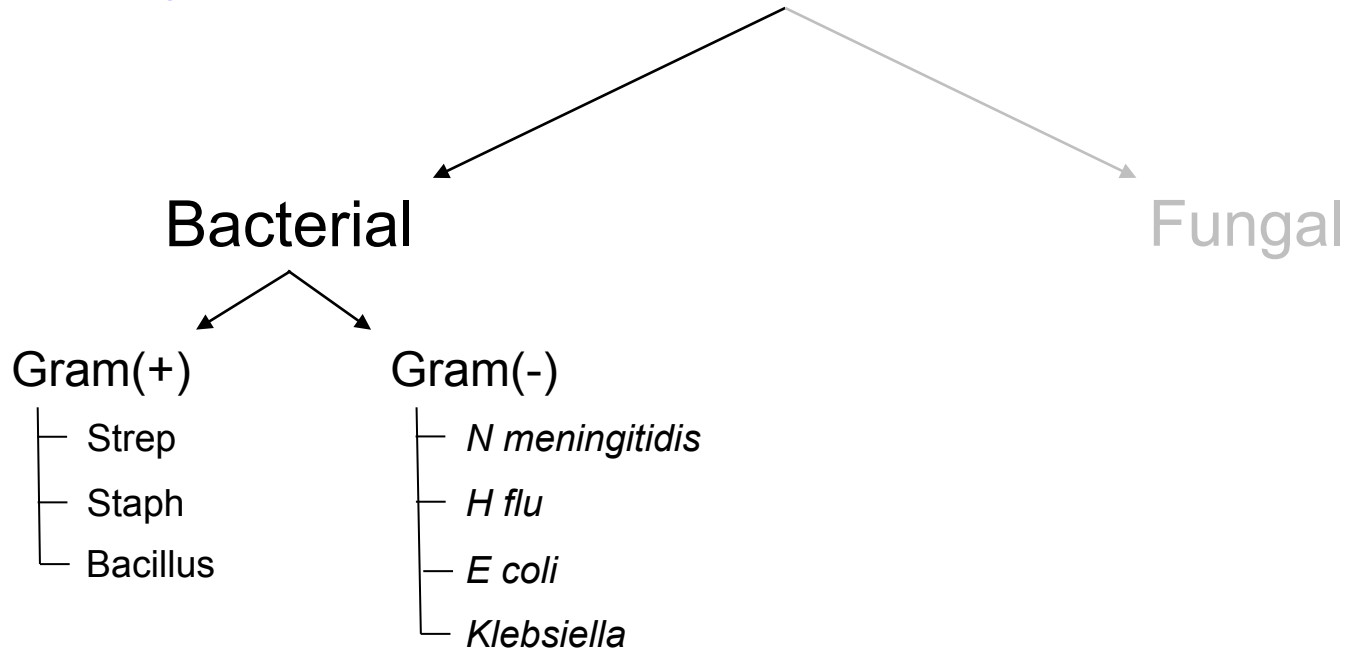
--**Liver abscess? *Klebsiella***

--UTI? *E coli*

Which is the most common in **Asia**?

60% of endogenous endophthalmitis there is associated with *Klebsiella* liver abscesses!

Endogenous Endophthalmitis



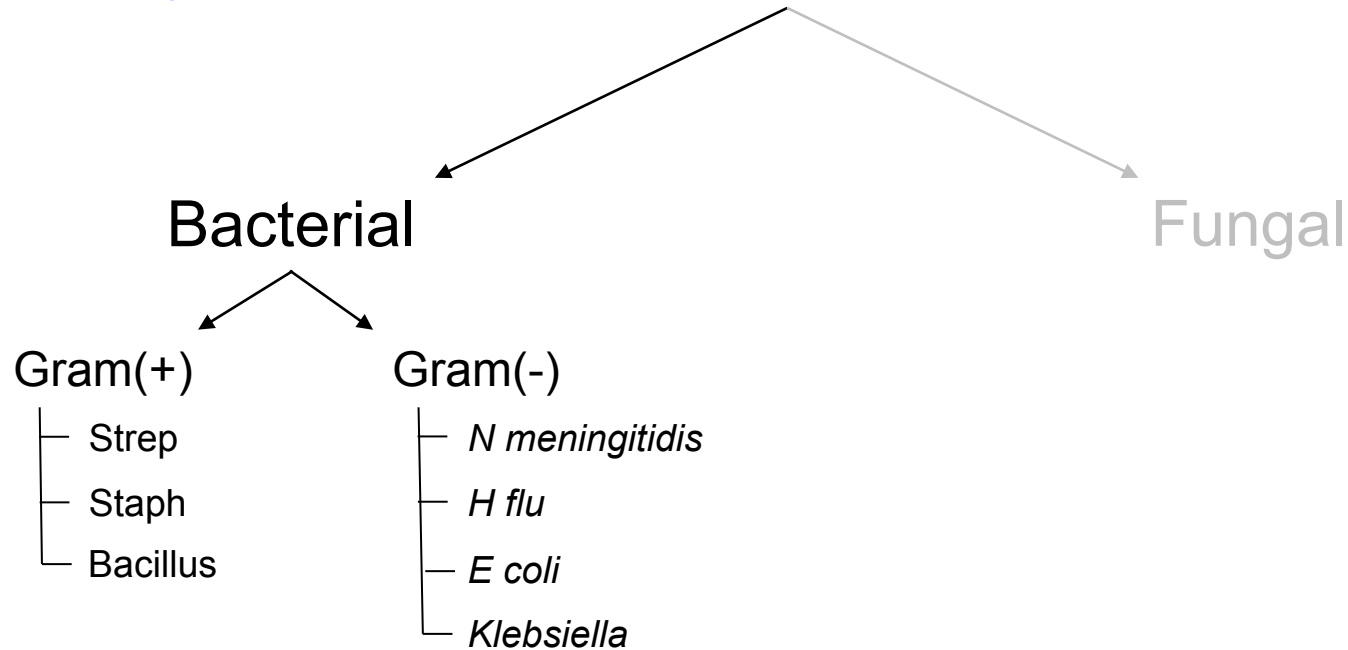

What are the five classic clinical scenarios associated with endogenous endophthalmitis?

Which bacterial cause above is classically associated with each?

- Endocarditis? *Strep*
- Skin infection? *Staph*
- IVDU? *Bacillus*
- Liver abscess? *Klebsiella*
- UTI? *E coli*

How is endogenous bacterial endophthalmitis treated?

Endogenous Endophthalmitis



What are the five classic clinical scenarios associated with endogenous endophthalmitis?

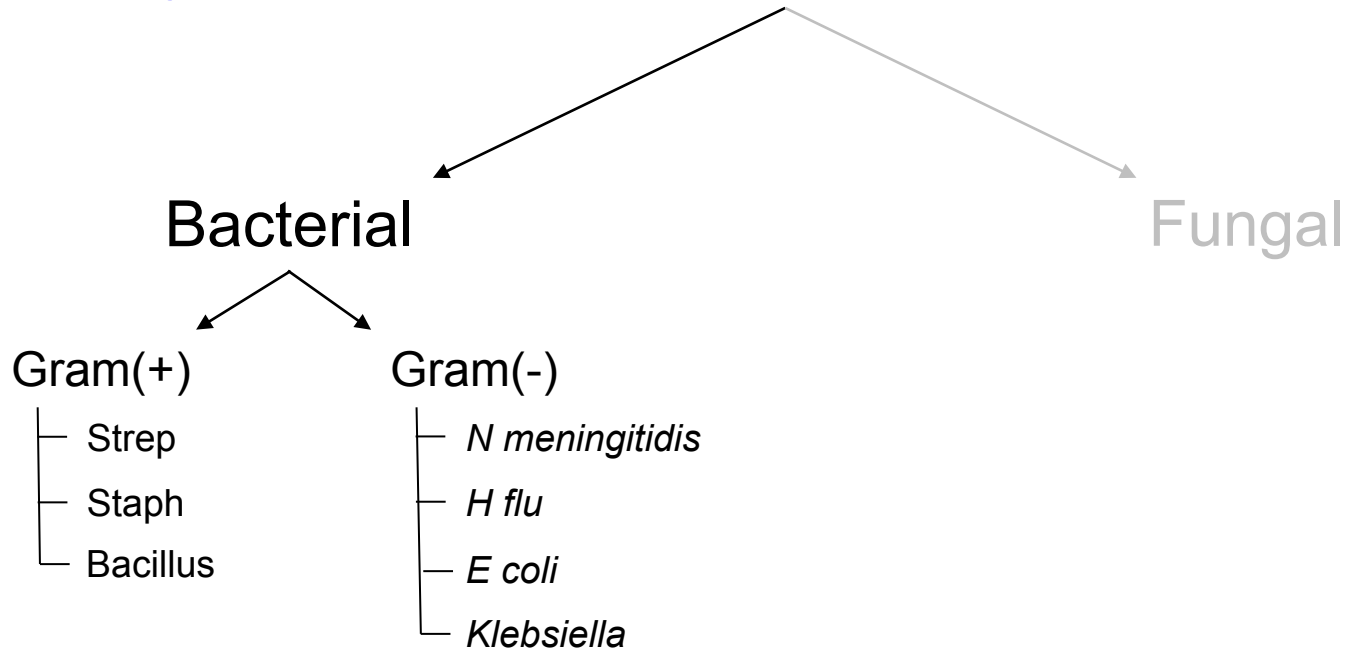
Which bacterial cause above is classically associated with each?

- Endocarditis? *Strep*
- Skin infection? *Staph*
- IVDU? *Bacillus*
- Liver abscess? *Klebsiella*
- UTI? *E coli*

How is endogenous bacterial endophthalmitis treated?

With vitrectomy and intravitreal antibiotics. Consideration should be given to IV abx as well.

Endogenous Endophthalmitis



What are the five classic clinical scenarios associated with endogenous endophthalmitis?

Which bacterial cause above is classically associated with each?

- Endocarditis? *Strep*
- Skin infection? *Staph*
- IVDU? *Bacillus*
- Liver abscess? *Klebsiella*
- UTI? *E coli*

How is endogenous bacterial endophthalmitis treated?


With vitrectomy and intravitreal antibiotics. Consideration should be given to IV abx as well.

Additionally, the extraocular nidus of infection should be managed by the appropriate service.

Endogenous Endophthalmitis

Bacterial

Fungal



*How does the presentation of endogenous **fungal** endophthalmitis differ from the bacterial form?*

Endogenous Endophthalmitis

Bacterial

Fungal




*How does the presentation of endogenous **fungal** endophthalmitis differ from the bacterial form?*
The onset of symptoms (pain, redness decreased vision) is generally more insidious

Endogenous Endophthalmitis

Bacterial

Fungal



*How does the presentation of endogenous **fungal** endophthalmitis differ from the bacterial form?*
The onset of symptoms (pain, redness decreased vision) is generally more insidious

What ocular signs are typically found?

Endogenous Endophthalmitis

Bacterial

Fungal

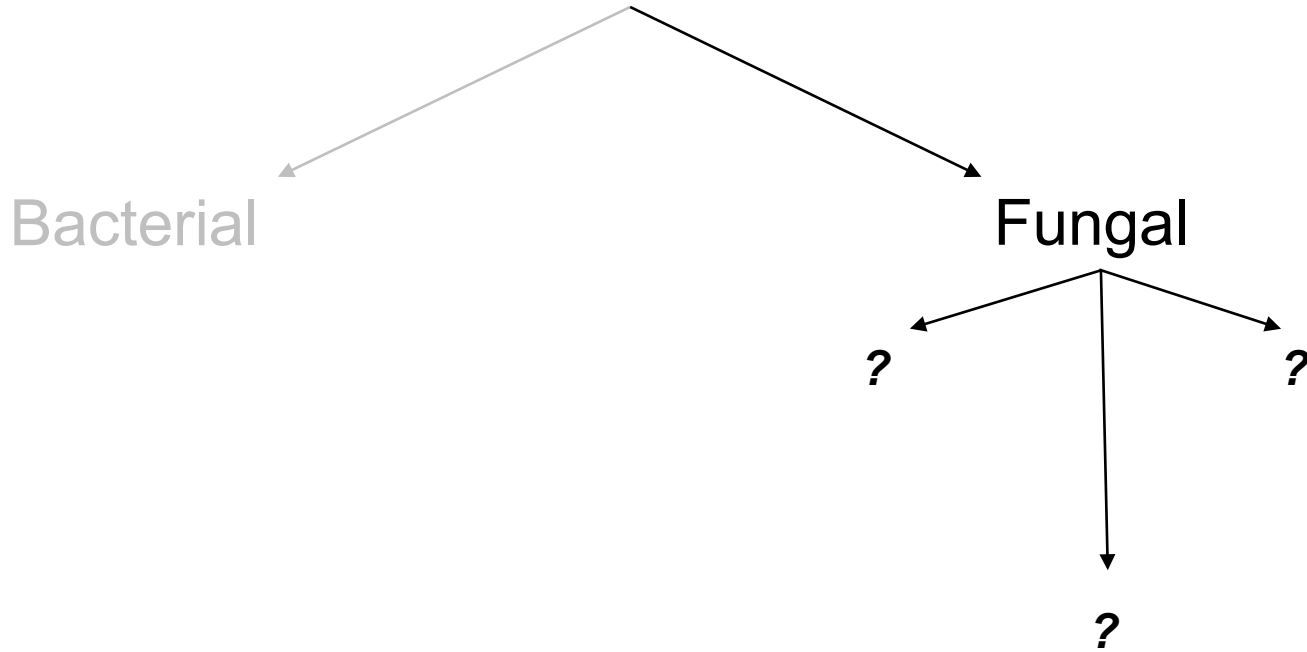



*How does the presentation of endogenous **fungal** endophthalmitis differ from the bacterial form?*
The onset of symptoms (pain, redness decreased vision) is generally more insidious

What ocular signs are typically found?

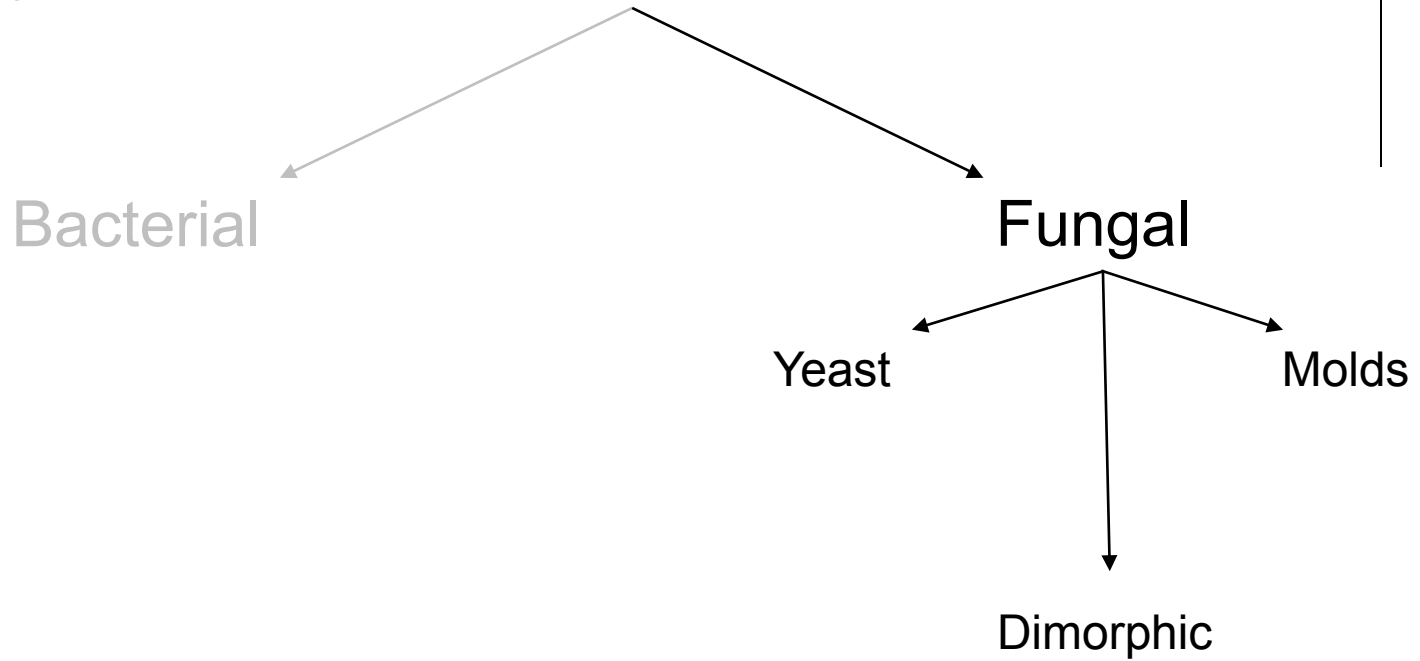
Endogenous fungal endophthalmitis generally progresses in a particular fashion. First, isolated choroidal metastatic lesions appear. With time, these break through Bruch's membrane to involve the retina. Eventually, the bug reaches the vitreous, and (if still unchecked) the anterior segment.

Endogenous Endophthalmitis



Fungi are frequently classified with respect to a basic microbiologic property. What is it?

Endogenous Endophthalmitis



Fungi are frequently classified with respect to a basic microbiologic property. What is it?
Whether they are **yeast**, **molds** or **dimorphic**

Endogenous Endophthalmitis



Bacterial

Fungal

What's the difference between a yeast and a mold?

Yeast

Molds

Dimorphic

*Fungi are frequently classified with respect to a basic microbiologic property. What is it?
Whether they are **yeast, molds** or dimorphic*

Endogenous Endophthalmitis



Bacterial

Fungal

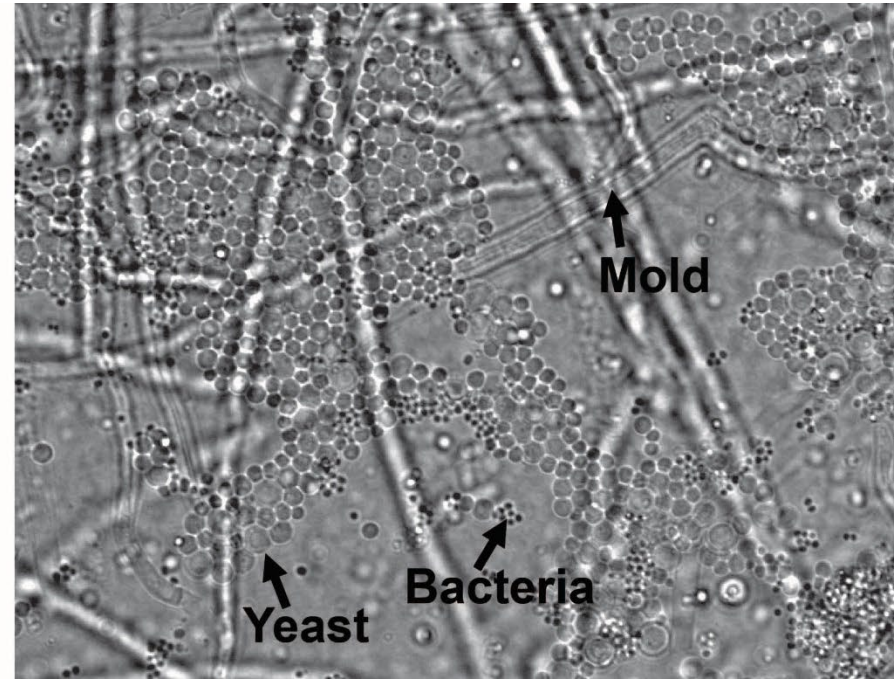
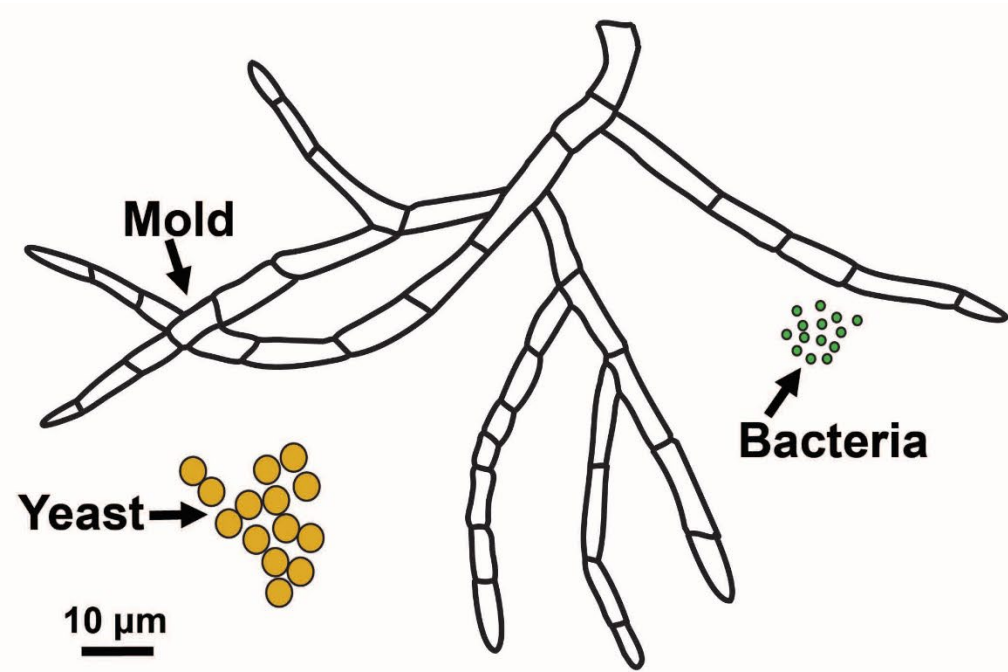

Yeast

Molds

Dimorphic

What's the difference between a yeast and a mold?
Yeasts are fungi that exist mainly as unicellular entities, whereas molds are multicellular organisms organized as structures called **hyphae** (the fancy term for the long, branching filaments molds form as they grow).

Fungi are frequently classified with respect to a basic microbiologic property. What is it?
Whether they are **yeast, molds** or dimorphic



Yeast vs Molds (vs bacteria)

Endogenous Endophthalmitis



Bacterial

Fungal

Yeast

Molds

Dimorphic

What's the difference between a yeast and a mold?
Yeasts are fungi that exist mainly as unicellular entities, whereas molds are multicellular organisms organized as structures called **hyphae** (the fancy term for the long, branching filaments molds form as they grow).

What does it mean to say a fungus is dimorphic?

Fungi are frequently classified with respect to a basic microbiologic property. What is it?
Whether they are yeast, molds or **dimorphic**

Endogenous Endophthalmitis



Bacterial

Fungal

Yeast

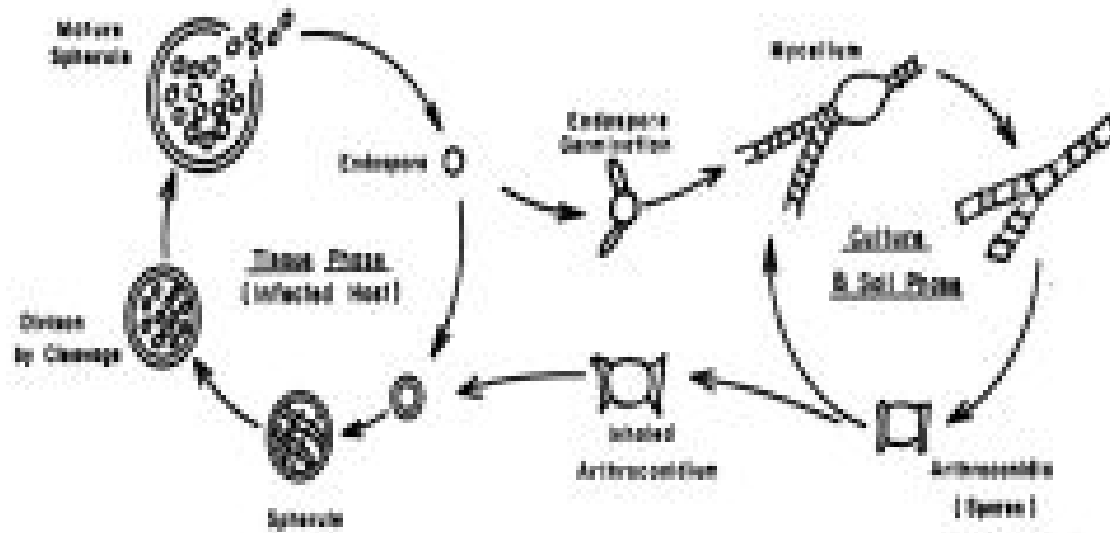

Molds

Dimorphic

What's the difference between a yeast and a mold?
Yeasts are fungi that exist mainly as unicellular entities, whereas molds are multicellular organisms organized as structures called **hyphae** (the fancy term for the long, branching filaments molds form as they grow).

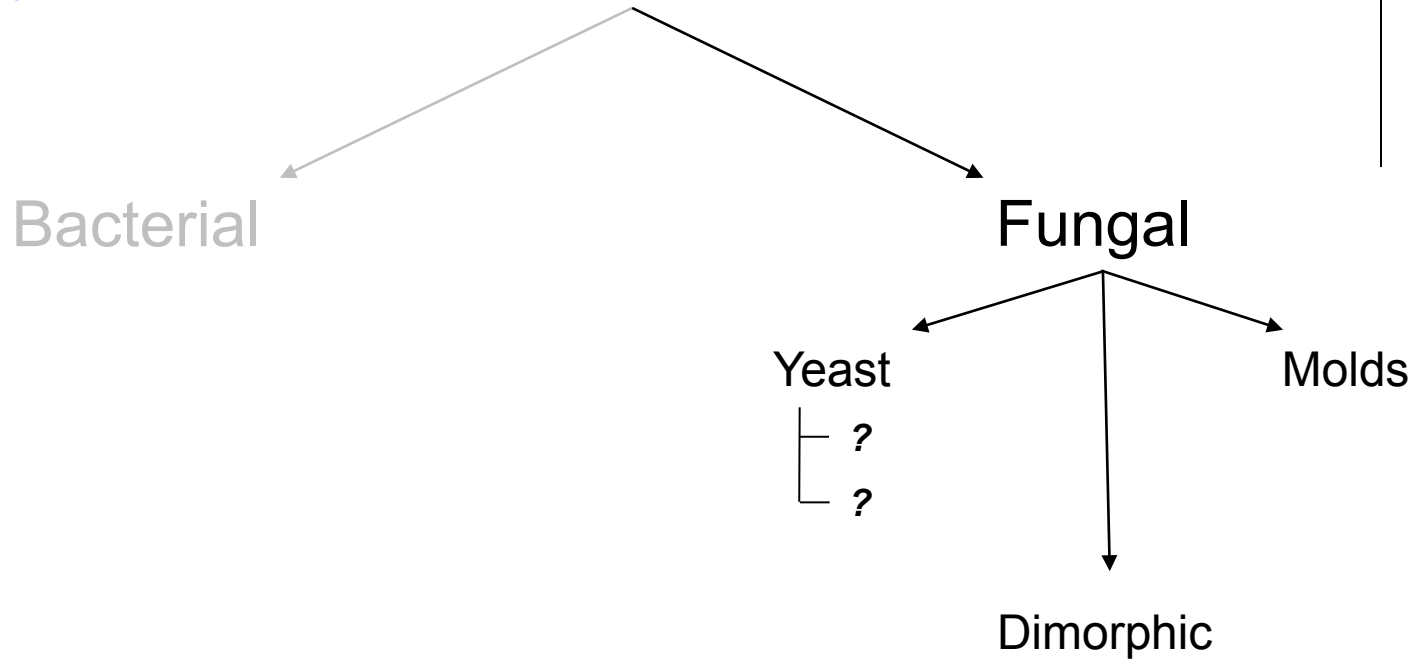
What does it mean to say a fungus is dimorphic?
It means the organism exists as a yeast in the body, but as a mold in the environment

Fungi are frequently classified with respect to a basic microbiologic property. What is it?
Whether they are yeast, molds or **dimorphic**



Yeast vs Molds (vs bacteria)

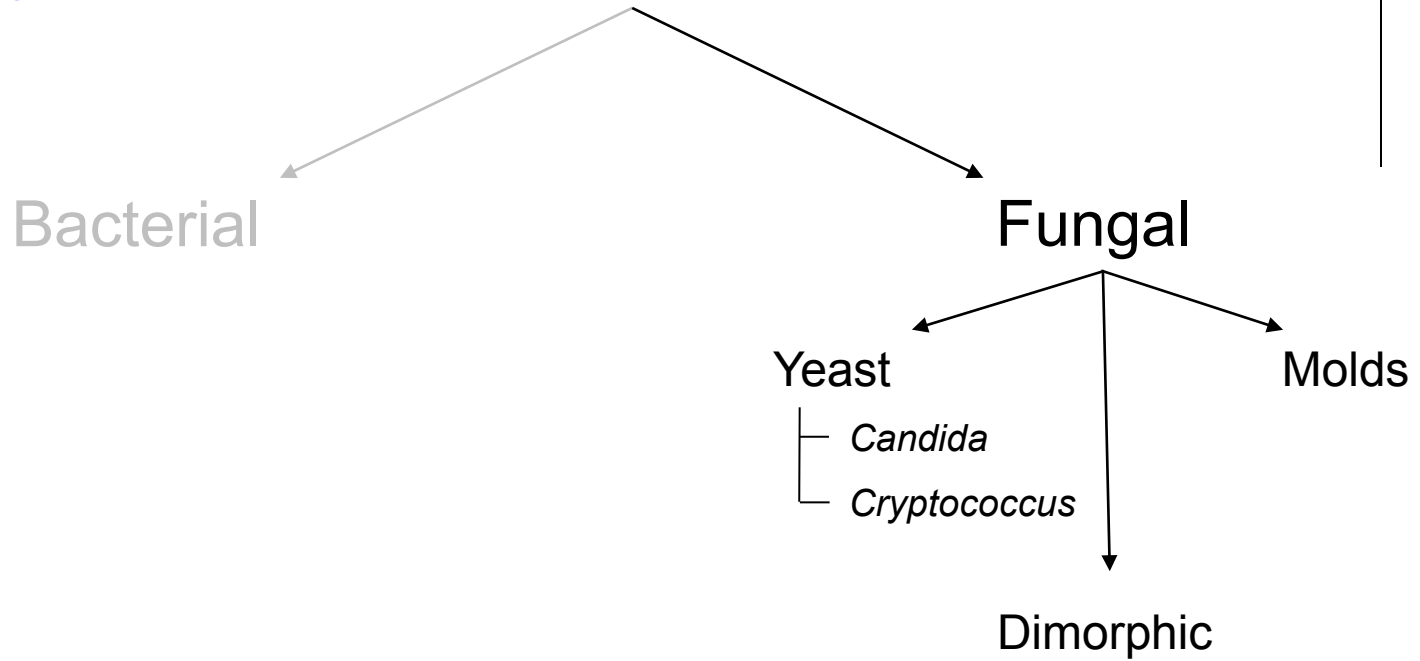
Endogenous Endophthalmitis



Fungi are frequently classified with respect to a basic microbiologic property. What is it?
Whether they are **yeast**, **molds** or **dimorphic**

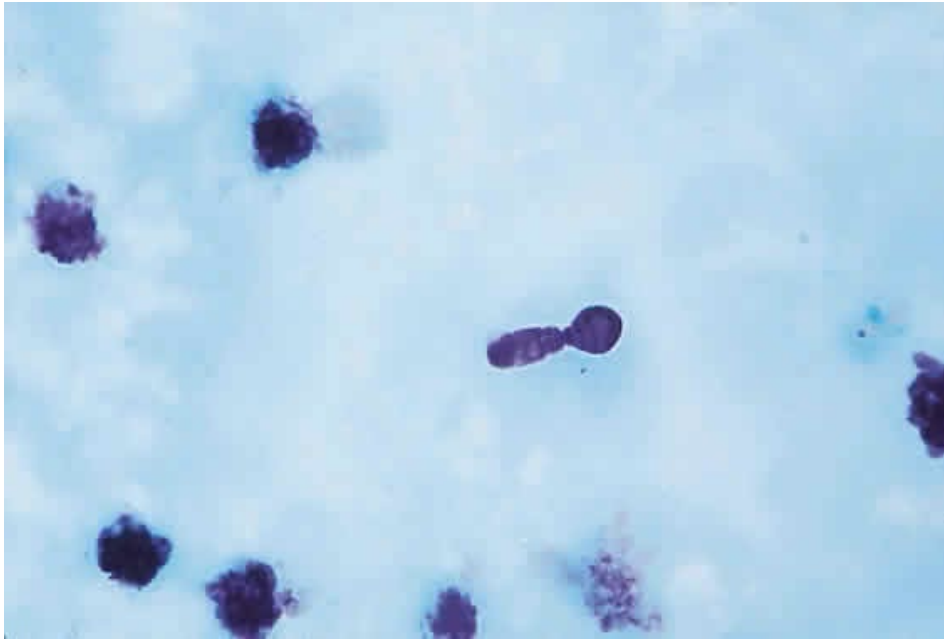Which two yeasts are most commonly implicated in endogenous fungal endophthalmitis?

Endogenous Endophthalmitis

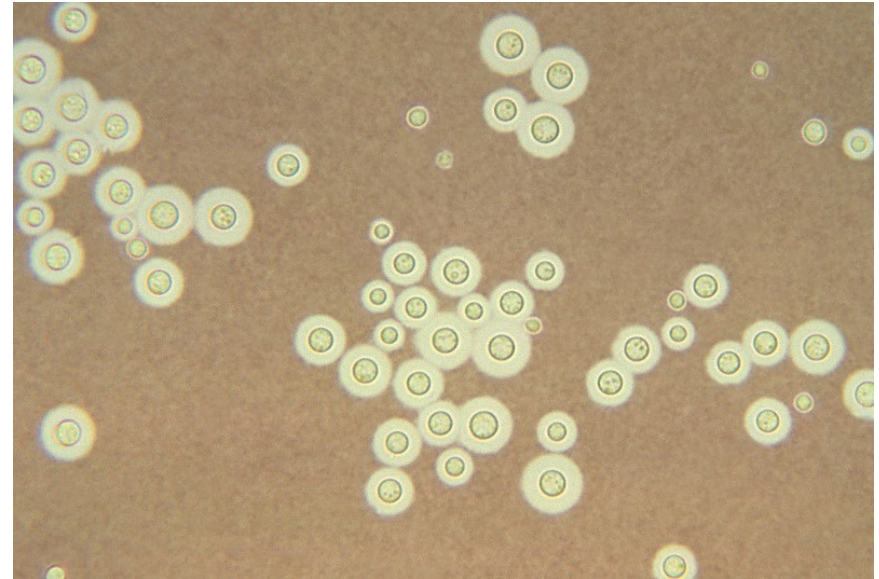


Fungi are frequently classified with respect to a basic microbiologic property. What is it?
Whether they are **yeast**, **molds** or **dimorphic**

Which two yeasts are most commonly implicated in endogenous fungal endophthalmitis?

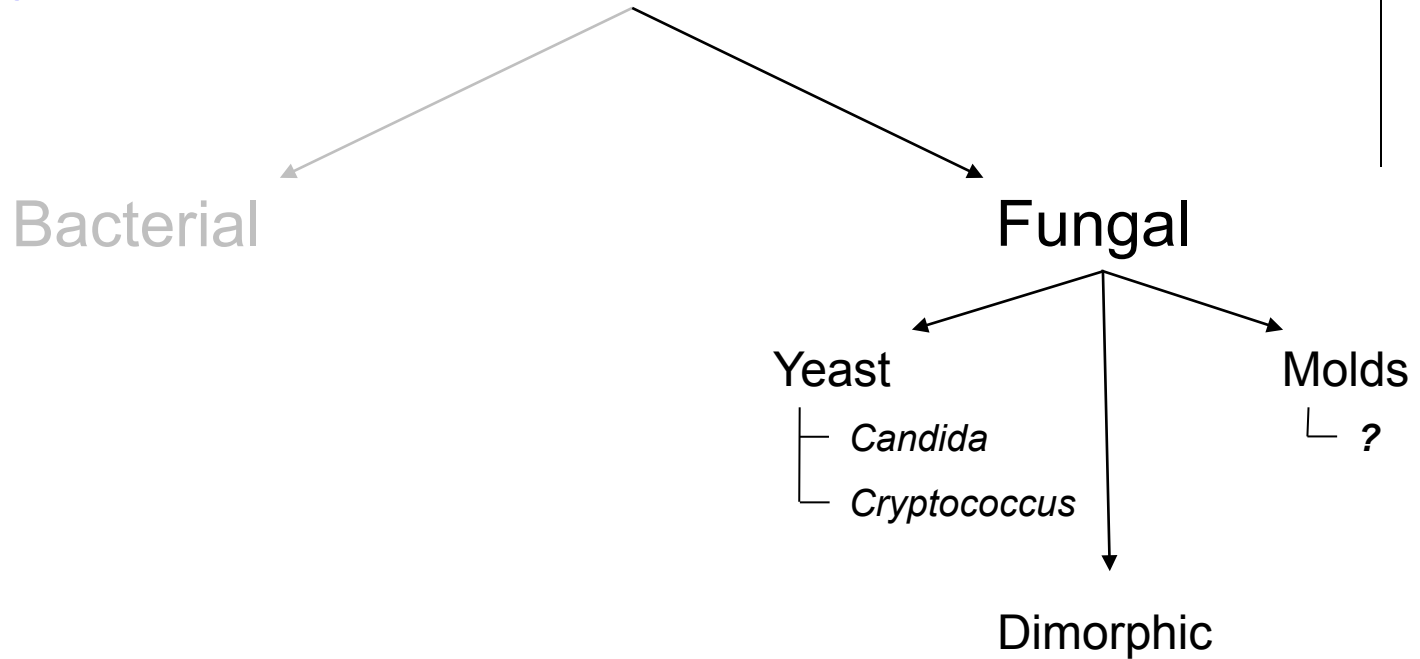


Candida: 'Budding'



Cryptococcus: 'India ink'

Endogenous Endophthalmitis

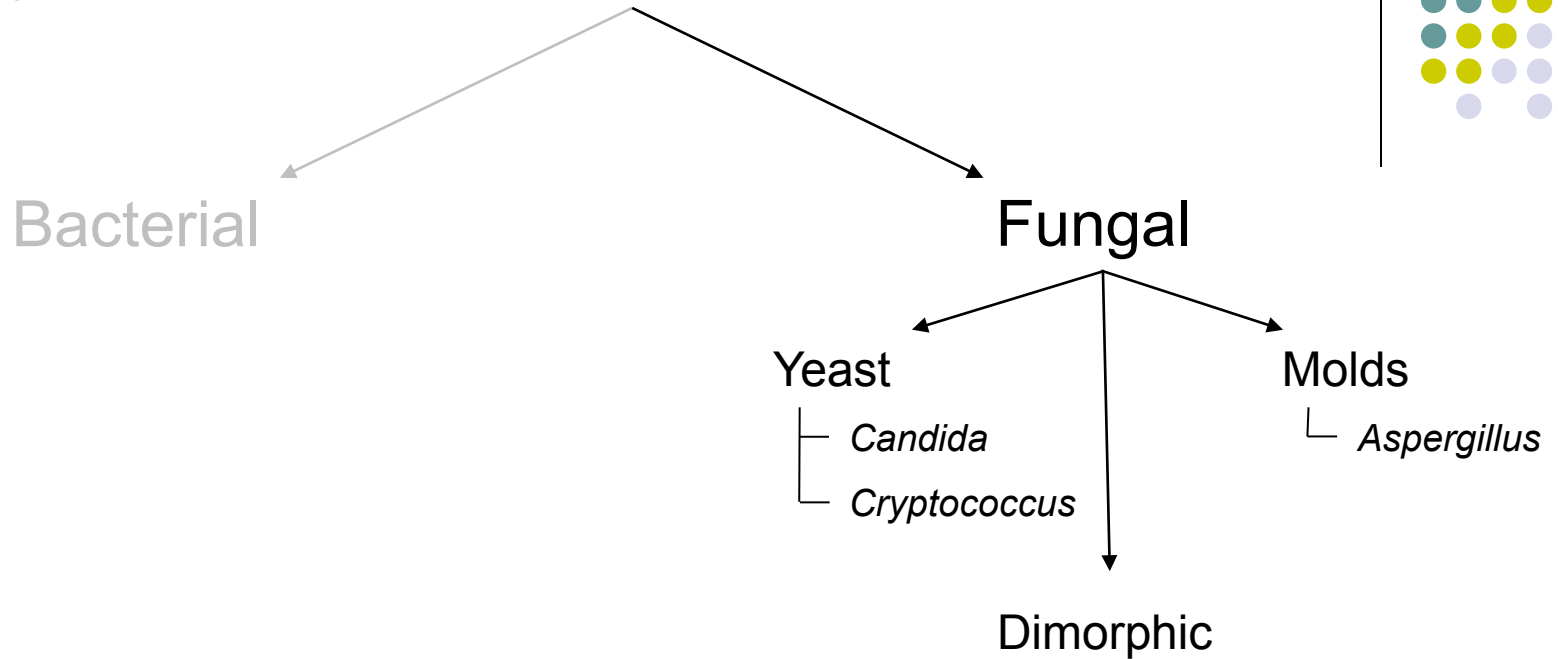


*Fungi are frequently classified with respect to a basic microbiologic property. What is it?
Whether they are **yeast**, **molds** or **dimorphic***

Which two yeasts are most commonly implicated in endogenous fungal endophthalmitis?

Which mold is most commonly implicated in endogenous fungal endophthalmitis?

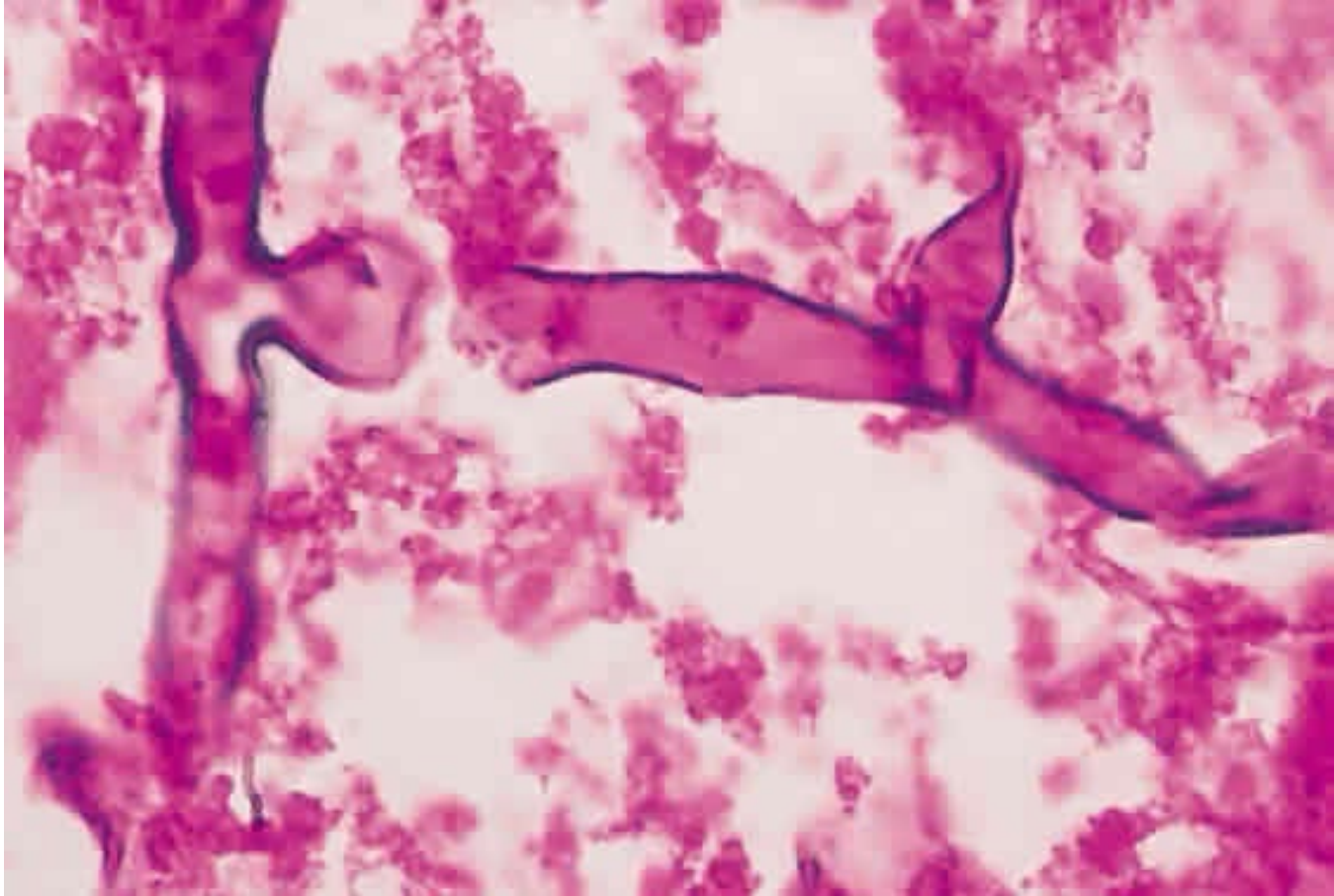

Endogenous Endophthalmitis



*Fungi are frequently classified with respect to a basic microbiologic property. What is it?
Whether they are **yeast**, **molds** or **dimorphic***

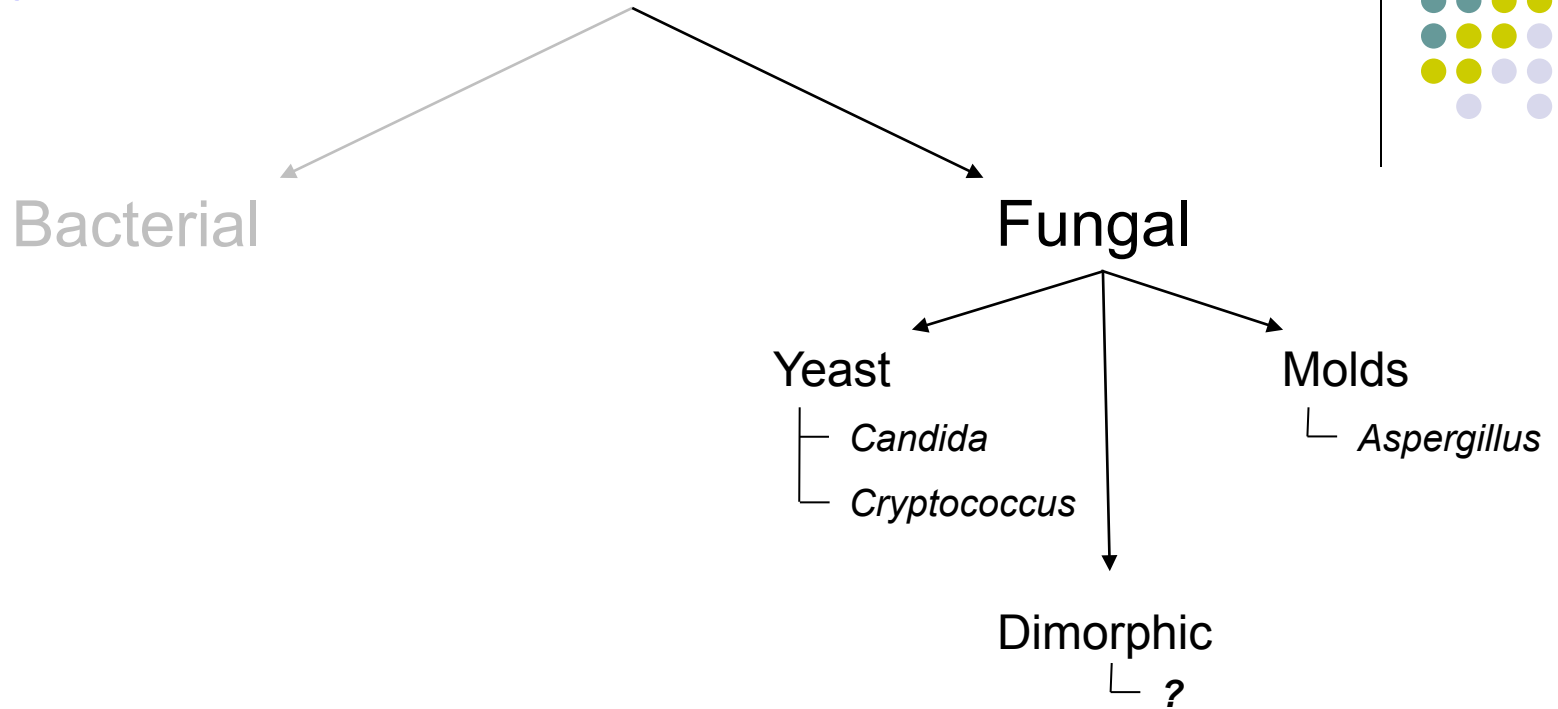
Which two yeasts are most commonly implicated in endogenous fungal endophthalmitis?

Which mold is most commonly implicated in endogenous fungal endophthalmitis?



Aspergillus: 'Broad hyphae'

Endogenous Endophthalmitis



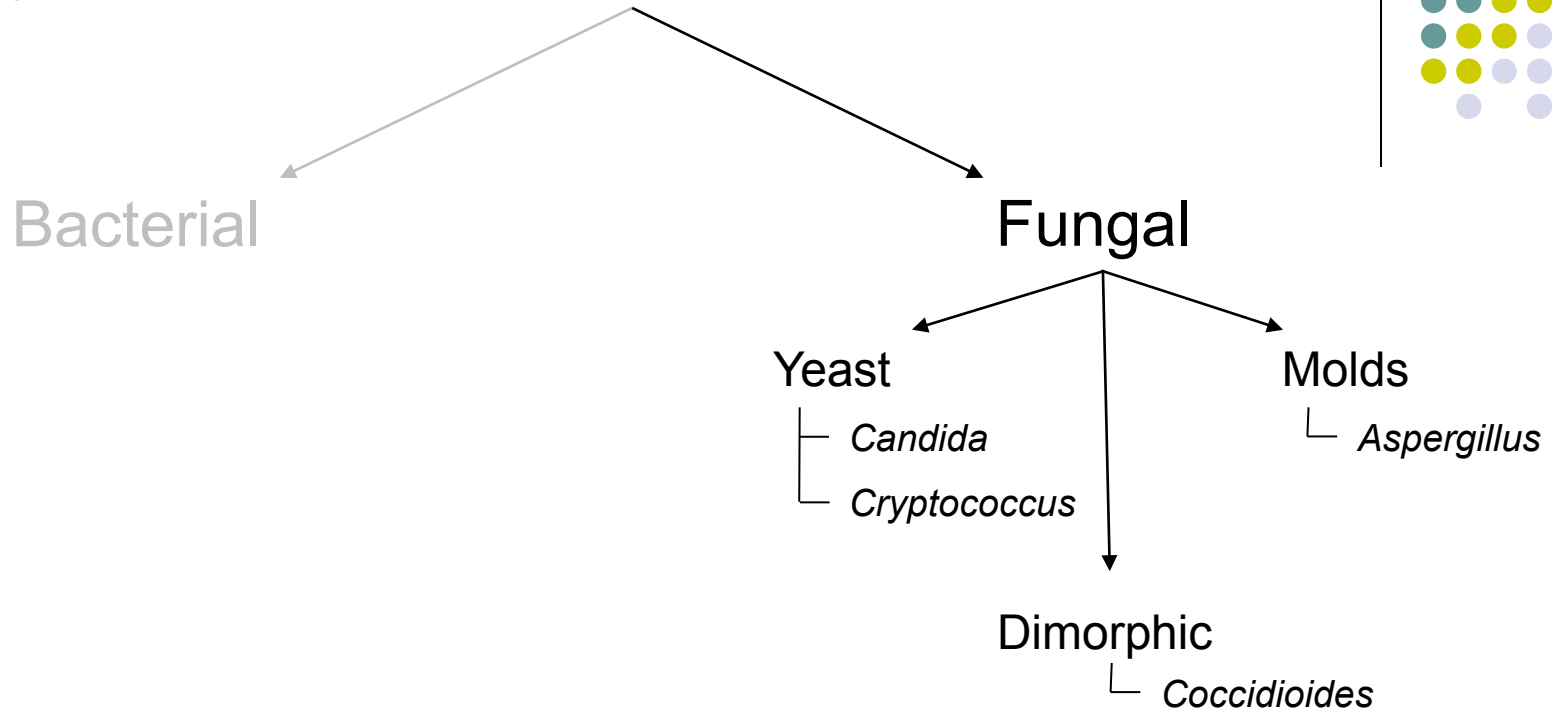
*Fungi are frequently classified with respect to a basic microbiologic property. What is it?
Whether they are **yeast**, **molds** or **dimorphic***

Which two yeasts are most commonly implicated in endogenous fungal endophthalmitis?

Which mold is most commonly implicated in endogenous fungal endophthalmitis?

Which dimorphic fungus is most commonly implicated in endogenous fungal endophthalmitis?

Endogenous Endophthalmitis

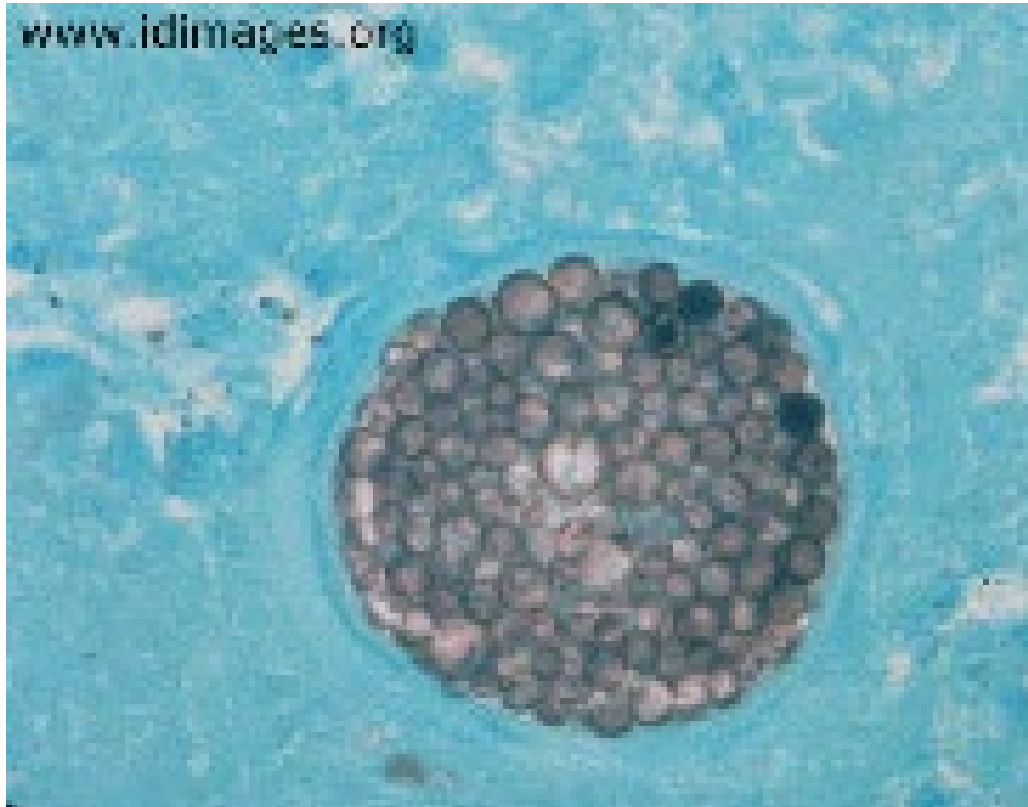


*Fungi are frequently classified with respect to a basic microbiologic property. What is it?
Whether they are **yeast**, **molds** or **dimorphic***

Which two yeasts are most commonly implicated in endogenous fungal endophthalmitis?

Which mold is most commonly implicated in endogenous fungal endophthalmitis?

Which dimorphic fungus is most commonly implicated in endogenous fungal endophthalmitis?

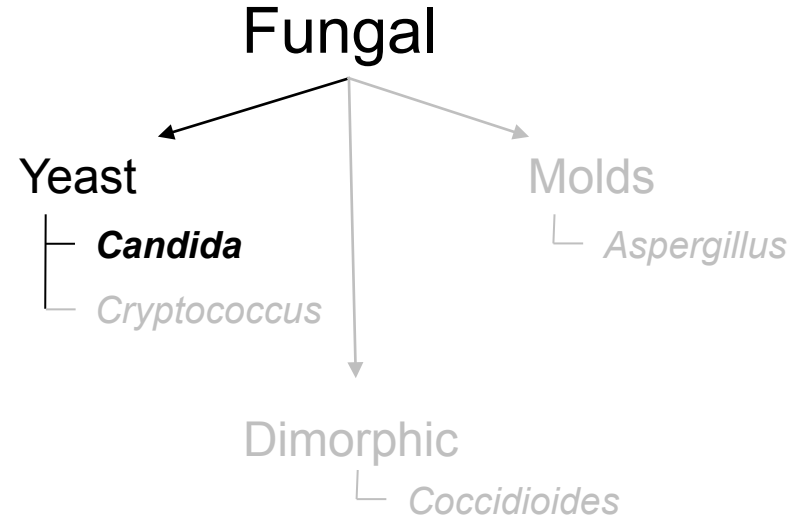


Coccidioides: 'Spherules'

Endogenous Endophthalmitis



Is Candida a common cause of endogenous fungal endophthalmitis?

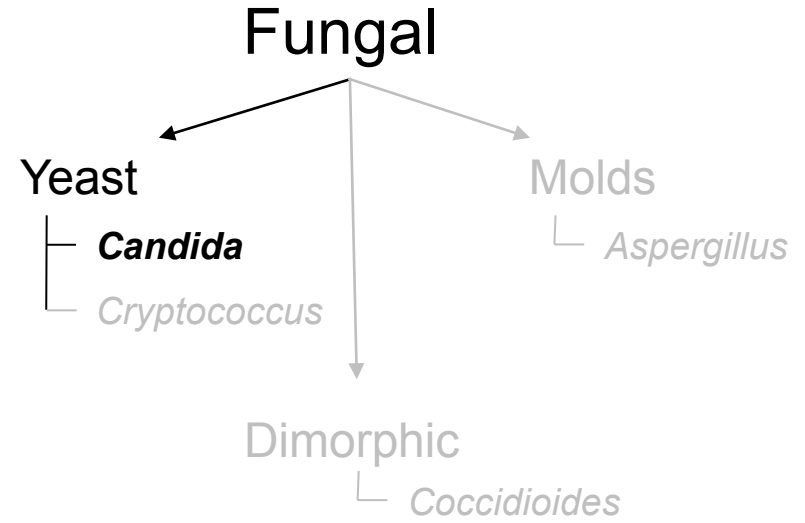


Endogenous Endophthalmitis



Is Candida a common cause of endogenous fungal endophthalmitis?

Yes--in fact, it is the most common cause in both adults and children



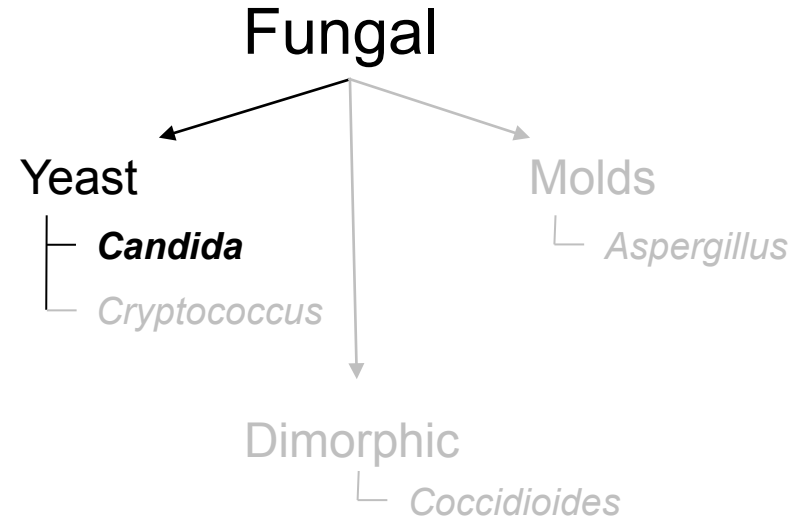
Endogenous Endophthalmitis



Is Candida a common cause of endogenous fungal endophthalmitis?

Yes--in fact, it is the most common cause in both adults and children

Generally speaking, who is at risk?



Endogenous Endophthalmitis

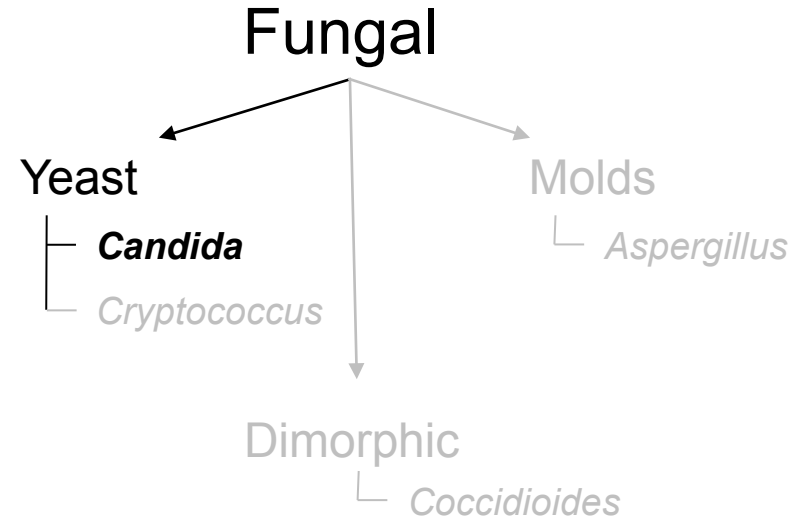


Is Candida a common cause of endogenous fungal endophthalmitis?

Yes--in fact, it is the most common cause in both adults and children

Generally speaking, who is at risk?

Hospitalized, debilitated individuals



Endogenous Endophthalmitis



Is Candida a common cause of endogenous fungal endophthalmitis?

Yes--in fact, it is the most common cause in both adults and children

Generally speaking, who is at risk?

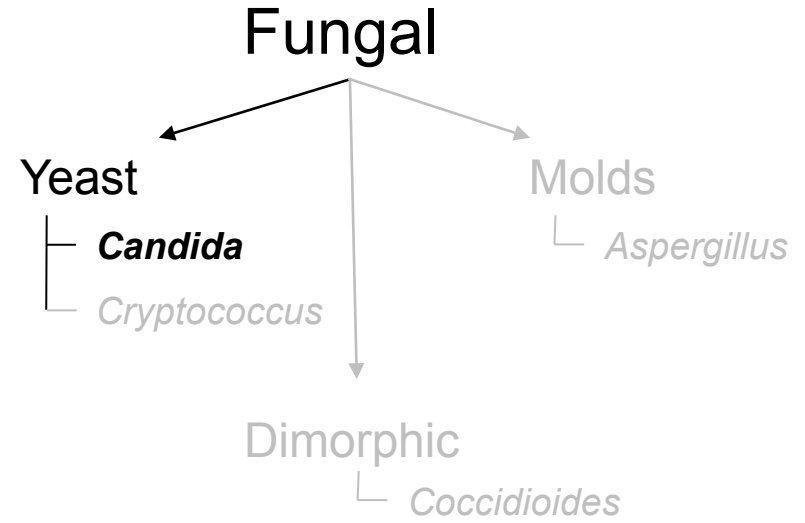
Hospitalized, debilitated individuals

Is there anything in particular that puts them at risk?

--

--

--



Endogenous Endophthalmitis



Is Candida a common cause of endogenous fungal endophthalmitis?

Yes--in fact, it is the most common cause in both adults and children

Generally speaking, who is at risk?

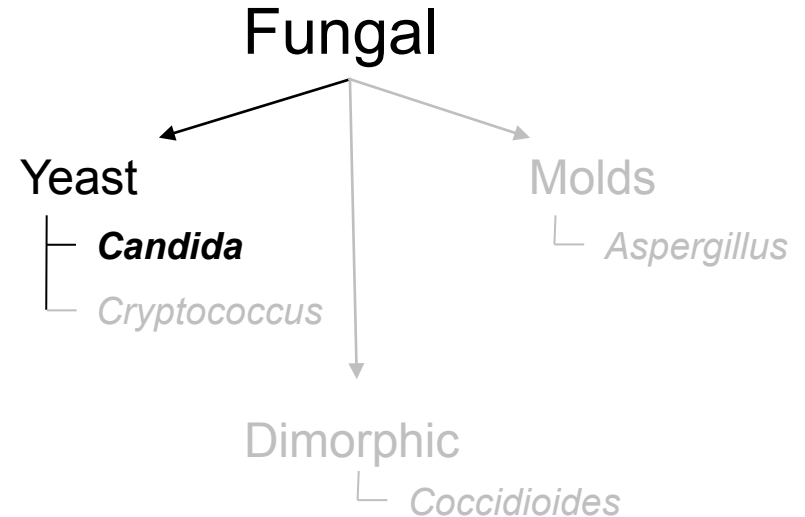
Hospitalized, debilitated individuals

Is there anything in particular that puts them at risk?

--Hx major GI surgery

--Chronic lines/catheters (Classic story: Pt s/p GI surgery is NPO and receiving TPN)

--Systemic antibiotics (think sepsis pt)



Endogenous Endophthalmitis



Is Candida a common cause of endogenous fungal endophthalmitis?

Yes--in fact, it is the most common cause in both adults and children

Generally speaking, who is at risk?

Hospitalized, debilitated individuals

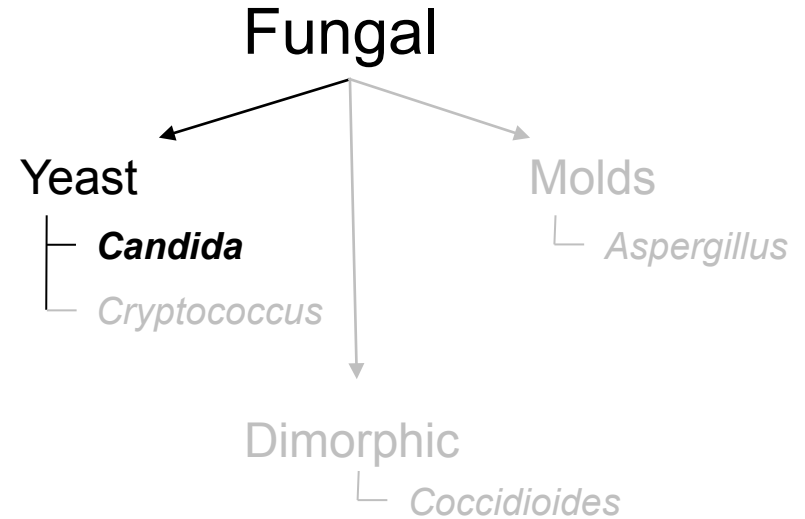
Is there anything in particular that puts them at risk?

--Hx major GI surgery

--Chronic lines/catheters (Classic story: Pt s/p GI surgery is NPO and receiving TPN)

--Systemic antibiotics (think sepsis pt)

How about being immunocompromised?



Endogenous Endophthalmitis



Is Candida a common cause of endogenous fungal endophthalmitis?

Yes--in fact, it is the most common cause in both adults and children

Generally speaking, who is at risk?

Hospitalized, debilitated individuals

Is there anything in particular that puts them at risk?

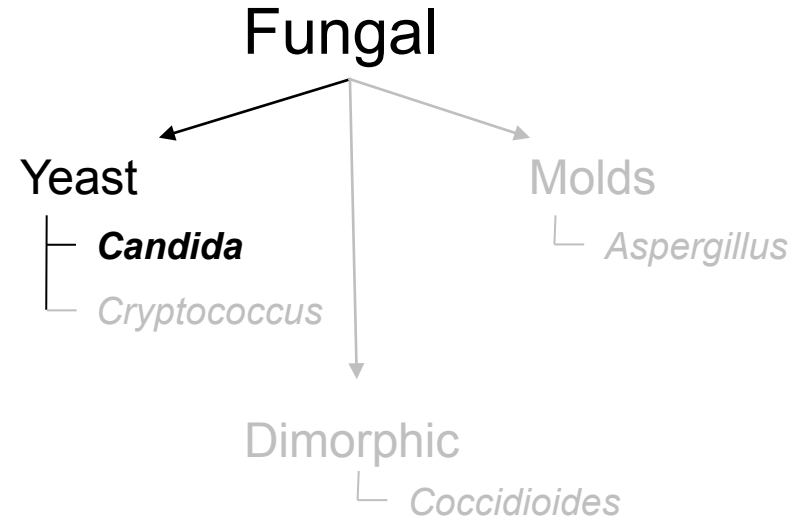
--Hx major GI surgery

--Chronic lines/catheters (Classic story: Pt s/p GI surgery is NPO and receiving TPN)

--Systemic antibiotics (think sepsis pt)

How about being immunocompromised?

This does not seem to be a risk factor (eg, HIV/AIDS is **not** a risk factor for *Candida* endophthalmitis)



Endogenous Endophthalmitis



Is Candida a common cause of endogenous fungal endophthalmitis?

Yes--in fact, it is the most common cause in both adults and children

Generally speaking, who is at risk?

Hospitalized, debilitated individuals

Is there anything in particular that puts them at risk?

--Hx major GI surgery

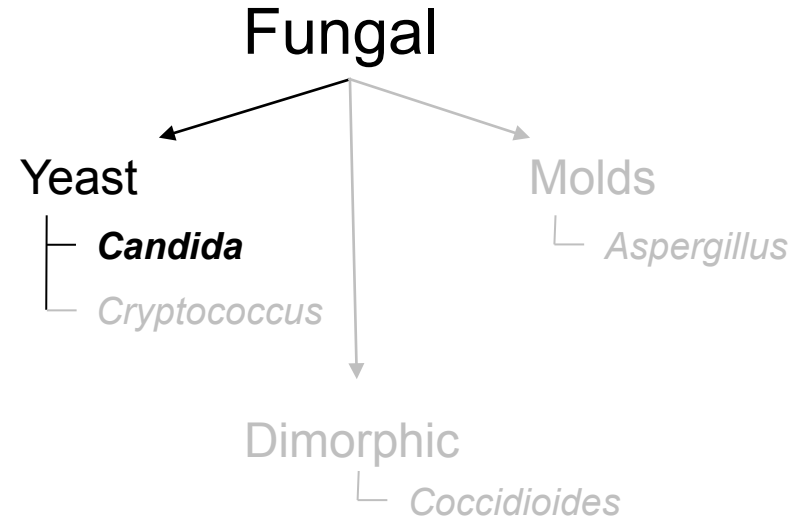
--Chronic lines/catheters (Classic story: Pt s/p GI surgery is NPO and receiving TPN)

--Systemic antibiotics (think sepsis pt)


How about being immunocompromised?

This does not seem to be a risk factor (eg, HIV/AIDS is **not** a risk factor for *Candida* endophthalmitis)

If a pt is found to have candidemia, what should the primary team do (besides treat it)?



Endogenous Endophthalmitis



Is Candida a common cause of endogenous fungal endophthalmitis?

Yes--in fact, it is the most common cause in both adults and children

Generally speaking, who is at risk?

Hospitalized, debilitated individuals

Is there anything in particular that puts them at risk?

--Hx major GI surgery

--Chronic lines/catheters (Classic story: Pt s/p GI surgery is NPO and receiving TPN)

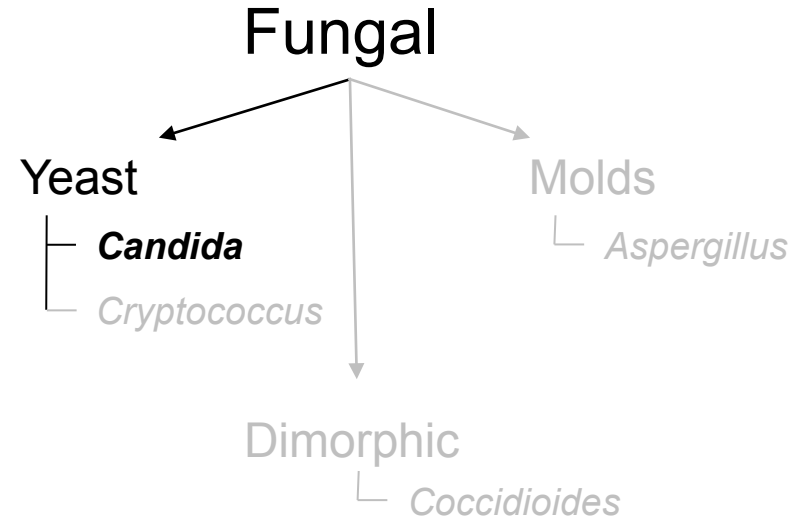
--Systemic antibiotics (think sepsis pt)

How about being immunocompromised?

This does not seem to be a risk factor (eg, HIV/AIDS is **not** a risk factor for *Candida* endophthalmitis)

If a pt is found to have candidemia, what should the primary team do (besides treat it)?

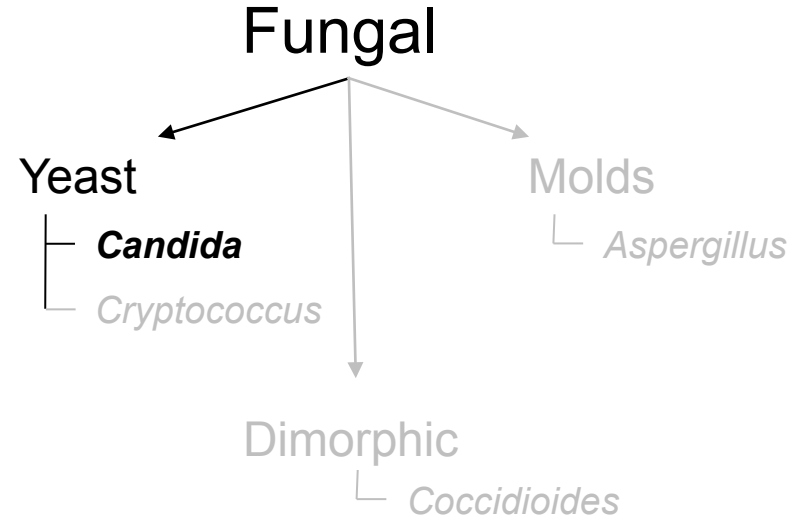
They should consult ophthalmology for an urgent DFE, and the pt should be followed closely for at least two weeks to ensure *Candida* endophthalmitis doesn't develop



Endogenous Endophthalmitis



How does *Candida endophthalmitis* present?



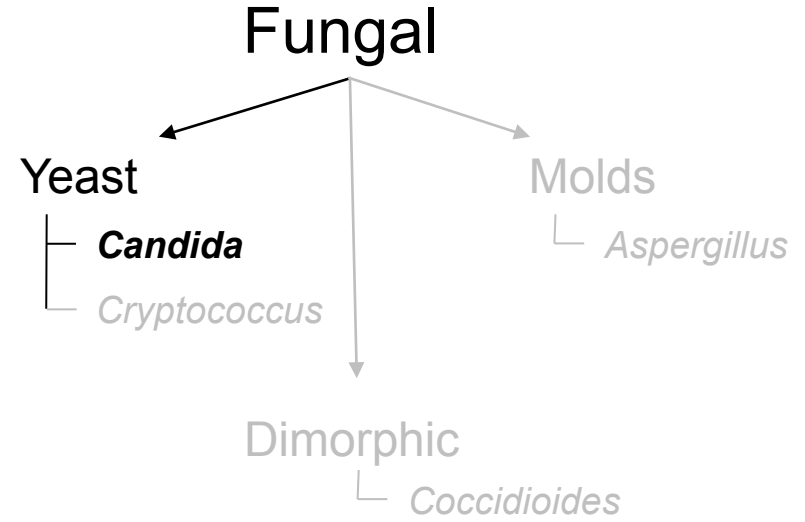
Endogenous Endophthalmitis

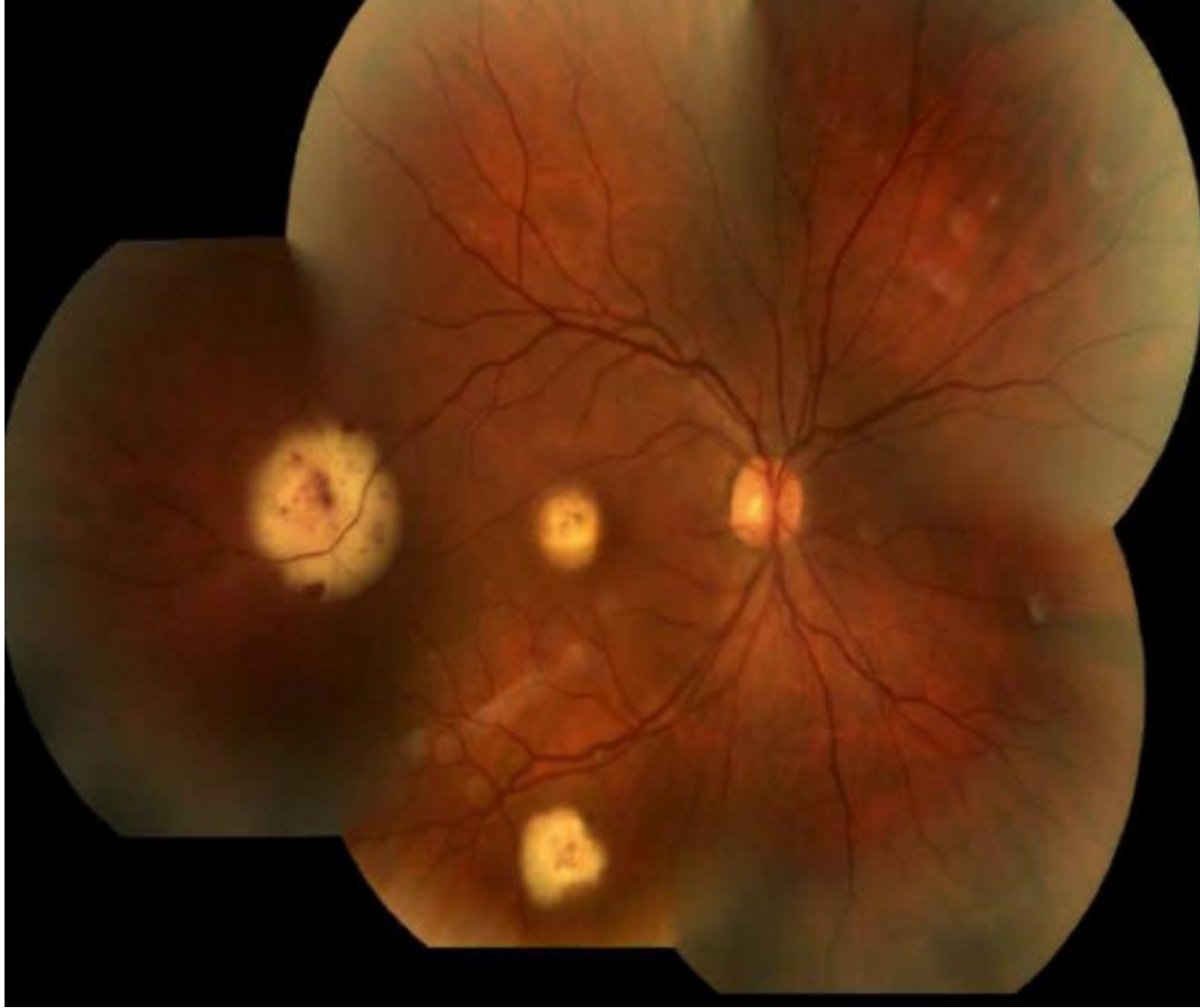

How does Candida endophthalmitis present?

Like other fungal entities, it starts with choroidal lesions. Pts will c/o decreased VA if one of the lesions affects the macular region.

Specifically, the choroidal lesions are bilateral, multiple, white and small (<1DD).





Candida endophthalmitis

Endogenous Endophthalmitis

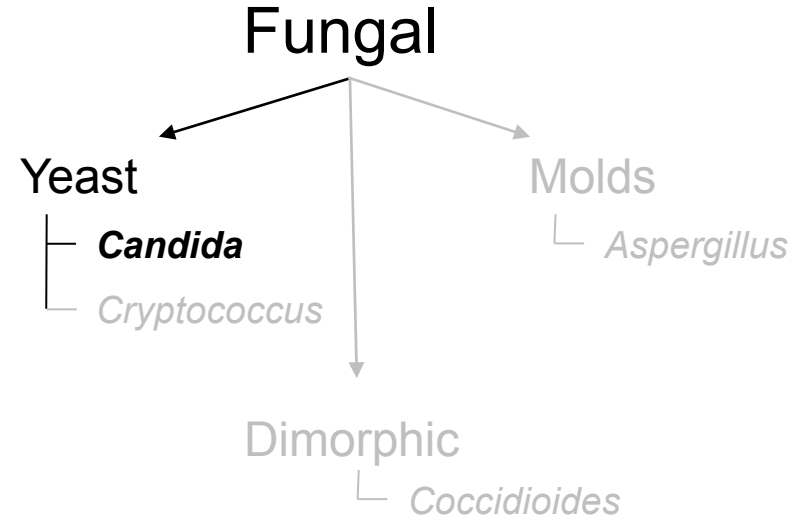


How does Candida endophthalmitis present?

Like other fungal entities, it starts with choroidal lesions. Pts will c/o decreased VA if one of the lesions affects the macular region.

Specifically, the choroidal lesions are bilateral, multiple, white and small (<1DD).

What about the vitreous?



Endogenous Endophthalmitis



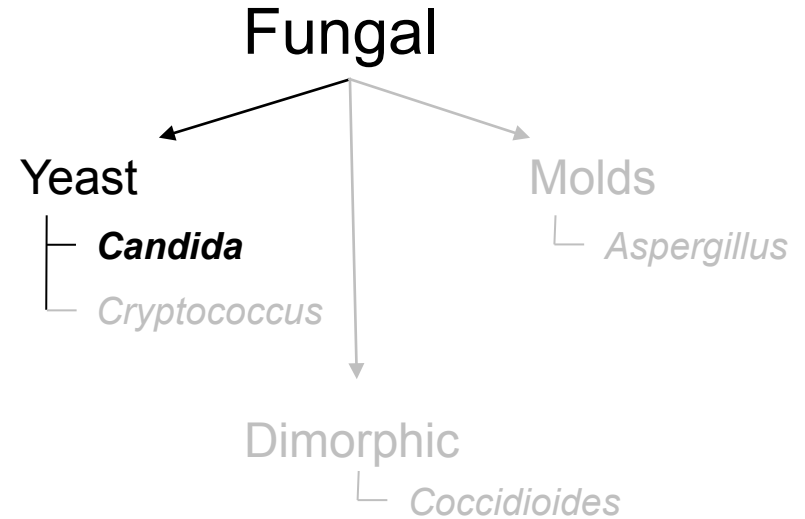
How does Candida endophthalmitis present?

Like other fungal entities, it starts with choroidal lesions. Pts will c/o decreased VA if one of the lesions affects the macular region.

Specifically, the choroidal lesions are bilateral, multiple, white and small (<1DD).

What about the vitreous?

The classic finding is inflammatory aggregates arranged like a 'three words'



Endogenous Endophthalmitis



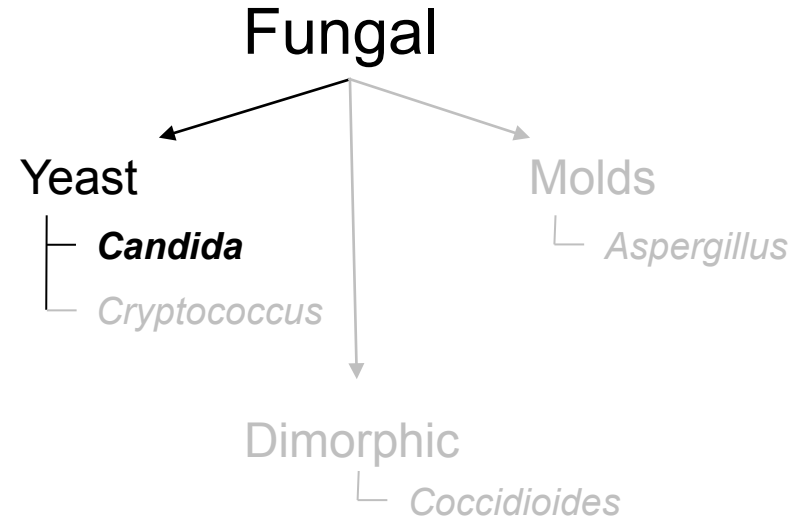
How does Candida endophthalmitis present?

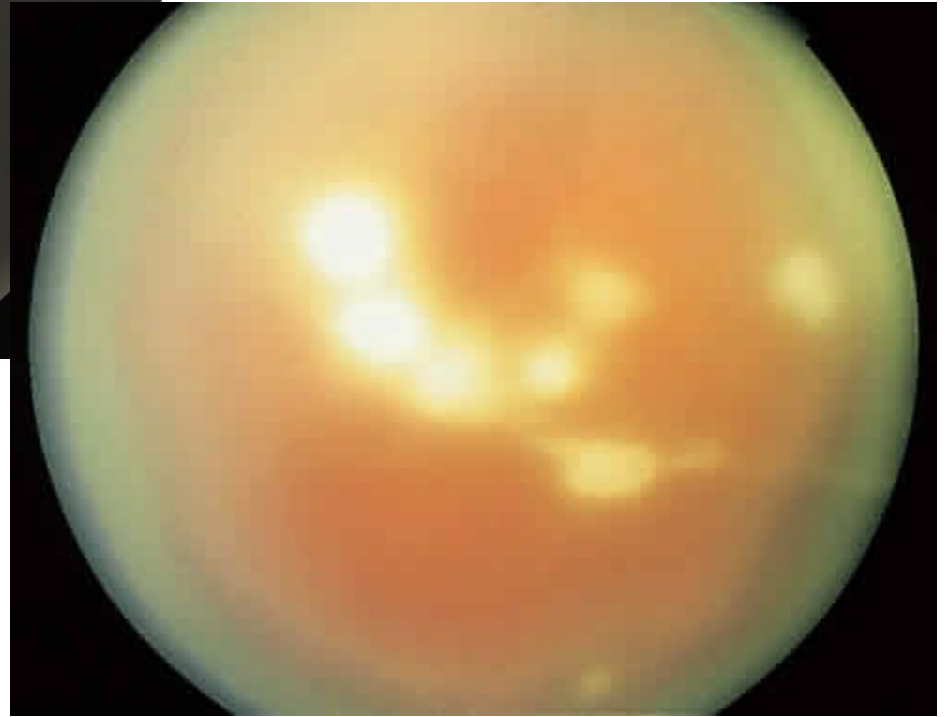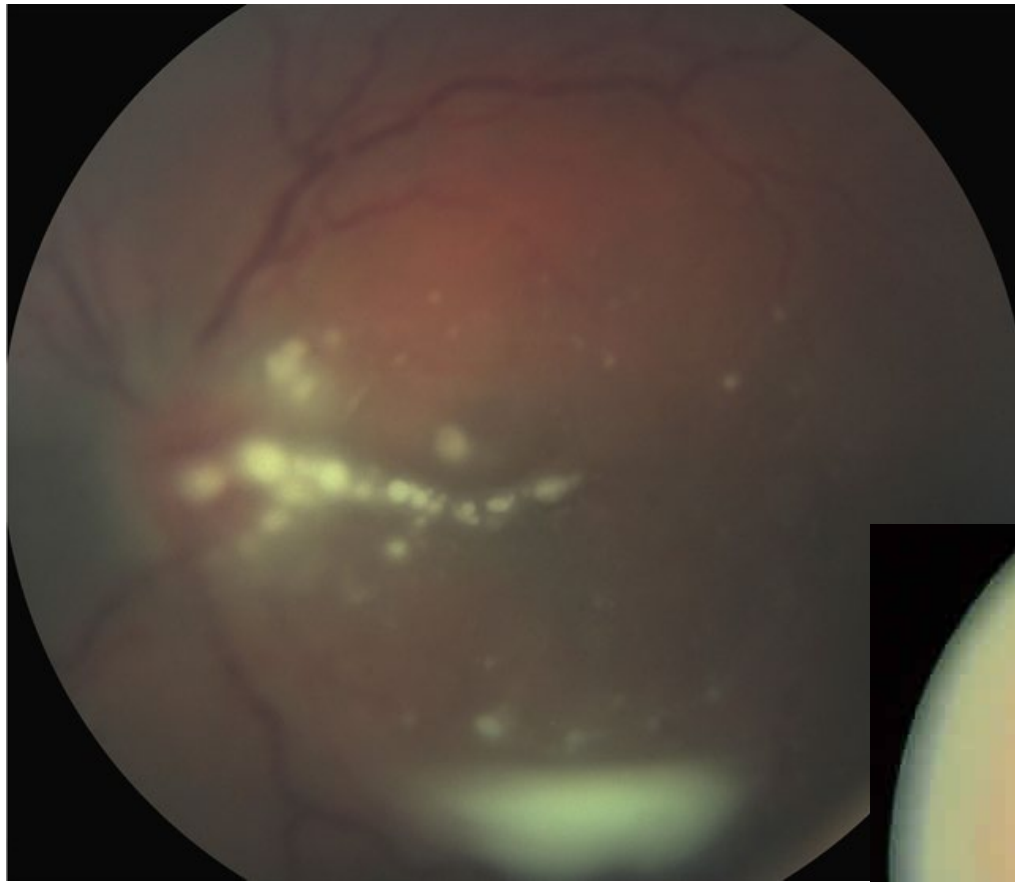

Like other fungal entities, it starts with choroidal lesions. Pts will c/o decreased VA if one of the lesions affects the macular region.

Specifically, the choroidal lesions are bilateral, multiple, white and small (<1DD).

What about the vitreous?


The classic finding is inflammatory aggregates arranged like a 'string of pearls'





Candida endophthalmitis: 'String of pearls'

Endogenous Endophthalmitis



How does Candida endophthalmitis present?

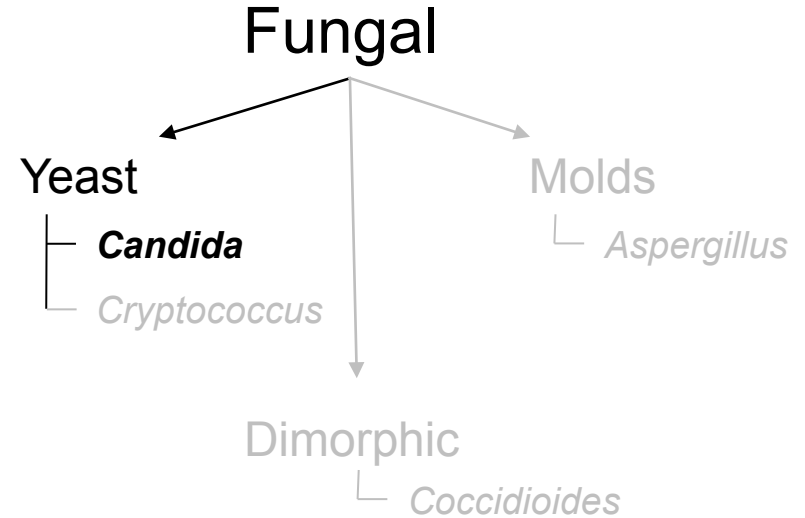
Like other fungal entities, it starts with choroidal lesions. Pts will c/o decreased VA if one of the lesions affects the macular region.

Specifically, the choroidal lesions are bilateral, multiple, white and small (<1DD).

What about the vitreous?

The classic finding is inflammatory aggregates arranged like a 'string of pearls'

Can the anterior segment be involved?



Endogenous Endophthalmitis



How does Candida endophthalmitis present?

Like other fungal entities, it starts with choroidal lesions. Pts will c/o decreased VA if one of the lesions affects the macular region.

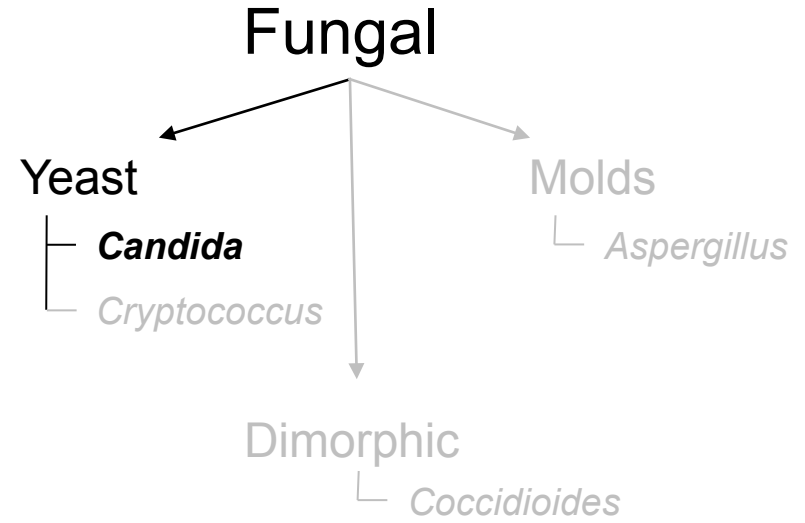
Specifically, the choroidal lesions are bilateral, multiple, white and small (<1DD).

What about the vitreous?

The classic finding is inflammatory aggregates arranged like a 'string of pearls'

Can the anterior segment be involved?

Yes. And if it is, the pain is usually severe.



Endogenous Endophthalmitis



How does Candida endophthalmitis present?

Like other fungal entities, it starts with choroidal lesions. Pts will c/o decreased VA if one of the lesions affects the macular region.

Specifically, the choroidal lesions are bilateral, multiple, white and small (<1DD).

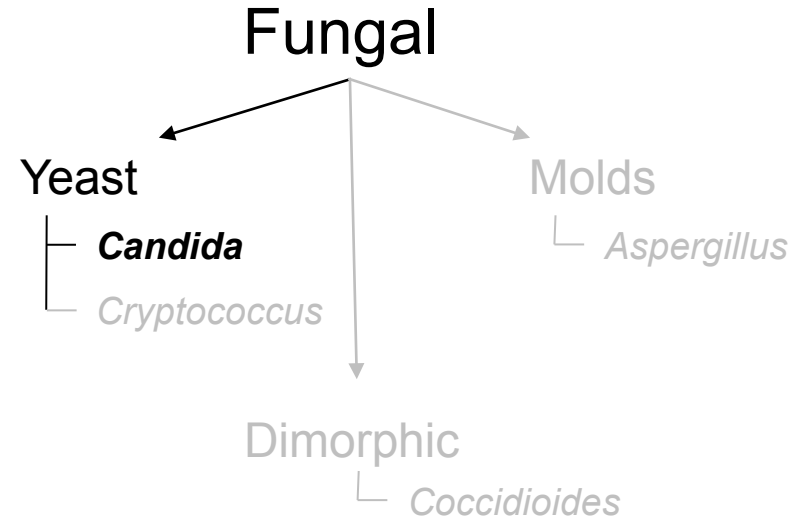
What about the vitreous?

The classic finding is inflammatory aggregates arranged like a 'string of pearls'

Can the anterior segment be involved?

Yes. And if it is, the pain is usually severe.

How is Candida endophthalmitis treated?



Endogenous Endophthalmitis



How does Candida endophthalmitis present?

Like other fungal entities, it starts with choroidal lesions. Pts will c/o decreased VA if one of the lesions affects the macular region.

Specifically, the choroidal lesions are bilateral, multiple, white and small (<1DD).

What about the vitreous?

The classic finding is inflammatory aggregates arranged like a 'string of pearls'

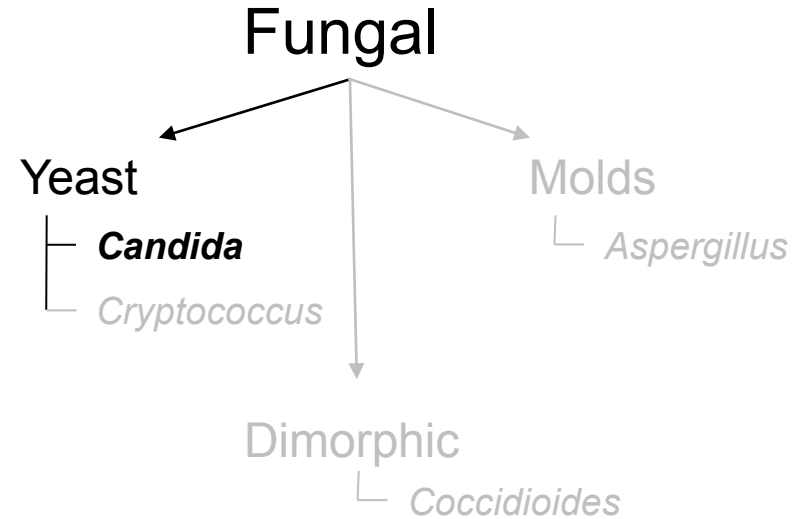
Can the anterior segment be involved?

Yes. And if it is, the pain is usually severe.

How is Candida endophthalmitis treated?

This depends upon what 'phase' the disease is in...

--If the infection is limited to the choroid (ie, there is no vitreal involvement):



Endogenous Endophthalmitis



How does Candida endophthalmitis present?

Like other fungal entities, it starts with choroidal lesions. Pts will c/o decreased VA if one of the lesions affects the macular region.

Specifically, the choroidal lesions are bilateral, multiple, white and small (<1DD).

What about the vitreous?

The classic finding is inflammatory aggregates arranged like a 'string of pearls'

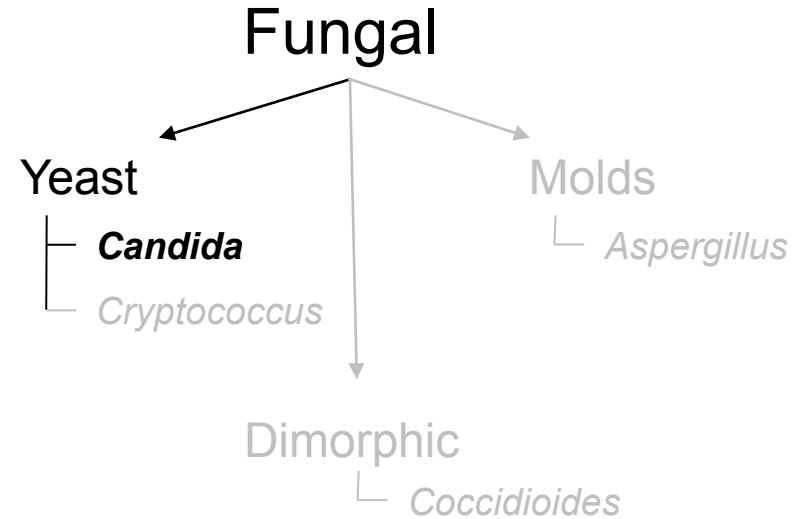
Can the anterior segment be involved?

Yes. And if it is, the pain is usually severe.


How is Candida endophthalmitis treated?

This depends upon what 'phase' the disease is in...

--If the infection is limited to the choroid (ie, there is no vitreal involvement): it can be treated with PO fluconazole + voriconazole.



Endogenous Endophthalmitis



How does Candida endophthalmitis present?

Like other fungal entities, it starts with choroidal lesions. Pts will c/o decreased VA if one of the lesions affects the macular region.

Specifically, the choroidal lesions are bilateral, multiple, white and small (<1DD).

What about the vitreous?

The classic finding is inflammatory aggregates arranged like a 'string of pearls'

Can the anterior segment be involved?

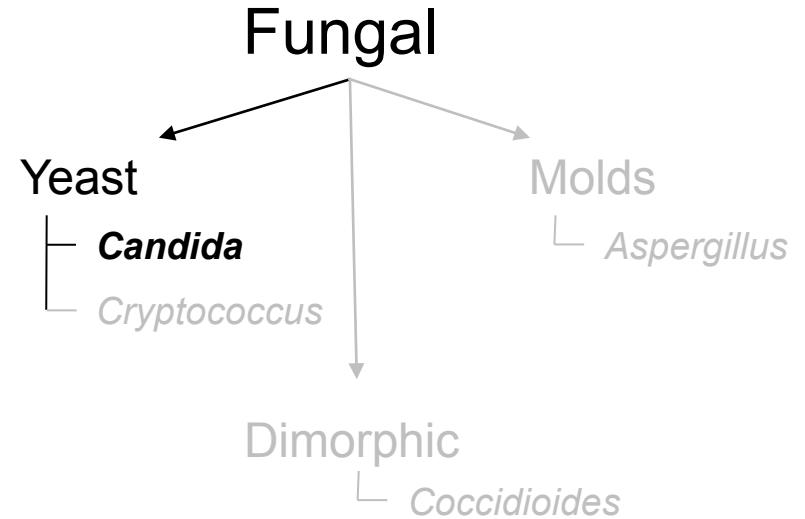
Yes. And if it is, the pain is usually severe.

How is Candida endophthalmitis treated?

This depends upon what 'phase' the disease is in...

--If the infection is limited to the choroid (ie, there is no vitreal involvement): it can be treated with PO fluconazole + voriconazole.

--Once the infection involves the vitreous:



Endogenous Endophthalmitis



How does Candida endophthalmitis present?

Like other fungal entities, it starts with choroidal lesions. Pts will c/o decreased VA if one of the lesions affects the macular region.

Specifically, the choroidal lesions are bilateral, multiple, white and small (<1DD).

What about the vitreous?

The classic finding is inflammatory aggregates arranged like a 'string of pearls'

Can the anterior segment be involved?

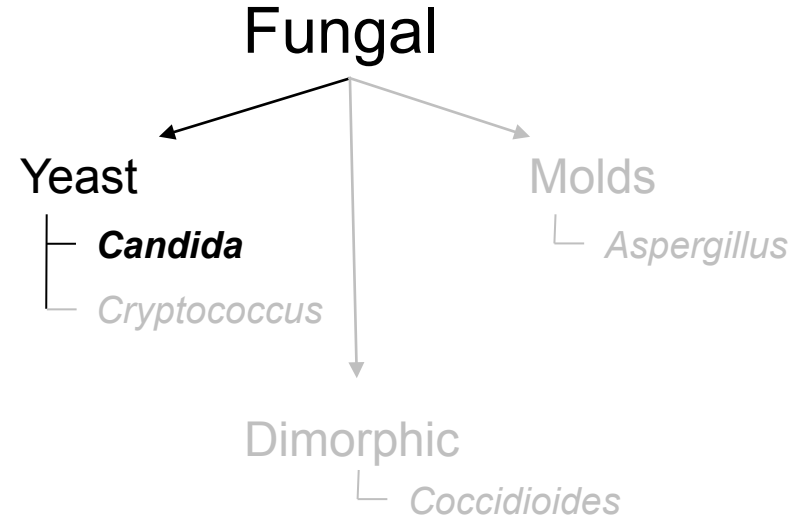
Yes. And if it is, the pain is usually severe.

How is Candida endophthalmitis treated?

This depends upon what 'phase' the disease is in...

--If the infection is limited to the choroid (ie, there is no vitreal involvement): it can be treated with PO fluconazole + voriconazole.

--Once the infection involves the vitreous: intravitreal antifungals (Ampho B; voriconazole) +/- dexamethasone should be used; vitrectomy should be considered.



Endogenous Endophthalmitis



How does Candida endophthalmitis present?

Like other fungal entities, it starts with choroidal lesions. Pts will c/o decreased VA if one of the lesions affects the macular region.

Specifically, the choroidal lesions are bilateral, multiple, white and small (<1DD).

What about the vitreous?

The classic finding is inflammatory aggregates arranged like a 'string of pearls'

Can the anterior segment be involved?

Yes. And if it is, the pain is usually severe.

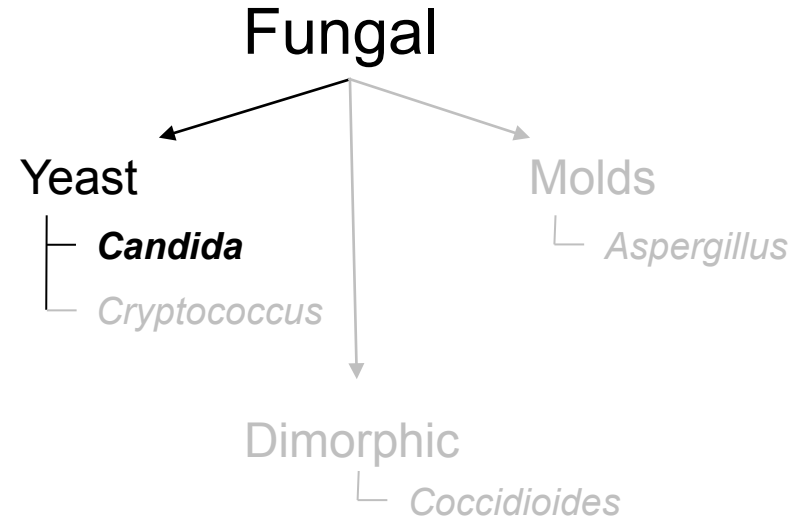
How is Candida endophthalmitis treated?

This depends upon what 'phase' the disease is in...


--If the infection is limited to the choroid (ie, there is no vitreal involvement): it can be treated with PO fluconazole + voriconazole.

--Once the infection involves the vitreous: intravitreal antifungals (Ampho B; voriconazole) +/- dexamethasone should be used; vitrectomy should be considered.

--Severe cases require:



Endogenous Endophthalmitis



How does Candida endophthalmitis present?

Like other fungal entities, it starts with choroidal lesions. Pts will c/o decreased VA if one of the lesions affects the macular region.

Specifically, the choroidal lesions are bilateral, multiple, white and small (<1DD).

What about the vitreous?

The classic finding is inflammatory aggregates arranged like a 'string of pearls'

Can the anterior segment be involved?

Yes. And if it is, the pain is usually severe.

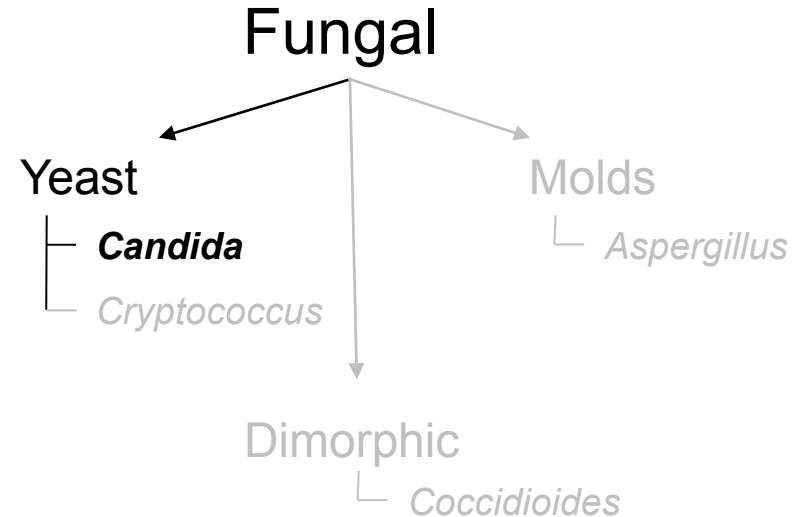
How is Candida endophthalmitis treated?

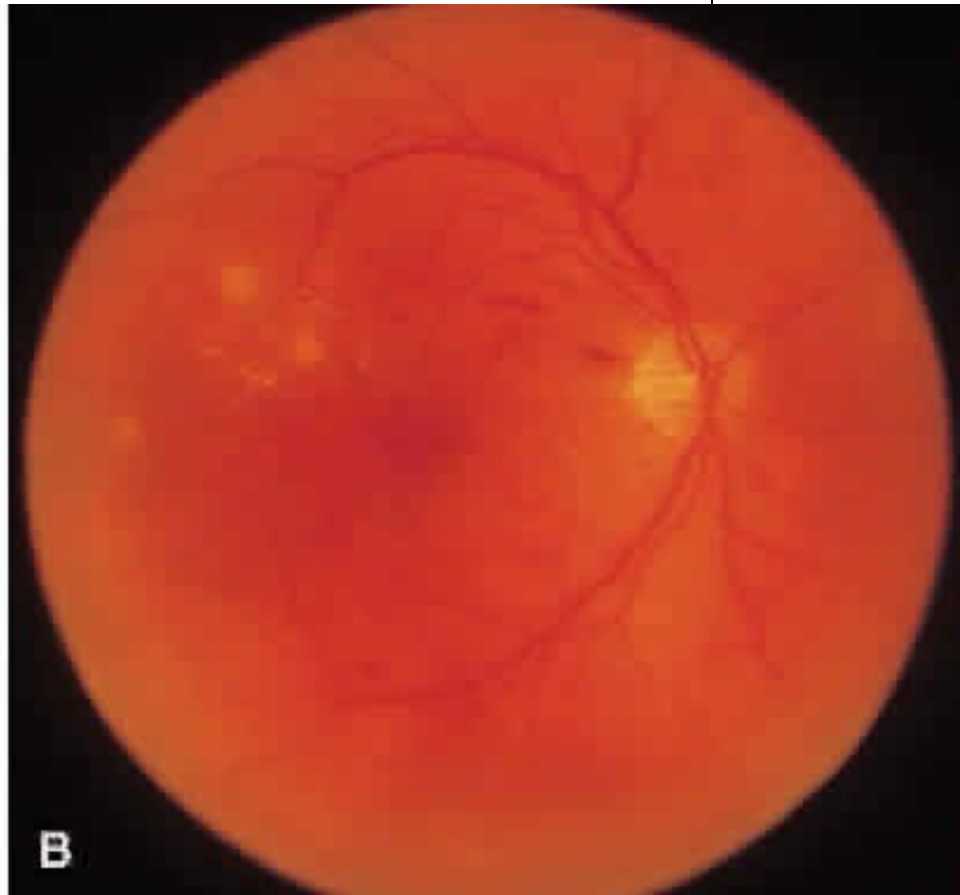
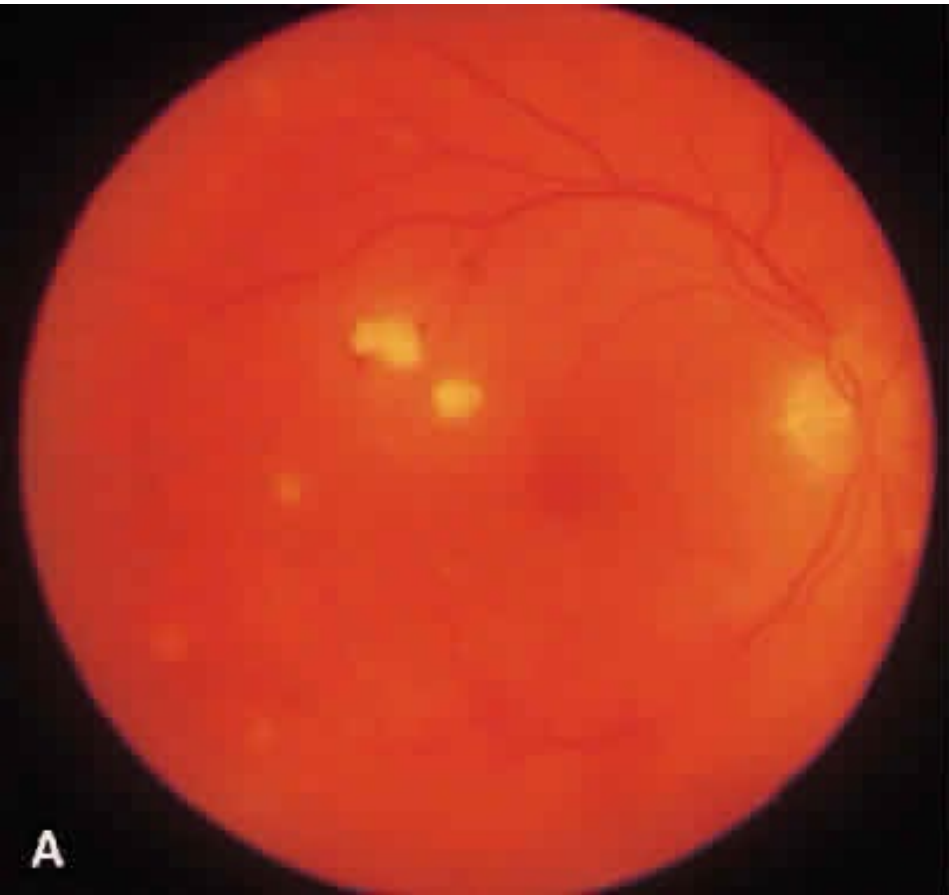
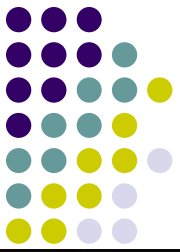This depends upon what 'phase' the disease is in...

--If the infection is limited to the choroid (ie, there is no vitreal involvement): it can be treated with PO fluconazole + voriconazole.

--Once the infection involves the vitreous: intravitreal antifungals (Ampho B; voriconazole) +/- dexamethasone should be used; vitrectomy should be considered.

--Severe cases require: PPV, intravenous Ampho B, and oral voriconazole (+/- other agents).



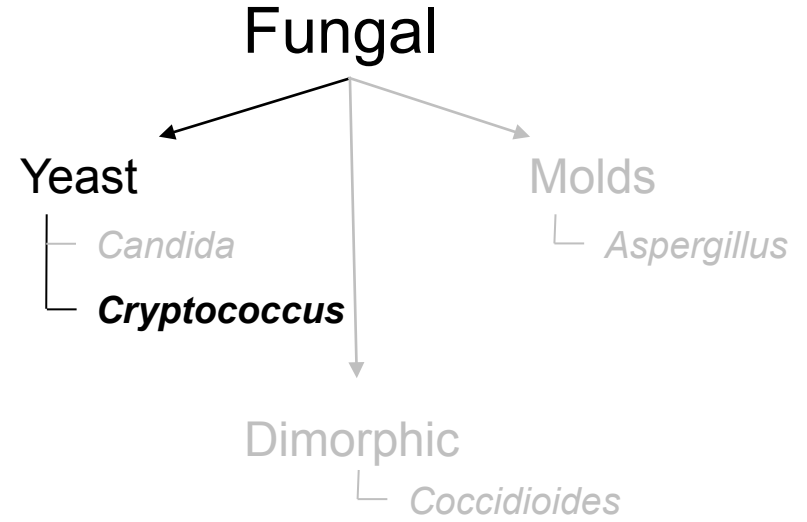


Candida endophthalmitis: Pre- and post-tx

Endogenous Endophthalmitis



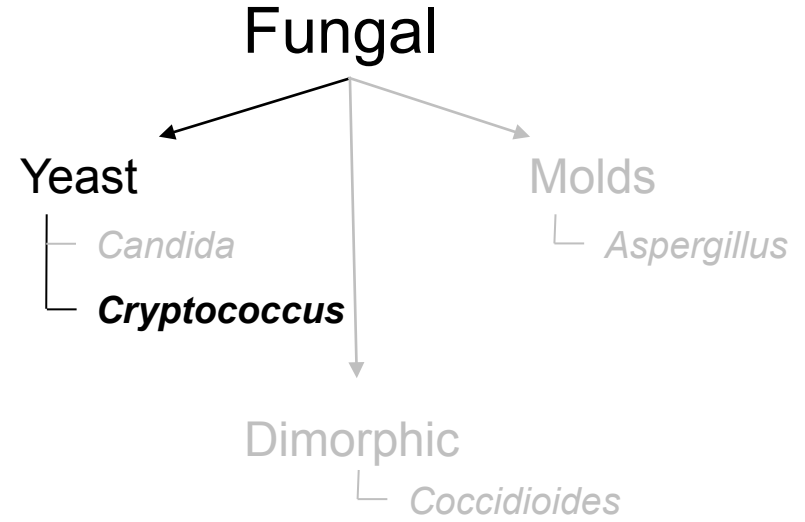
Is being immunocompromised a risk factor for *Cryptococcus endophthalmitis*?



Endogenous Endophthalmitis



Is being immunocompromised a risk factor for Cryptococcus endophthalmitis?
Definitely. Cryptococcus is a common fungal ocular infection in HIV/AIDS.



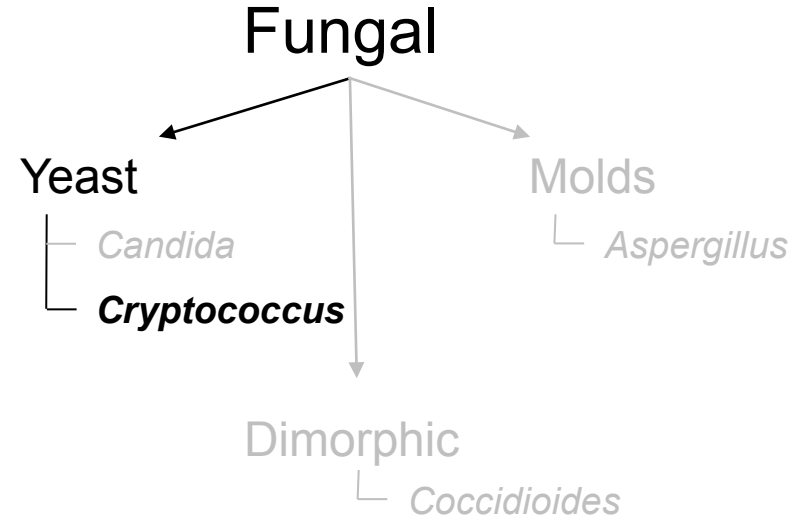
Endogenous Endophthalmitis



Is being immunocompromised a risk factor for Cryptococcus endophthalmitis?

Definitely. Cryptococcus is a common fungal ocular infection in HIV/AIDS.

Cryptococcus is notorious for causing what nonocular condition in HIV/AIDS pts?



Endogenous Endophthalmitis

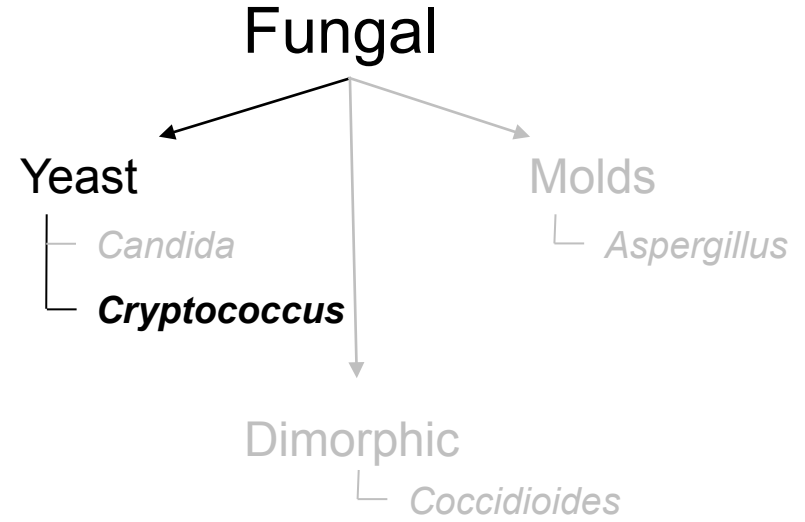


Is being immunocompromised a risk factor for Cryptococcus endophthalmitis?

Definitely. Cryptococcus is a common fungal ocular infection in HIV/AIDS.

Cryptococcus is notorious for causing what nonocular condition in HIV/AIDS pts?

Fungal meningitis



Endogenous Endophthalmitis



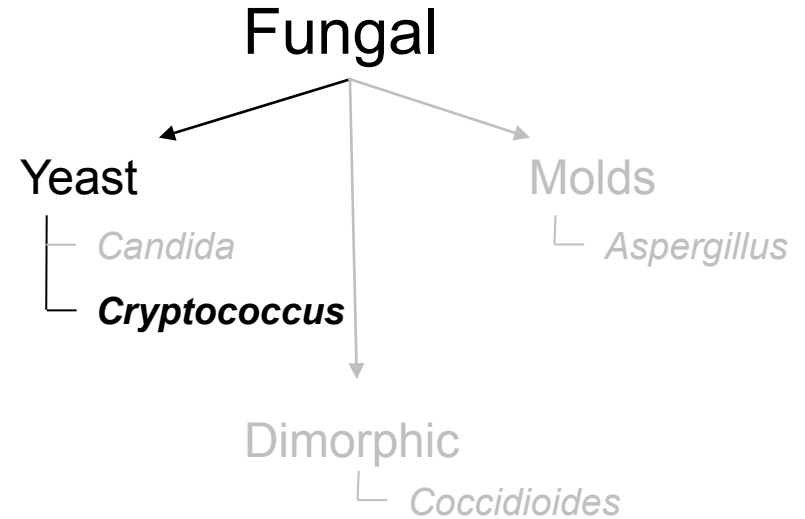
Is being immunocompromised a risk factor for Cryptococcus endophthalmitis?

Definitely. Cryptococcus is a common fungal ocular infection in HIV/AIDS.

Cryptococcus is notorious for causing what nonocular condition in HIV/AIDS pts?

Fungal meningitis

Who is at risk for Cryptococcus endophthalmitis?



Endogenous Endophthalmitis



Is being immunocompromised a risk factor for Cryptococcus endophthalmitis?

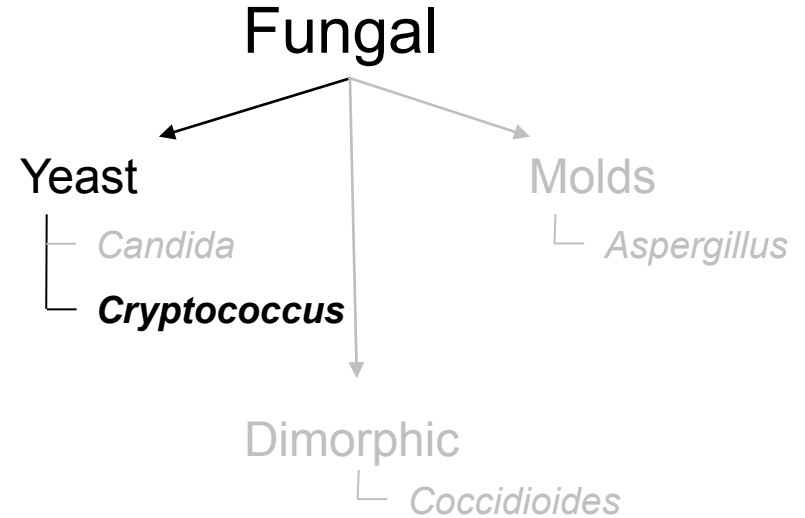
Definitely. Cryptococcus is a common fungal ocular infection in HIV/AIDS.

Cryptococcus is notorious for causing what nonocular condition in HIV/AIDS pts?

Fungal meningitis

Who is at risk for Cryptococcus endophthalmitis?

An HIV/AIDS pt with cryptococcal meningitis



Endogenous Endophthalmitis



Is being immunocompromised a risk factor for Cryptococcus endophthalmitis?

Definitely. Cryptococcus is a common fungal ocular infection in HIV/AIDS.

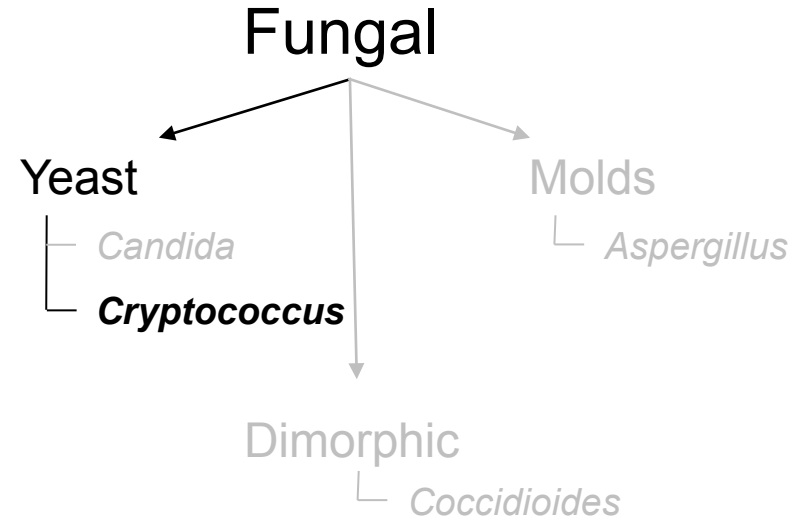
Cryptococcus is notorious for causing what nonocular condition in HIV/AIDS pts?

Fungal meningitis

Who is at risk for Cryptococcus endophthalmitis?

An HIV/AIDS pt with cryptococcal meningitis

How does Cryptococcus endophthalmitis present?



Endogenous Endophthalmitis



Is being immunocompromised a risk factor for Cryptococcus endophthalmitis?

Definitely. Cryptococcus is a common fungal ocular infection in HIV/AIDS.

Cryptococcus is notorious for causing what nonocular condition in HIV/AIDS pts?

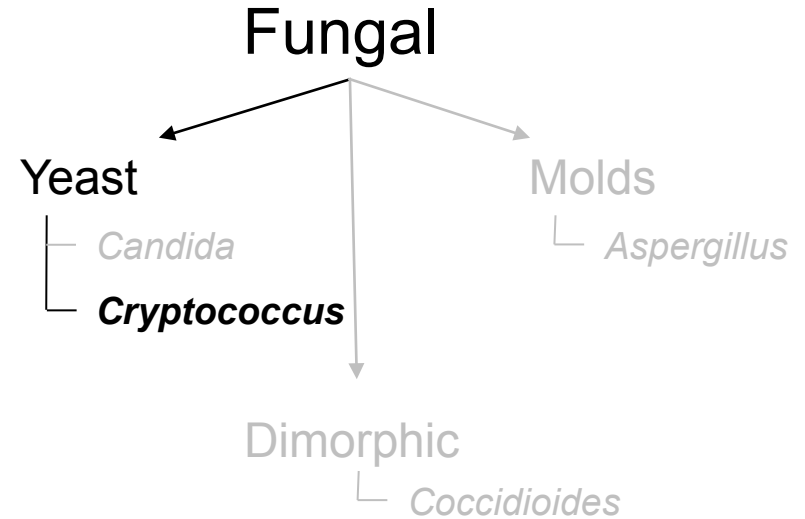
Fungal meningitis

Who is at risk for Cryptococcus endophthalmitis?

An HIV/AIDS pt with cryptococcal meningitis

How does Cryptococcus endophthalmitis present?

As with *Candida*, it starts with choroidal lesions, and pts will c/o decreased VA if one of the lesions affects the macular region.



Endogenous Endophthalmitis



Is being immunocompromised a risk factor for *Cryptococcus endophthalmitis*?

Definitely. *Cryptococcus* is a common fungal ocular infection in HIV/AIDS.

Cryptococcus is notorious for causing what nonocular condition in HIV/AIDS pts?

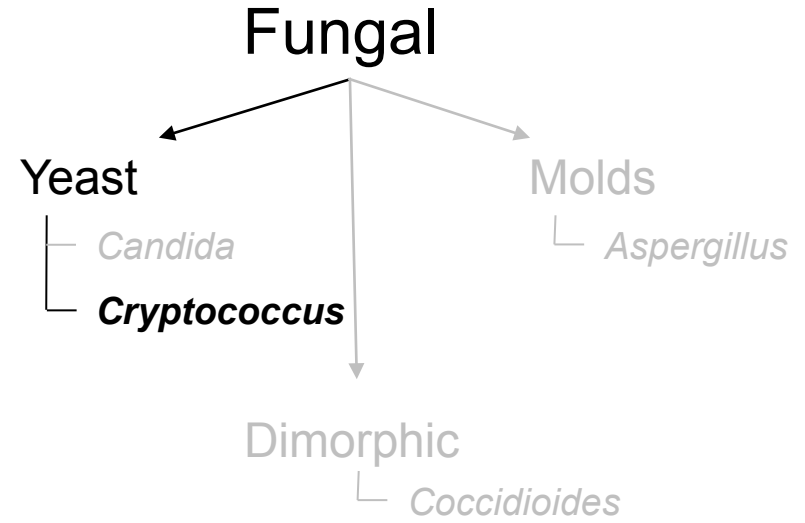
Fungal meningitis

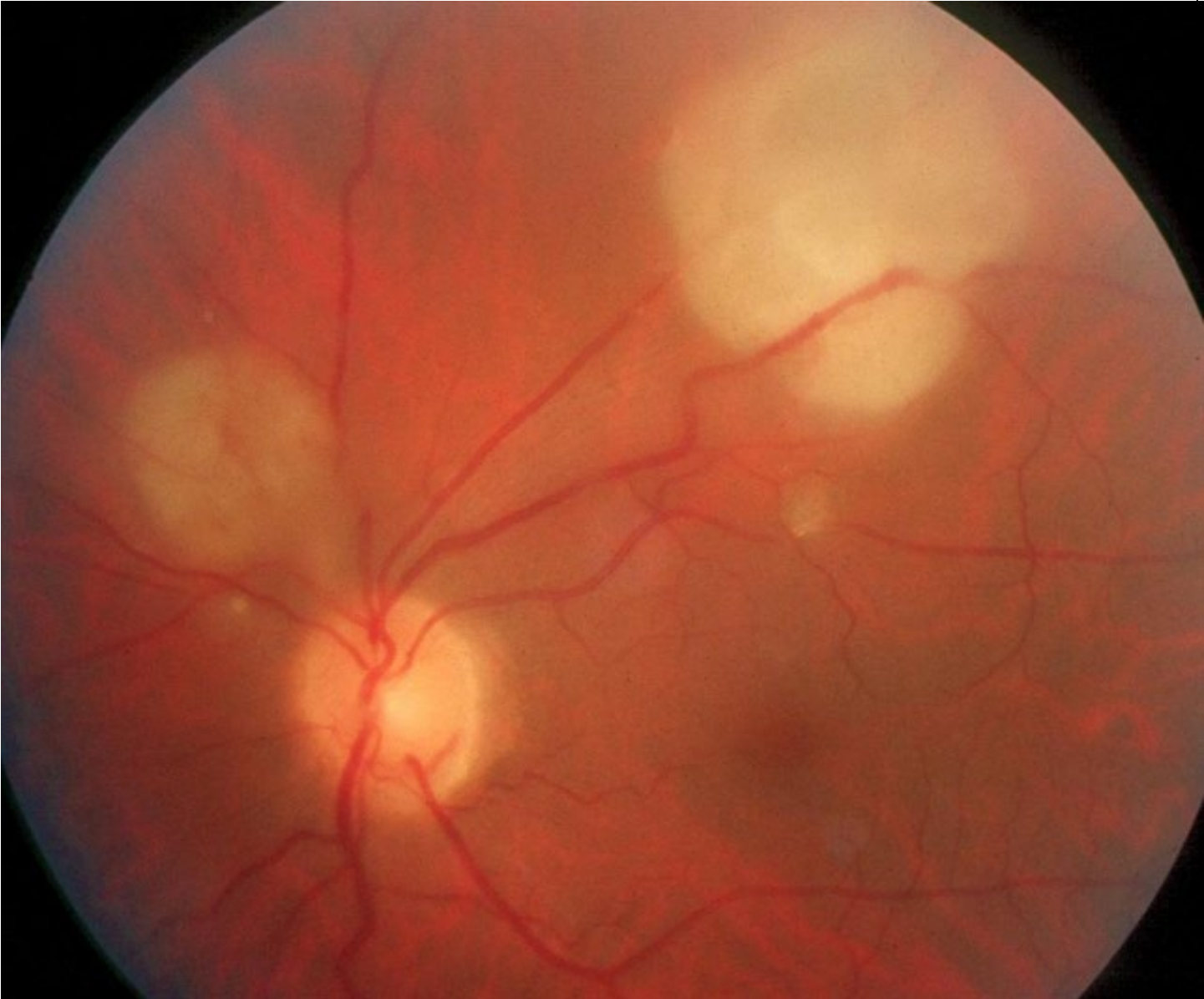
Who is at risk for *Cryptococcus endophthalmitis*?

An HIV/AIDS pt with cryptococcal meningitis

How does *Cryptococcus endophthalmitis* present?

As with *Candida*, it starts with choroidal lesions, and pts will c/o decreased VA if one of the lesions affects the macular region. Unlike *Candida*, the choroidal lesions tend to be **larger** and **fewer in number**.





Cryptococcus endophthalmitis

Endogenous Endophthalmitis



Is being immunocompromised a risk factor for Cryptococcus endophthalmitis?

Definitely. Cryptococcus is a common fungal ocular infection in HIV/AIDS.

Cryptococcus is notorious for causing what nonocular condition in HIV/AIDS pts?

Fungal meningitis

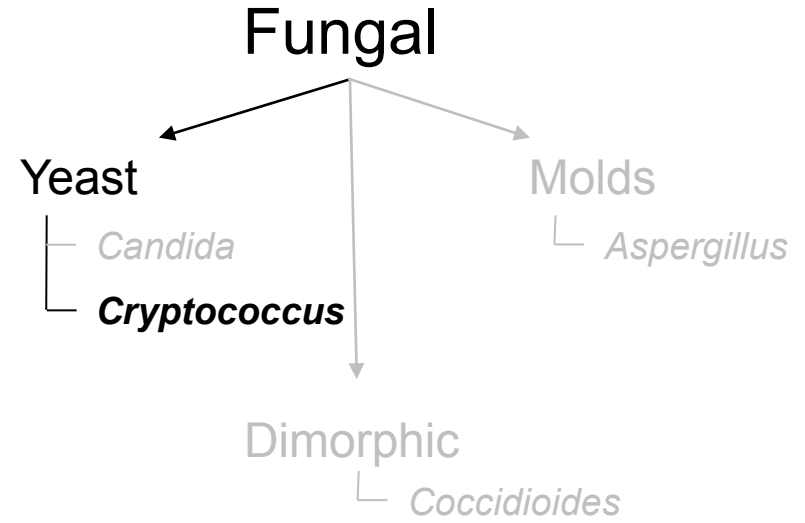
Who is at risk for Cryptococcus endophthalmitis?

An HIV/AIDS pt with cryptococcal meningitis


How does Cryptococcus endophthalmitis present?

As with *Candida*, it starts with choroidal lesions, and pts will c/o decreased VA if one of the lesions affects the macular region. Unlike *Candida*, the choroidal lesions tend to be **larger** and **fewer in number**.

The ONH may be edematous--why?



Endogenous Endophthalmitis



Is being immunocompromised a risk factor for Cryptococcus endophthalmitis?

Definitely. Cryptococcus is a common fungal ocular infection in HIV/AIDS.

Cryptococcus is notorious for causing what nonocular condition in HIV/AIDS pts?

Fungal meningitis

Who is at risk for Cryptococcus endophthalmitis?

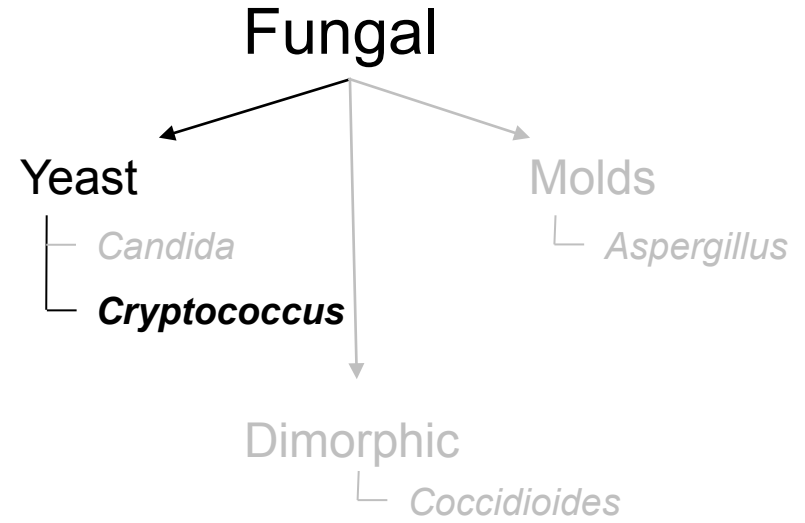
An HIV/AIDS pt with cryptococcal meningitis

How does Cryptococcus endophthalmitis present?

As with *Candida*, it starts with choroidal lesions, and pts will c/o decreased VA if one of the lesions affects the macular region. Unlike *Candida*, the choroidal lesions tend to be **larger** and **fewer in number**.

The ONH may be edematous--why?

Because of concomitant meningitis and increased ICP



Endogenous Endophthalmitis



Is being immunocompromised a risk factor for Cryptococcus endophthalmitis?

Definitely. Cryptococcus is a common fungal ocular infection in HIV/AIDS.

Cryptococcus is notorious for causing what nonocular condition in HIV/AIDS pts?

Fungal meningitis

Who is at risk for Cryptococcus endophthalmitis?

An HIV/AIDS pt with cryptococcal meningitis

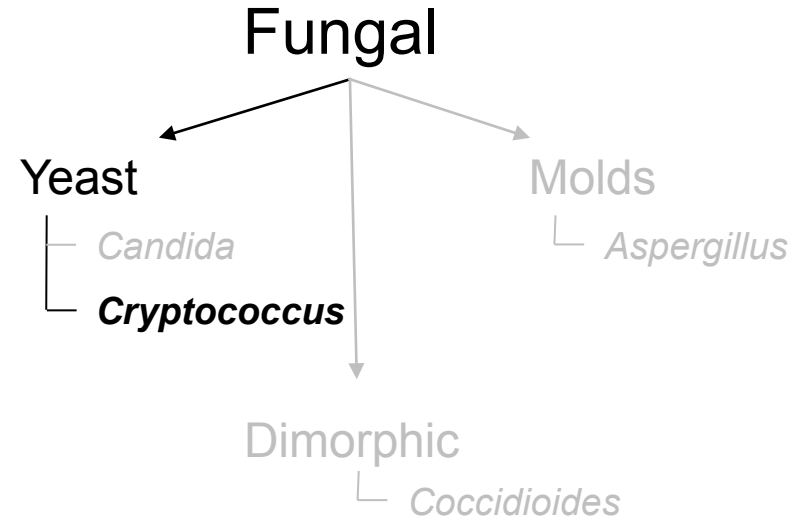
How does Cryptococcus endophthalmitis present?

As with *Candida*, it starts with choroidal lesions, and pts will c/o decreased VA if one of the lesions affects the macular region. Unlike *Candida*, the choroidal lesions tend to be **larger** and **fewer in number**.

The ONH may be edematous--why?

Because of concomitant meningitis and increased ICP

How is Cryptococcus endophthalmitis managed?



Endogenous Endophthalmitis



Is being immunocompromised a risk factor for Cryptococcus endophthalmitis?

Definitely. Cryptococcus is a common fungal ocular infection in HIV/AIDS.

Cryptococcus is notorious for causing what nonocular condition in HIV/AIDS pts?

Fungal meningitis

Who is at risk for Cryptococcus endophthalmitis?

An HIV/AIDS pt with cryptococcal meningitis

How does Cryptococcus endophthalmitis present?

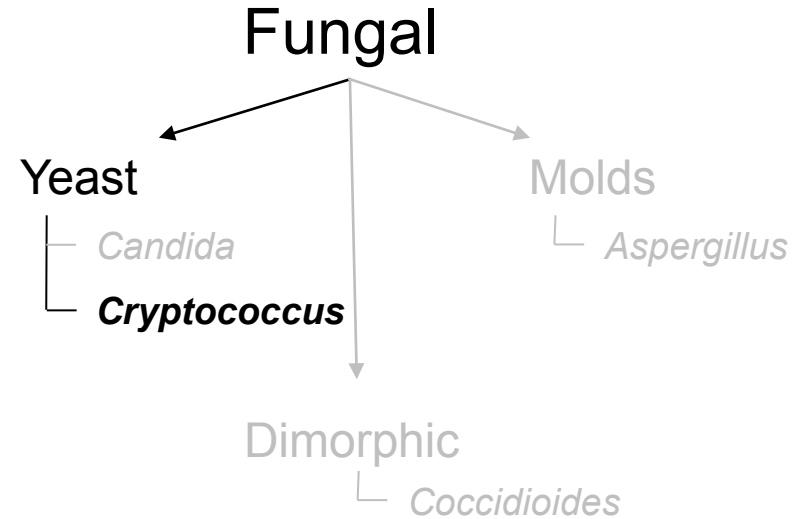
As with *Candida*, it starts with choroidal lesions, and pts will c/o decreased VA if one of the lesions affects the macular region. Unlike *Candida*, the choroidal lesions tend to be **larger** and **fewer in number**.

The ONH may be edematous--why?


Because of concomitant meningitis and increased ICP

How is Cryptococcus endophthalmitis managed?

Intravenous Ampho B is the mainstay of treatment



Endogenous Endophthalmitis



Is *Aspergillus* a common cause of endogenous fungal endophthalmitis?

Fungal

Molds


└ *Aspergillus*

Dimorphic

└ *Coccidioides*

Candida
coccus

Endogenous Endophthalmitis



Is *Aspergillus* a common cause of endogenous fungal endophthalmitis?
No, it is quite rare

Fungal


Molds

└ *Aspergillus*

Dimorphic

└ *Coccidioides*

Endogenous Endophthalmitis



Is Aspergillus a common cause of endogenous fungal endophthalmitis?

No, it is quite rare

Generally, speaking, who is at risk?

Fungal

Molds

└ ***Aspergillus***

Dimorphic

└ *Coccidioides*

*Haemophilus
coccus*

Endogenous Endophthalmitis



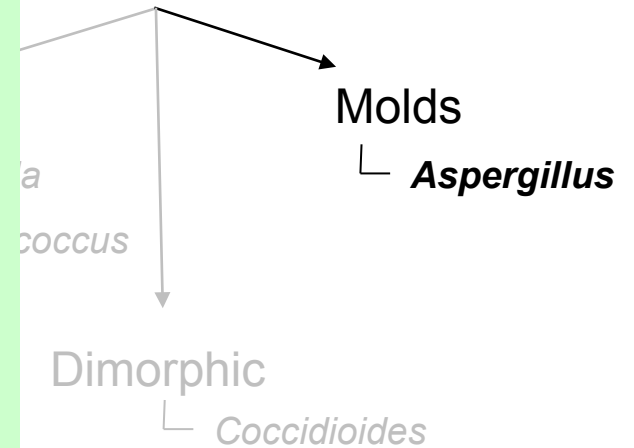
Is *Aspergillus* a common cause of endogenous fungal endophthalmitis?

No, it is quite rare

Generally, speaking, who is at risk?

Very debilitated individuals--those with chronic severe lung dz, cancer, endocarditis, or severely immunocompromised. One group particularly at risk are those who have undergone major medical procedure (two words)

Fungal



Endogenous Endophthalmitis


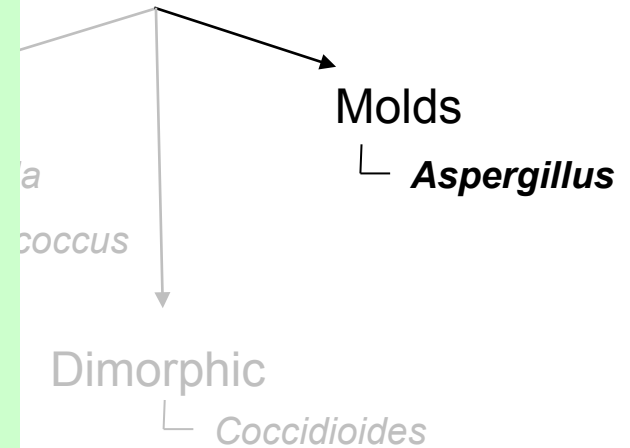
Is *Aspergillus* a common cause of endogenous fungal endophthalmitis?
No, it is quite rare

Generally, speaking, who is at risk?

Very debilitated individuals--those with chronic severe lung dz, cancer, endocarditis, or severely immunocompromised. One group particularly at risk are those who have undergone **liver transplantation**.

A *aspergillus*
fter liver transplant

Fungal



Endogenous Endophthalmitis



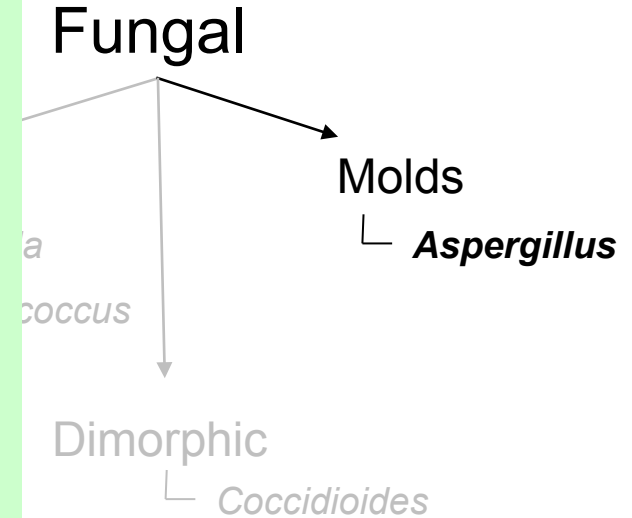
Is Aspergillus a common cause of endogenous fungal endophthalmitis?

No, it is quite rare

Generally, speaking, who is at risk?

Very debilitated individuals--those with chronic severe lung dz, cancer, endocarditis, or severely immunocompromised. One group particularly at risk are those who have undergone **liver transplantation**.

How does Aspergillus endophthalmitis present?



Endogenous Endophthalmitis



Is Aspergillus a common cause of endogenous fungal endophthalmitis?

No, it is quite rare

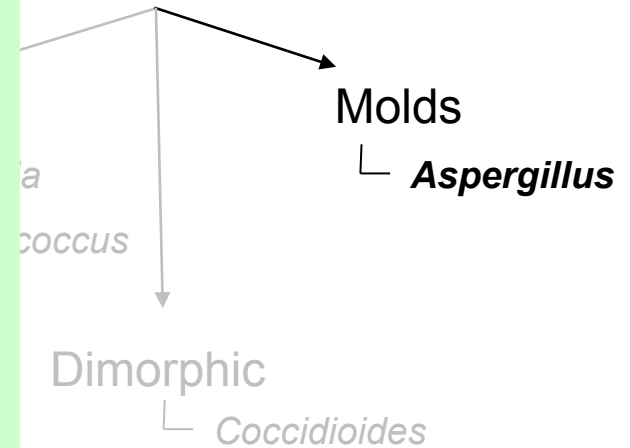
Generally, speaking, who is at risk?

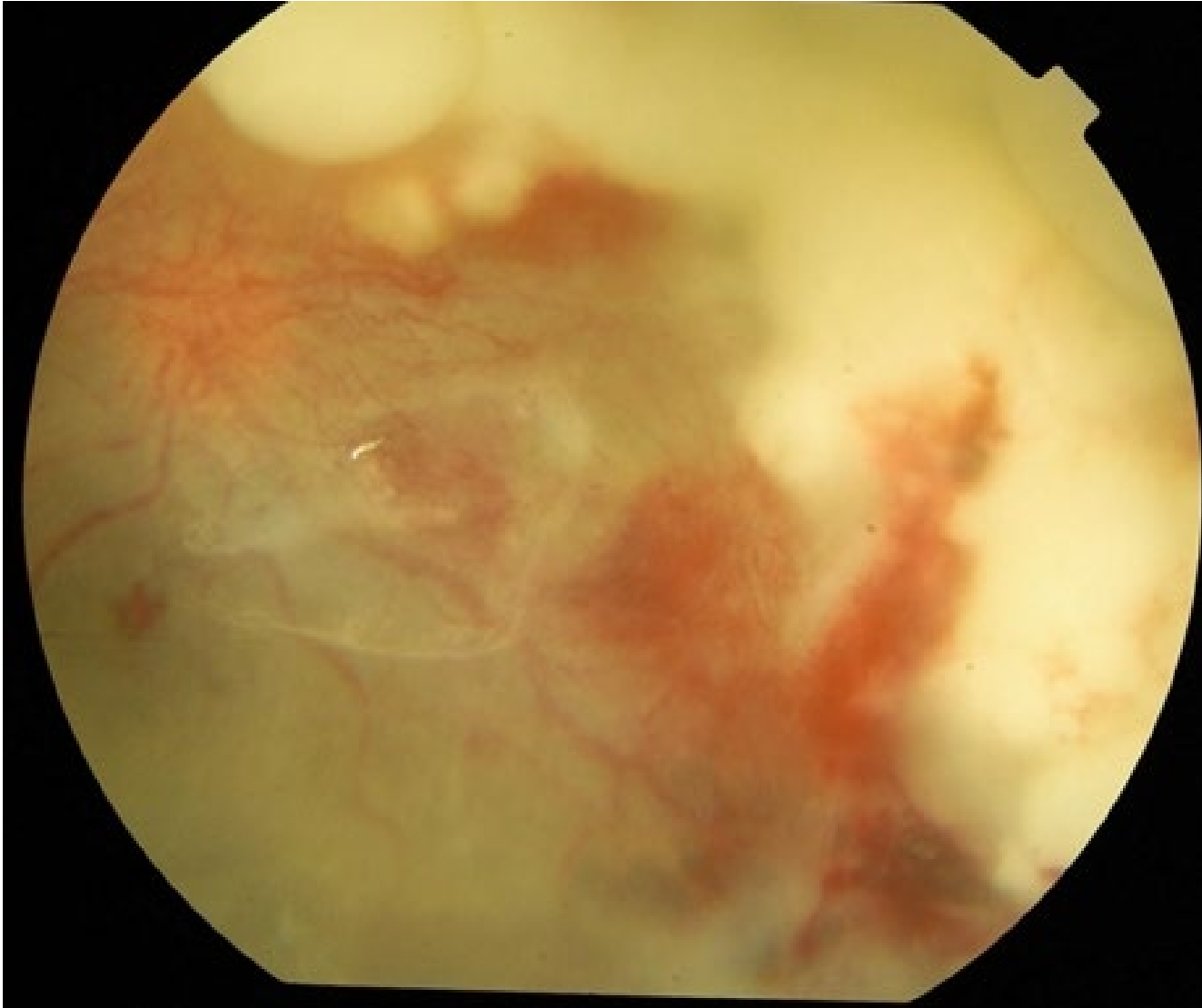
Very debilitated individuals--those with chronic severe lung dz, cancer, endocarditis, or severely immunocompromised. One group particularly at risk are those who have undergone **liver transplantation**.

How does Aspergillus endophthalmitis present?

Unlike other fungal entities, the onset of pain and vision loss is fairly acute. The choroidal lesions are **large, macular**, and often accompanied by **hemorrhagic choroidal and/or retinal lesions**. (Unlike the other fungal pathogens discussed, *Aspergillus* has a propensity for invading blood vessels.)

Fungal





Aspergillus endophthalmitis

Endogenous Endophthalmitis



Is Aspergillus a common cause of endogenous fungal endophthalmitis?

No, it is quite rare

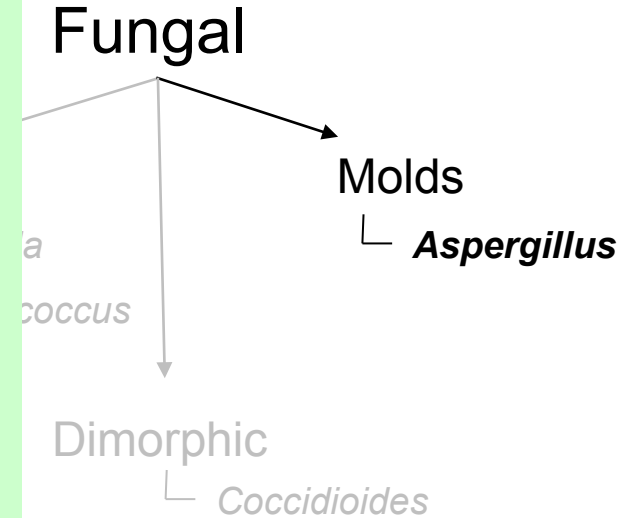
Generally, speaking, who is at risk?

Very debilitated individuals--those with chronic severe lung dz, cancer, endocarditis, or severely immunocompromised. One group particularly at risk are those who have undergone **liver transplantation**.


How does Aspergillus endophthalmitis present?

Unlike other fungal entities, the onset of pain and vision loss is fairly acute. The choroidal lesions are **large, macular**, and often accompanied by **hemorrhagic choroidal and/or retinal lesions**. (Unlike the other fungal pathogens discussed, *Aspergillus* has a propensity for invading blood vessels.)

What about the vitreous?



Endogenous Endophthalmitis



Is Aspergillus a common cause of endogenous fungal endophthalmitis?

No, it is quite rare

Generally, speaking, who is at risk?

Very debilitated individuals--those with chronic severe lung dz, cancer, endocarditis, or severely immunocompromised. One group particularly at risk are those who have undergone **liver transplantation**.

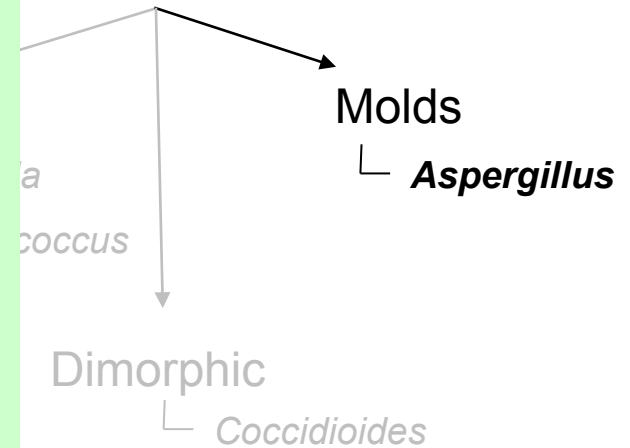
How does Aspergillus endophthalmitis present?

Unlike other fungal entities, the onset of pain and vision loss is fairly acute. The choroidal lesions are **large, macular**, and often accompanied by **hemorrhagic choroidal and/or retinal lesions**. (Unlike the other fungal pathogens discussed, *Aspergillus* has a propensity for invading blood vessels.)

What about the vitreous?

Unlike *Candida* endophthalmitis (in which vitreous inflammation may be prominent), the vitreous reaction in *Aspergillus* endophthalmitis tends to be mild. This dz focuses on the choroid and retina.

Fungal



Endogenous Endophthalmitis



Is Aspergillus a common cause of endogenous fungal endophthalmitis?
No, it is quite rare

Generally, speaking, who is at risk?

Very debilitated individuals--those with chronic severe lung dz, cancer, endocarditis, or severely immunocompromised. One group particularly at risk are those who have undergone **liver transplantation**.

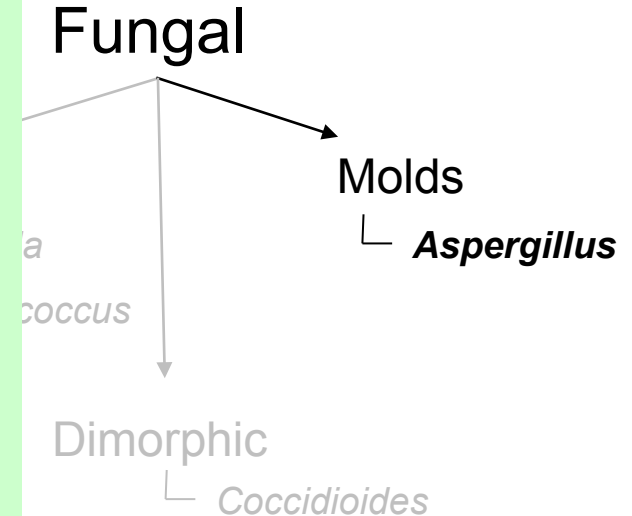
How does Aspergillus endophthalmitis present?

Unlike other fungal entities, the onset of pain and vision loss is fairly acute. The choroidal lesions are **large, macular**, and often accompanied by **hemorrhagic choroidal and/or retinal lesions**. (Unlike the other fungal pathogens discussed, *Aspergillus* has a propensity for invading blood vessels.)


What about the vitreous?

Unlike *Candida* endophthalmitis (in which vitreous inflammation may be prominent), the vitreous reaction in *Aspergillus* endophthalmitis tends to be mild. This dz focuses on the choroid and retina.

While technically incorrect, it is helpful to think of it this way:



Endogenous Endophthalmitis



Is Aspergillus a common cause of endogenous fungal endophthalmitis?
No, it is quite rare

Generally, speaking, who is at risk?

Very debilitated individuals--those with chronic severe lung dz, cancer, endocarditis, or severely immunocompromised. One group particularly at risk are those who have undergone **liver transplantation**.

How does Aspergillus endophthalmitis present?

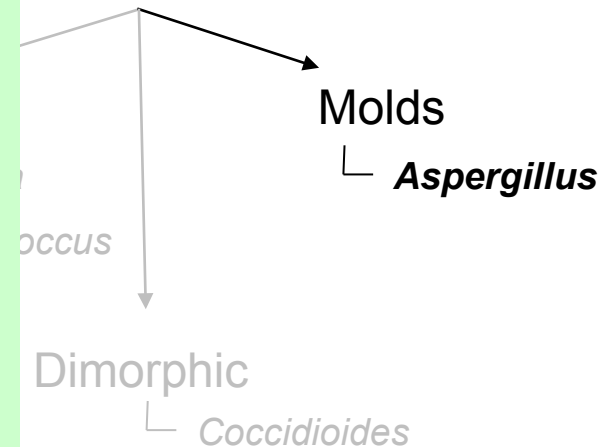
Unlike other fungal entities, the onset of pain and vision loss is fairly acute. The choroidal lesions are **large, macular**, and often accompanied by **hemorrhagic choroidal and/or retinal lesions**. (Unlike the other fungal pathogens discussed, *Aspergillus* has a propensity for invading blood vessels.)

What about the vitreous?

Unlike **Candida endophthalmitis (in which vitreous inflammation may be prominent)**, the vitreous reaction in *Aspergillus* endophthalmitis tends to be mild. This dz focuses on the choroid and retina.

While technically incorrect, it is helpful to think of it this way:
--*Candida* endophthalmitis is a dz of the vitreous, whereas

Fungal



Endogenous Endophthalmitis



Is Aspergillus a common cause of endogenous fungal endophthalmitis?
No, it is quite rare

Generally, speaking, who is at risk?

Very debilitated individuals--those with chronic severe lung dz, cancer, endocarditis, or severely immunocompromised. One group particularly at risk are those who have undergone **liver transplantation**.

How does Aspergillus endophthalmitis present?

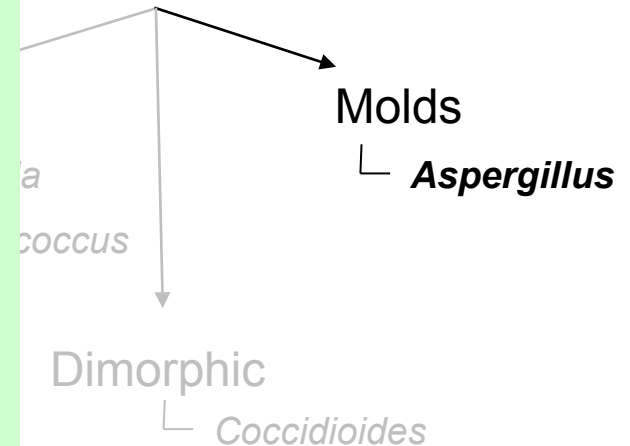
Unlike other fungal entities, the onset of pain and vision loss is fairly acute. The choroidal lesions are **large, macular**, and often accompanied by **hemorrhagic choroidal and/or retinal lesions**. (Unlike the other fungal pathogens discussed, *Aspergillus* has a propensity for invading blood vessels.)

What about the vitreous?


Unlike *Candida* endophthalmitis (in which vitreous inflammation may be prominent), the vitreous reaction in *Aspergillus* endophthalmitis tends to be mild. **This dz focuses on the choroid and retina.**

While technically incorrect, it is helpful to think of it this way:
--*Candida* endophthalmitis is a dz of the vitreous, whereas
--*Aspergillus* endophthalmitis is a dz of the retina/choroid

Fungal



Endogenous Endophthalmitis



Is Aspergillus a common cause of endogenous fungal endophthalmitis?

No, it is quite rare

Generally, speaking, who is at risk?

Very debilitated individuals--those with chronic severe lung dz, cancer, endocarditis, or severely immunocompromised. One group particularly at risk are those who have undergone **liver transplantation**.

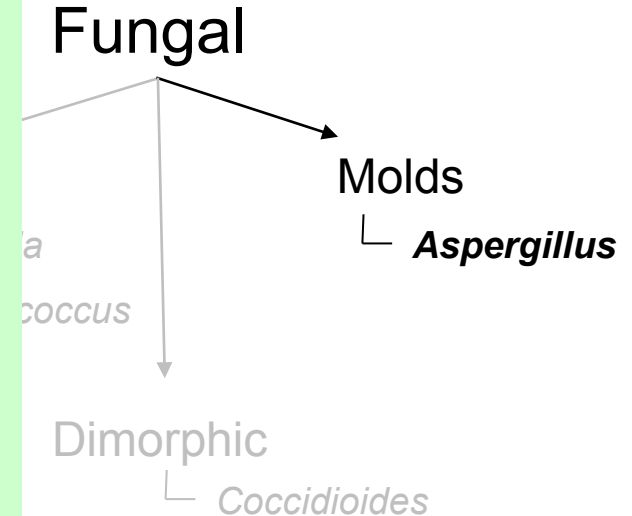
How does Aspergillus endophthalmitis present?

Unlike other fungal entities, the onset of pain and vision loss is fairly acute. The choroidal lesions are **large, macular**, and often accompanied by **hemorrhagic choroidal and/or retinal lesions**. (Unlike the other fungal pathogens discussed, *Aspergillus* has a propensity for invading blood vessels.)

What about the vitreous?

Unlike *Candida* endophthalmitis (in which vitreous inflammation may be prominent), the vitreous reaction in *Aspergillus* endophthalmitis tends to be mild. This dz focuses on the choroid and retina.

How is Aspergillus endophthalmitis managed?



Endogenous Endophthalmitis



Is Aspergillus a common cause of endogenous fungal endophthalmitis?

No, it is quite rare

Generally, speaking, who is at risk?

Very debilitated individuals--those with chronic severe lung dz, cancer, endocarditis, or severely immunocompromised. One group particularly at risk are those who have undergone **liver transplantation**.

How does Aspergillus endophthalmitis present?

Unlike other fungal entities, the onset of pain and vision loss is fairly acute. The choroidal lesions are **large, macular**, and often accompanied by **hemorrhagic choroidal and/or retinal lesions**. (Unlike the other fungal pathogens discussed, *Aspergillus* has a propensity for invading blood vessels.)

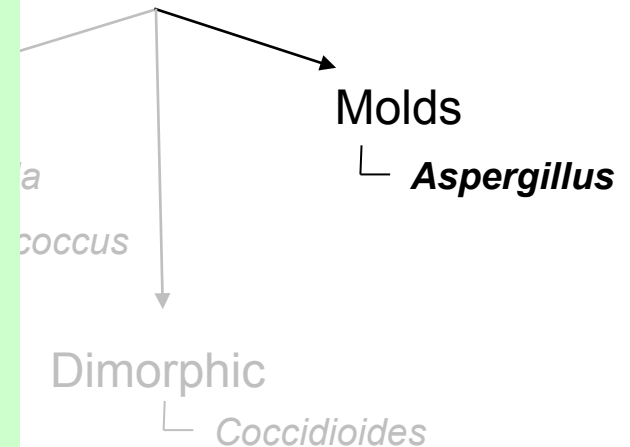
What about the vitreous?

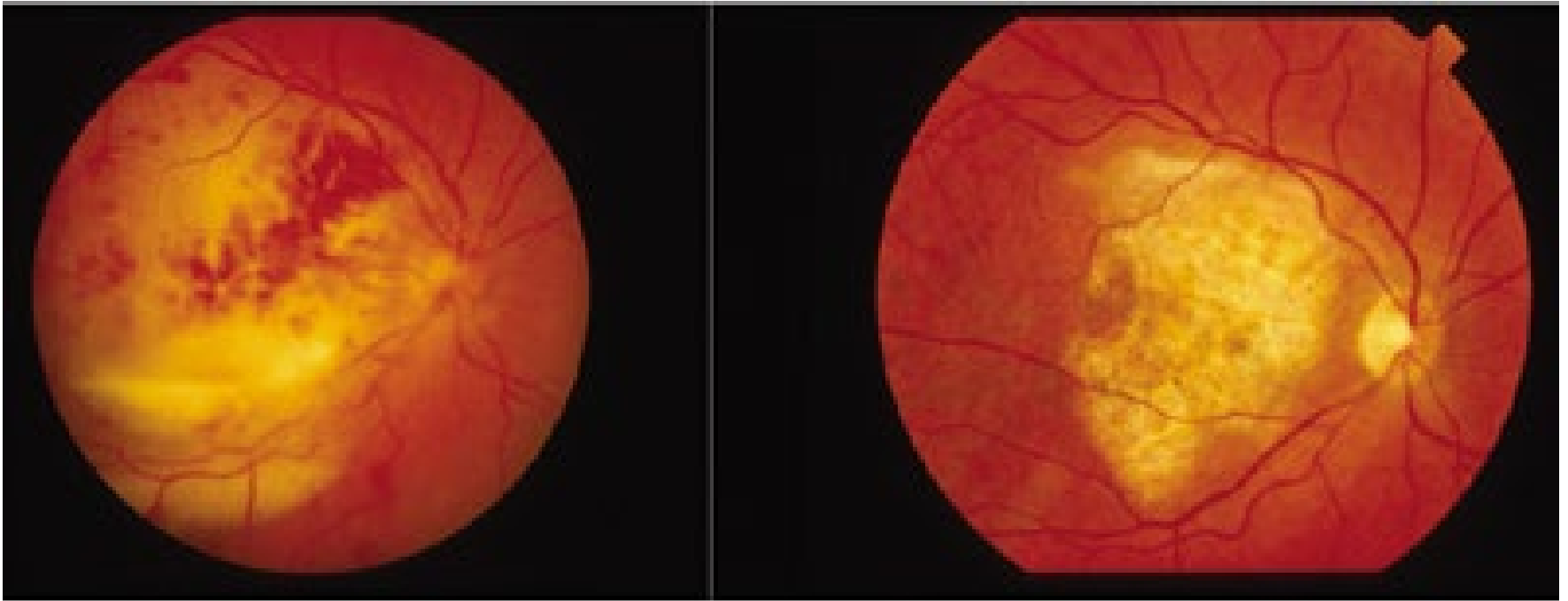
Unlike *Candida* endophthalmitis (in which vitreous inflammation may be prominent), the vitreous reaction in *Aspergillus* endophthalmitis tends to be mild. This dz focuses on the choroid and retina.

How is Aspergillus endophthalmitis managed?

It is an aggressive dz, so aggressive management is the norm. PPV, intravitreal *and* IV Ampho B, PO antifungals--the whole shebang. Despite aggressive management, VA outcomes are generally poor.

Fungal





Aspergillus endophthalmitis: Pre- and post tx

Endogenous Endophthalmitis



Is Aspergillus a common cause of endogenous fungal endophthalmitis?
No, it is quite rare

Generally, speaking, who is at risk?

Very debilitated individuals--those with chronic severe lung dz, cancer, endocarditis, or severely immunocompromised. One group particularly at risk are those who have undergone **liver transplantation**.

How does Aspergillus endophthalmitis present?

Unlike other fungal entities, the onset of pain and vision loss is fairly acute. The choroidal lesions are **large, macular**, and often accompanied by **hemorrhagic choroidal and/or retinal lesions**. (Unlike the other fungal pathogens discussed, *Aspergillus* has a propensity for invading blood vessels.)

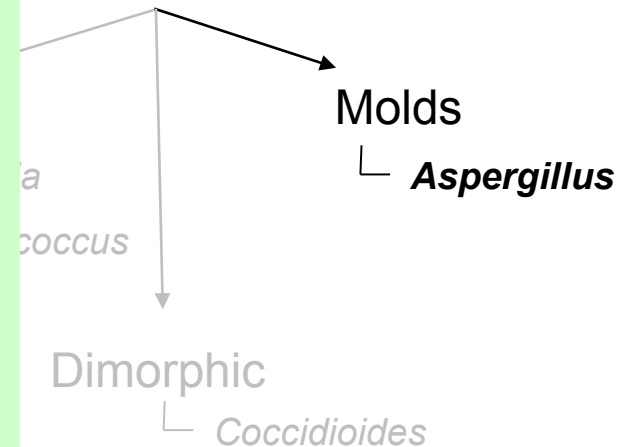
What about the vitreous?

Unlike *Candida* endophthalmitis (in which the vitreous is often prominent), the vitreous reaction in *Aspergillus* is typically to be mild. This dz focuses on the choroid.

How is Aspergillus endophthalmitis managed?

It is an aggressive dz, so aggressive management is the norm. PPV, intravitreal *and* IV Ampho B, PO antifungals--the whole shebang. Despite aggressive management, **VA outcomes are generally poor**.

Fungal



Why are visual outcomes poor in Aspergillus endophthalmitis?

Endogenous Endophthalmitis



Is Aspergillus a common cause of endogenous fungal endophthalmitis?
No, it is quite rare

Generally, speaking, who is at risk?

Very debilitated individuals--those with chronic severe lung dz, cancer, endocarditis, or severely immunocompromised. One group particularly at risk are those who have undergone **liver transplantation**.

How does Aspergillus endophthalmitis present?

Unlike other fungal entities, the onset of pain and vision loss is fairly acute. The choroidal lesions are **large, macular**, and often accompanied by **hemorrhagic choroidal and/or retinal lesions**. (Unlike the other fungal pathogens discussed, **Aspergillus has a propensity for invading blood vessels.**)

What about the vitreous?

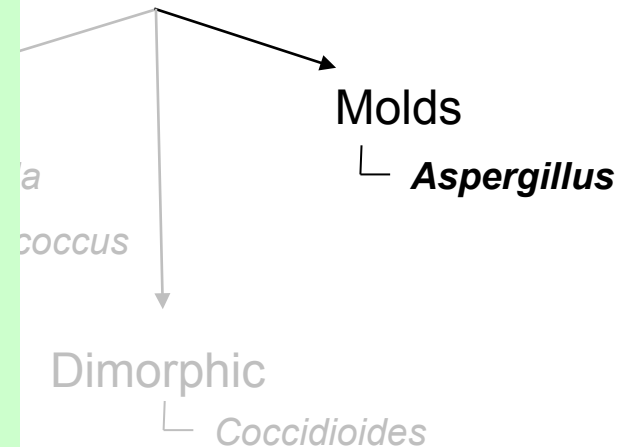
Unlike Candida endophthalmitis (in which vitreous opacities are prominent), the vitreous opacities in Aspergillus endophthalmitis tend to be mild. This dz focu

Why are visual outcomes poor in Aspergillus endophthalmitis?
Its tendency to invade blood vessels leads to ischemic maculopathy

How is Aspergillus endophthalmitis managed?

It is an aggressive dz, so aggressive management is the norm. PPV, intravitreal *and* IV Ampho B, PO antifungals--the whole shebang. Despite aggressive management, **VA outcomes are generally poor.**

Fungal



Endogenous Endophthalmitis



Bacterial

Fungal

Is Coccidioides a common cause of endogenous endophthalmitis?

andida

tococcus

Molds

└ *Aspergillus*

Dimorphic

└ ***Coccidioides***

Endogenous Endophthalmitis



Bacterial

Fungal

Is Coccidioides a common cause of endogenous endophthalmitis?
No, it is VERY rare. It is vastly more likely to cause diseases of the ocular surface (eg, conjunctivitis)

Clavaria

Botrytis

Molds

└ *Aspergillus*

Dimorphic

└ ***Coccidioides***

Endogenous Endophthalmitis

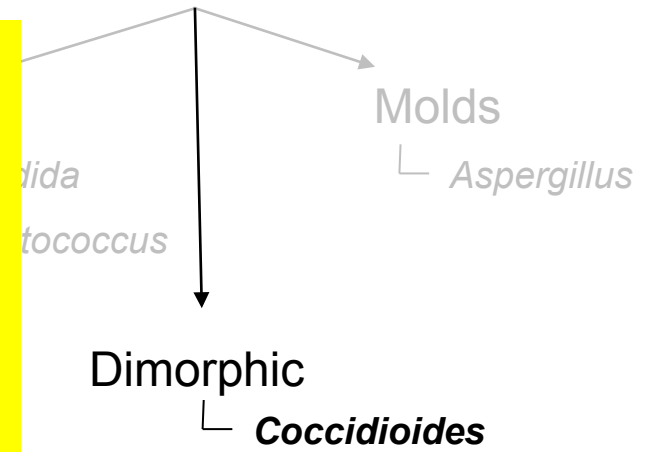


Bacterial

Fungal

Is Coccidioides a common cause of endogenous endophthalmitis?
No, it is VERY rare. It is vastly more likely to cause diseases of the ocular surface (eg, conjunctivitis)

What is the classic geographic location for this organism?



Endogenous Endophthalmitis



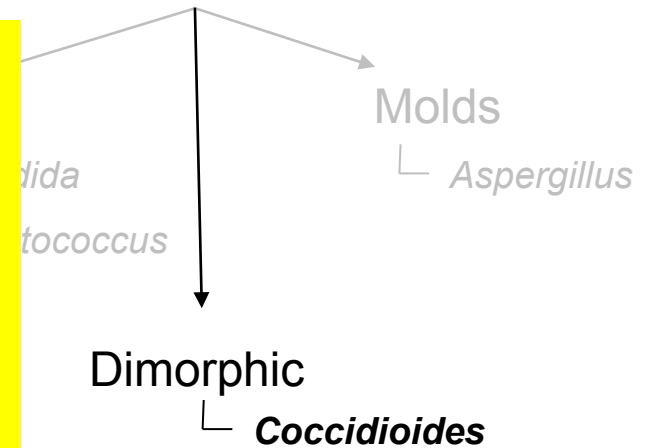
Bacterial

Fungal

Is Coccidioides a common cause of endogenous endophthalmitis?
No, it is VERY rare. It is vastly more likely to cause diseases of the ocular surface (eg, conjunctivitis)

What is the classic geographic location for this organism?

The San Joaquin Valley of central California. It is also found in the Southwest, Mexico and Argentina.



Endogenous Endophthalmitis



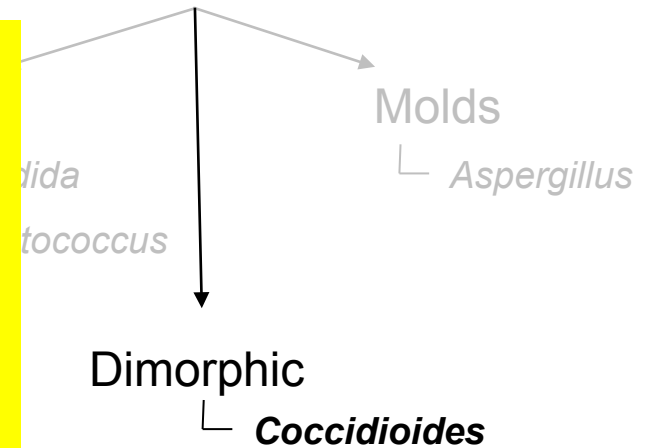
Bacterial

Fungal

Is Coccidioides a common cause of endogenous endophthalmitis?
No, it is VERY rare. It is vastly more likely to cause diseases of the ocular surface (eg, conjunctivitis)

What is the classic geographic location for this organism?
The San Joaquin Valley of central California. It is also found in the Southwest, Mexico and Argentina.

How does Coccidioides endophthalmitis present?



Endogenous Endophthalmitis



Bacterial

Fungal

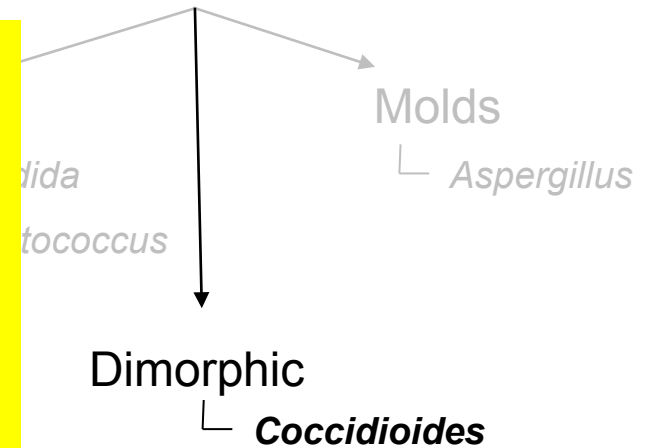
Is Coccidioides a common cause of endogenous endophthalmitis?
No, it is VERY rare. It is vastly more likely to cause diseases of the ocular surface (eg, conjunctivitis)

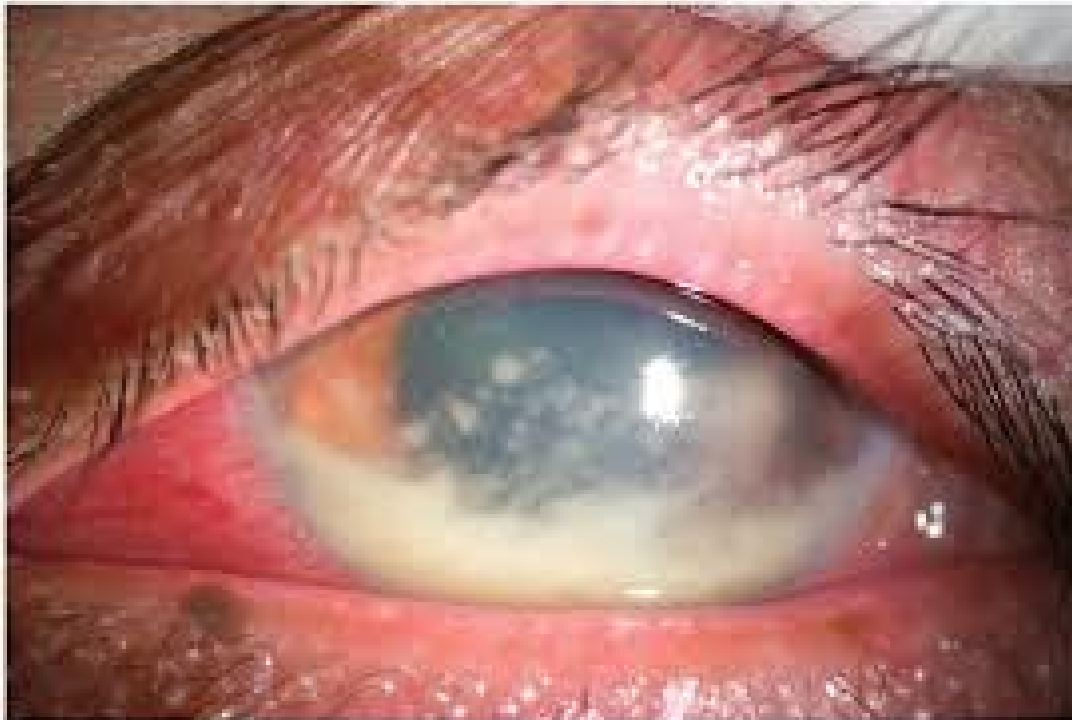
What is the classic geographic location for this organism?

The San Joaquin Valley of central California. It is also found in the Southwest, Mexico and Argentina.

How does Coccidioides endophthalmitis present?

Unlike other fungal entities, the anterior segment tends to be as affected as the posterior. Pts typically present with a **granulomatous uveitis** (including large **iris granulomas**), accompanied by chorioretinal lesions of the sort seen in *Candida* endophthalmitis.





Coccidioides endophthalmitis

Endogenous Endophthalmitis



Bacterial

Fungal

Is Coccidioides a common cause of endogenous endophthalmitis?
No, it is VERY rare. It is vastly more likely to cause diseases of the ocular surface (eg, conjunctivitis)

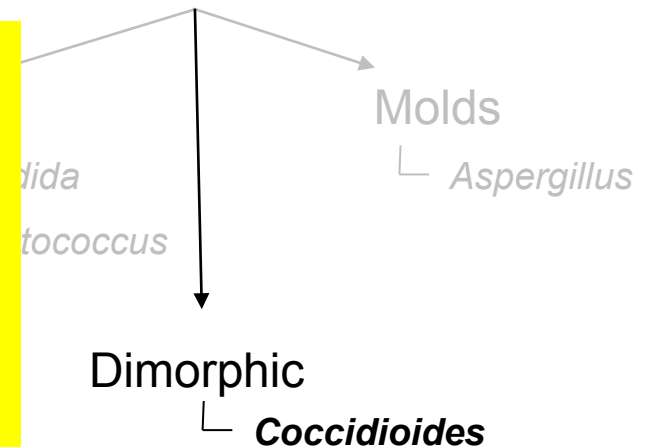
What is the classic geographic location for this organism?

The San Joaquin Valley of central California. It is also found in the Southwest, Mexico and Argentina.

How does Coccidioides endophthalmitis present?

Unlike other fungal entities, the anterior segment tends to be as affected as the posterior. Pts typically present with a **granulomatous uveitis** (including large **iris granulomas**), accompanied by chorioretinal lesions of the sort seen in *Candida* endophthalmitis.

How is Coccidioides endophthalmitis managed?



Endogenous Endophthalmitis



Bacterial

Fungal

Is Coccidioides a common cause of endogenous endophthalmitis?
No, it is VERY rare. It is vastly more likely to cause diseases of the ocular surface (eg, conjunctivitis)

What is the classic geographic location for this organism?
The San Joaquin Valley of central California. It is also found in the Southwest, Mexico and Argentina.

How does Coccidioides endophthalmitis present?
Unlike other fungal entities, the anterior segment tends to be as affected as the posterior. Pts typically present with a **granulomatous uveitis** (including large **iris granulomas**), accompanied by chorioretinal lesions of the sort seen in *Candida* endophthalmitis.

How is Coccidioides endophthalmitis managed?
PO itraconazole unless very severe (in which case Ampho B).
Severe cases may require PPV, and iris granulomas may need to be surgically debulked.

