

# Endogenous Endophthalmitis: Diagnosis and Treatment

**E**ndogenous endophthalmitis (EE) is an uncommon intraocular infection with potentially devastating visual consequences. An endogenous source is responsible for roughly 2% to 8% of all endophthalmitis.<sup>1</sup> Prompt diagnosis and treatment are essential to obtain the best visual outcomes. The underlying infection should also be investigated and managed, although it remains unidentified in many cases.

## Etiology

About half of reported EE cases are caused by bacteria and half by fungi.<sup>2</sup> In North America and Europe, the most frequently identified causative bacteria are *Staphylococcus aureus* and *Streptococcus pneumoniae*, while in East Asia, *Klebsiella pneumoniae* is chiefly responsible.<sup>1</sup> Among fungal etiologies, *Candida albicans* (Fig. 1) is the most common yeast, and *Aspergillus* (Fig. 2) is the most common mold.<sup>3</sup>

Major risk factors for EE are immunocompromised states (for example, chronic corticosteroid use, malignancy, end-stage liver/renal disease, organ transplant, diabetes mellitus), intravenous drug use, indwelling catheter, or dental procedures. In rare cases, EE has also been reported in healthy individuals. Mean patient age was 63 years (range, 30-85 years) in a study of 27 patients.<sup>2</sup> The condition occurs very infrequently in children.

## Pathogenesis

The infectious agent travels via the bloodstream and multiplies in the choroid, eventually infiltrating the retina and spreading into the vitreous.<sup>4</sup>

A diagnosis of EE merits a systemic workup for the source of infection, although in 44% of cases no source is found.<sup>2</sup> EE has been most commonly associated with liver abscesses, sinus infections, endocarditis, meningitis, or presence of indwelling catheters.

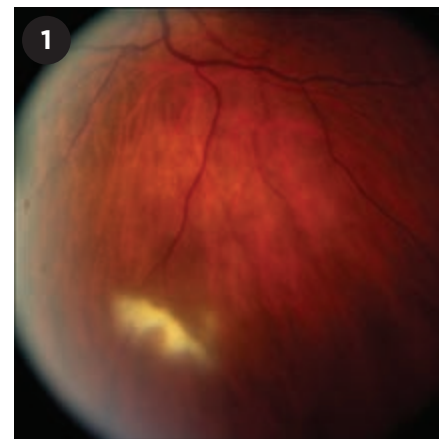## Diagnosis

**Presentation.** Patient presentation ranges from asymptomatic to symptoms typical of severe uveitis, including a red, painful eye with photophobia, floaters, or reduced vision. Although EE is most often unilateral, up to a third of cases have bilateral involvement.<sup>5</sup>

**Ocular examination.** Symptomatic patients may have reduced visual acuity, conjunctival injection, corneal edema, hypopyon, anterior chamber cells, iritis, and vitritis.

A key diagnostic finding associated with an endogenous cause is the presence of a white infiltrate originating in the choroid and sometimes erupting into the vitreous cavity (Fig. 1). The fundus may be obscured because of vitreous haze or vitritis. If the posterior segment cannot be visualized, B-scan ultrasound can help identify vitritis or chorioretinal infiltrates.

**Differential diagnosis.** A number of



**YEAST INFECTION.** Fundus photo of a white, fluffy chorioretinal infiltrate erupting into the vitreous. Vitreous fluid grew *Candida albicans*.

conditions, infectious and noninfectious, should be considered in formulating the diagnosis. See “Differential Diagnosis” on the next page.

**Diagnostic tests.** Suspected EE should prompt a systemic workup for an occult infection; see Table 1 for tests that might be useful, depending on patient presentation and history. Selected tests from the table are discussed in greater detail below.

**Vitreous fluid biopsy.** Vitreous fluid obtained by means of vitrectomy has a higher diagnostic yield than vitreous fluid from needle biopsies, although both are preferable to aqueous tap, most likely because the sample is taken closer to the infectious nidus.<sup>4</sup>

Blood cultures are positive in only a third of cases.<sup>5</sup> Polymerase chain reaction (PCR) can identify both bacteria and fungi, even in culture-negative cases.<sup>4</sup>

BY FAITH BIRNBAUM, MD, AND GAURAV GUPTA, MD, MBA. EDITED BY SHARON FEKRAT, MD, AND INGRID U. SCOTT, MD, MPH.

**Beta-glucan assay.** In cases of suspected fungal EE, a serum beta-glucan assay can detect the presence of beta-D glucan found in the fungal walls of many species. The sensitivity and specificity depend on the cutoff value and the commercial kit used; for example, a study in Japan using a threshold of 60 picograms/mL for invasive fungal infections showed a positive predictive value of 70% and a negative predictive value of 98%. These values are higher than those obtained with blood cultures.<sup>6</sup>

**Imaging.** Neuroimaging can evaluate for an intraocular foreign body as well as for intraorbital or intracranial sources of infection.

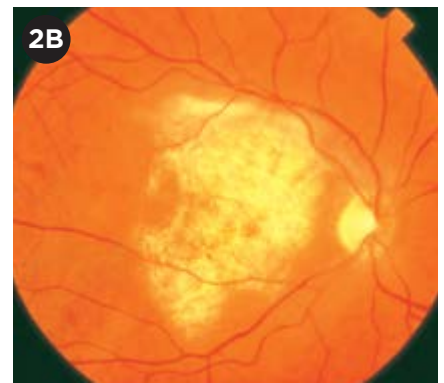
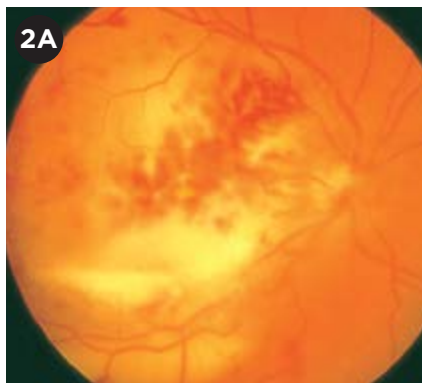### Treatment

Treatment should be initiated as soon as endophthalmitis is suspected, even before a definitive diagnosis is made. In our experience, this should start with prompt intravitreal antibiotic administration, combined with hospitalization, infectious disease consultation, and intravenous antibiotics.

In determining the therapeutic approach, the potential causative organism and the extent of ocular involvement should direct the aggressiveness of therapy. If the ocular lesion is confined to the choroid, systemic therapy with antibiotics or antifungals and close observation may be adequate; if the infection has spread beyond the choroid into the vitreous, then more aggressive intravitreal antibiotic therapy, with or without pars plana vitrectomy, should be added to the regimen.

### Systemic Therapy

**Bacterial.** In choosing systemic antibiotics, the clinician should keep in mind both breadth of coverage and intraocular penetration. Although intraocular penetration of systemic drugs is ordinarily limited by the blood-retina barrier of the posterior segment and the blood-aqueous barrier of the anterior segment, inflammation may make the blood-retina barrier more permeable and allow better penetration. Regardless, patients being treated with intravitreal antibiotics should also receive systemic antibiotics.<sup>7-9</sup>



**MOLD INFECTION.** (2A) Findings in this eye with aspergillosis include vitritis, a diffuse chorioretinal lesion, subretinal/subhyaloid hypopyon, intraretinal hemorrhage, and papillitis. (2B) 2 months after treatment, macular scar, preserved overlying retinal vessels, and temporal disc pallor were present. Final visual acuity was 20/400.

Wide-spectrum antibiotics, including fluoroquinolones, aminoglycosides, third-generation cephalosporins, and clindamycin, may be considered.

Systemic fluoroquinolones have good ocular penetration for most bacteria, and it improves with repeat doses.<sup>7</sup> In particular, the fourth-generation fluoroquinolones (moxifloxacin, levofloxacin) have demonstrated excellent penetration in animal and human studies.<sup>8,9</sup>

Ocular penetration of ciprofloxacin, though not as good as the fourth-generation drugs, can reach therapeutic levels with higher and multiple doses, and it can supplement intravitreal injections to maintain therapeutic concentrations.<sup>9,10</sup>

Aminoglycosides (gentamicin, amikacin) reach intraocular therapeutic levels for some pathogens, but not reliably.<sup>10</sup>

Although ceftazidime, a third-generation cephalosporin, is a favorable choice in terms of its broad gram-negative and *Pseudomonas* coverage, it has poor intraocular penetration.<sup>8</sup> Rabbit studies have shown that in inflamed eyes, ceftazidime reaches the mean inhibitory concentration threshold for *Proteus*, *Haemophilus influenzae*, and *Neisseria* but not for *Pseudomonas* or *Acinetobacter* when delivered through a systemic route only.<sup>8</sup>

Intravenous vancomycin has limited ocular penetration, even in inflamed eyes with penetrating injury.<sup>8</sup>

**Fungal.** The ophthalmologist should

consider administering intravenous amphotericin-B (0.7-1.0 mg/kg daily), with or without flucytosine (100 mg/kg daily in 4 divided doses) until drug sensitivity results are available. Alternatively, oral voriconazole or fluconazole can be effective, although some isolates of *Candida* are fluconazole resistant. Echinocandins (e.g., caspofungin) do not adequately penetrate the eye.

For *Aspergillus*, voriconazole is the drug of choice; it has adequate

## Differential Diagnosis

### Noninfectious uveitis

- Idiopathic
- Sarcoidosis
- Behçet syndrome
- Sterile endophthalmitis from recent intravitreal injection (e.g., anti-VEGF or steroid)
- Sympathetic ophthalmia
- Juvenile idiopathic arthritis
- Vogt-Koyanagi-Harada disease

### Infectious chorioretinitis

- Herpes simplex virus
- Varicella-zoster virus
- Epstein-Barr virus
- Cytomegalovirus

### Malignancy

- Intraocular lymphoma
- Leukemic infiltrate
- Retinoblastoma

### Intraocular foreign body

### White dot syndromes

intraocular penetration when used systemically and can be administered intravitreally as well.<sup>11</sup> Trough levels between 2 and 5 µg/mL are the goal,<sup>11</sup> as higher concentrations have been associated with neurotoxicity (visual and auditory hallucinations, confusion) and hepatotoxicity, while lower concentrations are associated with treatment failure.<sup>12</sup> Multiple factors influence plasma concentrations, such as genetic polymorphisms and coadministered medications.<sup>12</sup> The optimal duration of voriconazole therapy is not known, but a common approach is to treat systemically for 4 to 6 weeks, depending on observed ophthalmologic improvement. Systemic voriconazole therapy should be managed by an infectious disease physician experienced in its use.

### Intravitreal Therapy

Ceftazidime (2.25 mg/0.1 mL) and

vancomycin (1.0 mg/0.1 mL) are the preferred intravitreal antibiotics for bacterial EE.<sup>1</sup> Amikacin (0.4 mg/0.1 mL) and clindamycin (1.0 mg/0.1 mL) are alternatives for penicillin-allergic patients.

For patients with fungal infection, intravitreal amphotericin-B (5-10 µg/0.1 mL) or, less frequently, voriconazole (100 µg/0.1 mL) are options.

Patients should be monitored daily for response to treatment. If, after 2 to 3 days, there is worsening inflammation, declining vision, or increasing pain, then repeated injections or vitrectomy may be necessary.

### Vitrectomy

Vitrectomy may reduce the burden of infectious organisms and inflammatory mediators, but there is no consensus about the indications. A systematic review of 342 cases of bacterial EE

found that eyes treated with vitrectomy and intravitreal antibiotics were approximately 2 times more likely to have vision better than 20/200 and 3 times less likely to require evisceration or enucleation when compared with intravitreal antibiotics alone.<sup>1</sup>

Vitrectomy is generally advised in cases of moderate vitritis and retinal infiltration. A decline in vision due to inflammation, vitritis, corneal edema, or anterior segment inflammation further supports the use of immediate vitrectomy.

### Prognosis

Outcomes of EE are variable and are generally dictated by the aggressiveness of the causative organism. In general, yeasts are associated with the best visual outcomes, bacteria with moderate outcomes, and molds with the worst. For example, 56% of patients with EE caused by *Candida* achieved a visual acuity of 20/200 or better,<sup>3</sup> compared with 41% who had bacterial EE<sup>1</sup> and 33% who had EE caused by molds.

1 Jackson TL et al. *Surv Ophthalmol*. 2014;59(6):627-635.

2 Binder M et al. *Medicine*. 2003;82(2):97-105.

3 Lingappan A et al. *Am J Ophthalmol*. 2012;153(1):162-166.

4 Zhang Y, Wang W. *Retina*. 2005;25(6):746-750.

5 Vaziri K et al. *Clin Ophthalmol*. 2015;9:95-108.

6 Obayashi T et al. *Clin Infect Dis*. 2008;46(12):1864-1870.

7 Smith A et al. *Drugs*. 2001;61(6):747-761.

8 Ahmed S et al. *J Ocul Pharmacol Ther*. 2014;30(10):823-830.

9 Garcia-Sáenz MC et al. *J Cataract Refract Surg*. 2001;27(12):1969-1974.

10 Davis JL. *Am J Ophthalmol*. 1996;122(5):724-726.

11 Riddell J et al. *Clin Infect Dis*. 2011;52(5):648-653.

12 Dolton MJ, McLachlan AJ. *Int J Antimicrob Agents*. 2014;44(3):183-193.

Dr. Birnbaum will be a resident in ophthalmology at Duke University, Durham, N.C.; at the time of writing, she was a medical student at Alpert Medical School, Brown University, Providence, R.I. Dr. Gupta is clinical assistant professor of surgery (ophthalmology) at Alpert Medical School, Brown University. *Relevant financial disclosures: None.*

**Table 1: Diagnostic Workup for Suspected EE**

|  |  |
|--|--|
| <b>Ocular fluid (vitreal or aqueous)</b> | <ul style="list-style-type: none"> <li>• Gram stain and culture</li> <li>• Fungal stain and culture</li> <li>• PCR (if indicated) for herpes simplex virus types 1 and 2, varicella-zoster virus, cytomegalovirus, <i>Toxoplasma</i></li> </ul>  |
| <b>Blood tests</b>                       | <ul style="list-style-type: none"> <li>• Bacterial culture</li> <li>• Fungal culture</li> <li>• Complete blood count with differential</li> <li>• Blood chemistries, including liver function tests</li> <li>• Tests for systemic infections/inflammation: HIV, <i>Toxoplasma</i> IgM and IgG, hepatitis C virus, angiotensin-converting enzyme (for sarcoidosis), erythrocyte sedimentation rate, rapid plasma reagin and fluorescent treponemal antibody absorption (for syphilis), Quantiferon-TB Gold, Lyme serology, beta-D glucan assay (for fungal infection), galactomannan assay (for aspergillosis)</li> </ul> |
| <b>Other laboratory tests</b>            | <ul style="list-style-type: none"> <li>• Urine culture</li> <li>• Cerebrospinal fluid culture</li> <li>• Purified protein derivative (skin test)</li> </ul>  |
| <b>Imaging</b>                           | <ul style="list-style-type: none"> <li>• B-scan ultrasound</li> <li>• Transesophageal echocardiogram</li> <li>• Chest x-ray or, if high suspicion, chest computed tomography</li> <li>• Magnetic resonance imaging of brain and orbits</li> <li>• Ultrasound of right upper quadrant</li> </ul>  |