
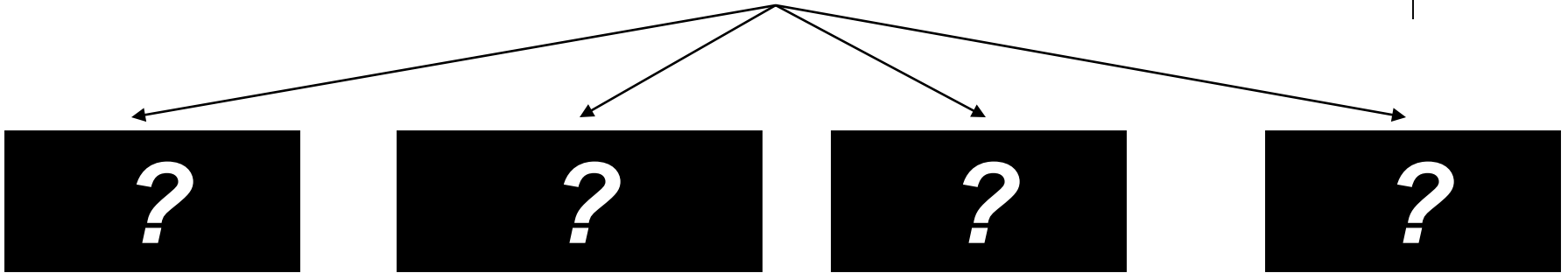


Iridocorneal Endothelial (ICE) Syndrome




ICE: *Signs*

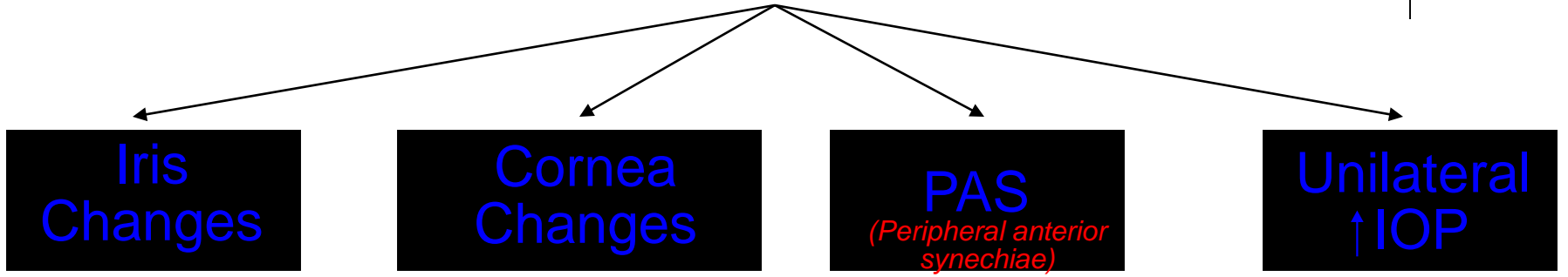


What are the classic signs of ICE syndrome?

Iridocorneal Endothelial (ICE) Syndrome




ICE: *Signs*

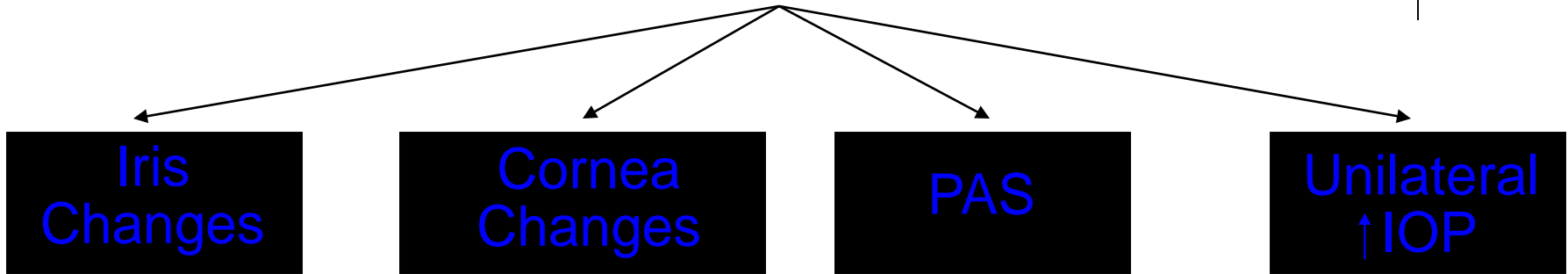


What are the classic signs of ICE syndrome?

Iridocorneal Endothelial (ICE) Syndrome




ICE: *Signs*



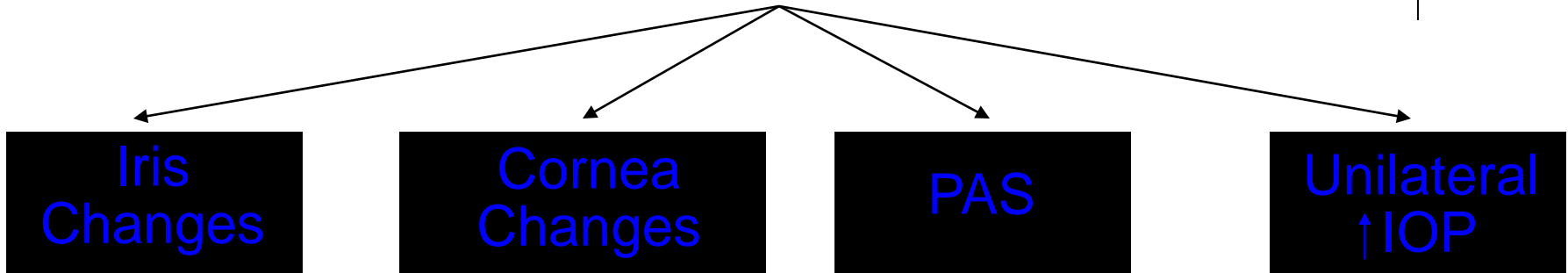
What are the classic signs of ICE syndrome?

Who is the typical patient?

Iridocorneal Endothelial (ICE) Syndrome



ICE: *Signs*




What are the classic signs of ICE syndrome?

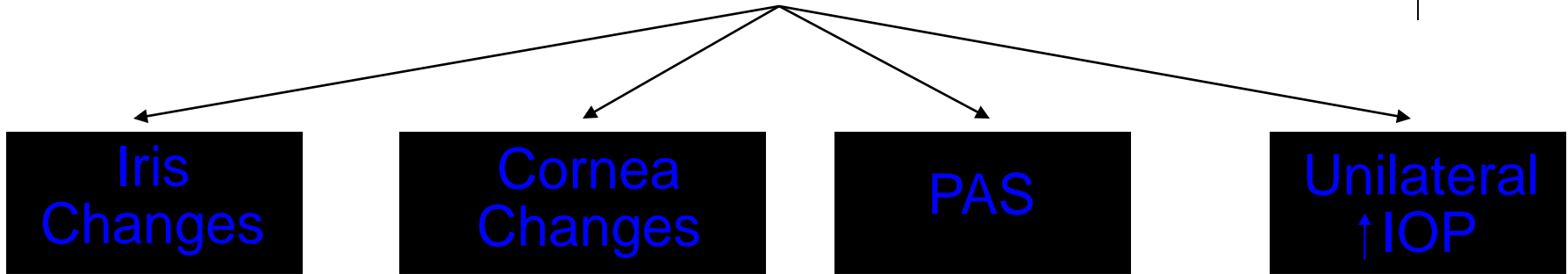
Who is the typical patient?

A young-to-middle-aged adult female

Iridocorneal Endothelial (ICE) Syndrome



ICE: Signs



What are the classic signs of ICE syndrome?

Who is the typical patient?


A young-to-middle-aged adult female

How will a pt with ICE present? (On the OKAP, that is.)

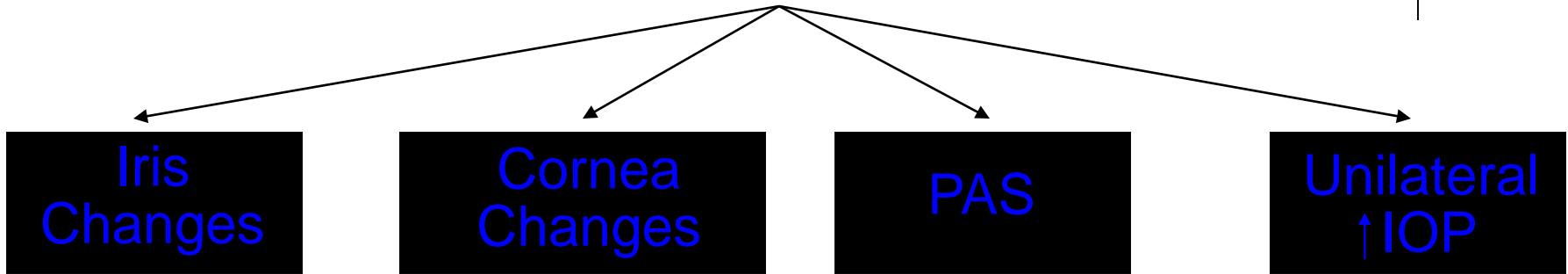
--The pt will be an **adult female**

--
--
--
--

Iridocorneal Endothelial (ICE) Syndrome



ICE: Signs



What are the classic signs of ICE syndrome?

Who is the typical patient?

A young-to-middle-aged adult female


How will a pt with ICE present? (On the OKAP, that is.)

--The pt will be an **adult female**

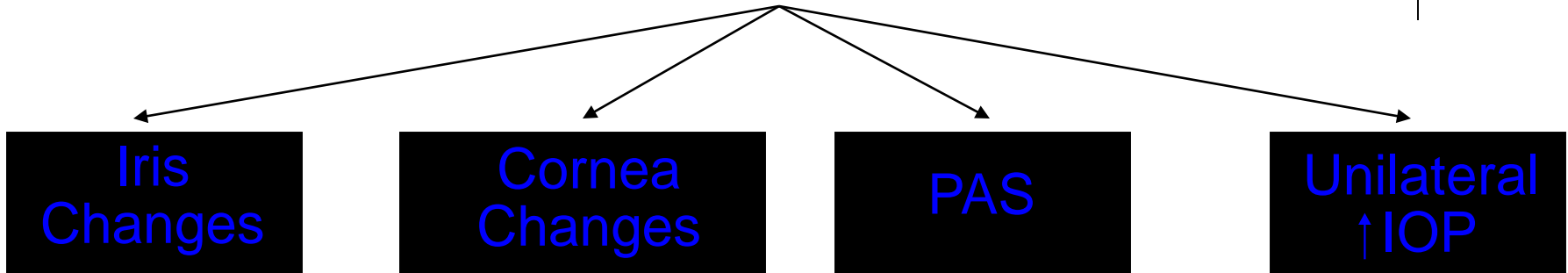
--Pt will complain of 1) changes in the , 2) , and/or 3)

--
--
--

Iridocorneal Endothelial (ICE) Syndrome



ICE: Signs



What are the classic signs of ICE syndrome?

Who is the typical patient?

A young-to-middle-aged adult female

How will a pt with ICE present? (On the OKAP, that is.)

--The pt will be an **adult female**

--Pt will complain of 1) changes in the **eye's appearance** , 2) **pain** , and/or 3) **decreased VA**

--

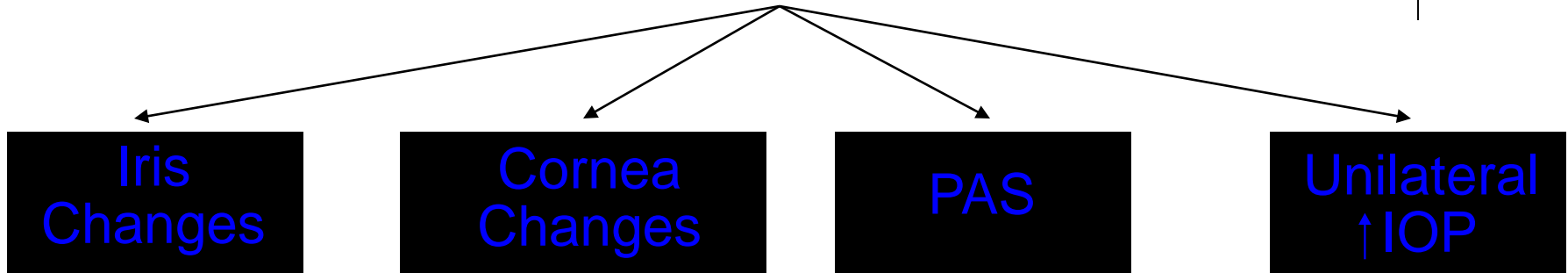
--

--

Iridocorneal Endothelial (ICE) Syndrome



ICE: *Signs*



What are the classic signs of ICE syndrome?

Who is the typical patient?

A young-to-middle-aged adult female

How will a pt with ICE present? (On the OKAP, that is.)

--The pt will be an **adult female**


--Pt will complain of 1) changes in the **eye's appearance** , 2) **pain** , and/or 3) **decreased VA**

--Pt will have one word + one abb. in that eye +/- two words + one abb.

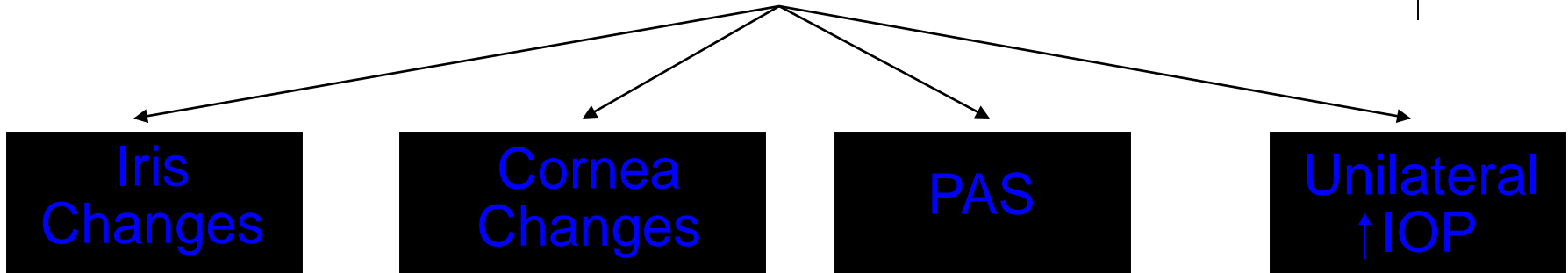
--

--

Iridocorneal Endothelial (ICE) Syndrome



ICE: Signs



What are the classic signs of ICE syndrome?

Who is the typical patient?

A young-to-middle-aged adult female

How will a pt with ICE present? (On the OKAP, that is.)

--The pt will be an **adult female**


--Pt will complain of 1) changes in the **eye's appearance** , 2) **pain** , and/or 3) **decreased VA**

--Pt will have **elevated IOP** in that eye +/- **glaucomatous ONH damage**

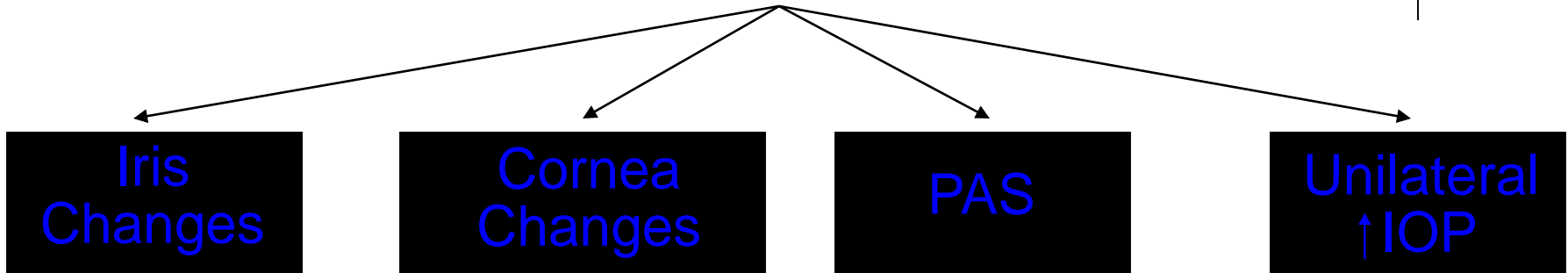
--

--

Iridocorneal Endothelial (ICE) Syndrome



ICE: Signs



What are the classic signs of ICE syndrome?

Who is the typical patient?

A young-to-middle-aged adult female

How will a pt with ICE present? (On the OKAP, that is.)


--The pt will be an **adult female**

--Pt will complain of 1) changes in the **eye's appearance** , 2) **pain** , and/or 3) **decreased VA**

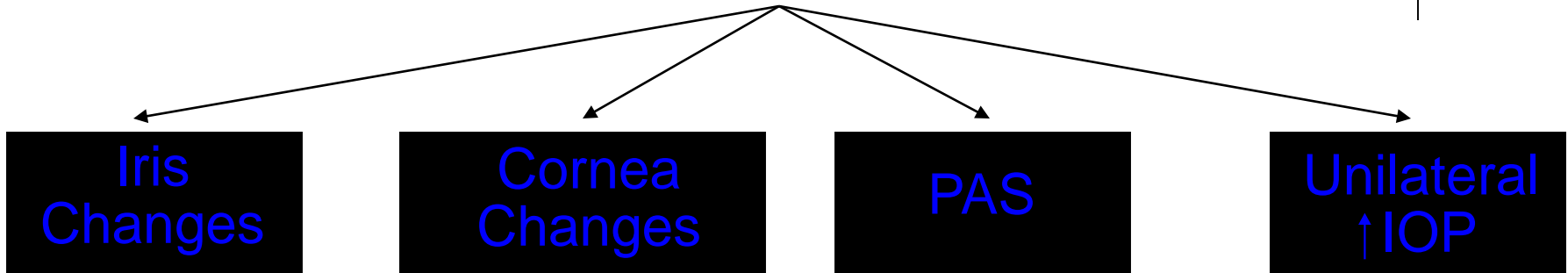
--Pt will have **elevated IOP** in that eye +/- **glaucomatous ONH damage**

--The cornea of the affected eye will have , and may be

--



ICE: Signs



What are the classic signs of ICE syndrome?

Who is the typical patient?

A young-to-middle-aged adult female

How will a pt with ICE present? (On the OKAP, that is.)

--The pt will be an **adult female**


--Pt will complain of 1) changes in the **eye's appearance** , 2) **pain** , and/or 3) **decreased VA**

--Pt will have **elevated IOP** in that eye +/- **glaucomatous ONH damage**

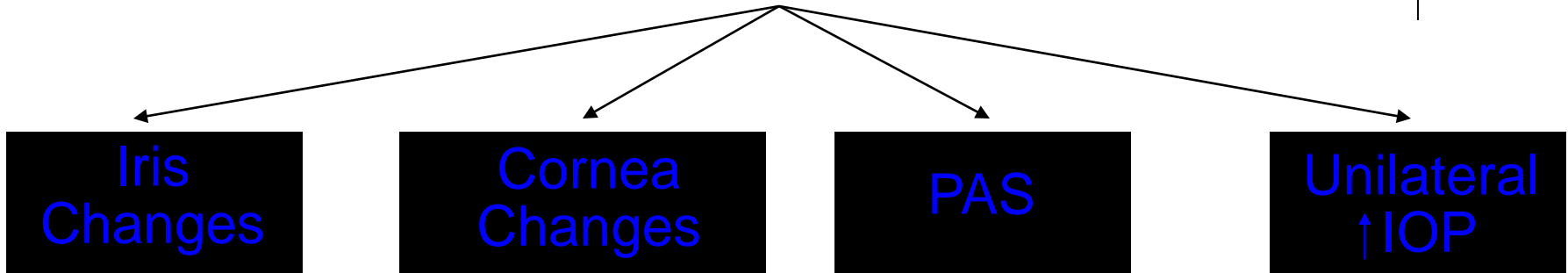
--The cornea of the affected eye will have **abnormal endothelium** , and may be **edematous**

--

Iridocorneal Endothelial (ICE) Syndrome



ICE: Signs



What are the classic signs of ICE syndrome?

Who is the typical patient?

A young-to-middle-aged adult female

How will a pt with ICE present? (On the OKAP, that is.)

--The pt will be an **adult female**

--Pt will complain of 1) changes in the **eye's appearance** , 2) **pain** , and/or 3) **decreased VA**

--Pt will have **elevated IOP** in that eye +/- **glaucomatous ONH damage**

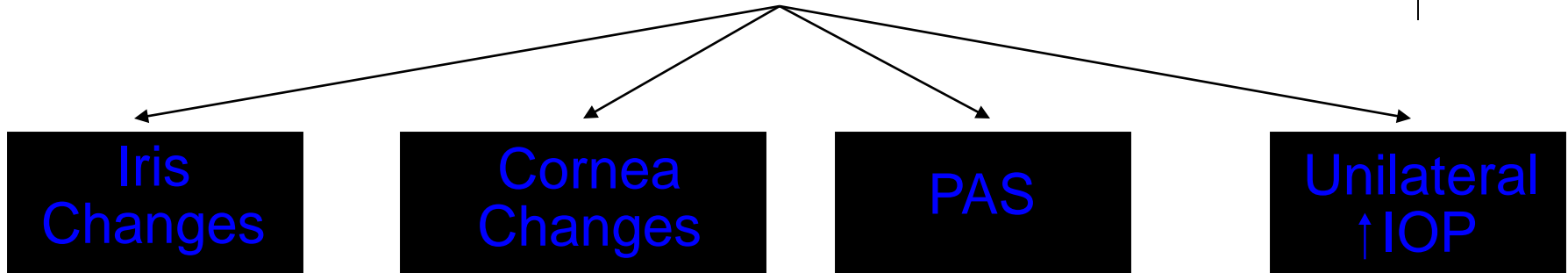
--The cornea of the affected eye will have **abnormal endothelium** , and may be **edematous**

--The fellow eye will be essentially , with the possible exception of subtle changes to the two words

Iridocorneal Endothelial (ICE) Syndrome



ICE: Signs



What are the classic signs of ICE syndrome?

Who is the typical patient?

A young-to-middle-aged adult female

How will a pt with ICE present? (On the OKAP, that is.)

--The pt will be an **adult female**


--Pt will complain of 1) changes in the **eye's appearance** , 2) **pain** , and/or 3) **decreased VA**

--Pt will have **elevated IOP** in that eye +/- **glaucomatous ONH damage**

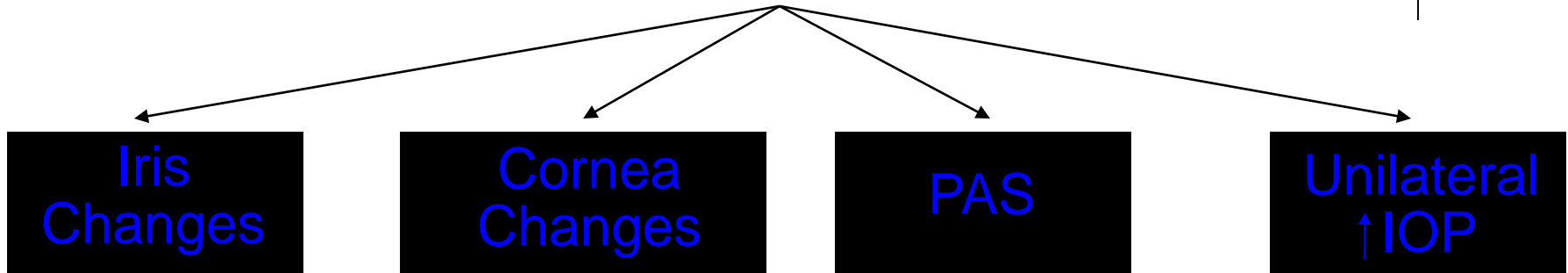
--The cornea of the affected eye will have **abnormal endothelium** , and may be **edematous**

--The fellow eye will be essentially **normal**, with the possible exception of subtle changes to the **corneal endothelium**

Iridocorneal Endothelial (ICE) Syndrome



ICE: Signs



What are the classic signs of ICE syndrome?

Who is the typical patient?

A young-to-middle-aged adult female

How will a pt with ICE present? (On the OKAP, that is.)

--The pt will be an **adult female**

--Pt will complain of 1) changes in the **eye's appearance** , 2) **pain** , and/or 3) **decreased VA**


--Pt will have **elevated IOP** in that eye +/- **glaucomatous ONH damage**

--The cornea of the affected eye will have **abnormal endothelium** , and may be **edematous**

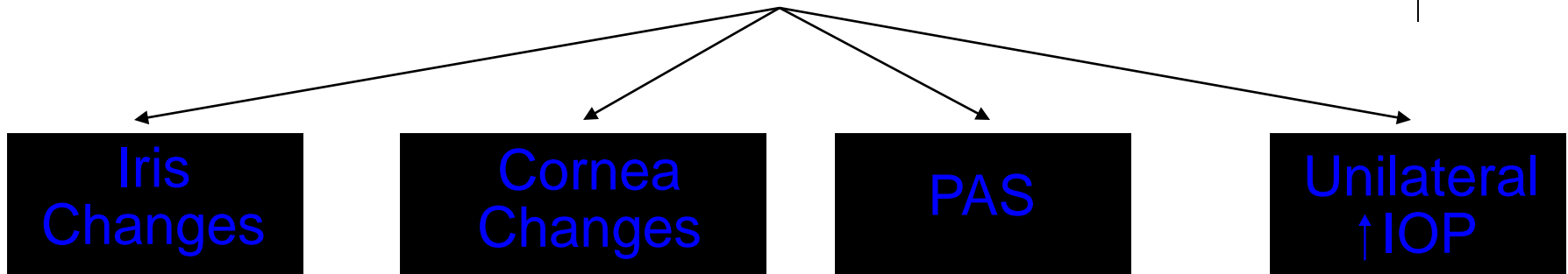
--The fellow eye will be essentially **normal**, with the possible exception of subtle changes to the **corneal endothelium**

What 'pertinent negative' will be elicited when taking a history?

Iridocorneal Endothelial (ICE) Syndrome



ICE: Signs



What are the classic signs of ICE syndrome?

Who is the typical patient?

A young-to-middle-aged adult female

How will a pt with ICE present? (On the OKAP, that is.)

--The pt will be an **adult female**

--Pt will complain of 1) changes in the **eye's appearance** , 2) **pain** , and/or 3) **decreased VA**

--Pt will have **elevated IOP** in that eye +/- **glaucomatous ONH damage**


--The cornea of the affected eye will have **abnormal endothelium** , and may be **edematous**

--The fellow eye will be essentially **normal**, with the possible exception of subtle changes to the **corneal endothelium**

What 'pertinent negative' will be elicited when taking a history?

She will deny any family history of similar eye findings

Iridocorneal Endothelial (ICE) Syndrome




What are the subtypes of ICE syndrome?



ICE: *Subtypes*

Iridocorneal Endothelial (ICE) Syndrome



What are the subtypes of ICE syndrome?

This is a difficult question, and the answer depends in part on who you ask. Let's start with the easy ones. The identities of two subtypes are not in dispute. These are:

--

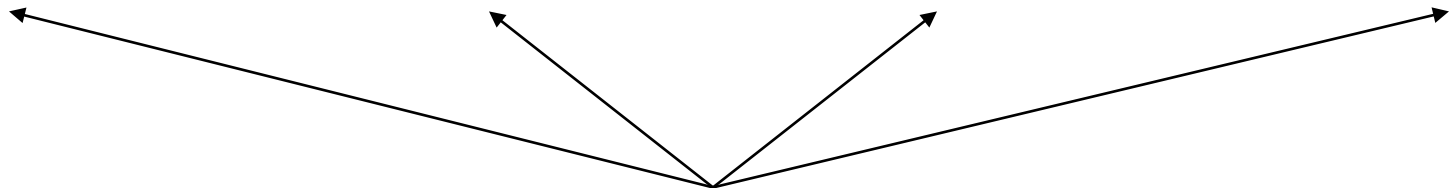
--

Iris Nevus
Syndrome

Cogan-Reese
Syndrome


Chandler
Syndrome

Essential
Iris Atrophy



ICE: *Subtypes*

Iridocorneal Endothelial (ICE) Syndrome



What are the subtypes of ICE syndrome?

This is a difficult question, and the answer depends in part on who you ask. Let's start with the easy ones. The identities of two subtypes are not in dispute. These are:

--**Chandler syndrome**

--**Essential iris atrophy** (Note: Some authors call this variant

three words

or

four words

)

Iris Nevus
Syndrome

Cogan-Reese
Syndrome

**Chandler
Syndrome**

**Essential
Iris Atrophy**

ICE: *Subtypes*

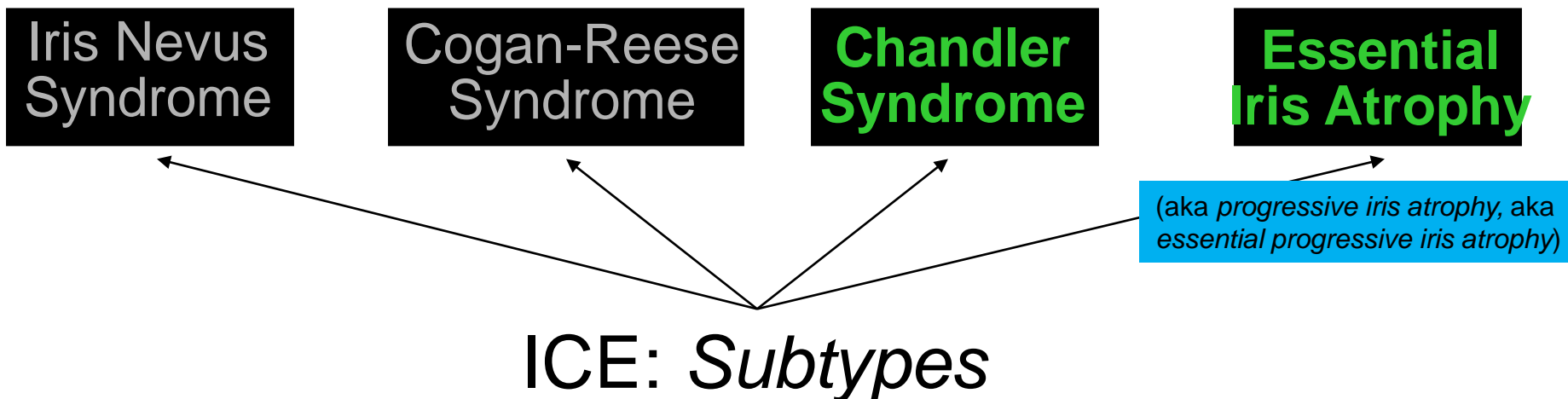
Iridocorneal Endothelial (ICE) Syndrome

What are the subtypes of ICE syndrome?


This is a difficult question, and the answer depends in part on who you ask. Let's start with the easy ones. The identities of two subtypes are not in dispute. These are:

--**Chandler syndrome**

--**Essential iris atrophy** (Note: Some authors call this variant **progressive iris atrophy**, or **essential progressive iris atrophy**)



Iridocorneal Endothelial (ICE) Syndrome



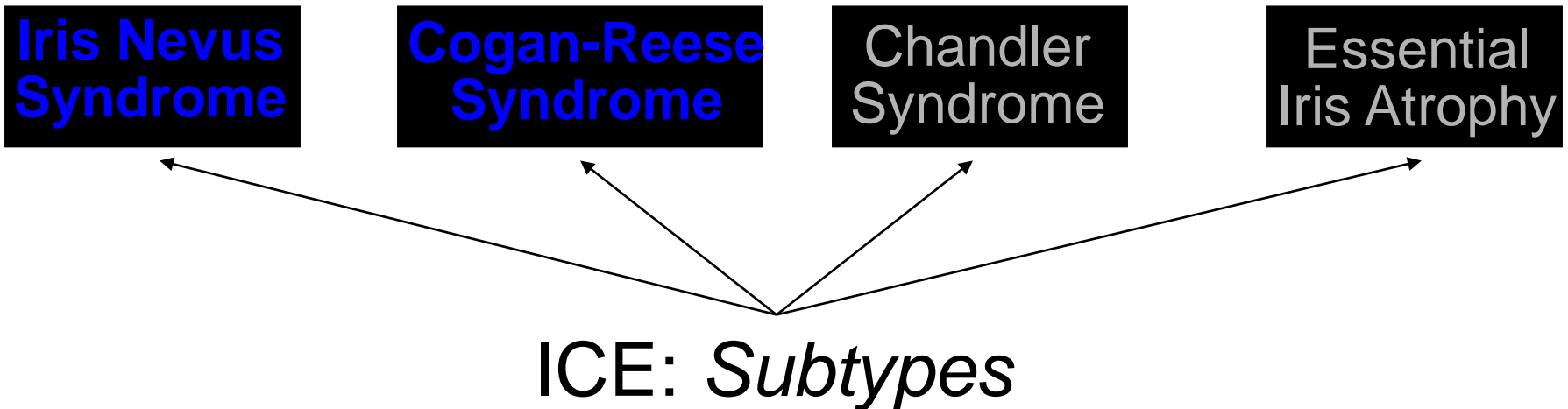
What are the subtypes of ICE syndrome?

This is a difficult question, and the answer depends in part on who you ask. Let's start with the easy ones. The identities of two subtypes are not in dispute. These are:


--**Chandler syndrome**

--**Essential iris atrophy** (Note: Some authors call this variant **progressive iris atrophy**, or **essential progressive iris atrophy**)

What's up with the status of Cogan-Reese and iris nevus syndrome?



Iridocorneal Endothelial (ICE) Syndrome



What are the subtypes of ICE syndrome?

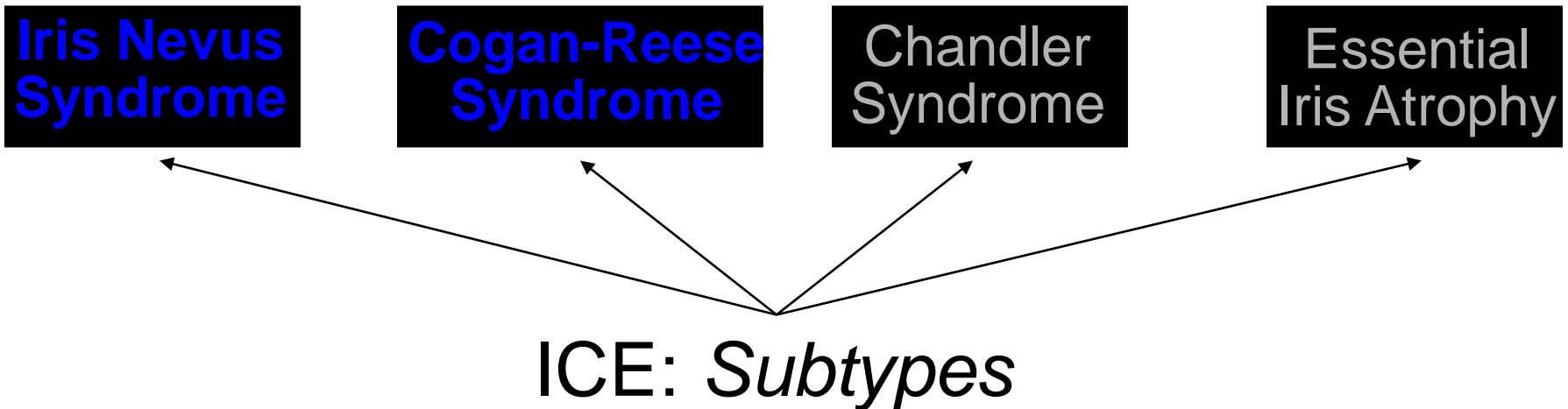
This is a difficult question, and the answer depends in part on who you ask. Let's start with the easy ones. The identities of two subtypes are not in dispute. These are:

--**Chandler syndrome**


--**Essential iris atrophy** (Note: Some authors call this variant **progressive iris atrophy**, or **essential progressive iris atrophy**)

What's up with the status of Cogan-Reese and iris nevus syndrome?

Here's the thing: The BCSC books treat these terms as synonyms. Other sources contend that these are two separate and distinct subtypes of ICE. Still others argue that iris nevus syndrome is a separate disease entirely, ie, not a subtype of ICE at all.



Iridocorneal Endothelial (ICE) Syndrome



What are the subtypes of ICE syndrome?

This is a difficult question, and the answer depends in part on who you ask. Let's start with

For the OKAP, I recommend thinking of them as the BCSC does:

Iris nevus syndrome (aka Cogan-Reese syndrome)

Chandler syndrome

Essential iris atrophy

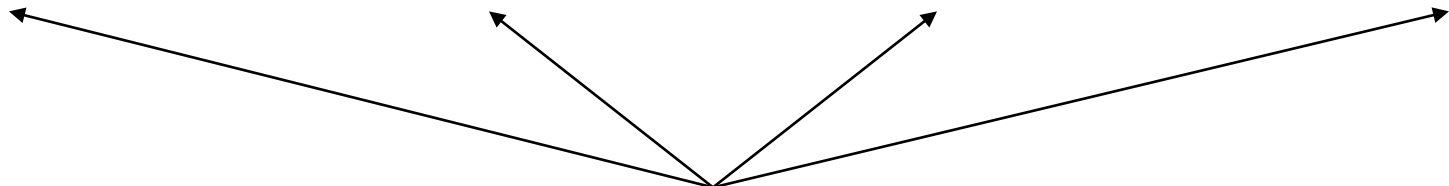
**Iris Nevus
Syndrome**

aka

**Cogan-Reese
Syndrome**


**Chandler
Syndrome**

**Essential
Iris Atrophy**



ICE: Subtypes

Iridocorneal Endothelial (ICE) Syndrome



What are the subtypes of ICE syndrome?

This is a difficult question, and the answer depends in part on who you ask. Let's start with

For the OKAP, I recommend thinking of them as the BCSC does:

Iris nevus syndrome (aka Cogan-Reese syndrome)

Chandler syndrome

Essential iris atrophy

Note that this creates a very apropos mnemonic for remembering the ICE subtypes!

Iris Nevus Syndrome

aka


Cogan-Reese Syndrome

Chandler Syndrome

Essential Iris Atrophy

ICE: Subtypes

Iridocorneal Endothelial (ICE) Syndrome



What are the subtypes of ICE syndrome?

This is a difficult question, and the answer depends in part on who you ask. Let's start with

For the OKAP, I recommend thinking of them as the BCSC does:

Iris nevus syndrome (aka Cogan-Reese syndrome)

Chandler syndrome

Essential iris atrophy

Which subtype is most common?

Iris Nevus Syndrome

aka

Cogan-Reese Syndrome

Chandler Syndrome

Essential Iris Atrophy

ICE: Subtypes

Iridocorneal Endothelial (ICE) Syndrome



What are the subtypes of ICE syndrome?

This is a difficult question, and the answer depends in part on who you ask. Let's start with

For the OKAP, I recommend thinking of them as the BCSC does:

Iris nevus syndrome (aka Cogan-Reese syndrome)

Chandler syndrome

Essential iris atrophy

Which subtype is most common?

Chandler syndrome—it accounts for about % of all cases

**Iris Nevus
Syndrome**

aka

**Cogan-Reese
Syndrome**

**Chandler
Syndrome**

**Essential
Iris Atrophy**

ICE: Subtypes

Iridocorneal Endothelial (ICE) Syndrome



What are the subtypes of ICE syndrome?

This is a difficult question, and the answer depends in part on who you ask. Let's start with

For the OKAP, I recommend thinking of them as the BCSC does:

Iris nevus syndrome (aka Cogan-Reese syndrome)

Chandler syndrome

Essential iris atrophy

Which subtype is most common?

Chandler syndrome—it accounts for about half of all cases

**Iris Nevus
Syndrome**

aka


**Cogan-Reese
Syndrome**

**Chandler
Syndrome**


**Essential
Iris Atrophy**

ICE: Subtypes

Iridocorneal Endothelial (ICE) Syndrome




ICE: *Signs*

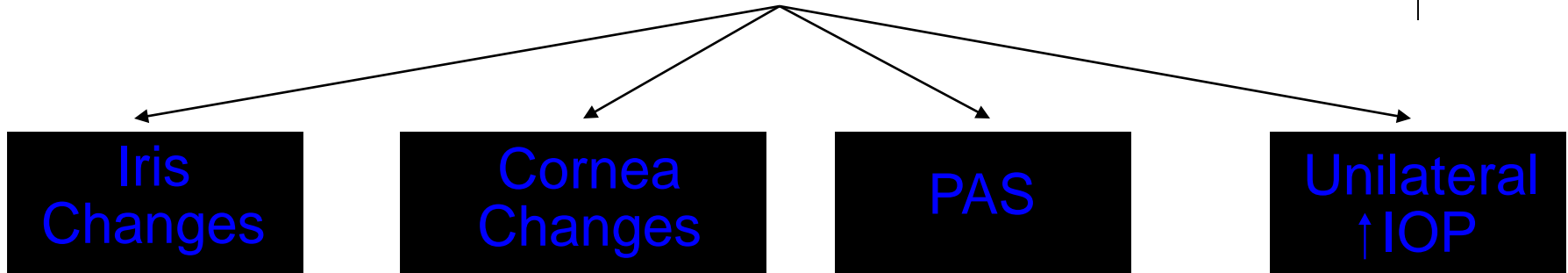


What is the fundamental pathology (ie, the basic underlying problem) in ICE?

Iridocorneal Endothelial (ICE) Syndrome




ICE: *Signs*

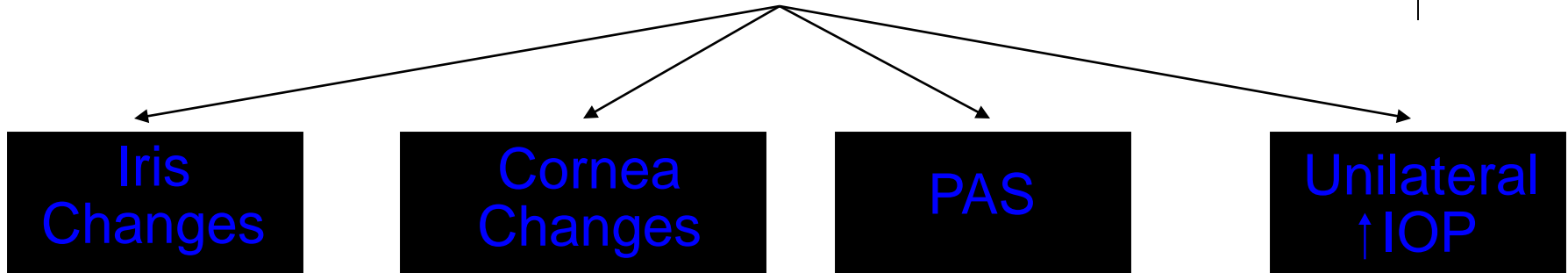


What is the fundamental pathology (ie, the basic underlying problem) in ICE?
A subset of endothelium maldifferentiates, resulting in a cohort of abnormal cells that migrate across the angle and onto the iris, laying down a membrane (histologically similar to Descemet's) as it goes.


Iridocorneal Endothelial (ICE) Syndrome



ICE: *Signs*




What is the fundamental pathology (ie, the basic underlying problem) in ICE?
A subset of endothelium maldifferentiates, resulting in a cohort of abnormal cells that migrate across the angle and onto the iris, laying down a membrane (histologically similar to Descemet's) as it goes. **These abnormal, migrating endothelial cells and associated membrane account for all of the signs found in ICE.**



Iridocorneal Endothelial (ICE) Syndrome

ICE: Signs



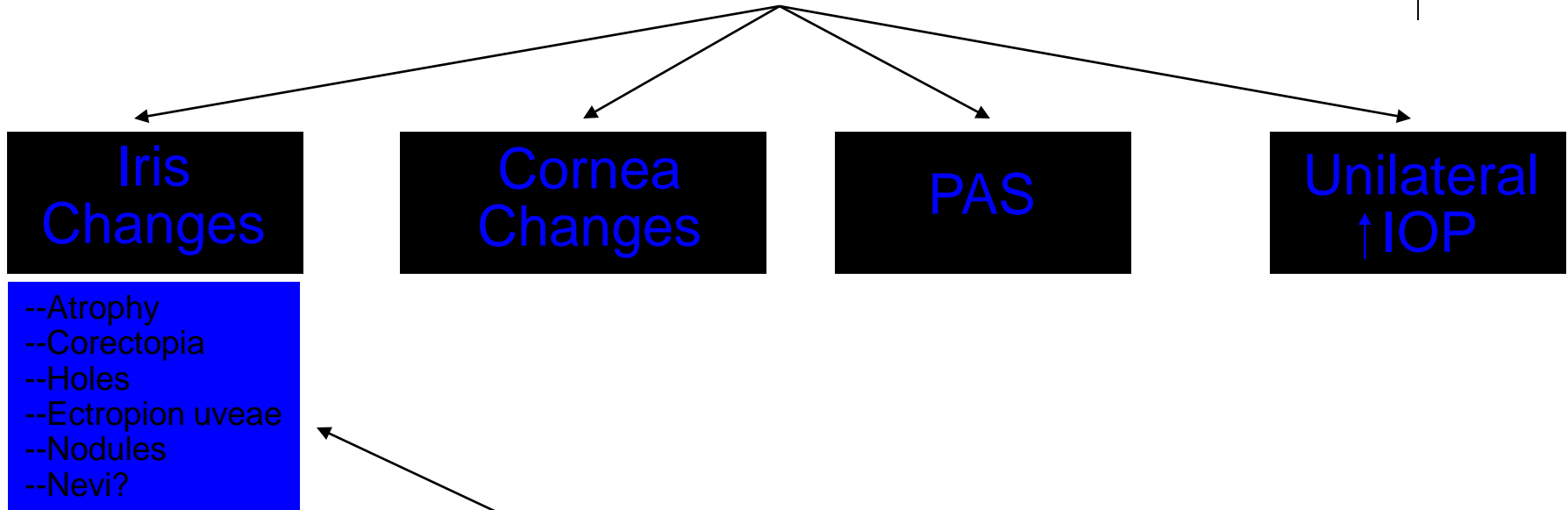
--
--
--
--
--
--

What are the specific findings?

Iridocorneal Endothelial (ICE) Syndrome




ICE: *Signs*



What are the specific findings?

Iridocorneal Endothelial (ICE) Syndrome



ICE: Signs

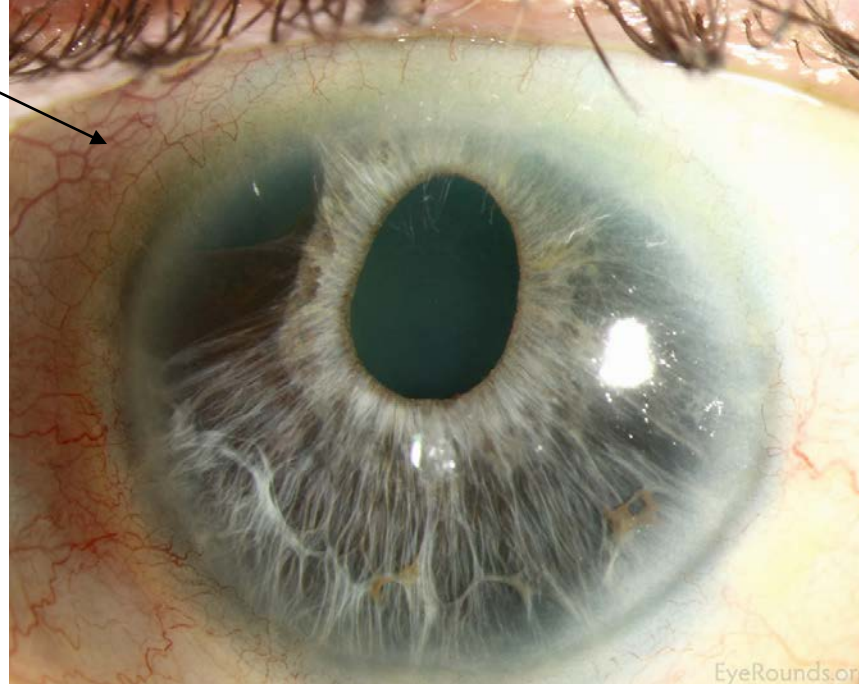
Iris
Changes

Cornea
Changes


PAS

Unilateral
↑ IOP

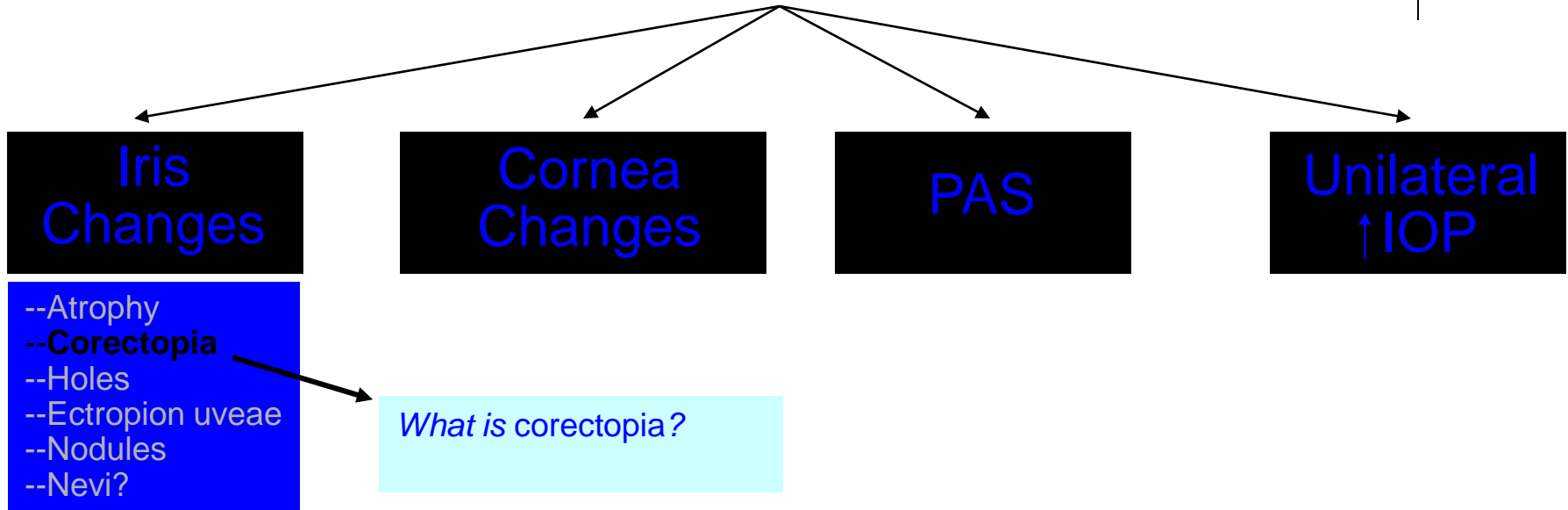
--Atrophy
--Corectopia
--Holes
--Ectropion uveae
--Nodules
--Nevi?



Iridocorneal Endothelial (ICE) Syndrome



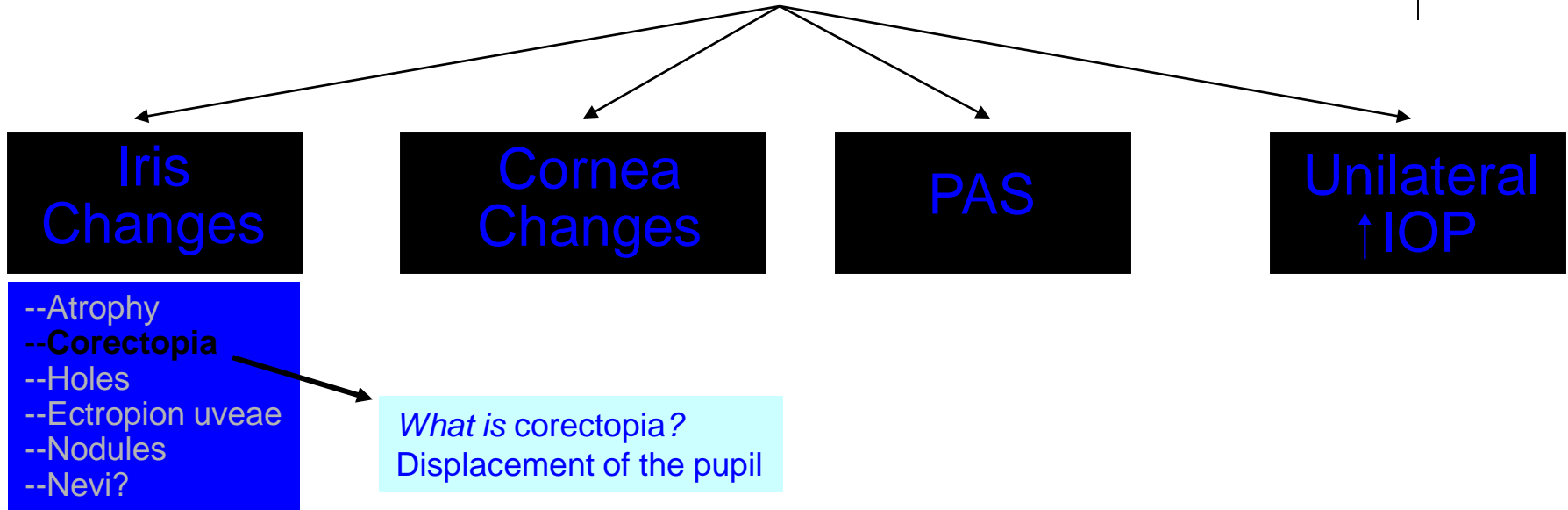
ICE: *Signs*



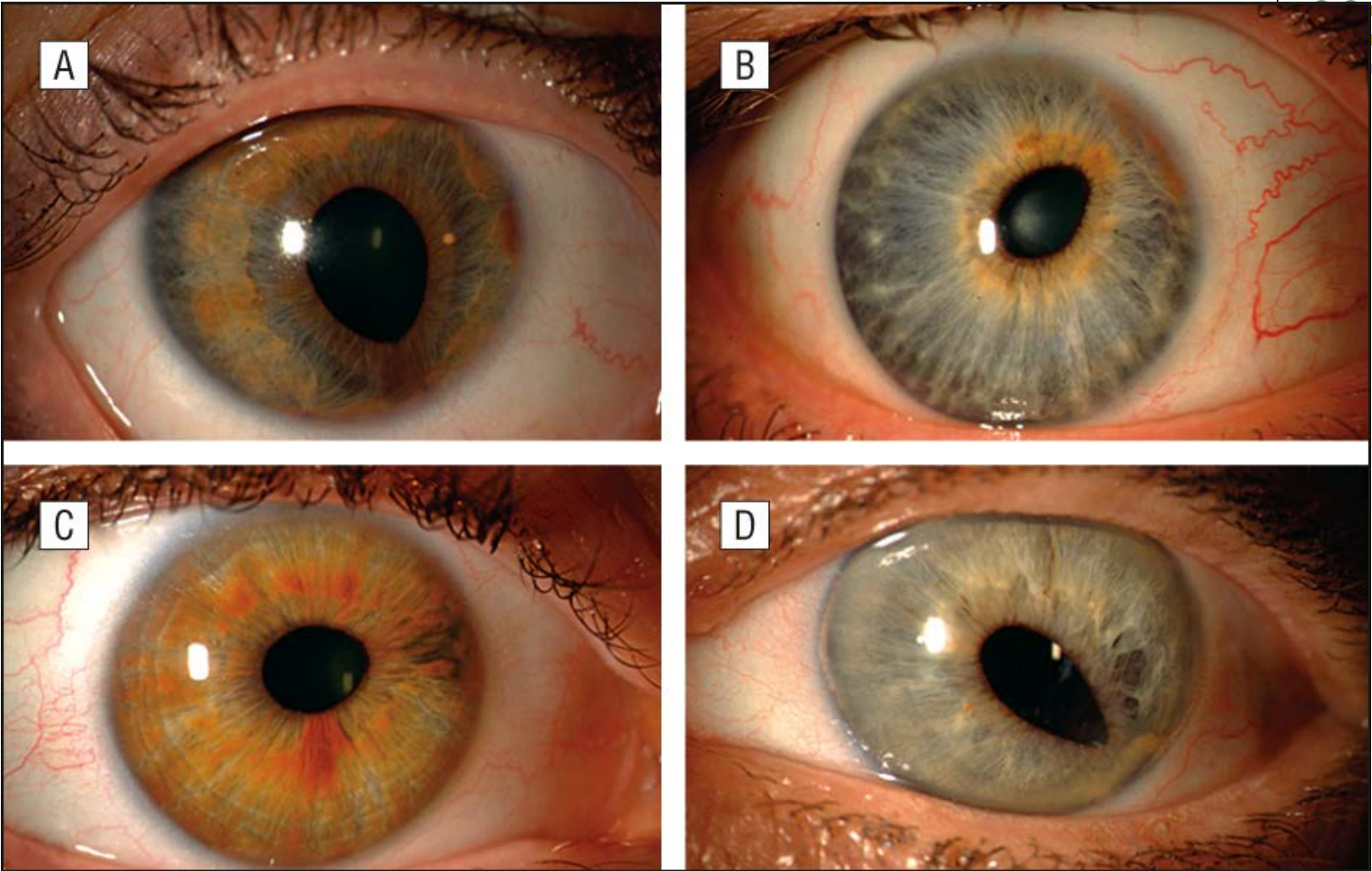
Iridocorneal Endothelial (ICE) Syndrome




ICE: *Signs*



Iridocorneal Endothelial (ICE) Syndrome



Corectopia



Iridocorneal Endothelial (ICE) Syndrome

ICE: Signs

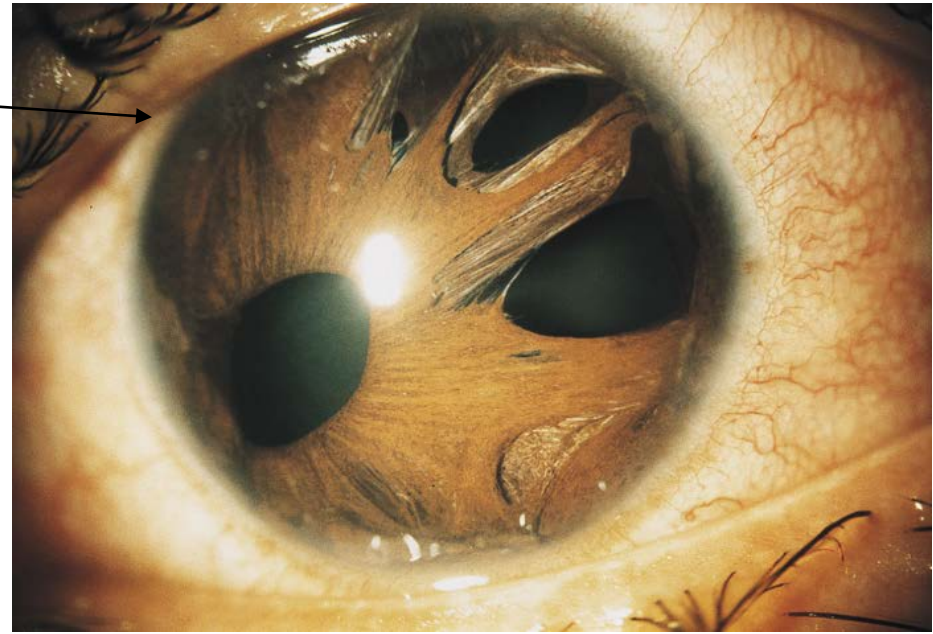Iris Changes

Cornea Changes


PAS

Unilateral ↑ IOP

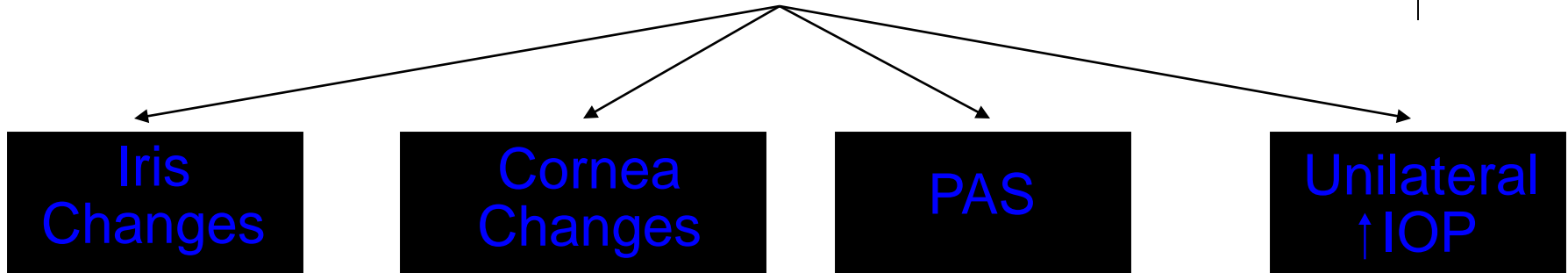
- Atrophy
- Corectopia
- Holes**
- Ectropion uveae
- Nodules
- Nevi?



Iridocorneal Endothelial (ICE) Syndrome




ICE: *Signs*



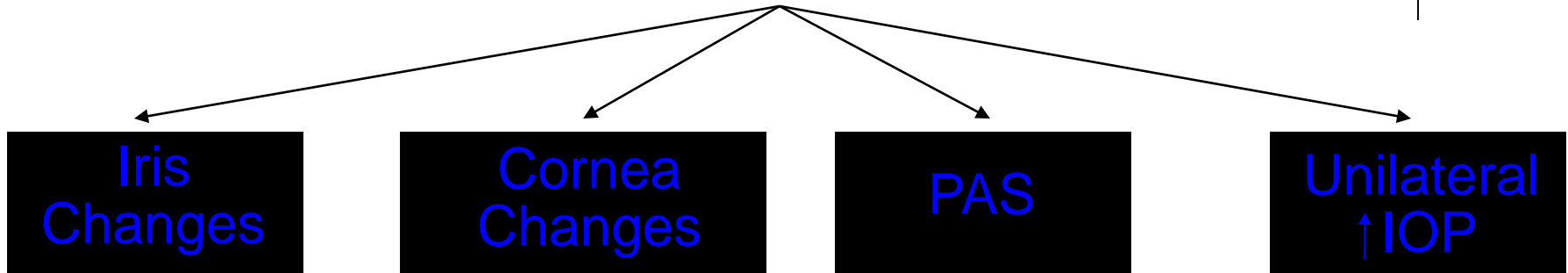
- Atrophy
- Corectopia
- Holes
- Ectropion uveae**
- Nodules
- Nevi?

What is ectropion uveae?

Iridocorneal Endothelial (ICE) Syndrome



ICE: Signs

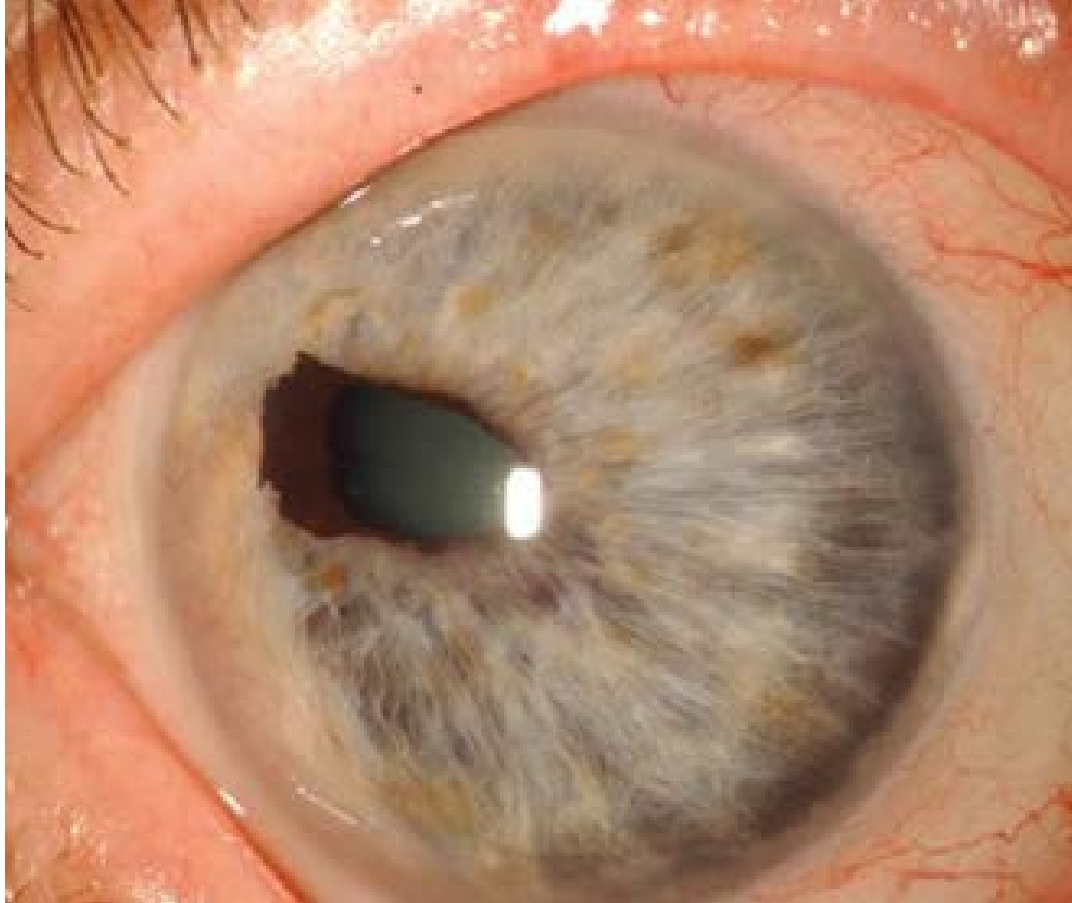


- Atrophy
- Corectopia
- Holes
- Ectropion uveae**
- Nodules
- Nevi?

What is ectropion uveae?


The presence of posterior pigmented epithelium at the pupil margin and adjacent anterior iris surface

Iridocorneal Endothelial (ICE) Syndrome

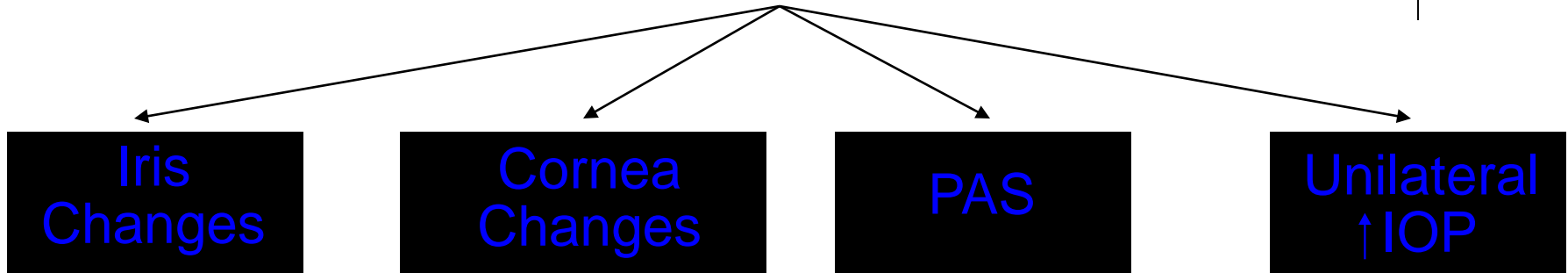


ICE: Ectropion uveae

Iridocorneal Endothelial (ICE) Syndrome



ICE: *Signs*



- Atrophy
- Corectopia
- Holes
- Ectropion uveae**
- Nodules
- Nevi?

What is ectropion uveae?

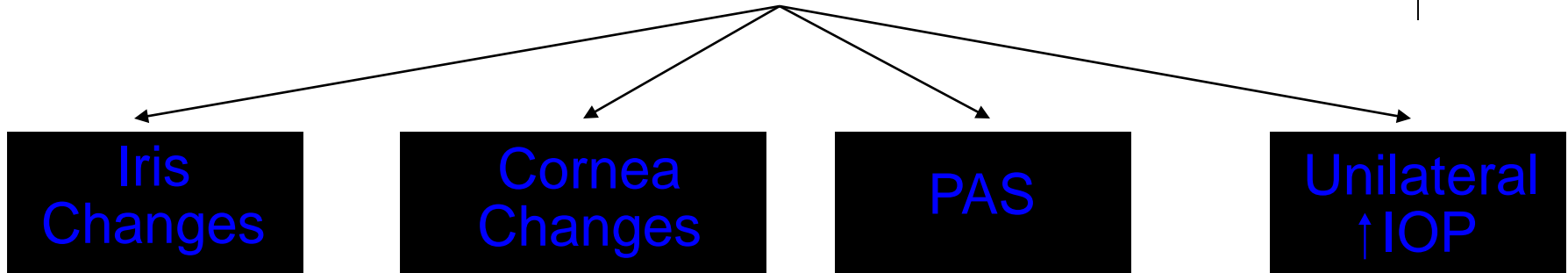
The presence of posterior pigmented epithelium at the pupil margin and adjacent anterior iris surface

How does it get there?

Iridocorneal Endothelial (ICE) Syndrome



ICE: *Signs*



--Atrophy
 --Corectopia
 --Holes
 --**Ectropion uveae**
 --Nodules
 --Nevi?


What is ectropion uveae?

The presence of posterior pigmented epithelium at the pupil margin and adjacent anterior iris surface

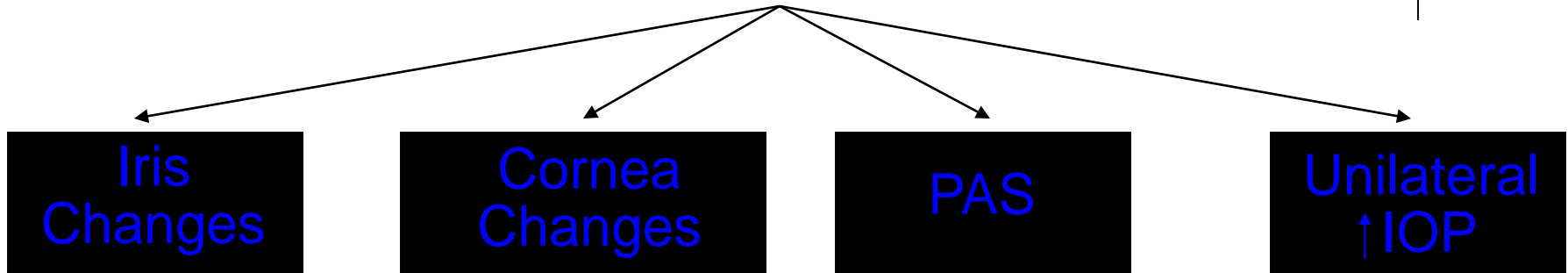
How does it get there?

It is pulled around the margin of the pupil by the contracting membrane on the surface of the iris

Iridocorneal Endothelial (ICE) Syndrome




ICE: *Signs*



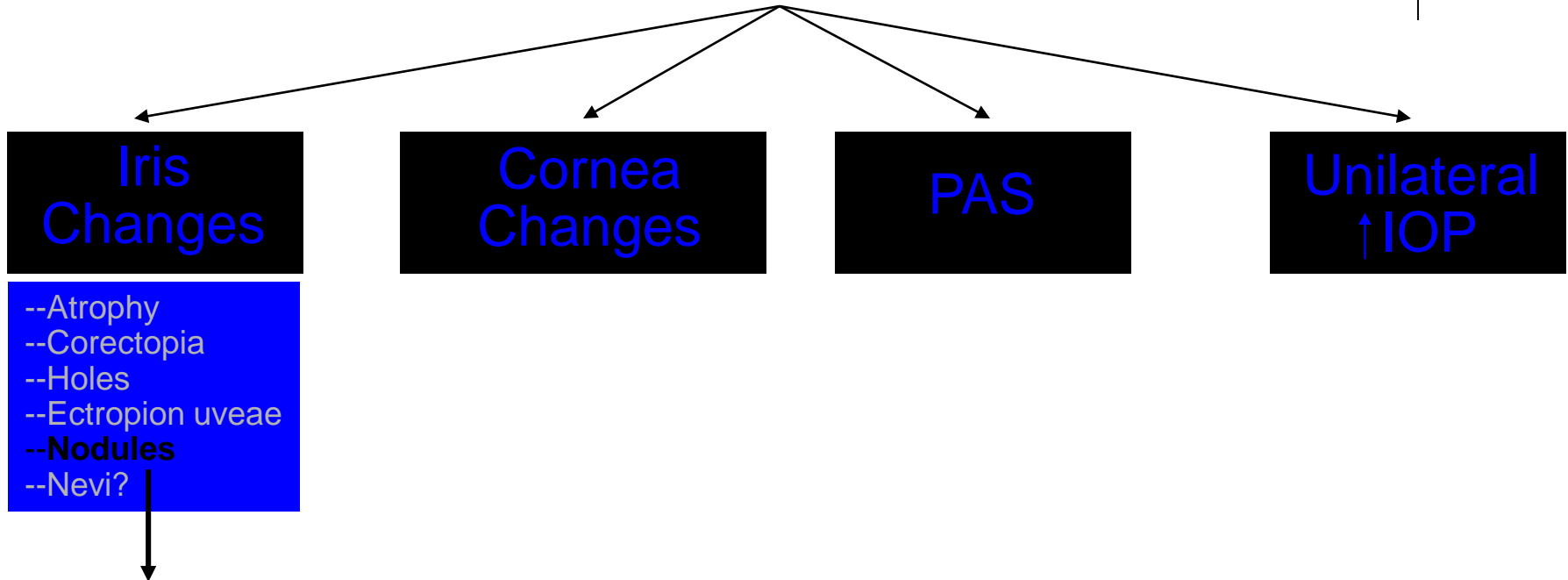
--Atrophy
--Corectopia
--Holes
--Ectropion uveae
--**Nodules**
--Nevi?

*What one-word description
is applied to the nodules?*

Iridocorneal Endothelial (ICE) Syndrome



ICE: *Signs*




*What one-word description
is applied to the nodules?
'Pedunculated'*


Iridocorneal Endothelial (ICE) Syndrome



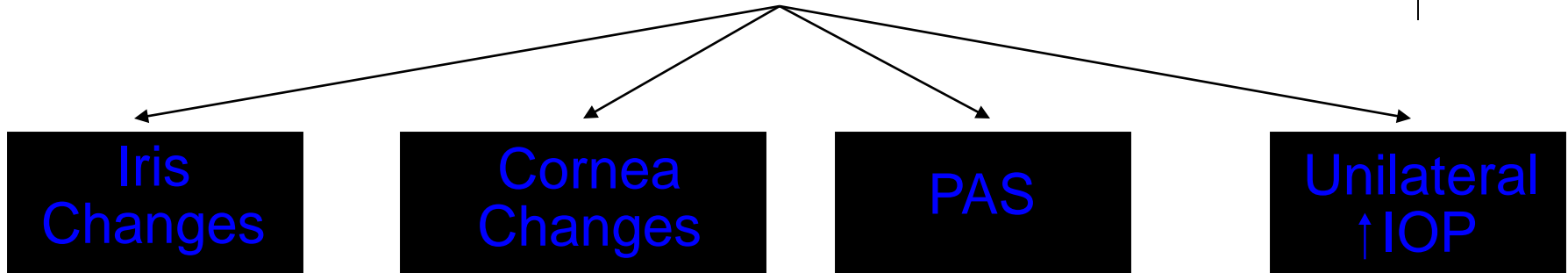
ICE: Iris nodules (note also the ectropion uveae)



Iridocorneal Endothelial (ICE) Syndrome




ICE: *Signs*



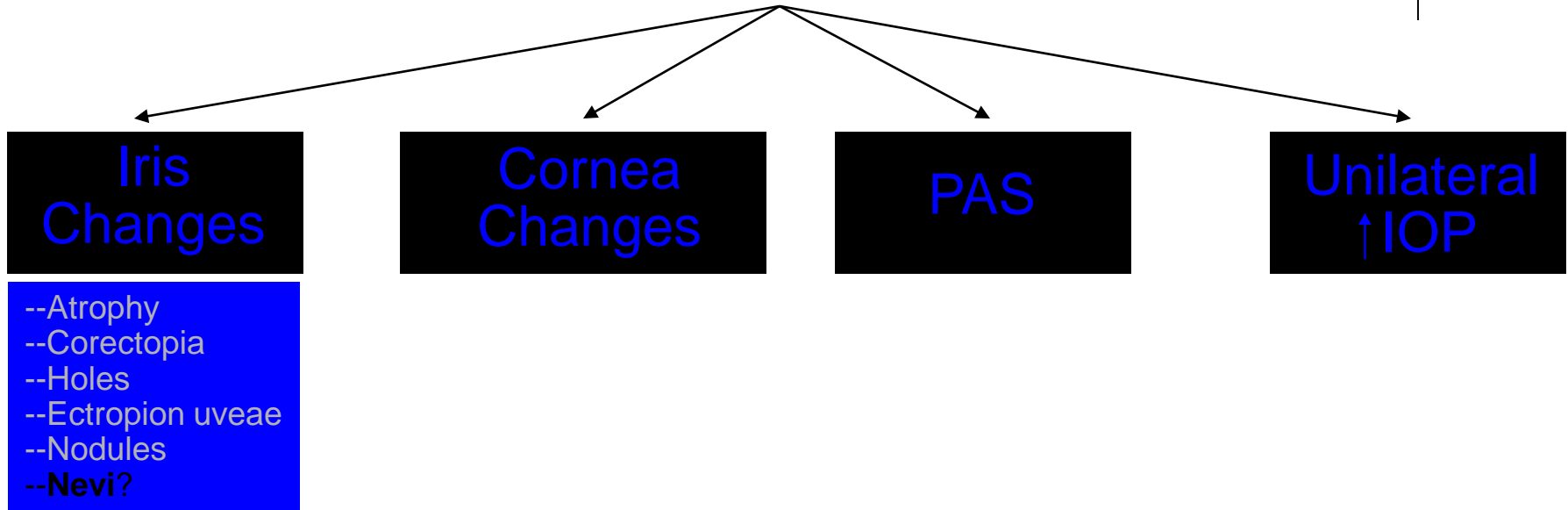
--Atrophy
--Corectopia
--Holes
--Ectropion uveae
--Nodules
--**Nevi?**

Are the 'nevi' actually nevi (ie, collections of melanocytes)?

Iridocorneal Endothelial (ICE) Syndrome

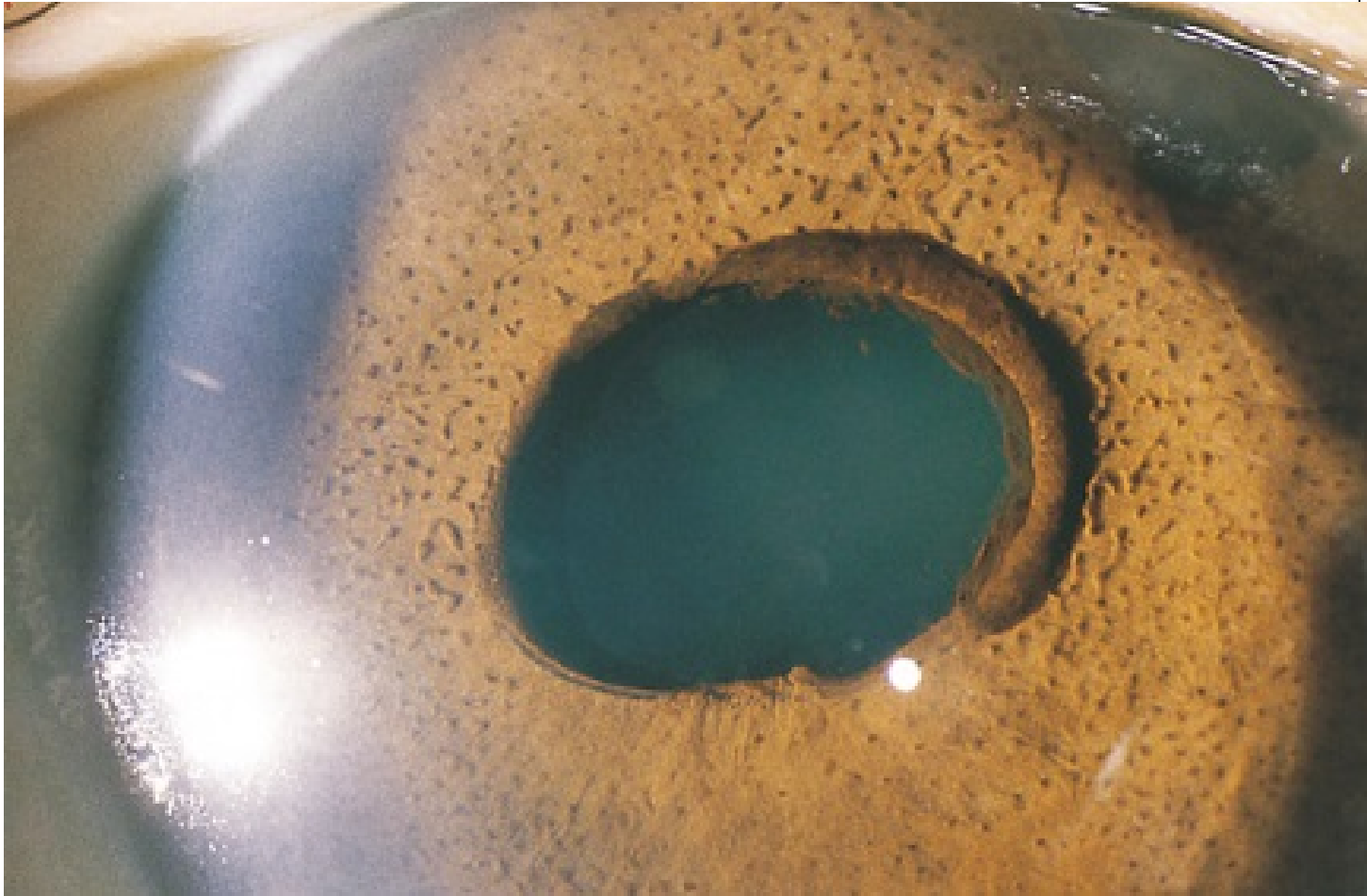


ICE: Signs




Are the 'nevi' actually nevi (ie, collections of melanocytes)?
No, they are pseudo-nevi--comprised in this case of focal areas of compressed iris stroma

Iridocorneal Endothelial (ICE) Syndrome

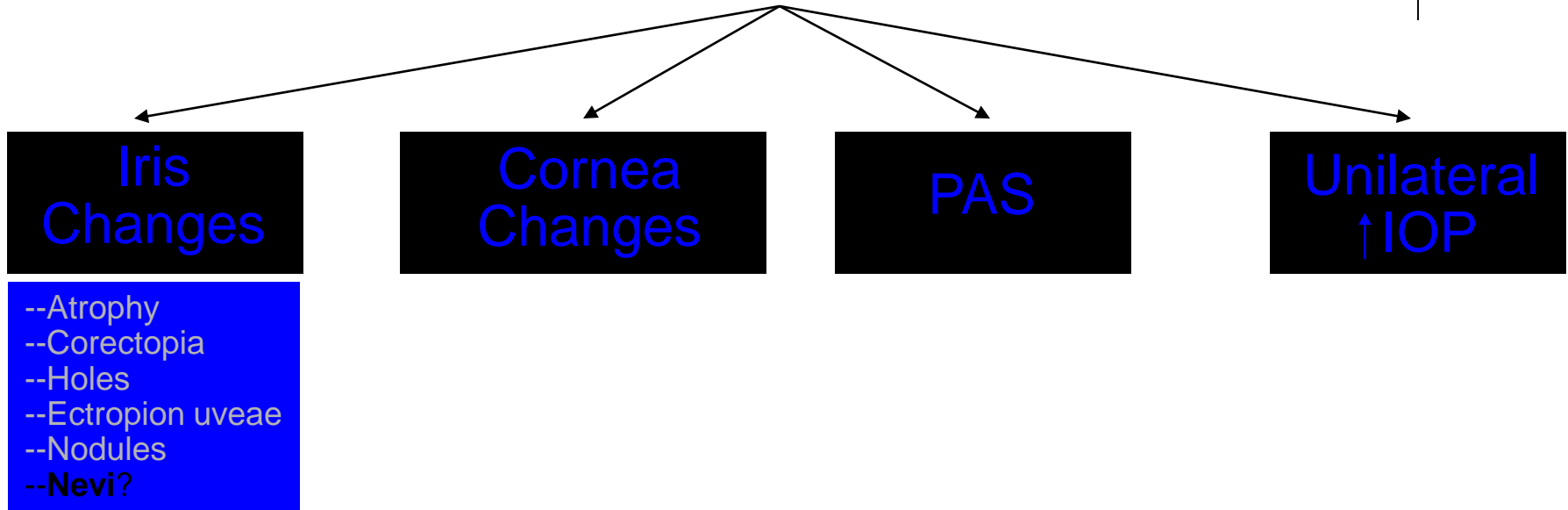


ICE: Iris nevi (and ectropion uveae)

Iridocorneal Endothelial (ICE) Syndrome



ICE: Signs



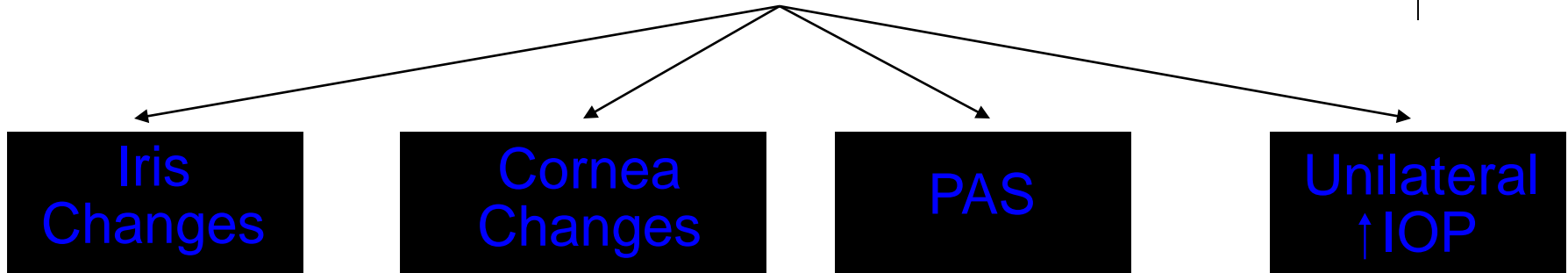
Are the 'nevi' actually nevi (ie, collections of melanocytes)?
 No, they are pseudo-nevi--comprised in this case of focal areas of compressed iris stroma

What is the etiology of the iris-stroma compression?

Iridocorneal Endothelial (ICE) Syndrome




ICE: Signs



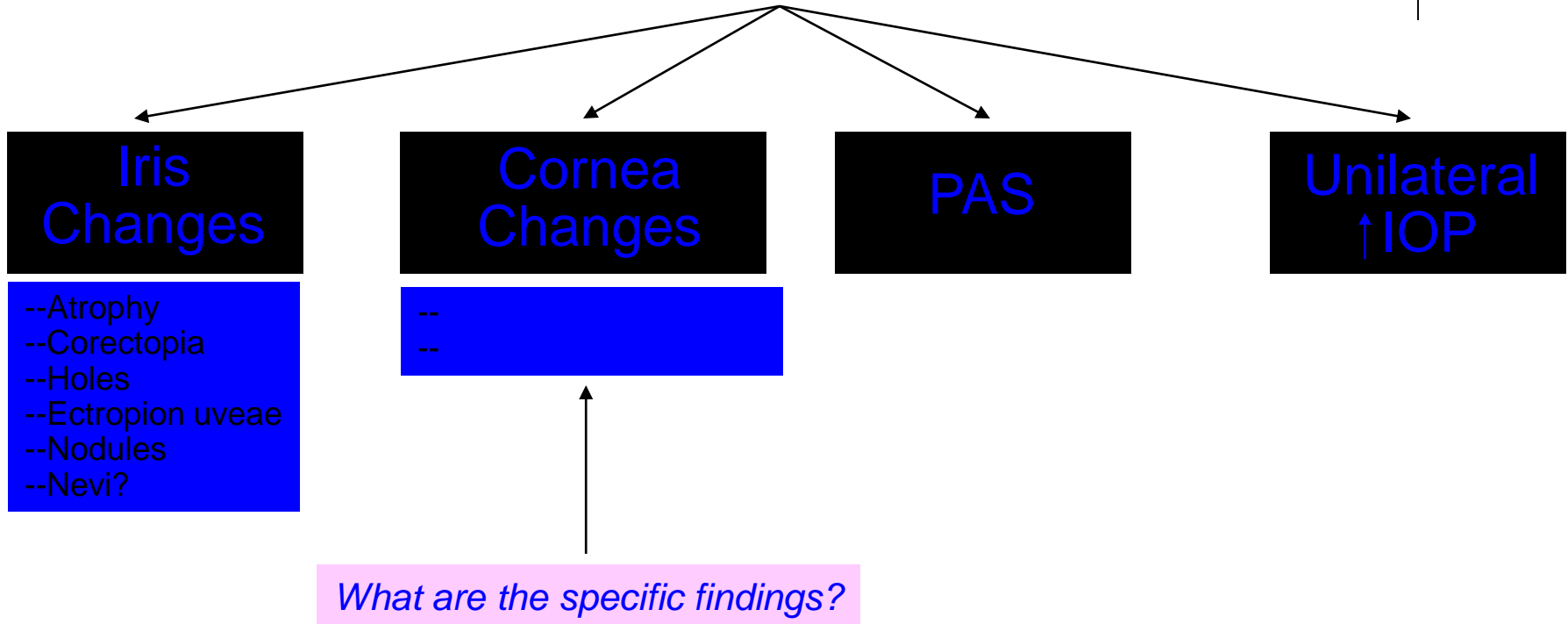
--Atrophy
 --Corectopia
 --Holes
 --Ectropion uveae
 --Nodules
 --**Nevi?**


Are the 'nevi' actually nevi (ie, collections of melanocytes)?
 No, they are pseudo-nevi--comprised in this case of focal areas of compressed iris stroma

What is the etiology of the iris-stroma compression?
 Contraction of the ICE membrane

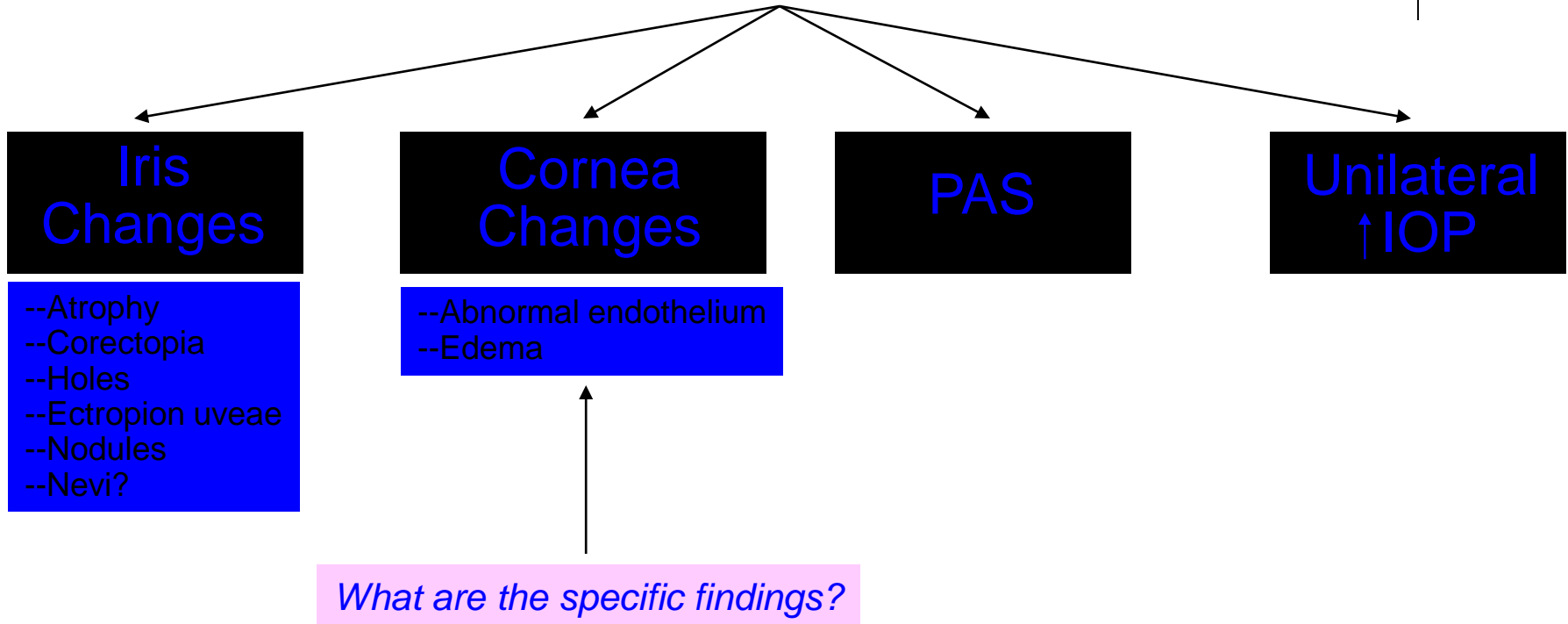


ICE: *Signs*






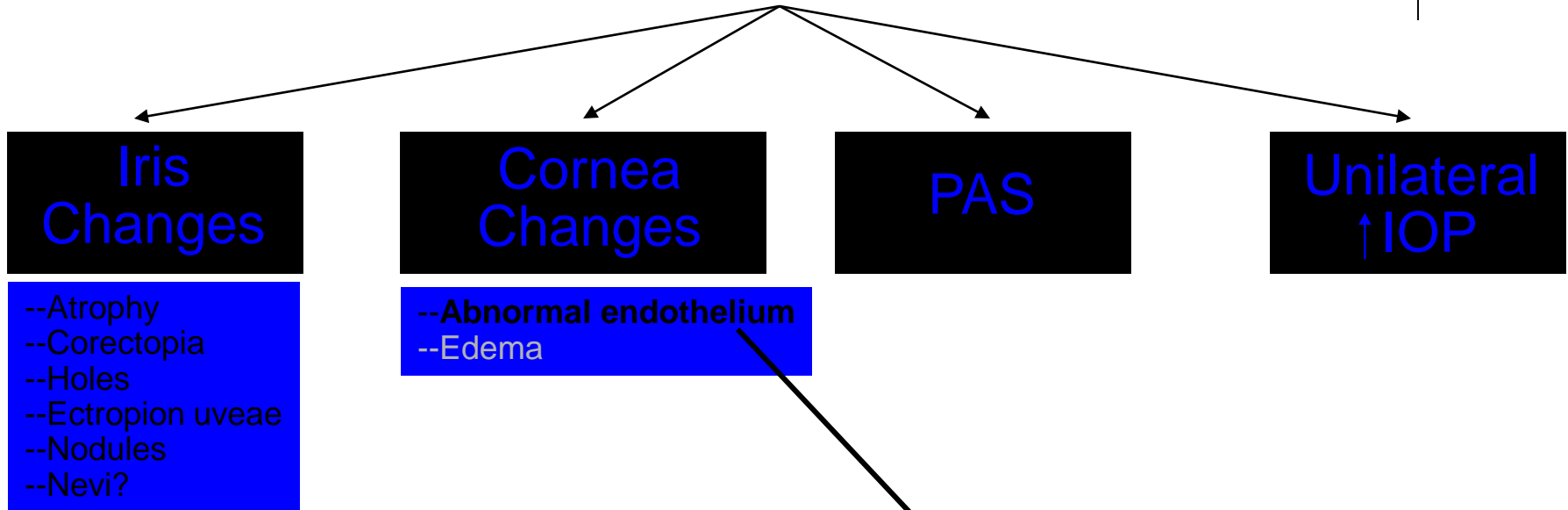
ICE: *Signs*



Iridocorneal Endothelial (ICE) Syndrome



ICE: *Signs*

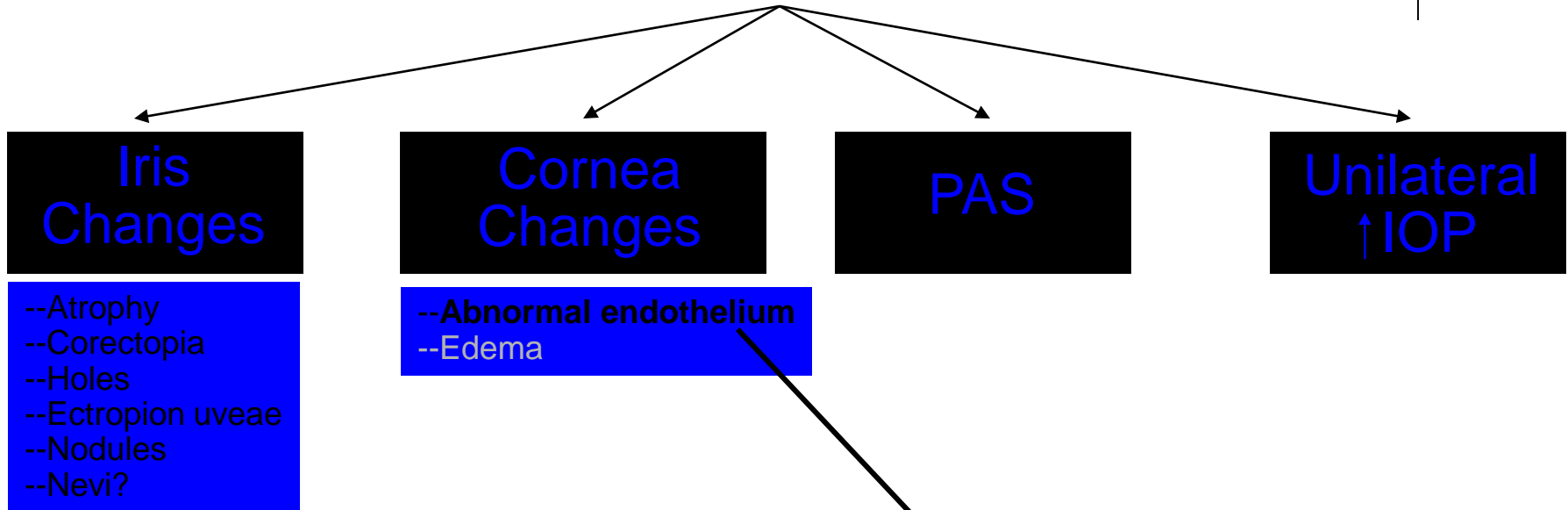


What is the classic two-word description of the endothelium's slit-lamp appearance in ICE?

Iridocorneal Endothelial (ICE) Syndrome

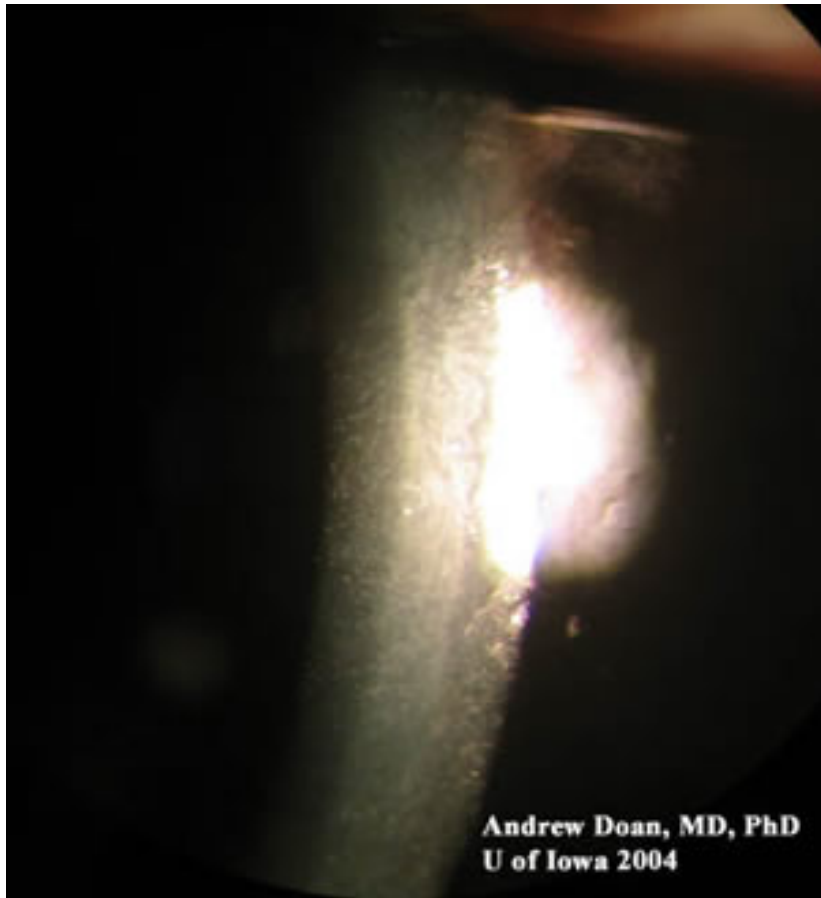



ICE: *Signs*



What is the classic two-word description of the endothelium's slit-lamp appearance in ICE?
'Hammered silver'

Iridocorneal Endothelial (ICE) Syndrome




Low res



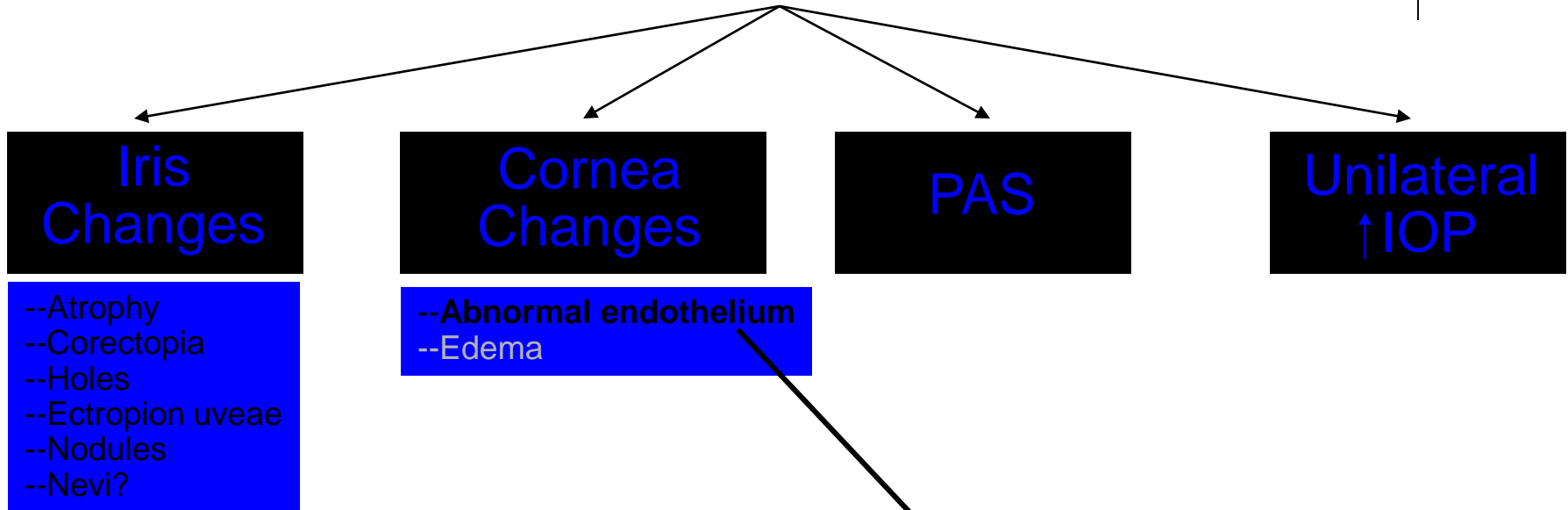
High res

ICE: 'Hammered silver' corneal endothelium

Iridocorneal Endothelial (ICE) Syndrome



ICE: Signs




What is the classic two-word description of the endothelium's slit-lamp appearance in ICE?

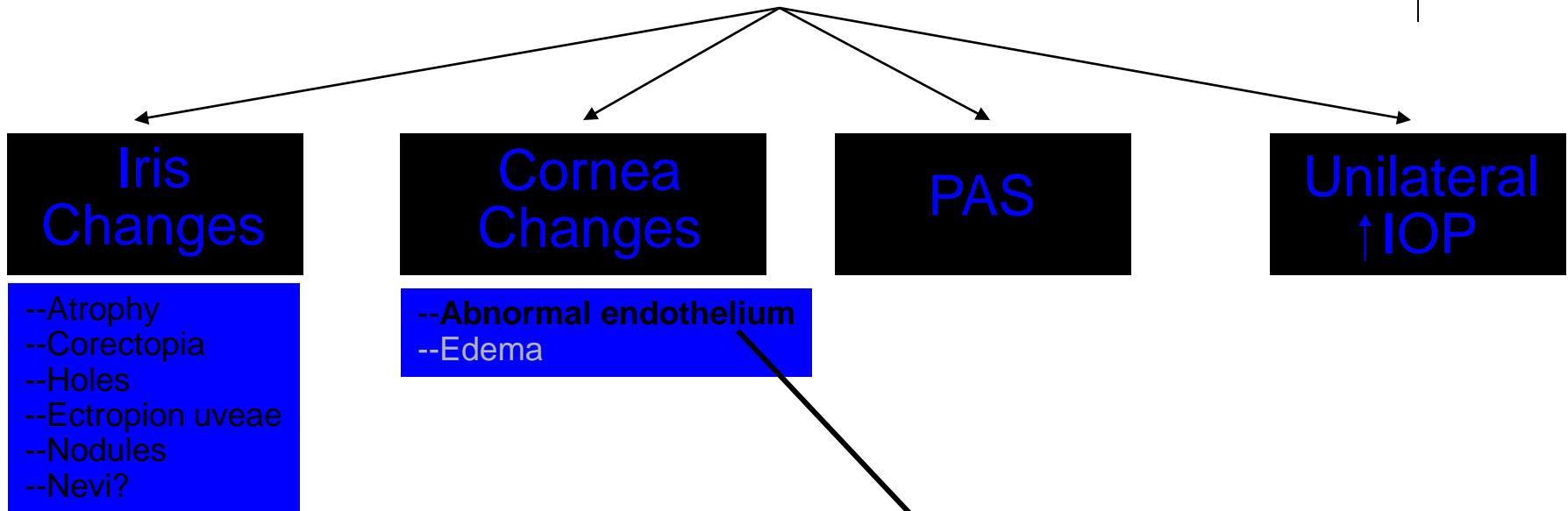
'Hammered silver'

*Another two-word descriptor for ICE endothelium is **beaten bronze**. In what other condition is this term used to describe the endothelium?*

Iridocorneal Endothelial (ICE) Syndrome



ICE: Signs




What is the classic two-word description of the endothelium's slit-lamp appearance in ICE?

'Hammered silver'


*Another two-word descriptor for ICE endothelium is **beaten bronze**. In what other condition is this term used to describe the endothelium?*

Fuch's endothelial dystrophy



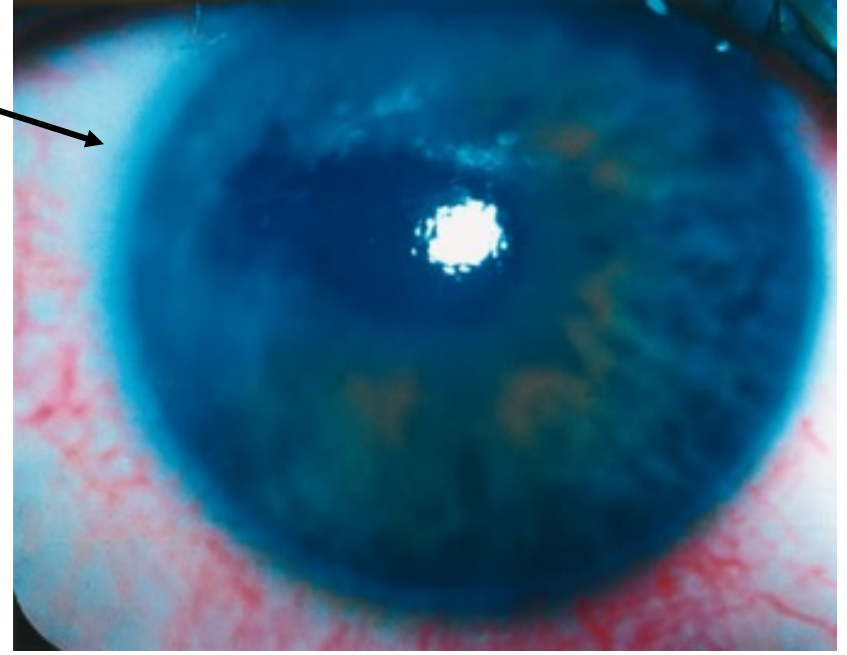
Iridocorneal Endothelial (ICE) Syndrome

ICE: Signs




- Atrophy
- Corectopia
- Holes
- Ectropion uveae
- Nodules
- Nevi?

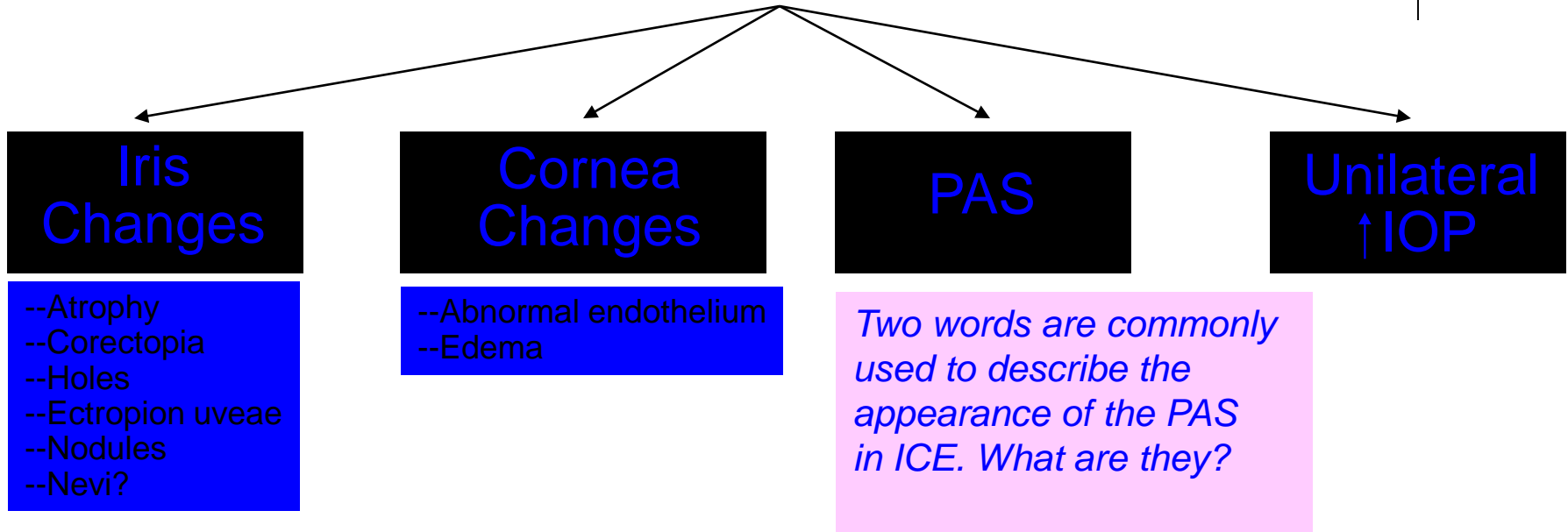
- Abnormal endothelium
- Edema



Iridocorneal Endothelial (ICE) Syndrome



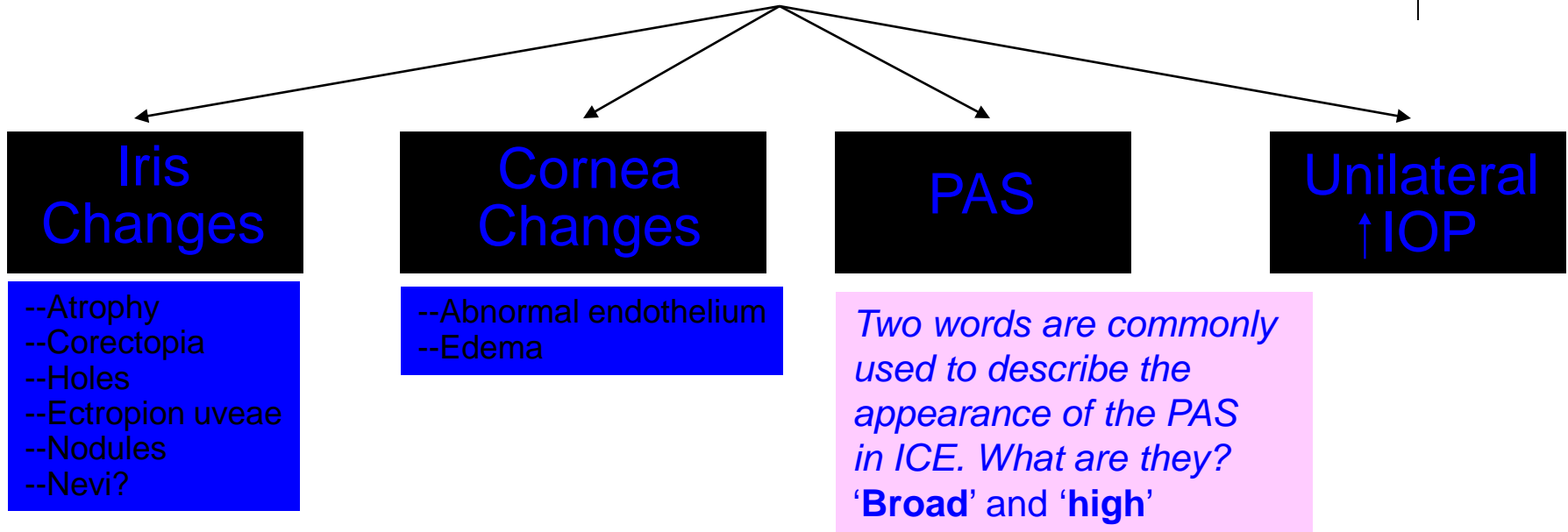
ICE: Signs




Iridocorneal Endothelial (ICE) Syndrome

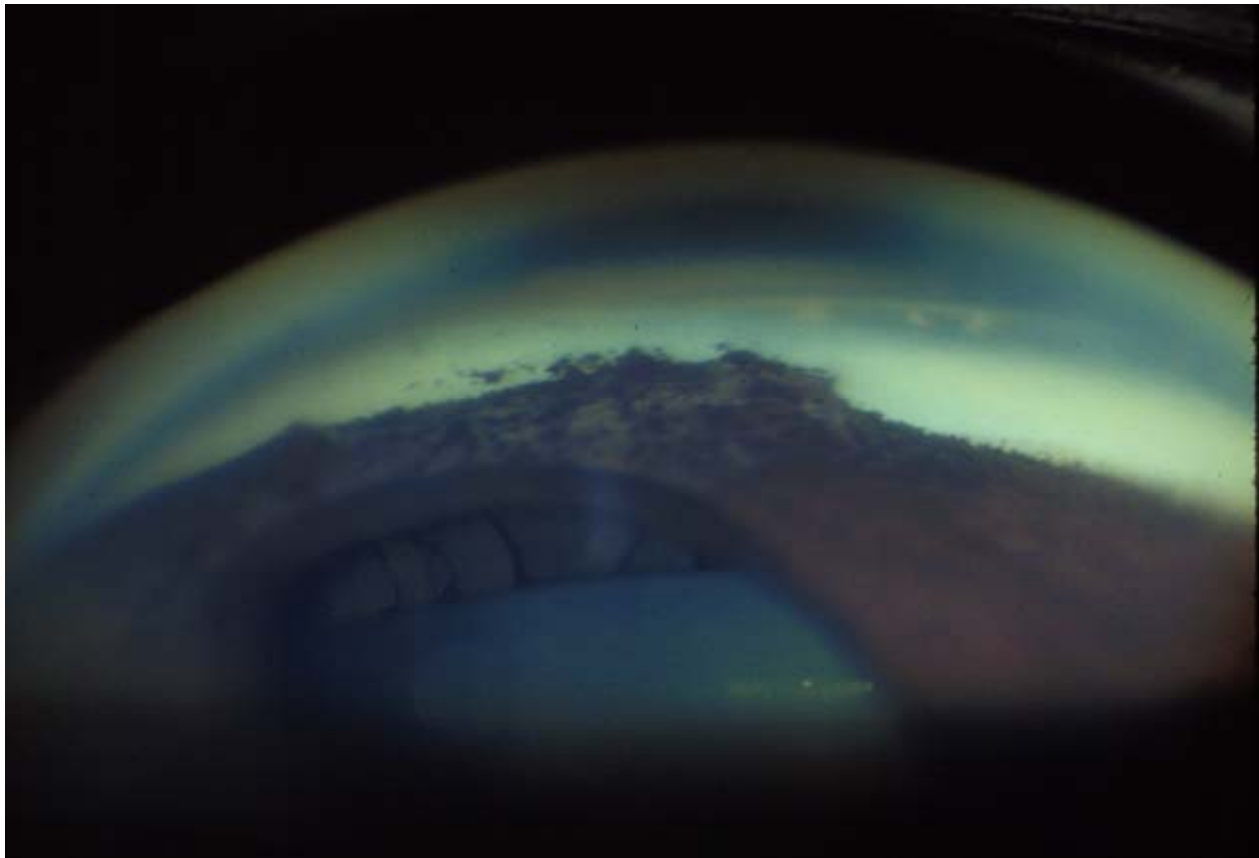


ICE: *Signs*






Iridocorneal Endothelial (ICE) Syndrome

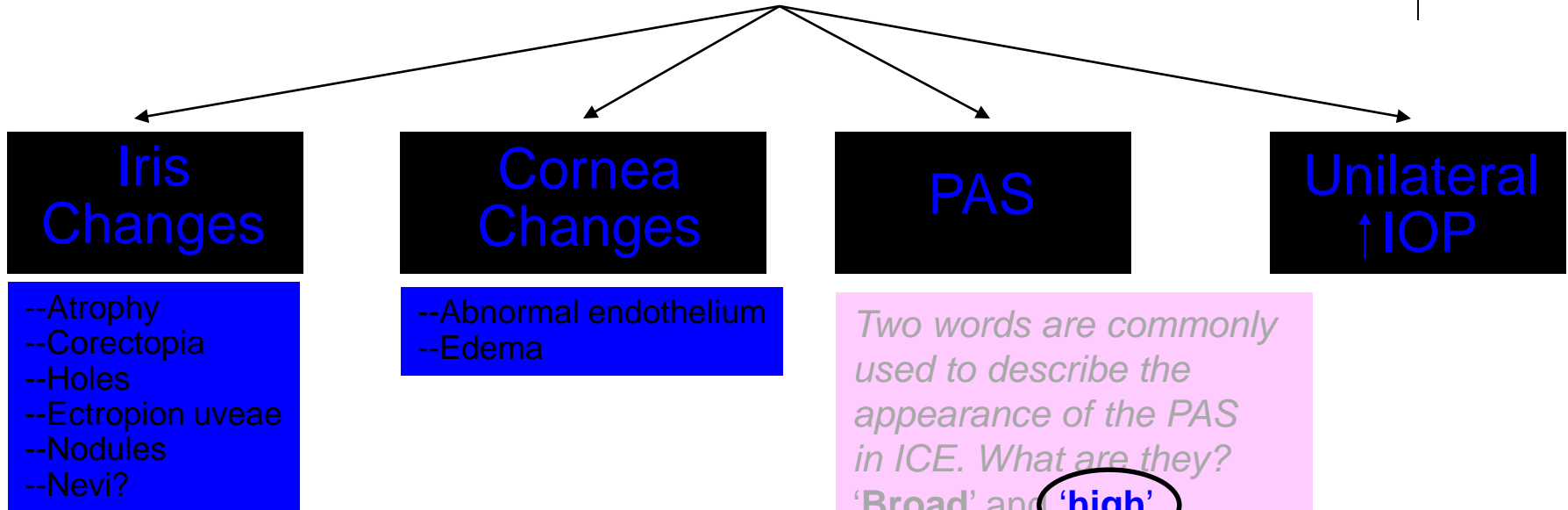


ICE: PAS

Iridocorneal Endothelial (ICE) Syndrome



ICE: Signs

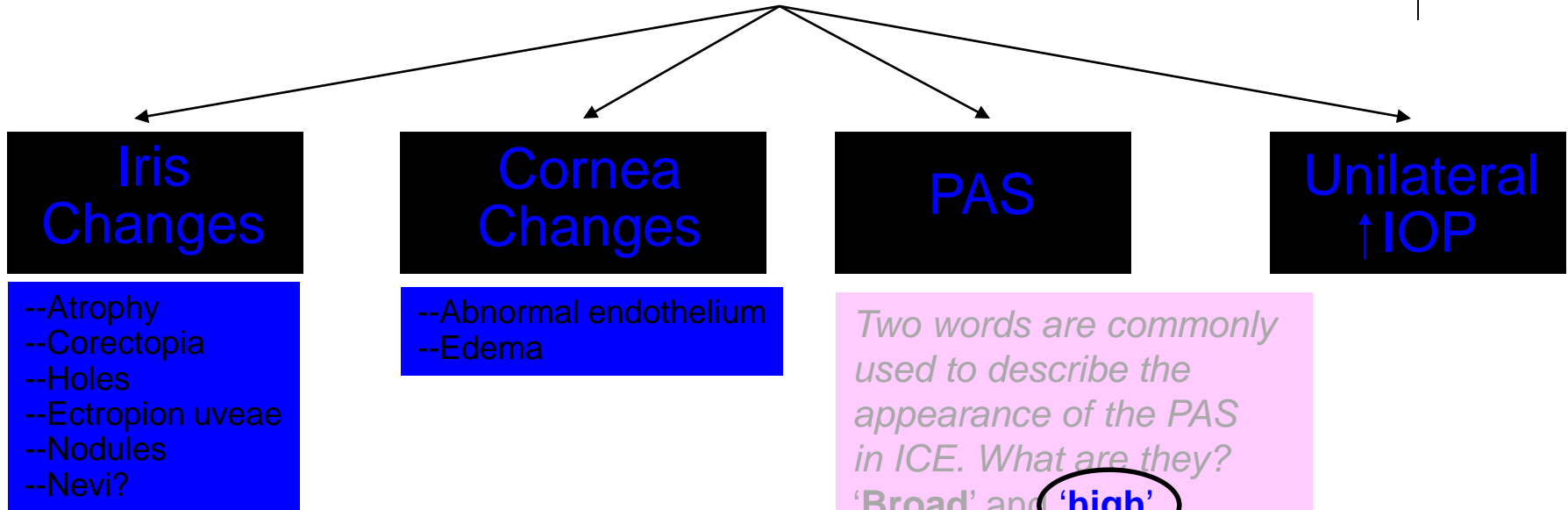


What does high mean in this context?

Iridocorneal Endothelial (ICE) Syndrome




ICE: Signs

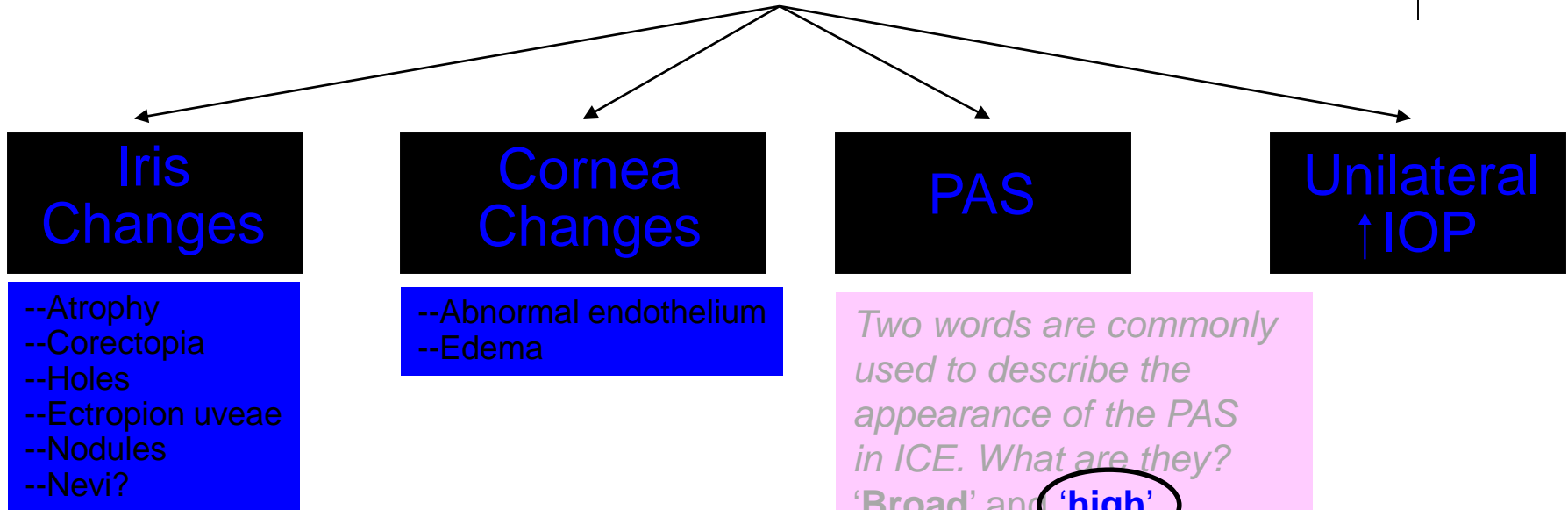


*What does high mean in this context?
That the PAS extend beyond Schwalbe's line (SL)*

Iridocorneal Endothelial (ICE) Syndrome



ICE: Signs



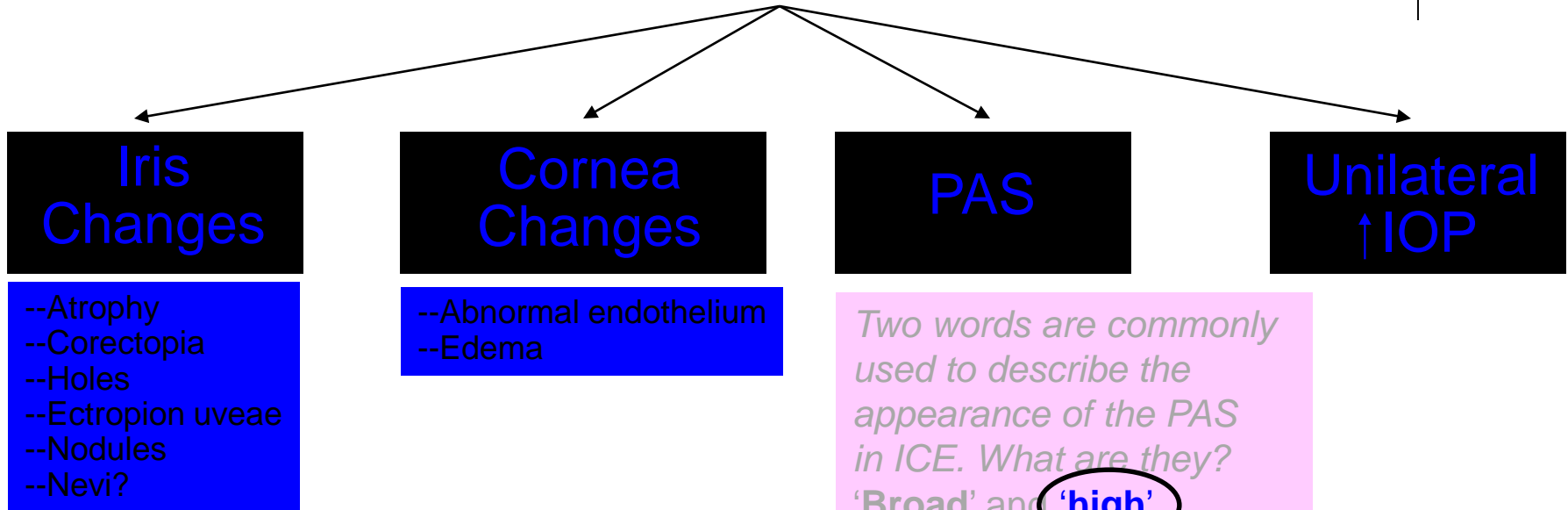
*What does high mean in this context?
That the PAS extend beyond Schwalbe's line (SL)*

Why is this considered 'high'?

Iridocorneal Endothelial (ICE) Syndrome




ICE: Signs



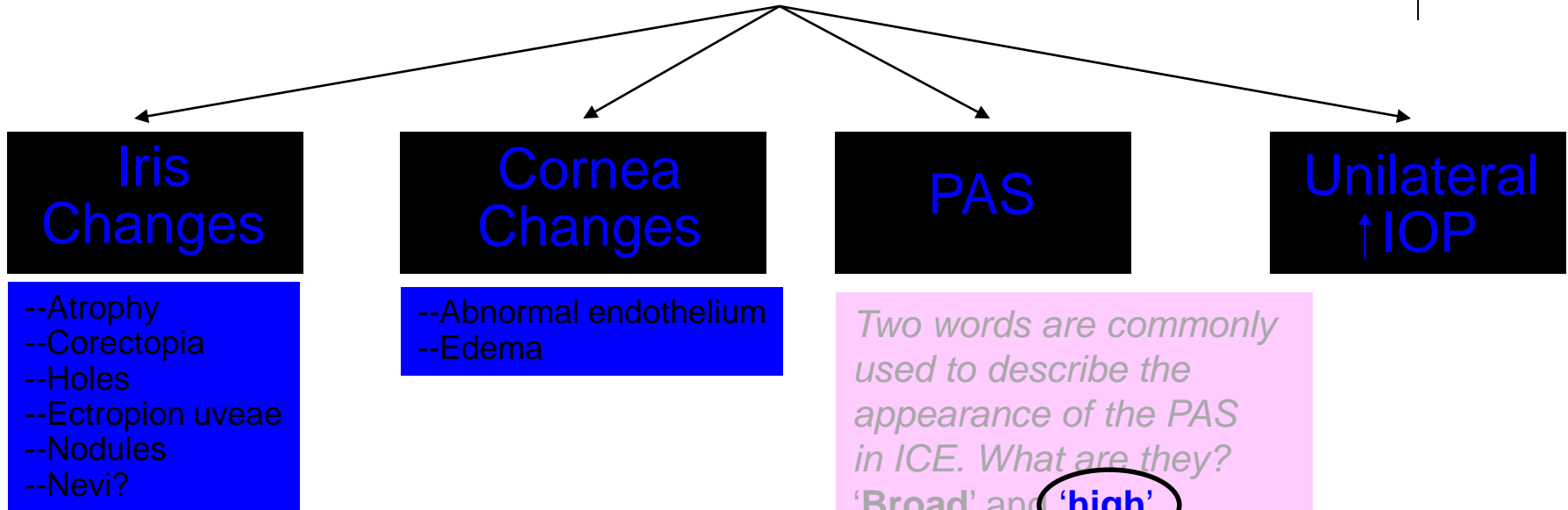
What does high mean in this context?
That the PAS extend beyond Schwalbe's line (SL)

Why is this considered 'high'?
Because PAS secondary to NVI/NVA **end** at SL

Iridocorneal Endothelial (ICE) Syndrome



ICE: Signs



What does high mean in this context?
That the PAS extend beyond Schwalbe's line (SL)

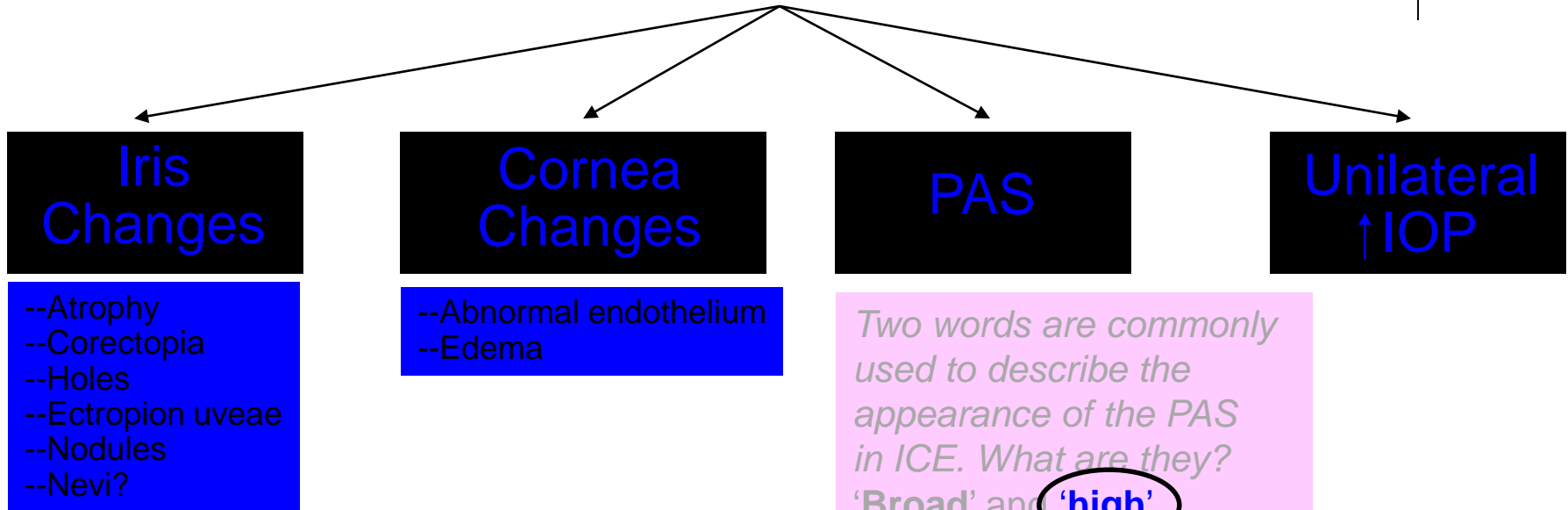
Why is this considered 'high'?
Because PAS secondary to NVI/NVA **end** at SL

Why does neo-related PAS end at SL?

Iridocorneal Endothelial (ICE) Syndrome



ICE: Signs




What does high mean in this context?
That the PAS extend beyond Schwalbe's line (SL)

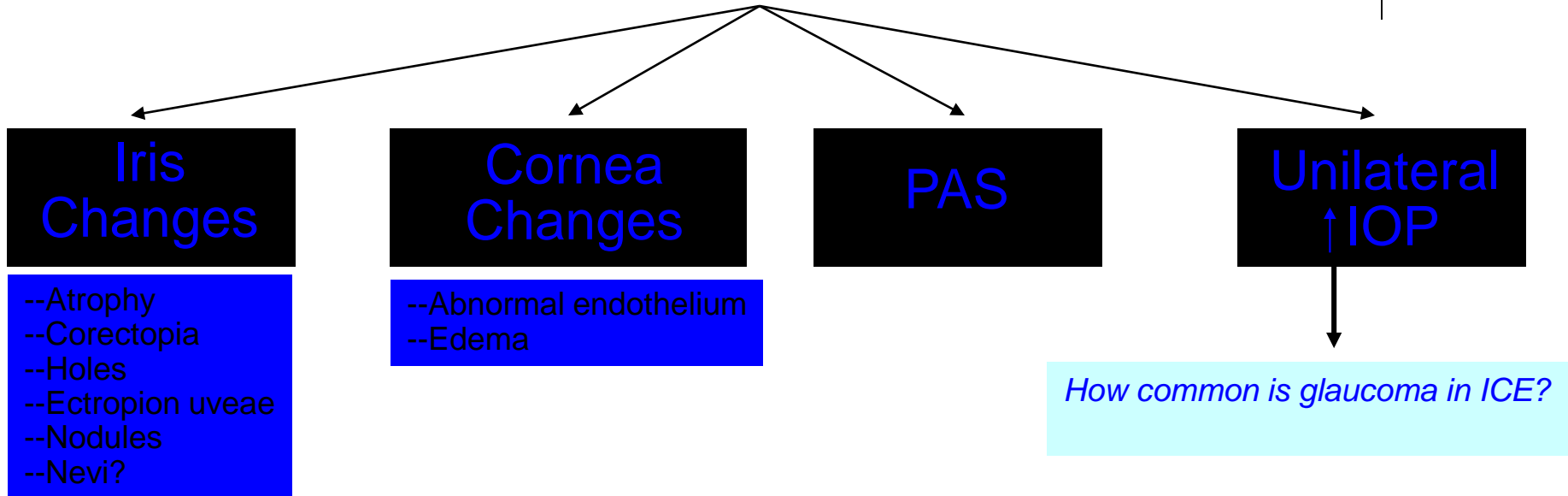
Why is this considered 'high'?
Because PAS secondary to NVI/NVA **end** at SL

Why does neo-related PAS end at SL?
Because neo can't grow over 'normal' endothelium


Iridocorneal Endothelial (ICE) Syndrome



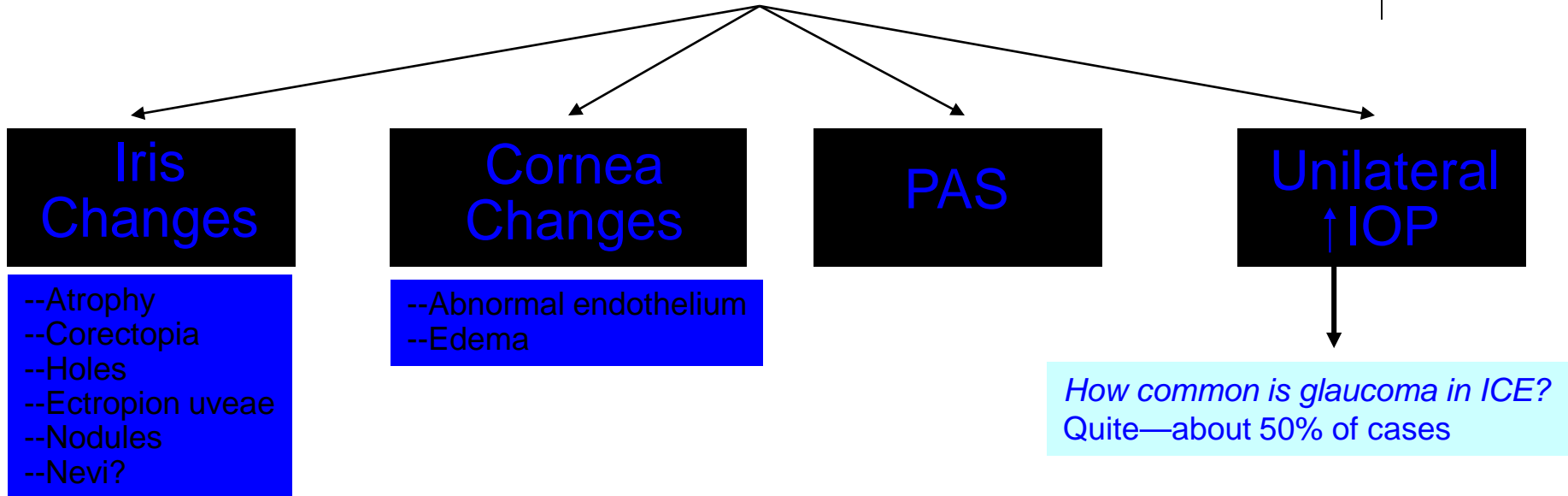
ICE: Signs




Iridocorneal Endothelial (ICE) Syndrome



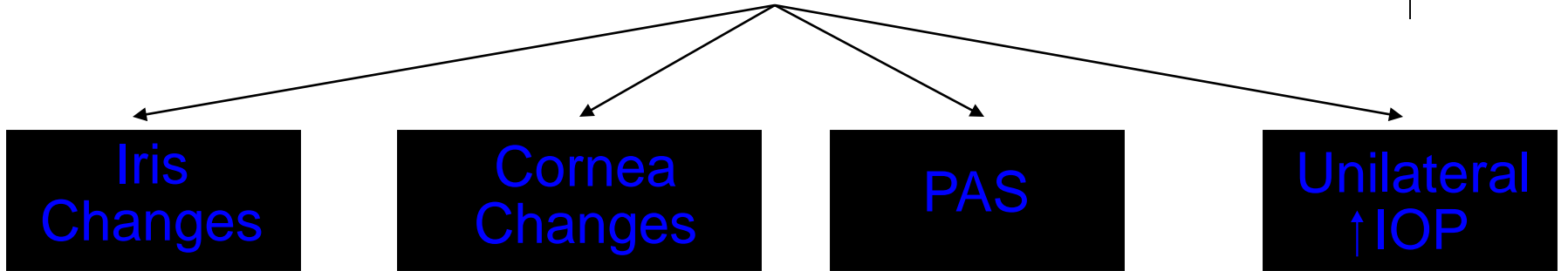
ICE: Signs





Iridocorneal Endothelial (ICE) Syndrome

ICE: Signs



- Iris Changes**
- Atrophy
 - Corectopia
 - Holes
 - Ectropion uveae
 - Nodules
 - Nevi?

- Cornea Changes**
- Abnormal endothelium
 - Edema

PAS

**Unilateral
↑ IOP**

Iris Nevus Syndrome

aka


Cogan-Reese Syndrome

Chandler Syndrome

Essential Iris Atrophy

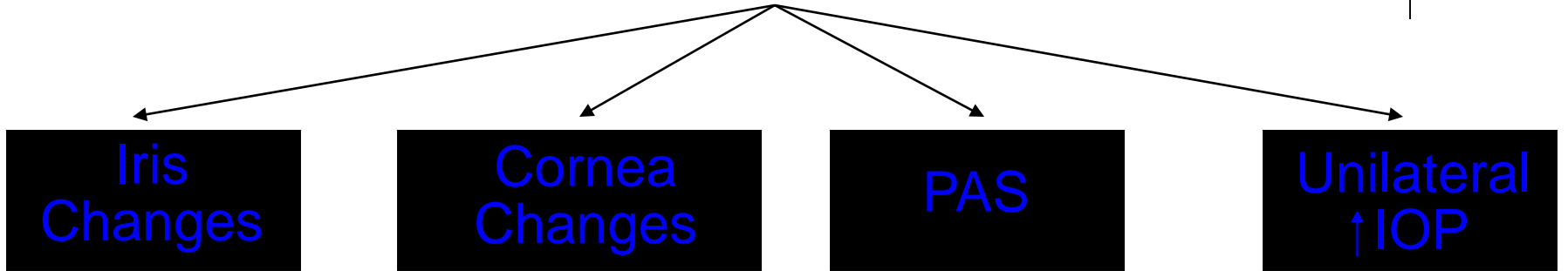
Now let's look at how the ICE subtypes manifest the various ICE signs...

ICE: Subtypes



Iridocorneal Endothelial (ICE) Syndrome

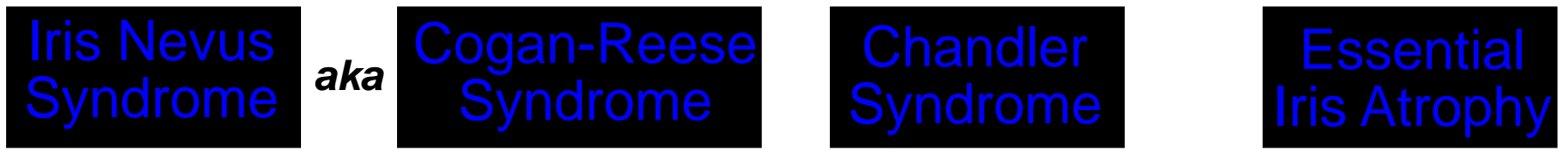ICE: Signs



- Atrophy
- Corectopia
- Holes
- Ectropion uveae
- Nodules
- Nevi?

- Abnormal endothelium
- Edema

All subtypes demonstrate, to varying degrees, **three findings:**




... ?

... ?

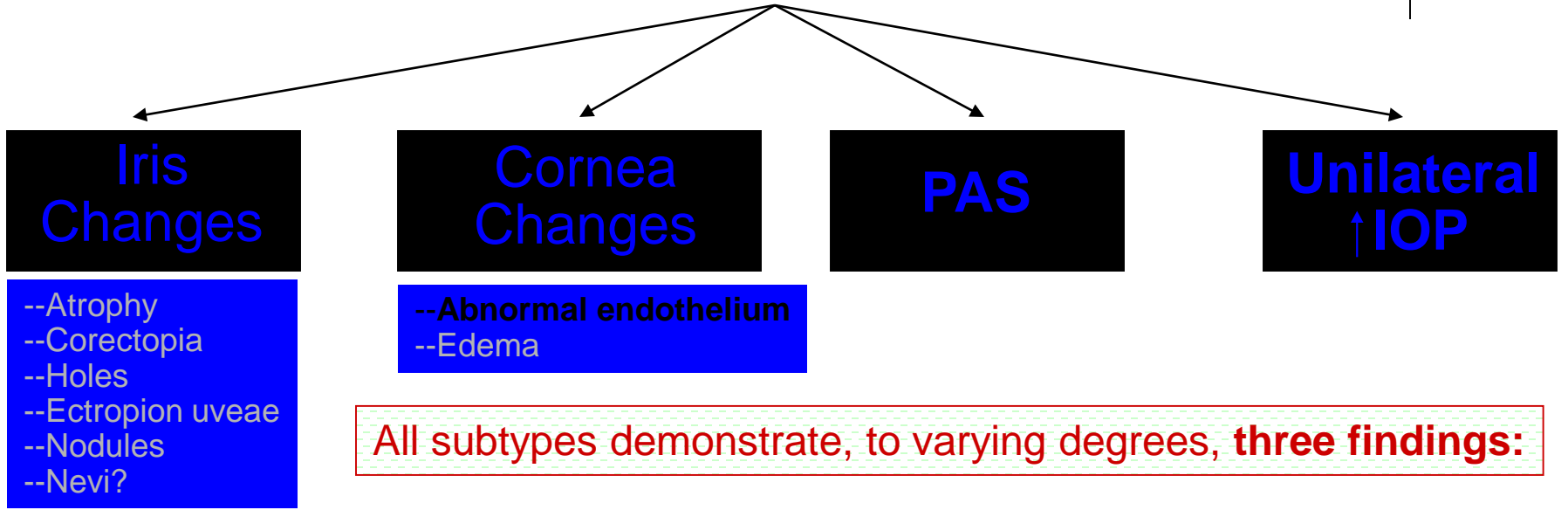
... ?

ICE: Subtypes

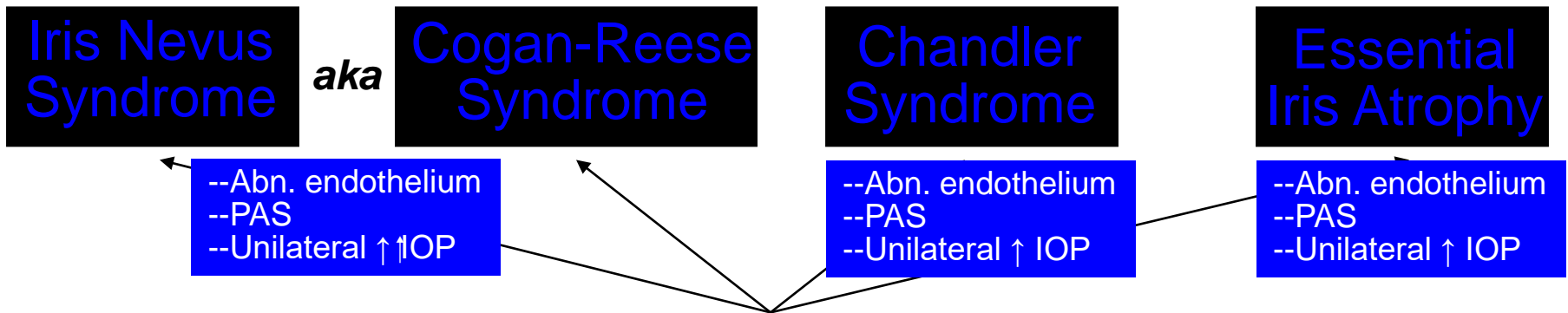


Iridocorneal Endothelial (ICE) Syndrome


ICE: Signs



All subtypes demonstrate, to varying degrees, **three findings:**




ICE: Subtypes




Iridocorneal Endothelial (ICE) Syndrome

ICE: Signs



- Atrophy
- Corectopia
- Holes
- Ectropion uveae
- Nodules
- Nevi?

- Abnormal endothelium
- Edema




- Abn. endothelium
- PAS
- Unilateral ↑ IOP

- Abn. endothelium
- PAS
- Unilateral ↑ IOP


- Abn. endothelium
- PAS
- Unilateral ↑ IOP

One subtype tends to have more modest IOP elevation than the others—which one?



Iridocorneal Endothelial (ICE) Syndrome

ICE: Signs



- Atrophy
- Corectopia
- Holes
- Ectropion uveae
- Nodules
- Nevi?

- Abnormal endothelium
- Edema

Iris Nevus Syndrome

aka

Cogan-Reese Syndrome

Chandler Syndrome


Essential Iris Atrophy

- Abn. endothelium
- PAS
- Unilateral ↑ IOP

- Abn. endothelium
- PAS
- Unilateral ↑ IOP

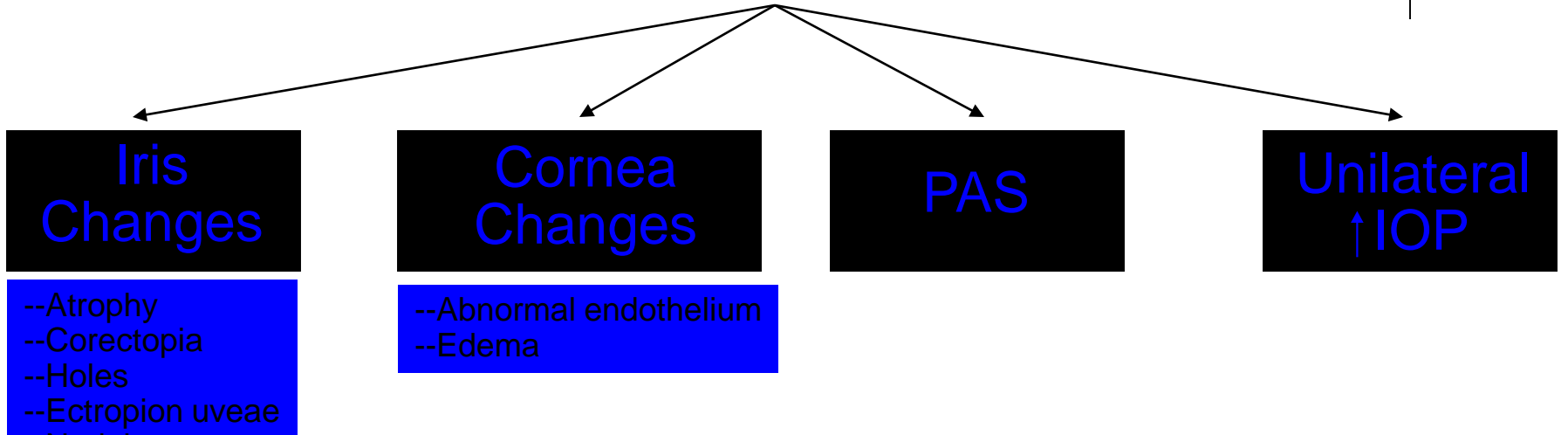
- Abn. endothelium
- PAS
- Unilateral ↑ IOP

One subtype tends to have more modest IOP elevation than the others—which one?
Chandler syndrome

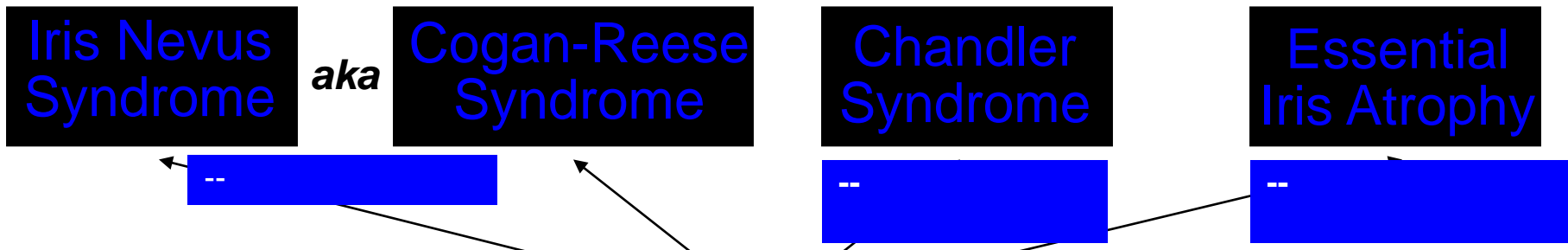


Iridocorneal Endothelial (ICE) Syndrome

ICE: Signs



However, each has a **key finding** that 'makes' the subtype:

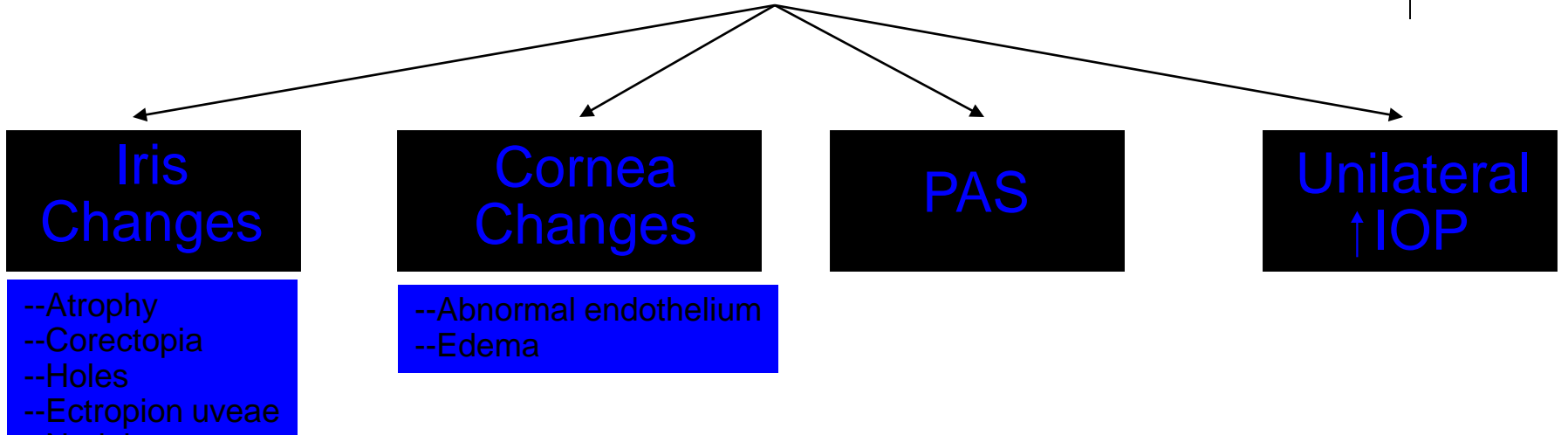


ICE: Subtypes



Iridocorneal Endothelial (ICE) Syndrome

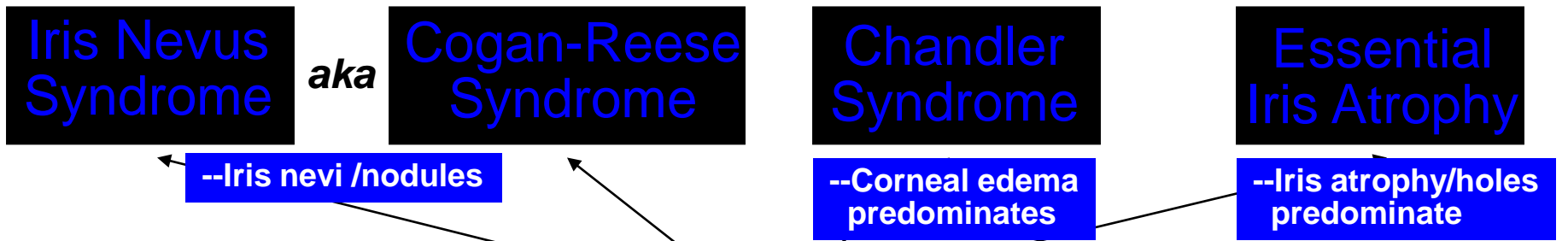
ICE: Signs



- Atrophy
- Corectopia
- Holes
- Ectropion uveae
- Nodules
- Nevi?

- Abnormal endothelium
- Edema

However, each has a **key finding** that 'makes' the subtype:

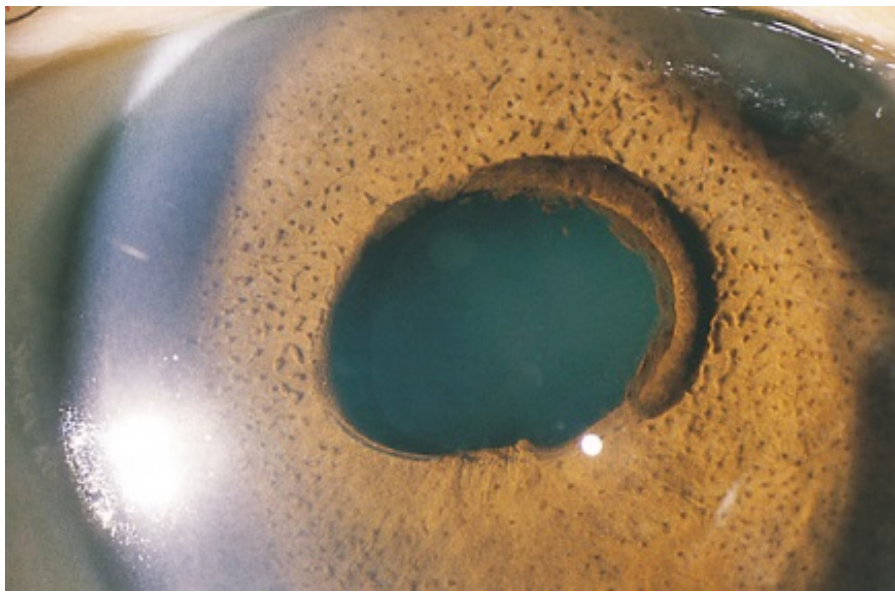


--Iris nevi /nodules


--Corneal edema predominates

--Iris atrophy/holes predominate

ICE: Subtypes

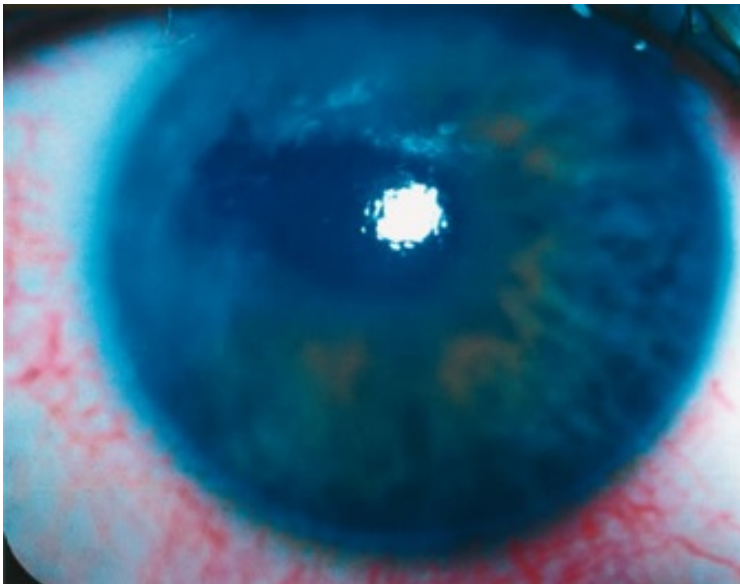


heli

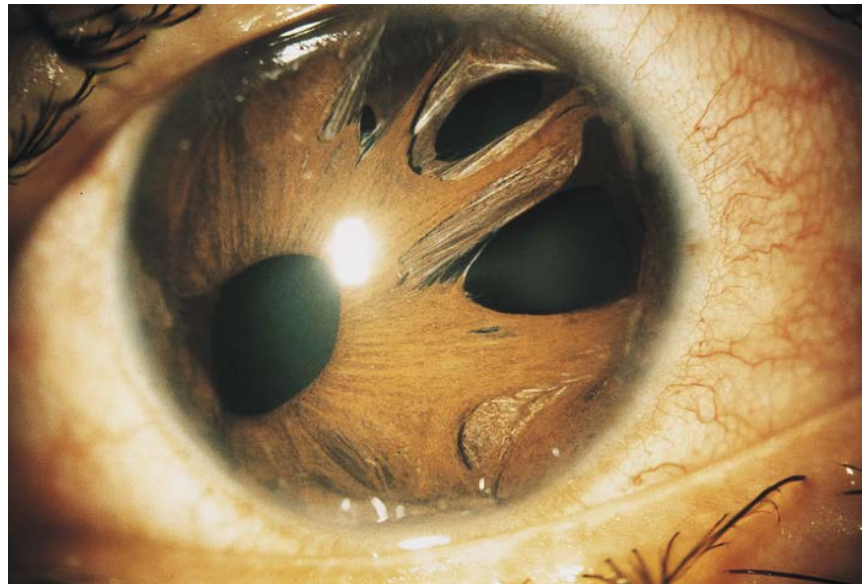

Iris nevus/Cogan-Reese syndrome


Iris nevus/Cogan-Reese syndrome



Chandler syndrome




Essential iris atrophy



Iridocorneal Endothelial (ICE) Syndrome

ICE: Signs




--Atrophy

--Abnormal endothelium

Of the four categories of signs (ie, iris changes, cornea changes, PAS and elevated IOP), which one is most important in differentiating among the ICE subtypes?

--Nevi?



aka

--Iris nevi /nodules

--Corneal edema predominates

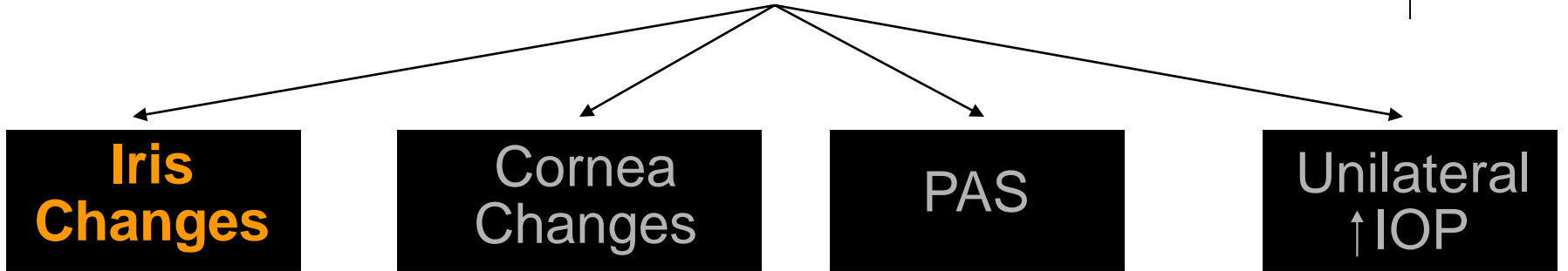
--Iris atrophy/holes predominate

ICE: Subtypes

Iridocorneal Endothelial (ICE) Syndrome



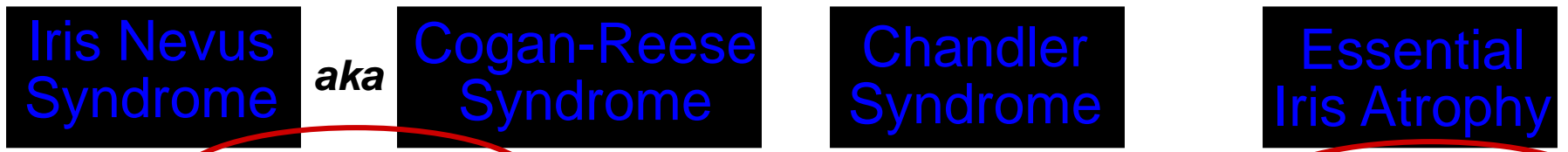ICE: Signs



- Atrophy
- Nevi?

--Abnormal endothelium

Of the four categories of signs (ie, iris changes, cornea changes, PAS and elevated IOP), which one is most important in differentiating among the ICE subtypes?
The **clinical status of the iris** is most important




--Iris nevi/nodules

--Corneal edema predominates
--Relatively *nl* iris

--Iris atrophy/holes predominate

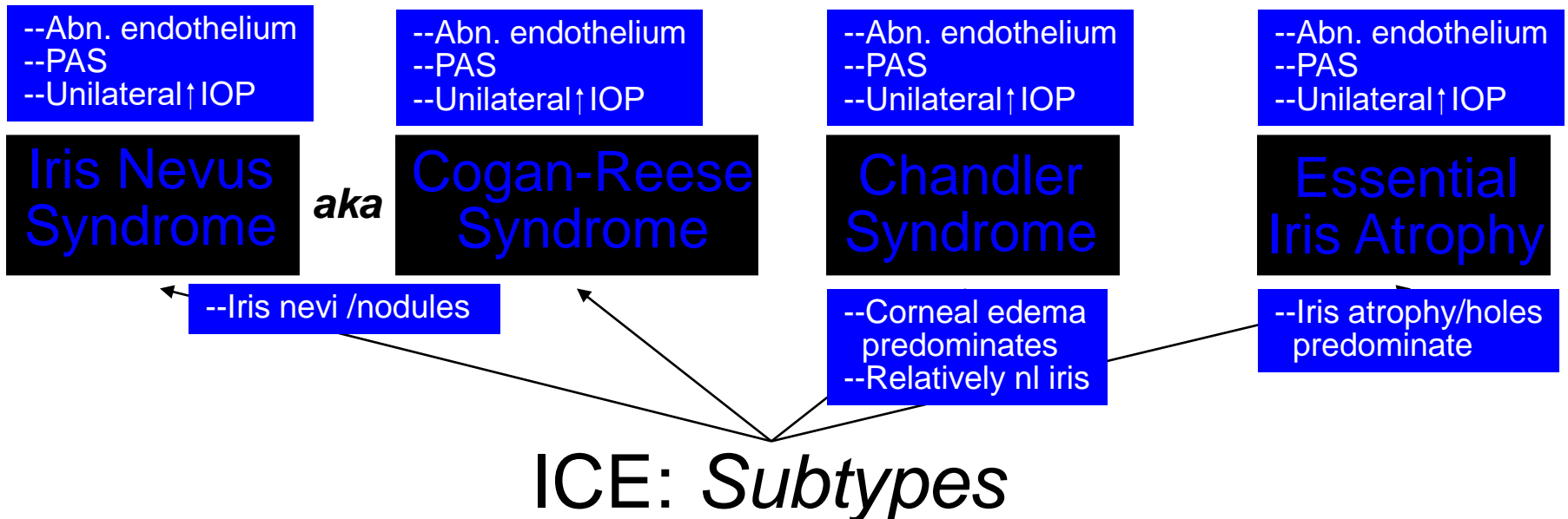
(Note that one of the hallmarks of **Chandler syndrome** is the relative **absence of iris changes**, which makes iris status important in its diagnosis too)

Iridocorneal Endothelial (ICE) Syndrome




What are the main management issues in ICE?

1)
2)

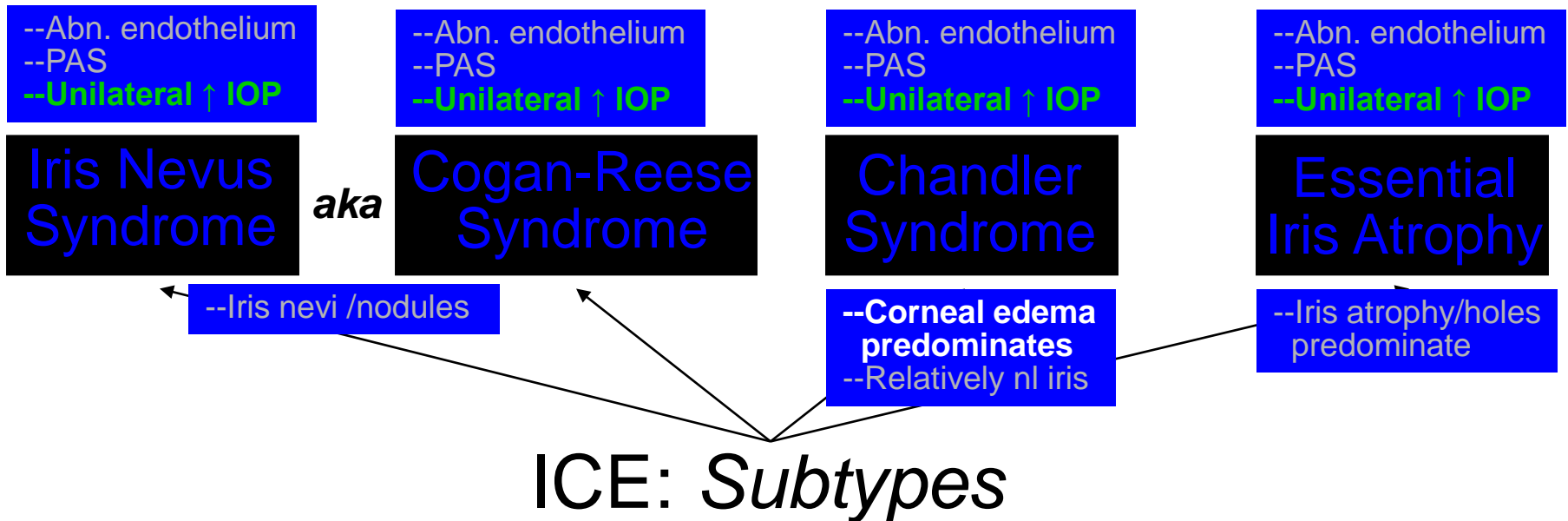


Iridocorneal Endothelial (ICE) Syndrome



What are the main management issues in ICE?

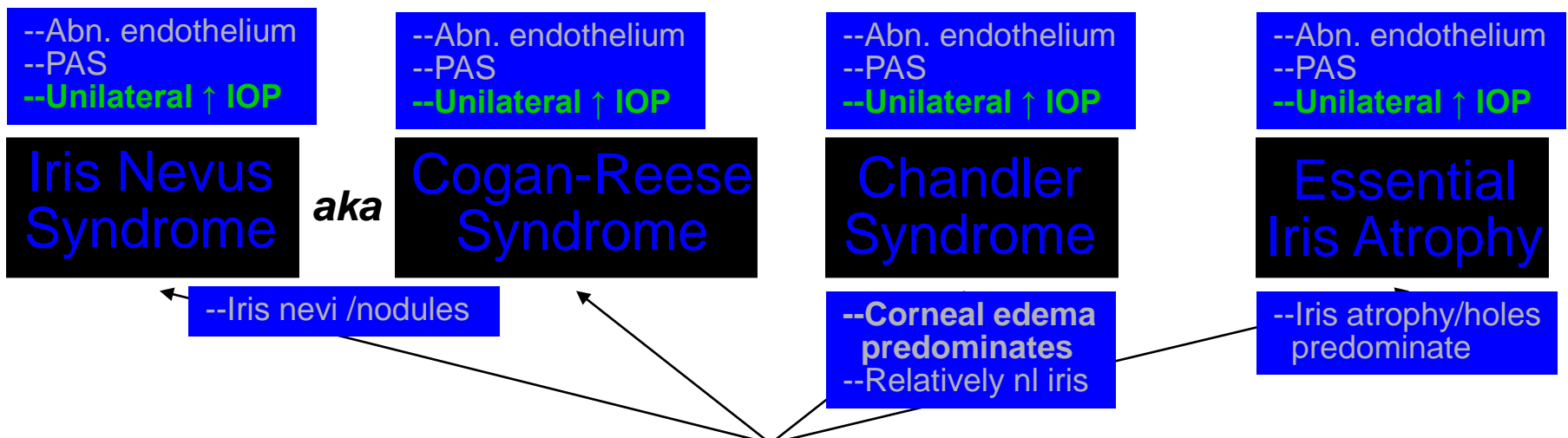
- 1) IOP/glaucoma control
- 2) Minimizing corneal edema



Iridocorneal Endothelial

Which meds are most effective?

What are the main management issues in ICE?
1) IOP/glaucoma control
 2) Minimizing corneal edema



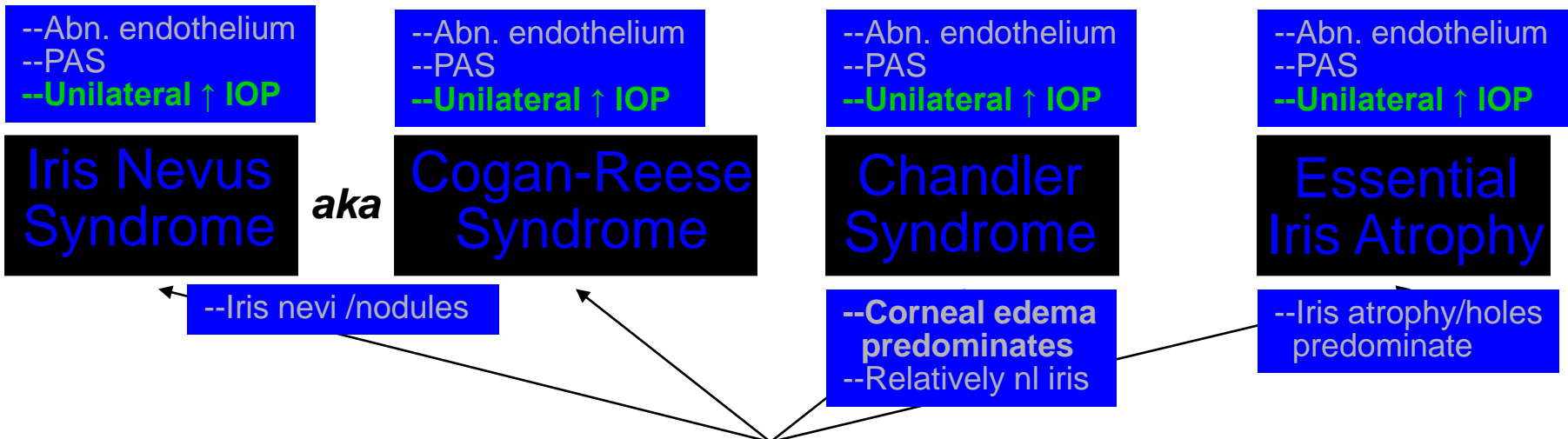
ICE: Subtypes

Iridocorneal Endothelial

Which meds are most effective?
Aqueous suppressants, which are:
-- β blockers
--Carbonic anhydrase inhibitors
-- α agonists

What are the main management issues in ICE?

- 1) IOP/glaucoma control
- 2) Minimizing corneal edema



ICE: Subtypes

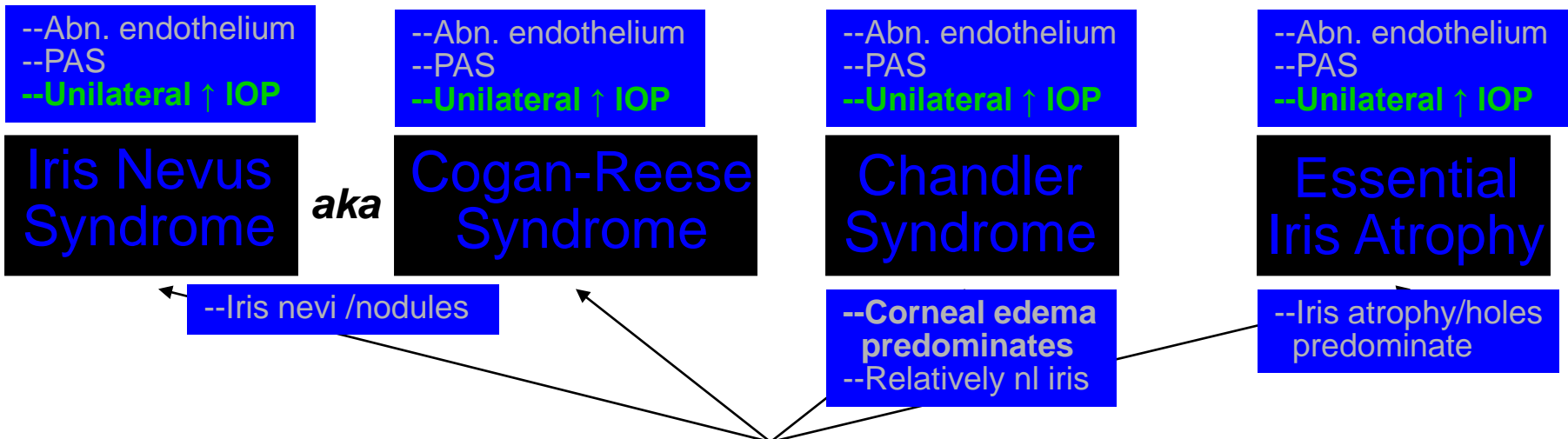
Iridocorneal Endothelial

Which meds are most effective?
 Aqueous suppressants, which are:
 -- β blockers
 --Carbonic anhydrase inhibitors
 -- α agonists

If medical management is inadequate, should filtering surgery be attempted?

What are the main management issues in ICE?

- 1) IOP/glaucoma control
- 2) Minimizing corneal edema



ICE: Subtypes

Iridocorneal Endothelial

Which meds are most effective?

Aqueous suppressants, which are:

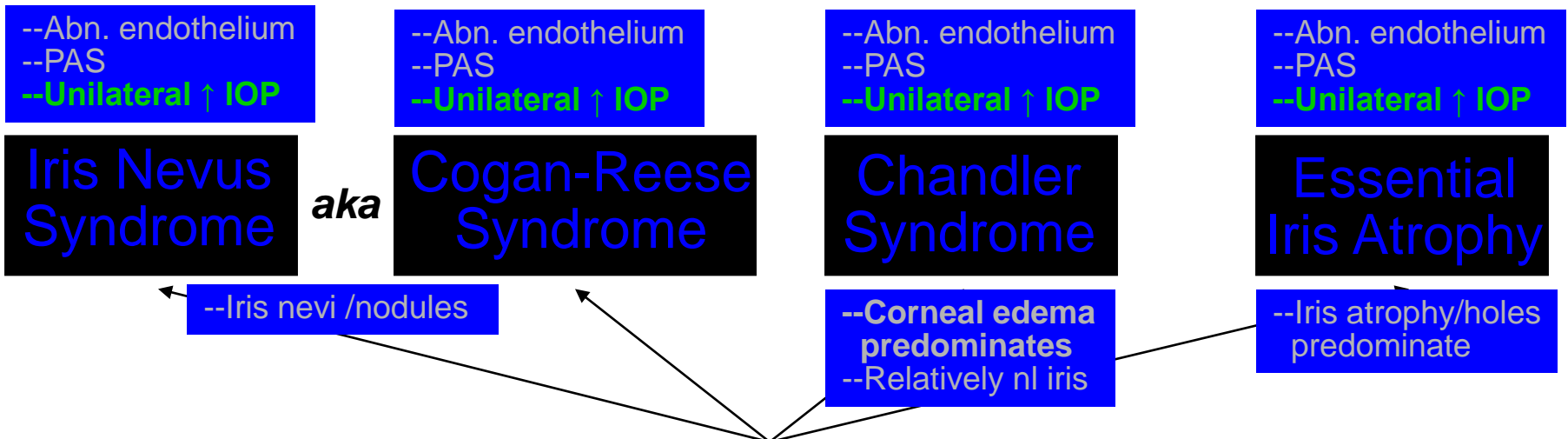
- β blockers
- Carbonic anhydrase inhibitors
- α agonists

If medical management is inadequate, should filtering surgery be attempted?

Yes

What are the main management issues in ICE?

- 1) IOP/glaucoma control
- 2) Minimizing corneal edema



ICE: Subtypes

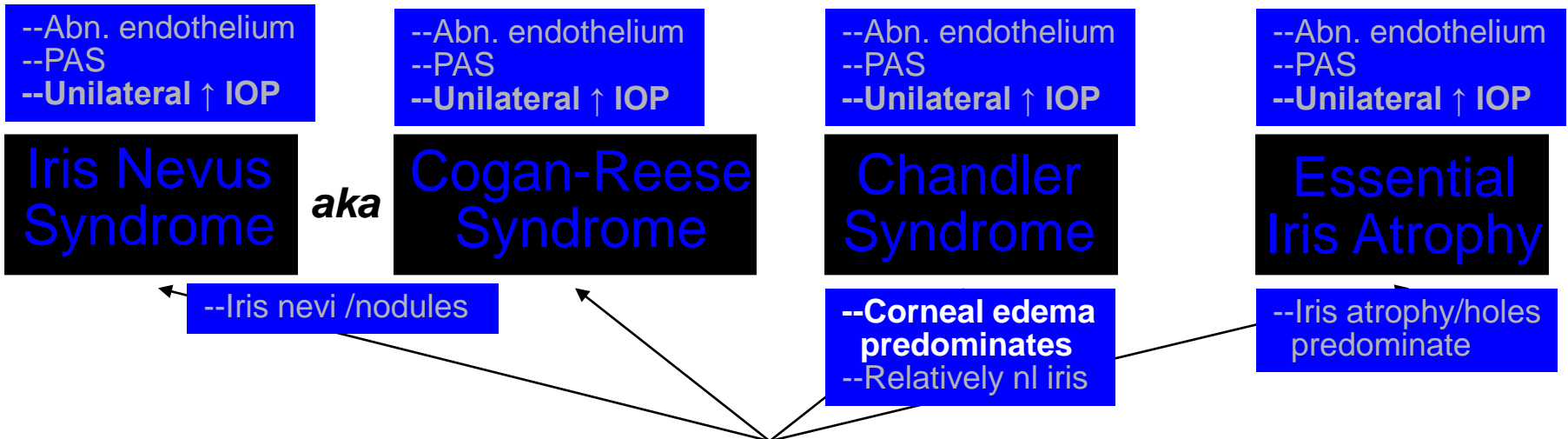
Iridocorneal Endothelial

Which meds are most effective?
 Aqueous suppressants, which are:
 --β blockers
 --Carbonic anhydrase inhibitors
 --α agonists

If medical management is inadequate, should filtering surgery be attempted?
 Yes

What are the main management issues in ICE?
 1) IOP/glaucoma control
 2) Minimizing corneal edema

Which meds are most effective?



ICE: Subtypes

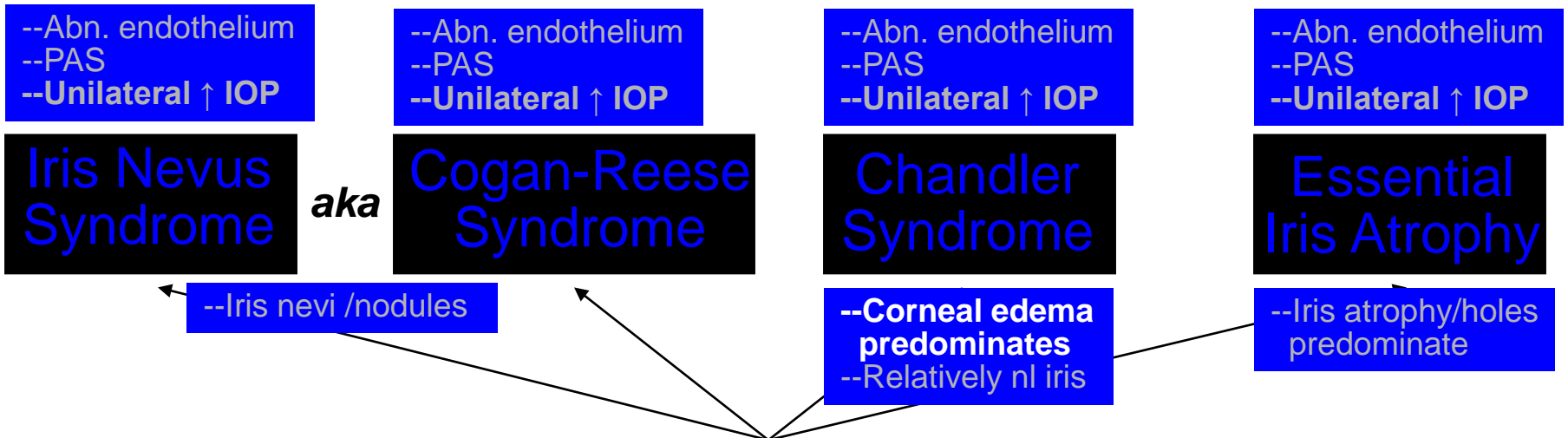
Iridocorneal Endothelial (ICE)

Which meds are most effective?
 Aqueous suppressants, which are:
 --β blockers
 --Carbonic anhydrase inhibitors
 --α agonists

If medical management is inadequate, should filtering surgery be attempted?
 Yes

Which meds are most effective?
 Hypertonic saline solutions

What are the main management issues in ICE?
 1) IOP/glaucoma control
 2) Minimizing corneal edema



ICE: Subtypes

Iridocorneal Endothelial

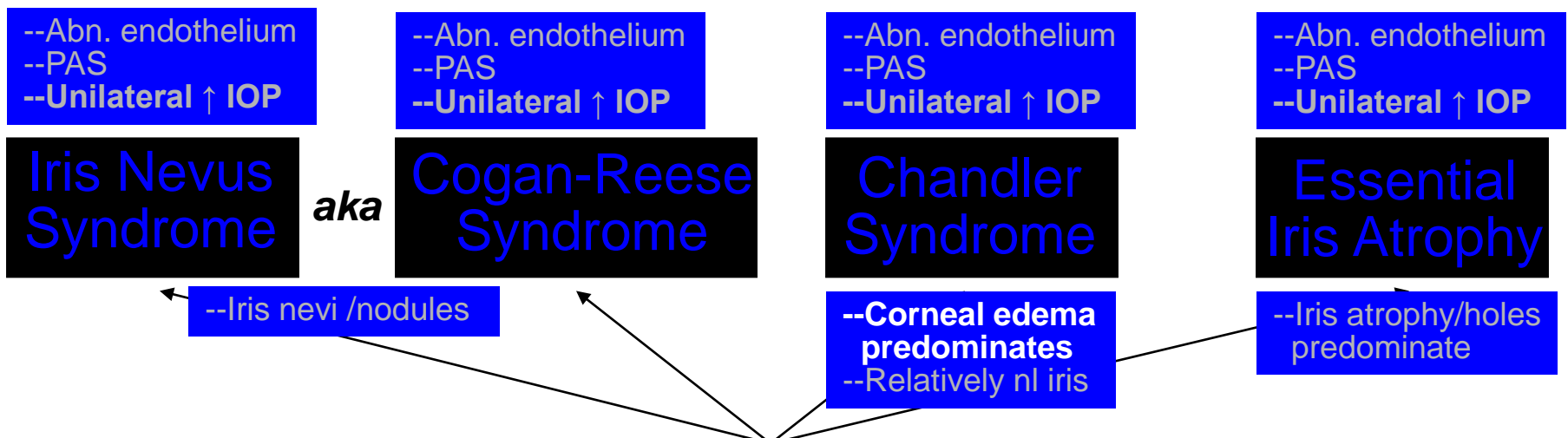
Which meds are most effective?
 Aqueous suppressants, which are:
 --β blockers
 --Carbonic anhydrase inhibitors
 --α agonists

If medical management is inadequate, should filtering surgery be attempted?
 Yes

Which meds are most effective?
 Hypertonic saline solutions

If medical management is inadequate, should PK be attempted?

What are the main management issues in ICE?
 1) IOP/glaucoma control
 2) Minimizing corneal edema



ICE: Subtypes

Iridocorneal Endothelial

Which meds are most effective?
 Aqueous suppressants, which are:
 --β blockers
 --Carbonic anhydrase inhibitors
 --α agonists

If medical management is inadequate, should filtering surgery be attempted?
 Yes

Which meds are most effective?
 Hypertonic saline solutions

If medical management is inadequate, should PK be attempted?
 Yes

What are the main management issues in ICE?
 1) IOP/glaucoma control
 2) Minimizing corneal edema

--Abn. endothelium
 --PAS
 --Unilateral ↑ IOP

--Abn. endothelium
 --PAS
 --Unilateral ↑ IOP

--Abn. endothelium
 --PAS
 --Unilateral ↑ IOP

--Abn. endothelium
 --PAS
 --Unilateral ↑ IOP

Iris Nevus Syndrome

aka

Cogan-Reese Syndrome

Chandler Syndrome

Essential Iris Atrophy

--Iris nevi /nodules

--Corneal edema predominates
 --Relatively nl iris

--Iris atrophy/holes predominate

ICE: Subtypes