


Persistent Fetal Vasculature


In a nutshell: What is the issue in PFV?



Persistent Fetal Vasculature

In a nutshell: What is the issue in PFV?

Portions of the posterior fetal vasculature of the lens (aka the two words) continue to exist (ie, it 'persists') past the developmental stage at which it should have regressed



Persistent Fetal Vasculature

In a nutshell: What is the issue in PFV?

Portions of the posterior fetal vasculature of the lens (aka the *primary vitreous*) continue to exist (ie, it 'persists') past the developmental stage at which it should have regressed



Persistent Fetal Vasculature

In a nutshell: What is the issue in PFV?

Portions of the posterior fetal vasculature of the lens (aka the *primary vitreous*) continue to exist (ie, it 'persists') past the developmental stage at which it should have regressed

By what name was PFV formerly known?




Persistent Fetal Vasculature

In a nutshell: What is the issue in PFV?

Portions of the posterior fetal vasculature of the lens (aka the ***primary vitreous***) continue to exist (ie, it ***persists***) past the developmental stage at which it should have regressed

By what name was PFV formerly known?

Persistent hyperplastic primary vitreous (PHPV)



Persistent Fetal Vasculature


In a nutshell: What is the issue in PFV?

Portions of the posterior fetal vasculature of the lens (aka the **primary vitreous**) continue to exist (ie, it **persists**) past the developmental stage at which it should have regressed

*The term **primary** vitreous implies the existence of a secondary vitreous. Is this the case?*

By wh

Persistent hyperplastic primary vitreous (PHPV)




Persistent Fetal Vasculature

In a nutshell: What is the issue in PFV?

Portions of the posterior fetal vasculature of the lens (aka the **primary vitreous**) continue to exist (ie, it **persists**) past the developmental stage at which it should have regressed

*The term **primary** vitreous implies the existence of a secondary vitreous. Is this the case?*

By wh Indeed it is. In fact, there is also a *tertiary* vitreous.
Persistent hyperplastic primary vitreous (PHPV)





Persistent Fetal Vasculature

In a nutshell: What is the issue in PFV?

Portions of the posterior fetal vasculature of the lens (aka the **primary vitreous**) continue to exist (ie, it **persists**) past the developmental stage at which it should have regressed

The term **primary vitreous** implies the existence of


a **secondary vitreous**. Is this the case?

By what? Indeed it is. In fact, there is also a **tertiary vitreous**.

Persistent hyperplastic primary vitreous (PHPV)

What are the three vitreouses, ie, what do they form?

- The primary vitreous = the fetal vasculature comprising the system
- The secondary vitreous
- The tertiary vitreous



Persistent Fetal Vasculature

In a nutshell: What is the issue in PFV?

Portions of the posterior fetal vasculature of the lens (aka the **primary vitreous**) continue to exist (ie, it **persists**) past the developmental stage at which it should have regressed

The term **primary vitreous** implies the existence of

a **secondary vitreous**. Is this the case?

By wh

Indeed it is. In fact, there is also a **tertiary vitreous**.

Persistent hyperplastic primary vitreous (PHPV)

What are the three vitreouses, ie, what do they form?

- The primary vitreous = the fetal vasculature comprising the *hyaloid system*
- The secondary vitreous
- The tertiary vitreous



Persistent Fetal Vasculature

In a nutshell: What is the issue in PFV?

Portions of the posterior fetal vasculature of the lens (aka the **primary vitreous**) continue to exist (ie, it **persists**) past the developmental stage at which it should have regressed

The term **primary vitreous** implies the existence of


a **secondary vitreous**. Is this the case?

By what? Indeed it is. In fact, there is also a **tertiary vitreous**.

Persistent hyperplastic primary vitreous (PHPV)

What are the three vitreouses, ie, what do they form?

- The primary vitreous = the fetal vasculature comprising the *hyaloid system*
- The secondary vitreous =
- The tertiary vitreous



Persistent Fetal Vasculature

In a nutshell: What is the issue in PFV?

Portions of the posterior fetal vasculature of the lens (aka the **primary vitreous**) continue to exist (ie, it **persists**) past the developmental stage at which it should have regressed

The term **primary vitreous** implies the existence of


a **secondary vitreous**. Is this the case?

By what? Indeed it is. In fact, there is also a **tertiary vitreous**.

Persistent hyperplastic primary vitreous (PHPV)

What are the three vitreouses, ie, what do they form?

- The primary vitreous = the fetal vasculature comprising the *hyaloid system*
- The secondary vitreous = the main vitreous body
- The tertiary vitreous



Persistent Fetal Vasculature

In a nutshell: What is the issue in PFV?

Portions of the posterior fetal vasculature of the lens (aka the **primary vitreous**) continue to exist (ie, it **persists**) past the developmental stage at which it should have regressed

The term **primary vitreous** implies the existence of


a **secondary vitreous**. Is this the case?

By wh Indeed it is. In fact, there is also a **tertiary vitreous**.

Persistent hyperplastic primary vitreous (PHPV)

What are the three vitreouses, ie, what do they form?

- The primary vitreous = the fetal vasculature comprising the *hyaloid system*
- The secondary vitreous = the main vitreous body
- The tertiary vitreous =



Persistent Fetal Vasculature

In a nutshell: What is the issue in PFV?

Portions of the posterior fetal vasculature of the lens (aka the **primary vitreous**) continue to exist (ie, it **persists**) past the developmental stage at which it should have regressed

The term **primary vitreous** implies the existence of


a **secondary vitreous**. Is this the case?

By wh Indeed it is. In fact, there is also a **tertiary vitreous**.

Persistent hyperplastic primary vitreous (PHPV)

What are the three vitreouses, ie, what do they form?

- The primary vitreous = the fetal vasculature comprising the *hyaloid system*
- The secondary vitreous = the main vitreous body
- The tertiary vitreous = the zonules



Persistent Fetal Vasculature

In a nutshell: What is the issue in PFV?

Portions of the posterior fetal vasculature of the lens (aka the **primary vitreous**) continue to exist (ie, it **persists**) past the developmental stage at which it should have regressed


The term **primary vitreous** implies the existence of a **secondary vitreous**. Is this the case?

By wh Indeed it is. In fact, there is also a **tertiary vitreous**.
Persistent hyperplastic primary vitreous (PHPV)

What are the three vitreouses, ie, what do they form?

- The primary vitreous = the fetal vasculature comprising the **hyaloid system**
- The secondary vitreous = the main vitreous body
- The tertiary vitreous = the zonules

What is the hyaloid system?



Persistent Fetal Vasculature

In a nutshell: What is the issue in PFV?

Portions of the posterior fetal vasculature of the lens (aka the **primary vitreous**) continue to exist (ie, it **persists**) past the developmental stage at which it should have regressed

The term **primary vitreous** implies the existence of a **secondary vitreous**. Is this the case?


By wh Indeed it is. In fact, there is also a **tertiary vitreous**.
Persistent hyperplastic primary vitreous (PFPV)

What are the three vitreouses, ie, what do they form?

- The primary vitreous = the fetal vasculature comprising the **hyaloid system**
- The secondary vitreous = the main vitreous body
- The tertiary vitreous = the zonules

What is the hyaloid system?

The fetal vasculature that derives from the hyaloid artery



Persistent Fetal Vasculature

In a nutshell: What is the issue in PFV?

Portions of the posterior fetal vasculature of the lens (aka the **primary vitreous**) continue to exist (ie, it **persists**) past the developmental stage at which it should have regressed

The term **primary vitreous** implies the existence of a **secondary vitreous**. Is this the case?

By **wh** Indeed it is. In fact, there is also a **tertiary vitreous**.
Persistent hyperplastic primary vitreous (PHPV)

What are the three vitreouses, ie, what do they form?

- The primary vitreous = the fetal vasculature comprising the **hyaloid system**
- The secondary vitreous = the main vitreous body
- The tertiary vitreous = the zonules

What is the hyaloid system?

The fetal vasculature that derives from the **hyaloid artery**

Where does the hyaloid artery run?



Persistent Fetal Vasculature

In a nutshell: What is the issue in PFV?

Portions of the posterior fetal vasculature of the lens (aka the **primary vitreous**) continue to exist (ie, it **persists**) past the developmental stage at which it should have regressed

The term **primary vitreous** implies the existence of a **secondary vitreous**. Is this the case?

By what? Indeed it is. In fact, there is also a **tertiary vitreous**.
Persistent hyperplastic primary vitreous (PHPV)

What are the three vitreouses, ie, what do they form?

- The primary vitreous = the fetal vasculature comprising the **hyaloid system**
- The secondary vitreous = the main vitreous body
- The tertiary vitreous = the zonules

What is the hyaloid system?

The fetal vasculature that derives from the **hyaloid artery**

Where does the hyaloid artery run?

From the optic nerve head to the back of the lens
(we will have **much** more to say about the hyaloid artery)

Persistent Fetal Vasculature

In a nutshell: What is the issue in PFV?

Portions of the posterior fetal vasculature of the lens (aka the *primary vitreous*) continue to exist (ie, it 'persists') past the developmental stage at which it should have regressed

Is PFV primarily sporadic, or hereditary (or are both equally likely)?




Persistent Fetal Vasculature

In a nutshell: What is the issue in PFV?

Portions of the posterior fetal vasculature of the lens (aka the *primary vitreous*) continue to exist (ie, it 'persists') past the developmental stage at which it should have regressed

Is PFV primarily sporadic, or hereditary (or are both equally likely)?

The vast majority of cases are




Persistent Fetal Vasculature

In a nutshell: What is the issue in PFV?

Portions of the posterior fetal vasculature of the lens (aka the *primary vitreous*) continue to exist (ie, it 'persists') past the developmental stage at which it should have regressed

Is PFV primarily sporadic, or hereditary (or are both equally likely)?

The vast majority of cases are sporadic



Persistent Fetal Vasculature

In a nutshell: What is the issue in PFV?

Portions of the posterior fetal vasculature of the lens (aka the *primary vitreous*) continue to exist (ie, it 'persists') past the developmental stage at which it should have regressed

Is PFV primarily sporadic, or hereditary (or are both equally likely)?

The vast majority of cases are sporadic

Does PFV usually present unilaterally, or bilaterally (or are both equally likely)?



Persistent Fetal Vasculature

In a nutshell: What is the issue in PFV?


Portions of the posterior fetal vasculature of the lens (aka the *primary vitreous*) continue to exist (ie, it 'persists') past the developmental stage at which it should have regressed

Is PFV primarily sporadic, or hereditary (or are both equally likely)?

The vast majority of cases are sporadic

Does PFV usually present unilaterally, or bilaterally (or are both equally likely)?

It is in over % of cases



Persistent Fetal Vasculature

In a nutshell: What is the issue in PFV?


Portions of the posterior fetal vasculature of the lens (aka the *primary vitreous*) continue to exist (ie, it 'persists') past the developmental stage at which it should have regressed

Is PFV primarily sporadic, or hereditary (or are both equally likely)?

The vast majority of cases are sporadic

Does PFV usually present unilaterally, or bilaterally (or are both equally likely)?

It is unilateral in over 90% of cases

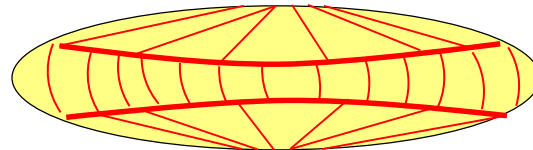




Persistent Fetal Vasculature

- The vascular supply encapsulating the developing lens is called the .

?

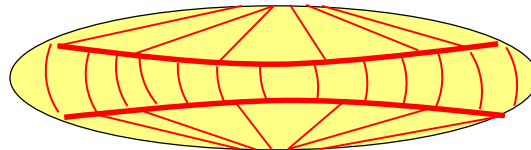





Persistent Fetal Vasculature

- The vascular supply encapsulating the developing lens is called the **tunica vasculosa lentis**.

Tunica vasculosa lentis



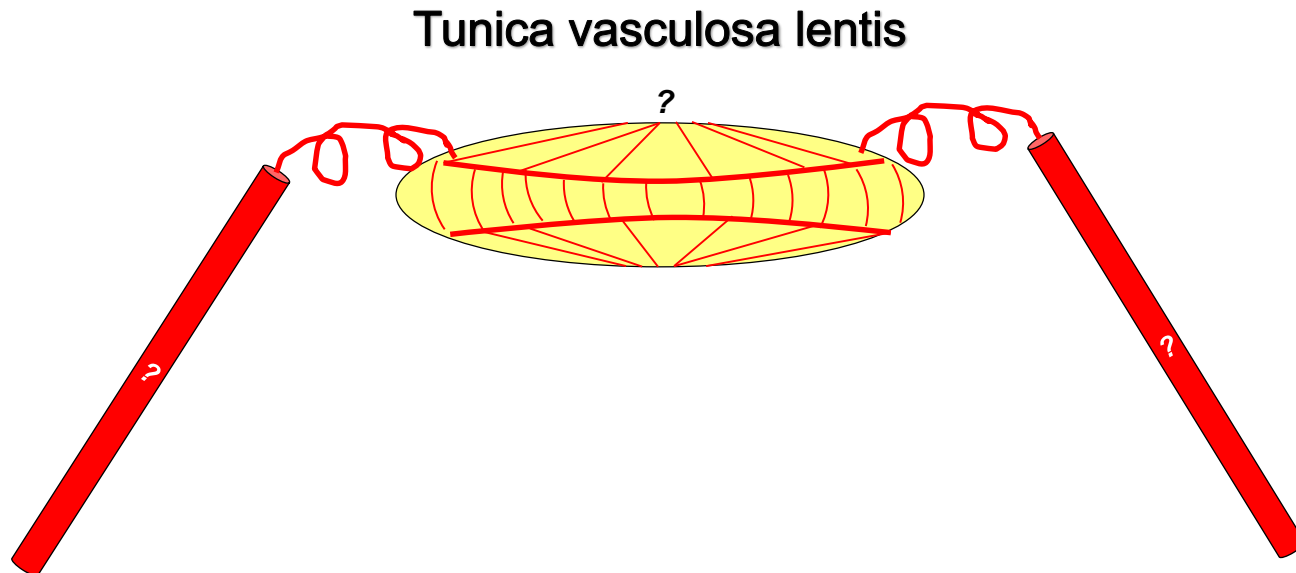


Persistent Fetal Vasculature

- The vascular supply encapsulating the developing lens is called the **tunica vasculosa lentis**.

It has three sections:

- 1) The derives from the arteries
- 2)
- 3)



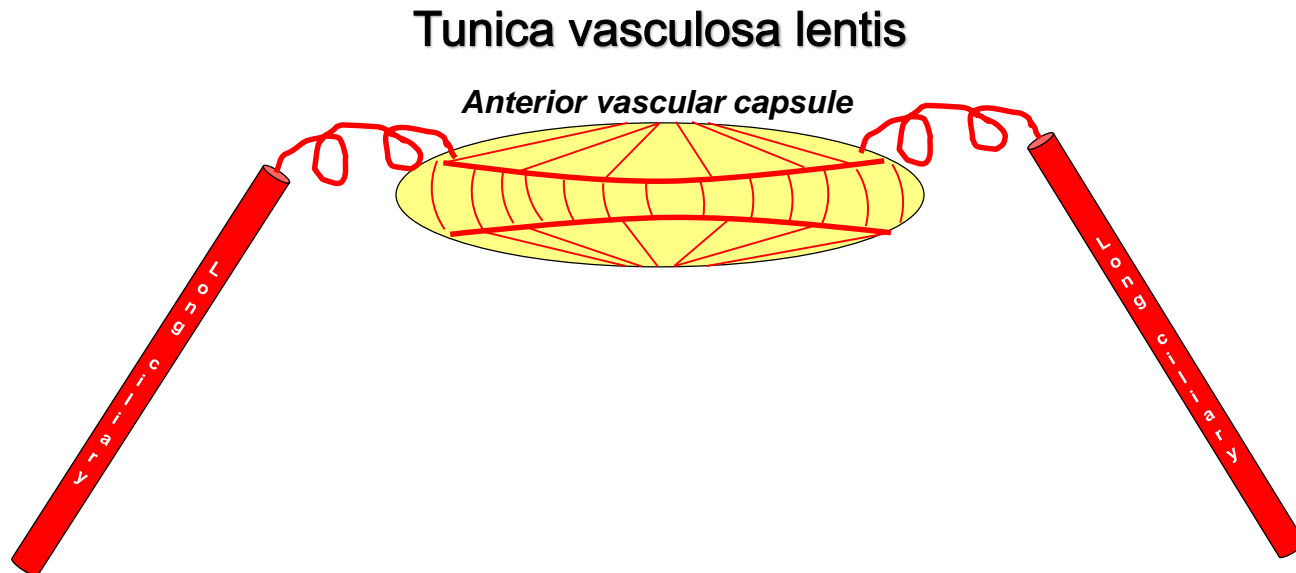



Persistent Fetal Vasculature

- The vascular supply encapsulating the developing lens is called the **tunica vasculosa lentis**.

It has three sections:

- 1) The **anterior vascular capsule** derives from the **long ciliary** arteries
- 2)
- 3)



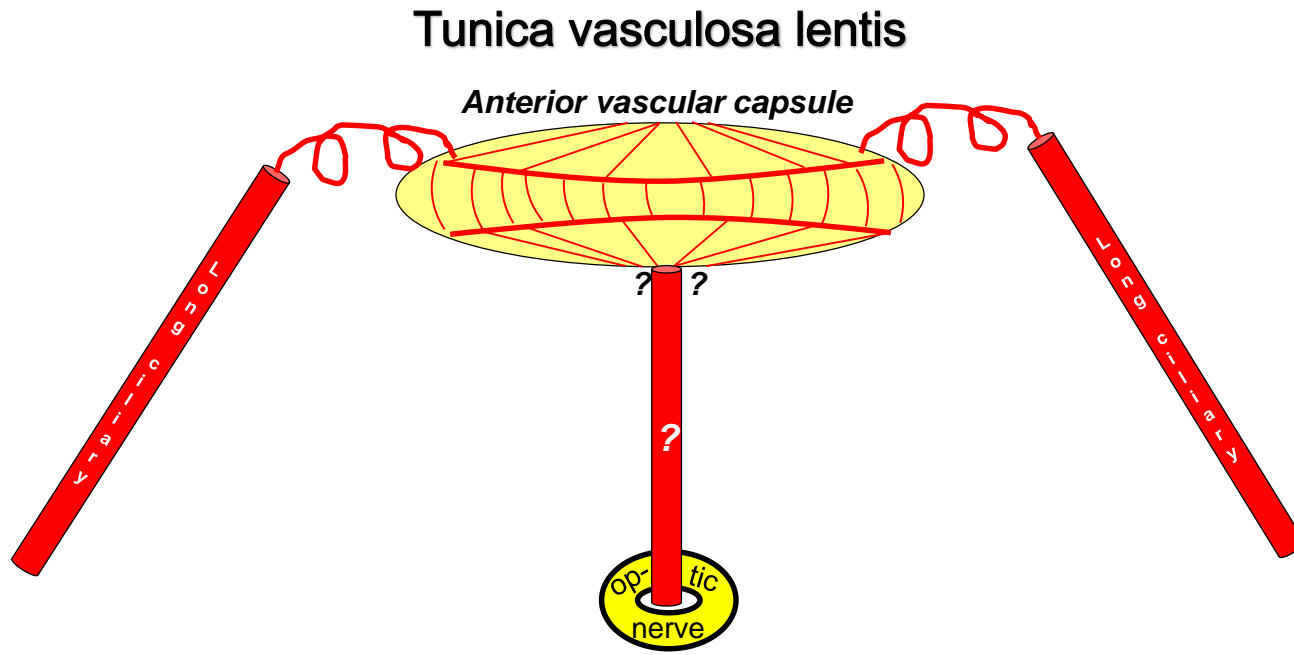



Persistent Fetal Vasculature

- The vascular supply encapsulating the developing lens is called the **tunica vasculosa lentis**.

It has three sections:

- 1) The **anterior vascular capsule** derives from the **long ciliary** arteries
- 2) The three words arises from the artery
- 3)



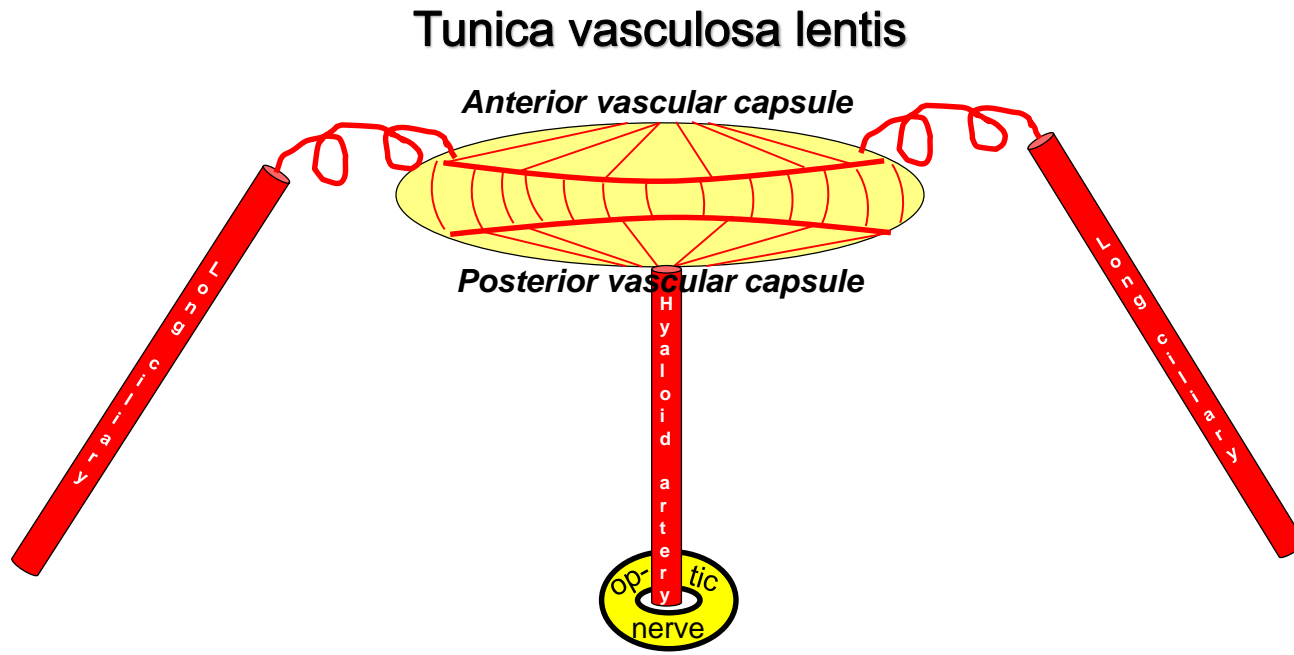



Persistent Fetal Vasculature

- The vascular supply encapsulating the developing lens is called the **tunica vasculosa lentis**.

It has three sections:

- 1) The **anterior vascular capsule** derives from the **long ciliary** arteries
- 2) The **posterior vascular capsule** arises from the **hyaloid** artery
- 3)



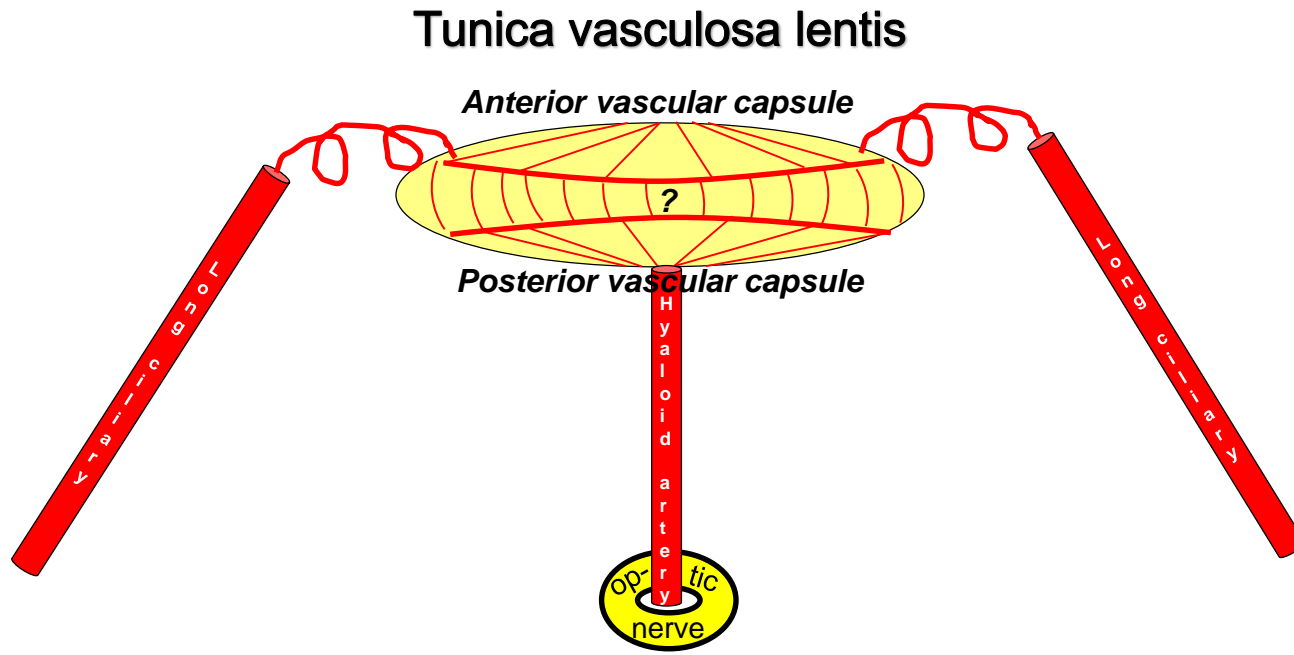



Persistent Fetal Vasculature

- The vascular supply encapsulating the developing lens is called the **tunica vasculosa lentis**.

It has three sections:

- 1) The **anterior vascular capsule** derives from the **long ciliary** arteries
- 2) The **posterior vascular capsule** arises from the **hyaloid** artery
- 3) The one long word **portion** anastomoses the anterior and posterior sections of the tunica



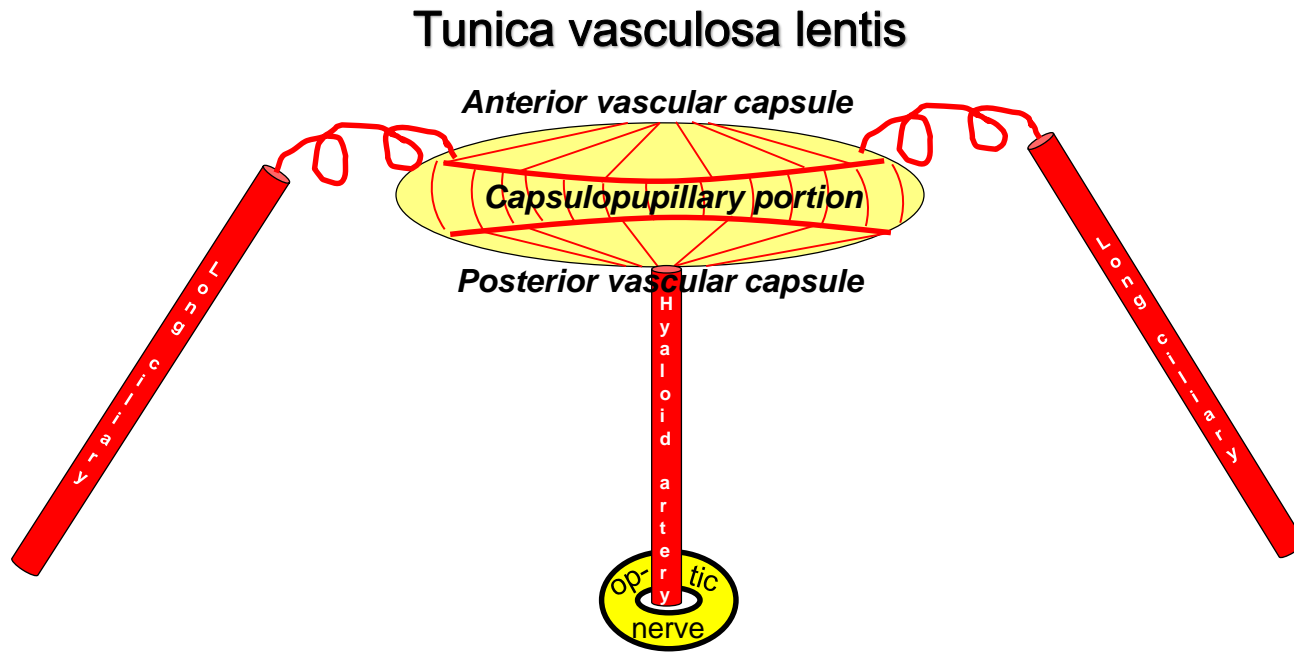


Persistent Fetal Vasculature

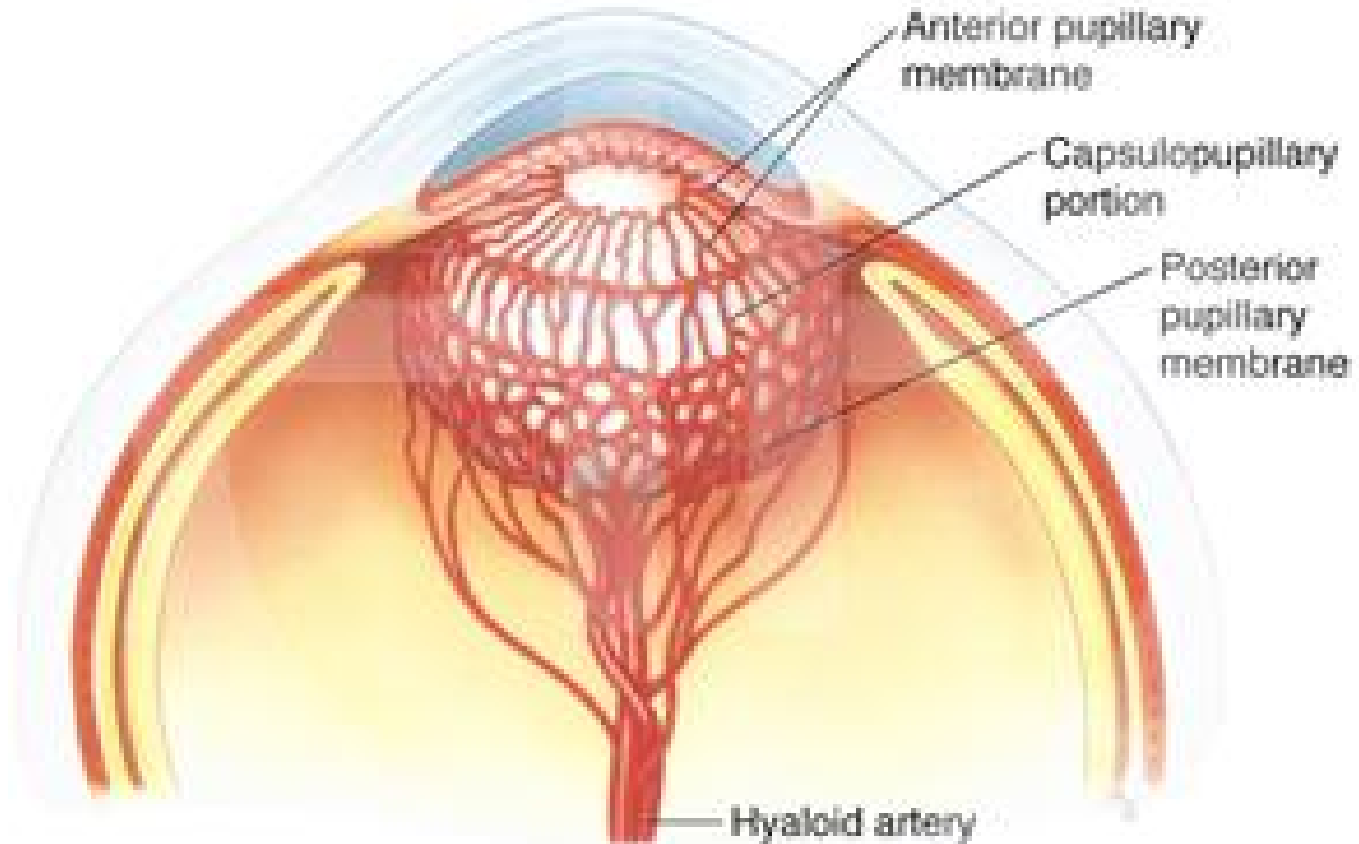
- The vascular supply encapsulating the developing lens is called the **tunica vasculosa lentis**.

It has three sections:


- 1) The **anterior vascular capsule** derives from the **long ciliary** arteries
- 2) The **posterior vascular capsule** arises from the **hyaloid** artery
- 3) The **capsulopupillary portion** anastomoses the anterior and posterior sections of the tunica



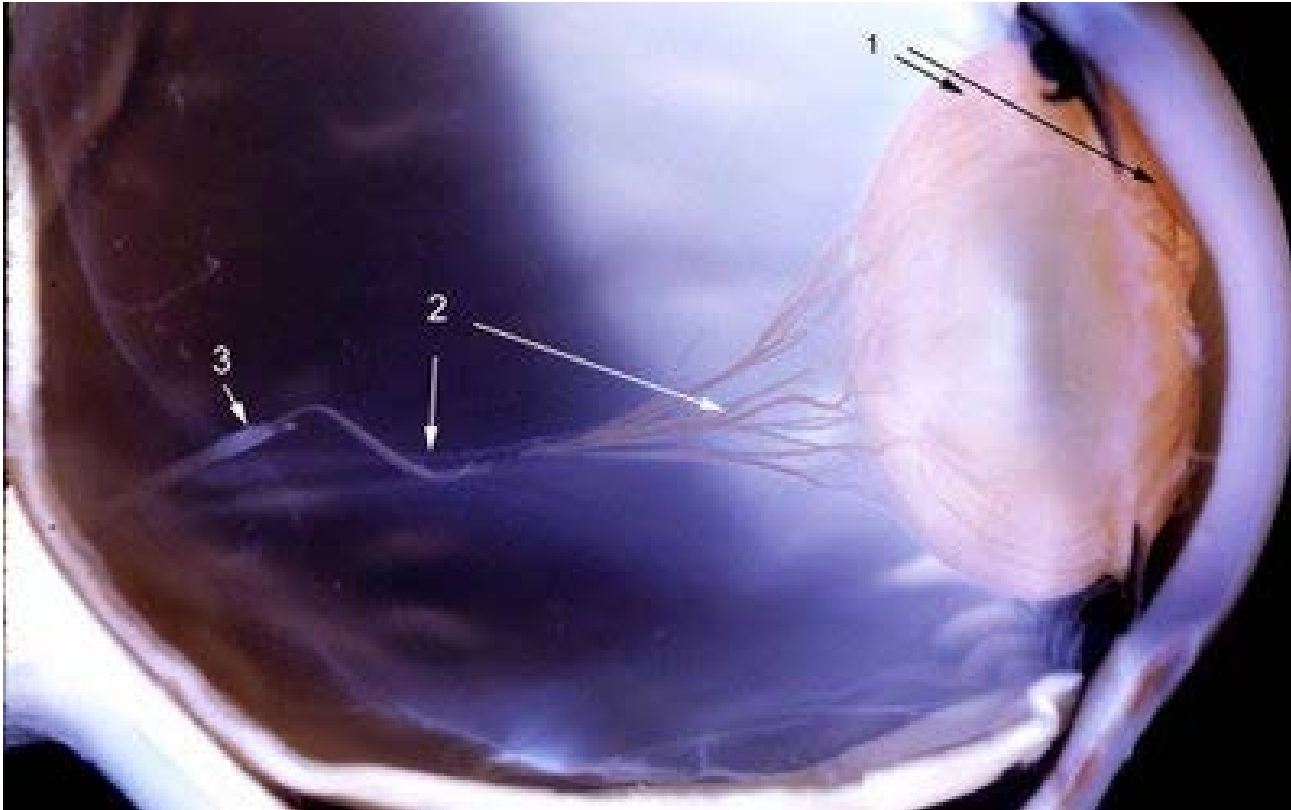
Persistent Fetal Vasculature




Tunica vasculosa lentis



Persistent Fetal Vasculature



In the figure of this very premature infant, the tunical vasculosa lentis surrounds the lens (arrows 1) and is contiguous with the hyaloid vascular system (arrow 2). Notice the glial sheath of the hyaloid artery (arrow 3).

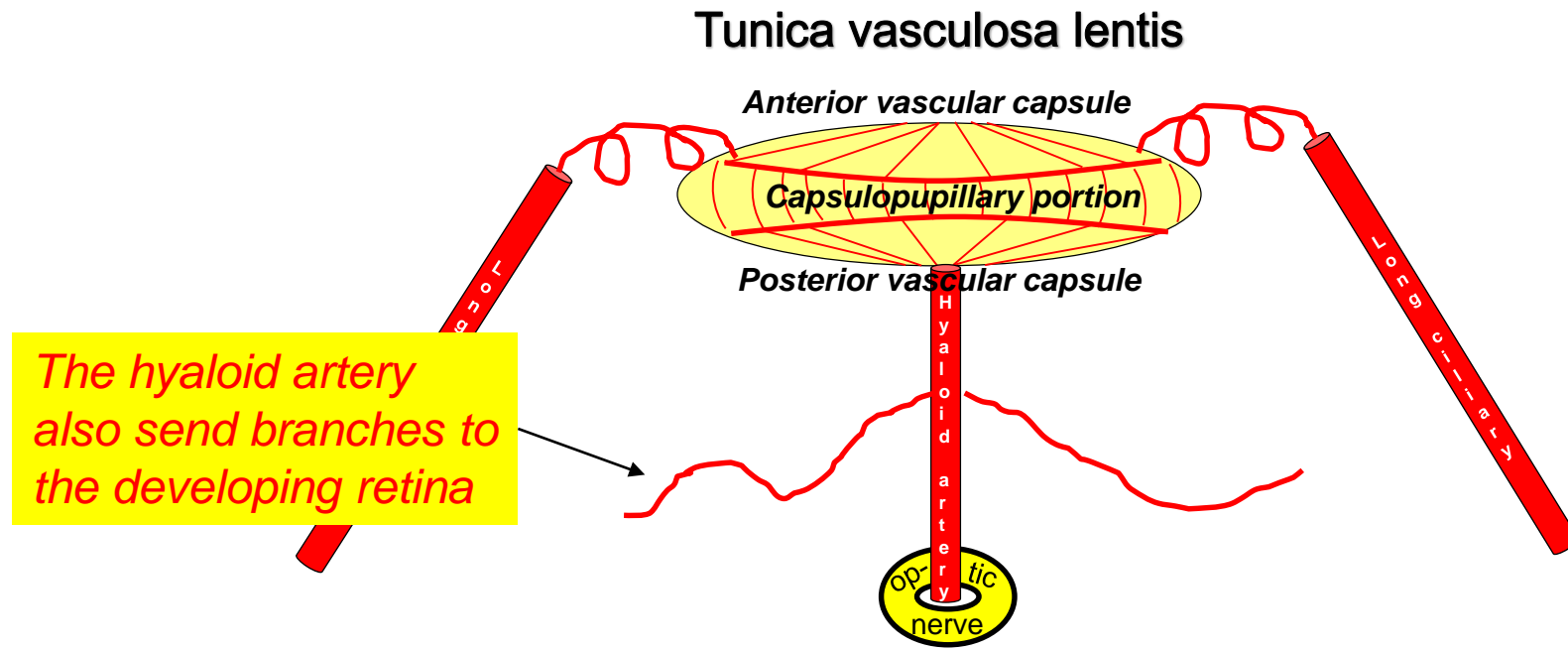



Persistent Fetal Vasculature

The vascular supply encapsulating the developing lens is called the **tunica vasculosa lentis**.

It has three sections:

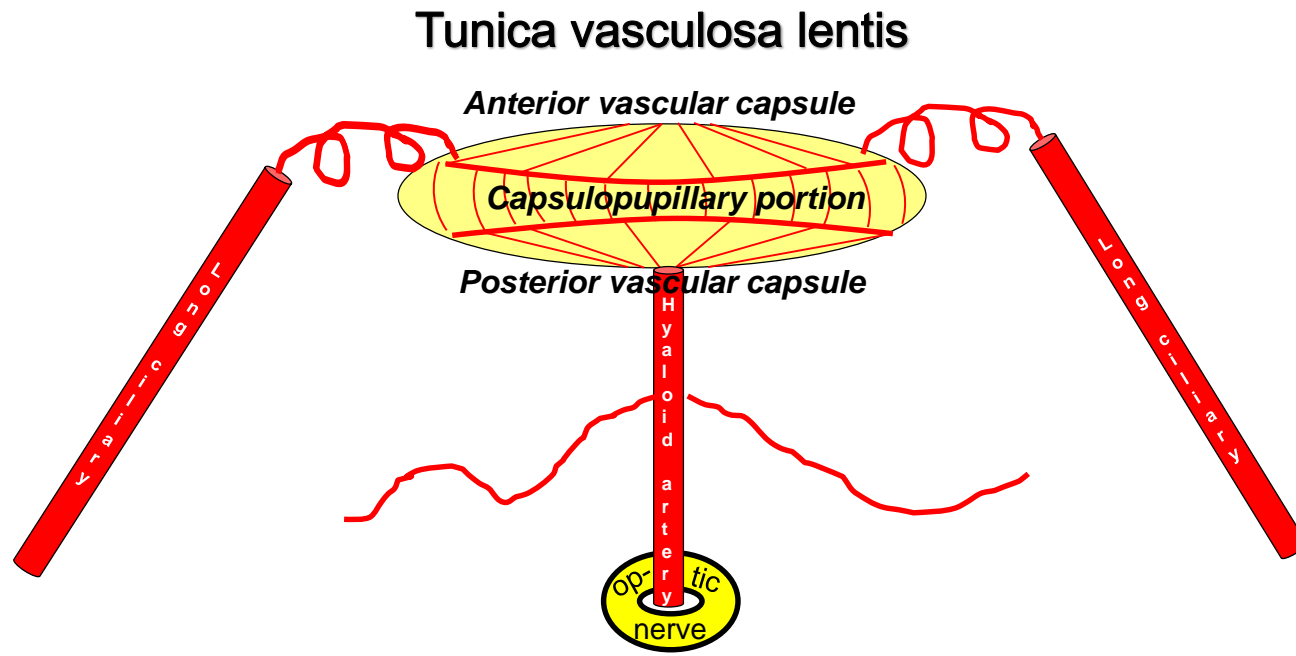
- 1) The **anterior vascular capsule** derives from the **long ciliary** arteries
- 2) The **posterior vascular capsule** arises from the **hyaloid** artery
- 3) The **capsulopupillary** portion anastomoses the anterior and posterior sections of the tunica





Persistent Fetal Vasculature

What is the normal natural history of the hyaloid system specifically, and the tunica vasculosa lentis in general?

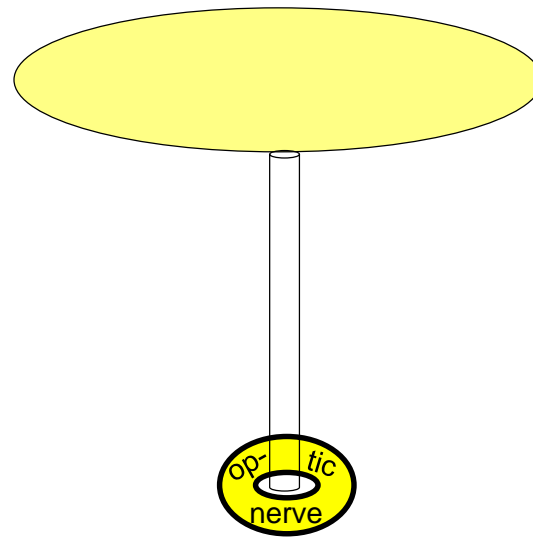





Persistent Fetal Vasculature

What is the normal natural history of the hyaloid system specifically, and the tunica vasculosa lentis in general?

The hyaloid system regresses in the month, whereas the anterior portion hangs on until the month

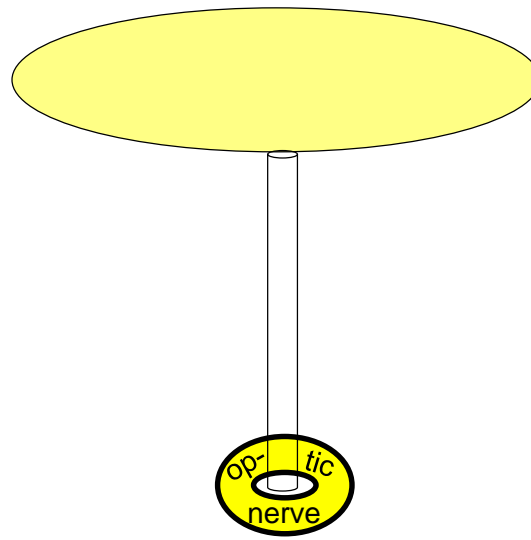



Persistent Fetal Vasculature



What is the normal natural history of the hyaloid system specifically, and the tunica vasculosa lentis in general?

The hyaloid system regresses in the 8th month, whereas the anterior portion hangs on until the 9th



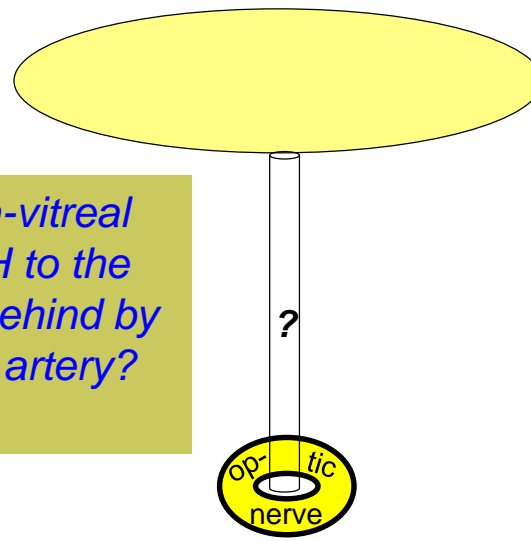


Persistent Fetal Vasculature

What is the normal natural history of the hyaloid system specifically, and the tunica vasculosa lentis in general?

The hyaloid system regresses in the 8th month, whereas the anterior portion hangs on until the 9th

What is the name of the intra-vitreous space, running from the ONH to the back of the lens, that is left behind by the regression of the hyaloid artery?





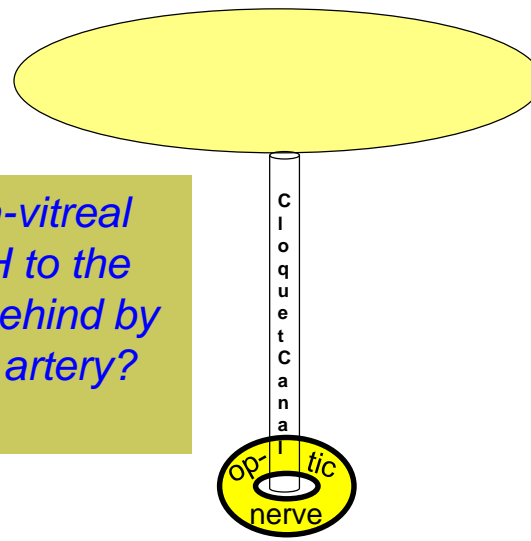
Persistent Fetal Vasculature

What is the normal natural history of the hyaloid system specifically, and the tunica vasculosa lentis in general?

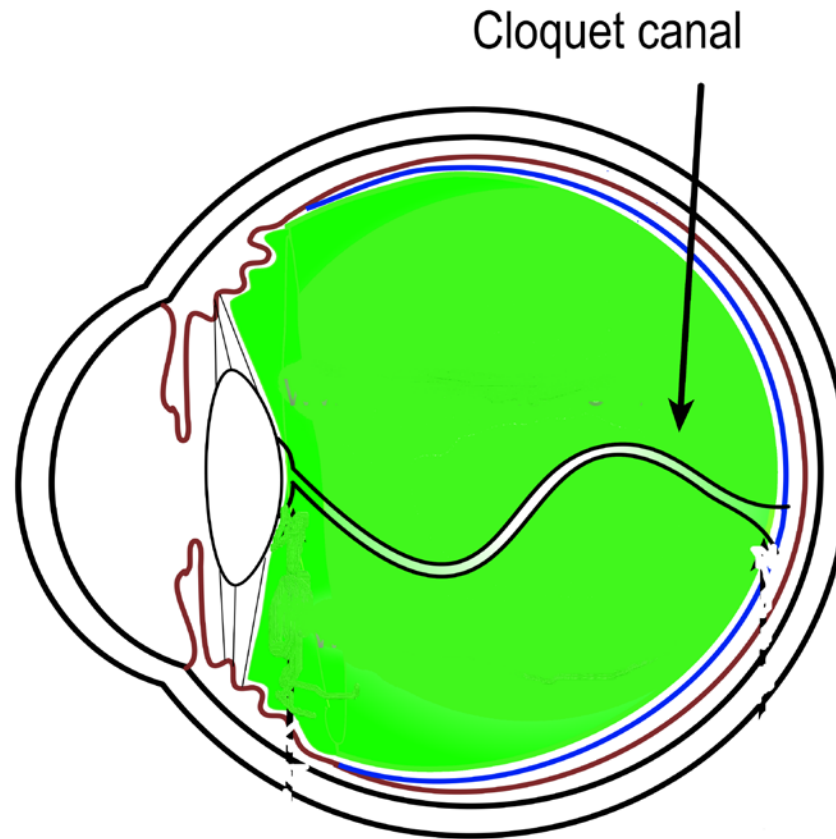
The hyaloid system regresses in the 8th month, whereas the anterior portion hangs on until the 9th

What is the name of the intra-vitreous space, running from the ONH to the back of the lens, that is left behind by the regression of the hyaloid artery?


Cloquet's canal




Persistent Fetal Vasculature

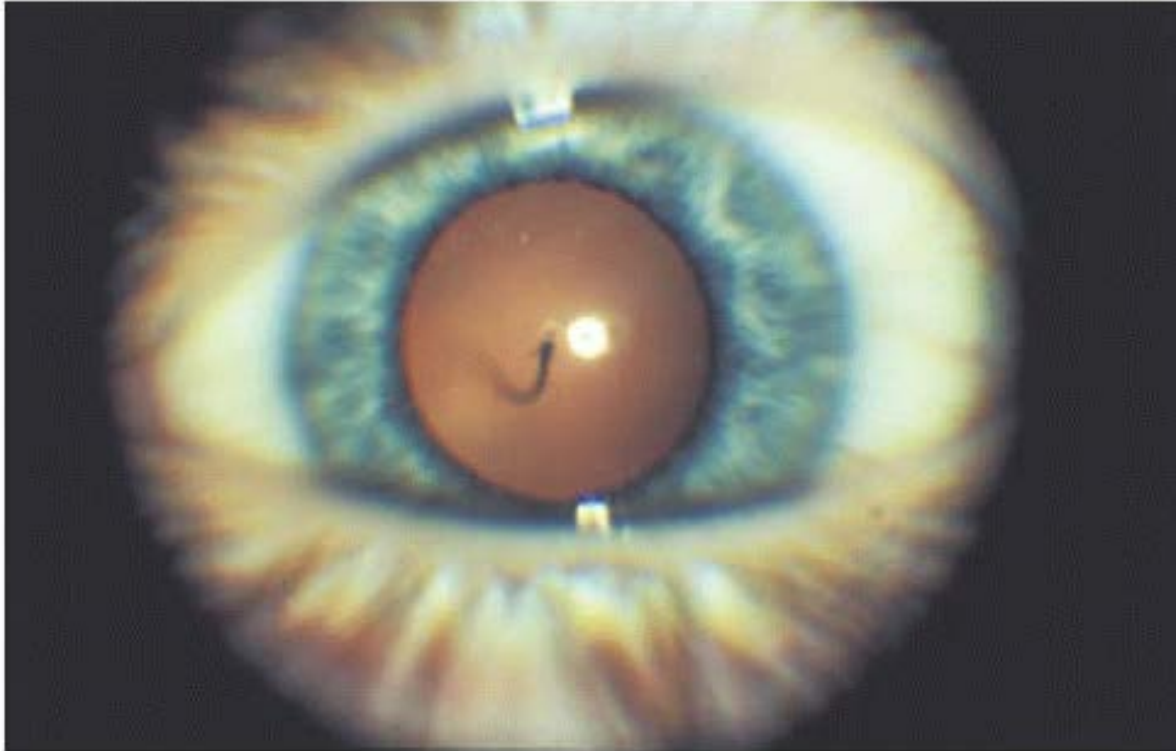


Cloquet's canal





Persistent Fetal Vasculature




Single loop of a persistent hyaloid artery extending anteriorly within Cloquet's canal to insert on the posterior capsule of the lens.

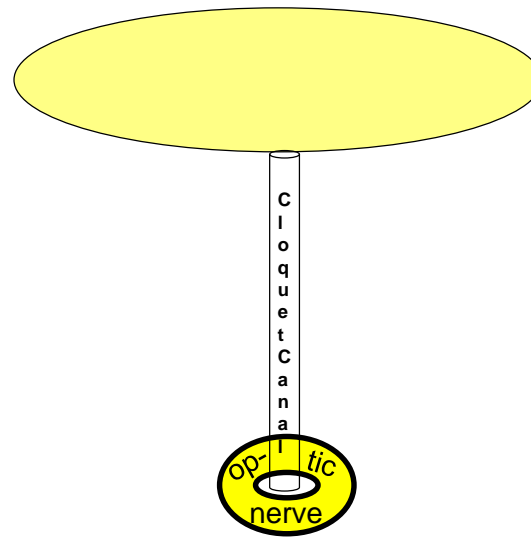



Persistent Fetal Vasculature

In a nutshell: What is the issue in PFV?



*Harkening back to a question from a previous slide as a refresher:
What did we say was the issue in PFV?*






Persistent Fetal Vasculature

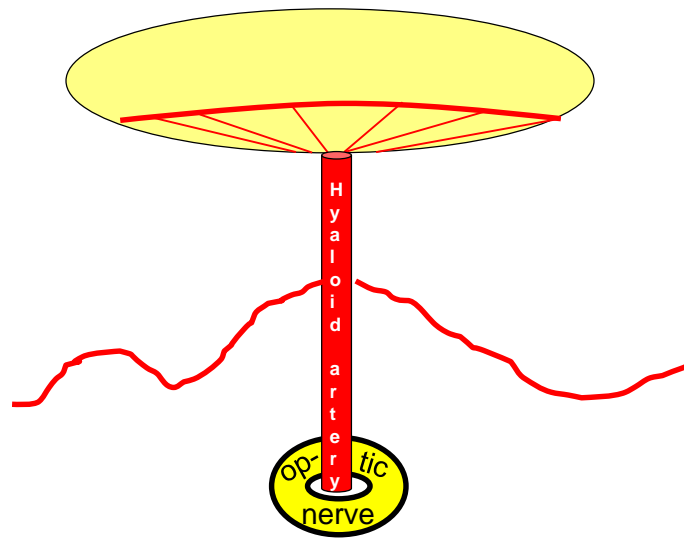
In a nutshell: What is the issue in PFV?

Portions of the posterior fetal vasculature of the lens (aka the *primary vitreous*) continue to exist (ie, it 'persists') past the developmental stage at which it should have regressed



*Harkening back to a question from a previous slide as a refresher:
What did we say was the issue in PFV?*

We said the issue was a **failure of the hyaloid system to fully regress**

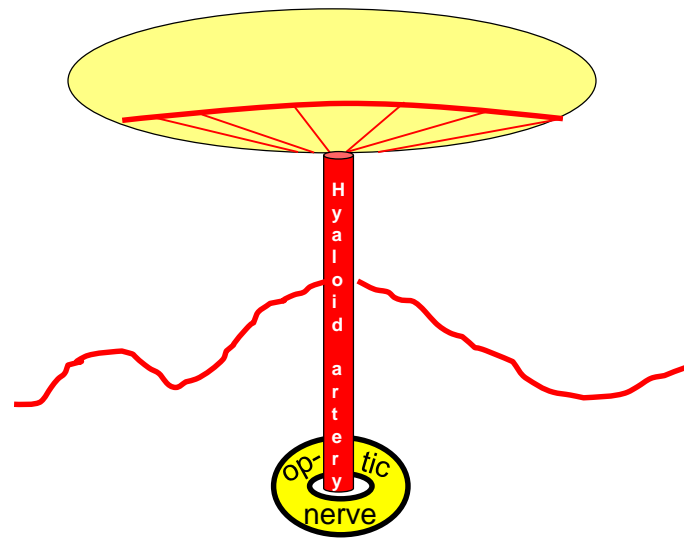


Persistent Fetal Vasculature

?

?

PFV comes in two forms. What are they?

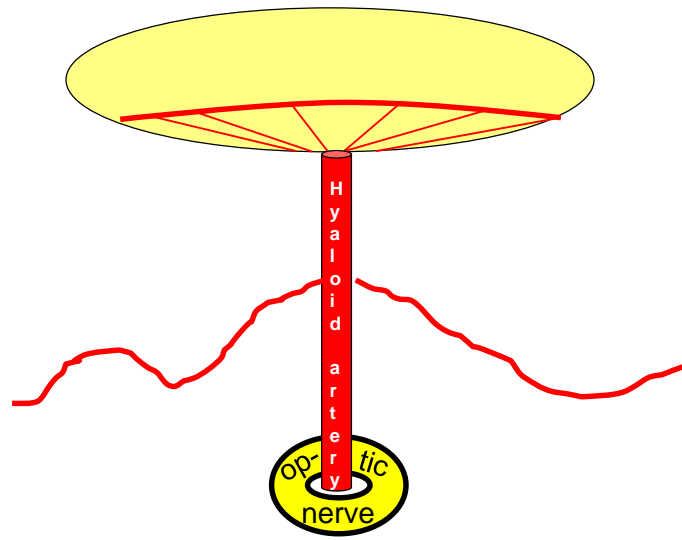



Persistent Fetal Vasculature

Anterior

Posterior

PFV comes in two forms. What are they?
Anterior and posterior





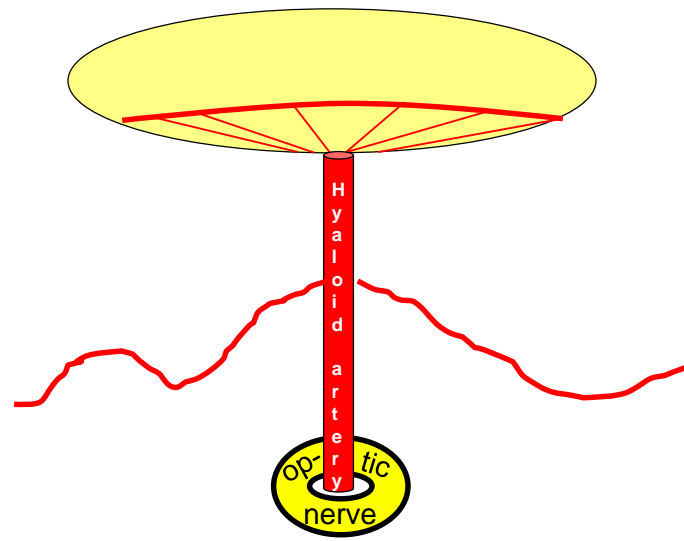
Persistent Fetal Vasculature

Anterior

Posterior

*PFV comes in two forms. What are they?
Anterior and posterior*

What is the basic nature of each?



Persistent Fetal Vasculature

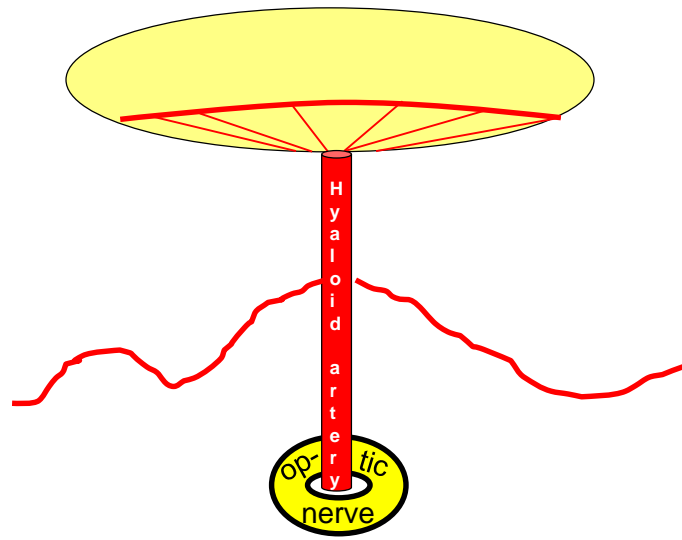
Anterior

Posterior

*PFV comes in two forms. What are they?
Anterior and posterior*

*What is the basic nature of each?
Anterior PFV involves pathology... [location]
Posterior PFV involves pathology...*

Anterior PFV:





Persistent Fetal Vasculature

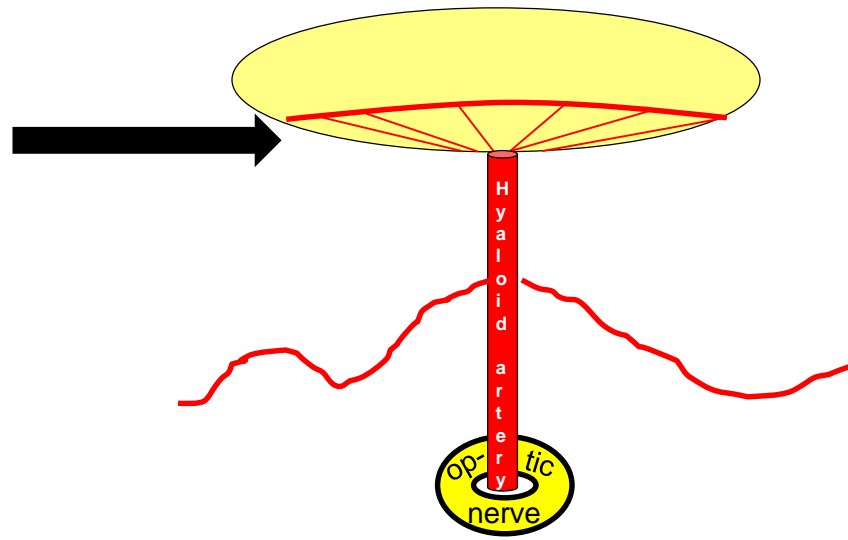
Anterior

Posterior

PFV comes in two forms. What are they?
Anterior and posterior

What is the basic nature of each?
Anterior PFV involves pathology...in the retrolental space
Posterior PFV involves pathology...

Anterior PFV:
Retrolental space



Persistent Fetal Vasculature

Anterior

Posterior

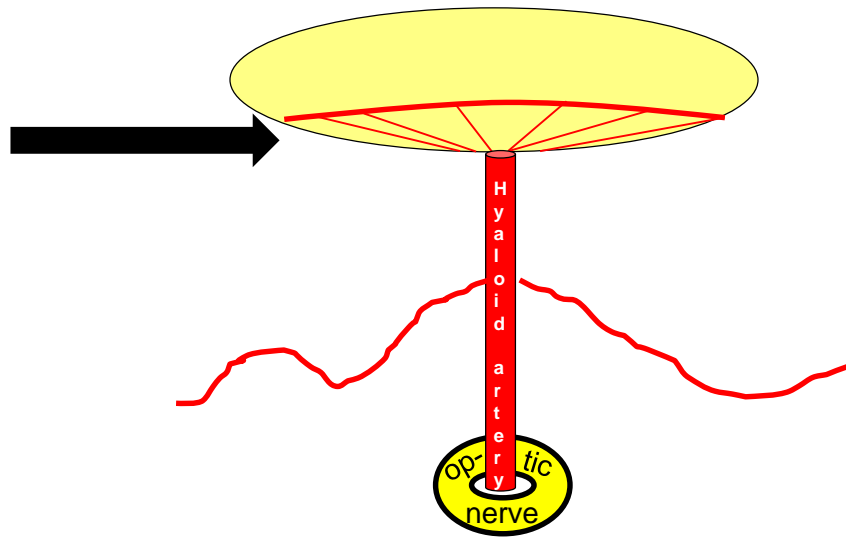
PFV comes in two forms. What are they?
Anterior and posterior

What is the basic nature of each?


Anterior PFV involves pathology...in the retrolental space

Posterior PFV involves pathology... [anatomy issue]

Anterior PFV:
Retrolental space



Posterior PFV:



Persistent Fetal Vasculature

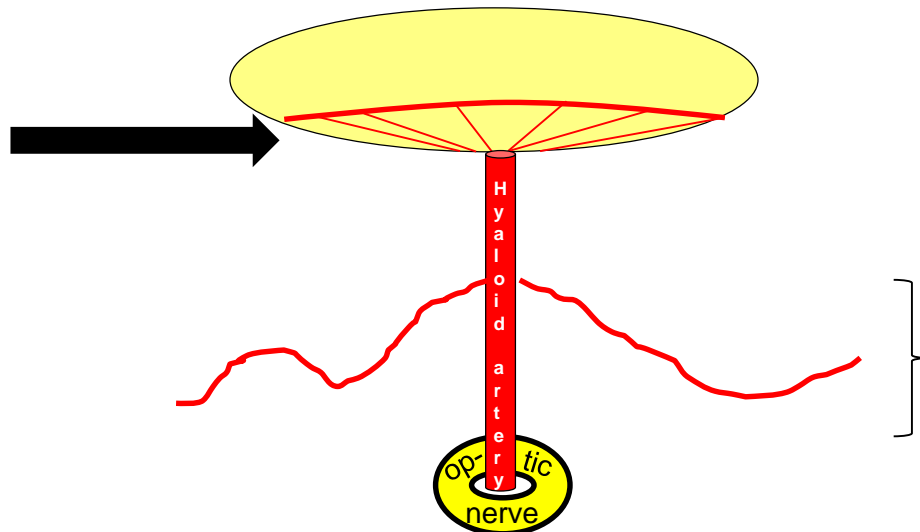
Anterior

Posterior

PFV comes in two forms. What are they?
Anterior and posterior

What is the basic nature of each?
Anterior PFV involves pathology...in the retrolental space
Posterior PFV involves pathology...related to the retinal branches of the hyaloid artery

Anterior PFV:
Retrolental space



Posterior PFV:
Retinal branch remnants



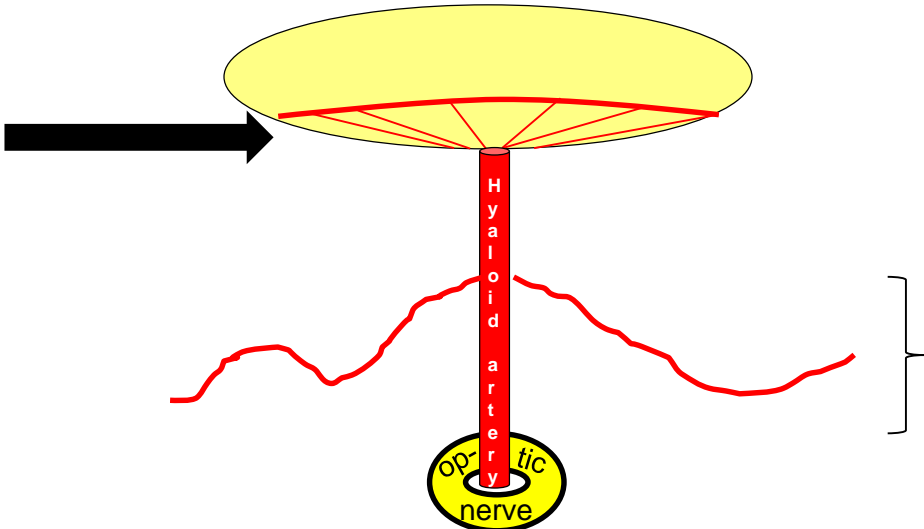
Persistent Fetal Vasculature

Anterior


Posterior

Can both anterior and posterior PFV be present in the same eye?

*Anterior PFV:
Retrolental space*



*Posterior PFV:
Retinal branch remnants*



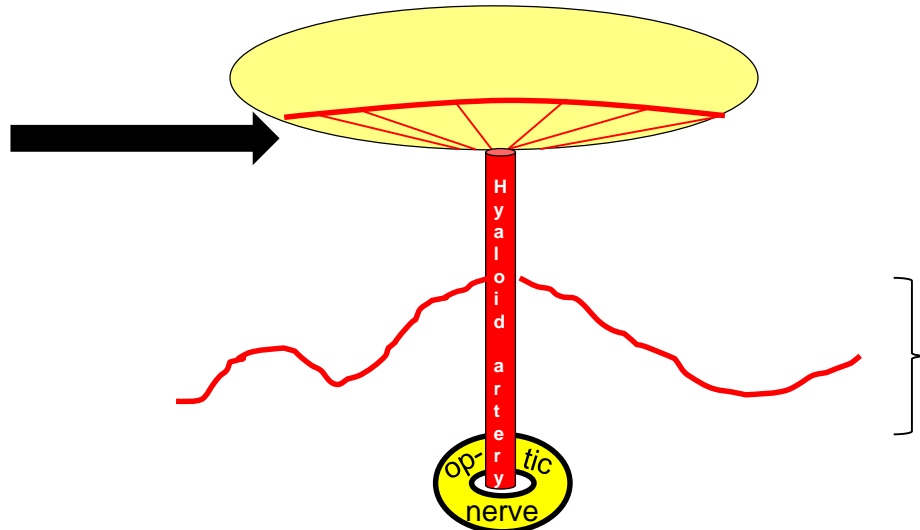
Persistent Fetal Vasculature

Anterior

Posterior

*Can both anterior and posterior PFV be present in the same eye?
Yes*

*Anterior PFV:
Retrolental space*




*Posterior PFV:
Retinal branch remnants*

Persistent Fetal Vasculature

Anterior

Posterior

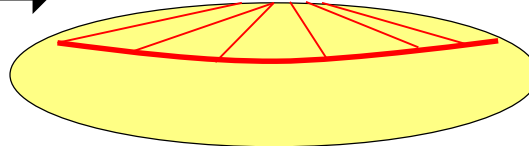


*Shouldn't a failure to regress by the **anterior** vascular capsule constitute **anterior** PFV?*

Anterior PFV?




Anterior vascular capsule



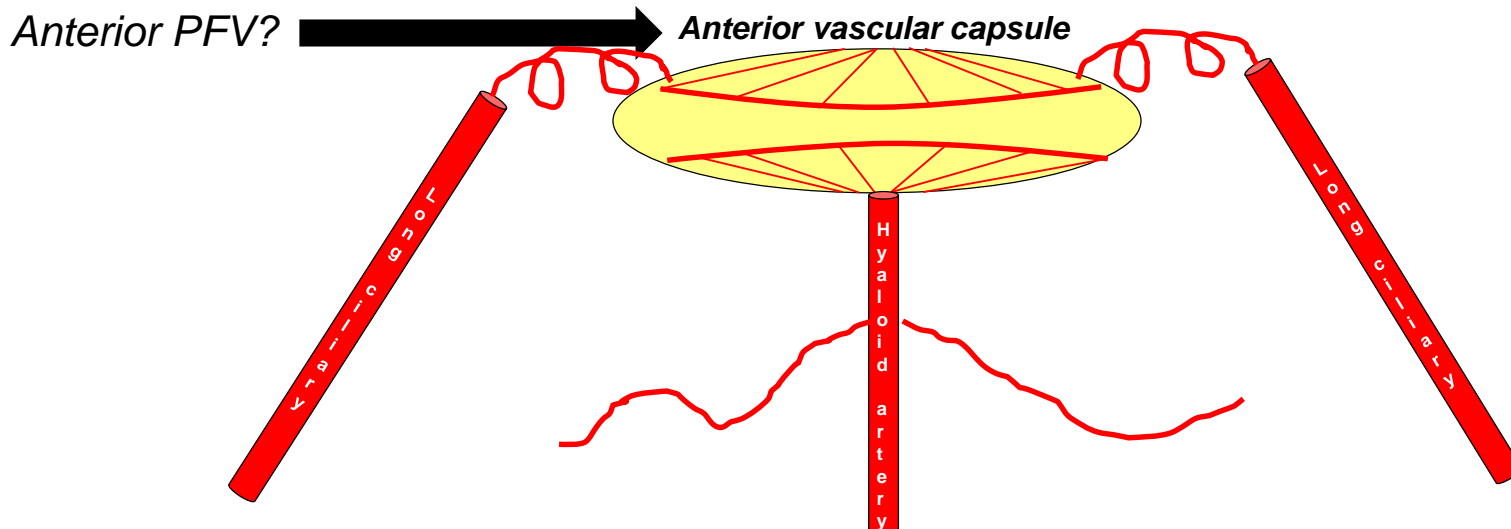
Persistent Fetal Vasculature

Anterior

Posterior



*Shouldn't a failure to regress by the **anterior** vascular capsule constitute **anterior** PFV?*
 No, because the anterior vasc capsule derives from the long ciliary arteries, not the hyaloid system





Persistent Fetal Vasculature

Anterior

Posterior

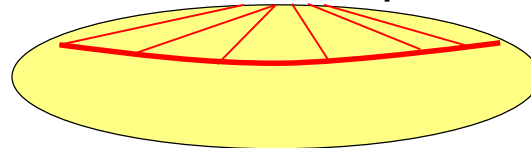
Speaking of: Two remnants of a failed-to-completely-regress anterior vascular capsule are commonly encountered at the slit lamp. What are they?

--?

--?

Shouldn't a failure to regress by the anterior vascular capsule constitute anterior PFV?
 No, because the anterior vasc capsule derives from the long ciliary arteries, not the
 hyaloid system

Anterior vascular capsule





Persistent Fetal Vasculature

Anterior

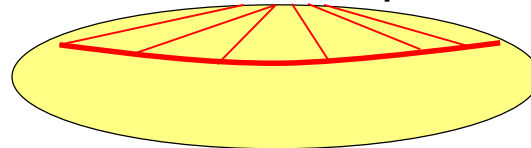
Posterior


Speaking of: Two remnants of a failed-to-completely-regress anterior vascular capsule are commonly encountered at the slit lamp. What are they?

- Epicapsular star
- Persistent pupillary membrane

Shouldn't a failure to regress by the anterior vascular capsule constitute anterior PFV?
 No, because the anterior vasc capsule derives from the long ciliary arteries, not the hyaloid system

Anterior vascular capsule





Persistent Fetal Vasculature

Anterior

Posterior

Speaking of: Two remnants of a failed-to-completely-regress anterior vascular capsule are commonly encountered at the slit lamp. What are they?

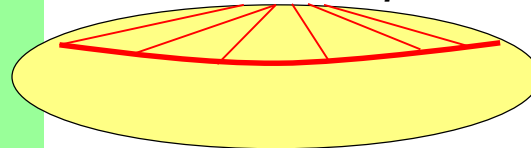
--Epicapsular star


--Persistent pupillary membrane

Shouldn't a failure to regress by the anterior vascular capsule constitute anterior PFV?
 No, because the anterior vasc capsule derives from the long ciliary arteries, not the
 hyaloid system.

How does an epicapsular star present?

Anterior vascular capsule





Persistent Fetal Vasculature

Anterior

Posterior

Speaking of: Two remnants of a failed-to-completely-regress anterior vascular capsule are commonly encountered at the slit lamp. What are they?

--Epicapsular star

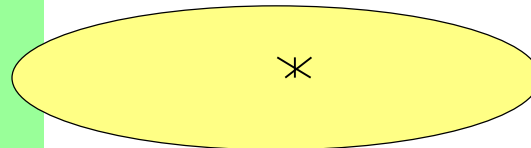
--Persistent pupillary membrane


Shouldn't a failure to regress by the anterior vascular capsule constitute anterior PFV?

No, because the anterior vasc capsule derives from the long ciliary arteries, not the hyaloid system

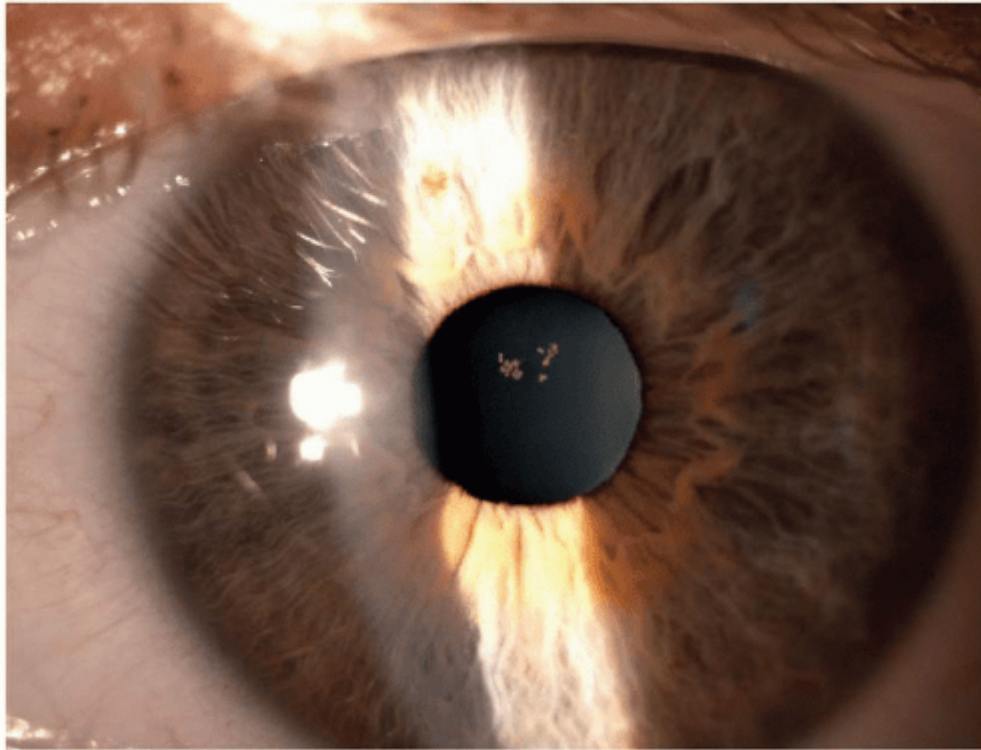
How does an epicapsular star present?

As a tiny, star-shaped schmutz on the anterior capsule





Persistent Fetal Vasculature



Epicapsular star



Persistent Fetal Vasculature

Anterior

Posterior

Speaking of: Two remnants of a failed-to-completely-regress anterior vascular capsule are commonly encountered at the slit lamp. What are they?

--Epicapsular star

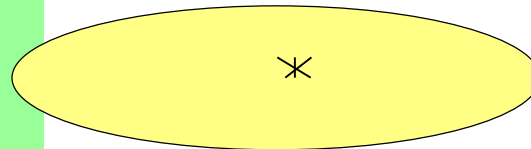
--Persistent pupillary membrane


Shouldn't a failure to regress by the anterior vascular capsule constitute anterior PFV?
 No, because the anterior vasc capsule derives from the long ciliary arteries, not the hyaloid system.

How does an epicapsular star present?

As a tiny, star-shaped schmutz on the anterior capsule

Is it common?





Persistent Fetal Vasculature

Anterior

Posterior

Speaking of: Two remnants of a failed-to-completely-regress anterior vascular capsule are commonly encountered at the slit lamp. What are they?

--Epicapsular star

--Persistent pupillary membrane

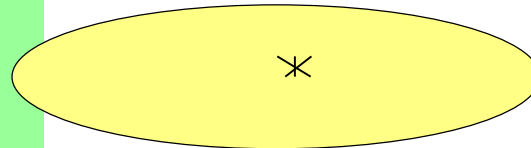
Shouldn't a failure to regress by the anterior vascular capsule constitute anterior PFV?
 No, because the anterior vasc capsule derives from the long ciliary arteries, not the hyaloid system.


How does an epicapsular star present?

As a tiny, star-shaped schmutz on the anterior capsule

Is it common?

Very





Persistent Fetal Vasculature

Anterior

Posterior

Speaking of: Two remnants of a failed-to-completely-regress anterior vascular capsule are commonly encountered at the slit lamp. What are they?

--Epicapsular star

--Persistent pupillary membrane

Shouldn't a failure to regress by the anterior vascular capsule constitute anterior PFV?
 No, because the anterior vasc capsule derives from the long ciliary arteries, not the hyaloid system.

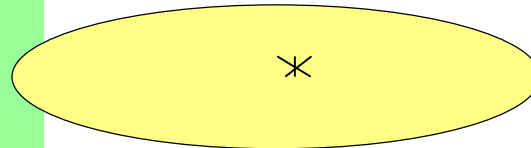
How does an epicapsular star present?


As a tiny, star-shaped schmutz on the anterior capsule

Is it common?

Very

Is it visually/medically significant?





Persistent Fetal Vasculature

Anterior

Posterior

Speaking of: Two remnants of a failed-to-completely-regress anterior vascular capsule are commonly encountered at the slit lamp. What are they?

--Epicapsular star

--Persistent pupillary membrane

Shouldn't a failure to regress by the anterior vascular capsule constitute anterior PFV?
 No, because the anterior vasc capsule derives from the long ciliary arteries, not the
 hyaloid system

How does an epicapsular star present?

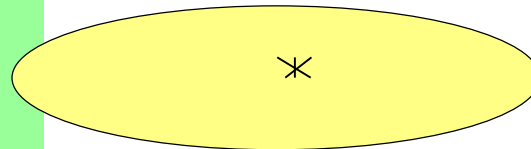
As a tiny, star-shaped schmutz on the
 anterior capsule

Is it common?

Very

Is it visually/medically significant?

Never





Persistent Fetal Vasculature

Anterior

Posterior

Speaking of: Two remnants of a failed-to-completely-regress anterior vascular capsule are commonly encountered at the slit lamp. What are they?

--Epicapsular star

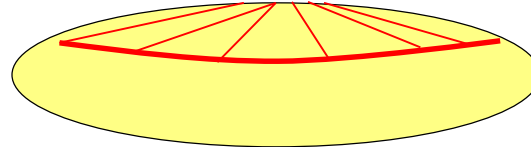
--**Persistent pupillary membrane**

Shouldn't a failure to regress by the anterior vascular capsule constitute anterior PFV?

Not because the anterior vascular capsule derives from the long ciliary arteries, not the

How does a persistent pupillary membrane present?

Anterior vascular capsule





Persistent Fetal Vasculature

Anterior

Posterior

Speaking of: Two remnants of a failed-to-completely-regress anterior vascular capsule are commonly encountered at the slit lamp. What are they?

--Epicapsular star

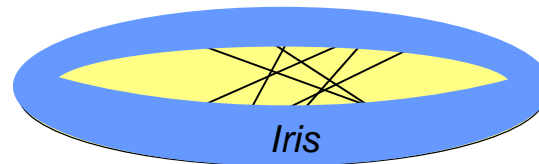
--**Persistent pupillary membrane**

Shouldn't a failure to regress by the anterior vascular capsule constitute anterior PFV?

Not because the anterior vascular capsule derives from the long ciliary arteries, not the

How does a persistent pupillary membrane present?

As fibers stretching across the pupillary aperture





Persistent Fetal Vasculature

Anterior

Posterior

Speaking of: Two remnants of a failed-to-completely-regress anterior vascular capsule are commonly encountered at the slit lamp. What are they?

--Epicapsular star

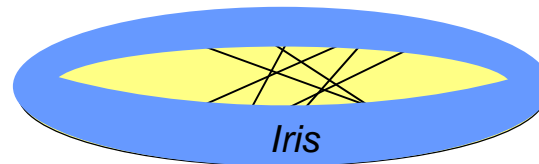
--**Persistent pupillary membrane**

*Shouldn't a failure to regress by the anterior vascular capsule constitute anterior PFV?
 No because anterior vascular capsule derives from the long ciliary arteries, not the*

How does a persistent pupillary membrane present?

As fibers stretching across the pupillary aperture

How extensive is it?





Persistent Fetal Vasculature

Anterior

Posterior

Speaking of: Two remnants of a failed-to-completely-regress anterior vascular capsule are commonly encountered at the slit lamp. What are they?

--Epicapsular star

--**Persistent pupillary membrane**

Shouldn't a failure to regress by the anterior vascular capsule constitute anterior PFV?

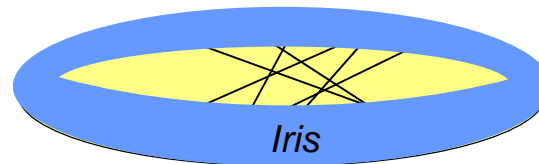
Note: The anterior vascular capsule derives from the long ciliary arteries, not the

How does a persistent pupillary membrane present?

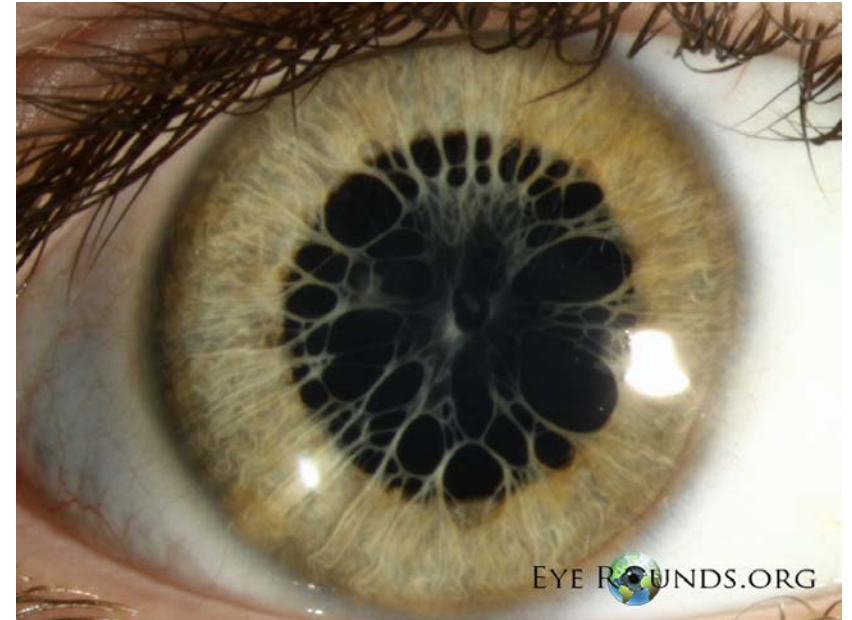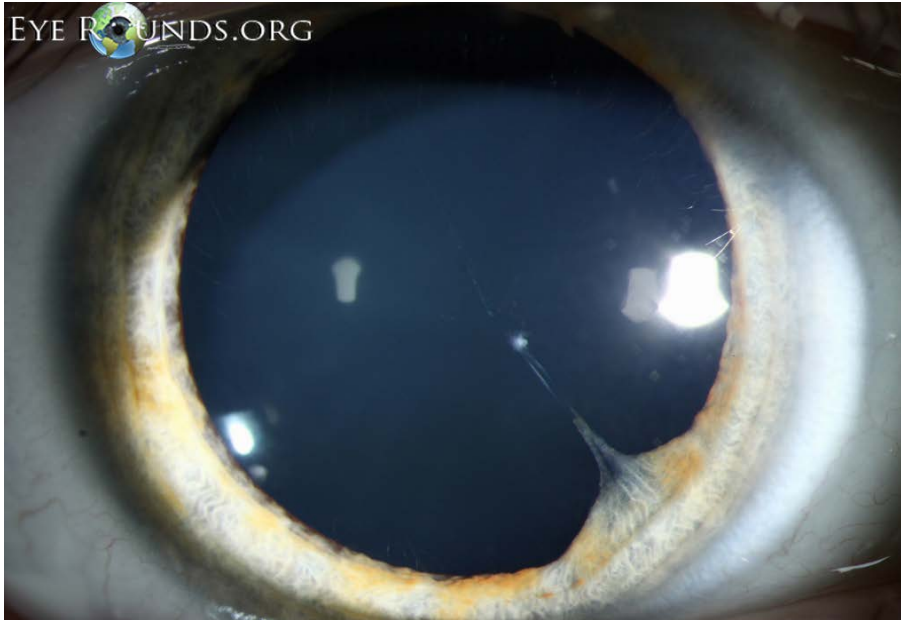

As fibers stretching across the pupillary aperture

How extensive is it?


It varies significantly, from a few barely-visible strands to a vast and intricate web



Persistent Fetal Vasculature



Persistent pupillary membrane



Persistent Fetal Vasculature

Anterior

Posterior

Speaking of: Two remnants of a failed-to-completely-regress anterior vascular capsule are commonly encountered at the slit lamp. What are they?

--Epicapsular star

--**Persistent pupillary membrane**

*Shouldn't a failure to regress by the anterior vascular capsule constitute anterior PFV?
No, because the anterior vascular capsule derives from the long ciliary arteries, not the*

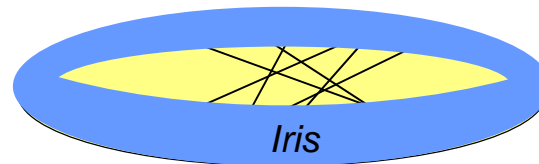
How does a persistent pupillary membrane present?


As fibers stretching across the pupillary aperture

How extensive is it?

It varies significantly, from a few barely-visible strands to a vast and intricate web

Is it common?





Persistent Fetal Vasculature

Anterior

Posterior

Speaking of: Two remnants of a failed-to-completely-regress anterior vascular capsule are commonly encountered at the slit lamp. What are they?

--Epicapsular star

--**Persistent pupillary membrane**

*Shouldn't a failure to regress by the anterior vascular capsule constitute anterior PFV?
No because the anterior vascular capsule derives from the long ciliary arteries, not the*

How does a persistent pupillary membrane present?

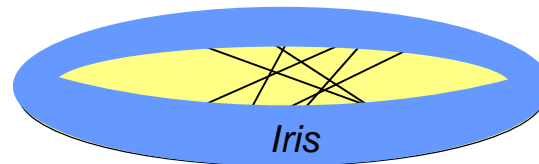
As fibers stretching across the pupillary aperture

How extensive is it?

It varies significantly, from a few barely-visible strands to a vast and intricate web

Is it common?

Very





Persistent Fetal Vasculature

Anterior

Posterior

Speaking of: Two remnants of a failed-to-completely-regress anterior vascular capsule are commonly encountered at the slit lamp. What are they?

--Epicapsular star

--**Persistent pupillary membrane**

Shouldn't a failure to regress by the anterior vascular capsule constitute anterior PFV?

Not because the anterior vascular capsule derives from the long ciliary arteries, not the

How does a persistent pupillary membrane present?

As fibers stretching across the pupillary aperture

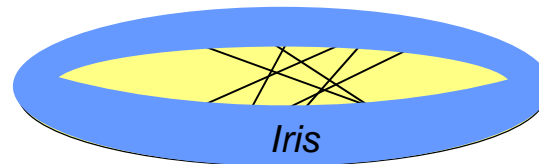
How extensive is it?


It varies significantly, from a few barely-visible strands to a vast and intricate web

Is it common?

Very

Is it visually/medically significant?





Persistent Fetal Vasculature

Anterior

Posterior

Speaking of: Two remnants of a failed-to-completely-regress anterior vascular capsule are commonly encountered at the slit lamp. What are they?

--Epicapsular star

--**Persistent pupillary membrane**

*Shouldn't a failure to regress by the anterior vascular capsule constitute anterior PFV?
No because anterior vascular capsule derives from the long ciliary arteries, not the*

How does a persistent pupillary membrane present?

As fibers stretching across the pupillary aperture

How extensive is it?

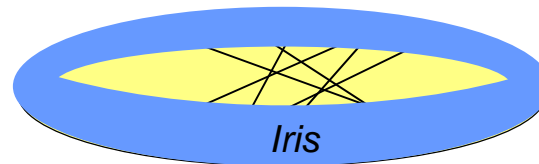
It varies significantly, from a few barely-visible strands to a vast and intricate web


Is it common?

Very

Is it visually/medically significant?

Rarely





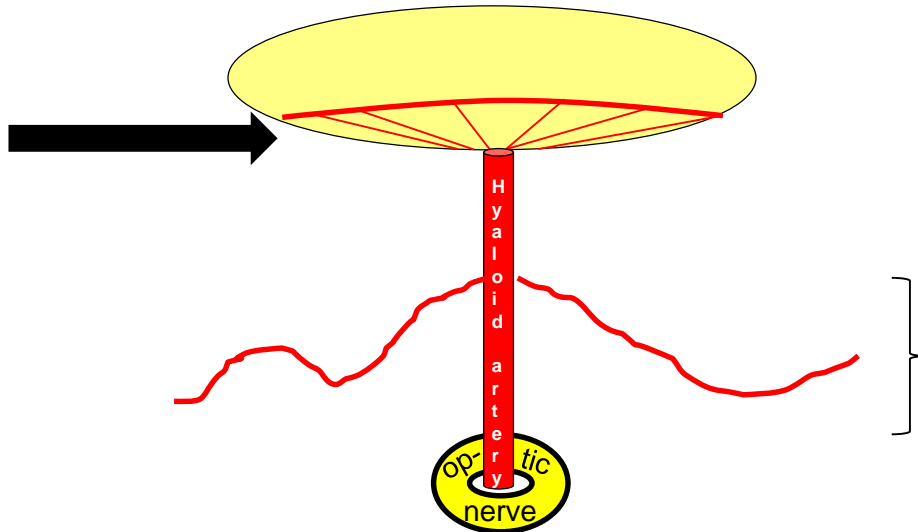
Persistent Fetal Vasculature

Anterior


Posterior

OK, back to PFV. Take note:

Anterior PFV:
Retrolental space



Posterior PFV:
Retinal branch remnants



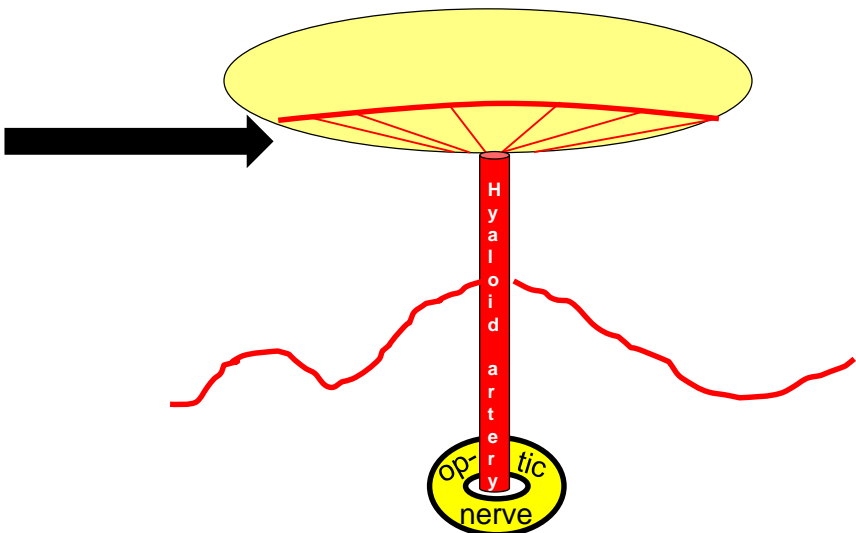
Persistent Fetal Vasculature




Anterior and posterior PFV both exist on a 'continuum of severity' ranging from clinically insignificant to clinically devastating

OK, back to PFV. Take note:

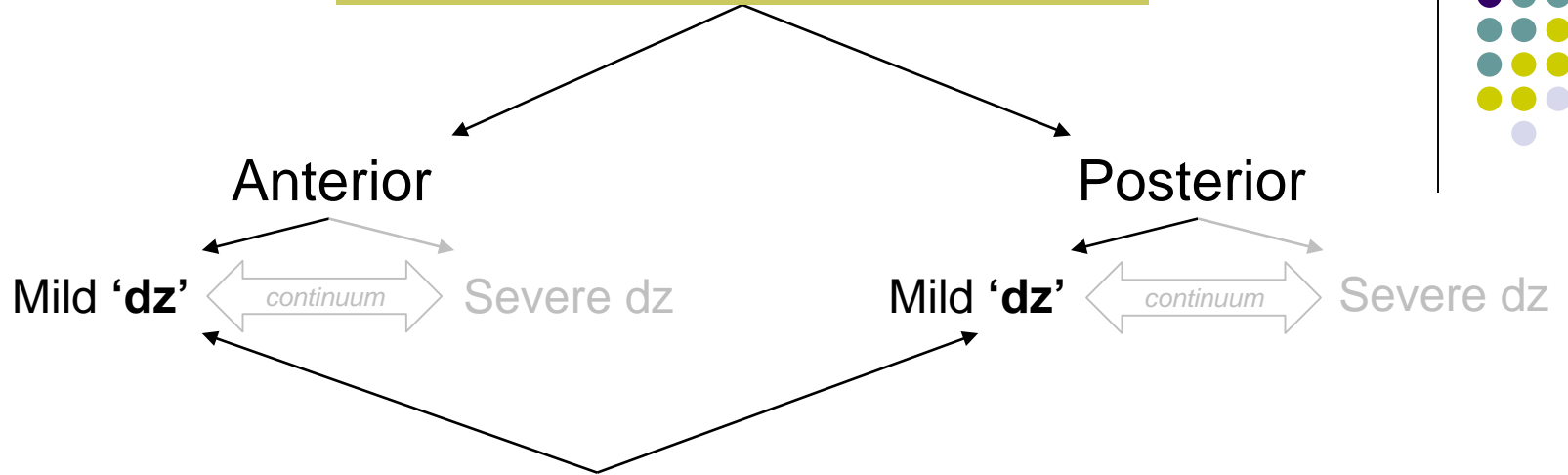
Anterior PFV:
Retrolental space



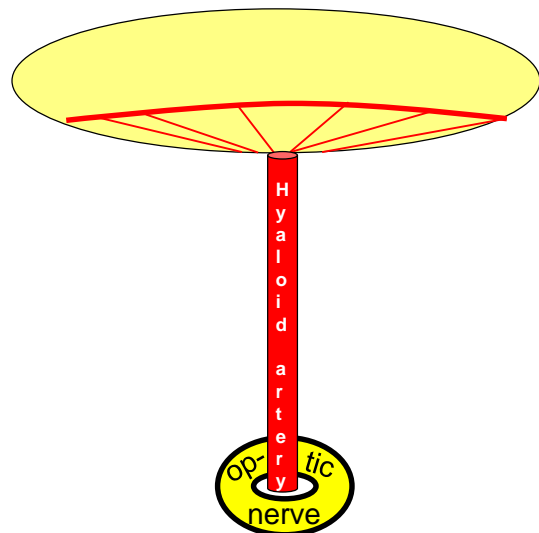
Posterior PFV:
Retinal branch remnants



Persistent Fetal Vasculature

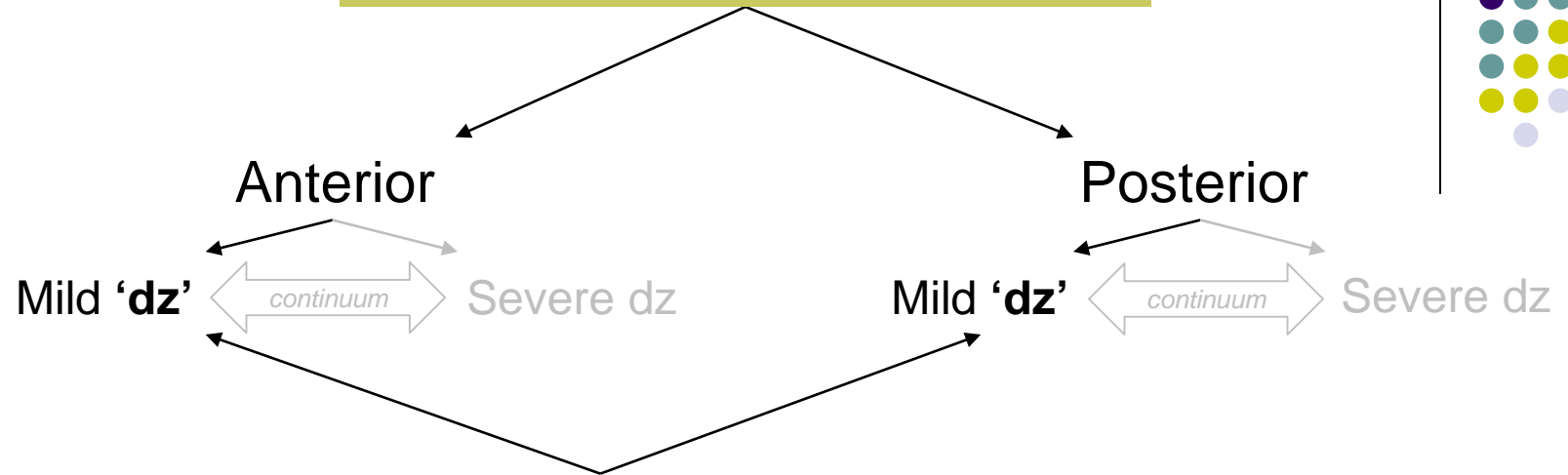


Why is the word disease in 'quotes' here?

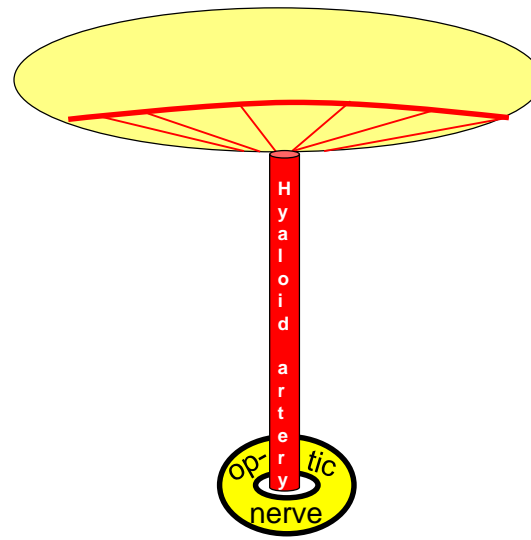




Persistent Fetal Vasculature



Why is the word disease in 'quotes' here?
 Because mild PFV is so clinically insignificant it doesn't really count as a disease *per se*

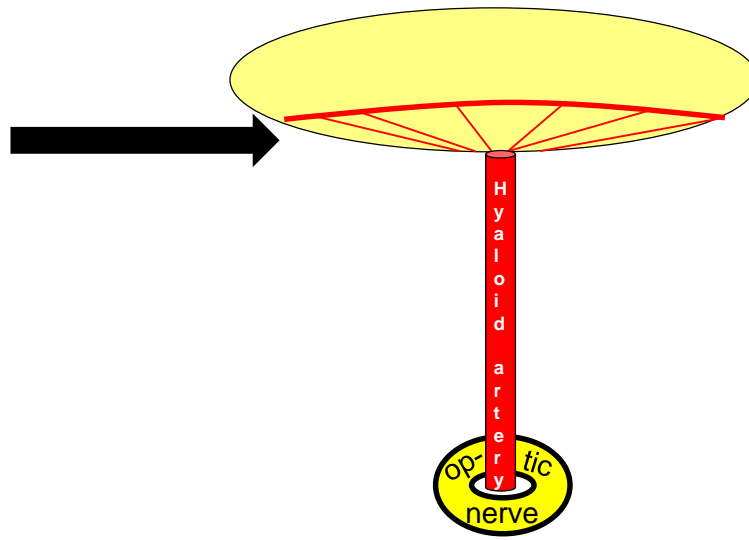


Persistent Fetal Vasculature



What is the eponymous name of the classic manifestation of mild, clinically insignificant anterior PFV?

*Anterior PFV:
Retrolental space*



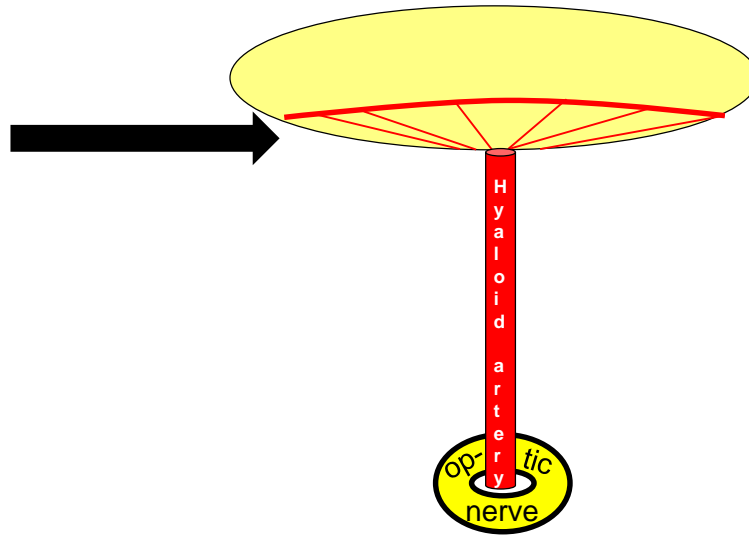
Persistent Fetal Vasculature



What is the eponymous name of the classic manifestation of mild, clinically insignificant anterior PFV?

A two words

Anterior PFV:
Retrolental space



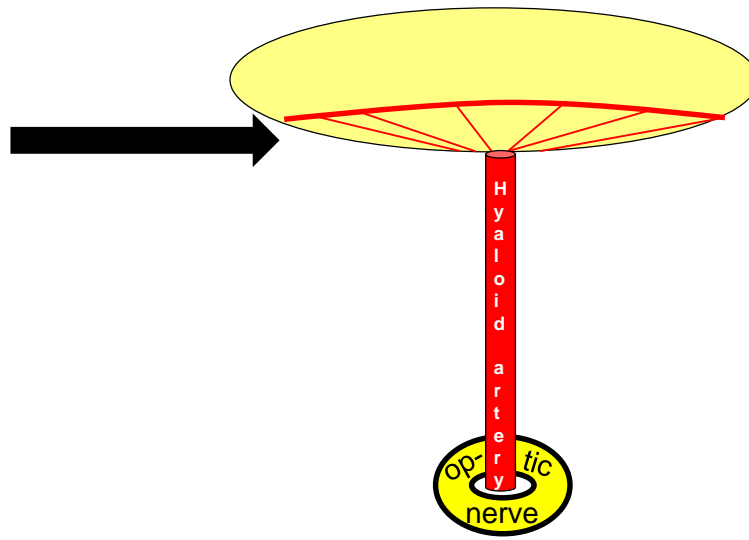
Persistent Fetal Vasculature



What is the eponymous name of the classic manifestation of mild, clinically insignificant anterior PFV?

A dot

Anterior PFV:
Retrolental space



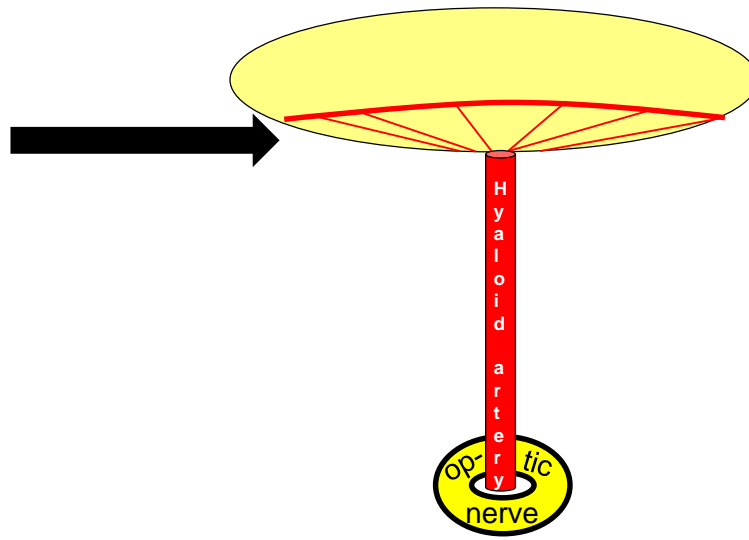
Persistent Fetal Vasculature



What is the eponymous name of the classic manifestation of mild, clinically insignificant anterior PFV?

A Mittendorf dot

Anterior PFV:
Retrolental space



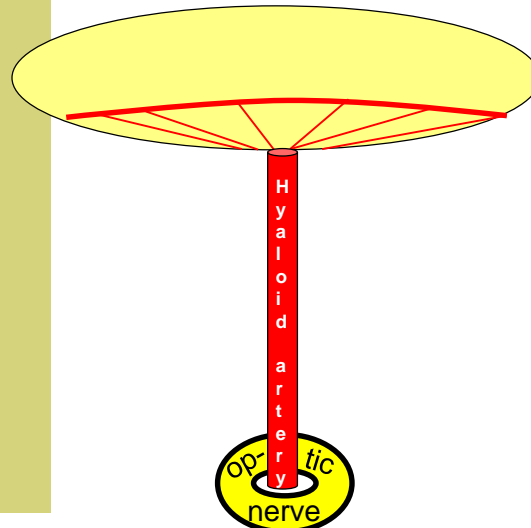
Persistent Fetal Vasculature




What is the eponymous name of the classic manifestation of mild, clinically insignificant anterior PFV?

A **Mittendorf dot**

How does a Mittendorf dot present?





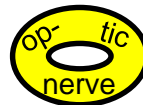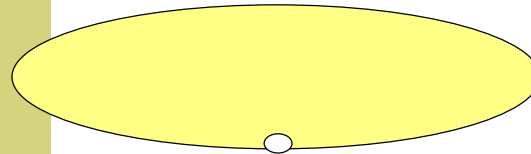
Persistent Fetal Vasculature



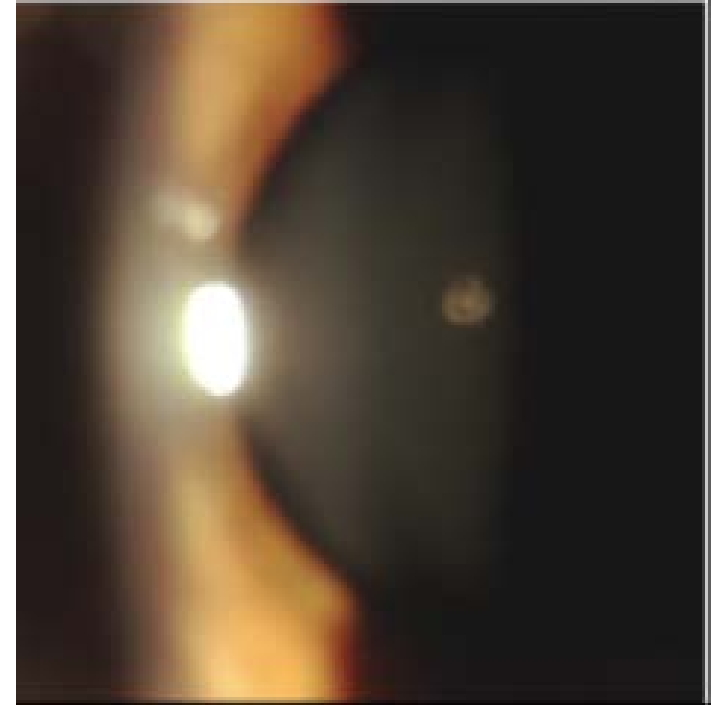
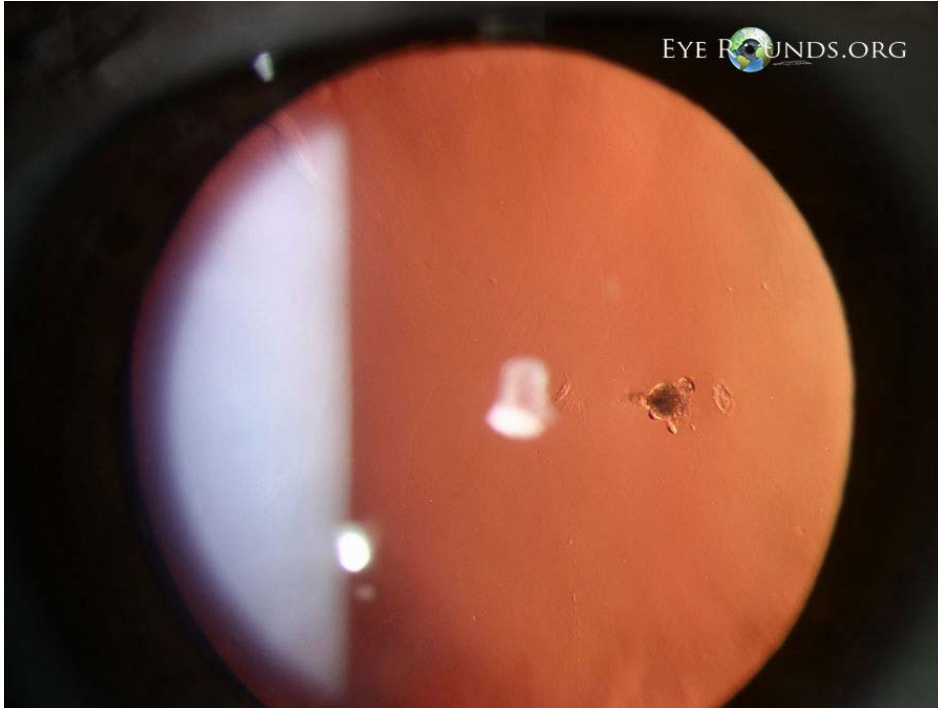What is the eponymous name of the classic manifestation of mild, clinically insignificant anterior PFV?

A **Mittendorf dot**

How does a Mittendorf dot present?
As a minute white dot on the back of the lens, slightly inferonasal to center



Persistent Fetal Vasculature



Mittendorf dot



Persistent Fetal Vasculature



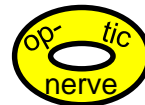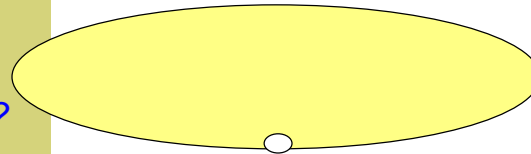
What is the eponymous name of the classic manifestation of mild, clinically insignificant anterior PFV?

A **Mittendorf dot**

How does a Mittendorf dot present?

As a minute white dot on the back of the lens, slightly inferonasal to center

How does it relate to the hyaloid system?





Persistent Fetal Vasculature



What is the eponymous name of the classic manifestation of mild, clinically insignificant anterior PFV?

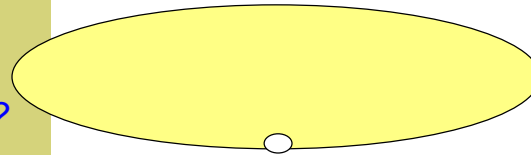
A **Mittendorf dot**


How does a Mittendorf dot present?

As a minute white dot on the back of the lens, slightly inferonasal to center

How does it relate to the hyaloid system?

It is a vestige of the attachment of the hyaloid artery to the back of the lens





Persistent Fetal Vasculature



What is the eponymous name of the classic manifestation of mild, clinically insignificant anterior PFV?

A **Mittendorf dot**

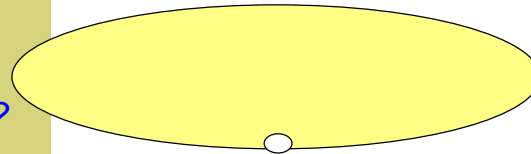
How does a Mittendorf dot present?


As a minute white dot on the back of the lens, slightly inferonasal to center

How does it relate to the hyaloid system?

It is a vestige of the attachment of the hyaloid artery to the back of the lens

Is it common?





Persistent Fetal Vasculature



What is the eponymous name of the classic manifestation of mild, clinically insignificant anterior PFV?

A **Mittendorf dot**

How does a Mittendorf dot present?

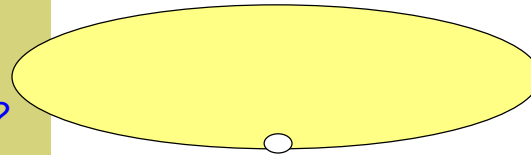
As a minute white dot on the back of the lens, slightly inferonasal to center

How does it relate to the hyaloid system?

It is a vestige of the attachment of the hyaloid artery to the back of the lens

Is it common?

Very





Persistent Fetal Vasculature



What is the eponymous name of the classic manifestation of mild, clinically insignificant anterior PFV?

A **Mittendorf dot**

How does a Mittendorf dot present?

As a minute white dot on the back of the lens, slightly inferonasal to center

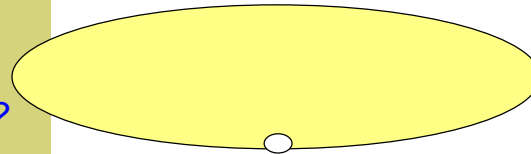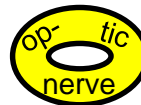
How does it relate to the hyaloid system?

It is a vestige of the attachment of the hyaloid artery to the back of the lens

Is it common?

Very

Is it visually/medically significant?





Persistent Fetal Vasculature



What is the eponymous name of the classic manifestation of mild, clinically insignificant anterior PFV?

A **Mittendorf dot**

How does a Mittendorf dot present?

As a minute white dot on the back of the lens, slightly inferonasal to center

How does it relate to the hyaloid system?

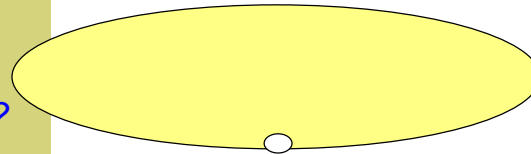
It is a vestige of the attachment of the hyaloid artery to the back of the lens


Is it common?

Very

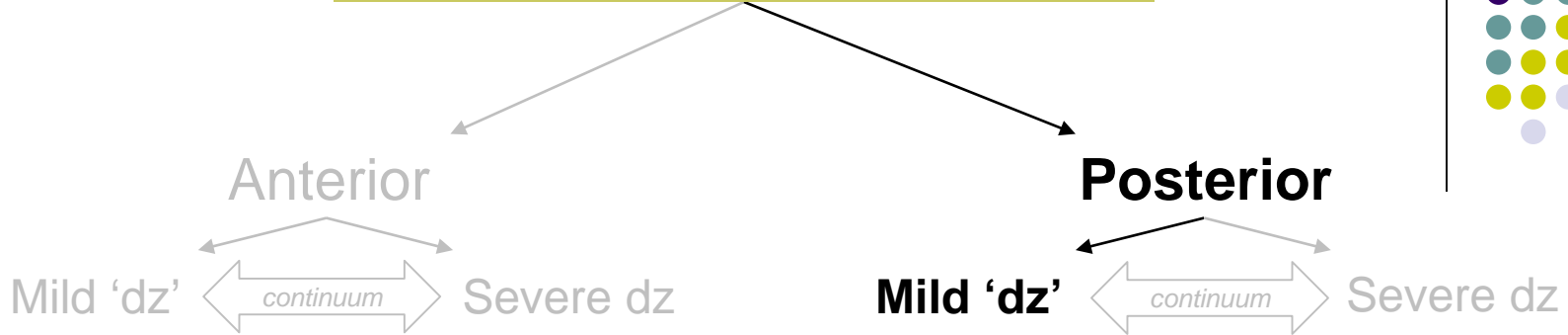
Is it visually/medically significant?

Never

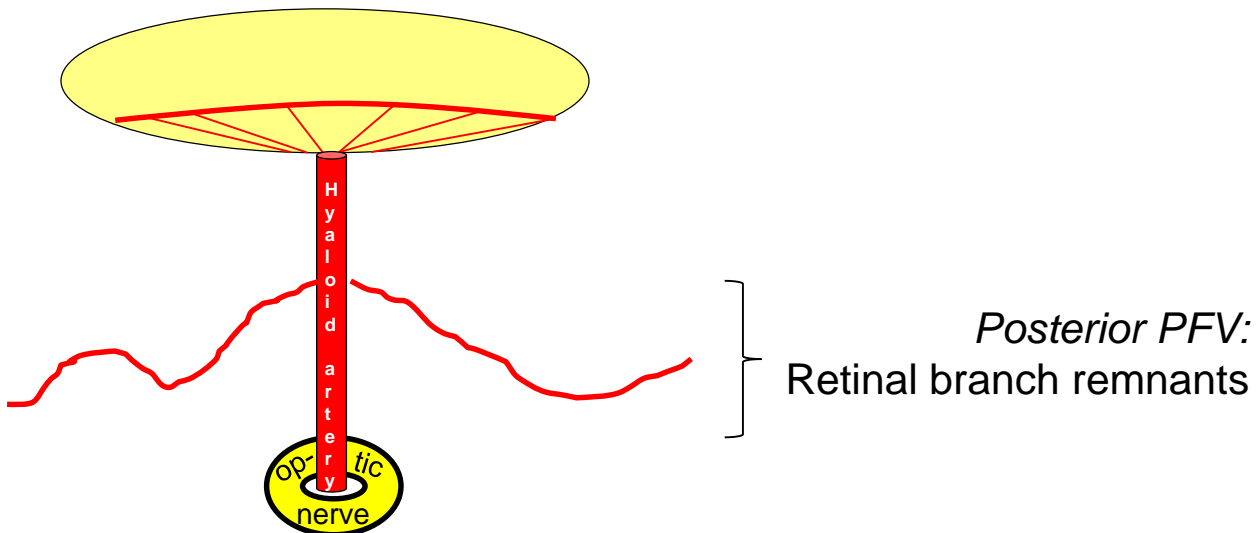





Persistent Fetal Vasculature

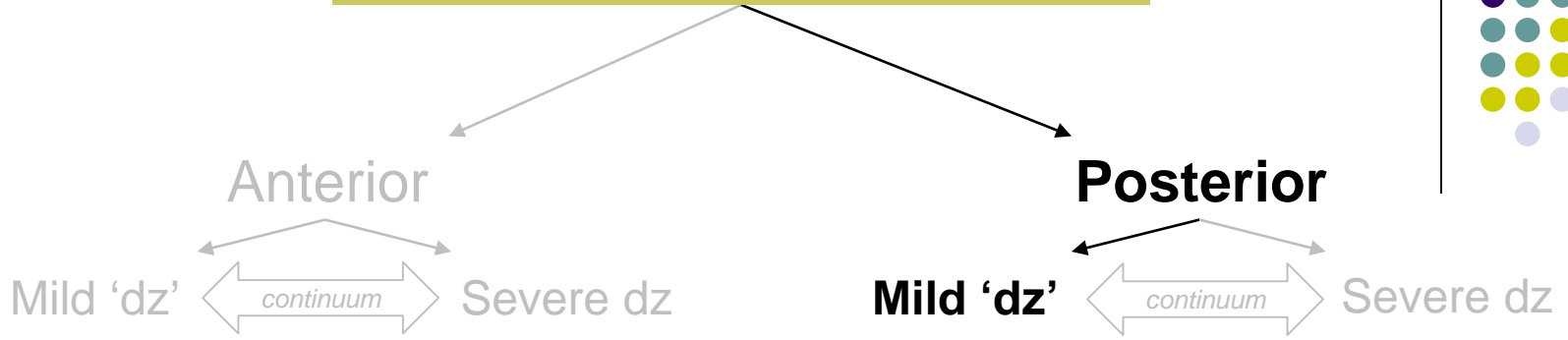


What is the eponymous name of the classic manifestation of mild, clinically insignificant posterior PFV?



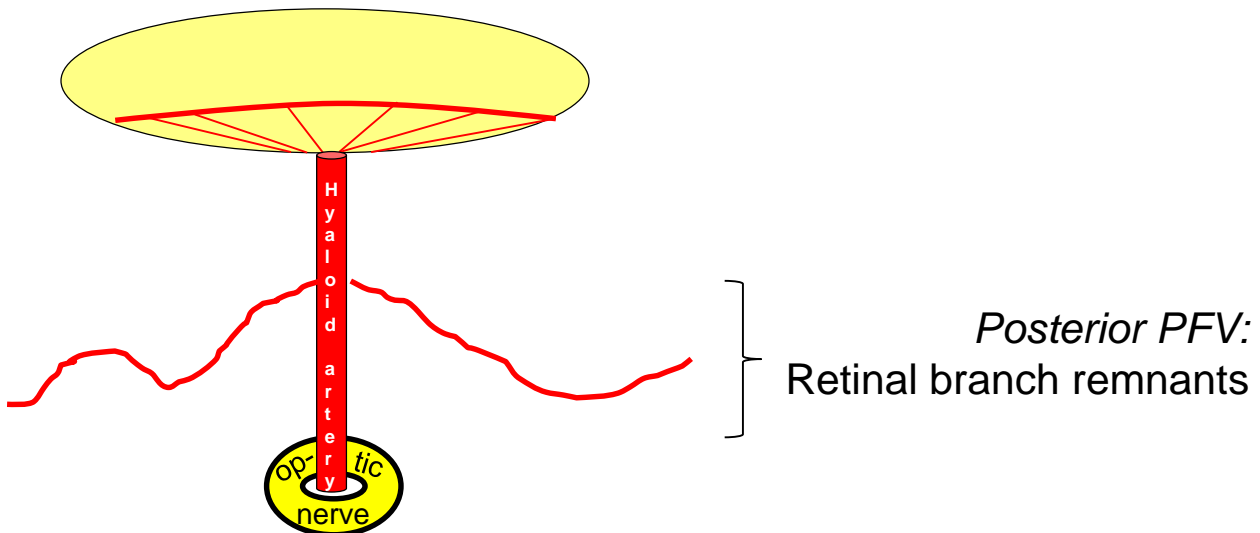



Persistent Fetal Vasculature



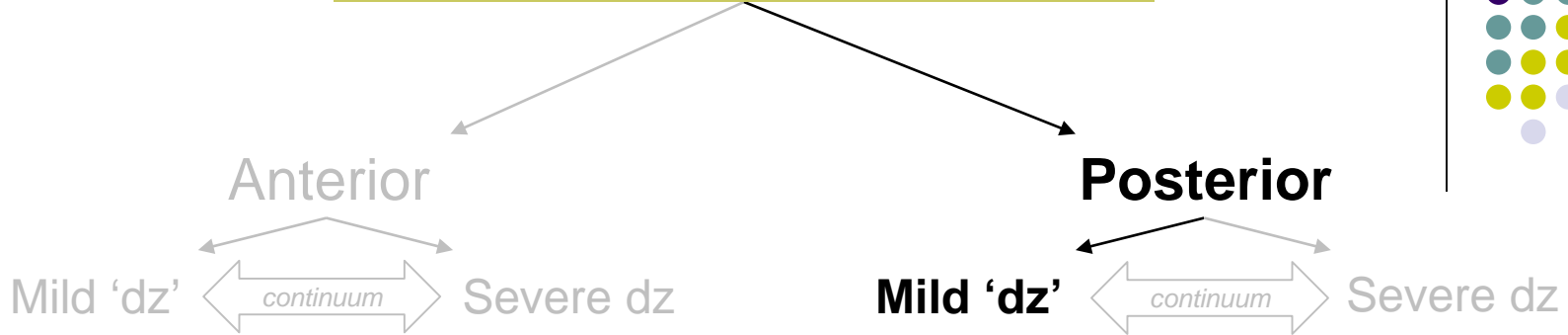
What is the eponymous name of the classic manifestation of mild, clinically insignificant **posterior PFV**?

A two words



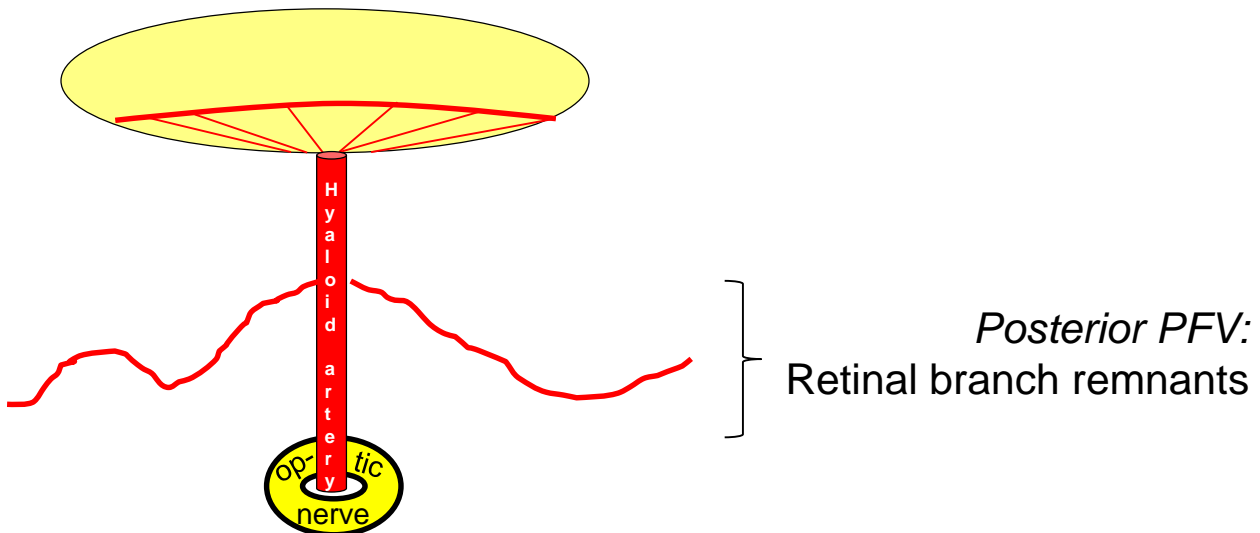


Persistent Fetal Vasculature



What is the eponymous name of the classic manifestation of mild, clinically insignificant posterior PFV?

A papilla

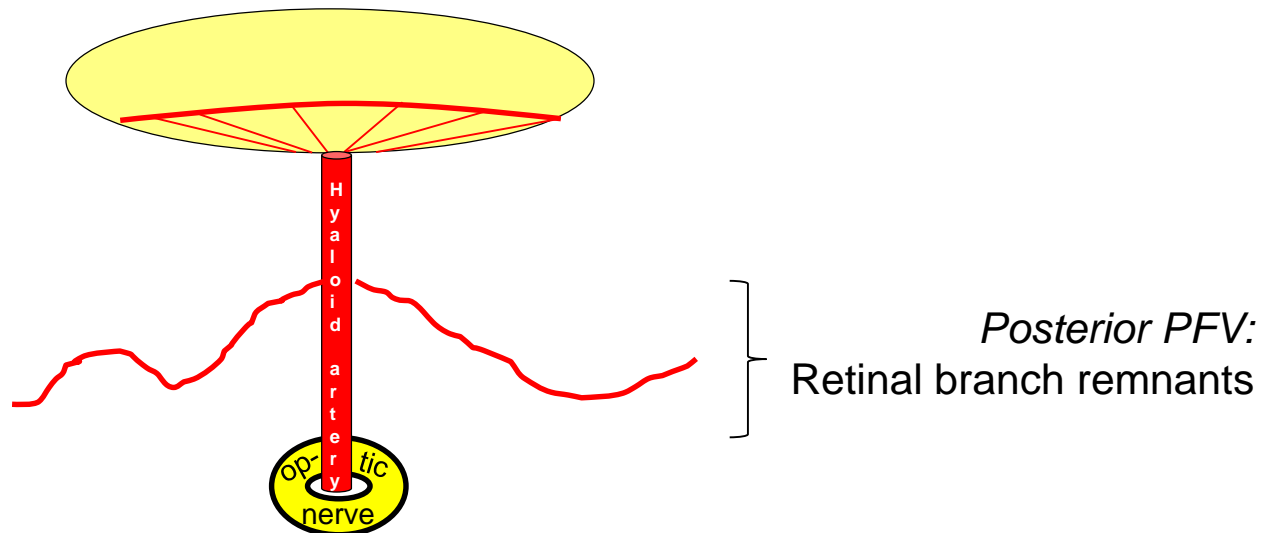


Persistent Fetal Vasculature



*What is the eponymous name of the classic manifestation of mild, clinically insignificant **posterior** PFV?*

A Bergmeister papilla



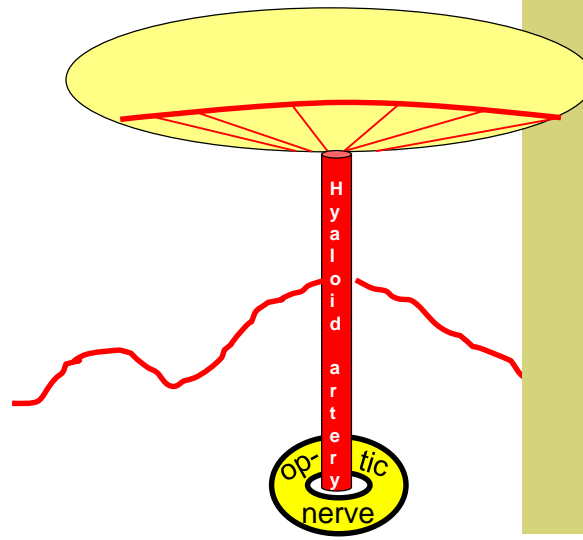
Persistent Fetal Vasculature



What is the eponymous name of the classic manifestation of mild, clinically insignificant posterior PFV?

Bergmeister papilla

How does a Bergmeister papilla present?



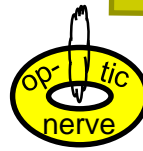Persistent Fetal Vasculature




What is the eponymous name of the classic manifestation of mild, clinically insignificant posterior PFV?

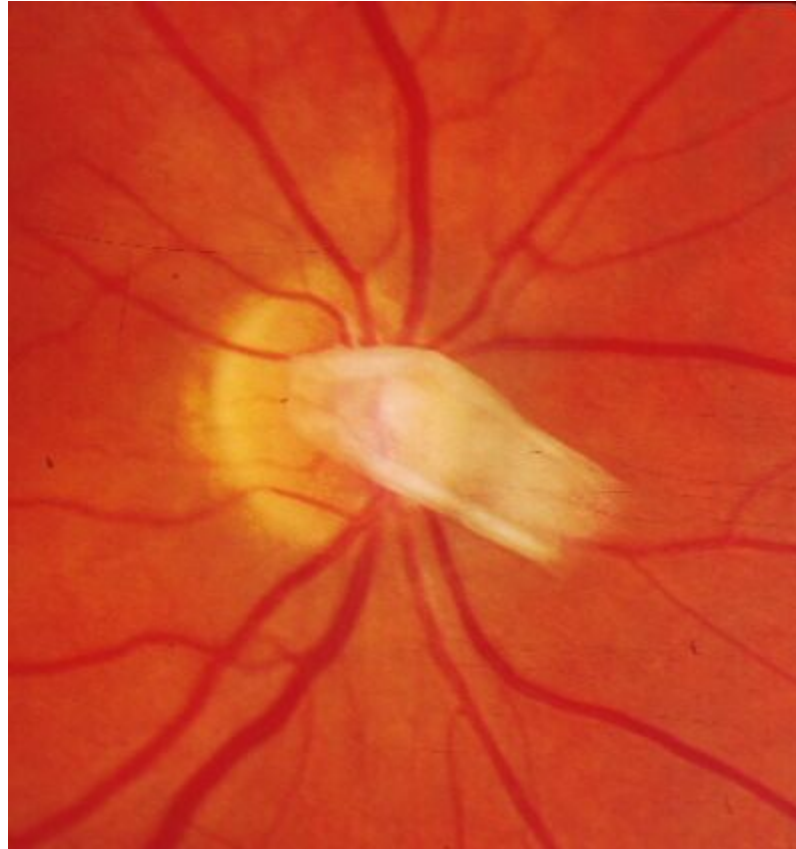
Bergmeister papilla

How does a Bergmeister papilla present?
As a small tuft of glial tissue in the V that emanates from the ONH






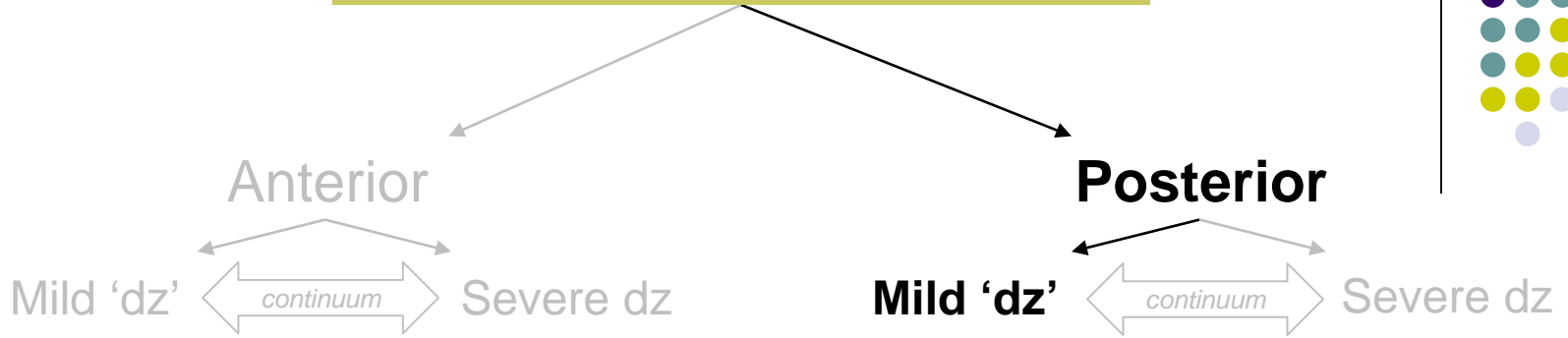
Persistent Fetal Vasculature



Bergmeister papillae

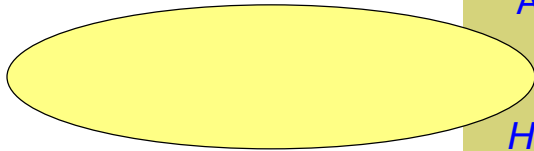


Persistent Fetal Vasculature



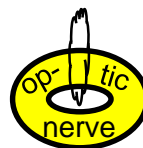
What is the eponymous name of the classic manifestation of mild, clinically insignificant posterior PFV?

Bergmeister papilla



How does a Bergmeister papilla present?
As a small tuft of glial tissue in the V that emanates from the ONH

How does it relate to the hyaloid system?



Persistent Fetal Vasculature

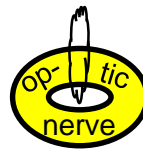


What is the eponymous name of the classic manifestation of mild, clinically insignificant posterior PFV?

Bergmeister papilla

How does a Bergmeister papilla present?
As a small tuft of glial tissue in the V that emanates from the ONH

How does it relate to the hyaloid system?
It is a vestige of the **origin** of the hyaloid artery at the ONH



Persistent Fetal Vasculature



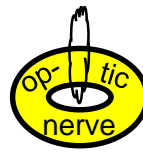
What is the eponymous name of the classic manifestation of mild, clinically insignificant posterior PFV?

Bergmeister papilla

How does a Bergmeister papilla present?
As a small tuft of glial tissue in the V that emanates from the ONH

How does it relate to the hyaloid system?
It is a vestige of the **origin** of the hyaloid artery at the ONH

Is it common?



Persistent Fetal Vasculature



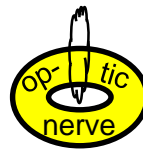
What is the eponymous name of the classic manifestation of mild, clinically insignificant posterior PFV?

Bergmeister papilla

How does a Bergmeister papilla present?
As a small tuft of glial tissue in the V that emanates from the ONH

How does it relate to the hyaloid system?
It is a vestige of the **origin** of the hyaloid artery at the ONH

Is it common?
Yes



Persistent Fetal Vasculature



What is the eponymous name of the classic manifestation of mild, clinically insignificant posterior PFV?

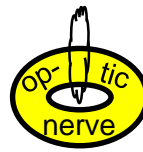
Bergmeister papilla

How does a Bergmeister papilla present?
As a small tuft of glial tissue in the V that emanates from the ONH

How does it relate to the hyaloid system?
It is a vestige of the **origin** of the hyaloid artery at the ONH

Is it common?
Yes

Is it visually/medically significant?



Persistent Fetal Vasculature



What is the eponymous name of the classic manifestation of mild, clinically insignificant posterior PFV?

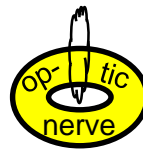
Bergmeister papilla

How does a Bergmeister papilla present?
As a small tuft of glial tissue in the V that emanates from the ONH

How does it relate to the hyaloid system?
It is a vestige of the **origin** of the hyaloid artery at the ONH

Is it common?
Yes

Is it visually/medically significant?
Never



Persistent Fetal Vasculature



What is the eponymous name of the classic manifestation of mild, clinically insignificant posterior PFV?

Bergmeister papilla

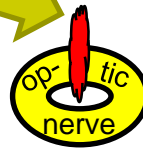How does a Bergmeister papilla present?
As a small tuft of glial tissue in the V that emanates from the ONH

How does it relate to the hyaloid system?
It is a vestige of the **origin** of the hyaloid artery at the ONH

Is it common?
Yes

Is it visually/medically significant?
Never

I saw a Bergmeister papilla that was perfused. Is this a still-viable hyaloid artery remnant?



Persistent Fetal Vasculature



What is the eponymous name of the classic manifestation of mild, clinically insignificant posterior PFV?

Bergmeister papilla

How does a Bergmeister papilla present?

As a small tuft of glial tissue in the V that emanates from the ONH

How does it relate to the hyaloid system?

It is a vestige of the **origin** of the hyaloid artery at the ONH

Is it common?

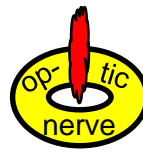Yes

Is it visually/medically significant?

Never

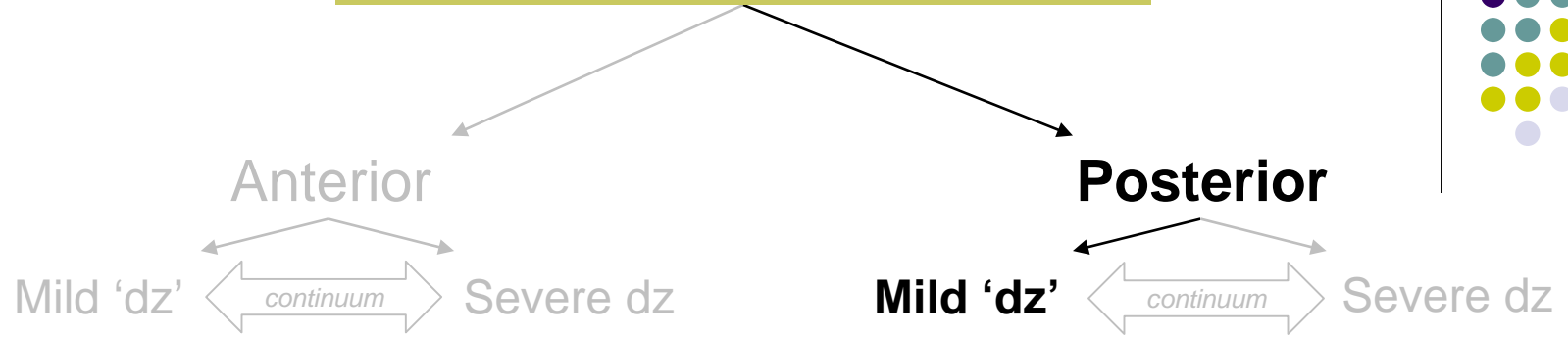
I saw a Bergmeister papilla that was perfused. Is this a still-viable hyaloid artery remnant?

You'd think so, but no. It's a prepapillary vascular loop.



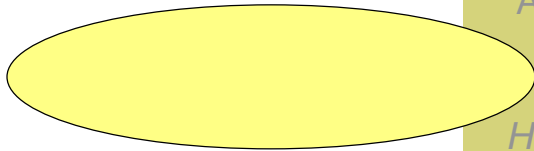


Persistent Fetal Vasculature



What is the eponymous name of the classic manifestation of mild, clinically insignificant posterior PFV?

Bergmeister papilla



How does a Bergmeister papilla present?
As a small tuft of glial tissue in the V that emanates from the ONH

How does it relate to the hyaloid system?
It is a vestige of the **origin** of the hyaloid artery at the ONH

Is it common?
Yes

Is it visually/medically significant?
Never

I saw a Bergmeister papilla that was perfused. Is this a still-viable hyaloid artery remnant?
You'd think so, but no. It's a **prepapillary vascular loop.**

What is a prepapillary vascular loop?





Persistent Fetal Vasculature



What is the eponymous name of the classic manifestation of mild, clinically insignificant posterior PFV?

Bergmeister papilla

How does a Bergmeister papilla present?
As a small tuft of glial tissue in the V that emanates from the ONH

How does it relate to the hyaloid system?
It is a vestige of the **origin** of the hyaloid artery at the ONH

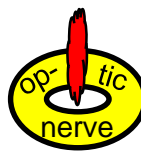Is it common?
Yes

Is it visually/medically significant?
Never

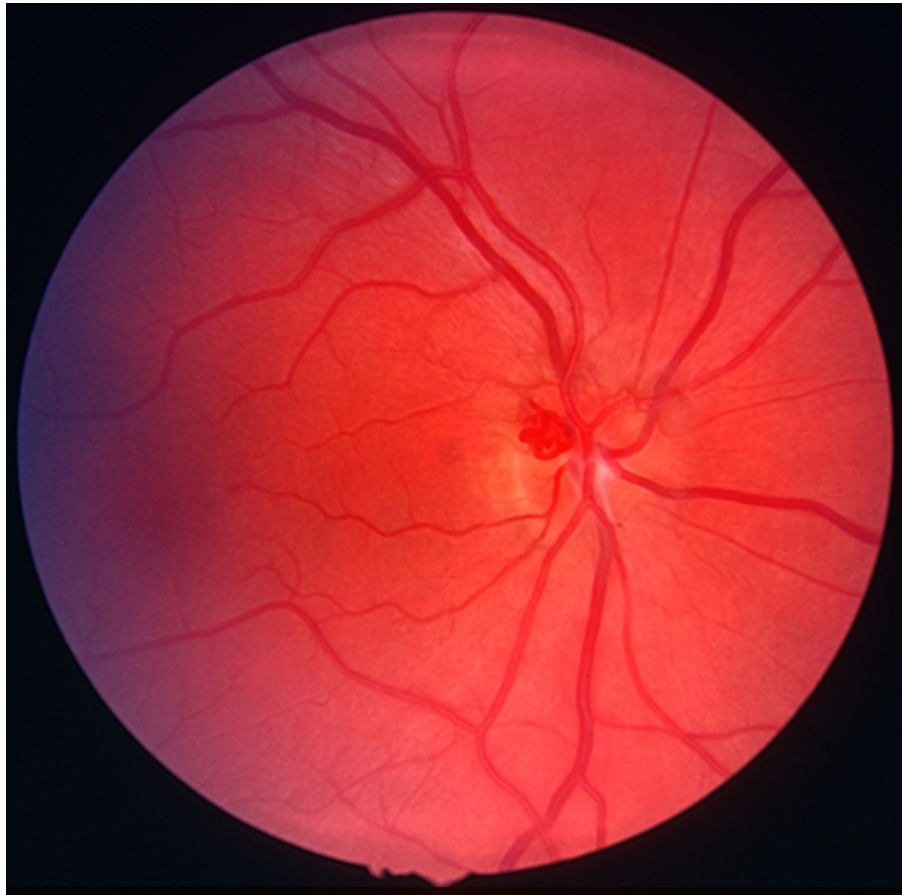I saw a Bergmeister papilla that was perfused. Is this a still-viable hyaloid artery remnant?

You'd think so, but no. It's a **prepapillary vascular loop.**

What is a prepapillary vascular loop?
It is a normal retinal vessel that 'loops' into a Bergmeister papilla, then exits



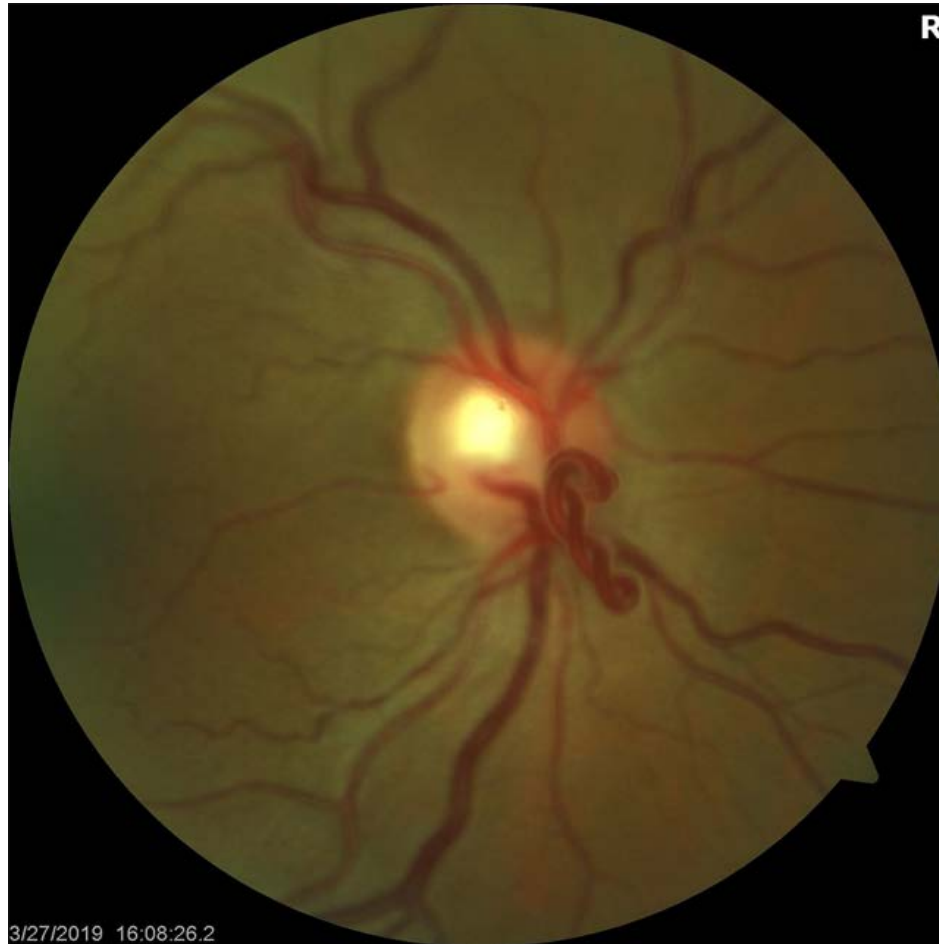Persistent Fetal Vasculature



Prepapillary vascular loop



Persistent Fetal Vasculature



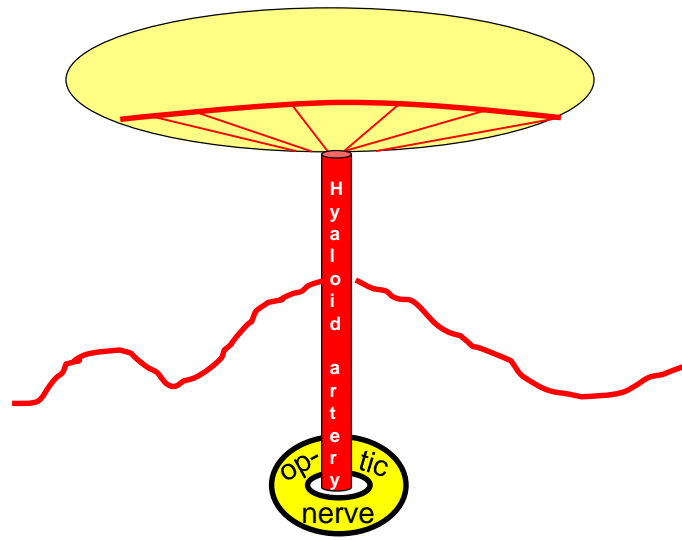
Prepapillary vascular loop with a figure-of-eight configuration



Persistent Fetal Vasculature



What is the main manifestation of severe anterior PFV?

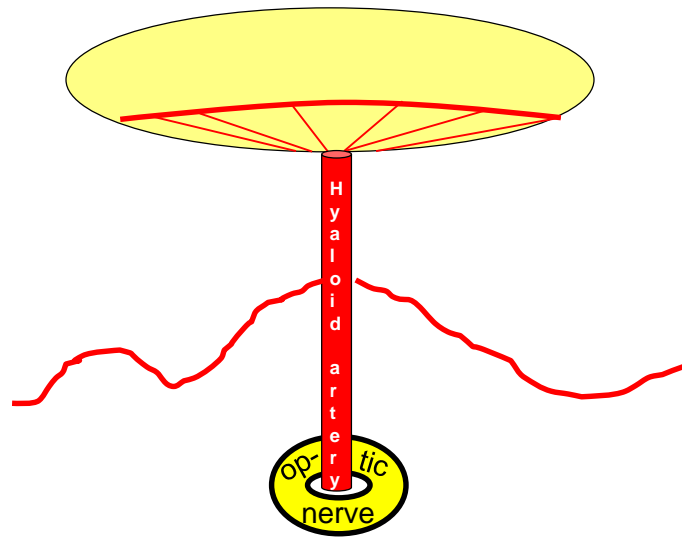


Persistent Fetal Vasculature




What is the main manifestation of severe anterior PFV?

A color, vascular status, location, membrane



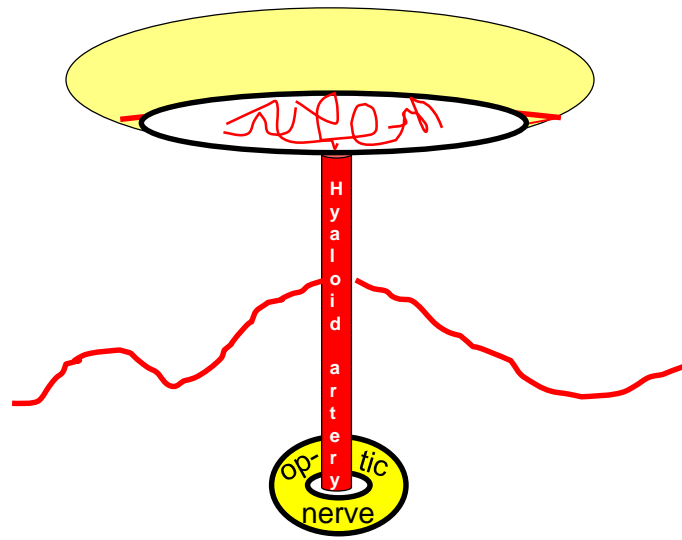



Persistent Fetal Vasculature



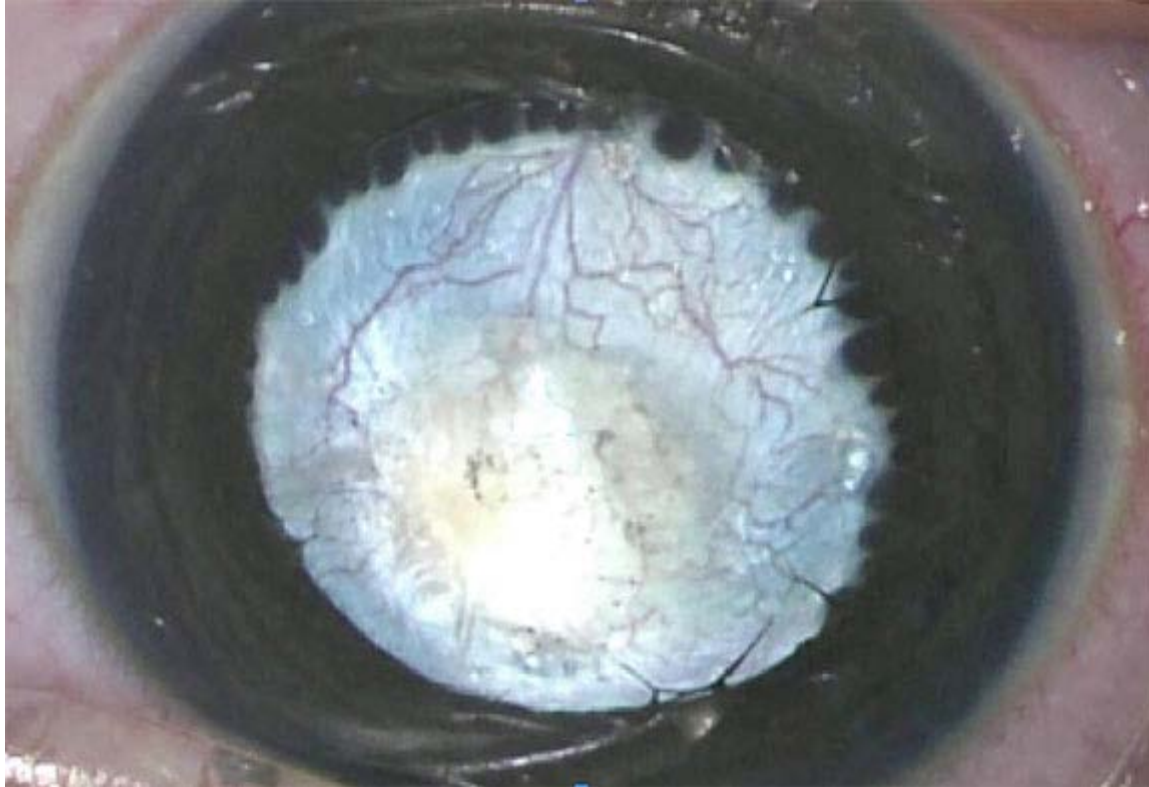
What is the main manifestation of severe anterior PFV?

A **white**, **vascularized** retrolental membrane






Persistent Fetal Vasculature



PFV: Retrolental membrane

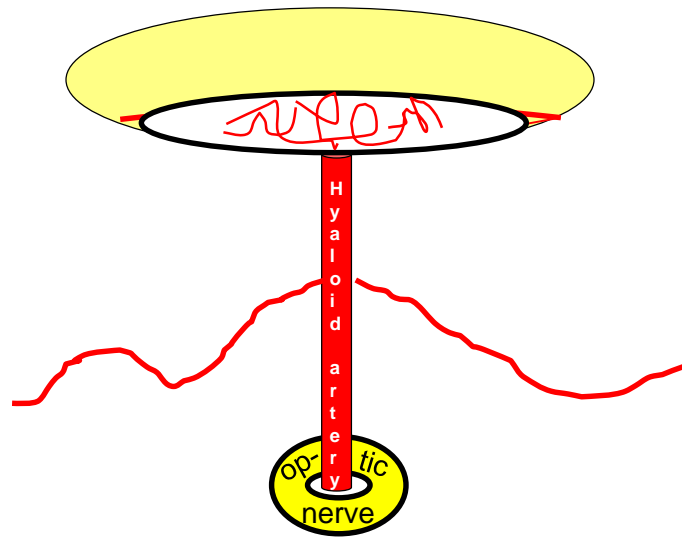
Persistent Fetal Vasculature



What is the main manifestation of severe anterior PFV?

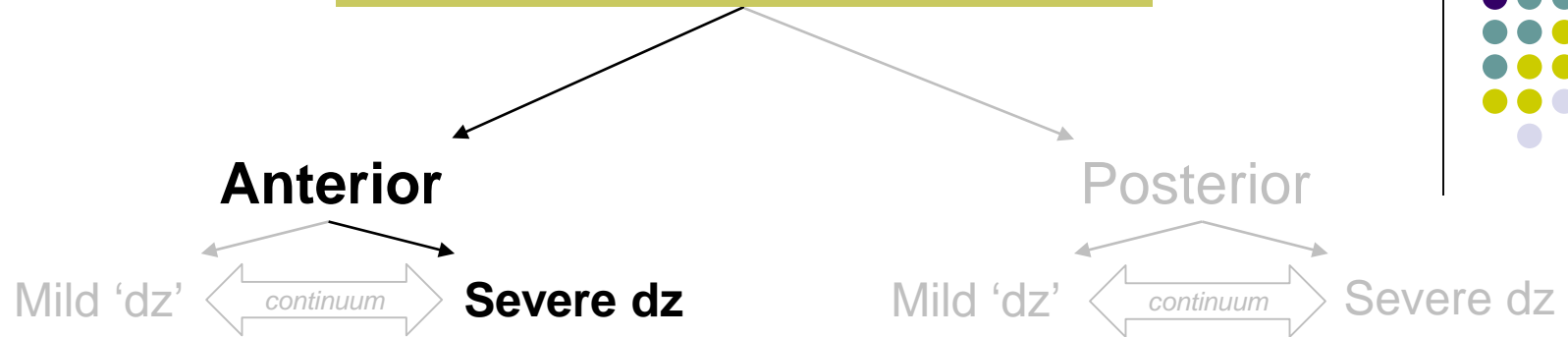A **white**, **vascularized** retrolental membrane

What finding—described in the BCSC as “classic” for anterior PFV—is associated with the peripheral aspect of the retrolental membrane?





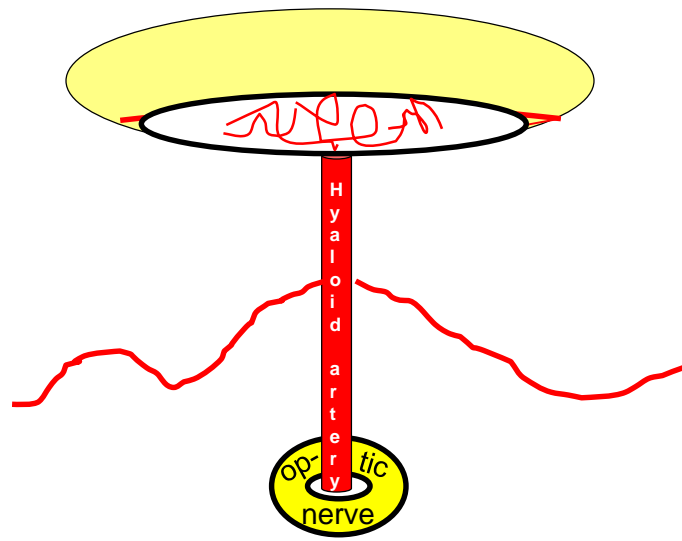
Persistent Fetal Vasculature



What is the main manifestation of severe anterior PFV?

A **white**, **vascularized** retrolental membrane

What finding—described in the BCSC as “classic” for anterior PFV—is associated with the peripheral aspect of the retrolental membrane?
Elongated are visible through the pupil when dilated





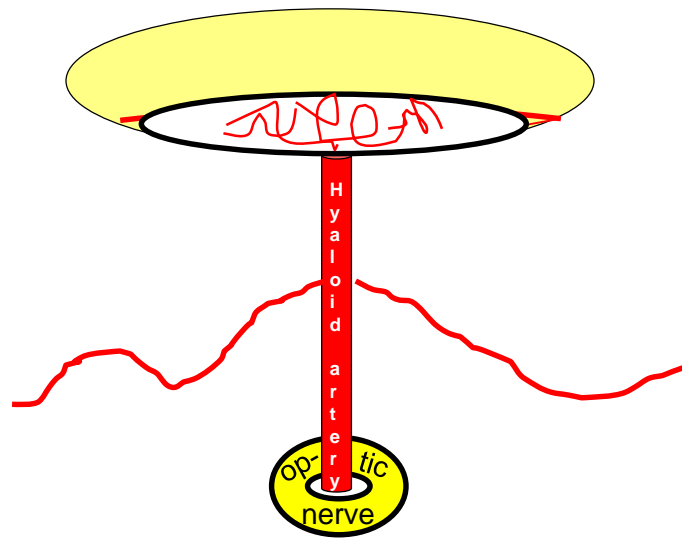
Persistent Fetal Vasculature




What is the main manifestation of severe anterior PFV?

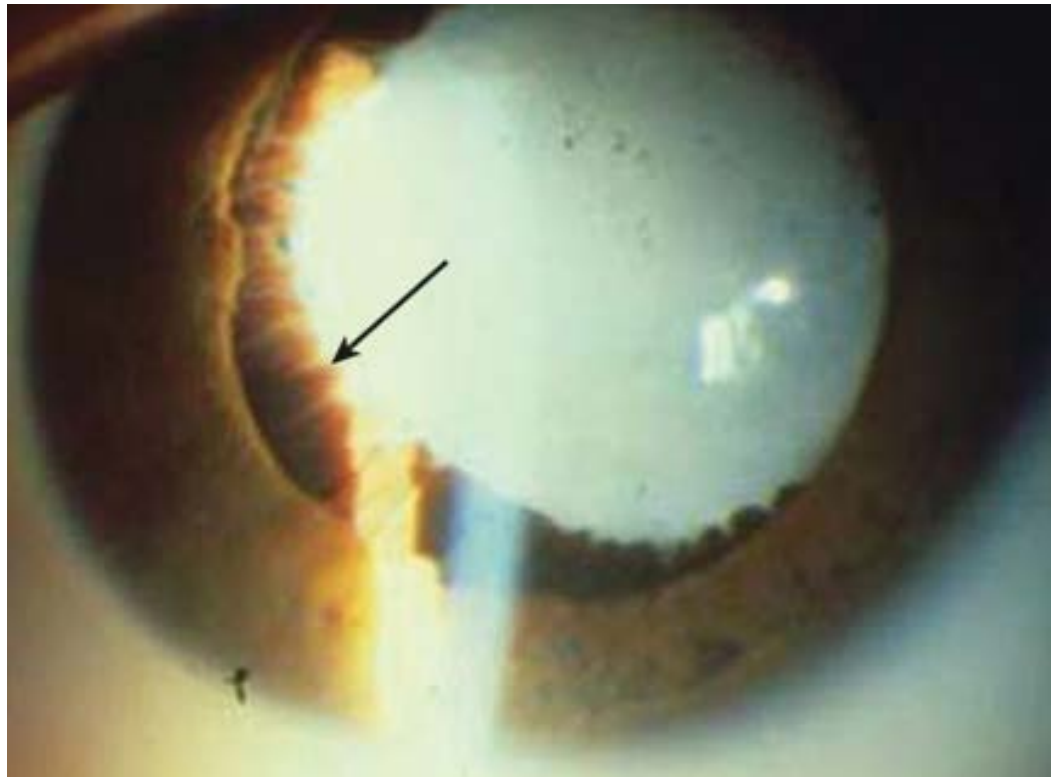
A **white**, **vascularized** retrolental membrane

What finding—described in the BCSC as “classic” for anterior PFV—is associated with the peripheral aspect of the retrolental membrane?
Elongated **ciliary processes** are visible through the pupil when dilated





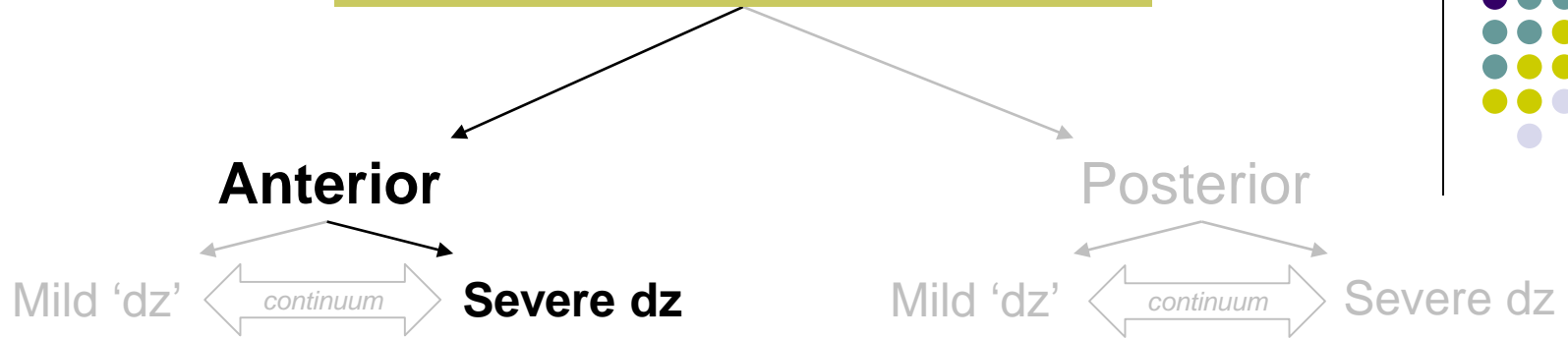Persistent Fetal Vasculature



PFV: Retrolental membrane. Note the ciliary processes (arrow)



Persistent Fetal Vasculature



What is the main manifestation of severe anterior PFV?

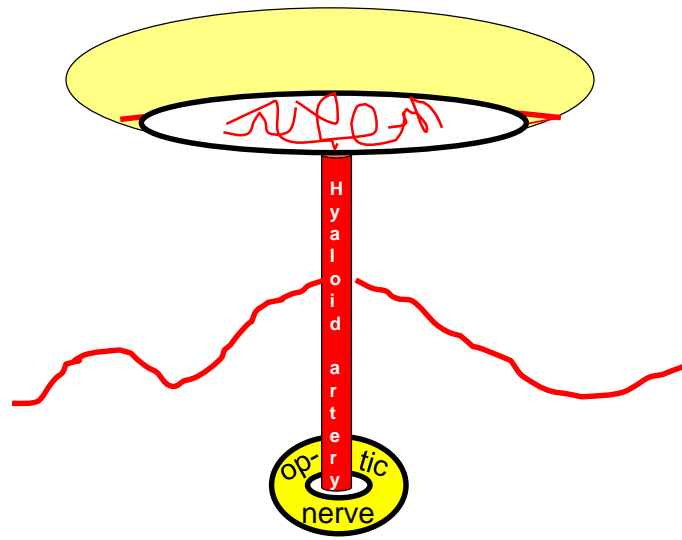
A **white**, **vascularized** retrolental membrane

Three other classic manifestations of severe anterior PFV:

--The eye is...[size]

--The lens is...

--The anterior chamber is...



Persistent Fetal Vasculature



What is the main manifestation of severe anterior PFV?

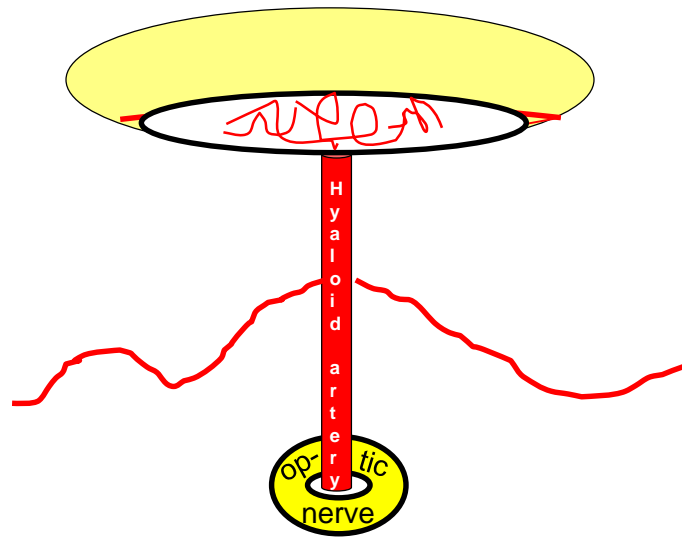
A **white**, **vascularized** retrolental membrane

Three other classic manifestations of severe anterior PFV:

--The eye is...**microphthalmic**

--The lens is...

--The anterior chamber is...



Persistent Fetal Vasculature



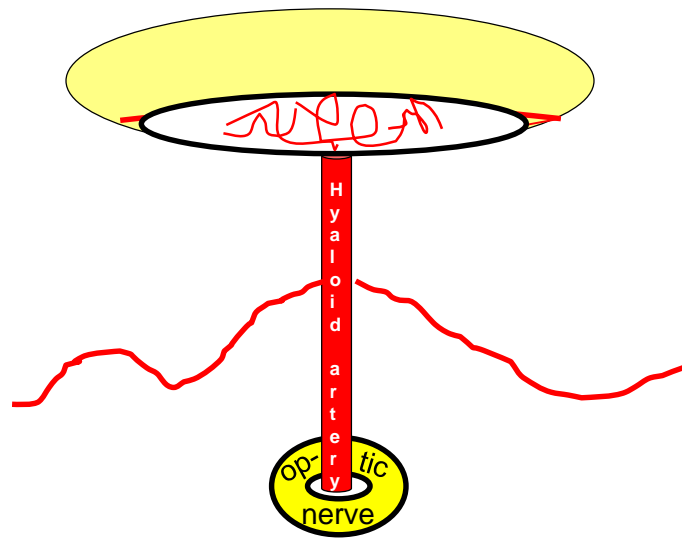
What is the main manifestation of severe anterior PFV?

A **white**, vascularized retrolental membrane

Three other classic manifestations

- The eye is **microphthalmic**
- The lens is...
- The anterior chamber is...

How prevalent is microphthalmia in severe anterior PFV?



Persistent Fetal Vasculature



What is the main manifestation of severe anterior PFV?

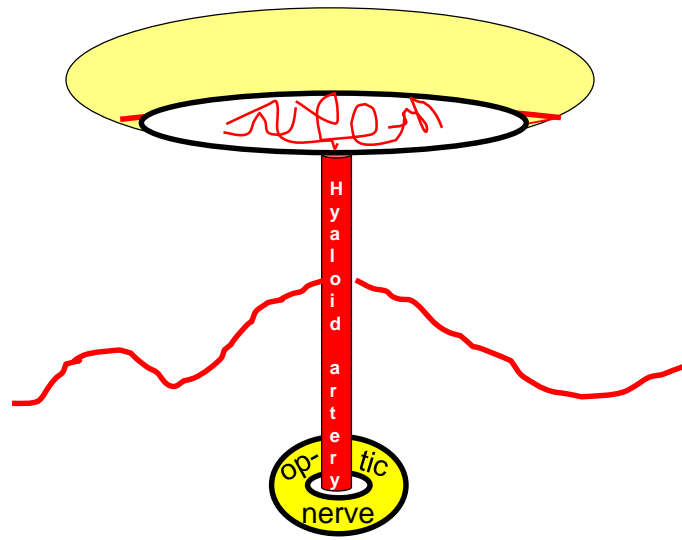
A **white**, vascularized retrolental membrane


Three other classic manifestations

- The eye is. **microphthalmic**
- The lens is...
- The anterior chamber is...

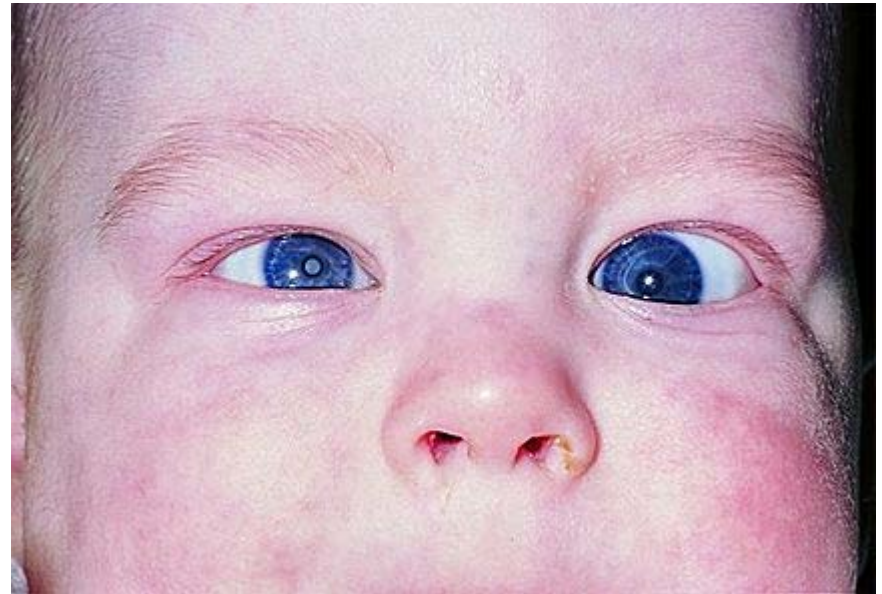How prevalent is microphthalmia in severe anterior PFV?

Very. In fact, if an eye with apparent PFV isn't microphthalmic, you should question the diagnosis.





Persistent Fetal Vasculature



PFV: Microphthalmia

Persistent Fetal Vasculature

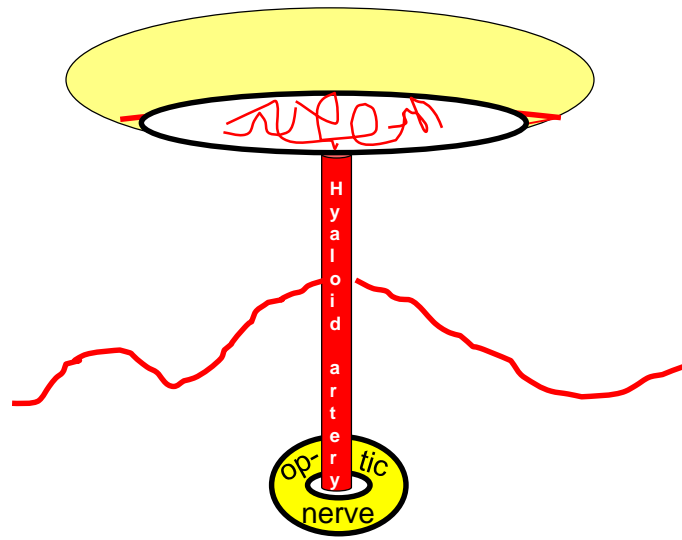


What is the main manifestation of severe anterior PFV?

A **white**, **vascularized** retrolental membrane

Three other classic manifestations of severe anterior PFV:

- The eye is...**microphthalmic**
- The lens is...[two key attributes]
- The anterior chamber is...



Persistent Fetal Vasculature



What is the main manifestation of severe anterior PFV?

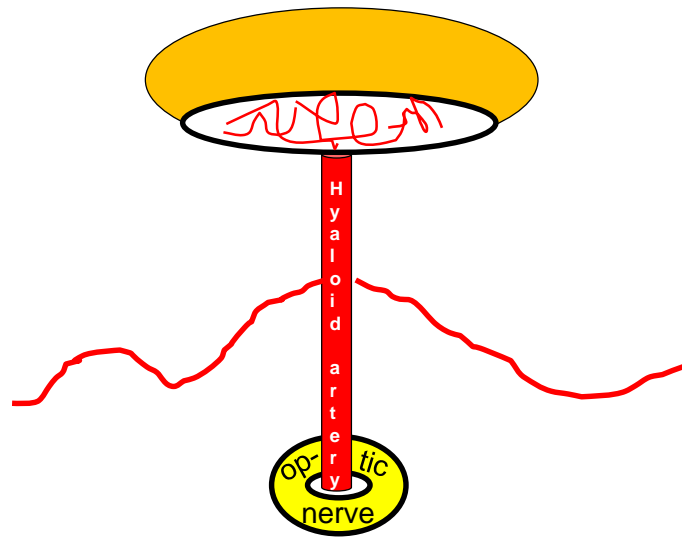
A **white**, **vascularized** retrolental membrane

Three other classic manifestations of severe anterior PFV:

--The eye is...**microphthalmic**

--The lens is...**small** and **cataractous**

--The anterior chamber is...



Persistent Fetal Vasculature



What is the main manifestation of severe anterior PFV?

A **white**, vascularized retrolental membrane

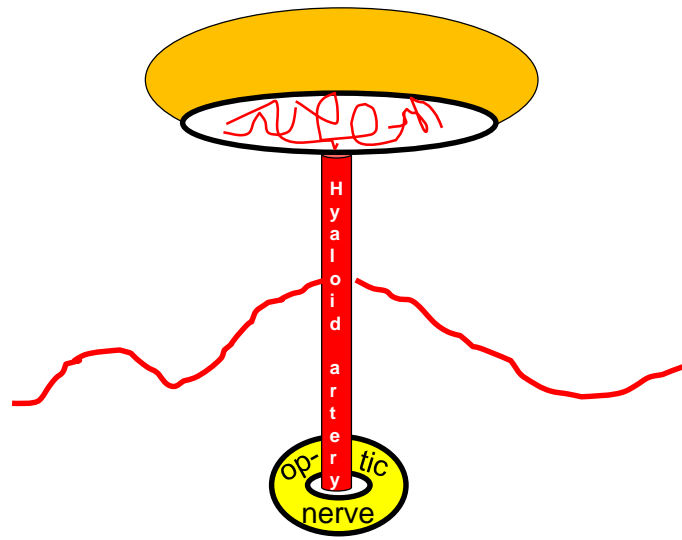
Three other classic manifestations of severe anterior PFV:

--The eye is...**microphthalmic**

--The lens is...**small** and **cataractous**

--The anterior chamber is...

Where does anterior PFV rank as a cause of unilateral cataract in kids?



Persistent Fetal Vasculature



What is the main manifestation of severe anterior PFV?

A **white**, vascularized retrolental membrane

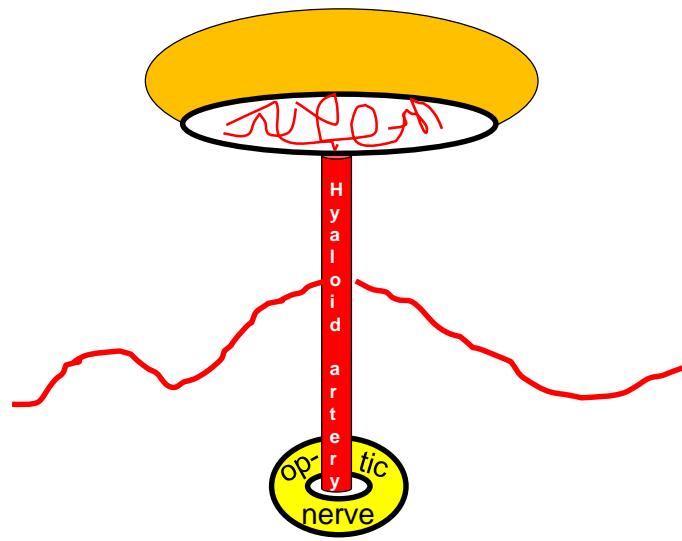
Three other classic manifestations of severe anterior PFV:

--The eye is...**microphthalmic**

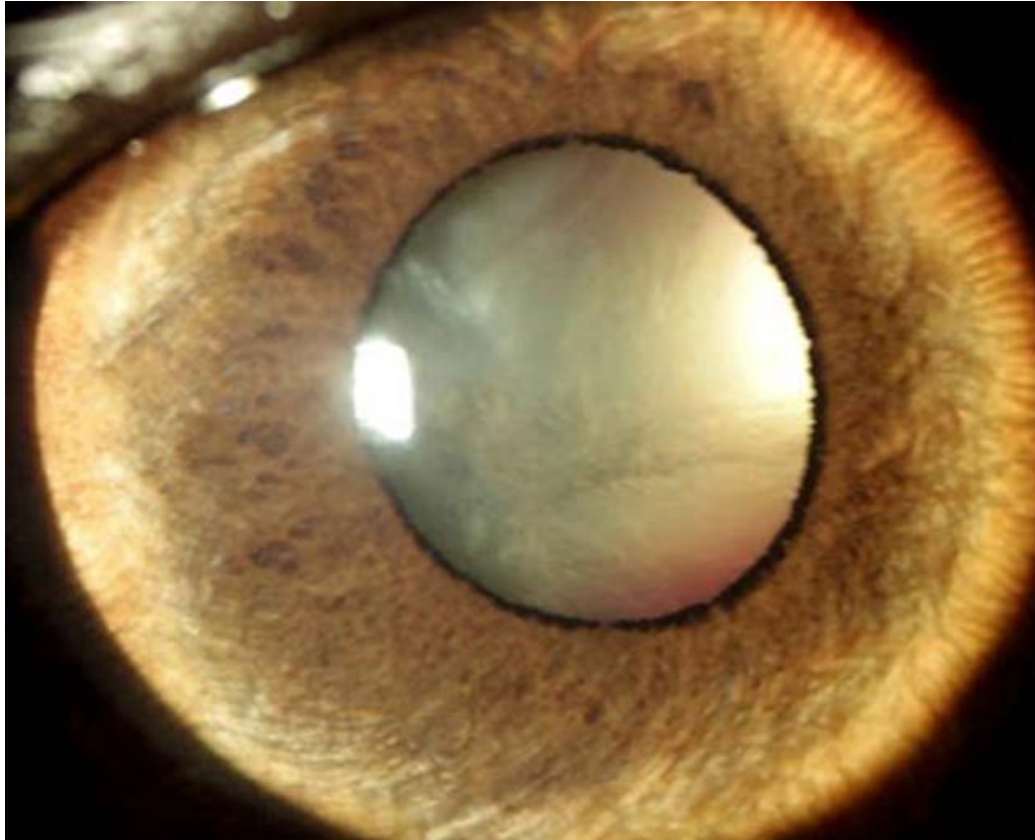

--The lens is...**small and cataractous**

--The anterior chamber is...

Where does anterior PFV rank as a cause of unilateral cataract in kids?
#1



Persistent Fetal Vasculature



PFV: Cataract

Persistent Fetal Vasculature

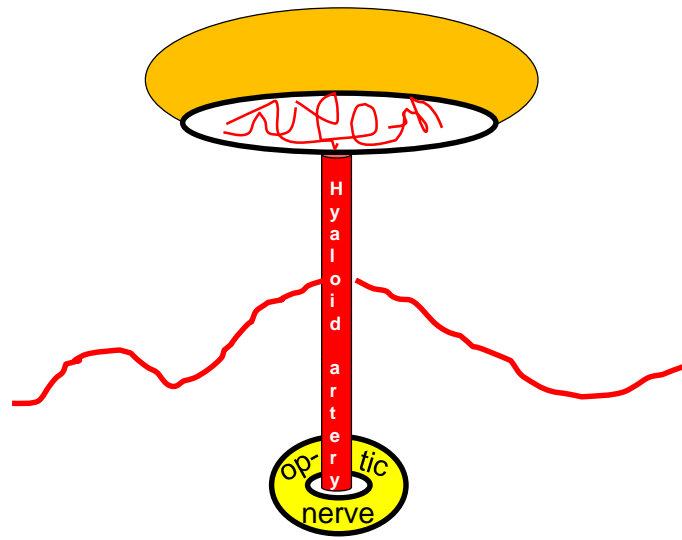


What is the main manifestation of severe anterior PFV?

A **white**, **vascularized** retrolental membrane

Three other classic manifestations of severe anterior PFV:

- The eye is...**microphthalmic**
- The lens is...**small** and **cataractous**
- The anterior chamber is...[ominous status]



Persistent Fetal Vasculature

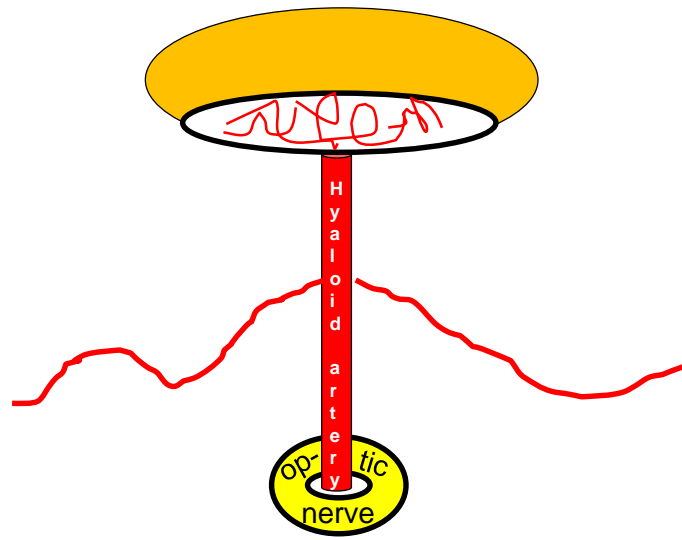



What is the main manifestation of severe anterior PFV?

A **white**, **vascularized** retrolental membrane

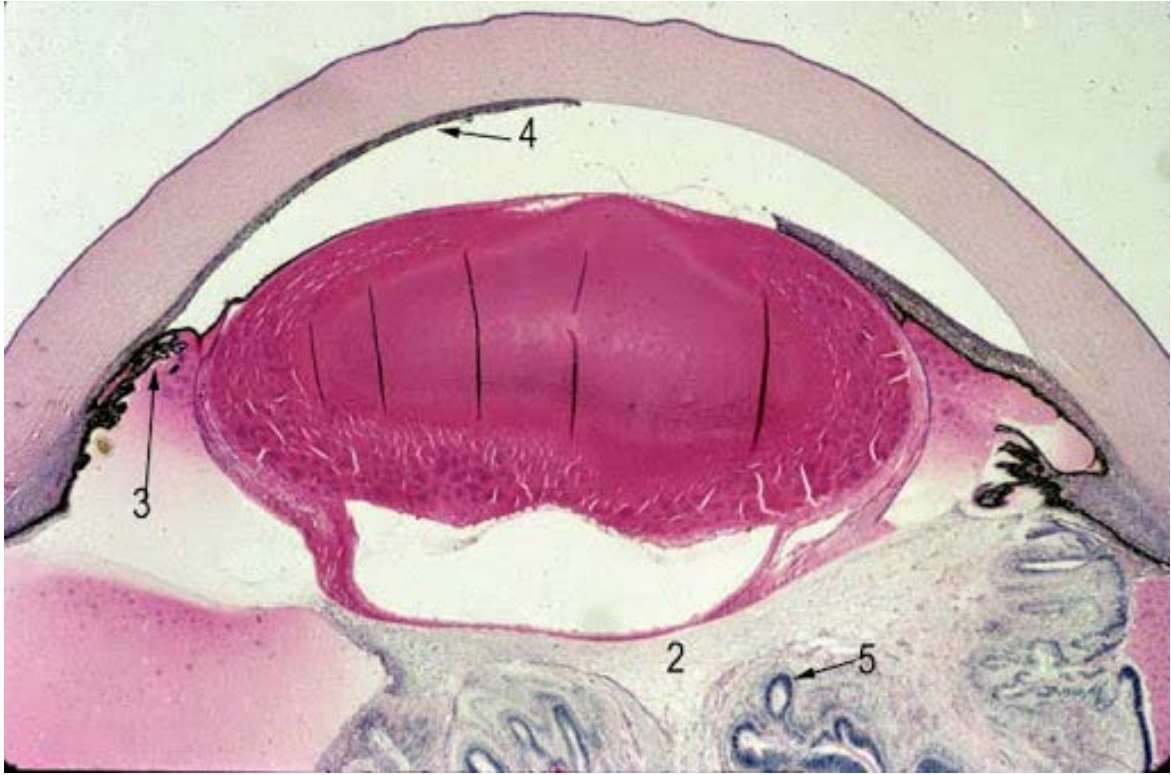
Three other classic manifestations of severe anterior PFV:

- The eye is...**microphthalmic**
- The lens is...**small** and **cataractous**
- The anterior chamber is...**shallow**





Persistent Fetal Vasculature



PFV: Shallow AC

Persistent Fetal Vasculature



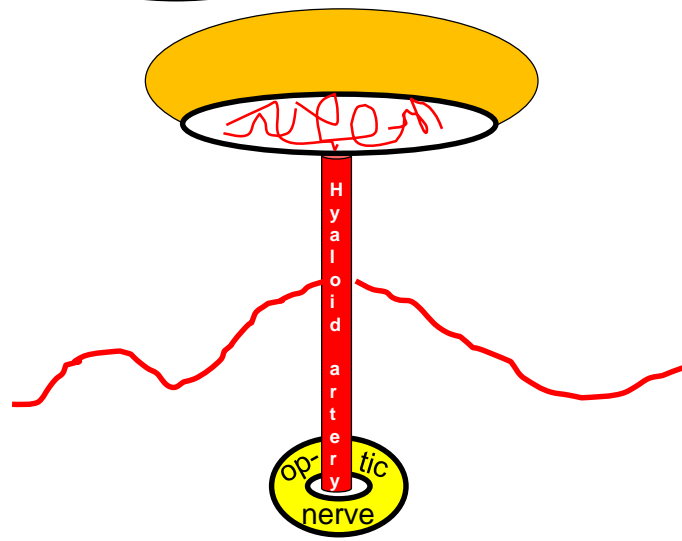
What is the main manifestation of severe anterior PFV?

A **white**, vascularized retrolental membrane

Why refer to the shallow-ness of the anterior chamber as 'ominous'?

--The lens is...small and cataractous

--The anterior chamber is...**shallow**



Persistent Fetal Vasculature



What is the main manifestation of severe anterior PFV?

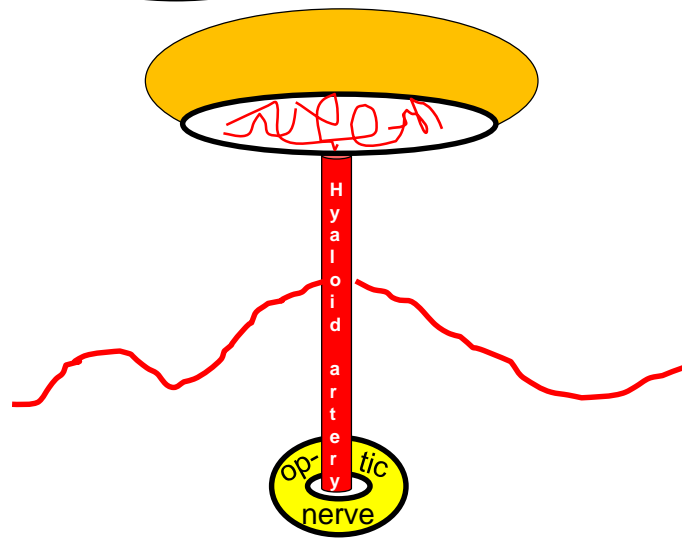
A **white**, vascularized retrolental membrane

Why refer to the shallow-ness of the anterior chamber as 'ominous'?

-- Because it places the eye at significant risk for angle-closure glaucoma

--The lens is...small and cataractous

--The anterior chamber is...**shallow**



Persistent Fetal Vasculature



What is the main manifestation of severe anterior PFV?

A **white**, **vascularized** retrolental membrane

Three other classic manifestations of severe anterior PFV:

- The eye is...**microphthalmic**
- The lens is...**small** and **cataractous**
- The anterior chamber is...**shallow**

What is the natural hx of severe anterior PFV?

Persistent Fetal Vasculature



What is the main manifestation of severe anterior PFV?

A **white**, **vascularized** retrolental membrane

Three other classic manifestations of severe anterior PFV:

- The eye is...**microphthalmic**
- The lens is...**small** and **cataractous**
- The anterior chamber is...**shallow**

What is the natural hx of severe anterior PFV?

Relentless progression of the [redacted] and [redacted], resulting in [redacted] and [redacted]

Persistent Fetal Vasculature



What is the main manifestation of severe anterior PFV?

A **white**, vascularized retrolental membrane

Three other classic manifestations of severe anterior PFV:

--The eye is...**microphthalmic**

--The lens is...**small** and **cataractous**

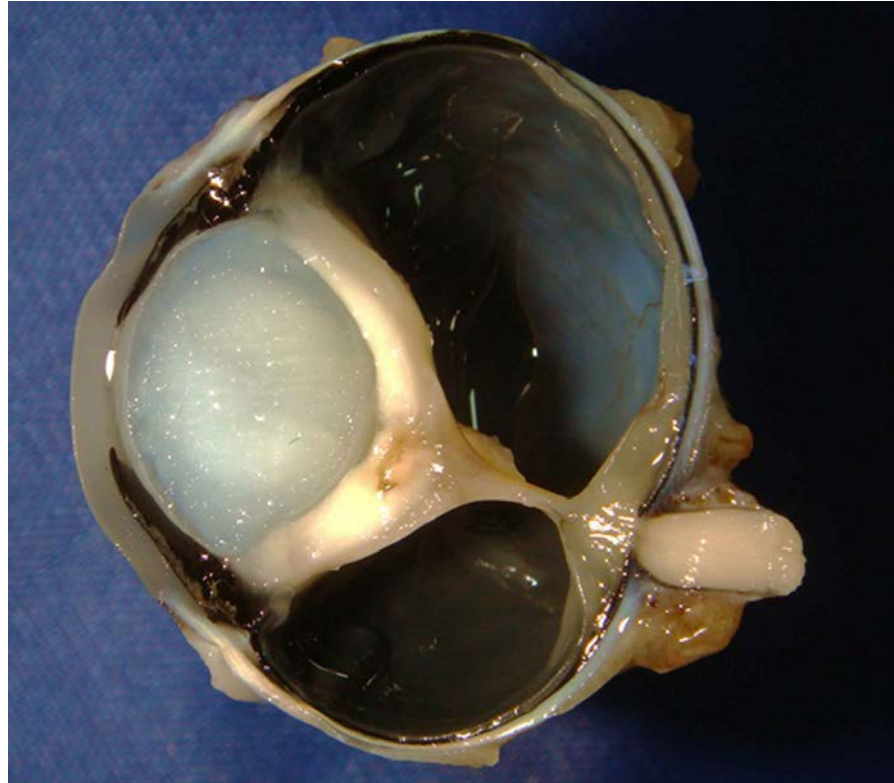--The anterior chamber is...**shallow**

What is the natural hx of severe anterior PFV?

Relentless progression of the cataract and AC shallowing , resulting in blindness and glaucoma



Persistent Fetal Vasculature



PFV: Note the advanced cataract and severely shallow AC. (Note also the thick white retrolental membrane, and the persistent hyaloid artery)

Persistent Fetal Vasculature



What is the main manifestation of severe anterior PFV?

A **white**, vascularized retrolental membrane

Three other classic manifestations of severe anterior PFV:

--The eye is...**microphthalmic**

--The lens is...**small** and **cataractous**

--The anterior chamber is...**shallow**

What is the natural hx of severe anterior PFV?

Relentless progression of the cataract and AC shallowing , resulting in blindness and glaucoma

Is severe PFV amenable to surgical intervention?

Persistent Fetal Vasculature



What is the main manifestation of severe anterior PFV?

A **white**, vascularized retrolental membrane

Three other classic manifestations of severe anterior PFV:

--The eye is...**microphthalmic**

--The lens is...**small** and **cataractous**

--The anterior chamber is...**shallow**

What is the natural hx of severe anterior PFV?

Relentless progression of the cataract and AC shallowing, resulting in blindness and glaucoma

Is severe PFV amenable to surgical intervention?

Yes. The cataract and retrolental membrane can be removed, and this usually precludes development of secondary glaucoma. However, the post-op course is fraught, and the visual prognosis guarded.

At what age does severe anterior PFV present?



Mild 'dz'

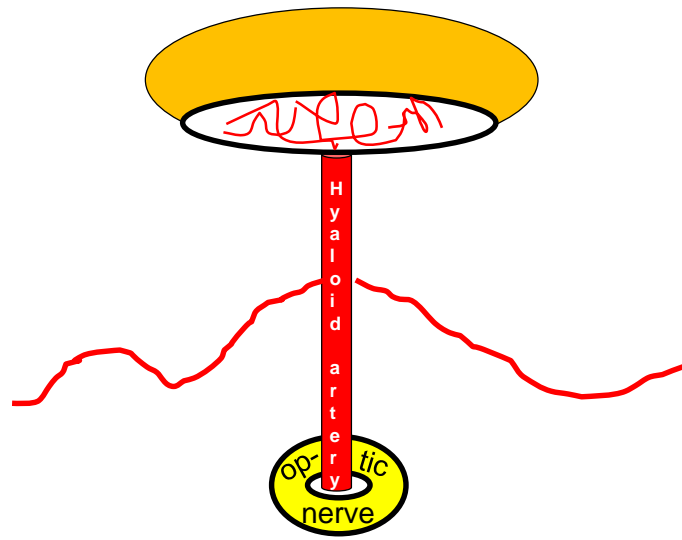
Severe dz

What is the main manifestation of severe anterior PFV?


A **white**, vascularized retrolental membrane

Three other classic manifestations of severe anterior PFV:

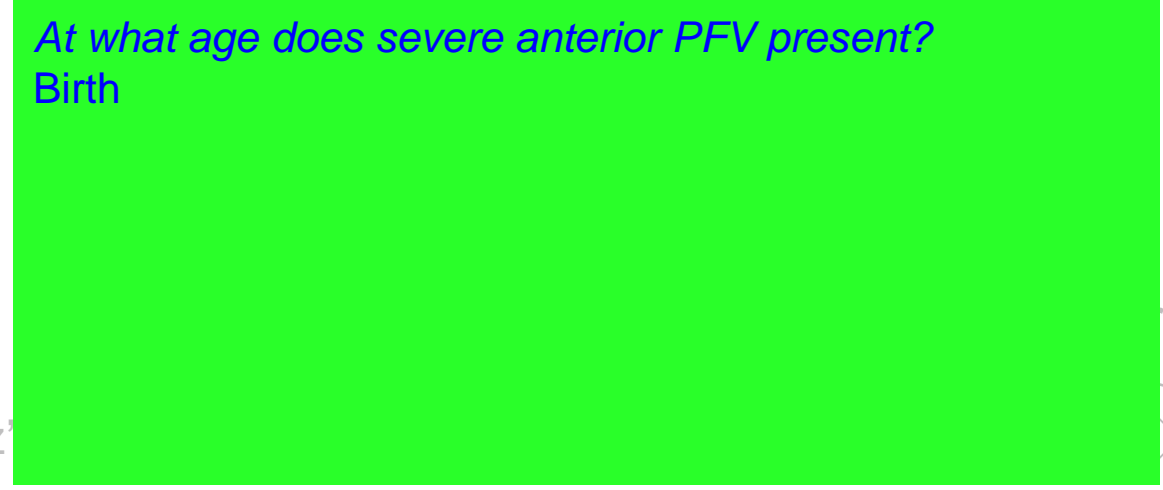
- The eye is...**microphthalmic**
- The lens is...**small** and **cataractous**
- The anterior chamber is...**shallow**



At what age does severe anterior PFV present?
Birth



Mild 'dz'



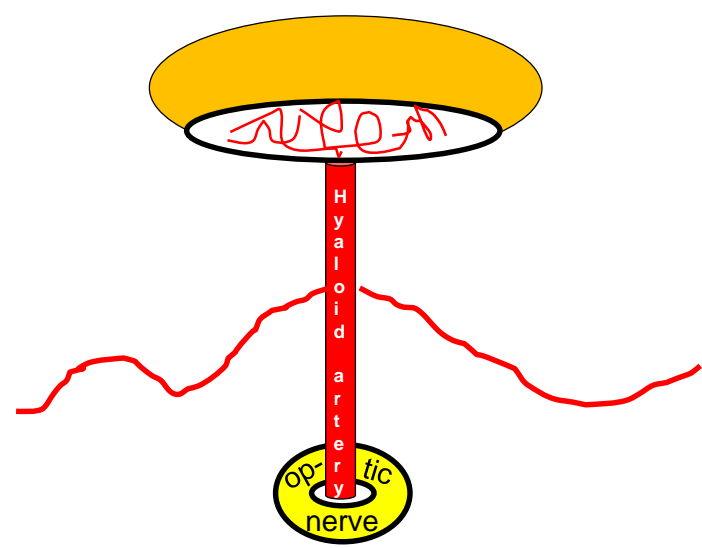
Severe dz

What is the main manifestation of severe anterior PFV?

A **white**, vascularized retrolental membrane

Three other classic manifestations of severe anterior PFV:

- The eye is...**microphthalmic**
- The lens is...**small** and **cataractous**
- The anterior chamber is...**shallow**



At what age does severe anterior PFV present?

Birth

What is the classic clinical finding that alerts the pediatrician to the presence of a significant ocular issue?



Mild 'dz'

Severe dz

What is the main manifestation of severe anterior PFV?

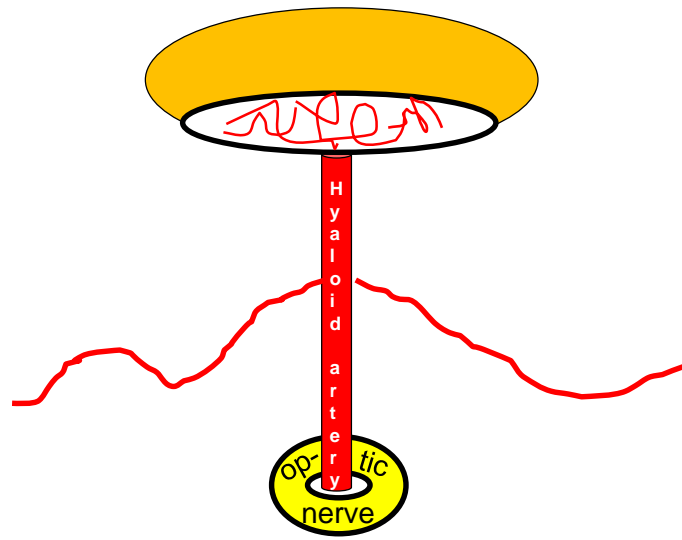
A **white**, vascularized retrolental membrane


Three other classic manifestations of severe anterior PFV:

--The eye is...**microphthalmic**

--The lens is...**small** and **cataractous**

--The anterior chamber is...**shallow**





At what age does severe anterior PFV present?

Birth

What is the classic clinical finding that alerts the pediatrician to the presence of a significant ocular issue?

Leukocoria. Anterior PFV is very high on the DDX for it.

Mild 'dz'

Severe dz

What is the main manifestation of severe anterior PFV?

white

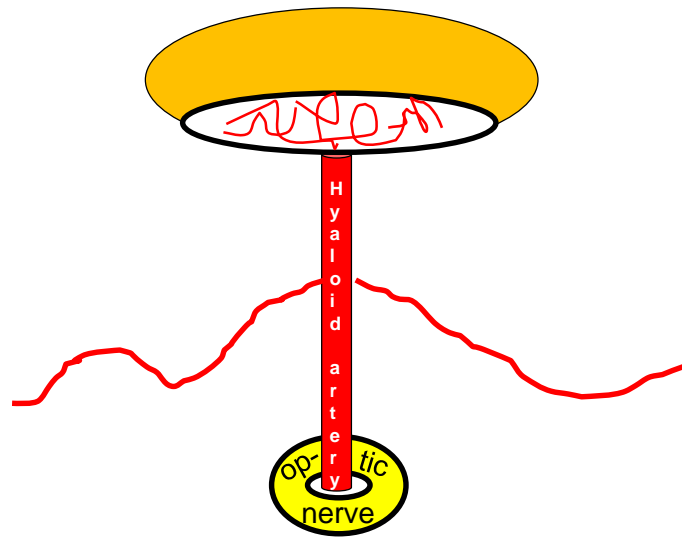
vascularized retrolental membrane

Three other classic manifestations of severe anterior PFV:

--The eye is...**microphthalmic**

--The lens is...**small** and **cataractous**

--The anterior chamber is...**shallow**





At what age does severe anterior PFV present?

Birth

What is the classic clinical finding that alerts the pediatrician to the presence of a significant ocular issue?

Leukocoria. Anterior PFV is very high on the DDx for it.

What is the most feared dx on the leukocoria DDx?

Mild 'dz'

Severe dz

What is the main manifestation of severe anterior PFV?

white

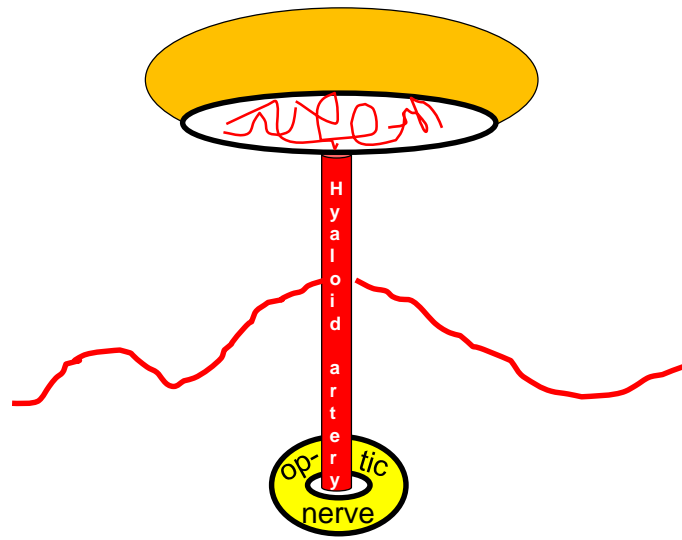
vascularized retrolental membrane

Three other classic manifestations of severe anterior PFV:

--The eye is...**microphthalmic**

--The lens is...**small** and **cataractous**

--The anterior chamber is...**shallow**





At what age does severe anterior PFV present?

Birth

What is the classic clinical finding that alerts the pediatrician to the presence of a significant ocular issue?

Leukocoria. Anterior PFV is very high on the DDX for it.

What is the most feared dx on the leukocoria DDX?

Retinoblastoma (Rb)

Mild 'dz'

Severe dz

What is the main manifestation of severe anterior PFV?

white

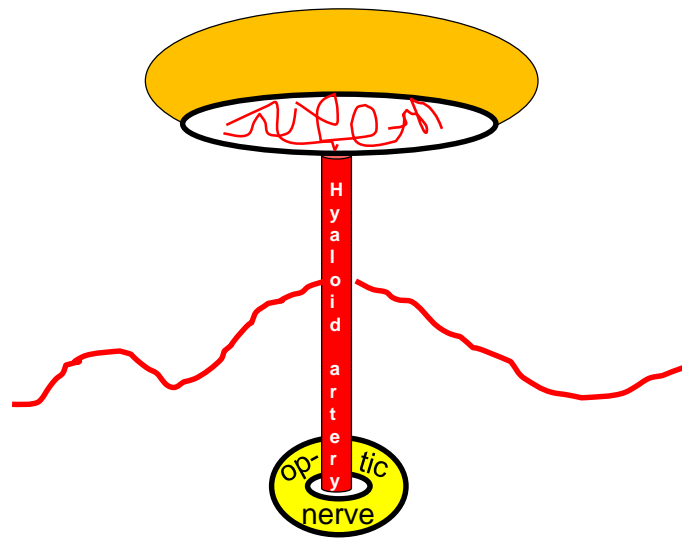
vascularized retrolental membrane

Three other classic manifestations of severe anterior PFV:

--The eye is...**microphthalmic**

--The lens is...**small** and **cataractous**

--The anterior chamber is...**shallow**



At what age does **severe anterior PFV** present?

Birth

It's crucial that you be able to distinguish between anterior PFV and Rb, both in the clinic and on the OKAP/Boards. So let's see how Rb stacks up against what we've learned about anterior PFV.

What is the most feared dx on the leukocoria DDX?

Mild 'dz

Retinoblastoma (Rb)

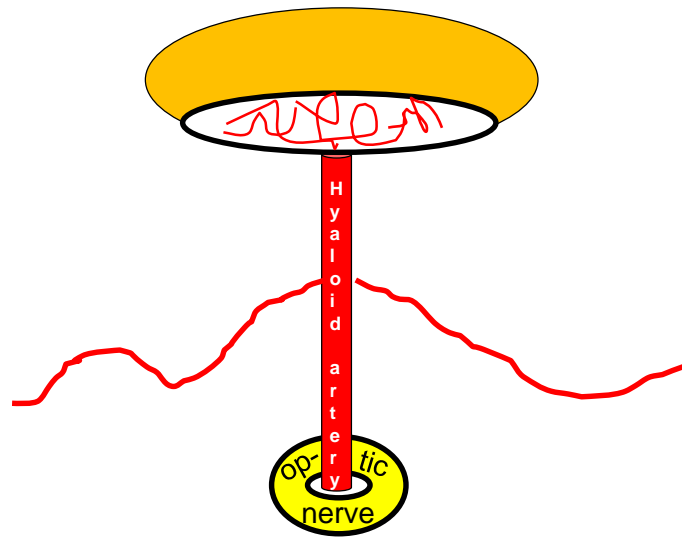
Severe dz


What is the main manifestation of severe anterior PFV?

A **white**, vascularized retrolental membrane

Three other classic manifestations of severe anterior PFV:

- The eye is...**microphthalmic**
- The lens is...**small** and **cataractous**
- The anterior chamber is...**shallow**





At what age does severe anterior PFV present?

Birth

What is the classic clinical finding that alerts the pediatrician to the presence of a significant ocular issue?

Leukocoria. Anterior PFV is very high on the DDX for it.

What is the most feared dx on the leukocoria DDX?

Mild 'dz

Retinoblastoma (Rb)

Severe dz

Does Rb present with leukocoria at birth?

What is the main manifestation of severe anterior PFV?

A **white**, vascularized **retrolental membrane**


Three other classic manifestations of severe anterior PFV:

--The eye is...**microphthalmic**

--The lens is...**small** and **cataractous**

--The anterior chamber is...**shallow**





At what age does severe anterior PFV present?

Birth

What is the classic clinical finding that alerts the pediatrician to the presence of a significant ocular issue?

Leukocoria. Anterior PFV is very high on the DDX for it.

What is the most feared dx on the leukocoria DDX?

Mild 'dz

Retinoblastoma (Rb)

Severe dz

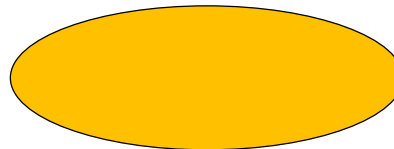
Does Rb present with leukocoria at birth? No


What is the main manifestation of severe anterior PFV?

~~A **white**, vascularized, retroental membrane~~

Three other classic manifestations of severe anterior PFV:

- The eye is...**microphthalmic**
- The lens is...**small** and **cataractous**
- The anterior chamber is...**shallow**





At what age does severe anterior PFV present?

Birth

What is the classic clinical finding that alerts the pediatrician to the presence of a significant ocular issue?
Leukocoria. Anterior PFV is very high on the DDX for it.

What is the most feared dx on the leukocoria DDX?

Mild 'dz

Retinoblastoma (Rb)

Severe dz

Does Rb present with leukocoria at birth? **No**

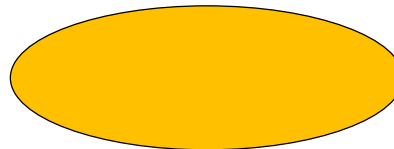
What is the main manifestation of severe anterior PFV?

A **white** vascularized retrolental

Does this mean Rb can't be present at birth?

Three other classic manifestations of severe anterior PFV:

- The eye is...**microphthalmic**
- The lens is...**small** and **cataractous**
- The anterior chamber is...**shallow**





At what age does severe anterior PFV present?

Birth

What is the classic clinical finding that alerts the pediatrician to the presence of a significant ocular issue?
Leukocoria. Anterior PFV is very high on the DDx for it.

What is the most feared dx on the leukocoria DDx?

Retinoblastoma (Rb)

Does Rb present with leukocoria at birth? **No**

What is the main manifestation of severe anterior PFV?


A **white** vascularized retrolental mass

Does this mean Rb can't be present at birth?

Oh no, it mos def can. It just isn't **obvious**, ie, it isn't causing leukocoria (or any other outward sign).

Three other classic manifestations of severe anterior PFV:

- The eye is...**microphthalmic**
- The lens is...**small** and **cataractous**
- The anterior chamber is...**shallow**





At what age does severe anterior PFV present?

Birth

What is the classic clinical finding that alerts the pediatrician to the presence of a significant ocular issue?

Leukocoria. Anterior PFV is very high on the DDX for it.

What is the most feared dx on the leukocoria DDX?

Mild 'dz

Retinoblastoma (Rb)

Severe dz

Does Rb present with leukocoria at birth? **No**

What is the main manifestation of severe anterior PFV?

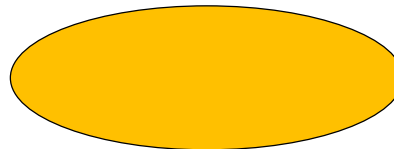
~~A white vascularized retrolental membrane~~

Three other classic manifestations Are Rb eyes microphthalmic?

--The eye is...**microphthalmic?**

--The lens is...**small** and **cataractous**

--The anterior chamber is...**shallow**





At what age does severe anterior PFV present?

Birth

What is the classic clinical finding that alerts the pediatrician to the presence of a significant ocular issue?
Leukocoria. Anterior PFV is very high on the DDX for it.

What is the most feared dx on the leukocoria DDX?

Mild 'dz

Retinoblastoma (Rb)

Severe dz

Does Rb present with leukocoria at birth? **No**

What is the main manifestation of severe anterior PFV?

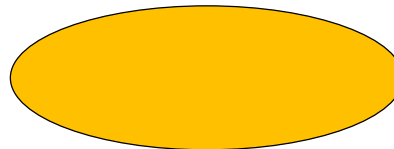
~~A **white**, vascularized, retroretinal membrane~~


Three other classic manifestations **Are Rb eyes microphthalmic? No**

~~--The eye is... **microphthalmic**~~

--The lens is... **small** and **cataractous**

--The anterior chamber is... **shallow**





At what age does severe anterior PFV present?

Birth

What is the classic clinical finding that alerts the pediatrician to the presence of a significant ocular issue?
Leukocoria. Anterior PFV is very high on the DDX for it.

What is the most feared dx on the leukocoria DDX?

Mild 'dz

Retinoblastoma (Rb)

Severe dz

Does Rb present with leukocoria at birth? **No**

What is the main manifestation of severe anterior PFV?

~~A **white**, vascularized, retroretinal membrane~~

Three other classic manifestations


Are Rb eyes microphthalmic? **No**


~~--The eye is... **microphthalmic**~~

--The lens is... **small and cataractous?**

Do Rb eyes have small/ataractous lenses?

--The anterior chamber is... **shallow**





At what age does severe anterior PFV present?

Birth

What is the classic clinical finding that alerts the pediatrician to the presence of a significant ocular issue?
Leukocoria. Anterior PFV is very high on the DDX for it.

What is the most feared dx on the leukocoria DDX?

Mild 'dz

Retinoblastoma (Rb)

Severe dz

Does Rb present with leukocoria at birth? **No**

What is the main manifestation of severe anterior PFV?

~~A **white**, vascularized, retroretinal membrane~~

Three other classic manifestations

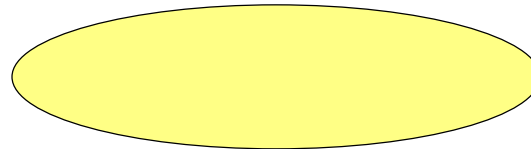
Are Rb eyes microphthalmic? **No**

--~~The eye is...microphthalmic~~

--~~The lens is...small and cataractous~~

Do Rb eyes have small/ataractous lenses? **No**

--The anterior chamber is...**shallow**





At what age does severe anterior PFV present?

Birth

What is the classic clinical finding that alerts the pediatrician to the presence of a significant ocular issue?
Leukocoria. Anterior PFV is very high on the DDx for it.

What is the most feared dx on the leukocoria DDx?

Mild 'dz

Retinoblastoma (Rb)

Severe dz

Does Rb present with leukocoria at birth? **No**

What is the main manifestation of severe anterior PFV?

~~A **white**, vascularized, retroretinal membrane~~

Three other classic manifestations

Are Rb eyes microphthalmic? **No**


~~--The eye is... **microphthalmic**~~


~~--The lens is... **small and cataractous**~~

Do Rb eyes have small/cataractous lenses? **No**

--The anterior chamber is... **shallow?**

Do Rb eyes have shallow ACs?





At what age does severe anterior PFV present?

Birth

What is the classic clinical finding that alerts the pediatrician to the presence of a significant ocular issue?

Leukocoria. Anterior PFV is very high on the DDx for it.

What is the most feared dx on the leukocoria DDx?

Retinoblastoma (Rb)

Does Rb present with leukocoria at birth? **No**

Mild 'dz

Severe dz

What is the main manifestation of severe anterior PFV?

~~A white, vascularized, retrorenal membrane~~

Are Rb eyes microphthalmic? **No**

Three other classic manifestatio


~~--The eye is...microphthalmic~~


~~--The lens is...small and cataractous~~

~~--The anterior chamber is...shallow~~

Do Rb eyes have small/cataractous lenses? **No**

Do Rb eyes have shallow ACs? **No**





At what age does severe anterior PFV present?

Birth

What is the classic clinical finding that alerts the pediatrician to the presence of a significant ocular issue?

	Anterior PFV	Rb
<i>Leukocoria at birth?</i>	Yes	No
<i>Microphthalmic?</i>	Yes	No
<i>Cataract present?</i>	Yes	No
<i>AC shallow?</i>	Yes	No

(Review slide—no question, proceed when ready)



At what age does severe anterior PFV present?

Birth

What is the classic clinical finding that alerts the pediatrician to the presence of a significant ocular issue?

	Anterior PFV	Rb
Mild		
What		
A wh		
Thre		
--Th		
--Th		
--The		
AC shallow?	Yes	No

Next, we will change gears and consider clinically significant posterior PFV

(Review slide—no question, proceed when ready)

Persistent Fetal Vasculature



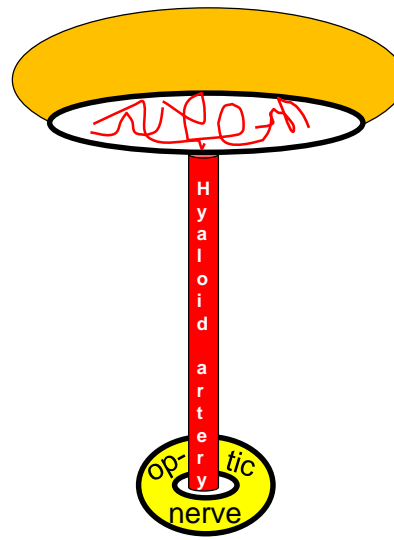
A **white**, vascularized retrolental membrane

In severe posterior PFV...

The eye is...microphthalmic

The lens is...small and cataractous

The anterior chamber is...shallow



Persistent Fetal Vasculature



A **white**, **vascularized** **retrolental** **membrane**?

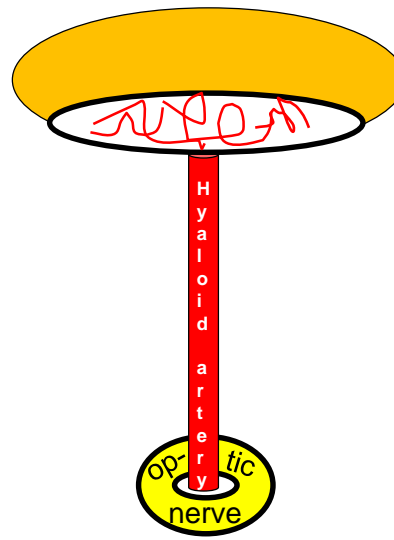
In severe posterior PFV...

Is a retrolental membrane present?

The eye is...microphthalmic

The lens is...small and cataractous

The anterior chamber is...shallow



Persistent Fetal Vasculature



~~A white vascularized retrolental membrane?~~

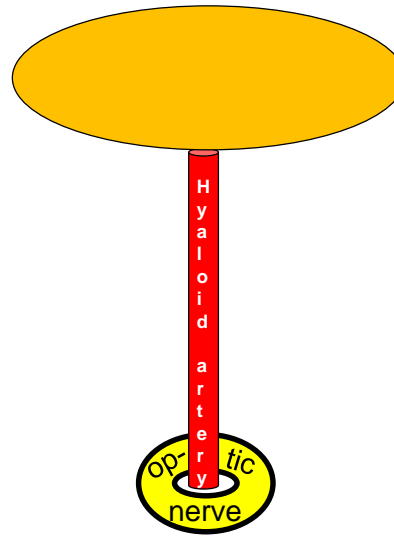
In severe posterior PFV...

*Is a retrolental membrane present? **No***

The eye is...microphthalmic

The lens is...small and cataractous

The anterior chamber is...shallow



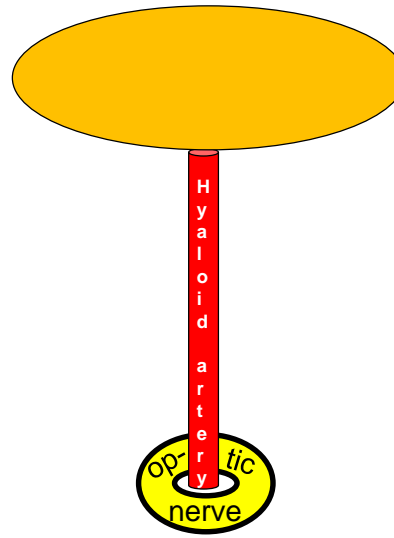
Persistent Fetal Vasculature




~~A white vascularized retrolental membrane?~~

*In severe posterior PFV...
Is the eye microphthalmic?*

*The eye is...microphthalmic?
The lens is...small and cataractous
The anterior chamber is...shallow*



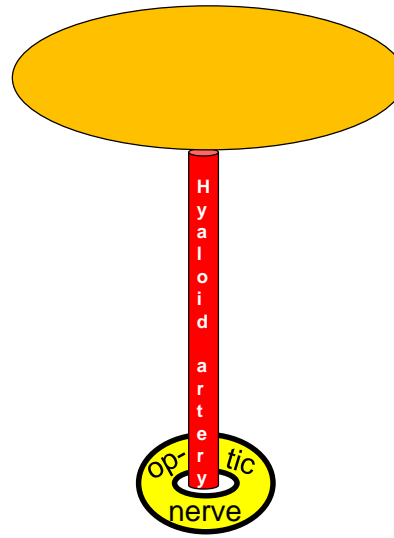
Persistent Fetal Vasculature



~~A white vascularized retrolental membrane?~~

*In severe posterior PFV...
Is the eye microphthalmic? Yes*

*The eye is...microphthalmic!
The lens is...small and cataractous
The anterior chamber is...shallow*



Persistent Fetal Vasculature



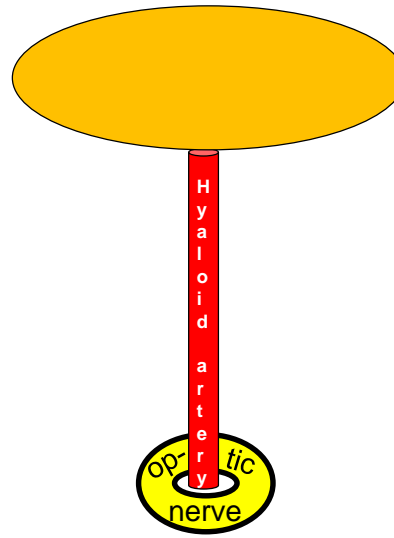
~~A white vascularized retrolental membrane?~~

*In severe posterior PFV...
Is the lens small/cataractous?*

The eye is...microphthalmic!

The lens is...small and cataractous?

The anterior chamber is...shallow



Persistent Fetal Vasculature



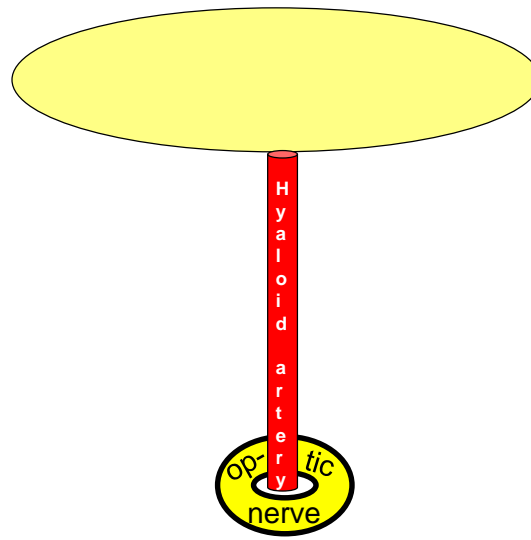
~~A white, vascularized, retrolental membrane?~~

*In severe posterior PFV...
Is the lens small/cataractous? No*

The eye is...microphthalmic!

~~The lens is...small and cataractous.~~

The anterior chamber is...shallow



Persistent Fetal Vasculature



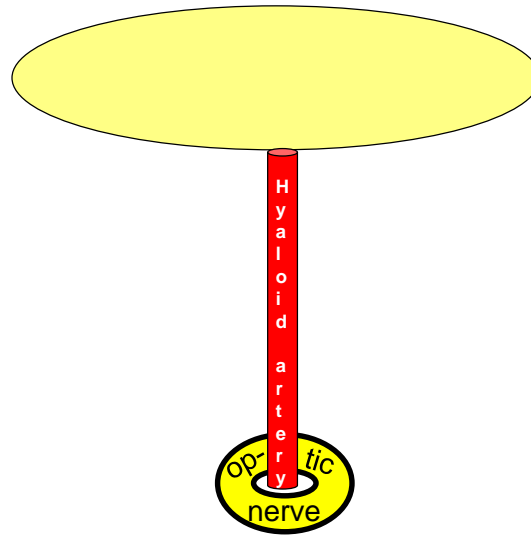
~~A white vascularized retrolental membrane?~~

*In severe posterior PFV...
Is the AC shallow?*

The eye is...microphthalmic!

~~*The lens is...small and cataractous.*~~

The anterior chamber is...shallow?



Persistent Fetal Vasculature



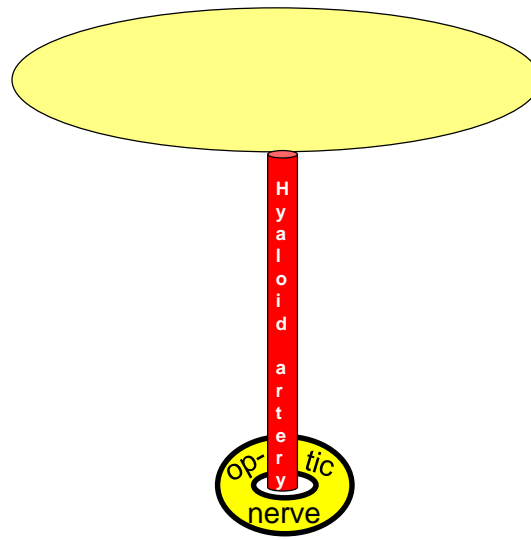
~~A **white** vascularized retrolental membrane?~~

*In severe posterior PFV...
Is the AC shallow? No*

The eye is...microphthalmic!

~~The lens is...small and cataractous.~~

~~The anterior chamber is...shallow.~~



Persistent Fetal Vasculature



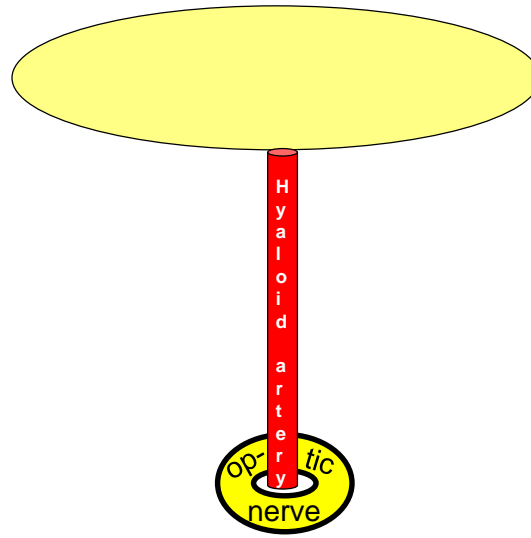
~~A **white** vascularized retrolental membrane?~~

What is the defining feature of severe posterior PFV?

The eye is...microphthalmic!

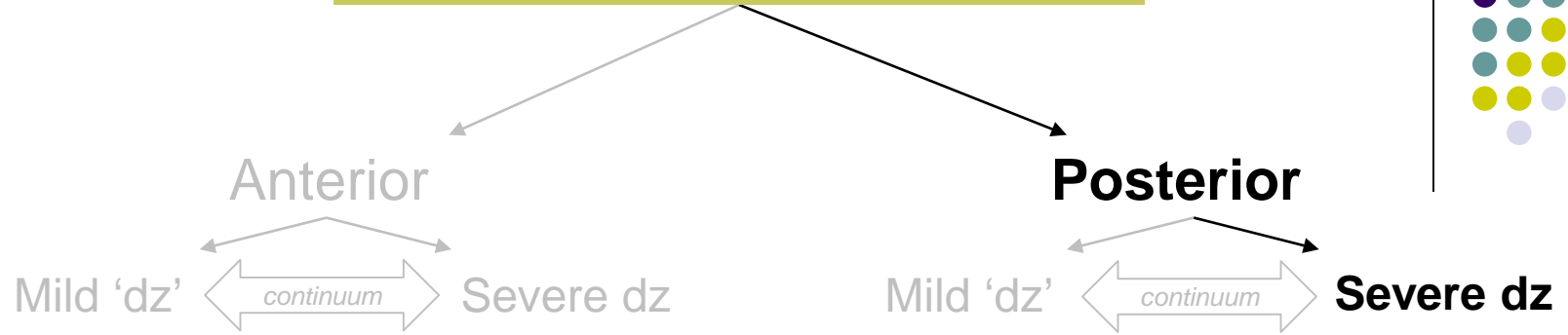~~The lens is...small and cataractous.~~

~~The anterior chamber is...shallow.~~





Persistent Fetal Vasculature



~~A white vascularized retrolental membrane?~~

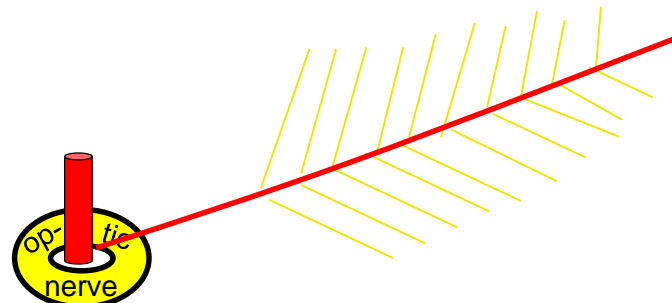
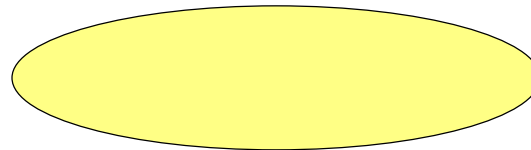
The eye is...microphthalmic!

~~The lens is...small and cataractous~~


~~The anterior chamber is...shallow~~

What is the defining feature of severe posterior PFV?
 Persistent hyaloid branches emanating from the ONH, running atop (and causing) a

two words



Persistent Fetal Vasculature



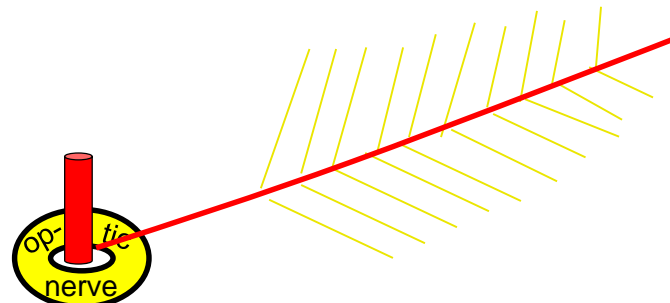
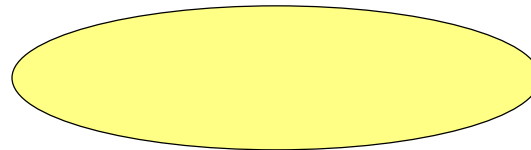
~~A white vascularized retrolental membrane?~~

What is the defining feature of severe posterior PFV?
 Persistent hyaloid branches emanating from the ONH,
 running atop (and causing) a retinal fold

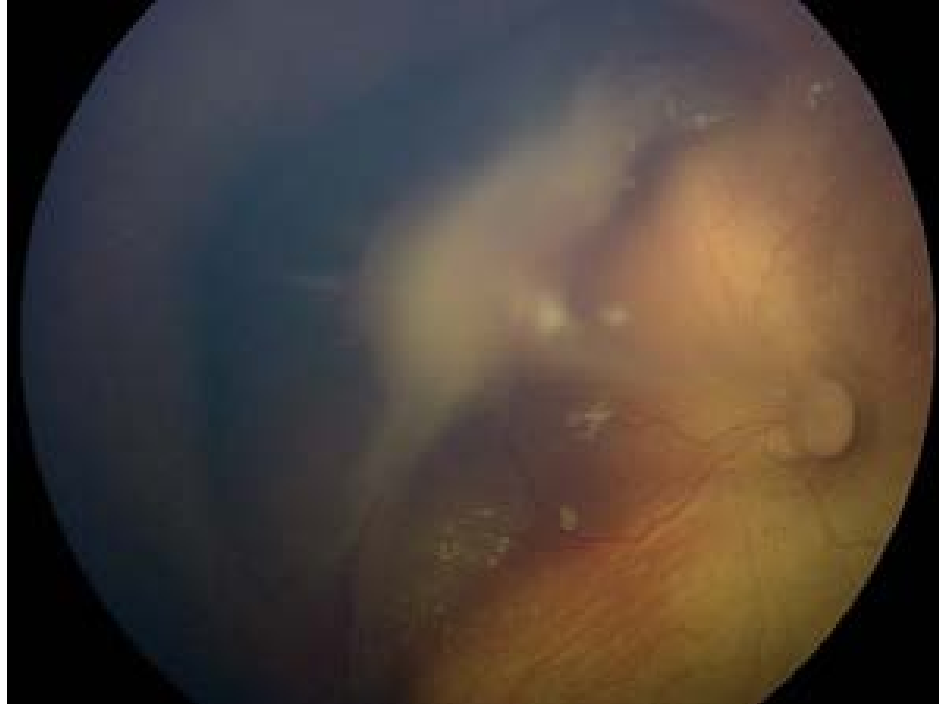

The eye is...microphthalmic!

~~The lens is...small and cataractous~~


~~The anterior chamber is...shallow~~



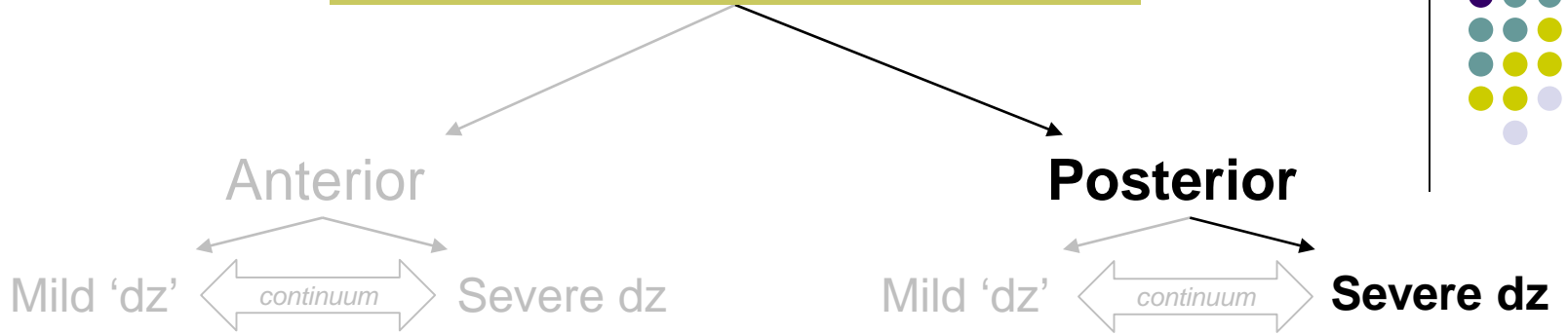Persistent Fetal Vasculature



Posterior PFV with a fibrovascular stalk



Persistent Fetal Vasculature



~~A white~~

What conditions top the DDx for posterior PFV?

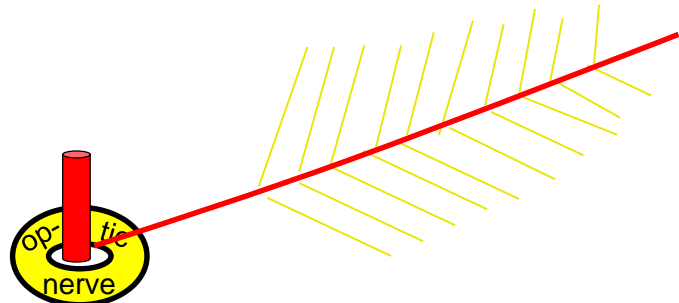
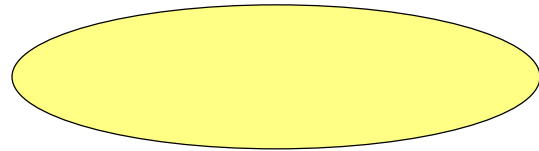
- ?
- ?
- ?

~~The eye is.~~

~~--The lens is~~

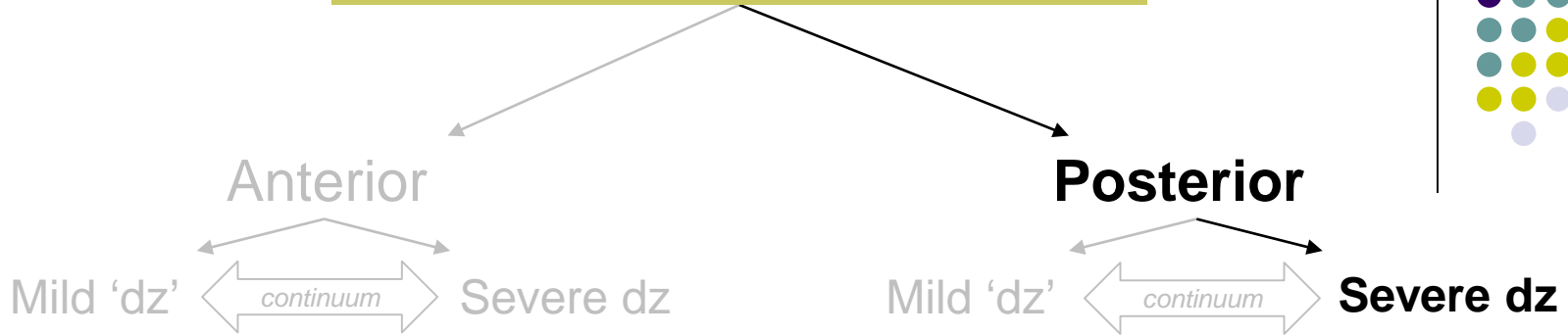~~The anterior chamber is...shallow.~~

ere **posterior PFV?**
 originating from the ONH,
 (using) a retinal fold





Persistent Fetal Vasculature



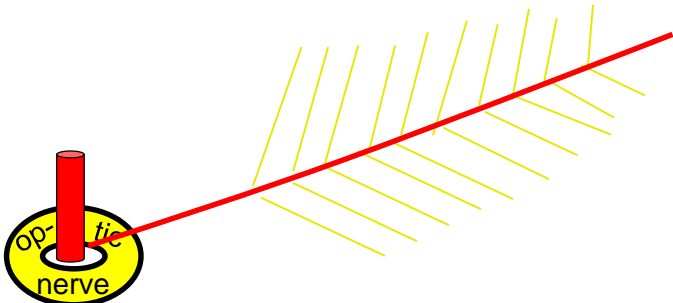
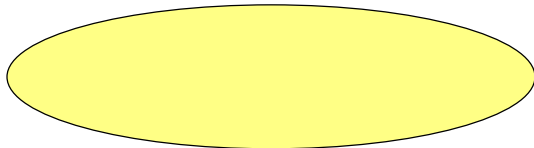
~~A white~~

What conditions top the DDx for posterior PFV?

- ROP
- FEVR
- Toxocariasis

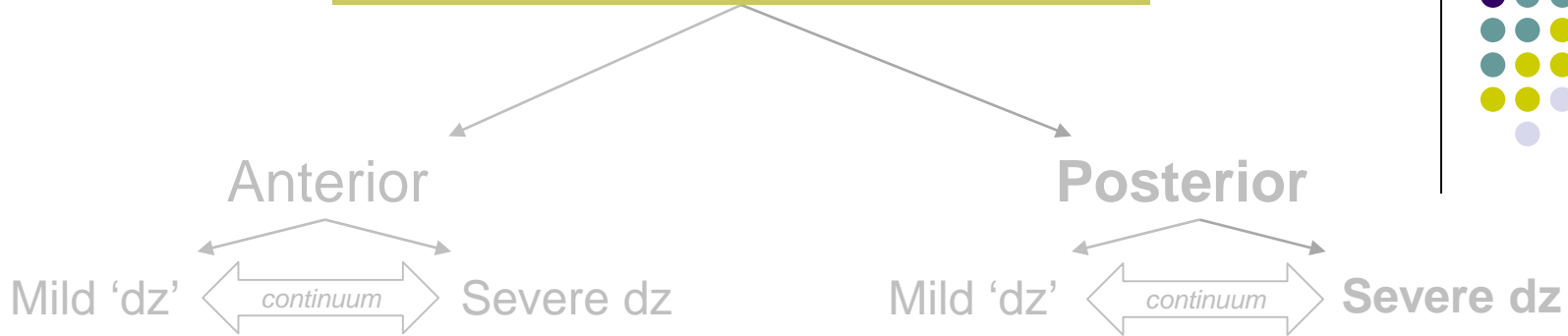~~The eye is.~~
~~--The lens is~~
~~The anterior chamber is...shallow.~~

ere **posterior PFV?**
 ating from the ONH,
 using) a retinal fold





Persistent Fetal Vasculature



~~A white~~

What conditions top the DDx for posterior PFV?
 --ROP
 --FEVR
 --Toxocariasis

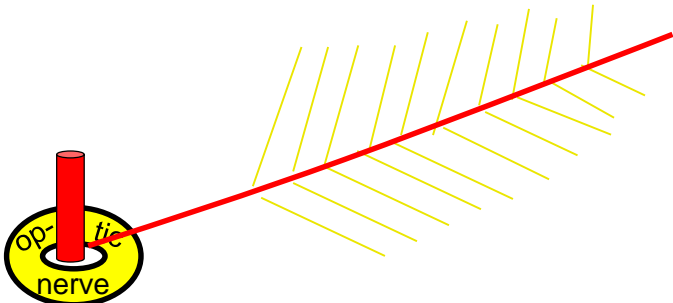
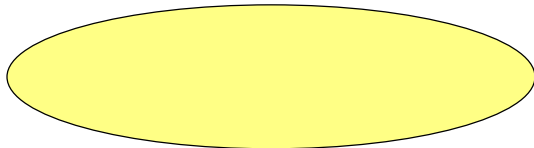
What does ROP stand for here?


~~The eye is.~~

~~--The lens is~~

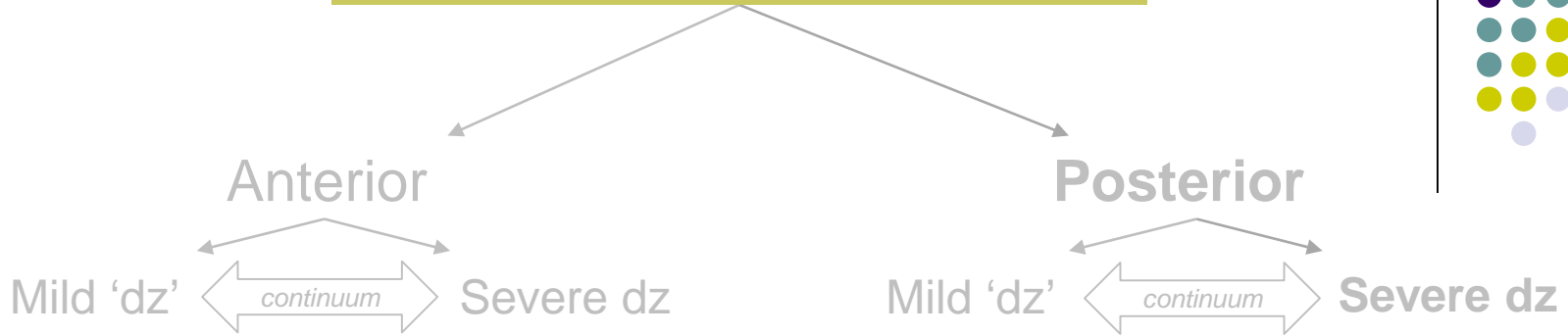~~The anterior chamber is...shallow.~~

ere posterior PFV?
 ating from the ONH,
 using) a retinal fold





Persistent Fetal Vasculature



~~A white~~

What conditions top the DDx for posterior PFV?

- ROP
- FEVR
- Toxocariasis

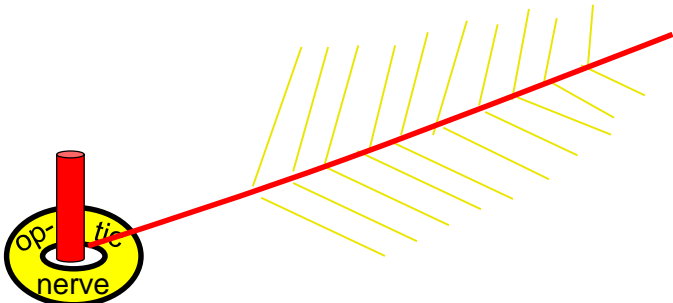
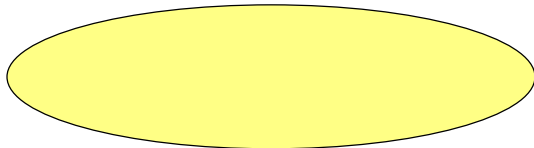
What does ROP stand for here?
 Retinopathy of prematurity (it has its own slide-set if you're interested)


~~The eye is.~~

~~--The lens is~~

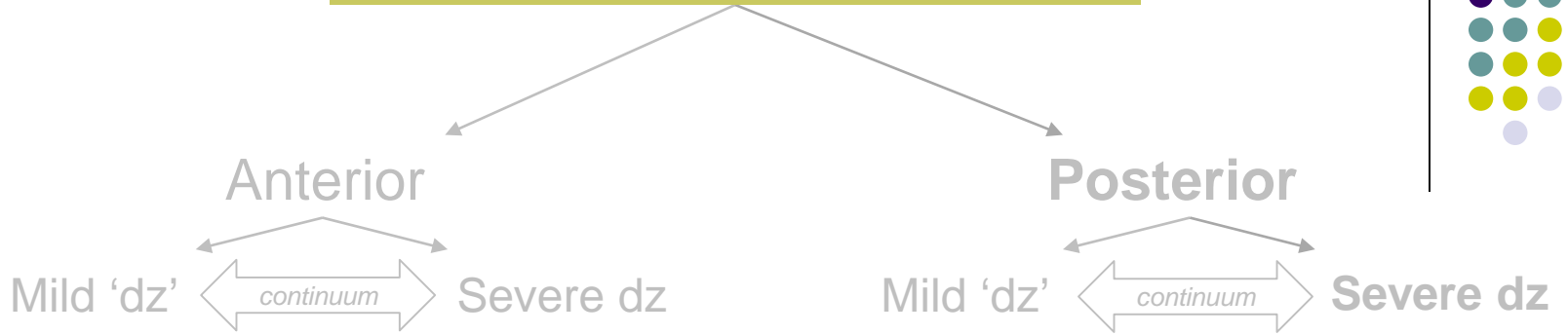
~~The anterior chamber is...shallow.~~

ere posterior PFV?
 ...ating from the ONH,
 ...using) a retinal fold





Persistent Fetal Vasculature



~~A white~~

What conditions top the DDx for posterior PFV?

- ROP
- FEVR**
- Toxocariasis

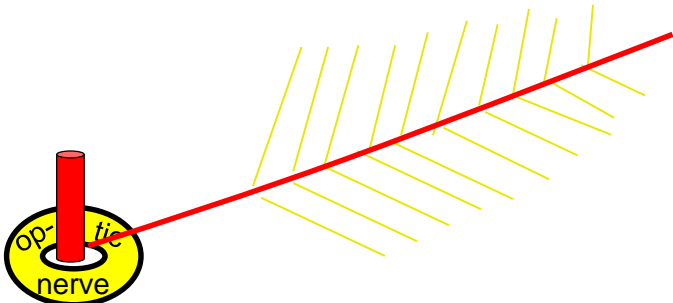
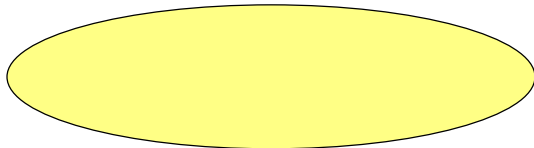
How about FEVR?

~~The eye is.~~

~~--The lens is~~

~~The anterior chamber is...shallow.~~

ere posterior PFV?
ating from the ONH,
(using) a retinal fold





Persistent Fetal Vasculature



~~A white~~

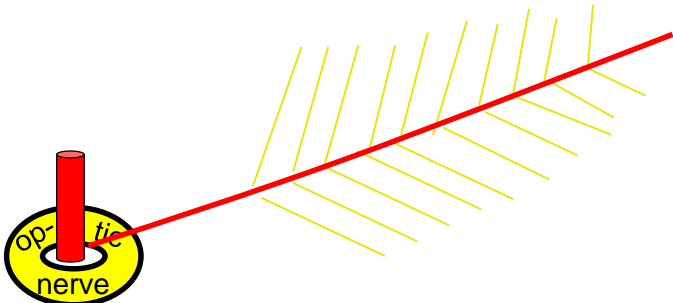
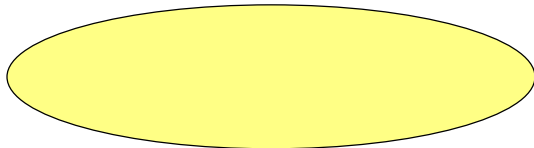
What conditions top the DDx for posterior PFV?


- ROP
- FEVR**
- Toxocariasis

How about FEVR?
 Familial exudative vitreoretinopathy (covered in slide-set R3)

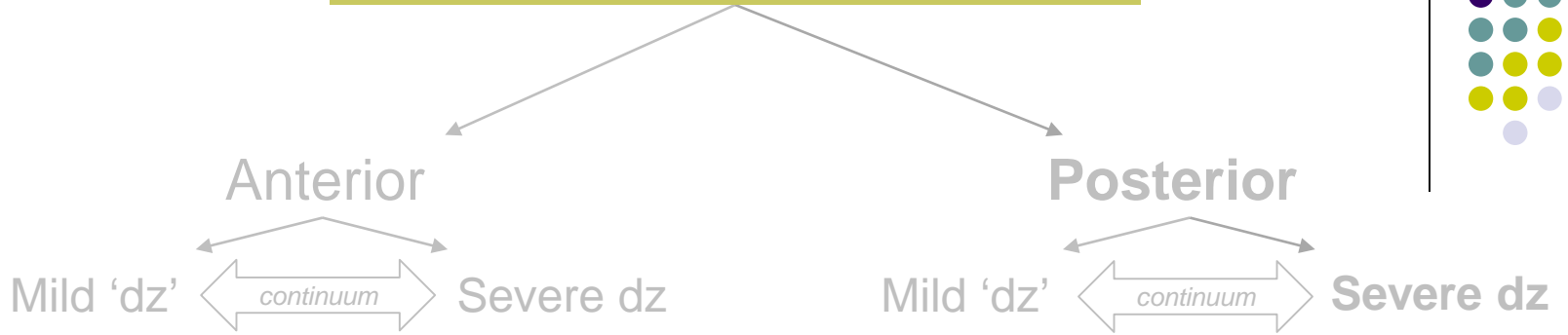
~~The eye is.~~
~~--The lens is~~
~~The anterior chamber is...shallow.~~

ere posterior PFV?
 ...ing from the ONH,
 (using) a retinal fold





Persistent Fetal Vasculature

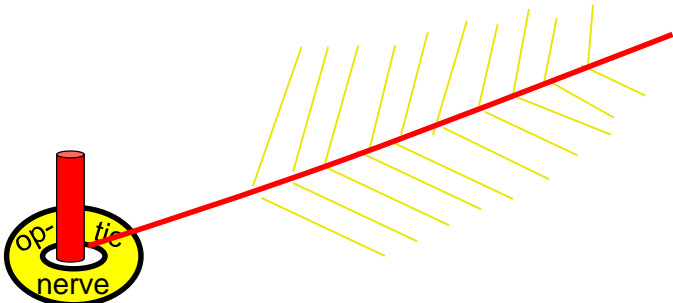
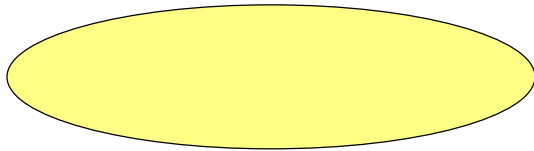


~~A white~~

What conditions top the DDx for posterior PFV?
 --ROP In a word, what sort of bug is Toxocara?
 --FEVR
 --**Toxocariasis**

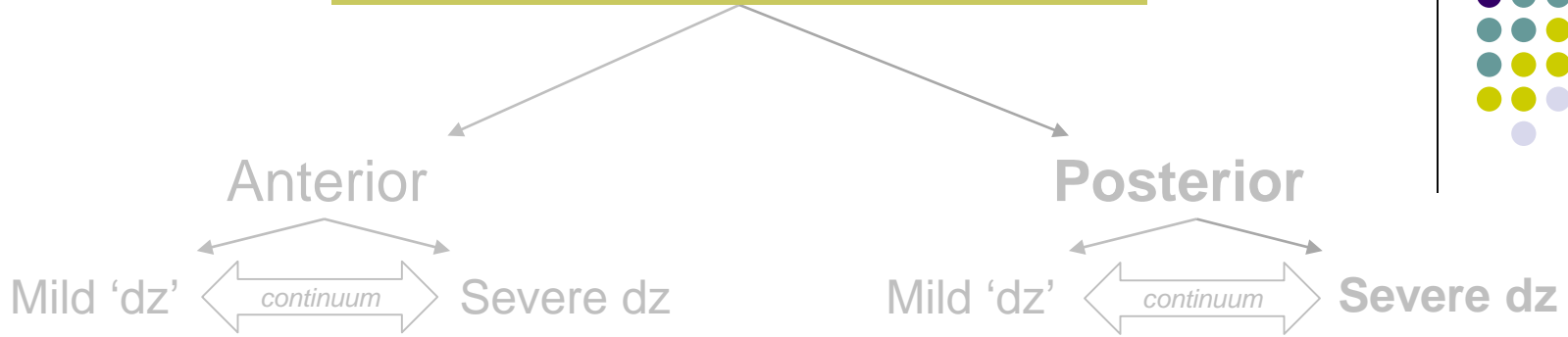ere posterior PFV?
 ating from the ONH,
 using) a retinal fold

~~The eye is.~~
~~--The lens is~~
~~The anterior chamber is...shallow.~~





Persistent Fetal Vasculature



~~A white~~

What conditions top the DDx for posterior PFV?

- ROP
- FEVR
- Toxocariasis**

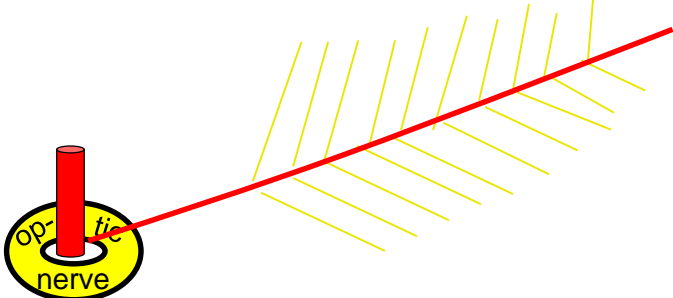
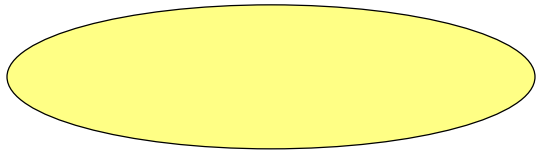
In a word, what sort of bug is Toxocara?
 A roundworm (it has its own slide-set)

ere posterior PFV?
 originating from the ONH,
 (using) a retinal fold


~~The eye is.~~

~~--The lens is~~

~~The anterior chamber is...shallow.~~



Persistent Fetal Vasculature



The next section is a brief recapitulation of the high points for severe anterior PFV

Q

Persistent Fetal Vasculature



- *Anterior PFV: Basics*



classic descriptors (three words)

membrane present behind lens

A

Persistent Fetal Vasculature



- *Anterior PFV: Basics*
 - White vascularized fibrous membrane present behind lens

Q

Persistent Fetal Vasculature




- *Anterior PFV: Basics*

- White vascularized fibrous membrane present behind lens
- Associated with:
 - eye size

A

Persistent Fetal Vasculature



- *Anterior PFV: Basics*
 - **White vascularized fibrous** membrane present behind lens
 - Associated with:
 - **Microphthalmos**

Q

Persistent Fetal Vasculature




- *Anterior PFV: Basics*

- White vascularized fibrous membrane present behind lens
- Associated with:
 - Microphthalmos
 - Leukocoria how early in life?

A

Persistent Fetal Vasculature




- *Anterior PFV: Basics*

- White vascularized fibrous membrane present behind lens
- Associated with:
 - Microphthalmos
 - Leukocoria at birth

Q

Persistent Fetal Vasculature




- *Anterior PFV: Basics*

- White vascularized fibrous membrane present behind lens
- Associated with:
 - Microphthalmos
 - Leukocoria at birth
 - deep vs shallow anterior chamber

A

Persistent Fetal Vasculature




- *Anterior PFV: Basics*

- White vascularized fibrous membrane present behind lens
- Associated with:
 - Microphthalmos
 - Leukocoria at birth
 - Shallow anterior chamber

Q

Persistent Fetal Vasculature




- *Anterior PFV: Basics*

- White vascularized fibrous membrane present behind lens
- Associated with:
 - Microphthalmos
 - Leukocoria at birth
 - Shallow anterior chamber
 - Long two words visible around small lens

A

Persistent Fetal Vasculature



- *Anterior PFV: Basics*

- White vascularized fibrous membrane present behind lens
- Associated with:
 - Microphthalmos
 - Leukocoria at birth
 - Shallow anterior chamber
 - Long ciliary processes visible around small lens



Q


Persistent Fetal Vasculature

● Anterior PFV: Basics

- White vascularized fibrous membrane present behind lens
- Associated with:
 - Microphthalmos
 - Leukocoria at birth
 - Shallow anterior chamber
 - Long ciliary processes visible around small lens
- Dehiscence of posterior capsule → lens → cataract and glaucoma


A

Persistent Fetal Vasculature



- *Anterior PFV: Basics*

- White vascularized fibrous membrane present behind lens
- Associated with:
 - Microphthalmos
 - Leukocoria at birth
 - Shallow anterior chamber
 - Long ciliary processes visible around small lens
- Dehiscence of posterior capsule → lens intumescence → cataract and 2° angle closure glaucoma



Q

Persistent Fetal Vasculature

● Anterior PFV: Basics

- White vascularized fibrous membrane present behind lens
- Associated with:
 - Microphthalmos
 - Leukocoria at birth
 - Shallow anterior chamber
 - Long ciliary processes visible around small lens
- Dehiscence of posterior capsule → lens intumescence → cataract and 2° angle closure glaucoma
- Anterior PFV: Management
 - surgical procedure and another surgical procedure to prevent angle closure

A

Persistent Fetal Vasculature



- *Anterior PFV: Basics*

- White vascularized fibrous membrane present behind lens
- Associated with:
 - Microphthalmos
 - Leukocoria at birth
 - Shallow anterior chamber
 - Long ciliary processes visible around small lens
- Dehiscence of posterior capsule → lens intumescence → cataract and 2° angle closure glaucoma
- *Anterior PFV: Management*
 - Lensectomy and membranectomy to prevent angle closure