

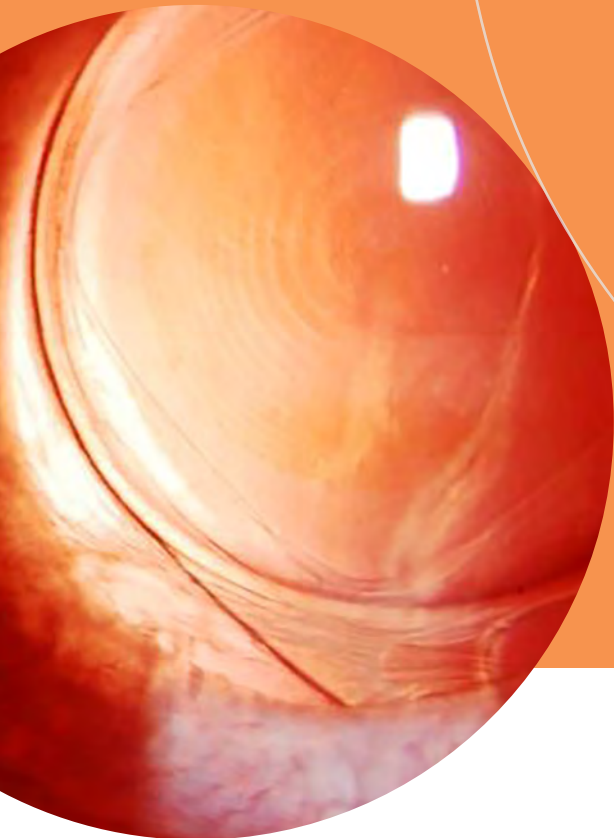AMERICAN ACADEMY  
OF OPHTHALMOLOGY®

# EyeNet Selections

## Refractive Cataract 2018

Recent Articles From  
*EyeNet® Magazine*



Protecting Sight. Empowering Lives.®



### Indications and Usage

BromSite® (bromfenac ophthalmic solution) 0.075% is a nonsteroidal anti-inflammatory drug (NSAID) indicated for the treatment of postoperative inflammation and prevention of ocular pain in patients undergoing cataract surgery.

### Recommended Dosing

One drop of BromSite® should be applied to the affected eye twice daily (morning and evening) 1 day prior to surgery, the day of surgery, and 14 days postsurgery.

### Important Safety Information

- **Slow or Delayed Healing:** All topical nonsteroidal anti-inflammatory drugs (NSAIDs), including BromSite®, may slow or delay healing. Topical corticosteroids are also known to slow or delay healing. Concomitant use of topical NSAIDs and topical steroids may increase the potential for healing problems.
- **Potential for Cross-Sensitivity:** There is the potential for cross-sensitivity to acetylsalicylic acid, phenylacetic acid derivatives, and other NSAIDs, including BromSite®.

Therefore, caution should be used when treating individuals who have previously exhibited sensitivities to these drugs.

- **Increased Bleeding Time of Ocular Tissue:** With some NSAIDs, including BromSite®, there exists the potential for increased bleeding time due to interference with platelet aggregation. There have been reports that ocularly applied NSAIDs may cause increased bleeding of ocular tissues (including hyphemas) in conjunction with ocular surgery. It is recommended that BromSite® be used with caution in patients with known bleeding tendencies or who are receiving other medications which may prolong bleeding time.
- **Keratitis and Corneal Effects:** Use of topical NSAIDs may result in keratitis. In some susceptible patients, continued use of topical NSAIDs may result in epithelial breakdown, corneal thinning, corneal erosion, corneal ulceration or corneal perforation. Patients with evidence

The **FIRST** and **ONLY** NSAID indicated to prevent ocular pain in cataract surgery patients<sup>1</sup>

# A DROP OF PREVENTION

## FOR YOUR CATARACT SURGERY PATIENTS

Defend against ocular pain and combat postoperative inflammation with the penetrating power of BromSite<sup>®</sup> formulated with DuraSite<sup>®</sup><sup>1</sup>

- DuraSite<sup>®</sup> increases ocular surface retention time, resulting in increased bromfenac absorption<sup>2-5</sup>
- Provides 24-hour coverage with BID dosing<sup>1</sup>
- Available in 5 mL bottle

Visit [bromsite.com](http://bromsite.com) to find out more.

**BromSITE<sup>®</sup>**  
(bromfenac ophthalmic solution) 0.075%

Formulated with **DURASITE<sup>®</sup>** DELIVERY SYSTEM

of corneal epithelial breakdown should immediately discontinue use of topical NSAIDs, including BromSite<sup>®</sup>, and should be closely monitored for corneal health. Patients with complicated ocular surgeries, corneal denervation, corneal epithelial defects, diabetes mellitus, ocular surface diseases (e.g., dry eye syndrome), rheumatoid arthritis, or repeat ocular surgeries within a short period of time may be at increased risk for corneal adverse events which may become sight threatening. Topical NSAIDs should be used with caution in these patients. Post-marketing experience with topical NSAIDs also suggests that use more than 24 hours prior to surgery or use beyond 14 days postsurgery may increase patient risk for the occurrence and severity of corneal adverse events.

- **Contact Lens Wear:** BromSite<sup>®</sup> should not be administered while wearing contact lenses. The preservative in BromSite<sup>®</sup>, benzalkonium chloride, may be absorbed by soft contact lenses.

- **Adverse Reactions:** The most commonly reported adverse reactions in 1% to 8% of patients were anterior chamber inflammation, headache, vitreous floaters, iritis, eye pain, and ocular hypertension.

**Please see brief summary of Full Prescribing Information on the adjacent page.**

NSAID=nonsteroidal anti-inflammatory drug.

**References:** **1.** BromSite<sup>®</sup> [package insert]. Cranbury, NJ: Sun Pharmaceutical Industries, Inc.; 2016. **2.** Hosseini K, Hutcheson J, Bowman L. Aqueous humor concentration of bromfenac 0.09% (Bromday<sup>™</sup>) compared with bromfenac in DuraSite<sup>®</sup> 0.075% (BromSite<sup>™</sup>) in cataract patients undergoing phacoemulsification after 3 days dosing. Poster presented at: ARVO Annual Meeting; May 5-9, 2013; Seattle, Washington. **3.** ClinicalTrials.gov. Aqueous humor concentration of InSite Vision (ISV) 303 (bromfenac in DuraSite) to Bromday once daily (QD) prior to cataract surgery. <https://clinicaltrials.gov/ct2/show/results/NCT01387464?sect=X70156&term=inSITE+vision&rank=1>. Accessed March 2, 2017. **4.** Si EC, Bowman LM, Hosseini K. Pharmacokinetic comparisons of bromfenac in DuraSite and Xibrom. *J Ocul Pharmacol Ther.* 2011;27(1):61-66. **5.** Bowman LM, Si E, Pang J, et al. Development of a topical polymeric mucoadhesive ocular delivery system for azithromycin. *J Ocul Pharmacol Ther.* 2009;25(2):133-139.

Sun Ophthalmics is a division of Sun Pharmaceutical Industries, Inc.  
© 2017 Sun Pharmaceutical Industries, Inc. All rights reserved.  
BromSite and DuraSite are registered trademarks of  
Sun Pharma Global FZE.  
SUN-OPH-BRO-219 03/2017



# BromSite® (bromfenac ophthalmic solution) 0.075% Brief Summary

## INDICATIONS AND USAGE

BromSite® (bromfenac ophthalmic solution) 0.075% is indicated for the treatment of postoperative inflammation and prevention of ocular pain in patients undergoing cataract surgery.

## CONTRAINDICATIONS

None

## WARNINGS AND PRECAUTIONS

### Slow or Delayed Healing

All topical nonsteroidal anti-inflammatory drugs (NSAIDs), including BromSite® (bromfenac ophthalmic solution) 0.075%, may slow or delay healing. Topical corticosteroids are also known to slow or delay healing. Concomitant use of topical NSAIDs and topical steroids may increase the potential for healing problems.

### Potential for Cross-Sensitivity

There is the potential for cross-sensitivity to acetylsalicylic acid, phenylacetic acid derivatives, and other NSAIDs, including BromSite® (bromfenac ophthalmic solution) 0.075%. Therefore, caution should be used when treating individuals who have previously exhibited sensitivities to these drugs.

### Increased Bleeding Time of Ocular Tissue

With some NSAIDs, including BromSite® (bromfenac ophthalmic solution) 0.075%, there exists the potential for increased bleeding time due to interference with platelet aggregation. There have been reports that ocularly applied NSAIDs may cause increased bleeding of ocular tissues (including hyphemas) in conjunction with ocular surgery.

It is recommended that BromSite® be used with caution in patients with known bleeding tendencies or who are receiving other medications which may prolong bleeding time.

### Keratitis and Corneal Reactions

Use of topical NSAIDs may result in keratitis. In some susceptible patients, continued use of topical NSAIDs may result in epithelial breakdown, corneal thinning, corneal erosion, corneal ulceration or corneal perforation. These events may be sight threatening. Patients with evidence of corneal epithelial breakdown should immediately discontinue use of topical NSAIDs, including BromSite® (bromfenac ophthalmic solution) 0.075%, and should be closely monitored for corneal health.

Post-marketing experience with topical NSAIDs suggests that patients with complicated ocular surgeries, corneal denervation, corneal epithelial defects, diabetes mellitus, ocular surface diseases (e.g., dry eye syndrome), rheumatoid arthritis, or repeat ocular surgeries within a short period of time may be at increased risk for corneal adverse events which may become sight threatening. Topical NSAIDs should be used with caution in these patients.

Post-marketing experience with topical NSAIDs also suggests that use more than 24 hours prior to surgery or use beyond 14 days postsurgery may increase patient risk for the occurrence and severity of corneal adverse events.

### Contact Lens Wear

BromSite® should not be administered while wearing contact lenses. The preservative in BromSite®, benzalkonium chloride, may be absorbed by soft contact lenses.

## ADVERSE REACTIONS

The following serious adverse reactions are described elsewhere in the Brief Summary:

- Slow or Delayed Healing
- Potential for Cross-Sensitivity
- Increased Bleeding Time of Ocular Tissue
- Keratitis and Corneal Reactions
- Contact Lens Wear

### Clinical Trial Experience

Because clinical trials are conducted under widely varying conditions, adverse reaction rates observed in the clinical trials of a drug cannot be directly compared to rates in the clinical trials of another drug and may not reflect the rates observed in clinical practice.

The most commonly reported adverse reactions in 1–8% of patients were: anterior chamber inflammation, headache, vitreous floaters, iritis, eye pain and ocular hypertension.

## USE IN SPECIFIC POPULATIONS

### Pregnancy

#### Risk Summary

There are no adequate and well-controlled studies in pregnant women to inform any drug associated risks. Treatment of pregnant rats and rabbits with oral bromfenac did not produce teratogenic effects at clinically relevant doses.

#### Clinical Considerations

Because of the known effects of prostaglandin biosynthesis-inhibiting drugs on the fetal cardiovascular system (closure of ductus arteriosus), the use of BromSite® during late pregnancy should be avoided.

#### Data

##### Animal Data

Treatment of rats with bromfenac at oral doses up to 0.9 mg/kg/day (195 times a unilateral daily human ophthalmic dose on a mg/m<sup>2</sup> basis, assuming 100% absorbed) and rabbits at oral doses up to 7.5 mg/kg/day (3243 times a unilateral daily dose on a mg/m<sup>2</sup> basis) produced no structural teratogenicity in reproduction studies. However, embryo-fetal lethality, neonatal mortality and reduced postnatal growth were produced in rats at 0.9 mg/kg/day, and embryo-fetal lethality was produced in rabbits at 7.5 mg/kg/day. Because animal reproduction studies are not always predictive of human response, this drug should be used during pregnancy only if the potential benefit justifies the potential risk to the fetus.

### Lactation

There are no data on the presence of bromfenac in human milk, the effects on the breastfed infant, or the effects on milk production; however, systemic exposure to bromfenac from ocular administration is low. The developmental and health benefits of breastfeeding should be considered along with the mother's clinical need for bromfenac and any potential adverse effects on the breast-fed child from bromfenac or from the underlying maternal condition.

### Pediatric Use

Safety and efficacy in pediatric patients below the age of 18 years have not been established.

### Geriatric Use

There is no evidence that the efficacy or safety profiles for BromSite® differ in patients 65 years of age and older compared to younger adult patients.

## NONCLINICAL TOXICOLOGY

### Carcinogenesis, Mutagenesis and Impairment of Fertility

Long-term carcinogenicity studies in rats and mice given oral doses of bromfenac up to 0.6 mg/kg/day (129 times a unilateral daily dose assuming 100% absorbed, on a mg/m<sup>2</sup> basis) and 5 mg/kg/day (540 times a unilateral daily dose on a mg/m<sup>2</sup> basis), respectively revealed no significant increases in tumor incidence.

Bromfenac did not show mutagenic potential in various mutagenicity studies, including the bacterial reverse mutation, chromosomal aberration, and micronucleus tests.

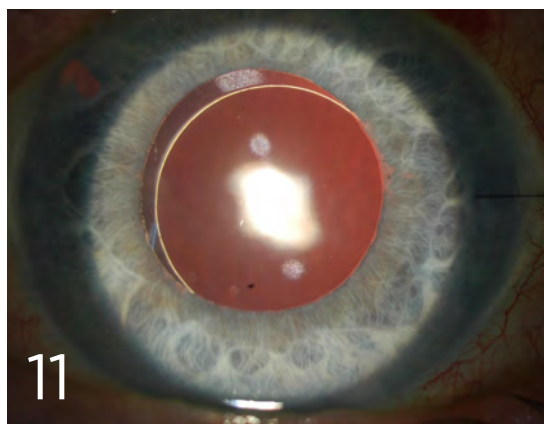
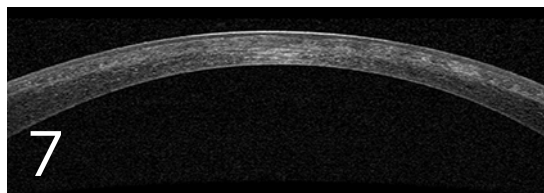
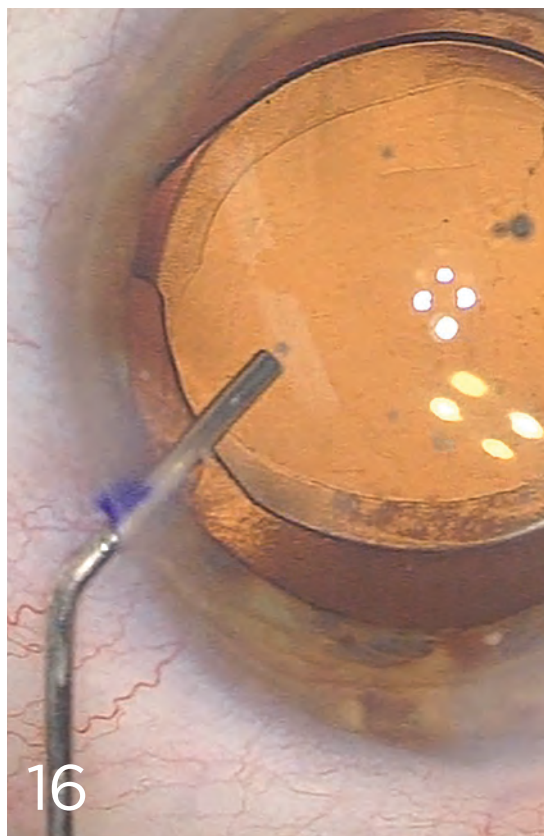
Bromfenac did not impair fertility when administered orally to male and female rats at doses up to 0.9 mg/kg/day and 0.3 mg/kg/day, respectively (195 and 65 times a unilateral daily dose, respectively, on a mg/m<sup>2</sup> basis).

### Rx Only

**Distributed by:** Sun Pharmaceutical Industries, Inc. Cranbury, NJ 08512

# EyeNet Selections CONTENTS

REPRINTS FOR  
REFRACTIVE CATARACT AT AAO 2018  
CHICAGO



## FEATURE

### 16-21 Cataract Innovations

An overview of 3 potentially disruptive technologies—intracameral antibiotics, refractive index shaping, and drops that “dissolve” cataracts.

*Originally published in September 2018.*

## CLINICAL INSIGHTS

### 7-9 SMILE

Is small incision lenticule extraction (SMILE) here to stay? Adopting it into your practice.

*Originally published in April 2018.*

### 11-13 Intrascleral Haptic Fixation

No capsular or zonular support? Try intrascleral haptic fixation. A look at 2 versions of this sutureless approach.

*Originally published in May 2018.*

COVER PHOTOGRAPHY  
Courtesy of Perfect Lens



AMERICAN ACADEMY  
OF OPHTHALMOLOGY®  
Protecting Sight. Empowering Lives.

**COPYRIGHT** © 2018, American Academy of Ophthalmology, Inc.\* All rights reserved. No part of this publication may be reproduced without written permission from the publisher. **Disclaimer.** The ideas and opinions expressed in *EyeNet* are those of the authors, and do not necessarily reflect any position of the editors, the publisher, or the American Academy of Ophthalmology. Because this publication provides information on the latest developments in ophthalmology, articles may include information on drug or device applications that are not considered community standard, or that reflect indications not included in approved FDA labeling. Such ideas are provided as information and education only so that practitioners

may be aware of alternative methods of the practice of medicine. Information in this publication should not be considered endorsement, promotion, or in any other way encouragement for the use of any particular procedure, technique, device, or product. *EyeNet*, its editors, the publisher, or the Academy in no event will be liable for any injury and/or damages arising out of any decision made or action taken or not taken in reliance on information contained herein. American Academy of Ophthalmic Executives®, EyeSmart®, EyeWiki®, IRIS® Registry, MIPS QCDR measures, and ONE® Network are trademarks of the American Academy of Ophthalmology®. All other trademarks are the property of their respective owners.

**DISCLOSURE KEY.** Financial interests are indicated by the following abbreviations: C = Consultant/Advisor; E = Employee; L = Speakers bureau; O = Equity owner; P = Patents/Royalty; S = Grant support. For definitions of each category, see [aao.org/eyenet/disclosures](http://aao.org/eyenet/disclosures).



# EyeNet Corporate Lunches

*EyeNet® Magazine* helps you make the most of your time at AAO 2018 by bringing you free corporate educational program lunches\* onsite at McCormick Place.

## Room E353c, Lakeside

McCormick Place

## Check-in and Lunch Pickup

12:15-12:30 p.m. Lunches are provided on a first-come basis.

## Program

12:30-1:30 p.m.

---

### Programs

#### **Saturday, Oct. 27** Diabetic Eye Disease: Clinical Challenges and Practical Tips for Multidisciplinary Disease Management

Speakers: Robert Busch, MD (endocrinologist), John W. Kitchens, MD

*Presented by Regeneron Pharmaceuticals, and designed for U.S. retina specialists.*

#### **Sunday, Oct. 28** INSiiGHTS AT AAO: A Spotlight on Dry Eye Treatment

Speakers: Eric D. Donnenfeld, MD, Edward J. Holland, MD, Terry Kim, MD

*Presented by Shire*

#### **Monday, Oct. 29** Cataract Surgery: Life is Beautiful When the Pupil Behaves

Speakers: Eric D. Donnenfeld, MD, Cynthia A. Matossian, MD, FACS, Steven M. Silverstein, MD, Denise M. Visco, MD, Keith A. Walter, MD

*Presented by Omeros Corporation, and designed for U.S. cataract surgeons.*

---

**Check [aao.org/eyenet/corporate-events](http://aao.org/eyenet/corporate-events) for updated program information.**

---

\* These programs are non-CME and are developed independently by industry. They are not affiliated with the official program of AAO 2018 or Subspecialty Day. By attending a lunch, you may be subject to reporting under the Physician Payment Sunshine Act.

## SMILE Begins to Make Inroads

**S**mall incision lenticule extraction, or SMILE, became clinically available as an alternative to LASIK in Europe and Asia in 2012. In September 2016, it was approved for the treatment of spherical myopia by the U.S. Food and Drug Administration (FDA). To date, more than 1 million SMILE procedures have been performed worldwide.<sup>1</sup>

During SMILE, the refractive surgeon uses a femtosecond (FS) laser to create a corneal lenticule, which is removed through a small incision—thus eliminating the need for one of the most iconic features of LASIK: the corneal flap.

### Slow Adoption?

“In describing the advent of minimally invasive SMILE relative to LASIK, ophthalmologists have used the comparison of arthroscopic surgery versus open surgery,” said Jon G. Dishler, MD, who practices in the Denver area. He noted that, as in other areas of medicine, this represents a significant step forward.

Despite this apparent advantage, SMILE has experienced a slow start in the United States, Dr. Dishler acknowledged. He attributed this to the fact that U.S. approval officially covers the correction of spherical myopia only between  $-1$  D and  $-8$  D in eyes with  $-0.5$  D or less of astigmatism. Elsewhere,

those parameters are broader, encompassing up to  $-10$  D of myopia and up to  $-6$  D of astigmatism. (Dr. Dishler noted that treatment in the United States can take place up to  $-10$  D, though a pop-up warning will occur.) In addition, at present, only the VisuMax (Carl Zeiss Meditec) is used for SMILE.

Moreover, “as with any new technology, there is usually a period of time during which adoption takes place, and there are new skills that surgeons must learn,” Dr. Dishler said (see “Challenges and Pearls,” below). “This is probably one of the most important factors” with regard to acceptance, he said.

### Benefits

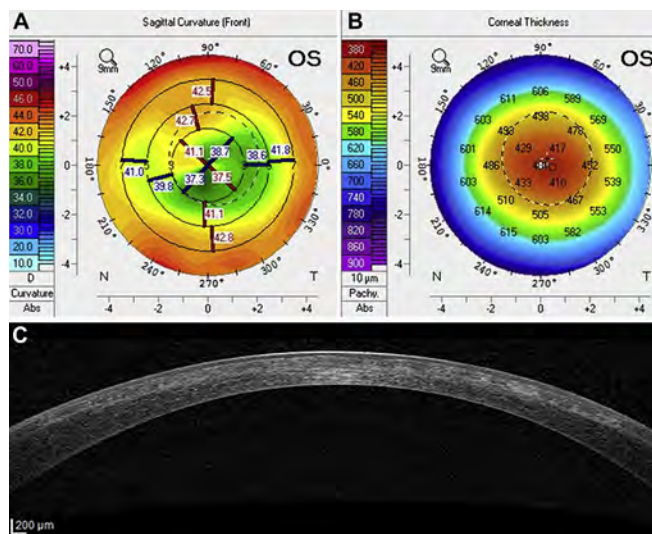
FDA approval for compound myopic astigmatism is anticipated to take place this year, and other FS laser platforms are reportedly being adapted for SMILE.<sup>2</sup> As the field begins to open up, U.S. surgeons who opt to consider SMILE

for their practices may be interested in the perspective of early adopters.

**Advantages over predecessors.** Overall, “SMILE has advantages over LASIK in that there is no flap—and advantages over PRK in terms of quicker recovery time,” said Jason E. Stahl, MD, who practices in Overland Park, Kansas.

In addition to doing away with the risk for traumatic flap displacement, SMILE is thought to offer better biomechanical corneal stability than LASIK and appears to place patients at lower risk for postoperative dry eye symptoms. From a workflow standpoint, patients don’t need to be moved from 1 laser platform to another.<sup>3</sup>

SMILE also offers advantages over



**LEARNING CURVE.** In an early study of outcomes, retreatment was needed in 7 cases, 6 of which were successful. However, the seventh retreatment produced irregular corneal topography (A, B) and a highly irregular corneal profile in the anterior stroma and a poorly defined SMILE interface (C).<sup>5</sup>

Originally published in April 2018.

BY LORI BAKER-SCHENA, MBA, EDD, CONTRIBUTING WRITER, INTERVIEWING JON G. DISHLER, MD, JOHN F. DOANE, MD, AND JASON E. STAHL, MD.

its immediate predecessor, FLEx (femto-second lenticule extraction), said John F. Doane, MD, who practices in Kansas and Missouri. “Instead of a small incision, the FLEx procedure requires a large incision, creating a LASIK-type flap that has to be lifted and peeled back to reach the lenticule—and then repositioned after the lenticule is removed,” said Dr. Doane. The result: a longer recovery time than that experienced by SMILE patients.

**Visual outcomes.** Clinical safety and effectiveness data for SMILE submitted to the FDA demonstrated stable vision correction at 6 months, with all but 1 of the 328 participants experiencing uncorrected visual acuity (VA) of 20/40 or better, and 88% experiencing uncorrected VA of 20/20 or better.<sup>4</sup>

Patients enrolled in this study had spherical myopia in the range of -1 D to -10 D and up to -0.50 D cylinder. SMILE was performed in 1 eye, and the nonstudy eye was treated with LASIK outside the clinical study.

**Postoperative complications.** In a study of more than 1,500 SMILE procedures, postoperative complications included trace haze (8%), epithelial dryness on postop day 1 (5%), interface inflammation secondary to central abrasion (0.3%), and minor interface infiltrates (0.3%).<sup>5</sup> Only 1 patient experienced corrected distance VA (CDVA) difficulties at 3 months.

**Long-term results.** Given SMILE’s status as a relative newcomer, long-term results are somewhat limited. But in a study of patients with high myopia (45 eyes of 35 patients with mean spherical equivalent of  $-7.10 \pm 0.95$  D), 86% of eyes with plano target had an uncorrected distance VA of 20/20 or better at 2 years after SMILE. All told, 2% of eyes lost 1 line of CDVA, while 32% gained 1 line.<sup>6</sup>

And 5-year results of the first cohort of international patients to undergo the procedure found that initial outcomes proved stable, and no late complications were observed.<sup>7</sup> CDVA improved from 0.02 (in logMAR) at 1 month postoperatively to -0.12 at 5 years, and 32 of the 56 eyes evaluated (58%) experienced a gain of 1 or 2 lines in vision. All patients were routinely

## A Procedural Primer

The FS laser delivers about 17 million spots in the cornea in 34 seconds, creating what has been compared to a perforated piece of paper, said Dr. Doane. The benefit of these perforations in SMILE is that they allow the lenticule to be easily removed.

To begin SMILE, the patient is raised to the contact glass of the FS laser, followed by activation of the suction ports to keep the patient’s eye fixated in the correct position while the intrastromal lenticule is created.

**Surgical steps.** Dr. Doane provided a basic outline of the 4 surgical steps involved.

**Posterior photodisruption.** This uses an out-to-in direction of the laser. It determines the refractive power change (horizontal plane) of the lenticule, which can range from 6 to 7 mm.

**Lenticular side cuts.** In this step, incisions are made around the perimeter of the lenticule (vertical plane).

**Anterior photodisruption (cap cut).** This uses an in-to-out direction of the laser (horizontal plane). It takes place parallel to the corneal surface; for the United States, it is set at 120  $\mu$ m.

**A single incision side cut.** This occurs at the superior position, with a width of 2.5 to 4.0 mm (vertical plane), to access the pocket to remove the lenticule.

**Patient repositioning.** The patient is then repositioned to the surgical microscope portion of the FS laser for the separation and extraction of the lenticule.

treated for dry eye symptoms within the first 3 months postoperatively; after this point, none of them needed further dry eye treatment.

### Challenges and Pearls

Refractive surgeons who are considering introducing SMILE into their refractive practice—described as “the leap from flap to cap”—have several challenges to consider.

**Learning curve.** The initial learning curve can be steep, a fact that Dr. Doane attributes to the 3-dimensional nature of the procedure.

“For example, in LASIK, you peel back a flap and have direct visualization when ablating the corneal tissue with the excimer laser,” he said. In contrast, “SMILE requires surgeons to see in 3-dimensional space, and it can get confusing if you don’t have the experience. You have to trust [that] the laser has done what you programmed it to do. After 5 to 10 cases, you start feeling comfortable.” Dr. Stahl agreed. “It is a new technique—freeing the lenticule and then extracting it.”

**One practice’s experience.** Dr. Stahl and his colleagues purchased the Visu-

Max laser in December 2016, 3 months after FDA approval. They spent the next 3 months becoming comfortable with the laser.

Initially, they made flaps to “understand the device’s unique features,” Dr. Stahl said. They also took wet lab courses to learn the procedure and viewed videos from experienced surgeons. Their first day of SMILE surgery occurred in March 2017, and their hands-on learning curve went smoothly, as the procedure became “quite easy” after a few cases, he said.

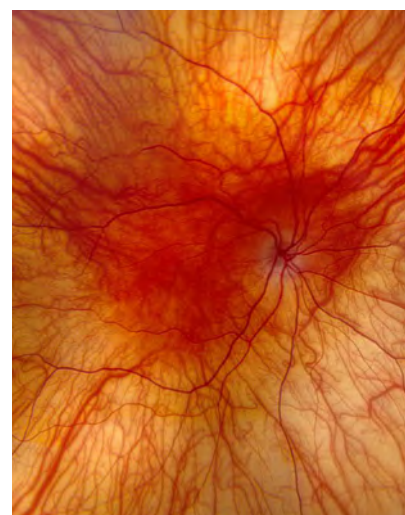**Patient selection.** “Patients who are LASIK candidates are also SMILE candidates, and from a biomechanical standpoint, SMILE appears stronger. We are interrupting fewer corneal nerve fibers, which in turn may minimize dry eye,” said Dr. Doane. He added, “I have patients who had SMILE in 1 eye and LASIK in the other, and their vision on postop day 1 was identical.”

“SMILE is not suitable for patients who are extremely anxious about undergoing refractive surgery or exhibit difficulty keeping their eyes open,” Dr. Dishler said, as this can contribute to loss of suction (see below). And as with



# EyeNet Gives You the Full Picture

Poll-topping, digestible coverage of all things ophthalmologic



Your one-stop shop for the following:

- **In-depth clinical information** in Pearls, Clinical Updates, and Features.
- **Bite-sized research summaries** in News in Review and Journal Highlights.
- **Intriguing mystery cases** in Morning Rounds and Blink.
- **Practice management tips from the experts** in Practice Perfect and Savvy Coder.
- **Thought-provoking editorials** in Opinion and Current Perspective.

Visit Us Online  
[aao.org/eyenet](http://aao.org/eyenet)

Write to Us  
[eyenet@aao.org](mailto:eyenet@aao.org)

Protecting Sight. Empowering Lives.®

LASIK, patients with keratoconus are not good candidates for SMILE.

### Potential surgical complications.

These include anterior cap and side cut tears, difficult lenticule dissection, and retained lenticule fragments.<sup>8</sup>

**Potential loss of suction.** The FS laser uses very low suction pressure to hold the eye, Dr. Stahl said. “If the patient moves or squeezes [the eyelids to blink], you can lose suction more easily than with other FS lasers. If you lose suction, you may need to convert to LASIK or PRK.” To minimize this risk, he suggested providing “verbal anesthesia,” talking the patient through the procedure with a calm, reassuring voice as the laser cuts the lenticule.

**Incomplete lenticule removal.** This potential complication is unique to SMILE, Dr. Stahl noted. He added that it is imperative for the surgeon to thoroughly inspect the lenticule upon completion of the dissection and removal—and that “if the surgeon finds that the lenticule is not complete, he or she must find the residual piece of lenticule and remove it.”

**Need for touch-ups.** Enhancements may be needed in cases of under- or overcorrection as well as in those of irregular astigmatism occurring as a result of decentered treatment, difficult lenticule dissection, or partially retained lenticule fragments.

**Rates and risks.** A study conducted in Singapore and published last year found that the incidence of enhancement after SMILE was 2.1% and 2.9% at 1 and 2 years, respectively.<sup>8</sup> Patients with greater initial refractive error (preoperative myopia > 6 D and preoperative astigmatism > 3 D) had higher enhancement rates. Intraoperative suction loss also was found to be a contributing factor.

At present, if an enhancement is necessary, PRK is recommended, Dr. Stahl said. However, if future software approvals increase the current laser parameters, this may allow LASIK enhancements to be performed after SMILE in certain eyes.

### Patient Feedback

With regard to patient acceptance, “I offer both LASIK and SMILE to

qualifying spherical myopia candidates. What I have found is that patients are excited about fast visual recovery, less dryness, and no flap,” Dr. Stahl said. He cited the admittedly unusual example of a patient who is a professional wrestler. The man chose SMILE because he did not want to worry about a flap being dislodged in the ring.

And Dr. Dishler reported that SMILE resonates with his active, millennial patients who want to return to their normal activities without a lot of “fussing” over their postoperative care. “The reality is that, beyond [my need to] see them 1 day postop and check them a month later, they tend to do well and do not need any subsequent appointments, although they are seen at 6 and 12 months postop for completeness.”

1 [www.carlzeiss.com](http://www.carlzeiss.com).

2 Marino G et al. *Asia-Pac J Ophthalmol*. 2017; 6(5):456-464.

3 Ji YW et al. *Am J Ophthalmol*. 2017;179:159-170.

4 FDA approves VisuMax Femtosecond Laser to surgically treat nearsightedness. Silver Spring, Md.: U.S. Food and Drug Administration; Sept. 13, 2016. [www.fda.gov/NewsEvents/Newsroom/PressAnnouncements/ucm520560.htm](http://www.fda.gov/NewsEvents/Newsroom/PressAnnouncements/ucm520560.htm). Accessed Feb. 22, 2018.

5 Ivarsen A et al. *Ophthalmology*. 2014;121(4):822-828.

6 Yıldırım Y et al. *Turk J Ophthalmol*. 2016;46(5): 200-204.

7 Blum M et al. *Br J Ophthalmol*. 2016;100:1192-1195.

8 Liu YC et al. *Ophthalmology*. 2017;124(6):813-821.

**Dr. Dishler** is in practice with the Dishler Laser Institute in Englewood and Aurora, Colo. *Relevant financial disclosures: Carl Zeiss Meditec: C.*


**Dr. Doane** is in practice with Discover Vision in Leawood, Kansas, and Independence, Mo. *Relevant financial disclosures: Carl Zeiss Meditec: C.*

**Dr. Stahl** is in practice with Durrie Vision in Overland Park, Kansas. *Relevant financial disclosures: None.*

See the disclosure key, page 5. For full disclosures, view this article at [aao.org/eyenet](http://aao.org/eyenet).



**MORE ONLINE.** View the SMILE procedure at [aao.org/clinical-video/real-time-relex-smile-procedure](http://aao.org/clinical-video/real-time-relex-smile-procedure).



AMERICAN ACADEMY  
OF OPHTHALMOLOGY®

## List Your Training Opportunities

The Academy's **Global Directory of Training Opportunities** ([aao.org/training-opportunities](https://aao.org/training-opportunities)) is an online resource for ophthalmologists seeking training opportunities. It is the best way to reach the broadest pool of candidates. If your academic medical center or private practice have fellowships or observerships available to ophthalmologists outside your country, list your opportunities in the Directory. It is free and only takes 2 to 3 minutes to post:

1. Go to [aao.org/gdto-submission](https://aao.org/gdto-submission).
2. Click "Submit a Training Opportunity."
3. Log in. (This will save you time.)
4. Enter opportunity information.

Questions? Email [gdto@aao.org](mailto:gdto@aao.org)

## Intrascleral Haptic Fixation as an Alternative to Sutures

**W**hen lack of capsular and zonular support prevents placement of an intraocular lens (IOL) in the posterior chamber, some surgeons turn to sutureless intrascleral fixation of a 3-piece, posterior chamber IOL (PCIOL) as the solution.

### Small Incision

Many ophthalmic surgeons who perform sutureless intrascleral fixation (also known as extracapsular fixation) say that this method of stabilizing IOLs, which uses a small-incision approach, represents an improvement over large-incision scleral suturing.

**Indications.** Intrascleral fixation is indicated in patients who have undergone traumatic injury or who have posterior capsular rupture, pseudoexfoliation, or other factors that have damaged the posterior capsule or weakened the zonules. These patients may have subluxations, crystalline lens fragments (or a dislocated IOL) in the vitreous, or visual problems from decentration, and they sometimes need a secondary implant.

**Improvement.** Before the development of intrascleral fixation methods, surgeons typically stabilized IOLs in problem eyes by suturing them to the sclera or the iris with polypropylene<sup>1</sup> or, more recently, Gore-Tex (an off-label use), said George H.H. Beiko,

BM, BCH, FRCSC, who practices in St. Catharines, Ontario, Canada. But iris- and scleral-sutured IOLs are not ideal, because of associated complications such as cystoid macular edema, postoperative inflammation, induced astigmatism, and late suture breakage, Dr. Beiko said.

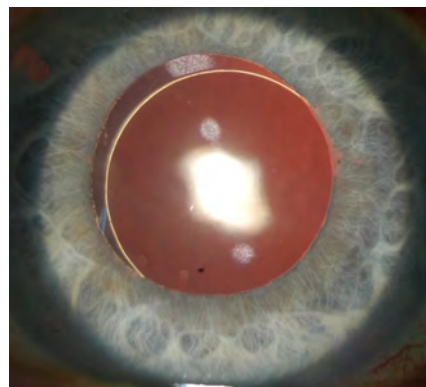
### Two Techniques

Surgeons considering intrascleral fixation have 2 methods to consider.

**Glue.** Building on earlier work by Gabor B. Sharioth, MD, PhD, Amar Agarwal, MD, first published the glued IOL technique in 2008.<sup>2</sup> For this technique, the surgeon uses forceps to place the lens haptics inside scleral tunnels, which are located underneath scleral flaps. The flaps are then repositioned over the haptics, and fibrin glue is applied to keep the flaps secure during the eye's early healing.

**Yamane.** This newer intrascleral fixation method was developed by Shin Yamane, MD, and colleagues,<sup>3,4</sup> and it is also known as the double-needle flanged haptic technique.

Using a pair of bent thin-walled, wide-bore 30-gauge needles, and with the IOL already in situ, the surgeon inserts the needles through the sclera 2 mm posterior to the limbus and feeds the PCIOL haptics into the lumen of the needles. The needles and sheathed haptics are then drawn out of the scleral tunnels, which simultaneously fixates



**DAY 1 POSTOP.** Sclerally fixated PCIOL using double-needle flanged haptic (Yamane) technique (dilated).

the 2 haptics in those tunnels. The surgeon cauterizes the protruding end of each haptic, fashioning flanges that prevent the haptics from slipping back into the eye through the tunnels and dislocating internally.

### Choosing One Over the Other

Both methods are “wonderful techniques, because you can stay [with the] small incision, and this can potentially lead to faster visual recovery and possibly better refractive outcomes,” said Nicole R. Fram, MD, who practices in Los Angeles. That said, surgeons differ as to which technique they prefer to use (see also “Pros and Cons”).

**Preference for glue.** “I prefer the glued fixation method,” Dr. Beiko said. “I’ve been doing it for 7 or 8 years, and I use it about a dozen times a year. Dr. Agarwal’s technique is generally thought to be the first-line method for intrascleral fixation.”

Dr. Beiko said that after trying the

---

Originally published in May 2018.

---

BY LINDA ROACH, CONTRIBUTING WRITER, INTERVIEWING **GEORGE H.H. BEIKO, BM, BCH, FRCSC, NICOLE R. FRAM, MD, AND SADEER B. HANNUSH, MD.**

Yamane technique in a few eyes and listening to presentations about it at international meetings, he concluded that the technique has problems that make it unsuitable for him to use.

“What they found in Japan, in a prospective study, was more IOL tilt with the Yamane than with the glued technique,” Dr. Beiko said. Specifically, the study found that IOLs fixated with the Yamane method were tilted, on average, 13.2 degrees, compared to 4.8 degrees with the glued IOLs.<sup>5</sup>

“The other thing I’ve never been quite happy with is just blindly leaving the first haptic that’s been placed within the needle floating in the back of the eye while I’m fixating on the other haptic,” Dr. Beiko said. “I’m worried that this loose haptic, which is hidden behind the iris, might be touching the retina. It’s a perfect place to create a break in the retina if you touch it.”

**Using both.** Sadeer B. Hannush, MD, at Wills Eye Hospital in Philadelphia, said he began using the glue-assisted fixation technique 5 years ago, after Dr. Agarwal’s group reported that their IOLs had remained stable for several years after implantation. “In 2013, it became my preferred fixation method in eyes with inadequate capsular support, and it remains the gold standard in sutureless intrascleral haptic fixation,” Dr. Hannush said.

Dr. Hannush started exploring the Yamane technique in late 2016, after stumbling on an early paper describing the procedure. Today, he uses both approaches. He cautioned that the eye should remain pressurized at all times either with a chamber maintainer or with perfusion through a sclerotomy.

“I believe both techniques are here to stay, each offering advantages in certain settings and in the hands of the particular surgeon,” he said. “The glued IOL technique is very effective, and it may be a little bit easier to perform for surgeons who don’t do a lot of intrascleral fixation.”

**Cautious about both.** Dr. Fram said she has primarily been using scleral suture fixation and some glued IOL techniques over the past 10 years. In the last year, she said she has been evaluating the Yamane technique, because

she views it as a clever small-incision technique with much promise. Another intriguing characteristic of the Yamane technique is that there is less hypotony associated with it in the early postoperative period, in comparison to larger-incision scleral suture fixation or even the glued IOL, she said.

But Dr. Fram is quick to point out that both intrascleral fixation methods are 2-point fixation and require symmetrical scleral tunneling and sclerotomy entries. Better standardization of these steps may improve outcomes, she said. “My experience with both the glued IOL and the Yamane technique is that critical steps of tunneling in the sclera and sclerotomy entry can be

challenging in terms of reproducibility and standardization. Because this is 2-point fixation, IOL tilt is an issue.”

Out of the approximately 42 Yamane procedures Dr. Fram has performed, 4 IOLs had significant tilt, and 2 of them required refixation. “Interestingly, I had a patient who was 20/20 uncorrected—and as he healed over a 2-week period he developed 2.5 D of astigmatism,” she said. While corneal topography and wavefront analysis (OPD-Scan; Marco) revealed little corneal astigmatism, internal astigmatism > 2 D was detected. Ultrasound biomicroscopy confirmed the IOL was tilted, she said.

“So although there can be very rapid visual recovery, which makes for a won-

---

## Pros and Cons

Dr. Hannush provided a concise overview of the 2 methods.

### Glue: advantages.

- It compartmentalizes the eye nicely into anterior and posterior segments.
- It allows the use of foldable IOLs and thus a small corneal incision.
- All maneuvers are performed under direct visualization.
- The desired length of the haptic may be embedded in a scleral tunnel. This may be adjusted to optimize IOL centration and minimize rotation.
- It has a decade-long track record.

### Glue: limitations.

- It requires familiarity with transscleral work, transferring the haptic from 1 forceps to the next (termed the “handshake technique” by Dr. Agarwal), as well as help from a third hand at certain points in surgery.
- It requires takedown of the conjunctiva and the creation of scleral flaps.
- It requires familiarity with the use of fibrin sealant.
- It requires familiarity with anterior vitrectomy techniques, ideally through the pars plana.

### Yamane: advantages.

- The technique is conceptually simple.
- The need for conjunctival takedown and scleral flaps is obviated.
- It allows implantation of a foldable IOL through a small incision.
- It is currently the fastest method of sutureless PCIOL intrascleral haptic fixation.
- Eyes tend to be very quiet postoperatively with rapid visual rehabilitation.

### Yamane: limitations.

- Despite its conceptual simplicity, it is surgically challenging even for a surgeon who is experienced in methods of scleral fixation.
- It requires familiarity with anterior vitrectomy techniques, ideally through the pars plana.
- As with the glued technique, and possibly more importantly, haptic placement is critical (180 degrees apart and 2 mm posterior to the limbus).
- The surgeon’s view is obstructed during the intrascleral passes.
- To decrease the chance of optic rotation, it is important to achieve at least a 2-mm tunnel during the intrascleral pass that is circumferential with the limbus.
- Limited international experience.

derful procedure that you want to try, you have to be prepared and know how to refixate the IOL in the event that you get significant tilt,” she said. In addition, it is imperative that the surgeon examine the patient every 6 months for potential extrusion of the haptics subconjunctivally through potentially thin-walled scleral tunnels.

## Surgical Tips and Pearls

**Two essentials.** In order to do these procedures, “a surgeon should feel comfortable with a thorough triamcinolone-assisted anterior vitrectomy prior to the fixation portion of the procedure,” Dr. Fram said. “This is a must-have [technique] in your skill set, or else you shouldn’t be attaching anything to the wall of the eye.”

It also is essential to use an anterior chamber maintainer during these procedures, Dr. Beiko noted.

**IOL selection.** Dr. Beiko implants a 3-piece silicone IOL (LI61SE, Bausch + Lomb) for his glued intrascleral fixation cases. “But I think that virtually any 3-piece IOL can be used,” he said, with 1 exception: IOLs with PMMA haptics, because these are very friable.

Dr. Hannush said that specific IOL selection is crucial in Yamane cases, because conventional PMMA haptics are prone to kinking, breaking, or even disinserting from the optic during the potentially significant manipulation that the method involves. He recommends the EC-3 PAL lens (originally available from Aeren Scientific, now renamed Lucia 602 and available from Carl Zeiss), because its haptics are made from polyvinylidene fluoride, which is very resilient.

**Special equipment.** With the glued technique, conventional intraocular forceps should not be used, because they might damage the haptics, Dr. Beiko said. The 23-gauge forceps he uses to externalize and manipulate the haptics have blunt ends; some surgeons use forceps with ridges on the ends, he said.

The Yamane technique requires a special type of 30-gauge needle with thin walls and a wide lumen, Dr. Hannush said. (The TSK Ultra Thin Wall Needle is manufactured in Japan and distributed by Delasco.)

**Geometry matters.** The surgeon performing a Yamane fixation lacks tools to assure that the intrascleral tunnels are precisely equal in length (with 20-degree angulation and 5-degree tilt) and that sclerotomy entry occurs in the right places, 180 degrees apart, Dr. Fram said. “These are hard things to standardize,” and this might help explain the IOL tilt problem in Yamane eyes, she said.

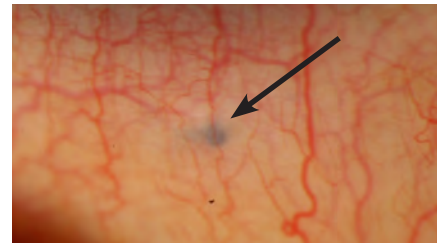
**Visualization.** “With the glued IOL technique, you are able to directly visualize everything, at every step,” Dr. Fram said. In contrast, “with the Yamane [technique], you are marking, and then you’re going through the conjunctiva, through Tenon’s, and through the sclera—and you’re doing it blind.”

Consequently, although the Yamane technique does not call for taking down the conjunctiva, sometimes it will be helpful to do a small peritomy, about 2 clock hours, for better visualization of the sclera, she said.

**Shorten the haptics.** In Yamane eyes, Dr. Hannush said he has learned from experience to clip off the haptic tips before making the flanges. “Sometimes the lens will rotate in the eye if I keep them long.” Instead, he recommended, “After the IOL is centered, an asymmetric amount of haptic is clipped off, as is deemed necessary by the surgeon, thus allowing continued good centration of the lens when the 2 haptics are tucked back into the sclera.”

**Glue or sutures?** Some surgeons modify Dr. Agarwal’s original technique by holding the scleral flap in place with a suture instead of fibrin glue, but Dr. Beiko recommends using the glue. “The main advantage of the glue is that it decreases the postoperative inflammation. It’s not so much for stabilization of the haptic. The eyes seem to be much quieter when you don’t use sutures.”

**Avoiding haptic loss.** After externalizing the leading haptic during a glued procedure, the surgeon must begin externalizing the second haptic. To keep the first haptic from moving, Dr. Beiko has a simple solution: He takes a tiny silicone ring (a “tire”) from an iris hook and threads the ring onto the haptic. “I’ve found this makes the fixation procedure easier for me, because it stops the haptic from slipping back into the eye.”



**POSTOP.** Flanged haptic end seen in the inferior subconjunctival space 2 mm from the limbus. (Arrow = haptic end.)

**Final note.** “With either technique, it may be a good idea to place 1 or 2 peripheral iridectomies to prevent reverse pupillary block,” Dr. Hannush said.

1 Hannush SB. Sutured posterior chamber intraocular Lenses. *Focal Points*. San Francisco: American Academy of Ophthalmology; 2006, module 9.

2 Agarwal A et al. *J Cataract Refract Surg*. 2008; 34(9):1433-1438.

3 Yamane S et al. *Ophthalmology*. 2014;121(1):61-66.

4 Yamane S et al. *Ophthalmology*. 2017;124(8):1136-1142.

5 Kobori A et al. The 39th Annual Meeting of the Japanese Society of Ophthalmic Surgery, 2016.

**Dr. Beiko** is in practice in St. Catharines, Ontario; a lecturer in the Department of Ophthalmology & Vision Sciences at the University of Toronto; and an associate clinical professor at McMaster University in Hamilton, Ontario, all in Canada. *Relevant financial disclosures:* Alcon: Nondisclosure Agreement; Bausch + Lomb: C,S; Carl Zeiss: C; Eyekon: Nondisclosure Agreement; Glaukos: C; Infinite Vision: C; Johnson & Johnson Vision: C,S; Latician: S; Ophtec: L.

**Dr. Fram** is in practice with Advanced Vision Care in Los Angeles, and a clinical instructor at the Jules Stein Eye Institute at the University of California, Los Angeles. *Relevant financial disclosures:* None.

**Dr. Hannush** is attending surgeon in the Cornea Service at Wills Eye Hospital, with the Department of Ophthalmology at the Sidney Kimmel Medical College at Jefferson University, and medical director of the Lions Eye Bank of Delaware Valley, all in Philadelphia. *Relevant financial disclosures:* None.

See the disclosure key, page 5.



**MORE ONLINE.** For additional images and videos, see this article at [aao.org/eyenet](http://aao.org/eyenet).

# ISRS at AAO 2018

## **REFRACTIVE SURGERY SUBSPECIALTY DAY 2018: BETTER TOGETHER – LENS AND CORNEA BASED SURGERY\***

### **The ISRS Annual Meeting**

Friday, 26 October | 08:00 – 17:30  
McCormick Place | E354

*ISRS Award Presentation at 10:45*

### **ISRS Member Only Lunch**

Friday, 26 October | 12:10 – 13:15  
McCormick Place | E450

## **BREAKFAST WITH EXPERTS\***

07:30 – 08:30 | McCormick Place | Hall A

### **Femtosecond Laser Cataract Surgery in Complex Cases (B104)**

**Complication Management in SMILE (B124)**  
Sunday, 28 October

### **Adjustable IOLs (B131)**

**Collagen Crosslinking (B149)**  
Monday, 29 October

### **Transepithelial Surface Ablation (B173)**

Tuesday, 30 October

## **SCIENTIFIC SESSIONS**

### **Introduction to Corneal and Lens-Based Refractive Surgery for Residents (SYM09)**

Sunday, 28 October | 08:00 – 11:00  
Grand Ballroom | S100C

### **The Era of Femtosecond Lasers (SYM25)**

Sunday, 28 October | 10:15 – 11:45  
McCormick Place | E450

## **SKILLS TRANSFER LABS\***

### **Laser Refractive Surgery (LAB 119A)**

Saturday, 27 October | 15:00 – 17:00  
McCormick Place | N227B

### **Laser Refractive Surgery Course (LEC 119)**

Sunday, 28 October | 14:00 – 16:15  
McCormick Place | N138

### **Laser Refractive Surgery (LAB 119B)**

Monday, 29 October | 10:30 – 12:30  
McCormick Place | N227B

## **INSTRUCTION COURSES\***

### **CXL: Basic and Advanced Indications (216)**

Sunday, 28 October | 11:30 – 12:30  
McCormick Place | N135

### **Advanced Corneal Topographic Analysis (281)**

Sunday, 28 October | 16:30 – 17:30  
McCormick Place | N137

### **A Step-by-Step Primer to Starting LASIK in 2018 (644)**

Tuesday, 30 October | 10:15 – 12:30  
McCormick Place | S102D

For more information on ISRS or to become a member, visit Member Services in the Academy Resource Center (Booth 508) or visit [www.isrs.org](http://www.isrs.org).

*\*Fee applies*

# Sun is on the rise

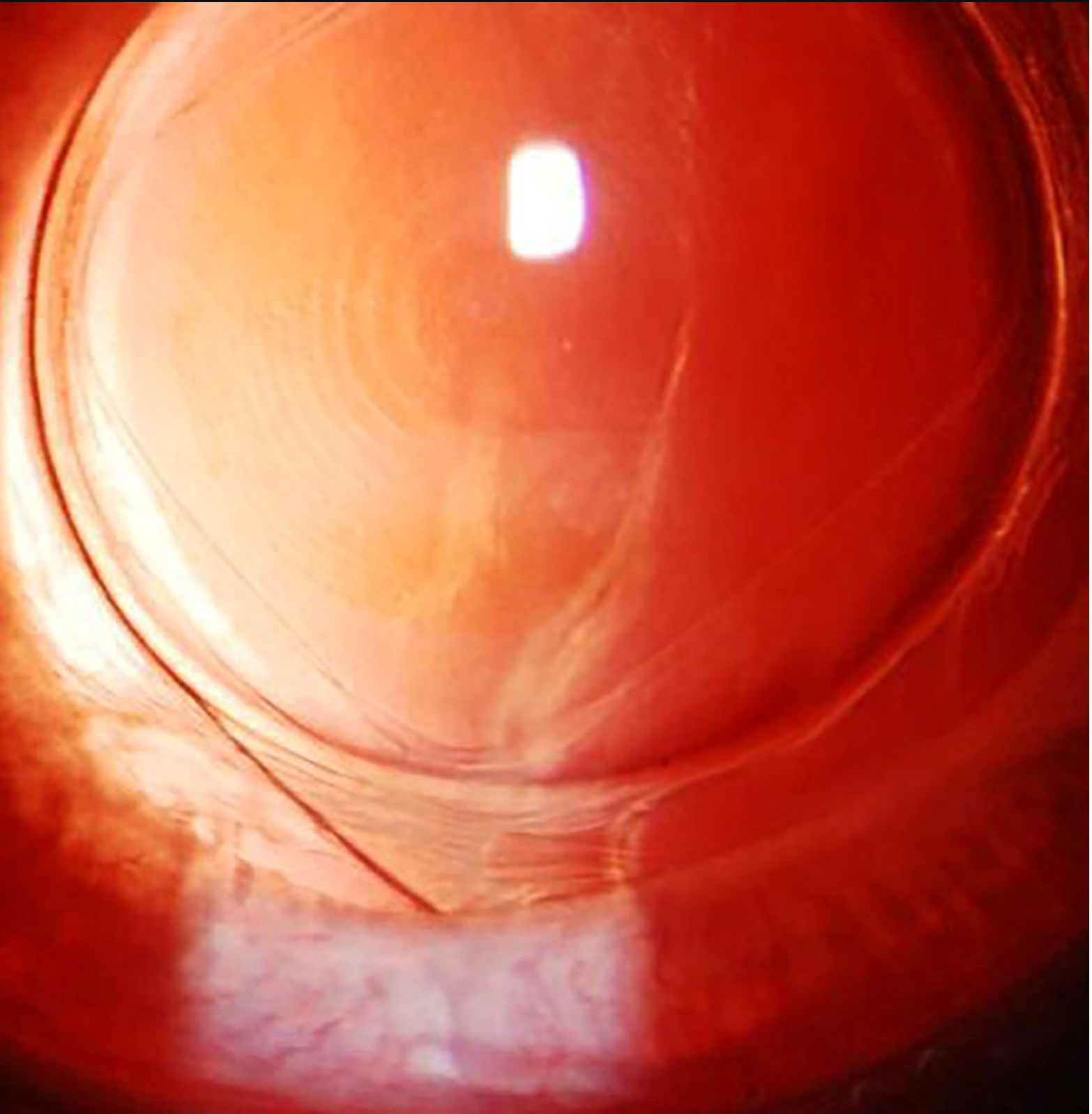
A **dedicated team** focused solely on eye care professionals.  
An innovative pipeline designed to improve the way you treat.  
A shared passion for advancing the field of ophthalmics.

**Sun Ophthalmics** is committed to reenergizing eye care and offers the promise of new beginnings in the ophthalmic landscape.

Discover a brighter eye care community at [SunIsOnTheRise.com](http://SunIsOnTheRise.com).

Brightening the future of eye care







# Cataract Innovations

Intracameral antibiotics, refractive indexing,  
and drops that “dissolve” cataracts:  
A look at 3 disruptive technologies  
poised to reshape the field.

By Annie Stuart, Contributing Writer

**A**LTHOUGH CATARACT SURGERY is already one of the safest, most effective surgeries worldwide, its evolution continues. Three technologies—1 now in use and 2 in development—may go a long way toward transforming the field, whether by reducing the need for postoperative drops, revolutionizing the approach to intraocular lens (IOL) adjustment, or allowing the clinician to circumvent cataract surgery altogether.

## Moving Toward Drop-Free Surgery

Around the turn of the millennium, the incidence of endophthalmitis in the United States was reported to range from 1 in 300 to 1 in 1,000, said Neal H. Shorstein, MD, at the Kaiser Permanente Medical Center in Walnut Creek, California. “Today, it’s more typical to see rates of 1 in 5,000 to 1 in 10,000,” he said.

**What’s behind this decrease?** “One reason is that surgeons are more aware of wound construction and management,” Dr. Shorstein said. Another contributing factor may be the increasing adoption of intracameral antibiotics (IA)—that is, direct delivery to the inside of the eye right after cataract surgery.

**Making inroads.** Although IA is a controversial practice, it is gaining momentum, based in part on the following.

**Drug delivery.** With IA, you inject directly into the anterior chamber, where you want the drug to stay for some time after surgery, said Dr. Shorstein. “Depending upon the agent and how much you are injecting, the concentrations in the eye are on

the order of about 1,000 to 3,000 micrograms per milliliter—high enough to overcome even resistant strains of coagulase-negative *Staphylococcus*, one of the most common causative organisms,” he said. “With topical drops applied to the surface of the eye, however, the concentration of antibiotic in the anterior chamber is too low to overcome organisms with higher resistance.”

**Patient perspective.** In general, IA is a financial win for patients because they will need fewer medications, said Michael Greenwood, MD, at Vance Thompson Vision in Fargo, North Dakota.

In addition, IA can circumvent problems with adherence. “Patients often have difficulty instilling eyedrops” and may inadvertently scratch their conjunctiva or cornea with the eyedrop container, Dr. Shorstein said. “Or they may never purchase their drops, fail to instill them in proper intervals, or simply stop using them (prematurely).” A quick, one-time injection by the surgeon circumvents these problems.

**Lingering concerns.** Those who are uneasy with the widespread adoption of IA cite the need for more level 1 evidence from randomized clinical trials (see “IA Research Notes”). Other barriers to its use include the following.

**No FDA approval.** U.S. surgeons do not have an FDA-approved IA agent available. Instead, ophthalmologists may have their hospital compound the antibiotic or use compounding pharmacies such as ImprimisRx, Leiters, and Avella Specialty Pharmacy, which are FDA-registered 503B outsourcing facilities, said Dr. Greenwood.

And because the surgery center generally bears

the cost of procuring the product, this adds another barrier in terms of increased operating costs.

**Potential toxicity.** Surgeons may also worry about compounding errors, which can lead to insufficient antibiotic strength or toxicity, said Dr. Greenwood. For example, a primary risk of cefuroxime, said Dr. Shorstein, is temporary or permanent macular toxicity. In rabbit studies and in human tissue culture, moxifloxacin has displayed a risk of corneal endothelial toxicity. Another potentially blinding complication is hemorrhagic occlusive retinal vasculitis (HORV), which has been linked to the use of vancomycin (see “Questions about half-life”).

“Any time you’re using a compounding pharmacy, you want to make sure it is following federal regulations,” Dr. Greenwood said. Similarly, if your clinic or local hospital is doing the compounding, the process must be painstakingly accurate and in accordance with all regulations, he said.


**Questions about half-life.** The research in the literature is slightly divergent on the exact half-life of drugs in the anterior chamber, said Dr. Shorstein. “For cefuroxime and moxifloxacin, the concentration is above typical organisms’ MIC90 for about 4 to 6 hours. For vancomycin, it’s longer.” However, because of the risk of HORV, he noted, the FDA and the American Society of Cataract and Refractive Surgery (ASCRS) strongly advise against the routine injection of vancomycin for the prophylaxis of endophthalmitis.

**Intracameral modifications.** Many surgeons who use IA also combine it with another medication. In addition, some surgeons use IA without adding topical antibiotic drops, Dr. Shorstein said (see “Going drop free,” below).

Dr. Greenwood places Dex-Moxi-Ketor (Imprimis-Rx) into the anterior chamber after surgery. (Dex-Moxi-Ketor is short for dexamethasone, moxifloxacin, and ketorolac, which are steroid, antibiotic, and nonsteroidal anti-inflammatory medications, respectively.) He and his colleagues<sup>1</sup> found that “intravitreal injection of an antibiotic and a steroid does not create significant intraocular pressure (IOP) spikes following cataract surgery in patients with glaucoma,” he said.

Dr. Greenwood’s approach is not entirely drop free, however. “For a month, patients take 1 drop once a day of a combination of prednisolone acetate, gatifloxacin, and bromfenac, a combination medication that is also from ImprimisRx,” he said. By doing so, he explained, he’s eliminated about 80 drops from his cataract patients’ postsurgical regimen.

**Going drop free.** In contrast, before cataract surgery, Dr. Shorstein’s patients receive only a dilating drop. After cataract surgery, he has



**ANTIBIOTICS.** Intracameral delivery of antibiotics immediately after cataract surgery. The procedure emerged in 2005 with the publication of a European study.

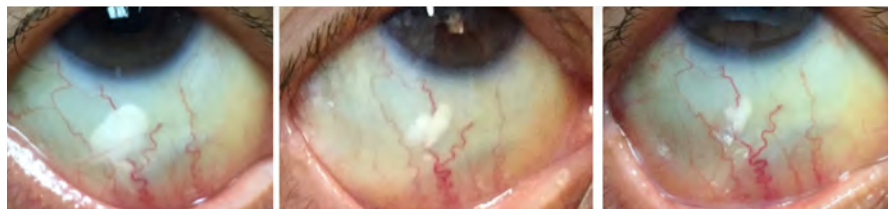patients apply no drops, pointing out that large studies have underscored the lower infection rates using IA alone (see “IA Research Notes”).

“Our study<sup>2</sup> showed that an injection of triamcinolone, delivered subconjunctivally, is just as effective in preventing postoperative macular edema as topical postop steroid drops,” said Dr. Shorstein, who does prescribe topical steroid drops postoperatively for patients with glaucoma and a compromised optic nerve. “This long-acting steroid injection, along with the intracameral antibiotic injection, make up the drop-free technique.”

**Other ways to lower risk.** A variety of techniques further lower the risk of endophthalmitis, said Dr. Greenwood. This includes a good Betadine prep prior to surgery, sterile techniques during surgery, and placement of a Betadine solution on the eye at the end of surgery.

In addition, some studies have concluded that, because IOP can dip soon after surgery, it’s advantageous to perform stromal hydration at the end of the surgery. “Leaving the eye adequately pressurized with a slightly increased IOP helps seal the corneal flaps together and ensure wound closure following the procedure,” said Dr. Shorstein.

After surgery, he also instructs his patients to avoid touching or rubbing their eyes for 24 to 48 hours, and to not apply any artificial tears. “Although there’s no hard evidence, it’s my belief that the less patients manipulate their eyes, the lower the risk of endophthalmitis,” he said.



**NO MORE DROPS?** From left: One day, 4 weeks, and 6 weeks following a subconjunctival injection of 3 mg of triamcinolone acetonide. Some research indicates that this prevents postoperative macular edema as effectively as postop steroid drops do.

## Rethinking Refractive Error Correction

Refractive index shaping—also known as refractive indexing—uses a minimally invasive, ultrafast femtosecond laser to change the refractive index ab interno of an IOL without measurably changing its shape, said Scott M. MacRae, MD, at the University of Rochester in New York. “The laser has about 100 times less pulse energy” than commercial femtosecond lasers now in use, he said.

**Procedure basics.** Before the laser adjustment, the subject receives topical anesthesia and drops to dilate pupils, said Liliana Werner, MD, PhD, at the University of Utah in Salt Lake City. The subject’s eye is aligned and docked to the femtosecond laser system, and appropriate laser treatment is then applied.

**Research.** Currently, 2 companies are evaluating the technology: Clerio Vision is working with researchers at the University of Rochester, and Perfect Lens is collaborating with researchers at the University of Utah.

“We are experimenting with different types of IOL materials to observe how they react and to determine the best energy levels to use,” said Dr. MacRae. “Although certain materials do change more than others, the response is very uniform for each type of material.” He added, “We have tested a variety of commercially available lenses and some noncommercial materials, and they have a predictable response to refractive indexing.”

The technology has not been tested with silicone or PMMA lenses, but it works well with commercially available hydrophobic and hydrophilic acrylic lenses, said Dr. Werner.

One option would be to use these types of monofocal lenses with the initial power selected for each eye, according to current standards of care, with the idea that they could be modified later. Another approach would involve developing a material that is very responsive to refractive indexing, which could provide even more control and flexibility, said Dr. MacRae.

**Multiple adjustments possible?** This technology opens up the possibility of responding to refractive error changes that occur over time, said Dr. MacRae. Many adjustments may be possible, said Dr. Werner, because each treatment is applied to only a very thin layer within the IOL. “Ongoing studies are assessing this, as well as the amount of power change that can be obtained before the quality of the IOL optic decreases,” she said.

**Potential benefits.** The laser treatment can be done in a noninvasive manner under topical anesthesia, and it is very fast, said Dr. Werner. “In our rabbit studies, the treatment took 23 seconds for a change of +3.6 D.” Other potential advantages include the following:

**Precision.** The precision obtained with the power adjustment by the femtosecond laser is within 0.1 D of the target and is very consistent, said Dr. Werner.

**Address a wide range of refractive errors.** “We know we can treat  $\pm 4$  diopters, and potentially quite a bit

more, depending upon the type of [IOL] material,” said Dr. MacRae. He added that refractive indexing can be used to treat residual myopia, hyperopia, astigmatism, and higher-order aberrations, as well as to create diffractive bifocals, trifocals, and other patterns.

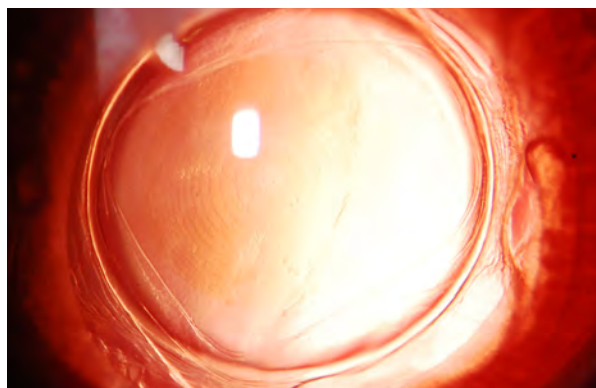
**Flexibility.** Analyses of the optical quality through modulation transfer function (MTF) measurements of the lenses<sup>3</sup> show that a monofocal lens can be changed into a multifocal lens, with resulting MTF values for far and near foci similar to commercially available multifocal lenses, said Dr. Werner. (The MTF of an IOL is a measurement of its ability to reproduce the image of an object.)

“That same lens can be turned back into a monofocal lens, and the final MTF obtained is very close to the original MTF of the initial monofocal lens. This means that all of those changes can be performed without any significant decrease in the optical quality of the original lens.”

**Negligible toxicity.** Standard tests have been performed on modified IOLs, and no leachables were found, said Dr. Werner. Also, in vivo studies performed in rabbits showed no inflammatory reaction or signs of toxicity up to 6 months postoperatively. Anti-inflammatory treatment was not applied to the rabbit eyes after laser treatment, she added.<sup>4</sup>

**Candidates.** Who might eventually benefit from refractive indexing? One example is children with congenital cataracts, whose refractive error changes over time as the eye develops. Other potential recipients include those patients who have residual refractive errors after cataract surgery, who would like to have their monofocal IOL converted to a multifocal IOL, or who cannot adapt to their current multifocal IOL, said Dr. Werner.

**Next up: results in humans.** Dr. Werner expects results from the first human trial shortly. And more human data on refractive indexing will become available over the next 1-2 years, said Dr. MacRae. “Big issues that need



**REFRACTIVE INDEXING.** This image is of a rabbit eye implanted with a commercially available IOL, 5 hours after refractive index shaping. What looks like a multi-focal pattern—visible individual zones in the IOL—is a refractive change.

to be fully worked out are reproducibility, long-term biocompatibility, and optical performance. All the work thus far has been done in animals or on the bench. It's exciting, but we need to make the airplane fly."

**Other uses for refractive index shaping.** Refractive index shaping also shows promise in 2 additional areas, Dr. MacRae said.

**Modifying contacts.** "Making diffractive and refractive index changes internally, rather than on the outside of the lens, means that [the clinician] could create a much thinner lens for high myopes or hyperopes, thus improving the oxygen permeability and comfort level," he said. "You could also create a diffractive multifocal optic internally in the contact lens." Doing so isn't possible with the current generation of multifocal contact lenses, which essentially are designed as "refractive" multifocals, he said.

**Treating corneas.** If it becomes possible to use refractive index shaping on the cornea, that would be a game changer, said Dr. MacRae, as it does not significantly affect corneal nerves or provoke much in the way of a wound healing response. "If refractive indexing can treat higher degrees of refractive error, it has the potential to revolutionize the field," he said. "And if the technology could be made portable, it could go a long way toward attacking the problem of refractive error."

In addition, any cornea treatments can be placed in layers so that multiple treatments could be done sequentially, as the refraction changes. "You can put a treatment in and go 20 microns deeper and then repeat the treatment, if needed," he said. "For example, if you treat

a 16-year-old with a diopter of myopia, you can re-treat at age 22 or 23, if she gains another diopter of myopia."

Dr. MacRae explained that the energy levels used in refractive indexing are so low as to be nondisruptive. "We are micromachining the cornea and causing densification of the collagen fiber spacing, based on our histopathologic studies." Animal models have demonstrated that this technology does work and is stable and persistent for at least 2 years, he said. With regard to impact upon keratocytes, the animal studies have found minimal, localized keratocyte death only within the laser focal zone.<sup>5</sup>

## Reducing Cataracts With an Eyedrop

In 2015, a team of researchers at the University of California, San Diego was reviewing the genetic makeup of 2 families with congenital cataracts. What they found was like so many serendipitous discoveries in medicine: Each family member with cataracts had a mutation in the lanosterol synthase gene (*LSS*), which had no previously known association with cataracts. This mutation stopped production of lanosterol, a naturally occurring steroid. "That led us to the idea that lanosterol was, in fact, important for keeping lens proteins from aggregating and producing cataracts," said Kang Zhang, MD, PhD, who heads the research team.

**Lanosterol.** "We conducted studies using a naturally occurring age-related cataract in rabbits and dogs," said Dr. Zhang.<sup>6</sup> "We took the rabbits' cataractous lenses out and incubated them in test tubes with lanosterol, showing that we could reduce cataracts and improve the

---

## IA Research Notes

Intracameral antibiotics entered the spotlight when a study by the European Society of Cataract and Refractive Surgeons (ESCRS) found that the rate of endophthalmitis was 5 times higher in those who did not receive an IA injection.<sup>1</sup> "The results also showed that there was no statistical benefit in adding perioperative topical antibiotics along with intracameral antibiotics," said Dr. Shorstein.

The study has received its fair share of criticism over the years, however, particularly with regard to its design,<sup>2,3</sup> and additional randomized clinical trials are needed.

**Kaiser study.** Dr. Shorstein and his colleagues<sup>4</sup> found the following in a study of 300,000 surgeries:

- IA reduced the incidence of endophthalmitis by about half, with no measurable differences between cefuroxime and moxifloxacin.
- Adding topical antibiotics to a regimen of IA did not further reduce the risk of endophthalmitis. In fact, doing so actually increased the risk of endophthalmitis, a finding that was not statistically significant. Dr. Shorstein suspects that any increase could be due to bottle tip contamination, patient error in administration, or trauma to the eye from applying drops.
- Patients on topical fluoroquinolone or polymyxin/tri-methoprim alone experienced a significantly lower incidence of

endophthalmitis compared to those who failed to fill their prescription for drops and to those on a topical aminoglycoside.

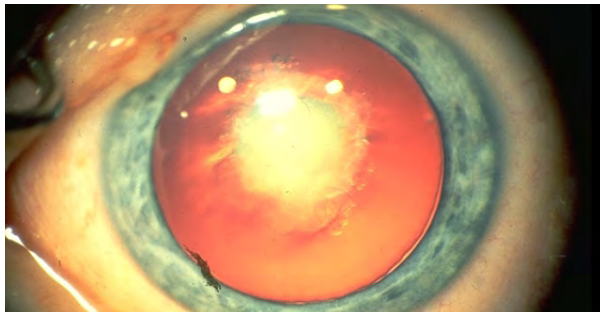
**Up next.** An ASCRS study is set to compare topical and intracameral moxifloxacin. The hope is that the investigation will lead to FDA approval of an intracameral indication for this existing antibiotic drug, Dr. Greenwood said.

1 Endophthalmitis Study Group. *J Cataract Refract Surg.* 2007;33(6):978-988.

2 Schwartz SG et al. *Ophthalmology.* 2016;123(7):1411-1413.

3 George NK, Stewart MW. *Ophthalmol Ther.* Published online July 5, 2018.

4 Herrinton LJ et al. *Ophthalmology.* 2016;123(2):287-294.



**DISSOLVING CATARACTS?** Research on drops to dissolve cataracts began with a fortuitous discovery linking congenital cataracts (shown here) with mutations in the LSS gene.

clarity of the lens.”

His team then did an experiment in live dogs. “After 6 weeks of treatment using lanosterol eyedrops, we were also able to reduce cataracts and significantly increase lens clarity.” Although 6 weeks was sufficient to reduce cataracts, he said, cataracts may recur, so retreatment may be needed. An eyedrop treatment has now been developed for treating cataracts in animals.

**New nanoparticle.** Now, Dr. Zhang and his team are turning their attention to developing a lanosterol eyedrop for humans. The biggest stumbling block has been the molecule itself, which is large and not easily soluble.

“But we have found a nice nanoparticle vehicle and developed a formula that can be used for delivery,” he said, explaining that the nanoparticle facilitates lanosterol crossing the cornea by creating an amphipathic molecule, which has both hydrophilic and hydrophobic parts. The lanosterol formula can be delivered as either an eyedrop or by implantation, he said, and he added that his team “implanted this nanoparticle gel into the subconjunctival space in monkeys and found it can perform sustained delivery for 2-3 months.”

**VP1-001.** Another research team, at ViewPoint Therapeutics in San Francisco, is working on a second eyedrop. In a study published in *Science*, they reported on a compound that stabilized lens crystallin proteins and prevented them from forming amyloids. The compound, now named VP1-001, improved lens transparency in murine models of hereditary cataract.<sup>7</sup> It also showed promise in aged mouse and human lenses.

**Next up: Studies in humans.** “In the last quarter of this year, we are going to initiate both human trials and animal studies in the United States and China,” said Dr. Zhang. He plans to enroll between 30 and 50 people in the phase 1 safety study, but expects toxicity to be minimal given the endogenous nature of lanosterol.

**Looking ahead.** Although cataract-dissolving eyedrops are unlikely to be used for rock-hard cataracts, Dr. Zhang sees this approach as a promising alternative to surgery in other instances—for example, with patients who are at risk of complications because they have certain eye conditions (such as weak zonules), bleeding disorders, and/or cardiovascular conditions.

The drops also might be appropriate for those patients who are bothered by symptoms such as glare or trouble seeing in dim light, but their symptoms are not considered severe enough to justify cataract surgery. Finally, eyedrops could be widely distributed in remote, resource-scarce areas where surgery is difficult to deliver or even unavailable—and where the burden of cataract-related blindness is greatest.

- 1 Kindle T et al. *J Cataract Refract Surg*. 2018;44(1):56-62.
- 2 Shorstein NH et al. *Ophthalmology*. 2015;122(12):2450-2456.
- 3 Nguyen J et al. *J Cataract Refract Surg*. 2018;44(2):226-230.
- 4 Werner L et al. *J Cataract Refract Surg*. 2017;43(8):1100-1106.
- 5 Wozniak KT et al. *Exp Eye Res*. 2017;165:20-28.
- 6 Zhao L et al. *Nature*. 2015;523(7562):607-611.
- 7 Makley LN et al. *Science*. 2015;350(6261):674-677.

## MEET THE EXPERTS



**Michael Greenwood, MD** Ophthalmologist at Vance Thompson Vision in Fargo, N.D. *Relevant financial disclosures:* None.

N.D. *Relevant financial disclosures:* None.



**Scott M. MacRae, MD** Director of refractive services in the department of ophthalmology at the University of Rochester and professor of ophthalmology and visual science at the University of Rochester’s

of Rochester and professor of ophthalmology and visual science at the University of Rochester’s

Center for Visual Science in Rochester, N.Y. *Relevant financial disclosures:* None.



**Neal H. Shorstein, MD** Ophthalmologist and associate chief of quality at the Kaiser Permanente Walnut Creek Medical Center in Walnut Creek, Calif. *Relevant financial disclosures:*

None.



**Liliana Werner, MD, PhD** Professor of ophthalmology and visual sciences and codirector of the Intermountain Ocular Research Center at the John A. Moran Eye

Center at the John A. Moran Eye

Center at the University of Utah in Salt Lake City. *Relevant financial disclosures:* Perfect Lens; S.



**Kang Zhang, MD, PhD** Professor of ophthalmology, chief of ophthalmic genetics; founding director, Institute for

Genomic Medicine; and codirector of biomaterials and tissue engineering, Institute for Engineering in Medicine, University of California, San Diego. *Relevant financial disclosures:* None.

**See disclosure key, page 5. For full disclosures, see this article at [aao.org/eyenet](http://aao.org/eyenet).**



AMERICAN ACADEMY  
OF OPHTHALMOLOGY®

## Access Innovative Tools to Enhance Quality Eye Care

Renew your Academy membership to take advantage of these unparalleled ophthalmic resources.

**IRIS® Registry (Intelligent Research in Sight)** — Benchmark your practice against 16,000+ other ophthalmologists using medicine's largest clinical database. In 2020, qualifying participants who reported MIPS successfully in 2018 will save an average of \$22,250 through penalties avoided.

**Ophthalmology®** comes to you monthly, packed with the latest research and clinical updates (a \$542 value).

**EyeNet® Magazine** delivers 12 issues of the latest industry news, plus clinical roundups and in-depth supplements such as the *MIPS 2018: A Primer and Reference* (a \$150+ value).

Activate your benefits and renew your valuable membership today.  
[aao.org/benefits](http://aao.org/benefits)



Diana R. Shiba, Academy fellow since 2010, shares an uplifting moment with her patient. The Academy's IRIS Registry aggregates patient data to facilitate new scientific discoveries.

Protecting Sight. Empowering Lives.®

**Brief Summary of Prescribing Information for CEQUA™ (cyclosporine ophthalmic solution) 0.09%, for topical ophthalmic use**

**CEQUA™ (cyclosporine ophthalmic solution) 0.09%  
See package insert for Full Prescribing Information.**

**INDICATIONS AND USAGE**

CEQUA ophthalmic solution is a calcineurin inhibitor immunosuppressant indicated to increase tear production in patients with keratoconjunctivitis sicca (dry eye).

**CONTRAINDICATIONS**

None.

**WARNINGS AND PRECAUTIONS**

**Potential for Eye Injury and Contamination**

To avoid the potential for eye injury and contamination, advise patients not to touch the vial tip to the eye or other surfaces.

**Use with Contact Lenses**

CEQUA should not be administered while wearing contact lenses. If contact lenses are worn, they should be removed prior to administration of the solution. Lenses may be reinserted 15 minutes following administration of CEQUA ophthalmic solution.

**ADVERSE REACTIONS**

**Clinical Trials Experience**

Because clinical trials are conducted under widely varying conditions, adverse reaction rates observed in the clinical trials of a drug cannot be directly compared to rates in the clinical trials of another drug and may not reflect the rates observed in practice.

In clinical trials, 769 patients received at least 1 dose of cyclosporine ophthalmic solution. The majority of the treated patients were female (83%).

The most common adverse reactions reported in greater than 5% of patients were pain on instillation of drops (22%) and conjunctival hyperemia (6%). Other adverse reactions reported in 1% to 5% of patients were blepharitis, eye irritation, headache, and urinary tract infection.

**USE IN SPECIFIC POPULATIONS**

**Pregnancy**

Risk Summary

There are no adequate and well-controlled studies of CEQUA administration in pregnant women to inform a drug-associated risk. Oral administration of cyclosporine to pregnant rats or rabbits did not produce teratogenicity at clinically relevant doses.

Data

*Animal Data*

Oral administration of cyclosporine oral solution (USP) to pregnant rats or rabbits was teratogenic at maternally toxic doses of 30 mg/kg/day in rats and 100 mg/kg/day in rabbits, as indicated by increased pre- and postnatal mortality, reduced fetal weight, and skeletal retardations. These doses (normalized to body weight) were approximately 3200 and 21,000 times higher than the maximum recommended human ophthalmic dose (MRHOD) of 1.5 mcg/kg/day, respectively. No adverse embryofetal effects were observed in rats or rabbits receiving cyclosporine during organogenesis at oral doses up to 17 mg/kg/day or 30 mg/kg/day, respectively (approximately 1800 and 6400 times higher than the MRHOD, respectively).

An oral dose of 45 mg/kg/day cyclosporine (approximately 4800 times higher than MRHOD) administered to rats from Day 15 of pregnancy until Day 21 postpartum produced maternal toxicity and an increase in postnatal mortality in offspring. No adverse effects in dams or offspring were observed at oral doses up to 15 mg/kg/day (approximately 1600 times greater than the MRHOD).

**Lactation**

Risk Summary

Cyclosporine blood concentrations are low following topical ocular administration of CEQUA. There is no information regarding the presence of cyclosporine in human milk following topical administration or on the effects of CEQUA on breastfed infants and milk production. Administration of oral cyclosporine to rats during lactation did not produce adverse effects in offspring at clinically relevant doses. The developmental and health benefits of breastfeeding should be considered along with the mother's clinical need for CEQUA and any potential adverse effects on the breastfed child from cyclosporine.

**Pediatric Use**

The safety and efficacy of CEQUA ophthalmic solution have not been established in pediatric patients below the age of 18.

**Geriatric Use**

No overall differences in safety or effectiveness have been observed between elderly and younger adult patients.

**PATIENT COUNSELING INFORMATION**

**Handling the Vial**

Advise patients to not allow the tip of the vial to touch the eye or any surface, as this may contaminate the solution. Advise patients also not to touch the vial tip to their eye to avoid the potential for injury to the eye.

**Use with Contact Lenses**

CEQUA should not be administered while wearing contact lenses. Patients with decreased tear production typically should not wear contact lenses. Advise patients that if contact lenses are worn, they should be removed prior to the administration of the solution. Lenses may be reinserted 15 minutes following administration of CEQUA ophthalmic solution.

**Administration**

Advise patients that the solution from one individual single-use vial is to be used immediately after opening for administration to one or both eyes, and the remaining contents should be discarded immediately after administration.

**Rx Only**

**Distributed by:** Sun Pharmaceutical Industries, Inc.  
Cranbury, NJ 08512



**Cequa**<sup>™</sup>  
(cyclosporine ophthalmic solution) 0.09%

## COMING SOON for the treatment of dry eye<sup>1</sup>

An innovative formulation of cyclosporine A delivered with advanced proprietary nanomicellar technology for increased ocular penetration<sup>2,3</sup>

Visit [Cequa.com](http://Cequa.com) to learn more

### INDICATIONS AND USAGE

CEQUA<sup>™</sup> (cyclosporine ophthalmic solution) 0.09% is a calcineurin inhibitor immunosuppressant indicated to increase tear production in patients with keratoconjunctivitis sicca (dry eye).

### IMPORTANT SAFETY INFORMATION

#### WARNINGS AND PRECAUTIONS

##### **Potential for Eye Injury and Contamination:**

To avoid the potential for eye injury and contamination, advise patients not to touch the vial tip to the eye or other surfaces.

**Use with Contact Lenses:** CEQUA should not be administered while wearing contact lenses.

If contact lenses are worn, they should be removed prior to administration of the solution. Lenses may be reinserted 15 minutes following administration of CEQUA ophthalmic solution.

#### ADVERSE REACTIONS

The most common adverse reactions reported in greater than 5% of patients were pain on instillation of drops (22%) and conjunctival hyperemia (6%). Other adverse reactions reported in 1% to 5% of patients were blepharitis, eye irritation, headache, and urinary tract infection.

**Please see brief summary of Full Prescribing Information on the adjacent page.**

**References:** 1. CEQUA<sup>™</sup> [package insert]. Cranbury, NJ: Sun Pharmaceutical Industries, Inc; 2018. 2. Mitra AK, Weiss SL, inventors; Sun Pharma Global FZE, assignee. Topical formulations and uses thereof. US patent 9,937,225 B2. April 10, 2018. 3. Data on file. Cranbury, NJ: Sun Pharmaceutical Industries, Inc.

© 2018 Sun Ophthalmics, a division of Sun Pharmaceutical Industries, Inc. All rights reserved.  
CEQUA is a trademark of Sun Pharma Global FZE.  
PM-US-OTX-0007 08/2018



**SUN**  
OPHTHALMICS