



AMERICAN ACADEMY
OF OPHTHALMOLOGY®

Protecting Sight. Empowering Lives.®

Conjunctivitis Preferred Practice Pattern®



AMERICAN ACADEMY™
OF OPHTHALMOLOGY

Secretary for Quality of Care
Roy S. Chuck, MD, PhD

Academy Staff
Andre Ambrus, MLIS
Meghan Daly
Flora C. Lum, MD

Medical Editor: Susan Garratt

Approved by: Board of Trustees
September 22, 2023

© 2023 American Academy of Ophthalmology®
All rights reserved

AMERICAN ACADEMY OF OPHTHALMOLOGY and PREFERRED PRACTICE PATTERN are registered trademarks of the American Academy of Ophthalmology. All other trademarks are the property of their respective owners.

Preferred Practice Pattern® guidelines are developed by the Academy's H. Dunbar Hoskins Jr., MD Center for Quality Eye Care without any external financial support. Authors and reviewers of the guidelines are volunteers and do not receive any financial compensation for their contributions to the documents. The guidelines are externally reviewed by experts and stakeholders before publication.

Correspondence:
Andre Ambrus, MLIS, American Academy of Ophthalmology, P. O. Box 7424, San Francisco, CA 94120-7424. E-mail: aambrus@aao.org.

CORNEA/EXTERNAL DISEASE PREFERRED PRACTICE PATTERN® DEVELOPMENT PROCESS AND PARTICIPANTS

The **Cornea/External Disease Preferred Practice Pattern Panel** members wrote the Conjunctivitis Preferred Practice Pattern guidelines (PPP). The PPP Panel members discussed and reviewed successive drafts of the document, meeting in person twice and conducting other review by e-mail discussion, to develop a consensus over the final version of the document.

Cornea/External Disease Preferred Practice Pattern Panel 2022–2023

Albert Y. Cheung, MD
 Daniel S. Choi, MD
 Sumayya Ahmad, MD, Methodologist
 Guillermo Amescua, MD
 Vishal Jhanji, MD, FRCS, FRCOphth
 Amy Lin, MD
 Shahzad I. Mian, MD
 Michelle K. Rhee, MD
 Elizabeth T. Viriya, MD
 Francis S. Mah, MD, Co-Chair
 Divya M. Varu, MD, Co-Chair

The **Preferred Practice Patterns Committee** members reviewed and discussed the document during a meeting in June 2023. The document was edited in response to the discussion and comments.

Preferred Practice Patterns Committee 2023

David K. Wallace, MD, MPH
 Christina J. Flaxel, MD
 Steven J. Gedde, MD
 Deborah S. Jacobs, MD
 Francis S. Mah, MD
 Kevin M. Miller, MD
 Thomas A. Oetting, MD
 Divya M. Varu, MD
 David C. Musch, PhD, MPH, Methodologist

The Conjunctivitis PPP was sent for review in July 2023 to improve the quality of the guideline, to gather feedback on the draft recommendations and to assess feasibility for and applicability to the target audience, including assessing the facilitators and barriers to implementing recommendations (e.g., U.S. ophthalmologists and other important groups, including patients, other physicians, international ophthalmologists, research organizations, ophthalmological organizations, and experts in the field). The PPP was sent for review to the following patient organizations to solicit the views and preferences of patients and the public: Consumers United for Evidence-Based Healthcare, American Foundation for the Blind, Foundation Fighting Blindness, Lighthouse Guild, National Federation of the Blind, and Prevent Blindness. All those returning comments were required to provide disclosure of relevant relationships with industry to have their comments considered (indicated with an asterisk below). Members of the Cornea/External Disease Preferred Practice Pattern Panel reviewed these comments and determined revisions to the document.

Academy Reviewers

Board of Trustees and Committee of Secretaries*
 Council
 General Counsel*
 Ophthalmic Technology Assessment Committee
 Cornea/External Disease Panel
 Basic and Clinical Science Course Section 8
 Subcommittee*

Practicing Ophthalmologists Advisory Committee for Education*

Invited Reviewers

American College of Surgeons, Advisory Council for Ophthalmic Surgery
 American Foundation for the Blind
 American Ophthalmological Society*

Conjunctivitis PPP

American Society of Cataract & Refractive Surgery
American Uveitis Society*
Asia Cornea Society*
Association for Research in Vision and Ophthalmology
Association of University Professors of Ophthalmology
Canadian Ophthalmological Society
Consumers United for Evidence-Based Health Care
Cornea Society*
Foundation Fighting Blindness
International Council of Ophthalmology

International Society of Refractive Surgery
Lighthouse Guild
National Eye Institute
National Federation of the Blind
National Medical Association, Ophthalmology Section
Ocular Microbiology and Immunology Group
Prevent Blindness
Women in Ophthalmology
Robert S. Feder, MD*
Jeanine Baqai, MD

This guideline will be formally re-evaluated and updated on a 5-year cycle in 2028. A Summary Benchmark is a resource to facilitate application of the guideline and to provide criteria that could be used to measure the application of recommendations, which will be available to all at www.aao.org/ppp.

FINANCIAL DISCLOSURES

There is no external funding, including industry/commercial support, for the development of this PPP or for the distribution of the guidelines. The Academy has fully funded the development of this PPP, and the views or interests of the Academy have not influenced the final recommendations which are based on evidence from systematic reviews. All those individuals significantly involved in the guideline development process, including guideline panel members, PPP Committee members, Secretary for Quality of Care, and Academy Staff, have declared competing/financial interests through a financial interest disclosure process as well as on the Open Payments website (available at <https://openpaymentsdata.cms.gov/>). The interests of the guideline panel members are provided at the beginning of each meeting and those with competing interests in a guideline topic do not participate in voting on areas of disagreement. In compliance with the Council of Medical Specialty Societies' Code for Interactions with Companies (available at <https://cmss.org/code-for-interactions-with-companies/>), relevant relationships with industry are listed. As per CMSS code, direct financial relationships with companies do not include food and beverage, research funds paid to the institution and relationships outside of the topic of the PPP. The Academy has Relationship with Industry Procedures to comply with the Code (available at www.aao.org/about-preferred-practice-patterns). A majority (73%) of the members of the Cornea/External Disease Preferred Practice Pattern Panel 2022–2023 had no direct financial relationships to disclose.

Cornea/External Disease Preferred Practice Pattern Panel 2022–2023

Albert Y. Cheung, MD: Sight Sciences, Inc.—Consultant/Advisor
 Daniel S. Choi, MD: No financial relationships to disclose
 Sumayya Ahmad, MD: No financial relationships to disclose
 Guillermo Amescua, MD: No financial relationships to disclose
 Vishal Jhanji, MD, FRCS, FRCOphth: No financial relationships to disclose
 Amy Lin, MD: No financial relationships to disclose
 Shahzad I. Mian, MD: No financial relationships to disclose
 Michelle K. Rhee, MD: NovaBay Pharmaceuticals—Consultant/Advisor
 Elizabeth T. Viriya, MD: No financial relationships to disclose
 Francis S. Mah, MD: AbbVie, Inc., Alcon Laboratories, Bausch + Lomb, iView Therapeutics, Johnson & Johnson Vision, Novartis Pharmaceuticals, Ocular Therapeutix, Okogen, Oyster Point Pharma, Santen, Inc., Sun Pharma, Verséa Health, Inc.—Consultant/Advisor; Bausch + Lomb, Novartis Pharmaceuticals, Sun Pharma—Lecture Fees
 Divya M. Varu, MD: No financial relationships to disclose

Preferred Practice Patterns Committee 2023

David K. Wallace, MD, MPH: No financial relationships to disclose
 Christina J. Flaxel, MD: No financial relationships to disclose
 Steven J. Gedde, MD: No financial relationships to disclose
 Deborah S. Jacobs, MD: Novartis Pharmaceuticals—Consultant/Advisor
 Francis S. Mah, MD: AbbVie Inc., Alcon Laboratories, Bausch + Lomb, iView Therapeutics, Johnson & Johnson Vision, Novartis Pharmaceuticals, Ocular Therapeutix, Okogen, Oyster Point Pharma, Santen, Inc., Sun Pharma, Verséa Health, Inc.—Consultant/Advisor ; Bausch & Lomb, Novartis Pharmaceuticals, Sun Pharma—Lecture Fees
 Kevin M. Miller, MD: Alcon Laboratories, Johnson & Johnson Vision, Oculus, Inc.—Consultant/Advisor
 Thomas A. Oetting, MD: No financial relationships to disclose
 Divya M. Varu, MD: No financial relationships to disclose
 David C. Musch, PhD, MPH: Santen, Inc.—Consultant/Advisor

Secretary for Quality of Care

Roy S. Chuck, MD, PhD: No financial relationships to disclose

Academy Staff

Andre Ambrus, MLIS: No financial relationships to disclose
 Meghan Daly: No financial relationships to disclose
 Susan Garratt: No financial relationships to disclose
 Flora C. Lum, MD: No financial relationships to disclose

The disclosures of relevant relationships to industry of other reviewers of the document from January to October 2023 are available online at www.aao.org/ppp.

TABLE OF CONTENTS

OBJECTIVES OF PREFERRED PRACTICE PATTERN GUIDELINES	P141
METHODS AND KEY TO RATINGS	P142
HIGHLIGHTED FINDINGS AND RECOMMENDATIONS FOR CARE	P144
INTRODUCTION	P145
Disease Definition.....	P145
Patient Population.....	P145
Clinical Objectives.....	P145
BACKGROUND	P145
Prevalence and Risk Factors	P146
Natural History	P146
CARE PROCESS	P163
Patient Outcome Criteria.....	P163
Diagnosis	P163
History	P163
Physical Examination.....	P163
Diagnostic Tests.....	P164
Management.....	P167
Prevention	P167
Treatment.....	P168
Provider and Setting.....	P177
Counseling and Referral	P177
Socioeconomic Considerations	P178
APPENDIX 1. QUALITY OF OPHTHALMIC CARE CORE CRITERIA	P181
APPENDIX 2. INTERNATIONAL STATISTICAL CLASSIFICATION OF DISEASES AND RELATED HEALTH PROBLEMS (ICD) CODES	P183
APPENDIX 3. OCULAR SURFACE DYE STAINING	P185
APPENDIX 4. SYSTEMIC ANTIBIOTIC THERAPY FOR GONOCOCCAL AND CHLAMYDIAL CONJUNCTIVITIS	P186
LITERATURE SEARCHES FOR THIS PPP	P189
RELATED ACADEMY MATERIALS	P191
REFERENCES	P192

OBJECTIVES OF PREFERRED PRACTICE PATTERN® GUIDELINES

As a service to its members and the public, the American Academy of Ophthalmology has developed a series of Preferred Practice Pattern guidelines that **identify characteristics and components of quality eye care**. Appendix 1 describes the core criteria of quality eye care.

The Preferred Practice Pattern guidelines are based on the best available scientific data as interpreted by panels of knowledgeable health professionals. In some instances, such as when results of carefully conducted clinical trials are available, the data are particularly persuasive and provide clear guidance. In other instances, the panels have to rely on their collective judgment and evaluation of available evidence.

These documents provide guidance for the pattern of practice, not for the care of a particular individual. While they should generally meet the needs of most patients, they cannot possibly best meet the needs of all patients. Adherence to these PPPs will not ensure a successful outcome in every situation. These practice patterns should not be deemed inclusive of all proper methods of care or exclusive of other methods of care reasonably directed at obtaining the best results. It may be necessary to approach different patients' needs in different ways. The physician must make the ultimate judgment about the propriety of the care of a particular patient in light of all of the circumstances presented by that patient. The American Academy of Ophthalmology is available to assist members in resolving ethical dilemmas that arise in the course of ophthalmic practice.

Preferred Practice Pattern guidelines are not medical standards to be adhered to in all individual situations. The Academy specifically disclaims any and all liability for injury or other damages of any kind, from negligence or otherwise, for any and all claims that may arise out of the use of any recommendations or other information contained herein.

References to certain drugs, instruments, and other products are made for illustrative purposes only and are not intended to constitute an endorsement of such. Such material may include information on applications that are not considered community standard, that reflect indications not included in approved U.S. Food and Drug Administration (FDA) labeling, or that are approved for use only in restricted research settings. The FDA has stated that it is the responsibility of the physician to determine the FDA status of each drug or device he or she wishes to use, and to use them with appropriate patient consent in compliance with applicable law.

Innovation in medicine is essential to ensure the future health of the American public, and the Academy encourages the development of new diagnostic and therapeutic methods that will improve eye care. It is essential to recognize that true medical excellence is achieved only when the patients' needs are the foremost consideration.

All Preferred Practice Pattern guidelines are reviewed by their parent panel annually or earlier if developments warrant and updated accordingly. To ensure that all PPPs are current, each is valid for 5 years from the "approved by" date unless superseded by a revision. Preferred Practice Pattern guidelines are funded by the Academy without commercial support. Authors and reviewers of PPPs are volunteers and do not receive any financial compensation for their contributions to the documents. The PPPs are externally reviewed by experts and stakeholders, including consumer representatives, before publication. The PPPs are developed in compliance with the Council of Medical Specialty Societies' Code for Interactions with Companies. The Academy has Relationship with Industry Procedures (available at www.aaopt.org/about-preferred-practice-patterns) to comply with the Code.

Appendix 2 contains the International Statistical Classification of Diseases and Related Health Problems (ICD) codes for the disease entities that this PPP covers. The intended users of the Conjunctivitis PPP are ophthalmologists.

METHODS AND KEY TO RATINGS

Preferred Practice Pattern guidelines should be clinically relevant and specific enough to provide useful information to practitioners. Where evidence exists to support a recommendation for care, the recommendation should be given an explicit rating that shows the strength of evidence. To accomplish these aims, methods from the Scottish Intercollegiate Guideline Network¹ (SIGN) and the Grading of Recommendations Assessment, Development and Evaluation² (GRADE) group are used. GRADE is a systematic approach to grading the strength of the total body of evidence that is available to support recommendations on a specific clinical management issue. Organizations that have adopted GRADE include SIGN, the World Health Organization, the Agency for Healthcare Research and Quality, and the American College of Physicians.³

- ◆ All studies used to form a recommendation for care are graded for strength of evidence individually, and that grade is listed with the study citation.
- ◆ To rate individual studies, a scale based on SIGN¹ is used. The definitions and levels of evidence to rate individual studies are as follows:

I++	High-quality meta-analyses, systematic reviews of randomized controlled trials (RCTs), or RCTs with a very low risk of bias
I+	Well-conducted meta-analyses, systematic reviews of RCTs, or RCTs with a low risk of bias
I-	Meta-analyses, systematic reviews of RCTs, or RCTs with a high risk of bias
II++	High-quality systematic reviews of case-control or cohort studies High-quality case-control or cohort studies with a very low risk of confounding or bias and a high probability that the relationship is causal
II+	Well-conducted case-control or cohort studies with a low risk of confounding or bias and a moderate probability that the relationship is causal
II-	Case-control or cohort studies with a high risk of confounding or bias and a significant risk that the relationship is not causal
III	Nonanalytic studies (e.g., case reports, case series)

- ◆ Recommendations for care are formed based on the body of the evidence. The body of evidence quality ratings are defined by GRADE² as follows:

Good quality	Further research is very unlikely to change our confidence in the estimate of effect
Moderate quality	Further research is likely to have an important impact on our confidence in the estimate of effect and may change the estimate
Insufficient quality	Further research is very likely to have an important impact on our confidence in the estimate of effect and is likely to change the estimate Any estimate of effect is very uncertain

- ◆ Key recommendations for care are defined by GRADE² as follows:

Strong recommendation	Used when the desirable effects of an intervention clearly outweigh the undesirable effects or clearly do not
Discretionary recommendation	Used when the trade-offs are less certain—either because of low-quality evidence or because evidence suggests that desirable and undesirable effects are closely balanced

- ◆ The Highlighted Findings and Recommendations for Care section lists points determined by the PPP panel to be of particular importance to vision and quality of life outcomes.
- ◆ All recommendations for care in this PPP were rated using the system described above. Ratings are embedded throughout the PPP main text in italics.
- ◆ Literature searches to update the PPP were undertaken on March 3, 2022 and June 7, 2023 in the PubMed database. Complete details of the literature search are available at www.aao.org/ppp.

- ◆ Recommendations are based on systematic reviews, as per the Institute of Medicine (Clinical Practice Guidelines We Can Trust, 2011). In formulating the recommendations, the health benefits, side effects/harms/risks, and the balance of benefits and risks are reviewed and considered. Final decisions are arrived at through informal consensus techniques. If there are areas of disagreement, a vote will be conducted among the members of the guideline panel. If there are individuals with direct financial relationships in the area of disagreement, these individuals will refrain from the vote.

HIGHLIGHTED FINDINGS AND RECOMMENDATIONS FOR CARE

Conjunctivitis rarely causes permanent visual loss or structural damage, but the economic impact of conjunctivitis is considerable and largely due to lost work or school time and the cost of medical visits, testing, and treatment.^{4,5}

Chronic and/or recalcitrant conjunctivitis may be indicative of an underlying malignancy such as sebaceous carcinoma, lymphoma, or squamous cell carcinoma; or an underlying inflammatory condition, such as mucous membrane pemphigoid; or a chronic infection such as chlamydia.

The ophthalmologist plays a critical role in breaking the chain of transmission of epidemic adenoviral conjunctivitis, primarily by educating the patient and family about proper hygiene. Infected individuals should be counseled to wash hands frequently, to use a separate towel and pillow, and to avoid close contact with others during the period of contagion, which is usually 10 to 14 days from onset.

Tonometers that are inadequately disinfected can transmit infection. Dilute bleach soak (sodium hypochlorite) at 1:10 concentration is an effective disinfectant for tonometers;^{6,7} 70% isopropyl alcohol (e.g., alcohol wipes), 3% hydrogen peroxide, and ethyl alcohol are no longer recommended.⁷ Tonometers that utilize single-use disposable tips can circumvent the issue of sterilization.

Indiscriminate use of topical antibiotics or corticosteroids should be avoided. Viral conjunctivitis will not respond to antibacterial agents, and mild bacterial conjunctivitis is likely to be self-limited. For acute exacerbations of vernal conjunctivitis, topical corticosteroids are usually necessary to control severe symptoms and signs.^{8,9} No evidence exists demonstrating the superiority of any topical antibiotic agent.¹⁰

Gonococcal conjunctivitis is a hyperacute, vision-threatening infectious condition that requires immediate systemic therapy. Single-use tubes of ophthalmic ointment containing 0.5% erythromycin are used as the standard prophylactic agent to prevent ophthalmia neonatorum.¹¹

Conjunctivitis can be associated with systemic diseases. Diagnosis of superior limbic keratoconjunctivitis may lead to further investigations that reveal a thyroid disorder. Diagnosis of floppy eyelid syndrome should prompt a sleep study to rule out sleep apnea.

Herpes zoster can cause conjunctivitis, keratitis, and ocular inflammation in multiple tissues of the eye. Herpes zoster vaccination is strongly recommended in patients 50 years or older and patients 19 years or older who are immunocompromised.¹²

INTRODUCTION

DISEASE DEFINITION

Conjunctivitis is an inflammation that affects the conjunctiva primarily.

PATIENT POPULATION

The patient population includes individuals of all ages who present with symptoms and signs suggestive of conjunctivitis, such as red eye or discharge.

CLINICAL OBJECTIVES

- ◆ Establish the diagnosis of conjunctivitis, differentiating it from other causes of red eye
- ◆ Identify the cause(s) of conjunctivitis
- ◆ Establish appropriate therapy
- ◆ Relieve discomfort and pain
- ◆ Prevent complications
- ◆ Prevent the spread of communicable diseases
- ◆ Educate and engage both the patient and the referring healthcare providers on conjunctivitis management

BACKGROUND

Conjunctivitis, or inflammation of the conjunctiva, is a general term that refers to a diverse group of diseases/disorders that affect primarily the conjunctiva. Most varieties of conjunctivitis are self-limited, but some progress and may cause serious ocular and extraocular complications.

Conjunctivitis can be classified as noninfectious or infectious and as acute, chronic, or recurrent. Noninfectious types of conjunctivitis include allergic, mechanical/irritative/toxic, immune-mediated, and neoplastic, and these types may overlap. The causes of infectious conjunctivitis include viruses and bacteria.

It is important to differentiate between primary conjunctival disease and conditions in which conjunctival inflammation is secondary to systemic or ocular diseases. For example, dry eye and blepharitis are the most frequent causes of conjunctival inflammation, and the treatment for each of these entities should be directed at correcting the underlying problems.^{13, 14} Systemic conditions such as atopy or acute infections such as gonorrhea may also cause conjunctival inflammation, and treatment of conjunctivitis must include addressing the underlying systemic disease.

This PPP addresses the following types of conjunctivitis that are either most common or are particularly important to detect and treat:

- ◆ Allergic
 - ◆ Seasonal/perennial allergic conjunctivitis
 - ◆ Vernal conjunctivitis
 - ◆ Atopic conjunctivitis
- ◆ Mechanical/irritative/toxic
 - ◆ Superior limbic keratoconjunctivitis (SLK)
 - ◆ Blepharoconjunctivitis
 - ◆ Keratoconjunctivitis sicca (dry eye)
 - ◆ Rosacea conjunctivitis
 - ◆ Contact lens–related keratoconjunctivitis
 - ◆ Giant papillary conjunctivitis (GPC)
 - ◆ Floppy eyelid syndrome
 - ◆ Giant fornix syndrome
 - ◆ Medication-induced/preservative-induced keratoconjunctivitis

- ◆ Conjunctival chalasis
- ◆ Dupilumab-associated ocular surface disease
- ◆ Immune-mediated
 - ◆ Ocular mucous membrane pemphigoid (OMMP)
 - ◆ Graft-versus-host disease (GVHD)
 - ◆ Stevens-Johnson syndrome (SJS)/toxic epidermal necrolysis (TEN)
 - ◆ Graves' disease ophthalmopathy
 - ◆ Vasculitis
- ◆ Neoplastic
 - ◆ Sebaceous carcinoma
 - ◆ Ocular surface squamous neoplasia
 - ◆ Melanoma
 - ◆ Conjunctival lymphoma
- ◆ Viral
 - ◆ Adenoviral conjunctivitis
 - ◆ Herpes simplex virus (HSV) conjunctivitis
 - ◆ Varicella (herpes) zoster virus (VZV) conjunctivitis
 - ◆ Molluscum contagiosum
 - ◆ Measles, mumps, and rubella (MMR)
 - ◆ Epstein-Barr virus
 - ◆ Zika
 - ◆ COVID-19 conjunctivitis
 - ◆ Monkeypox
- ◆ Bacterial
 - ◆ Bacterial conjunctivitis (including nongonococcal and gonococcal)
 - ◆ Chlamydial conjunctivitis
 - ◆ Parinaud oculoglandular syndrome
- ◆ Other
 - ◆ Ligneous conjunctivitis
 - ◆ Pediculosis palpebrarum (*Phthirus pubis*)
 - ◆ Factitious conjunctivitis
 - ◆ Mucus fishing syndrome

PREVALENCE AND RISK FACTORS

Conjunctivitis is a diagnosis that encompasses a diverse group of diseases that occur worldwide and affect all ages, all social strata, and all genders. Although there are no reliable figures that document the incidence or prevalence of all forms of conjunctivitis, this condition has been cited as one of the most frequent causes of patient self-referral.¹⁵ Conjunctivitis infrequently causes permanent visual loss or structural damage, but the economic impact of the disease in terms of lost work and school time, cost of medical visits, diagnostic testing, and medication is considerable.^{4, 5}

The risk factors for developing conjunctivitis depend on the etiology. The associated and predisposing factors for the types of conjunctivitis that are most common or most important to treat are listed in Table 1. Symptoms may be exacerbated by the coexistence of blepharitis, dry eye, or other causes of ocular surface inflammation.

NATURAL HISTORY

The natural history of each type of conjunctivitis depends on its etiology. Table 1 lists the natural history for the types of conjunctivitis that are most common or most important to treat.

TABLE 1 TYPICAL CLINICAL SIGNS OF ASSOCIATED/PREDISPOSING FACTORS FOR, AND NATURAL HISTORY OF CONJUNCTIVITIS

Type of Conjunctivitis	Clinical Signs	Associated/Predisposing Factors	Natural History	Potential Sequelae
<p>Allergic</p> <p>Seasonal/perennial</p>	<ul style="list-style-type: none"> Bilateral. Eyelid edema, periorbital hyperpigmentation (allergic shiners), conjunctival injection, chemosis, watery discharge, mild mucous discharge, papillary palpebral reaction 	<ul style="list-style-type: none"> Environmental allergens (e.g., grasses, pollens) Climate factors (low latitude, high mean annual temperature, and low annual outdoor humidity)¹⁶ Outdoor air pollution secondary to fuel combustion, forest fires, dust storms, truck traffic, mine dumps and industrial parks, pre- and postnatal exposure to environmental tobacco smoke¹⁷⁻²⁰ Exposure to dogs, cats, farm animals²¹ 	<ul style="list-style-type: none"> Recurrent, often associated with allergic rhinitis, dry eye, meibomian gland dysfunction (MGD) with mucin hyperproduction^{22, 23} 	<ul style="list-style-type: none"> Minimal, local
<p>Vernal</p>	<ul style="list-style-type: none"> Bilateral. Palpebral and limbal variants. Giant papillary hypertrophy of superior tarsal conjunctiva, bulbar conjunctival injection, conjunctival scarring, watery and stringy mucoid discharge, limbal Horner-Trantas dots, limbal "papillae," corneal epithelial erosions, corneal neovascularization and scarring, pseudogerontoxon, corneal plaque/shield ulcer 	<ul style="list-style-type: none"> Hot, dry environments such as Central and West Africa; parts of India; Mexico; Central, North, and South America; the Middle East; Japan;²⁴ and the Mediterranean region May be associated with deficiencies of growth hormone, sex-hormone binding globulin, and dihydrotestosterone, or high levels of estrone^{25, 26} Environmental allergens for acute exacerbations More common in males²⁷ 	<ul style="list-style-type: none"> Onset in childhood; chronic course with acute exacerbations during spring and summer. Gradual decrease in activity within 2 to 20 years. Vernal keratoconjunctivitis (VKC)-like disease noted in young adults without history of childhood allergic disease²⁸ 	<ul style="list-style-type: none"> Eyelid thickening; ptosis; conjunctival scarring (predominantly superior tarsal) and cicatrization; corneal neovascularization, thinning, ulceration, infection; visual loss; limbal stem cell deficiency; keratoconus; corticosteroid-induced cataract and glaucoma²⁹ Adult VKC with diffuse subepithelial thickening of tarsal plate without giant papillae, lower rate of corneal shield ulcers (less common than in children)

TABLE 1 TYPICAL CLINICAL SIGNS OF ASSOCIATED/PREDISPOSING FACTORS FOR, AND NATURAL HISTORY OF CONJUNCTIVITIS

Type of Conjunctivitis	Clinical Signs	Associated/Predisposing Factors	Natural History	Potential Sequelae
Atopic	<ul style="list-style-type: none"> Bilateral. Eczematoid blepharitis; eyelid thickening, scarring; periorbital hyperpigmentation; Dennie-Morgan lines; lash loss; papillary hypertrophy of superior and inferior tarsal conjunctiva; conjunctival injection and scarring; watery and stringy mucoid discharge; boggy edema; punctate epithelial keratitis; corneal neovascularization, ulcers and scarring 	<ul style="list-style-type: none"> More common in females ages 30–50 Genetic predisposition to atopy Environmental allergens and irritants for acute exacerbations 	<ul style="list-style-type: none"> Later (than vernal) onset; chronic course with acute exacerbations 	<ul style="list-style-type: none"> Eyelid thickening or tightening, loss of lashes; MGD;³⁰ conjunctival scarring/cicatrization (includes inferior); corneal scarring, neovascularization, thinning, infection, ulceration; erosions;³¹ cataract; visual loss; increased risk of retinal detachment, herpes simplex keratitis,³² limbal stem cell deficiency, keratoconus subcapsular cataract
Mechanical/Irritative/Toxic				
Superior limbic keratoconjunctivitis (SLK)	<ul style="list-style-type: none"> Bilateral superior bulbar conjunctival injection, laxity, edema, and keratinization. Superior corneal and conjunctival punctate epitheliopathy, corneal filaments, superior tarsal conjunctival alterations, papillary reaction, limbal hypertrophy 	<ul style="list-style-type: none"> Frequently associated with dysthyroid states (20%–65%³³⁻³⁵) Dry eye and meibomian gland dysfunction,³⁶ ocular graft-versus-host disease (GVHD), contact lens use More common in females 	<ul style="list-style-type: none"> Subacute onset of symptoms, usually bilateral. May wax and wane for years. 	<ul style="list-style-type: none"> Superior conjunctival keratinization, pannus, filamentary keratitis, chemosis
Blepharoconjunctivitis	<ul style="list-style-type: none"> Chronic with exacerbations. Anterior blepharitis affects the eyelid skin, base of the eyelashes, and the eyelash follicles. Posterior blepharitis causes MGD, tear film instability, concomitant dry eye, chalazia. Bilateral, can be asymmetric. See Blepharitis PPP³⁷ for further details on adult and pediatric blepharitis. 	<ul style="list-style-type: none"> Anterior: staphylococcal, <i>Demodex</i>, seborrheic Posterior: MGD Angular: <i>Staphylococcus aureus</i>, <i>Moraxella lacunata</i> 	<ul style="list-style-type: none"> Chronic blepharitis with acute exacerbation of conjunctival injection. May have a history of recurrent chalazia. 	<ul style="list-style-type: none"> Chronic blepharitis, conjunctivitis, keratitis, corneal neovascularization, ulceration, thinning, scarring, perforation³⁸
Keratoconjunctivitis sicca	<ul style="list-style-type: none"> (See Dry Eye PPP.¹¹) 			

TABLE 1 TYPICAL CLINICAL SIGNS OF ASSOCIATED/PREDISPOSING FACTORS FOR, AND NATURAL HISTORY OF CONJUNCTIVITIS

Type of Conjunctivitis	Clinical Signs	Associated/Predisposing Factors	Natural History	Potential Sequelae
Rosacea conjunctivitis	<ul style="list-style-type: none"> Bilateral chronic blepharitis, eyelid margin telangiectasias, meibomian gland inspissation with excessive sebum secretion, conjunctival injection, evaporative dry eye, chalazia, corneal neovascularization, stromal scarring Inferior involvement 	<ul style="list-style-type: none"> Eyelid margin telangiectasias, MGD, blepharitis, conjunctival hyperemia, injection, pannus (see Blepharitis PPP³⁷) Ocular involvement is present in about 75% of rosacea patients.³⁹ 	<ul style="list-style-type: none"> Chronic inflammatory conditions with episodic flares 	<ul style="list-style-type: none"> Evaporative dry eye, corneal neovascularization, stromal scarring, ulceration, and perforation. Can be associated with acne rosacea with characteristic malar rash, facial erythema, telangiectasias, papules, pustules, prominent sebaceous glands, rhinophyma
Contact lens–related keratoconjunctivitis	<ul style="list-style-type: none"> Ranges from mild to diffuse conjunctival injection, focal or diffuse corneal neovascularization, peripheral or circumferential corneal neovascularization, focal or diffuse superficial punctate keratopathy. Papillary hypertrophy of tarsal conjunctivitis is variable. May result in limbal and corneal edema. 	<ul style="list-style-type: none"> Occurs in association with contact lens wear as reaction to mechanical irritation, chronic hypoxia, or preservatives Can be related to duration of contact lens wear and hygiene 	<ul style="list-style-type: none"> Subacute to acute onset of symptoms. May take months or longer to resolve with treatment and withdrawal of contact lenses 	<ul style="list-style-type: none"> Corneal neovascularization; superior epitheliopathy and corneal scarring; limbal stem cell deficiency; may progress centrally into the pupillary area
Giant papillary conjunctivitis (GPC) ²³	<ul style="list-style-type: none"> Laterality associated with contact lens wear pattern or other inciting pathology. Papillary hypertrophy of superior tarsal conjunctiva (often localized over inciting pathology), mucoid discharge. Papillae with white fibrotic centers can be seen in patients with long-standing disease. In severe cases: eyelid swelling, ptosis, shield ulcer 	<ul style="list-style-type: none"> Contact lens wear (risk factors include soft contact lenses, infrequent lens replacement, prolonged wearing time, poor lens hygiene, allergenic contact lens solutions, high water content, or poor contact lens fit) Also occurs with irritation from exposed sutures and prostheses 	<ul style="list-style-type: none"> Chronic gradual increase in symptoms and signs with contact lens wear, exposed corneal or scleral sutures, ocular prosthesis 	<ul style="list-style-type: none"> Tarsal scarring, ptosis, corneal abrasion/erosions

TABLE 1 TYPICAL CLINICAL SIGNS OF ASSOCIATED/PREDISPOSING FACTORS FOR, AND NATURAL HISTORY OF CONJUNCTIVITIS

Type of Conjunctivitis	Clinical Signs	Associated/Predisposing Factors	Natural History	Potential Sequelae
	severe cases: eyelid swelling, ptosis, shield ulcer			
Floppy eyelid syndrome	<ul style="list-style-type: none"> Upper eyelid edema; upper eyelid easily everted, sometimes by simple elevation or lifting of eyelid; horizontal lid laxity; diffuse papillary reaction of superior tarsal conjunctiva; punctate epithelial keratopathy; pannus; mild discharge. Bilateral, often asymmetric 	<ul style="list-style-type: none"> Obesity, sleep apnea, upper-eyelid laxity, upper-eyelid excursion over lower eyelid (eyelid imbrication), thyroid disease (commonly Hashimoto's thyroiditis).⁴⁰ Increased risk of keratoconus⁴¹ 	<ul style="list-style-type: none"> Chronic ocular irritation due to nocturnal eyelid ectropion causing upper-tarsal conjunctiva to come in contact with bedding 	<ul style="list-style-type: none"> Punctate epithelial keratitis; corneal neovascularization, ulceration, and scarring
Giant fornix syndrome	<ul style="list-style-type: none"> Enlarged superior fornix with coagulum of mucopurulent material, ptosis 	<ul style="list-style-type: none"> Elderly women (eighth to tenth decade), upper-eyelid ptosis with large superior fornix^{42, 43} 	<ul style="list-style-type: none"> Chronic mucopurulent conjunctivitis that waxes and wanes with typical short courses of topical antibiotic therapy 	<ul style="list-style-type: none"> Ptosis, superior hyperemia, chronic conjunctivitis, Corneal neovascularization and perforation⁴⁴
Medication-induced/preservative-induced keratoconjunctivitis	<ul style="list-style-type: none"> Laterality based on drug use. Conjunctival injection, punctal edema, inferior fornix and bulbar conjunctival follicles, keratitis (especially inferonasal) including pseudodendrite Distinctive signs: contact dermatitis of eyelids with erythema, scaling in some cases 	<ul style="list-style-type: none"> Topical glaucoma medications, nonsteroidal anti-inflammatory drugs (NSAIDs), antibiotics, antivirals, others; may be associated with preservatives in all eye medications. Most common with multiple eye medications and/or frequent dosing Topical anesthetic abuse 	<ul style="list-style-type: none"> Gradual worsening with continued use 	<ul style="list-style-type: none"> Corneal epithelial erosion, persistent epithelial defect, corneal ulceration, pannus, corneal and conjunctival scarring, symblepharon, punctal occlusion, limbal stem cell deficiency
Conjunctival chalasis	<ul style="list-style-type: none"> Redundant conjunctiva, eyelid margin overhang, may occlude the inferior puncta 	<ul style="list-style-type: none"> Previous eye surgery Dry eye Redundant conjunctiva MGD³⁶ 	<ul style="list-style-type: none"> Chronic in nature, may follow previous chemosis 	<ul style="list-style-type: none"> Chronic irritation, dry eye keratitis, epiphora
Dupilumab-associated ocular surface disease	<ul style="list-style-type: none"> Bilateral conjunctival and limbal injection, watery or mucous discharge. Follicular, papillary, and cicatrizing conjunctival changes have been noted. 	<ul style="list-style-type: none"> Dupilumab use Severe atopic dermatitis, a history of atopic conjunctivitis and low serum levels of dupilumab 	<ul style="list-style-type: none"> Typically mild to moderate in severity, presents within several weeks to months of initiation of dupilumab treatment, limited to 	<ul style="list-style-type: none"> Often manageable with treatment, and most resolve while continuing treatment. Medication discontinuation and even dose frequency

TABLE 1 TYPICAL CLINICAL SIGNS OF ASSOCIATED/PREDISPOSING FACTORS FOR, AND NATURAL HISTORY OF CONJUNCTIVITIS

Type of Conjunctivitis	Clinical Signs	Associated/Predisposing Factors	Natural History	Potential Sequelae
	Keratitis, eyelid thickening, meibomian gland dysfunction	<ul style="list-style-type: none"> • Tralokinumab, a similar monoclonal antibody for atopic dermatitis, has also been associated with conjunctivitis⁴⁵ 	patients with atopic dermatitis treated with dupilumab (as opposed to asthma or other indications).	spacing are rarely needed to control. Keratitis, cicatrizing conjunctival changes, punctal stenosis can be seen. ⁴⁶⁻⁵¹
Immune mediated				
Ocular mucous membrane pemphigoid (OMMP)	<ul style="list-style-type: none"> • Bilateral, often asymmetric. Bulbar conjunctival injection, papillary conjunctivitis, conjunctival subepithelial fibrosis and keratinization, conjunctival scarring beginning in the fornices, punctal stenosis and keratinization, progressive conjunctival shrinkage, symblepharon, entropion, trichiasis, corneal ulcers/perforation, neovascularization, and scarring 	<ul style="list-style-type: none"> • Unknown (genetic predisposition may exist) • More common in women, onset generally over age 60 • Topical drugs may produce OMMP-like disease, with spectrum of severity ranging from self-limited to progressive disease indistinguishable from OMMP. Associated drugs include pilocarpine and timolol. Cicatrizing conjunctivitis appearing similar to OMMP can be associated with other disorders including atopic disease and underlying neoplasms, such as paraneoplastic pemphigus and paraneoplastic lichen planus.⁵² 	<ul style="list-style-type: none"> • Onset with goblet cell loss and mucin deficiency. Progressive chronic course, sometimes with remissions and exacerbations. More common in females 	<ul style="list-style-type: none"> • Conjunctival scarring and shrinkage with forniceal foreshortening; ankyloblepharon, symblepharon; trichiasis; corneal scarring, neovascularization, ulceration, perforation; ocular surface keratinization; bacterial conjunctivitis; cicatricial eyelid changes; severe tear deficiency; limbal stem cell deficiency; severe vision loss. May involve mucous membranes of the oral cavity, nasopharynx, larynx, esophagus, genitourinary tract, and anus
Graft-versus-host disease (GVHD)	<ul style="list-style-type: none"> • Bilateral. Conjunctival injection, chemosis, pseudomembranous conjunctivitis, keratoconjunctivitis sicca, superior limbic keratoconjunctivitis, cicatricial eyelid disease, episcleritis, corneal epithelial sloughing, limbal stem cell failure, calcareous corneal degeneration; rare intraocular involvement 	<ul style="list-style-type: none"> • Patients who have undergone allogeneic stem cell transplantation 	<ul style="list-style-type: none"> • Can involve multiple tissues including skin, liver, gastrointestinal system, lung, and eye. Graft-versus-host disease may follow acutely within the first 3 months following hematopoietic stem cell transplantation, but ocular disease is more common in the chronic phase 	<ul style="list-style-type: none"> • Subconjunctival fibrosis; symblepharon; lacrimal gland involvement; keratoconjunctivitis sicca; cicatricial eyelid disease. Less commonly limbal stem cell deficiency, corneal scarring, or intraocular involvement

TABLE 1 TYPICAL CLINICAL SIGNS OF ASSOCIATED/PREDISPOSING FACTORS FOR, AND NATURAL HISTORY OF CONJUNCTIVITIS

Type of Conjunctivitis	Clinical Signs	Associated/Predisposing Factors	Natural History	Potential Sequelae
Stevens-Johnson syndrome (SJS)/toxic epidermal necrolysis (TEN)	<ul style="list-style-type: none"> Bilateral, potentially asymmetric. Bulbar conjunctival injection, membranes, conjunctival subepithelial fibrosis and keratinization, conjunctival scarring, punctal stenosis and keratinization, progressive conjunctival shrinkage, symblepharon, entropion, trichiasis, corneal ulcers/perforation, neovascularization, and scarring 	<ul style="list-style-type: none"> Genetic predisposition⁵³ Prior infection (e.g., herpes simplex virus (HSV), mumps, mycoplasma pneumoniae) Systemic medications (e.g., sulfonamides, barbiturates, or phenytoin) produce inflammation and cicatricial changes of the various mucous membranes of the body including the bulbar and palpebral conjunctiva 	<ul style="list-style-type: none"> Acute episode of mucocutaneous reaction with epidermal necrosis and may involve the various mucous membranes including the gastrointestinal system, lung and eye following the systemic use of sensitizing medication or infectious agents Often single episode with avoidance of offending agent May have chronic inflammation 	<ul style="list-style-type: none"> Conjunctival scarring and shrinkage with goblet cell loss and mucin deficiency; symblepharon; trichiasis; corneal scarring, neovascularization, ulceration; limbal stem cell deficiency; ocular surface and lid keratinization; bacterial conjunctivitis; cicatricial eyelid changes; severe tear deficiency; severe vision loss
Vasculitis	<ul style="list-style-type: none"> Unilateral or bilateral. Conjunctivitis,⁵⁴ conjunctival nodules,⁵⁵ or granuloma, symblepharon and/or cicatrization,⁵⁶ proptosis, restrictive myopathy, episcleritis, necrotizing scleritis,⁵⁷ peripheral ulcerative keratitis,⁵⁸ keratic precipitates, corneal ulcers,⁵⁹ iris nodules, trabecular meshwork nodules, peripheral anterior synechiae,⁶⁰ uveitis, choroidal granulomas, vitreous opacities, optic disc swelling⁶¹ 	<ul style="list-style-type: none"> Sarcoidosis, granulomatosis with polyangiitis (granulomatosis with polyangiitis), Kawasaki disease, microscopic polyangiitis, eosinophilic granulomatosis with polyangiitis (Churg-Strauss syndrome), reactive arthritis, relapsing polychondritis, vasculitis secondary to infection, drug-induced vasculitis (methamphetamine, intravenous immunoglobulins, opioids, hydralazine, antifibrotics, antibiotics, leukotrienes),⁶² or vasculitis associated with malignancies 	<ul style="list-style-type: none"> Sarcoidosis (bimodal age of presentation, with the highest incidence reported between ages 20 and 39⁶³), granulomatosis with polyangiitis, Kawasaki disease (primarily affects children; fever of 5 days or more; red, swollen tongue [strawberry tongue]; cervical lymphadenopathy; swollen, red skin on the palms of the hands and the soles of the feet; polymorphous rash; irritability), linear IgA disease, mucous membrane pemphigoid 	<ul style="list-style-type: none"> Often involves multiple vessels, including the lungs, lymph nodes, kidneys, skin, nervous system Coronary artery aneurysm is a lethal complication of Kawasaki disease Kidney failure

TABLE 1 TYPICAL CLINICAL SIGNS OF ASSOCIATED/PREDISPOSING FACTORS FOR, AND NATURAL HISTORY OF CONJUNCTIVITIS

Type of Conjunctivitis	Clinical Signs	Associated/Predisposing Factors	Natural History	Potential Sequelae
Neoplastic				
Sebaceous carcinoma	<ul style="list-style-type: none"> • Unilateral. Intense bulbar conjunctival infection, conjunctival scarring. May have a mucopurulent discharge. Corneal epithelial invasion may occur • Eyelids may exhibit a hard nodular, nonmobile mass of the tarsal plate with yellowish discoloration; may appear as a subconjunctival, multilobulated yellow mass, may resemble a chalazion, may be chronic 	<ul style="list-style-type: none"> • Unknown (rarely follows radiation therapy) • Often history of multiple chalazion excisions 	<ul style="list-style-type: none"> • Chronic/recurrent nature • Occurs in fifth to ninth decades of life with fairly rapid progression⁶⁴ • Inflammation may be chronic and mistreated as an unresponsive blepharoconjunctivitis 	<ul style="list-style-type: none"> • Orbital invasion, regional or distant metastases
Ocular surface squamous neoplasia	<ul style="list-style-type: none"> • Conjunctival hyperemia, papillomatous or sessile nodules, may be leukoplakic or gelatinous • Palpebral area, limbal location, sentinel vessel 	<ul style="list-style-type: none"> • Associated with human papillomavirus (HPV); associated with significant exposure to ultraviolet (UV) light; long-standing chronic inflammation may be associated⁶⁵ • HIV patients • Smoking • Xeroderma pigmentosum 	<ul style="list-style-type: none"> • Inflammation may be chronic and mistreated as an unresponsive blepharoconjunctivitis 	<ul style="list-style-type: none"> • Conjunctival hyperemia, carcinoma in situ, or ocular surface squamous neoplasia, which can be locally invasive with regional metastases
Melanoma	<ul style="list-style-type: none"> • Painless, flat or nodular, brown or fleshy-pink lesion on the bulbar or palpebral conjunctiva or caruncle. Enlargement of the lesion, blood vessels or thickening, often trigger an office visit 	<ul style="list-style-type: none"> • Significant UV exposure, previous history of melanoma, previous primary acquired melanosis or Nevus of Ota • Fair skin • Xeroderma pigmentosum 	<ul style="list-style-type: none"> • Tends to spread to other adnexal structures and metastasize 	<ul style="list-style-type: none"> • Pigmented or nonpigmented lesion, invasive regional metastases, history of previous melanoma, primary may not be conjunctiva

TABLE 1 TYPICAL CLINICAL SIGNS OF ASSOCIATED/PREDISPOSING FACTORS FOR, AND NATURAL HISTORY OF CONJUNCTIVITIS

Type of Conjunctivitis	Clinical Signs	Associated/Predisposing Factors	Natural History	Potential Sequelae
Conjunctival lymphoma	<ul style="list-style-type: none"> Unilateral, painless, pink lesion with indolent fleshy, “salmon patch” conjunctival swelling on the superior or inferior conjunctiva.⁶⁶ Often presents with chronic palpebral or bulbar follicles. Most mobile and nonlobulated. Can have intrinsic vessels. 	<ul style="list-style-type: none"> Host immune deficiency, autoimmune conditions (Sjogren’s syndrome, Hashimoto’s, IgG4-related disease), genetic mutations, chronic infections (Heliobacter pylori, hepatitis C, and chlamydia)⁶⁷ 	<ul style="list-style-type: none"> Up to 20% with primary conjunctival lymphoma develop systemic disease Higher risk with location (fornix/mid bulbar) and increasing number of discrete tumors⁶⁶ 	<ul style="list-style-type: none"> Systemic involvement arising from conjunctival lymphoma is rare but varies based on lymphoma subtype
Viral				
Adenoviral	<ul style="list-style-type: none"> Abrupt onset. Unilateral or bilateral (often sequentially bilateral). Varies in severity. Bulbar conjunctival injection, watery discharge, follicular reaction of inferior tarsal conjunctiva, chemosis, eyelid swelling, erythema, and can resemble orbital cellulitis on exam. Distinctive signs: preauricular lymphadenopathy, petechial and subconjunctival hemorrhage, corneal epithelial defect, multifocal epithelial punctate keratitis evolving to anterior stromal keratitis, membrane/pseudomembrane formation, eyelid ecchymosis 	<ul style="list-style-type: none"> Exposure to infected individual (especially in school setting), concurrent upper respiratory infection, recent ocular testing 	<ul style="list-style-type: none"> Self-limited, with improvement of symptoms and signs within 5 to 14 days 	<ul style="list-style-type: none"> Mild cases: none. Severe cases: conjunctival/subtarsal scarring, symblepharon, keratitis and dry eye, subepithelial corneal infiltrates from epidemic keratoconjunctivitis (EKC), corneal scarring, lacrimal stenosis Pseudomembranes associated with higher rate of severe sequelae⁶⁸

TABLE 1 TYPICAL CLINICAL SIGNS OF ASSOCIATED/PREDISPOSING FACTORS FOR, AND NATURAL HISTORY OF CONJUNCTIVITIS

Type of Conjunctivitis	Clinical Signs	Associated/Predisposing Factors	Natural History	Potential Sequelae
Herpes simplex virus (HSV)	<ul style="list-style-type: none"> • Usually unilateral. Can be bilateral, especially in atopic, pediatric, or immunocompromised patients^{69, 70} • Bulbar conjunctival injection, watery discharge, mild follicular reaction of conjunctiva. May have palpable preauricular node. • Distinctive signs: vesicular rash or ulceration of eyelids, pleomorphic or excavated dendritic epithelial keratitis of cornea. Ulceration of the conjunctiva 	<ul style="list-style-type: none"> • Prior infection with HSV: trigger for reactivation may include stress, other acute viral or febrile illnesses, ultraviolet exposure, surgery, or trauma • Primary HSV infection: exposure to infected individual 	<ul style="list-style-type: none"> • Usually subsides without treatment within 4 to 7 days unless complications occur 	<ul style="list-style-type: none"> • Blepharitis, epithelial keratitis, corneal edema, endotheliitis, stromal keratitis, neovascularization, scarring, thinning, perforation, uveitis, trabeculitis, retinitis
Varicella (herpes) zoster virus (VZV)	<ul style="list-style-type: none"> • Usually unilateral. Bulbar conjunctival injection, watery discharge, mild follicular reaction of conjunctiva. May have palpable preauricular node. Typically, punctate keratitis in primary disease; punctate or pseudodendritic keratitis in recurrent disease • Distinctive signs: vesicular dermatomal rash or ulceration of eyelids (often with severe pain), pleomorphic or nonexcavated pseudodendritic epithelial keratitis of cornea 	<ul style="list-style-type: none"> • Acute chicken pox, exposure to an individual with active chicken pox or recurrent VZV (shingles) 	<ul style="list-style-type: none"> • Primary infection (chicken pox), as well as conjunctivitis from recurrent infection, usually subsides in a few days. Vesicles can form at the limbus, especially in primary infection 	<ul style="list-style-type: none"> • Necrosis and scarring from vesicles on the eyelid margins, conjunctiva, and in the corneal stroma in primary disease in children. Conjunctival scarring from secondary infection can lead to cicatricial ectropion. In recurrent disease, keratitis of the epithelium or stroma with subsequent scarring and late corneal anesthesia or dry eye, uveitis, retinitis

TABLE 1 TYPICAL CLINICAL SIGNS OF ASSOCIATED/PREDISPOSING FACTORS FOR, AND NATURAL HISTORY OF CONJUNCTIVITIS

Type of Conjunctivitis	Clinical Signs	Associated/Predisposing Factors	Natural History	Potential Sequelae
Molluscum contagiosum	<ul style="list-style-type: none"> Typically unilateral. Mild to severe follicular reaction, punctate epithelial keratitis. May have corneal pannus, especially if long-standing Distinctive signs: single or multiple shiny, dome-shaped umbilicated lesion(s) of the eyelid skin or margin Pruritis 	<ul style="list-style-type: none"> Predominantly older children and young adults. Immunocompromised state (e.g., HIV) may predispose to multiple and/or large molluscum periocular lesions Associated with chronic follicular conjunctivitis 	<ul style="list-style-type: none"> Chronic conjunctivitis is associated with eyelid lesions, which can spontaneously resolve or persist for months to years 	<ul style="list-style-type: none"> Conjunctival scarring, epithelial keratitis, pannus; less commonly, subepithelial infiltrates/haze/scar, occlusion of the puncta, follicular conjunctivitis
Measles (rubeola)	<ul style="list-style-type: none"> Bilateral conjunctivitis⁷¹ (bulbar/tarsal hyperemia), mucous secretion, epithelial keratitis (punctate, round defects, filaments, target shaped),⁷² subconjunctival hemorrhages, subepithelial⁷¹ corneal lesions 	<ul style="list-style-type: none"> Unvaccinated individuals Both rash and conjunctivitis are caused by immune-mediated clearance of measles virus-infected cells and may be absent in immunodeficient patients 	<ul style="list-style-type: none"> Fever and maculopapular rash followed by cough, coryza (or rhinitis) and/or conjunctivitis. While conjunctivitis develops at the prodromal phase, keratitis (photophobia) may develop before the development of rash 	<ul style="list-style-type: none"> Blindness from corneal scarring in vitamin A-deficient children⁷⁵
Mumps	<ul style="list-style-type: none"> Bilateral follicular conjunctivitis, chemosis, episcleritis, dacryoadenitis, keratitis, scleritis, anterior uveitis⁷³ 	<ul style="list-style-type: none"> Unvaccinated individuals 	<ul style="list-style-type: none"> Fever, bilateral parotid gland swelling, headache, nausea, vomiting. Conjunctivitis/keratitis follows parotid gland involvement 	<ul style="list-style-type: none"> Choroiditis, extraocular muscle palsy, optic neuritis
Rubella	<ul style="list-style-type: none"> Follicular conjunctivitis, palpebral > bulbar hyperemia, epithelial keratitis, corneal erosions⁷⁴ 	<ul style="list-style-type: none"> Unvaccinated individuals 	<ul style="list-style-type: none"> Mild fever, rash, and lymphadenopathy Ocular involvement often follows rash 	<ul style="list-style-type: none"> Keratitis often resolves in 1 week without sequelae

TABLE 1 TYPICAL CLINICAL SIGNS OF ASSOCIATED/PREDISPOSING FACTORS FOR, AND NATURAL HISTORY OF CONJUNCTIVITIS

Type of Conjunctivitis	Clinical Signs	Associated/Predisposing Factors	Natural History	Potential Sequelae
Epstein-Barr virus (EBV)	<ul style="list-style-type: none"> Follicular conjunctivitis, typically unilateral, can have ipsilateral lymphadenopathy Can present with hemorrhagic conjunctivitis: subconjunctival hemorrhage, periorbital edema⁷⁶ Conjunctival nodule is uncommon finding Systemic signs: generalized fatigue, fever, pharyngitis, lymphadenopathy, and splenomegaly 	<ul style="list-style-type: none"> Follicular conjunctivitis most common ocular disease during acute EBV infection⁷⁷ Other major causes of nonadenoviral acute hemorrhagic conjunctivitis are enterovirus 70 and coxsackievirus A24 	<ul style="list-style-type: none"> Often self-limiting disease Can present as oculoglandular syndrome 	<ul style="list-style-type: none"> Dry eye syndrome, dacryoadenitis, episcleritis, keratitis, uveitis, choroiditis, retinitis, retinal vasculitis, papillitis, and ophthalmoplegia⁷⁸
Zika virus	<ul style="list-style-type: none"> Nonpurulent conjunctivitis most common⁷⁹⁻⁸¹ Bilateral nongranulomatous hypertensive iridocyclitis, maculopathy Systemic signs: fever, maculopapular rash, headache, myalgia/arthralgia, and possibly Guillain-Barré syndrome 	<ul style="list-style-type: none"> Transmission via Aedes mosquito species Sexual, perinatal, and blood transfusion transmission possible Risk factors include infection in first trimester and smaller cephalic diameter at birth⁸⁰ 	<ul style="list-style-type: none"> Symptoms last from 3 to 7 days Ocular signs seem to be more significant in congenital disease⁸⁰ Conjunctivitis more common in acute Zika disease (versus congenital), less common in pregnant women with Zika 	<ul style="list-style-type: none"> Retinal involvement (retinal pigment epithelium disruption, chorioretinal atrophy, retinal hemorrhaging and mottling), optic neuritis, iris coloboma, lens subluxation, optic nerve hyperplasia
Severe acute respiratory syndrome coronavirus 2 (SARS-CoV-2)/Coronavirus disease 2019 (COVID-19)	<ul style="list-style-type: none"> Unilateral more than bilateral conjunctival injection.⁸² Follicular reaction typical. May have chemosis, watery discharge, superficial keratitis, pseudomembranes^{83, 84} 	<ul style="list-style-type: none"> SARS-CoV-2 exposure, unprotected eye exposure, significant travel history, or respiratory symptoms. 	<ul style="list-style-type: none"> Usually occurs early in disease, mild inflammation with disappearance of symptoms within a few days of treatment⁸⁵ Relatively low incidence/prevalence compared with other systemic manifestations, more common in children⁸⁴ Isolated or associated with systemic symptoms, 	<ul style="list-style-type: none"> Conjunctival symptoms appear self-limited with variable duration (5-21 days) Typically, no effect on visual acuity and no short-term complications

TABLE 1 TYPICAL CLINICAL SIGNS OF ASSOCIATED/PREDISPOSING FACTORS FOR, AND NATURAL HISTORY OF CONJUNCTIVITIS

Type of Conjunctivitis	Clinical Signs	Associated/Predisposing Factors	Natural History	Potential Sequelae
Mpox	<ul style="list-style-type: none"> • Injection, discharge, conjunctival ulcers, disseminated blistering or papular conjunctival lesions, follicular reaction, pseudomembranous/subconjunctival nodules⁸⁶⁻⁸⁸ • May have vesicular rash of periorbital/orbital areas and eyelid involvement 	<ul style="list-style-type: none"> • Immunocompromised and unvaccinated people, children more susceptible to conjunctivitis⁸⁹ • Increased rate of being bedridden with conjunctivitis⁸⁹ 	before or after onset of respiratory symptoms	<ul style="list-style-type: none"> • Corneal pitting, ulceration/keratitis, and scarring • Can lead to vision loss
Bacterial				
Nongonococcal	<ul style="list-style-type: none"> • Unilateral or bilateral. Bulbar conjunctival injection, purulent or mucopurulent discharge • See age stratification of associated/predisposing factors adjacent 	<ul style="list-style-type: none"> • Neonate: Vaginal delivery by infected mother; inadequate prenatal care⁹⁰ • Infant: Nasolacrimal duct obstruction, concomitant bacterial otitis media or pharyngitis, exposure to infected individual • Child: Contact with infected individual; concomitant bacterial otitis media, sinusitis, or pharyngitis; nasopharyngeal bacterial colonization • Adult: Contact with infected individual, unhygienic living conditions, infection or abnormality of adnexal structure, eyelid malposition, severe tear deficiency, immunosuppression, trauma 	<ul style="list-style-type: none"> • Mild: Self-limited in adults. May progress to complications in children • Severe: May persist without treatment, rarely hyperacute 	<ul style="list-style-type: none"> • Rare, but possibly corneal infection, preseptal cellulitis • Corneal infection; may be associated with pharyngitis, otitis media, meningitis

TABLE 1 TYPICAL CLINICAL SIGNS OF ASSOCIATED/PREDISPOSING FACTORS FOR, AND NATURAL HISTORY OF CONJUNCTIVITIS

Type of Conjunctivitis	Clinical Signs	Associated/Predisposing Factors	Natural History	Potential Sequelae
Gonococcal	<ul style="list-style-type: none"> • Unilateral or bilateral. Marked eyelid edema, bulbar conjunctival injection, significant purulent discharge, preauricular lymphadenopathy • Important sign to detect: corneal infiltrate or ulcer, which often begins superiorly, may lead to corneal perforation • See age stratification of associated/predisposing factors 	<ul style="list-style-type: none"> • Oculogenital spread; consider sexual abuse in children • Immunosuppression 	<ul style="list-style-type: none"> • Neonate: Manifests within 1 to 7 days after birth, later if a topical antibiotic was used. Rapid evolution to severe, purulent conjunctivitis • Adult: Rapid development of severe hyperpurulent conjunctivitis 	<ul style="list-style-type: none"> • Neonate: Corneal infection, corneal scarring, corneal perforation, septicemia with arthritis, meningitis • Adult: Corneal infection, corneal scarring, corneal perforation, urethritis, pelvic inflammatory disease, septicemia, arthritis
Chlamydial (inclusion)	<ul style="list-style-type: none"> • Neonate/infant: Unilateral or bilateral. Eyelid edema, bulbar conjunctival injection, discharge may be purulent, mucopurulent, or blood-stained;⁹¹ no follicles • Adult: Unilateral or bilateral. Follicular conjunctivitis, chemosis, papillary hypertrophy, corneal pannus, limbal follicles, superficial keratitis, subepithelial infiltrates. Distinctive sign: follicles on the bulbar conjunctiva and semilunar fold 	<ul style="list-style-type: none"> • Sexually transmitted • Caused by <i>Chlamydia trachomatis</i> serotypes D-K • Highly communicable via hands, fomites, flies, and other contact 	<ul style="list-style-type: none"> • Neonate: manifests 5 to 19 days following birth, earlier if placental membranes have ruptured prior to delivery. Untreated cases may persist for 3 to 12 months • Adult: chronic inflammation regresses to cicatricial changes of conjunctiva and cornea. • Consider co-infection with gonorrhea 	<ul style="list-style-type: none"> • Neonate: Corneal scarring, conjunctival scarring; up to 50% have associated nasopharyngeal, genital, or pulmonary infection • Adults: Corneal infiltrates, pannus, cervicitis, urethritis, salpingitis, endometritis, perihepatitis
Chlamydial (trachoma)	<ul style="list-style-type: none"> • Unilateral or bilateral. Chronic. Bulbar conjunctival injection, follicular reaction of tarsal conjunctiva, mucoid discharge, corneal pannus, punctate epithelial keratitis, corneal opacity, entropion, trichiasis, preauricular lymphadenopathy • Distinctive sign: bulbar conjunctival follicles 	<ul style="list-style-type: none"> • Caused by <i>C. trachomatis</i> serotypes A, B, and C • In low to middle income countries without adequate access to clean water and sanitation • Can be spread by direct or indirect contact with secretions from an affected person's eyes, nose, or throat 	<ul style="list-style-type: none"> • Repeated infections with conjunctivitis, mucopurulent discharge, preauricular lymphadenopathy • May persist/recur if untreated • Leading infectious cause of global blindness 	<ul style="list-style-type: none"> • Herbert pits, conjunctival scarring, cicatricial entropion, trichiasis, limbal stem cell deficiency, corneal scarring/opacification, perforation, neovascularization

TABLE 1 TYPICAL CLINICAL SIGNS OF ASSOCIATED/PREDISPOSING FACTORS FOR, AND NATURAL HISTORY OF CONJUNCTIVITIS

Type of Conjunctivitis	Clinical Signs	Associated/Predisposing Factors	Natural History	Potential Sequelae
Parinaud oculoglandular syndrome	<ul style="list-style-type: none"> • Unilateral granulomatous follicular palpebral or bulbar conjunctivitis • Associated ipsilateral regional (preauricular and submandibular) lymphadenopathy, fever, eyelid swelling, conjunctival granulomas, conjunctival injection, chemosis, serous discharge 	<ul style="list-style-type: none"> • Most commonly in cat scratch disease (<i>Bartonella henselae</i>), tularemia (<i>Francisella tularensis</i>), and sporotrichosis • Reported with various bacterial, fungal, mycobacterial, and viral infections^{92, 93} 	<ul style="list-style-type: none"> • Follicular conjunctivitis with lymphadenopathy (concomitant or delayed by several weeks) • May be self-limited (<i>Bartonella</i>) with improvement over a few weeks, but antimicrobials may hasten resolution • Tularemia-associated may be more challenging to diagnose but usually responds to antibiotics⁹² 	<ul style="list-style-type: none"> • Neuroretinitis, vitritis, ptosis • Long-term sequelae rare • Corneal perforation reported with <i>Yersinia enterocolitica</i> and <i>C. trachomatis</i>⁹²
Deficiency Disease (other) Ligneous conjunctivitis	<ul style="list-style-type: none"> • 50% of cases are bilateral, chronic, recurrent conjunctivitis with bilateral, mucoid discharge, tearing, conjunctival injection, followed by pseudomembrane formation of palpebral conjunctiva involving upper eyelid, lower eyelid, or bulbar conjunctiva 	<ul style="list-style-type: none"> • Genetic predisposition (may be inherited in autosomal recessive pattern) with PLG gene • Single report of ligneous and immunoglobulin G4-related disease.⁹⁴ • Females more likely symptomatic • Pseudomembrane growth may be triggered by a local infection or injury⁹⁵ 	<ul style="list-style-type: none"> • Systemic plasminogen deficiency characterized by recurrent mucoid conjunctivitis followed by palpebral fibrinous pseudomembrane formation and mucosal thickening • Can involve systemic pseudomembranous lesions and can be associated with fever, upper respiratory tract infection, ear infections, and/or urogenital tract infection • Associated with congenital hydrocephalus and juvenile colloid milium 	<ul style="list-style-type: none"> • Thick, firm/woody pseudomembranous structures on the palpebral conjunctiva. • Can cause chronic inflammation, corneal scarring, neovascularization, perforation, amblyopia, and vision loss • Can be life threatening if involves the respiratory tract

TABLE 1 TYPICAL CLINICAL SIGNS OF ASSOCIATED/PREDISPOSING FACTORS FOR, AND NATURAL HISTORY OF CONJUNCTIVITIS

Type of Conjunctivitis	Clinical Signs	Associated/Predisposing Factors	Natural History	Potential Sequelae
Pediculosis palpebrarum (<i>Phthirus pubis</i>)	<ul style="list-style-type: none"> Unilateral or bilateral follicular conjunctivitis. Adult lice at the base of the eyelashes, nits (eggs) adherent to the eyelash shafts, blood-tinged debris on the eyelashes and eyelids 	<ul style="list-style-type: none"> Typically, sexually transmitted. May have associated pubic lice or other sexually transmitted diseases. In children, may be an indication of sexual abuse 	<ul style="list-style-type: none"> Blepharitis and conjunctivitis persist until treated 	<ul style="list-style-type: none"> Chronic blepharitis, conjunctivitis, and, rarely, marginal keratitis
Factitious conjunctivitis	<ul style="list-style-type: none"> Unilateral or bilateral. May have injection, discharge, photophobia, possibly pseudomembranes. The more accessible inferior conjunctiva is involved. Bulbar more commonly affected than tarsal conjunctiva. Varied patterns of corneal involvement reported. Presence of foreign bodies. Inconsistent clinical findings⁹⁶ 	<ul style="list-style-type: none"> Mechanical trauma (i.e., scratching, beating, rubbing), chemical assaults, foreign bodies⁹⁷ Underlying psychosocial comorbidity⁹⁸ Younger age⁹⁹ 	<ul style="list-style-type: none"> Chronic ocular signs/symptoms are intentionally produced or feigned solely to assume the “sick role”⁹⁷ Unresponsive to conventional therapies but patching or tarsorrhaphy may serve a diagnostic/therapeutic role 	<ul style="list-style-type: none"> Corneal scarring and neovascularization¹⁰⁰ Severe forms of self-mutilation may escalate to include enucleation

TABLE 1 TYPICAL CLINICAL SIGNS OF ASSOCIATED/PREDISPOSING FACTORS FOR, AND NATURAL HISTORY OF CONJUNCTIVITIS

Type of Conjunctivitis	Clinical Signs	Associated/Predisposing Factors	Natural History	Potential Sequelae
Mucus fishing syndrome	<ul style="list-style-type: none"> Unilateral or bilateral. Signs of underlying disease causing irritation (e.g., dry eye, allergic conjunctivitis, or blepharitis) with excessive mucus and watery discharge, conjunctival injection, conjunctival staining of inferior fornix or globe.¹⁰¹ 	<ul style="list-style-type: none"> Mechanical trauma Associated disease causing irritation (e.g., dry eye, allergic conjunctivitis, or blepharitis) 	<ul style="list-style-type: none"> Starts with irritant or underlying external ocular disease. Cyclical, chronic nature of excessive mucous production and conjunctival inflammation is caused by repetitive mechanical removal of mucus from the surface of the globe or inferior cul-de-sac. 	<ul style="list-style-type: none"> Corneal or conjunctival scarring if repetitive damage from excoriation

NOTE: Typical clinical signs may not be present in all cases. Distinctive signs are most useful in making a clinical diagnosis but may occur uncommonly. In all entities, laterality may vary and may be asymmetrical.

CARE PROCESS

PATIENT OUTCOME CRITERIA

Outcome criteria for treating conjunctivitis include the following:

- ◆ Eliminate or reduce signs and symptoms of conjunctivitis
- ◆ Restore or maintain normal visual function
- ◆ Detect and treat the underlying systemic disease process when applicable
- ◆ Prevent or reduce the likelihood of damage to the ocular surface and eyelids
- ◆ Prevent the spread of infectious conjunctivitis

DIAGNOSIS

The initial evaluation of a patient should include the relevant aspects of the comprehensive medical eye evaluation,^{102, 103} but some elements of the evaluation may be deferred in patients with symptoms and signs suggestive of infectious conjunctivitis.

History

Questions about the following elements of the patient history may elicit helpful information:

- ◆ Symptoms and signs (e.g., conjunctival injection, matting and adherence of eyelids, itching, tearing, discharge, irritation, pain, photophobia, blurred vision)
- ◆ Duration of symptoms and time course
- ◆ Exacerbating factors
- ◆ Unilateral or bilateral presentation
- ◆ Character of discharge
- ◆ Recent exposure to an infected individual
- ◆ Trauma: mechanical, chemical, ultraviolet
- ◆ Recent surgery
- ◆ Mucus fishing behavior (i.e., repetitive manipulation and wiping of the conjunctiva leading to mechanical irritation)
- ◆ Contact lens wear: lens type, hygiene, and use regimen
- ◆ Symptoms and signs potentially related to systemic diseases (e.g., genitourinary discharge, dysuria, dysphagia, fever, upper respiratory infection, skin and mucosal lesions)
- ◆ Allergy, asthma, eczema
- ◆ Use of topical and systemic medications

The ocular history includes details about previous episodes of conjunctivitis, concomitant ocular surface diseases, and previous ophthalmic surgery.

The medical history considers the following:

- ◆ Compromised immune status (e.g., human immunodeficiency virus [HIV], chemotherapy, immunosuppressants)
- ◆ Current or prior systemic diseases (e.g., atopy, SJS /TEN, carcinoma, leukemia, chicken pox, GVHD), vaccination history

The social history should include smoking habits, exposure to second-hand smoke, occupation and hobbies, exposure to air pollutants, travel, exercise habits, diet, sexual activity, and use of illicit drugs.^{18, 19}

Physical Examination

The initial eye examination includes measurement of visual acuity, an external examination, and slit-lamp biomicroscopy. The typical clinical signs for the types of conjunctivitis that are most common or most important to treat are listed in Table 1.

The external examination should include careful evaluation of the following:

- ◆ Regional lymphadenopathy, particularly preauricular

- ◆ Skin: signs of rosacea, eczema, seborrhea
- ◆ Abnormalities of the eyelids and adnexae: swelling, discoloration, malposition, laxity, ulceration, nodules, ecchymosis, neoplasia, lateral flare, lash loss
- ◆ Orbits: fullness, asymmetry
- ◆ Conjunctiva: laterality, type of conjunctival reaction (follicular vs. papillary), distribution (diffuse vs. sectoral or quadrant), subconjunctival hemorrhage, chemosis, cicatricial change, symblepharon, masses, discharge

The slit-lamp biomicroscopy should include careful evaluation of the following:

- ◆ Eyelid margins: inflammation, edema, hyperpigmentation, meibomian gland dysfunction (MGD), ulceration, discharge, nodules or vesicles, blood-tinged debris, keratinization
- ◆ Eyelashes: loss of lashes, crusting, scurf, mites (*Demodex*), nits, lice, trichiasis
- ◆ Lacrimal puncta and canaliculi: pouting, discharge, edema
- ◆ Tarsal and forniceal conjunctiva:
 - ◆ Presence and size of papillae and/or follicles
 - ◆ Cicatricial changes, subepithelial fibrosis, fornix foreshortening, and symblepharon
 - ◆ Forniceal enlargement
 - ◆ Pseudomembranes and true membranes
 - ◆ Ulceration
 - ◆ Hemorrhages
 - ◆ Foreign material
 - ◆ Mucus discharge
 - ◆ Masses
 - ◆ Eyelid laxity
- ◆ Bulbar conjunctiva/limbus: follicles, edema, nodules, chemosis, laxity, papillae, ulceration, scarring, phlyctenules, hemorrhages, foreign material, keratinization
- ◆ Cornea:
 - ◆ Punctate keratopathy
 - ◆ Epithelial defects
 - ◆ Dendritic or pseudodendritic keratitis
 - ◆ Filaments
 - ◆ Infiltration, including subepithelial infiltrates and phlyctenules
 - ◆ Vascularization
 - ◆ Keratic precipitates with or without corneal edema
 - ◆ Ulceration
- ◆ Dye-staining pattern: conjunctiva and cornea (see Appendix 3), tear breakup time
- ◆ Anterior chamber/iris: inflammatory reaction, synechiae, transillumination defects

Diagnostic Tests

Some cases of conjunctivitis can be diagnosed on the basis of history and examination (e.g., viral conjunctivitis in the presence of an upper respiratory infection). In other cases, however, additional diagnostic tests may be helpful.

Cultures

Cultures for routine conjunctivitis (in the absence of listed risk factors) are rarely cost-effective or helpful in deciding on the treatment course. Cultures of the conjunctiva are indicated in all cases of suspected infectious neonatal conjunctivitis.¹⁰⁴ Bacterial cultures and antibiotic susceptibility testing¹⁰⁵ may be helpful for recurrent, severe, or chronic purulent conjunctivitis in any age group and in cases where the conjunctivitis has not responded to medication.

Viral Diagnostic Tests

Viral diagnostic tests are not routinely used in practice to establish the diagnosis of adenovirus, but they may prevent misdiagnosis, disease spread, unnecessary antibiotic use, increased health care costs, and lost productivity. A rapid, in-office immunodiagnostic test

using antigen detection is available for adenovirus conjunctivitis. In a study of 186 patients with acute conjunctivitis, this test had a sensitivity of 88% to 89% and a specificity of 91% to 94%.¹⁰⁶ Immunoassay and immunochromatography testing has demonstrated high specificity for adenovirus but variable sensitivity, ranging between 40% and 93%.^{107, 108} Other highly sensitive and specific tests that may assist in the early diagnosis of adenovirus include Raman spectroscopy of tears and the quantification of hyaluronic acid in tear fluid.^{109, 110} Polymerase chain reaction (PCR) may be used to detect viral deoxyribonucleic acid. Availability will vary depending on the laboratory.

Suspicion of certain less common viruses that can cause conjunctivitis (e.g., arboviruses, measles, COVID-19, Zika, and Mpox) is often based on history, particularly travel, exposures, vaccination status, and on review of systems. The appropriate identification test (often through PCR of a conjunctival sample or serum antibody) can be ordered. Detection of the SARS-CoV-2 (COVID-19) virus in ocular secretions involves reverse transcriptase-PCR, viral culture, or cytopathic effects via sampling from direct conjunctival (or oropharyngeal) swabs, Schirmer's test strips, and glass capillary micropipettes.^{83, 111}

Chlamydial Diagnostic Tests

Suspected cases of adult and neonatal chlamydial conjunctivitis can be confirmed by laboratory testing.¹¹² Immunologically based diagnostic tests are available, including a direct immunofluorescent antibody test and enzyme-linked immunosorbent assay.^{112, 113} These tests have been largely supplanted by PCR for genital specimens, and, therefore, their availability for conjunctival specimens is more limited. Although specimens from the eye have been used with satisfactory performance,¹¹⁴⁻¹¹⁶ these applications have not been approved by the U.S. Food and Drug Administration (FDA). Further testing can be performed through culture.

Smears/Cytology

Smears for cytology and special stains (e.g., Gram, Giemsa) are recommended in cases of suspected infectious neonatal conjunctivitis, chronic or recurrent conjunctivitis, and in cases of suspected gonococcal conjunctivitis in any age group.^{64, 104} Conjunctival scrapings of patients with vernal conjunctivitis often contain eosinophils and mast cells.^{117, 118} Epilation with microscopic examination can allow for detection of mites (e.g., *Demodex*) or pathogens such as lice/nits (e.g., *Phthirus pubis*).¹¹⁹

Biopsy

Conjunctival biopsy may be helpful in cases of conjunctivitis that are unresponsive to therapy or a diagnostic challenge (e.g., factitious). Because such eyes may harbor a neoplasm, directed biopsy may be both vision saving and lifesaving.⁶⁵ Conjunctival biopsy and immunofluorescent staining diagnostic tests may be helpful to establish the diagnosis of diseases such as ocular mucous membrane pemphigoid (OMMP) and paraneoplastic syndromes.^{120, 121} The diagnosis is typically one of exclusion, and a conjunctival biopsy for immunopathology confirms the diagnosis, although false negatives are frequent.¹²² If the biopsy is negative and the disease is progressive, OMMP should be assumed, and multiple biopsies should be avoided. In cases of suspected sebaceous carcinoma, a full-thickness eyelid biopsy is indicated.¹²³ Tissue biopsy from the skin, conjunctiva, lacrimal glands, orbital tissue, lungs, or lymph nodes remains the gold standard for the diagnosis of sarcoidosis and autoimmune vasculitis.¹²⁴ For suspected conjunctival lymphoma, incisional biopsy for histopathological and cytological examination is recommended with immunoprofiling via immunohistochemistry or flow cytometry and/or molecular studies.⁶⁷

Allergy Skin Testing

Allergy skin testing is highly sensitive and specific for aeroallergens. Skin prick testing (SPT) and pollen immunoglobulin E (IgE) detection may be helpful in identifying allergens to target with immunosuppression.

One Italian study showed that of patients with ocular allergy, 82% had positive tests for specific allergic sensitizations.¹²⁵ In vernal keratoconjunctivitis (VKC), a positive SPT identified at least one allergen in 43% to 55% of patients.²⁸

Patch testing can delineate the specific antigens if a delayed-type hypersensitivity (i.e., contact blepharoconjunctivitis) is suspected (e.g., preservatives such as benzalkonium chloride, thimerosal, contact lens solutions).¹²⁶

Tear Immunoglobulin E

Tear IgE quantitatively measures IgE in tears and may be useful in diagnosing allergic conjunctivitis and assessing its severity.¹²⁷ In patients with vernal conjunctivitis, IgE mediated hypersensitivity by component-resolved diagnostics in tears and serum may be helpful.¹²⁸ Component-resolved diagnostics maps the allergen sensitization at a molecular level, using purified natural or recombinant allergenic molecules instead of allergen extracts.

The association of vernal conjunctivitis with allergy/atopy is widely accepted, but it is associated with specific IgE sensitization in less than 50% of cases.

Conjunctival Allergen Challenge

An allergen challenge (provocation test) of the conjunctiva exposes the eyes to increasing concentrations of a specific allergen (that previously elicited a positive skin test reaction) until a reaction is induced on the ocular surface. The subjects evaluate ocular itching and trained clinicians evaluate redness.

Because the challenge reproduces the signs and symptoms of seasonal allergic conjunctivitis, it can be used to test the duration and activity of pharmacologic therapies. Although it is used primarily for study purposes, the challenge may be useful in predicting the impact of preseasonal immunotherapy on symptoms.¹²⁹

Blood Tests

Thyroid antibody tests are indicated for patients with SLK who do not have known thyroid disease.³⁴

Vitamin D level may be lower and serum IgE levels may be higher in patients with allergic conjunctivitis.^{130, 131} The benefits of supplementation with vitamin D are being studied.¹³²⁻¹³⁴ Serum IgE measurements should be considered in cases with inconsistent SPT results or when SPT is not possible.^{135, 136}

Certain serologies may be indicated based on presentation (i.e., *Bartonella henselae* and *Francisella tularensis* in the setting of Parinaud's Oculoglandular syndrome).

Patients with sarcoidosis often have elevated serum angiotensin-converting enzyme levels, elevated serum lysozyme, and/or abnormal liver enzyme tests. Testing for antineutrophil cytoplasmic antibodies may be used to diagnose autoimmune vasculitis, including granulomatosis with polyangiitis, microscopic polyangiitis, and eosinophilic granulomatosis with polyangiitis (Churg-Strauss syndrome).

Along with histopathological examination of the suspected "woody" lesions, low plasminogen activity may confirm suspicion of ligneous conjunctivitis.

Imaging Studies

A chest x-ray, chest computed tomography scan, and/or gallium scintigraphy may aid the diagnosis of sarcoidosis. In cases of Kawasaki disease, a transthoracic echocardiogram may detect cardiac artery abnormalities.

Corneal topography/tomography can be useful to screen for keratoconus in patients with allergic-type conjunctivitis (especially vernal and atopic) and floppy eyelid syndrome.¹³⁷⁻¹³⁹ Corneal biomechanical testing or corneal hysteresis may also have a role in detecting ectasia and keratoconus in this population.¹⁴⁰

Meibomography and anterior segment optical coherence tomography can be used to detect meibomian gland and corneal changes in patients with blepharoconjunctivitis and rosacea.¹⁴¹

MANAGEMENT

Prevention

Early diagnosis and treatment of infectious conjunctivitis is important to reduce the public health and economic impact of community spread. Additionally, patients with serious systemic disease may initially present with conjunctivitis. A thorough review of systems may help identify nonocular symptoms. For example, some types of neonatal conjunctivitis are associated with pneumonia, otitis media, or Kawasaki disease. In adults, conjunctivitis caused by OMMP, GVHD, gonococcus, and chlamydia is important to detect early because it is necessary to treat the concomitant systemic disorder. Diagnosis of SLK may lead to further investigations that reveal a thyroid disorder.^{142, 143} Diagnosis of floppy eyelid may aid in the diagnosis of sleep apnea or keratoconus.¹⁴⁴ Early detection of conjunctivitis associated with neoplasms may be lifesaving.

Individuals can protect against some chemical and toxin exposures by using adequate eye protection. Contact lens wearers can be instructed in appropriate lens care and frequent lens replacement to reduce the risk or severity of giant papillary conjunctivitis.

Allergen-specific immunotherapy is beneficial in reducing allergic conjunctivitis, more so in children than adults.¹⁴⁵ Both subcutaneous and sublingual immunotherapy have been found to reduce symptoms and medication requirements in patients with allergic rhinoconjunctivitis.¹⁴⁶ (*I-, Moderate, Strong*) A multidisciplinary approach with pediatricians, internists, and allergists is essential in managing ocular hypersensitivity disorders.

Infectious conjunctivitis can be prevented with prophylactic treatment, applying vaccination strategies, and breaking chains of transmission. Neonatal conjunctivitis can often be prevented by means of prenatal screening and treatment of the expectant mother and by prophylactic treatment of the infant at birth. Single-use tubes of ophthalmic ointment containing 0.5% erythromycin are used as the standard prophylactic agent to prevent ophthalmia neonatorum.¹¹⁻¹⁴⁷ (*I+, Insufficient, Strong*) Povidone-iodine solution 2.5% has been suggested as an alternative to antibiotic ointments to prevent neonatal conjunctivitis,^{148, 149} but it may be less effective and more toxic to the ocular surface.¹⁵⁰

The incidence of varicella (herpes) zoster virus is reduced by the chickenpox and the shingles vaccines. Currently, there is one herpes zoster vaccine available for adults in the United States: recombinant zoster vaccine (RZV). Zoster vaccine live was discontinued in November 2020. Ophthalmologists and other health care professionals should strongly recommend immunocompetent patients 50 years or older without contraindications to obtain vaccination against herpes zoster.¹² The vaccine is also recommended for immunocompromised patients 19 years and older.

The spread of measles can be effectively limited by vaccination. The CDC and the World Health Organization strongly recommend measles vaccination for children age 1 year and older and adults born in 1957 or later who do not display measles immunity.¹⁵¹ The spread of epidemic adenoviral conjunctivitis can be limited by educating the patient and family about proper hygiene. Infected individuals should be counseled to wash hands frequently with soap and water (as opposed to sanitizer only), use separate towels and pillows, and avoid close contact with others during the period of contagion. Avoiding contact with others is especially important for individuals in professions with high potential for transmission, such as healthcare workers and childcare providers. Although the exact length of the period of infectivity is variable, many consider 7 days from the onset of symptoms (in the second eye, when involved) as the contagious period, because the recovery of virus from infected cases is difficult after 7 to 10 days of infection.¹⁵² Other studies have suggested that patients should be considered potentially contagious for at least 10 to 14 days.^{153, 154}

Health care facilities have occasionally been associated with epidemic outbreaks of adenoviral keratoconjunctivitis that may last from weeks to years.^{6, 153-157} To avoid cross-contamination,

multiple-dose eyedrop containers should be discarded after inadvertent contact with the ocular surface.¹⁵⁸ Hand-washing procedures with antimicrobial soap and water¹⁵⁹ and disinfecting or using disposable ophthalmic equipment may reduce the risk of transmission of viral infection, as the virus can remain infectious in a desiccated state on surfaces for up to 28 days.^{160, 161}

The CDC and tonometer manufacturers recommend dilute bleach soaks (sodium hypochlorite) at 1:10 concentration for effective disinfection against adenovirus and HSV, the viruses most commonly associated with transmission in offices and subsequent outbreaks. Tonometer tips should be wiped clean and then disinfected by immersing them for 5 to 10 minutes in dilute bleach. Any disinfecting agent can result in iatrogenic corneal de-epithelialization and haze if not properly removed from the tonometer tip before use by thorough rinsing in tap water and air drying.⁶

Although it is a common practice, wiping the tonometer tip with a 70% isopropyl alcohol wipe does not provide adequate disinfection after exposure to a patient who has adenoviral keratoconjunctivitis.⁷ Disinfecting agents can also cause damage to the tonometer tip. Though not widely used due to increased cost, disposable tonometer tips can also be considered to eliminate cross infections.¹⁶² Alternatively, intraocular pressure (IOP) can be checked using a tonometer with a disposable coverlet.

Tonometer manufacturers recommend replacing tonometer prisms every 2 years, after a maximum of 100 disinfection cycles with 1:10 sodium hypochlorite, or if damaged.^{7, 163, 164}

Exposed surfaces on equipment can be decontaminated by wiping with sodium hypochlorite (a 1:10 dilution of household chlorine bleach) or other appropriate disinfectants.^{158, 159, 165} Surfaces should be disinfected with an EPA-registered hospital disinfectant in accordance with the label's use directions and safety precautions.

Despite the use of reasonable measures, it may not be possible to prevent all transmission of viral infection. Unless absolutely necessary, deferring IOP measurement for a patient with acute conjunctivitis should be considered. Attention should be paid to disinfecting items in addition to tonometer tips that may have come in contact with the patient's ocular secretions. During an active epidemic, consideration should be given to triaging patients upon arrival to the office and directing those who appear infected to a dedicated "red-eye room."

Treatment

Treatment of conjunctivitis is ideally directed at the root cause. Early detection and treatment can be both sight saving and, in select cases, lifesaving. Indiscriminate use of topical antibiotics or corticosteroids should be avoided because antibiotics can induce toxicity, and corticosteroids can potentially prolong adenoviral infections and worsen HSV infections. Treatment methods are described below for the most common types of conjunctivitis and for those types that are particularly important to treat.

Seasonal/Perennial Allergic Conjunctivitis

Recommendations often include wearing sunglasses as a barrier to airborne allergens, cold compresses, refrigerated artificial tears, avoiding eye rubbing, and avoiding allergens. Hypoallergenic bedding, eyelid cleansers to remove allergens, frequent clothes washing, and bathing/showering before bedtime may also be helpful.

Mild allergic conjunctivitis can be treated with an over-the-counter topical antihistamine/vasoconstrictor agent or with more effective second-generation topical histamine H₁-receptor antagonists.¹⁶⁶⁻¹⁶⁹ Many topical medications can be stored in the refrigerator, as the cooling sensation upon instillation of the eye drop can provide symptomatic relief. Chronic use of vasoconstrictor agents can be associated with rebound vasodilation once the agent is stopped. If the condition is frequently recurrent or persistent, mast-cell stabilizers can be used.¹⁶⁶ Many new medications combine antihistamine activity with mast-cell stabilizing properties and can be used for either acute or chronic disease.^{168, 170-176}

The use of topical mast-cell inhibitors can also be helpful in alleviating the symptoms of allergic rhinitis. Mast-cell inhibitors formulated as a nasal spray and aerosols are also helpful in alleviating the symptoms of allergic rhinitis and asthma in some patients.¹⁷⁷

If the symptoms are not adequately controlled, a brief course (1 to 2 weeks) of topical corticosteroids with a low side effect profile can be added to the regimen. Table 2 lists topical medications that can be used for seasonal allergic conjunctivitis. Oral antihistamines are commonly used but may induce or worsen dry eye syndrome and impair the tear film's protective barrier.¹⁷⁸ Concomitant use of cooled preservative-free artificial tears may alleviate coexisting tear deficiency and dilute allergens and inflammatory mediators on the ocular surface.^{179, 180} In severe cases, topical cyclosporine or tacrolimus can be considered.¹⁸¹⁻¹⁸³

TABLE 2 TOPICAL MEDICATIONS FOR SEASONAL ALLERGIC CONJUNCTIVITIS

Generic Name	Trade Name	Class	Typical Daily Dose
Alcaftadine	Lastacaft	H ₁ -antagonist	1
Azelastine HCl	Generic	H ₁ -antagonist/mast-cell inhibitor	2
Bepotastine besilate	Bepreve	H ₁ -antagonist/mast-cell inhibitor	2
Cromolyn sodium	Generic	Mast-cell inhibitor	4-6
Epinastine HCl	Generic	H ₁ - and H ₂ -antagonist/mast-cell inhibitor	2
Ketorolac tromethamine	Acular, Acular LS	NSAID [†]	4
Ketotifen fumarate	Alaway, Zaditor (OTC)	H ₁ -antagonist/mast-cell inhibitor	2
Lodoxamide tromethamine	Alomide	Mast-cell inhibitor	4
Loteprednol etabonate (0.2% or 0.5%)	Alrex, Lotemax	Corticosteroid [‡]	4
Naphazoline/antazoline	Vasocon-A (OTC)	Antihistamine/decongestant	4
Naphazoline/pheniramine	Naphcon-A (OTC) Opcon-A (OTC) Visine-A (OTC)	Antihistamine/decongestant/ Vasoconstrictor*	4
Nedocromil sodium	Alocril	Mast-cell inhibitor	2
Olopatadine HCl	Pataday Twice Daily (0.1%) Pataday Once Daily (0.2%) Pataday Once Daily Extra Strength (0.7%)	H ₁ -antagonist/mast-cell inhibitor	2 1 1
Cetirizine	Zerviate	H1 antagonist	2

Adapted with permission from PDR Network LLC. Table 11. Agents for Relief of Seasonal Allergic Conjunctivitis. In: *PDR® for Ophthalmic Medicines 2012*, 40th ed. Montvale, NJ: PDR Network LLC; 2011:9. Updated November 2022¹⁸⁴

HCL = hydrochloride; NSAID = nonsteroidal anti-inflammatory drug; OTC = over the counter.

* Caution: Should not be used long term owing to rebound vasodilation.

† Use with caution in patients who have ocular surface disease.

‡ Increased intraocular pressure, cataractogenesis.

Consultation with an allergist or dermatologist may be helpful for patients who have disease that cannot be adequately controlled with topical medications and oral antihistamines. Allergen-specific immunotherapy, in which increasing subcutaneous or sublingual doses of the trigger allergens are administered to achieve hyposensitization, are useful,^{145, 185-188} (*I+*, *Moderate*, *Strong*) but usage may be limited by expense, long-term patient commitment, and the risk of anaphylaxis.¹⁸⁹⁻¹⁹¹ (*I-*, *Moderate*, *Discretionary*)

Intralymphatic immunotherapy, which appears to also provide short-term benefits, has unclear efficacy beyond a year.¹⁹² (*I-, Moderate, Discretionary*)

Frequency of follow-up visits is based on the severity of disease presentation, etiology, and treatment. Timing of visits during symptomatic periods should be considered. A follow-up visit should include an interval history, measurement of visual acuity, and slit-lamp biomicroscopy. If corticosteroids are used in chronic or recurrent conjunctivitis, baseline and periodic measurement of IOP and pupillary dilation should be performed to evaluate for glaucoma¹⁹³ and cataract. Allergic conjunctivitis and atopic disease are associated with keratoconus—in these cases, adequate control of allergy and eye rubbing are important to decrease progression of ectasia.¹⁹⁴⁻¹⁹⁷ (This is discussed in more detail in the Corneal Ectasia PPP.¹⁹⁸)

Vernal Conjunctivitis

Strategies to treat vernal conjunctivitis parallel stepwise treatment in other ocular surface hypersensitivity disorders such as perennial allergic conjunctivitis. General treatment measures include modifying the environment to minimize exposure to allergens or irritants and using cool compresses and ocular lubricants. Topical and oral antihistamines and topical mast-cell stabilizers can be useful to maintain comfort.

For acute exacerbations of vernal conjunctivitis, topical corticosteroids are usually necessary to control severe symptoms and signs.^{8,9} (*I-, Moderate, Strong*) Topical cyclosporine 2% has demonstrated a reduction in signs and symptoms compared with placebo after 2 weeks of use in patients with VKC.^{199,200} Commercially available 0.05% topical cyclosporine used at least four times daily has also been shown to be effective for the treatment of severe vernal conjunctivitis, and it has been shown to be effective in preventing seasonal recurrences.²⁰¹⁻²⁰⁵ Cyclosporine 0.1% is the first and only topical immunomodulator FDA approved for the specific treatment of VKC in children and adults.²⁰⁶ Use of cyclosporine, interferon-alpha-2b, and tacrolimus may allow for reduced use of topical steroids²⁰⁷ and in cases refractory to steroid treatment.^{208,209} For severe sight-threatening vernal keratoconjunctivitis that is not responsive to topical therapy, supratarsal injection of corticosteroid can be considered.²¹⁰

Atopic Conjunctivitis

As with other ocular hypersensitivity disorders, conservative strategies to reduce allergen exposure with hand hygiene and lubrication are combined with milder therapies to reduce IgE response via antihistamines and mast cell stabilizers. Next-line therapies for moderate disease include topical corticosteroids and topical calcineurin inhibitors such as cyclosporine and tacrolimus targeted at T-cell activity.

Tacrolimus is available as a 0.03% and 0.1% topical ointment for dermatologic use in the United States (Protopic). It has been used off label for treatment of ophthalmic disease.²¹¹

In patients 2 years old or older, eyelid involvement can be treated with pimecrolimus cream 1% or topical tacrolimus ointment.²¹²⁻²¹⁴ Tacrolimus drops/ointment 0.03% is used for children 2 years to 15 years old; either 0.03% or 0.1% is used for patients 16 years and older.²¹⁵ Randomized clinical trials have demonstrated the efficacy of topical tacrolimus 0.1% applied conjunctivally in patients who had failed conjunctivitis therapy with topical corticosteroids, cyclosporine, and/or antiallergy medications.²¹⁶ These agents may make patients more susceptible to herpes simplex keratitis.²¹⁷ Systemic therapies are rarely warranted, but options include montelukast,²¹⁸ aspirin, and oral T-cell inhibitors, such as cyclosporine and tacrolimus.^{32, 117, 207, 219-221} The efficacy of these systemic treatments are inconclusive as there are no randomized trials.²²² (*Insufficient, Discretionary*) Tacrolimus or pimecrolimus are rarely associated with development of skin cancer or lymphoma.^{223, 224}

For all forms of allergic conjunctivitis, which may require repeat short-term therapy with topical corticosteroids, patients should be informed about potential complications of corticosteroid therapy, and general strategies to minimize corticosteroid use should be employed.

Frequency of follow-up visits is based on the severity of disease presentation, etiology, and treatment. Consultation with a dermatologist is often helpful. A follow-up visit should include an interval history, measurement of visual acuity, and slit-lamp biomicroscopy. If corticosteroids are prescribed, baseline and periodic measurement of IOP and pupillary dilation should be performed to evaluate for glaucoma and cataract. Discussion of treatment of complications such as corneal plaques and ulceration is beyond the scope of this document.²²⁵ Keratoconus, which is also associated with allergic and vernal conjunctivitis, is discussed in more detail in the Corneal Ectasia PPP.¹⁹⁸ Notably, vernal and atopic keratoconjunctivitis should be controlled prior to corneal cross-linking to decrease the risk of developing sterile keratitis.²²⁶

Superior Limbic Keratoconjunctivitis

Mild cases of SLK may respond to treatment of concomitant dry eye syndrome with lubricants, mast-cell stabilizers, cyclosporine,²²⁷ soft contact lenses, and/or punctal occlusion; however, the condition may not respond or the response may be temporary. Associated filamentary keratitis may occasionally respond to topical 10% acetylcysteine²²⁸ or hypertonic (5%) saline.²²⁹ The exact pathogenesis of SLK is unclear.²³⁰ Persistent symptoms may necessitate surgical intervention such as cautery (chemical or thermal) to tighten redundant conjunctiva or conjunctival resection.²³¹ Up to 65% of patients with SLK may have underlying thyroid dysfunction, and many of these have associated ophthalmopathy.³⁵ An underlying thyroid disorder should be investigated by means of thyroid antibody tests.^{34, 35} Because SLK may persist with exacerbations over a period of years, treatment and frequency of follow-up are driven by the patient's symptoms. Systemic treatment of underlying thyroid disease does not have an impact on the SLK, however. Patients should be informed that this is a chronic and recurrent condition that rarely can decrease vision.

Blepharoconjunctivitis

See the Blepharitis PPP.³⁷

Rosacea Conjunctivitis

Treatments include eyelid hygiene, warm compresses, systemic tetracyclines, topical corticosteroids and cyclosporine, topical metronidazole creams and ointment, mechanical thermal pulsations, and intense pulse light therapy. (See the Blepharitis PPP³⁷ for more details.)

Contact Lens-Related Keratoconjunctivitis

This phenomenon is essentially hypoxia of the limbal stem cells creating punctate epithelial keratitis, pannus, neovascularization, inflammation, edema, and ultimately epitheliopathy, which can impact visual function and, if ignored, can be permanent. If moderate or severe pain is present, amoebic keratitis should be considered. In cases of contact lens-related keratoconjunctivitis, contact lens wear should be discontinued until the cornea returns to normal. In mild cases, a brief (1 to 2 weeks) course of topical corticosteroids may be prescribed, in addition to longer-term use of topical cyclosporine 0.05%. If related to limbal stem cell failure, symptoms may be prolonged, but they will usually ultimately clear with contact lens abstinence.²³²⁻²³⁴ At the follow-up evaluation, the contact lens fit, type, and care regimen should be reviewed (e.g., nonpreserved lens care systems, daily disposable contact lenses, high DK/T ratio material, lens materials, reduction in contact lens wear time) and consideration should be given to alternatives to contact lenses (e.g., eyeglasses or refractive surgery) once the keratoconjunctivitis has resolved. Contact lens abstinence can be a challenge for some patients because the punctate keratopathy may lead to reduced vision correction in glasses.

Giant Papillary Conjunctivitis

The treatment of GPC generally involves modifying the causative entity. Protruding suture knots can be treated by removing or replacing the sutures, rotating the knots, or using a

therapeutic contact lens. However, long-term use of therapeutic contact lenses may be associated with an increased risk of microbial keratitis and GPC. Ocular prostheses that cause GPC can be cleaned, polished, or replaced. Mild contact lens-related GPC may respond to replacing lenses more frequently, decreasing contact lens wearing time, using preservative-free lens care systems, administering mast-cell stabilizing agents,²³⁵ refitting contact lenses, switching to daily disposable lenses, and/or changing the contact lens polymer. Associated abnormalities such as aqueous tear deficiency and MGD should be treated. In GPC, discontinuation of contact lens use in conjunction with topical anti-inflammatory agents may be effective.²³⁶ If corticosteroids are used for conjunctivitis, baseline and periodic measurement of IOP and pupillary dilation should be performed to evaluate for glaucoma and cataract.

Frequency of follow-up visits is based on the severity of disease and treatment used. At the follow-up visit, an interval history, measurement of visual acuity, and slit-lamp biomicroscopy should be performed.

Floppy Eyelid Syndrome

Temporary relief of floppy eyelid syndrome is afforded by taping the patient's eyelids shut or by having the patient wear a protective shield while sleeping.^{237, 238} Lubricants may help in managing mild cases. Definitive therapy involves surgical procedures such as lateral canthus repair,²³⁹ horizontal shortening of the upper eyelid, or excision of the medial upper lid.²⁴⁰⁻²⁴³ Follow-up depends on the patient's clinical course. Floppy eyelid syndrome has been associated with obstructive sleep apnea, keratoconus, and obesity,²⁴⁴⁻²⁴⁶ and providers may consider consultations with specialists.²⁴⁷

Giant Fornix Syndrome

Cultures are nearly always positive for *Staphylococcus aureus*, although other organisms are possible.^{42, 248} Many patients have concomitant nasolacrimal duct obstruction and chronic dacryocystitis, which may need to be addressed surgically. Treatment with antibiotic regimens used for routine cases of bacterial conjunctivitis generally result in only temporary improvement. Recommended treatment strategies include the prolonged use of systemic anti-staphylococcal antibiotics and intensive topical antibiotics and corticosteroids. More recently, supratarsal injections of antibiotics and corticosteroids, along with irrigation and sweeping of the superior fornix with povidone-iodine solution, have been advocated.^{249, 250} Given the increasing frequency of methicillin-resistant *S. aureus* (MRSA) in the general population, conjunctival cultures before starting treatment can help guide the appropriate choice of antibiotic. In addition, surgical correction of ptosis may be helpful.

Pediculosis Palpebrarum (*Phthirus pubis*)

Forceps can be used to mechanically remove the adult lice and nits (eggs) from the eyelids and eyelashes. Adherent nits may require epilation of the involved lashes. Cutting the lashes at their base with Westcott or other microsurgical scissors is an alternative for heavy infestation of adherent nits. A bland ophthalmic ointment (e.g., petrolatum, erythromycin, bacitracin) applied two to three times a day for 10 days will smother the adult lice and nits. Compliance is important for eradication. Patients and close contacts should be advised to use anti-lice lotion and shampoo for nonocular areas and to wash and dry clothing and bedding thoroughly (using the highest temperature of the dryer for 30 minutes). Patients and sexual contacts should be informed about the possibility of concomitant disease and should be referred appropriately. Sexual abuse should be considered in children with *P. pubis* infestation.

Medication-induced/Preservative-Induced Keratoconjunctivitis

Discontinuation of the agent responsible for medication-induced keratoconjunctivitis usually results in resolution over a period of weeks to months. If severe inflammation of the conjunctiva or eyelid is present, a brief course of topical corticosteroids is indicated, often with preservative-free formulations²⁵¹ At follow-up visits, the clinician should look

for early signs of cicatricial changes such as subconjunctival fibrosis. In severe cases, cicatricial changes may progress despite removing the offending medication.²⁵²

Ocular Mucous Membrane Pemphigoid Conjunctivitis

Topical corticosteroid therapy may aid in controlling acute conjunctival inflammation, but systemic immunosuppressive therapy is required to inhibit inflammation, prevent keratopathy, and prevent progression of conjunctival scarring.¹²² Because OMMP is a chronic, progressive disease characterized by subepithelial fibrosis with frequent remissions and exacerbations of disease activity, it may be difficult to gauge the response to therapy accurately. Grading systems and photographic documentation of the conjunctiva may be helpful to assess disease progression.^{121, 253} Mild and slowly progressive disease may be treated using mycophenolate mofetil, dapsone, azathioprine, or methotrexate.²⁵⁴⁻²⁵⁶ If dapsone is considered, caution should be taken in patients with glucose-6-phosphate dehydrogenase (G6PD) deficiency.²⁵⁷ For severe inflammation or for inflammation unresponsive to treatment with other agents, cyclophosphamide should be considered.^{254, 258} Other therapies that may be effective for treatment or adjunctive therapy include oral tetracycline and niacinamide,²⁵⁹ sulfasalazine,²⁶⁰ mycophenolate mofetil,^{255, 256, 261, 262} intravenous immunoglobulin,²⁶³ and biologics.²⁶¹ These therapies can be used alone or in combination. Refractory cases may benefit from combination intravenous immunoglobulin and rituximab.²⁶⁴ In general, a physician with expertise in immunosuppressive therapy should administer and monitor the treatment to minimize and manage side effects.^{265, 266} Associated dry eye state should be treated aggressively, and trichiasis, distichiasis, and entropion should be treated nonsurgically if possible. Mucous membrane or amniotic membrane grafting for fornix reconstruction may be considered. In advanced disease with corneal blindness, keratoprosthesis surgery may improve vision, however, all ocular reconstructive surgery is considered high risk.^{14, 267, 268}

The timing and frequency of follow-up visits is based on the severity of disease presentation, etiology, and treatment. A follow-up visit should include an interval history, visual acuity measurement, slit-lamp biomicroscopy, and documentation of corneal and conjunctival changes to monitor progression. Ocular procedures such as cataract surgery may worsen the disease. Perioperative immunosuppression and close postoperative follow-up are warranted in such cases.²⁵⁸

Graft-versus-Host Disease

Patients with multiorgan systemic GVHD are treated with systemic immunosuppression. Systemic corticosteroids are the mainstay of initial treatment and are commonly used in conjunction with a T-cell inhibitor (cyclosporine or tacrolimus). In corticosteroid-refractory GVHD, numerous therapies have been studied, including cyclophosphamide, biologics, and photopheresis,²⁶⁹ with varied success depending on the tissues involved and the severity of the disease.

For ocular GVHD, aggressive lubrication is particularly useful in treating patients with secondary keratoconjunctivitis sicca. Punctal occlusion can be considered. There is a role for topical corticosteroids in treating conjunctival hyperemia and scarring.²⁷⁰ Topical T-cell modulator (cyclosporine) and autologous serum tears can be used to treat dry eye syndrome associated with GVHD.²⁷¹⁻²⁷⁴ Treating the underlying inflammatory may help to reduce conjunctival damage leading to dry eye disease. Other secondary complications of ocular GVHD, such as cicatricial eyelid malposition or limbal stem cell failure, should be managed on a case-by-case basis. For vision correction and relief from dry eye symptoms in these patients, scleral lenses maybe helpful.²⁷⁵⁻²⁷⁷

Stevens-Johnson Syndrome/Toxic Epidermal Necrolysis

Early intervention is critical to prevent late ocular complications.²⁷⁸⁻²⁸⁰ Acutely, SJS/TEN ranges from hyperemia of the conjunctiva to complete sloughing of the ocular surface epithelium. Medical management with topical lubricants, antibiotics, and anti-inflammatories is recommended.²⁸¹ Eyelid hygiene and periodic sweeping of the conjunctival fornices may interrupt synechiae formation.²⁷⁸ Early amniotic membrane transplantation on the ocular surface and eyelid margin is highly recommended to stabilize

the ocular surface and prevent and treat cicatrization and conjunctival and corneal defects.^{282, 283}

Sebaceous Carcinoma

When a diagnosis of sebaceous carcinoma is confirmed by an eyelid biopsy, excision is indicated. The excision should be performed by a surgeon experienced in the treatment of eyelid tumors, and adjunctive therapy should be used as needed for any residual pagetoid component.²⁸⁴ If uncertainty in labelling, handling, or processing of the specimen exists, prior discussion with the pathologist who is to prepare and read the specimen is beneficial.

Ocular Surface Squamous Neoplasia

When a diagnosis of ocular surface squamous neoplasia is confirmed by biopsy, treatment may consist of local excision with cryotherapy to the edges²⁸⁵ and/or topical chemotherapeutic agents (mitomycin-C or fluorouracil). Interferon, an effective topical therapy for ocular surface squamous neoplasia, is no longer manufactured.²⁸⁶ Some studies have indicated that topical chemotherapeutics alone may completely lead to resolution of the malignancy. The optimal treatment should be tailored to the patient/tumor needs and be done by an experienced specialist.²⁸⁷ Anterior segment optical coherence tomography may facilitate diagnosis and follow-up for patients with ocular surface squamous neoplasia.

Adenoviral Conjunctivitis

The majority of cases of acute, infectious conjunctivitis in the adult population are viral and self-limited; these cases do not require antimicrobial treatment. Patients with adenoviral conjunctivitis need to understand that the condition is highly contagious and that this is a hearty virus that can survive for many weeks on a countertop or similar surface if careful disinfection doesn't occur. Because of its ability to infect multiple members of a family, classmates at school, or staff or clients at work, this infection is often termed epidemic keratoconjunctivitis (EKC).²⁸⁸ The patient should be educated about measures that will help reduce the spread of this infection⁶ and encouraged to make every attempt to minimize contact with other people for 10 to 14 days from the onset of symptoms in the last eye affected.²⁸⁹

To minimize spread within the clinic, consider an abbreviated exam in a dedicated exam room with limited physical interaction. Physical exam may include swollen and tender preauricular or submandibular lymph nodes. Slit-lamp exam should focus on identifying membranes or pseudomembranes, corneal epithelial defects, dendrites, filaments, or infiltrates. Depending on exam findings, follow-up might be a couple days to 1 to 2 weeks. The clinician is often asked for advice on how to balance public health concerns and work/school requirements. This can be a particularly difficult issue for patients working in health care, food service, or sales.²⁹⁰ Some occupations allow for work at home or from the privacy of an individual office or similar setting.

There is no proven effective treatment for eradication of adenovirus infection; however, artificial tears, topical antihistamines, topical steroids, oral analgesics, or cold compresses may be used to mitigate symptoms. The use of antibiotics in the management of this viral infection should be avoided because of potential adverse treatment effects.

Topical corticosteroids are helpful to reduce symptoms and may reduce scarring in severe cases of adenoviral keratoconjunctivitis with marked chemosis or eyelid swelling, epithelial sloughing, or membranous conjunctivitis. Close follow-up is warranted for patients with adenoviral conjunctivitis who are being treated with corticosteroids. In an animal model of adenoviral conjunctivitis, administration of topical corticosteroids led to prolonged viral shedding.²⁹¹ It is not known whether this is the case in humans. Because of its broad antimicrobial spectrum, povidone-iodine has been investigated as a treatment consideration.²⁹² Off-label use of topical ganciclovir 0.15% ophthalmic gel has been investigated for the treatment of EKC and has shown potential benefit against specific adenovirus serotypes, but further efficacy on a larger scale needs to be demonstrated before definitive recommendations can be made.²⁹³ For patients with membranous conjunctivitis, debridement of the membrane can be considered to prevent corneal epithelial abrasions or permanent cicatricial changes (e.g., foreshortening of the conjunctival fornix).

Patients with severe disease who have corneal epithelial ulceration or membranous conjunctivitis should be re-evaluated within 1 week. Patients who are prescribed prolonged topical corticosteroids should be monitored by periodically measuring IOP and pupillary dilation to evaluate for glaucoma and cataract. Topical corticosteroids should be tapered once inflammation is controlled.

Patients who are not treated with topical corticosteroids should be instructed to return for follow-up if they continue to experience symptoms of red eye, pain, or decreased vision after 2 to 3 weeks. This follow-up visit should include an interval history, measurement of visual acuity, and slit-lamp biomicroscopy.

During follow-up, patients should be evaluated for the presence of corneal subepithelial infiltrates, which typically occur 1 or more weeks after the onset of conjunctivitis. Treatment of subepithelial infiltrates varies with the severity of the disease. In mild cases, observation is sufficient. In cases with blurring, photophobia, and decreased vision, topical corticosteroids at the minimum effective dose may be considered. Cyclosporine drops ranging from commercially available concentrations of 0.05% to higher compounded dosages of 1% have been found to be a helpful alternative in reducing subepithelial infiltrates.^{294, 295}

Patients who are being treated with topical corticosteroids should have the dosage slowly tapered to the minimum effective dose. Corticosteroids with poor ocular penetration, including fluorometholone or site-specific corticosteroids such as loteprednol, may be less likely to result in elevated IOP or cataract formation. Follow-up examinations should be conducted regularly. Visits should include an interval history, measurement of visual acuity and IOP, and slit-lamp biomicroscopy. Recurrence of subepithelial infiltrates has been reported in patients with a history of adenoviral infection who have undergone photorefractive keratectomy or LASIK.²⁹⁶

Herpes Simplex Virus Conjunctivitis

Herpes simplex virus conjunctivitis is a self-limited acute condition. Treatment is usually instigated upon high suspicion or concomitant corneal involvement. Possible topical options include ganciclovir 0.15% gel used three to five times per day²⁹⁷ or trifluridine 1% solution five to eight times per day.²⁹⁸ Oral treatments for HSV conjunctivitis include acyclovir (200 to 400 mg five times a day), valacyclovir (500 mg two or three times a day), or famciclovir (250 mg twice a day). Anecdotal experience suggests that higher doses of oral antivirals may also be effective in cases that appear to demonstrate resistance to therapy. Topical trifluridine inevitably causes epithelial toxicity if used for more than 2 weeks. Topical ganciclovir is less toxic to the ocular surface.²⁹⁹ Oral antivirals alone may not be adequate in preventing the progression of HSV blepharoconjunctivitis, but the addition of topical antiviral treatment has been effective.³⁰⁰ Lower doses of oral antivirals are considered for long-term prophylaxis against recurrent HSV conjunctivitis and keratitis. Topical corticosteroids potentiate HSV epithelial infections and should be avoided. Within 1 week of treatment, patients should have a follow-up visit consisting of an interval history, visual acuity measurement, and slit-lamp biomicroscopy. Neonates require prompt consultation with the pediatrician or primary care physician, because systemic HSV infection is a life-threatening condition.³⁰¹

Varicella (Herpes) Zoster Virus Conjunctivitis

Children with chicken pox may present with conjunctivitis that is sometimes associated with eyelid ulceration and/or limbal or conjunctival vesicles. Many clinicians treat such patients with topical antibiotics to prevent secondary infection because the vesicles will undergo necrosis before healing. Severe conjunctival scarring from secondary bacterial infection can even lead to cicatricial ectropion.³⁰² Topical antivirals alone have not been shown to be helpful in treating VZV conjunctivitis but may be used as additive treatment in unresponsive patients.³⁰³ In rare cases, dendritic or stromal keratitis can occur. Varicella zoster virus conjunctivitis can be associated with other forms of ocular disease including pseudodendrites, keratitis, corneal scarring, corneal vascularization, iritis/uveitis, sectoral iris atrophy, and secondary glaucoma.³⁰⁴ With persistent or recalcitrant acute/subacute

disease in immunocompetent patients, oral antivirals may be beneficial at a dose of 800 mg five times daily for 7 days for acyclovir, 1000 mg every 8 hours for 7 days for valacyclovir, or 500 mg three times daily for 7 days for famciclovir.³⁰⁵⁻³⁰⁷ Patients who have chronic disease may require prolonged treatment with adjustment of the dose according to the clinical response. Patients with chronic sequelae may require prolonged treatment and/or long-term prophylaxis. Immunocompromised patients may need to be treated more aggressively. Caution is advised when using systemic antiviral therapy in patients with impaired renal clearance. Late sequelae include dry eye and corneal anesthesia with neurotrophic keratitis.³⁰⁸

Molluscum Contagiosum

Conjunctivitis and keratitis from molluscum contagiosum are due to viral shedding from the eyelid lesion(s) onto the surface of the eye. Molluscum lesions may spontaneously resolve, but they can also persist for months to years. Treatment to remove the lesions is indicated in symptomatic patients. Treatment options include incision and curettage (aggressive enough to cause bleeding), simple excision, excision and cautery, and cryotherapy. In patients with multiple lesions, care should be taken to identify and treat nascent lesions in order to reduce the risk of recurrence, but reduction of the viral load often allows the host immunologic response to eliminate residual virus. The conjunctivitis may require weeks to resolve after elimination of the lesion. In adults, large and multiple molluscum lesions with relatively little conjunctival inflammation may indicate an immunocompromised state.³⁰⁹ Follow-up is not usually necessary unless the conjunctivitis persists. Referral to a dermatologist may be necessary for examination of other suspicious lesions.

Bacterial Conjunctivitis

Mild Bacterial Conjunctivitis

Mild bacterial conjunctivitis is usually self-limited, and it typically resolves spontaneously without specific treatment in immune-competent adults.^{10, 251} Use of topical antibacterial therapy is associated with earlier clinical and microbiological remission compared with placebo in days 2 to 5 of treatment.²⁵¹ These advantages persist over days 6 to 10, but the extent of benefit over placebo lessens over time.²⁵¹ Treatment may reduce transmissibility and allow for an earlier return to school for children.³¹⁰ The choice of antibiotic is usually empiric. Because a 5- to 7-day course of a broad-spectrum topical antibiotic is usually effective, the most convenient or least expensive option can be selected; there is no clinical evidence suggesting the superiority of any particular antibiotic. Povidone-iodine 1.25% ophthalmic solution may be as effective as topical antibiotic therapy for treating bacterial conjunctivitis and could be considered when access to antibiotics is limited, such as in the low- to middle-income countries.³¹¹ Although there are no data supporting the cost-effectiveness of using antibiotics in mild bacterial conjunctivitis, the shortened morbidity associated with their use makes choice of therapy an individual decision.^{251,312}

Moderate to Severe Bacterial Conjunctivitis

Moderate to severe bacterial conjunctivitis is characterized by copious purulent discharge, pain, and marked inflammation of the eye. Conjunctival cultures and slides for Gram staining should be obtained if gonococcal infection is a possibility. In these cases, the choice of antibiotic is guided by the results of laboratory tests. Methicillin-resistant *S. aureus* has been isolated with increasing frequency from patients with bacterial conjunctivitis.^{313, 314} Increasing colonization of MRSA has been found in nursing home residents,³¹⁵ and the incidence of community-acquired MRSA infections also has risen.³¹⁶ Methicillin-resistant *S. aureus* organisms are resistant to many commercially available topical antibiotics.^{313, 314, 317} An epidemiologic study found that infants within the neonatal intensive care setting due to low birth weight and/or low gestational age have an increased incidence of gram-negative conjunctivitis that is often resistant to gentamicin.³¹⁸

Microbiology laboratory testing may guide therapy, which may include compounded topical antibiotics such as vancomycin (see Bacterial Keratitis PPP³¹⁹).

Gonococcal Conjunctivitis

Systemic antibiotic therapy is necessary to treat gonococcal conjunctivitis (see Appendix 4) Saline lavage may promote comfort and more rapid resolution of inflammation. If there is corneal involvement, topical treatment as for bacterial keratitis (see Bacterial Keratitis PPP³¹⁹) should be added. Patients and sexual contacts should be informed about the possibility of concomitant disease and referred appropriately. Sexual abuse should be considered in children with gonococcal or Chlamydia infections.

Patients with gonococcal conjunctivitis should be seen daily until resolution of the conjunctivitis. At each follow-up visit, an interval history, visual acuity measurement, and slit-lamp biomicroscopy should be performed. For other types of bacterial conjunctivitis, patients should be advised to return for a visit in 3 to 4 days if they note no improvement. *Neisseria meningitidis* should be eliminated as the causative organism before concluding that *N. gonorrhoeae* is responsible.

Chlamydial Conjunctivitis

Appendix 4 provides recommendations for the treatment of chlamydial conjunctivitis. Because more than 50% of infants with chlamydial conjunctivitis may also be infected at other sites such as the nasopharynx, genital tract, or lungs, systemic therapy is indicated.^{64, 320} Empiric antibiotic therapy can be considered in patients with symptoms and signs highly suggestive of chlamydia (e.g., follicular conjunctivitis that persists for several weeks). There are no data to support the use of topical therapy in addition to systemic therapy. Because the incidence of treatment failure can be as high as 19%,¹⁰⁴ patients should be re-evaluated following treatment. The follow-up visit should consist of an interval history, visual acuity measurement, and slit-lamp biomicroscopy. Adult conjunctivitis usually responds to systemic therapy, and sexual contacts should be treated at the same time. Patients and sexual contacts should be informed about the possibility of concomitant disease and should be referred appropriately. Sexual abuse should be considered in children with this condition. In low- to middle-income countries where antibiotic access is limited, povidone-iodine 1.25% ophthalmic solution can be used to treat chlamydial conjunctivitis.³¹¹

Vasculitis

When a diagnosis of vasculitis is confirmed, topical/periocular steroids may be considered in cases of unilateral ocular involvement. Bilateral ocular involvement, advanced vision loss, and/or systemic comorbidities often necessitate systemic treatment with corticosteroids, antimetabolites, calcineurin inhibitors,³²¹ biologics,³²² or intravenous immunoglobulins.³²³ Notably, infectious causes must be ruled out before considering immunosuppression.

Ligneous Conjunctivitis

Ligneous conjunctivitis is caused by plasminogen deficiency resulting in pseudomembranous disease of mucous membranes in the mouth, nasopharynx, trachea, and female genital tract. This chronic childhood membranous conjunctivitis has been treated successfully using intravenous lysplasminogen³²⁴ or topical plasminogen drops,³²⁵ or by surgical excision with immediate anticoagulation and immunosuppression.³²⁶

PROVIDER AND SETTING

Because there is a spectrum of etiologies and treatment, optimal diagnosis and management of conjunctivitis require broad medical skills and experience. Some types of conjunctivitis are associated with systemic diseases and may require systemic drug treatment.

Patients with conjunctivitis should be evaluated by an ophthalmologist in the following circumstances:

- ◆ Visual loss
- ◆ Moderate or severe pain
- ◆ Severe, purulent discharge

- ◆ Corneal involvement
- ◆ Conjunctival scarring
- ◆ Lack of response to therapy
- ◆ Recurrent episodes
- ◆ History of HSV eye disease
- ◆ History of immunocompromise

Most patients with conjunctivitis can be treated effectively in an outpatient setting. In children with acute bacterial conjunctivitis, consideration might be given to referral for an internal ear exam. Hospitalization may be necessary to administer parenteral therapy for severe gonococcal conjunctivitis and is mandatory for neonatal conjunctivitis.¹⁰

COUNSELING AND REFERRAL

Counseling is imperative for all contagious varieties of conjunctivitis to minimize or prevent spread of the disease in the community. Modes of transmission include eye-hand contact, sexual contact, exposure to contaminated droplets, and exposure to airborne pathogens. Hand washing is important to reduce the risk of transmission of infection. Return to school or work depends on the age of the patient, occupation, and type and severity of conjunctivitis.

When conjunctivitis is associated with sexually transmitted disease, treatment of sexual partners is essential to minimize recurrence and spread of the disease. Patients as well as their sexual partners should be referred to an appropriate medical specialist. The physician must remain alert to the possibility of child abuse in cases of potentially sexually transmitted ocular disease in children. In many states, sexually transmitted diseases and suspected child abuse must be reported to local health authorities or other state agencies.

In cases of ophthalmia neonatorum due to gonococcus, chlamydia, and HSV, the infant should be referred to an appropriate specialist. Infants who require systemic treatment are best managed in conjunction with a pediatrician.

When conjunctivitis appears to be a manifestation of systemic disease, patients should be referred to an appropriate medical specialist for evaluation.

SOCIOECONOMIC CONSIDERATIONS

Conjunctivitis is very common worldwide, and it has a broad spectrum of disease severity and underlying etiologies.

Allergic Conjunctivitis

Allergic conjunctivitis alone has been estimated to occur in 6% to 40% of the general population and symptoms are noted in 30% to 71% of patients with allergic rhinitis.³²⁷⁻³²⁹ There have been multiple studies that have examined how allergic conjunctivitis causes a reduction in quality of life³³⁰⁻³³³ and increases economic costs.^{331, 333-335} The costs include not only direct costs such as doctors' visits and medications but also indirect costs such as missed days from work and school, and decreased productivity while at work.³³⁶

Higher socioeconomic position or type 1 diabetes may be related to increased risk of developing allergies.^{337, 338} In countries with high rates of allergic diseases, it has been noted that children who had recently immigrated may have a protective premigration environment that results in a lower prevalence of asthma, conjunctivitis, and eczema.

An observational cross-sectional study on allergic rhinitis in four European countries showed that the presence of ocular symptoms reduces quality of life, reduces work productivity, and increases resource utilization regardless of the severity of nasal symptoms.³³¹ Another cross-sectional study looked at patients diagnosed with allergic conjunctivitis in 16 ophthalmology departments in Portugal. It found that 59% of patients had year-round symptoms, and that 46% had significant impairment in their quality of life during an acute episode.³³² Chronic allergic rhinitis/conjunctivitis is also a common disease among children.³³⁴ Among students with nasal and ocular symptoms, 42%, 24%, 36%, and 28% reported moderate to severe interference of daily activities, at least 1 day of absence from school, a visit to a health care professional, and drug usage for rhinitis, respectively. The total number of prescriptions written for ocular allergy increased by 20% per year between 1996 and 2005.³³⁹ Expenditure on treatment grew from an

estimated \$1 billion to \$1.43 billion between 2013 and 2018.^{339, 340} In the United States in 2007, the direct and indirect costs were estimated to be at least \$6 billion a year.³³⁵ Similar decreases in quality of life and progressively increasing economic costs for seasonal allergic conjunctivitis were also found in Spain and Oxfordshire, England.³⁴¹ Treatment options that address ocular symptoms may have a large beneficial impact on quality of life and decrease direct and indirect costs associated with allergic rhinitis.³³¹

Vernal keratoconjunctivitis is a chronic form of allergic conjunctivitis that is more common in children and young adults and is more prevalent in hot, dry climates.³⁴² A population-based case-control study conducted on 3,049 children in Rwanda identified hot climates, male gender, and higher socioeconomic status as risk factors.³⁴² The authors hypothesize that there may be differing immunologic and environmental mechanisms present in urban settings compared with rural settings that account for this socioeconomic finding, and they suggest that further study is warranted. In the Rwandan study, 36% of children with VKC missed 1 or more days of school in the last 3 months for an ocular reason.³⁴³ Topical cyclosporine and tacrolimus have been shown to be effective treatments, but cost may limit their use in the low- to middle-income countries.¹¹⁷ One study reported that during active flare-ups of adult VKC, productivity was reduced by 26% and social activities by 31%.²⁸

Bacterial Conjunctivitis

The economic impact of bacterial conjunctivitis is also substantial. A study was performed on a single outbreak of pneumococcal conjunctivitis at Dartmouth College in 2002 that affected 698 students.⁵ Even though the course of the disease was very short and there were no long-term ocular sequelae, the estimated cost, including doctors' visits, cultures, and antibiotics, ranged from \$66,468 to \$120,583. Another study looked at the entire country using data from the medical literature, existing national databases, and Current Procedural Terminology codes.⁴ The estimated number of cases of bacterial conjunctivitis in the United States in 2005 was 4 million, and the total direct and indirect cost of treating patients with bacterial conjunctivitis was \$589 million. Data on costs associated with missed work or school, as well as the economic impact of untreated bacterial conjunctivitis, are not available.

Adenoviral Conjunctivitis

Antibiotics are not indicated in the treatment of adenoviral conjunctivitis yet are frequently prescribed. In one retrospective study, 60% of patients diagnosed with adenoviral conjunctivitis filled antibiotic prescriptions, and one of five of these were for antibiotic-steroid combination drops, which are typically contraindicated in acute conjunctivitis. Prescriptions were given more often if an optometrist, urgent care physician, or primary care provider rather than an ophthalmologist made the initial diagnosis. Antibiotic prescriptions were also more likely to be filled by white, affluent, and/or educated patients.³⁴⁴ These practices contribute to avoidable increased health care costs and may promote antibiotic resistance.

Even though adenoviral conjunctivitis is a common condition that often results in several missed days of work/school and can lead to painful and visually debilitating keratoconjunctivitis, there are not yet any published studies on its overall economic impact in the general population. A single outbreak of adenoviral keratoconjunctivitis in a long-term care facility in 2000, which affected 29 residents and 12 staff, resulted in hospital costs of \$29,527 (\$1085 for medical costs, \$8210 for investigative costs, \$3048 for preventive measures, and \$17,184 for lost productivity).³⁴⁵ In 2018, a study looking at a breakout of adenovirus in a neonatal intensive care unit setting affecting 52 neonates and 59 neonatal intensive care unit healthcare workers estimated the total cost related to containment and productivity losses to be \$205,000.³⁴⁶ Preventive infection-control measures can be extremely cost-effective if such an outbreak is avoided. There are quick point-of-care tests for adenovirus; however, some studies show a low sensitivity limiting its potential utility.¹⁰⁷

Ocular Surface Squamous Neoplasia

Outcomes of medical versus surgical treatment in patients with ocular surface squamous neoplasia have been found to be equally efficacious.^{347, 348} Socioeconomic considerations do play a role in treatment decision-making. In 2019, Al Bayyat et al noted that out-of-pocket costs for

fluorouracil and mitomycin-C cost \$38 to \$75 and \$100 to \$200 per bottle, respectively.³⁴⁹ For patients with limited access to care, logistical considerations and the additive cost of chronic medical therapy versus potentially curative surgical therapy should be considered.³⁵⁰

APPENDIX 1. QUALITY OF OPHTHALMIC CARE CORE CRITERIA

*Providing quality care
is the physician's foremost ethical obligation, and is
the basis of public trust in physicians.*

AMA Board of Trustees, 1986

Quality ophthalmic care is provided in a manner and with the skill that is consistent with the best interests of the patient. The discussion that follows characterizes the core elements of such care.

The ophthalmologist is first and foremost a physician. As such, the ophthalmologist demonstrates compassion and concern for the individual, and utilizes the science and art of medicine to help alleviate patient fear and suffering. The ophthalmologist strives to develop and maintain clinical skills at the highest feasible level, consistent with the needs of patients, through training and continuing education. The ophthalmologist evaluates those skills and medical knowledge in relation to the needs of the patient and responds accordingly. The ophthalmologist also ensures that needy patients receive necessary care directly or through referral to appropriate persons and facilities that will provide such care, and he or she supports activities that promote health and prevent disease and disability.

The ophthalmologist recognizes that disease places patients in a disadvantaged, dependent state. The ophthalmologist respects the dignity and integrity of his or her patients and does not exploit their vulnerability.

Quality ophthalmic care has the following optimal attributes, among others.

- ◆ The essence of quality care is a meaningful partnership relationship between patient and physician. The ophthalmologist strives to communicate effectively with his or her patients, listening carefully to their needs and concerns. In turn, the ophthalmologist educates his or her patients about the nature and prognosis of their condition and about proper and appropriate therapeutic modalities. This is to ensure their meaningful participation (appropriate to their unique physical, intellectual and emotional state) in decisions affecting their management and care, to improve their motivation and compliance with the agreed plan of treatment, and to help alleviate their fears and concerns.
- ◆ The ophthalmologist uses his or her best judgment in choosing and timing appropriate diagnostic and therapeutic modalities as well as the frequency of evaluation and follow-up, with due regard to the urgency and nature of the patient's condition and unique needs and desires.
- ◆ The ophthalmologist carries out only those procedures for which he or she is adequately trained, experienced and competent, or, when necessary, is assisted by someone who is, depending on the urgency of the problem and availability and accessibility of alternative providers.
- ◆ Patients are assured access to, and continuity of, needed and appropriate ophthalmic care, which can be described as follows.
 - ◆ The ophthalmologist treats patients with due regard to timeliness, appropriateness, and his or her own ability to provide such care.
 - ◆ The operating ophthalmologist makes adequate provision for appropriate pre- and postoperative patient care.
 - ◆ When the ophthalmologist is unavailable for his or her patient, he or she provides appropriate alternate ophthalmic care, with adequate mechanisms for informing patients of the existence of such care and procedures for obtaining it.
 - ◆ The ophthalmologist refers patients to other ophthalmologists and eye care providers based on the timeliness and appropriateness of such referral, the patient's needs, the competence and qualifications of the person to whom the referral is made, and access and availability.
 - ◆ The ophthalmologist seeks appropriate consultation with due regard to the nature of the ocular or other medical or surgical problem. Consultants are suggested for their skill, competence, and accessibility. They receive as complete and accurate an accounting of the problem as necessary to provide efficient and effective advice or intervention, and in turn respond in an adequate and timely manner.
 - ◆ The ophthalmologist maintains complete and accurate medical records.
 - ◆ On appropriate request, the ophthalmologist provides a full and accurate rendering of the patient's records in his or her possession.

- ◆ The ophthalmologist reviews the results of consultations and laboratory tests in a timely and effective manner and takes appropriate actions.
- ◆ The ophthalmologist and those who assist in providing care identify themselves and their profession.
- ◆ For patients whose conditions fail to respond to treatment and for whom further treatment is unavailable, the ophthalmologist provides proper professional support, counseling, rehabilitative and social services, and referral as appropriate and accessible.
- ◆ Prior to therapeutic or invasive diagnostic procedures, the ophthalmologist becomes appropriately conversant with the patient's condition by collecting pertinent historical information and performing relevant preoperative examinations. Additionally, he or she enables the patient to reach a fully informed decision by providing an accurate and truthful explanation of the diagnosis; the nature, purpose, risks, benefits, and probability of success of the proposed treatment and of alternative treatment; and the risks and benefits of no treatment.
- ◆ The ophthalmologist adopts new technology (e.g., drugs, devices, surgical techniques) in judicious fashion, appropriate to the cost and potential benefit relative to existing alternatives and to its demonstrated safety and efficacy.
- ◆ The ophthalmologist enhances the quality of care he or she provides by periodically reviewing and assessing his or her personal performance in relation to established standards, and by revising or altering his or her practices and techniques appropriately.
- ◆ The ophthalmologist improves ophthalmic care by communicating to colleagues, through appropriate professional channels, knowledge gained through clinical research and practice. This includes alerting colleagues of instances of unusual or unexpected rates of complications and problems related to new drugs, devices or procedures.
- ◆ The ophthalmologist provides care in suitably staffed and equipped facilities adequate to deal with potential ocular and systemic complications requiring immediate attention.
- ◆ The ophthalmologist also provides ophthalmic care in a manner that is cost effective without unacceptably compromising accepted standards of quality.

Reviewed by: Council
Approved by: Board of Trustees
October 12, 1988

2nd Printing: January 1991

3rd Printing: August 2001

4th Printing: July 2005

APPENDIX 2. INTERNATIONAL STATISTICAL CLASSIFICATION OF DISEASES AND RELATED HEALTH PROBLEMS (ICD) CODES

Conjunctivitis includes entities with the following ICD-10 classifications:

	ICD-10 CM
Conjunctivitis, other diseases of conjunctiva caused by viruses	Code first underlying virus or chemical and intent H10.011 – H10.813 (approximately 65 codes in this range)
<i>Chlamydia</i> and ophthalmia neonatorum caused by gonococcus	A74.0, B30.0 – B30.9 A54.31
Blepharoconjunctivitis	H10.50-, H10.51-, H10.53-
Zika virus	A92.5
Ligneous	H10.51-
Measles	B05.81
Seasonal allergic conjunctivitis	H10.45
Vernal conjunctivitis	H10.44
Atopic conjunctivitis	H10.1-
Giant papillary conjunctivitis (GPC), which also has a mechanical component	H10.41-
Superior limbic keratoconjunctivitis (SLK)	H16.29-
Contact lens–related keratoconjunctivitis	H12.89
Floppy eyelid syndrome	H02.89
Giant fornix syndrome	H16.29_ (other keratoconjunctivitis)
Pediculosis palpebrarum (<i>Phthirus pubis</i>)	H44.52-
Medication-induced keratoconjunctivitis	H10.40_ (unspecified chronic conjunctivitis)
Conjunctival chalasis	H11.82-
Adenoviral conjunctivitis	B30.1
Herpes simplex virus (HSV) conjunctivitis	B00.53
Varicella (herpes) zoster virus (VZV) conjunctivitis	B02.31
Molluscum contagiosum	B08.1
Bacterial conjunctivitis (including nongonococcal and gonococcal)	H10.89
Chlamydial conjunctivitis	A74.0
Ocular mucous membrane pemphigoid (OMMP)	L12.1
Graft-versus-host disease (GVHD)	D89.810, D89.811, D89.812
Stevens-Johnson syndrome (SJS)/toxic epidermal necrolysis (TEN)	L51.3
SARS-COVID 19	U07.1

CM = Clinical Modification used in the United States; ICD = International Classification of Diseases; (–) = 1, right eye; 2, left eye; 3, bilateral

Additional information:

Conjunctivitis PPP

- Certain ICD-10 CM categories have applicable 7th characters. The applicable 7th character is required for all codes within the category, or as the notes in the Tabular List instruct. The 7th character must always be the 7th character in the data field. If a code that requires a 7th character is not 6 characters, a placeholder X must be used to fill in the empty characters.
- For bilateral sites, the final character of the codes in the ICD-10 CM indicates laterality. If no bilateral code is provided and the condition is bilateral, separate codes for both the left and right side should be assigned. Unspecified codes should only be used when there is no other code option available.
- When the diagnosis code specifies laterality, regardless of which digit it is found in (i.e., 4th digit, 5th digit, or 6th digit):
 - Right is always 1
 - Left is always 2
 - Bilateral is always 3

APPENDIX 3. OCULAR SURFACE DYE STAINING

Fluorescein, rose bengal, or lissamine green dyes may be used to assess the ocular surface.

Fluorescein dye stains areas of the corneal and conjunctival epithelium where there is sufficient disruption of intercellular junctions to allow the dye to permeate into the tissue.³⁵¹ Saline-moistened fluorescein strips or 1% to 2% sodium fluorescein solution are used to stain the tear film. After instilling the dye, the ocular surface is examined through a biomicroscope using a cobalt blue filter. Staining may become more apparent after 1 to 2 minutes. Staining is more intense when it is observed using a yellow filter. Mild fluorescein staining can be observed in normal eyes and may be more prominent in the morning. Exposure-zone punctate or blotchy fluorescein staining is observed in dry eye, and staining is more easily visualized on the cornea than on the conjunctiva.

Rose bengal dye stains ocular surface cells that lack a mucous coating as well as debris in the tear film,³⁵¹ and this staining may be easier to observe with a red-free filter (green filter). Rose bengal staining of the tear film may be performed using a saline-moistened strip or 1% solution. (Patients should be informed that the drop might irritate the eye.) The saline drop used to moisten the strip should remain in contact with the strip for at least a minute to achieve an adequate concentration of rose bengal to stain the ocular surface. Rose bengal staining is more intense on the conjunctiva than on the cornea. Rose bengal has antiviral properties and may affect herpes simplex virus-1 (HSV-1) culture results. It is also helpful when delineating the margins of ocular surface neoplasms.³⁵²

Lissamine green dye has a staining profile similar to that of rose bengal³⁵³ and may cause less ocular irritation.³⁵³ It is more useful for observing conjunctival staining and is not recommended for evaluating corneal epithelial disease.

Diffuse corneal and conjunctival staining is commonly seen in viral keratoconjunctivitis and medicamentosa. Staining of the inferior cornea and bulbar conjunctiva is typically observed in patients with staphylococcal blepharitis, meibomian gland dysfunction, lagophthalmos, and exposure, whereas staining of the superior bulbar conjunctiva is typically seen in superior limbic keratoconjunctivitis. A pattern of exposure zone (interpalpebral) corneal and bulbar conjunctival staining is typically seen with dry eye disease.^{354, 355}

APPENDIX 4. SYSTEMIC ANTIBIOTIC THERAPY FOR GONOCOCCAL AND CHLAMYDIAL CONJUNCTIVITIS

TABLE A4-1 SYSTEMIC ANTIBIOTIC THERAPY FOR GONOCOCCAL AND CHLAMYDIAL CONJUNCTIVITIS

Cause	Drug of Choice	Dosage
Adults and Adolescents		
Gonococcus*	Ceftriaxone [†] and Azithromycin or Doxycycline	500 mg IM, single dose 1 g orally, single dose 100 mg orally, twice a day for 7 days
	For cephalosporin-allergic patients:	
	Azithromycin [‡] plus Gentamicin	2 g orally, single dose 240 mg IM, single dose
	For ceftriaxone administration is not available or not feasible:	
	Cefixime	800 mg orally, single dose
	For pregnant patients:	
	Ceftriaxone	500 mg IM, single dose
	For disseminated gonococcal infections:	
	Ceftriaxone or Cefotaxime or Ceftizoxime	1 g IM or intravenous every 24 hours 1 g by intravenous every 8 hours 1 g every 8 hours

TABLE A4-1 SYSTEMIC ANTIBIOTIC THERAPY FOR GONOCOCCAL AND CHLAMYDIAL CONJUNCTIVITIS

Cause	Drug of Choice	Dosage
Chlamydia ^l	Azithromycin	1 g orally, single dose
	or Doxycycline	100 mg orally twice a day for 7 days
	or Levofloxacin	500 mg orally once a day for 7 days
For pregnant patients:		
	Azithromycin	1 g orally, single dose
	or Amoxicillin	500 mg orally three times a day for 7 days
Children ^s (<18 years)		
Gonococcus		
Children who weigh ≤45 kg	Ceftriaxone	25–50 mg/kg body weight intravenous or IM, single dose, not to exceed 250 mg IM
Children who weigh >45 kg	Same treatment as adults	
Chlamydia		
Infants and children who weigh <45 kg (nasopharynx, urogenital, and rectal)	Erythromycin base or ethylsuccinate	50 mg/kg body weight/day orally divided into four doses a day for 14 days
Children who weigh ≥45 kg but are aged <8 years (nasopharynx, urogenital, and rectal)	Azithromycin	1 g orally, single dose
Children ≥8 years	Azithromycin	1 g orally, single dose
	or Doxycycline	100 mg orally, twice a day for 7 days
Neonates		
Ophthalmia neonatorum caused by <i>N. gonorrhoeae</i>	Ceftriaxone	25–50 mg/kg intravenous or IM, single dose, not to exceed 250 mg
Ocular prophylaxis in neonates	Erythromycin	0.5% ophthalmic ointment in each eye in a single application at birth

TABLE A4-1 SYSTEMIC ANTIBIOTIC THERAPY FOR GONOCOCCAL AND CHLAMYDIAL CONJUNCTIVITIS

Cause	Drug of Choice	Dosage
	For neonates unable to receive ceftriaxone due to simultaneous administration of intravenous calcium:	
	Cefotaxime	100 mg/kg body weight intravenous or IM, single dose
Chlamydia	Erythromycin base or ethylsuccinate or Azithromycin suspension	50 mg/kg body weight/day orally divided into four doses a day for 14 days** 20 mg/kg body weight/day orally once a day for 3 days

NOTE: Pregnant women should not be treated with doxycycline, quinolones, or tetracyclines. Either erythromycin or amoxicillin is recommended for treatment of chlamydia during pregnancy.

Data from:

Centers for Disease Control and Prevention. Sexually transmitted diseases treatment guidelines, 2021. *MMWR Morb Mortal Wkly Rep.* 2021;70 (No. RR-4)

* The Centers for Disease Control and Prevention (CDC) currently recommends that patients treated for gonococcal infection also be treated routinely with a regimen effective against uncomplicated genital *Chlamydia trachomatis* infection, because patients infected with *Neisseria gonorrhoeae* often are coinfecting with *C. trachomatis*.

† If ceftriaxone is not available, cefixime 400 mg in a single dose or doxycycline 100 mg orally, twice a day for 7 days may be used. Consider lavage of infected eyes with saline solution once.

‡ A single oral dose of azithromycin 2 g is effective against uncomplicated gonococcal infections, but the CDC does not recommend widespread use of azithromycin because of concerns over emerging antimicrobial resistance to macrolides. Because data are limited regarding alternative regimens for treating gonorrhea among persons who have severe cephalosporin allergy, providers treating such patients should consult infectious disease specialists.

§ The CDC recommends advising all women and men with chlamydial or gonococcal infection to be retested approximately 3 months after treatment.

|| Sexual abuse must be considered a cause of infection in preadolescent children. A diagnosis of *C. trachomatis* or *N. gonorrhoeae* infection in preadolescent children should be documented by standard culture.

¶ Spectinomycin is not available in the United States; updated information from the CDC on the availability of spectinomycin will be available at www.cdc.gov/std/treatment.

** An association between oral erythromycin and infantile hypertrophic pyloric stenosis has been reported in infants aged less than 6 weeks who were treated with this drug. Infants treated with erythromycin should be followed for signs and symptoms of infantile hypertrophic pyloric stenosis

LITERATURE SEARCHES FOR THIS PPP

Literature searches of the PubMed database were conducted on March 3, 2022; the search strategies are listed below. Specific limited update searches were conducted on June 7, 2023. The searches had added filters for human, English-language randomized controlled trials and systematic reviews and date limiters to capture literature published since June 27, 2018. The panel analyzed 1,906 studies of which 65 were included in the PPP. The literature searches with the disease condition and the search term, patient values and patient preferences didn't yield results. The literature searches for economic evaluation and treatment cost yielded 1 study which was provided to the panel, and which was included in the PPP.

Conjunctivitis All: (conjunctivitis[majr:noexp] OR conjunctivitis, allergic[majr:noexp] OR conjunctivitis, bacterial[majr:noexp] OR conjunctivitis, viral[majr:noexp] OR keratoconjunctivitis[majr:noexp] OR conjunctivitis[tiab] OR keratoconjunctivitis[tiab])

Epidemiology: (conjunctivitis/epidemiology[majr:noexp] OR conjunctivitis, allergic/epidemiology[majr:noexp] OR conjunctivitis, bacterial/epidemiology[majr:noexp] OR conjunctivitis, viral/epidemiology[majr:noexp] OR keratoconjunctivitis/epidemiology[majr:noexp])

Risk Factors: (conjunctivitis[majr:noexp] OR conjunctivitis, allergic[majr:noexp] OR conjunctivitis, bacterial[majr:noexp] OR conjunctivitis, viral[majr:noexp] OR keratoconjunctivitis[majr:noexp]) AND (risk factors[MeSH Terms])

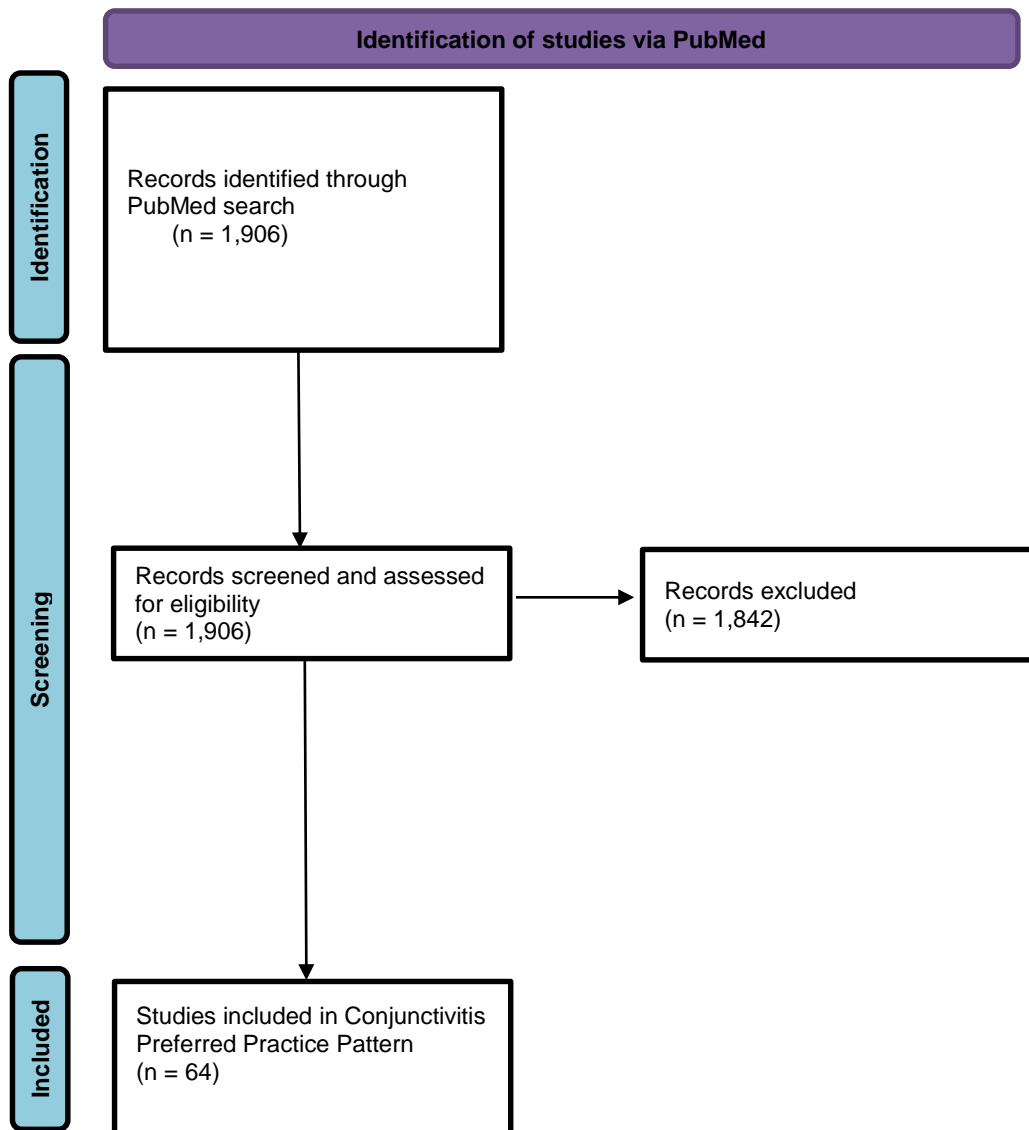
Contact Lenses: (conjunctivitis[mh:noexp] OR conjunctivitis, allergic[mh:noexp] OR conjunctivitis, bacterial[mh:noexp] OR conjunctivitis, viral[mh:noexp] OR keratoconjunctivitis[mh:noexp]) AND (contact lenses[mh])

Etiology: (conjunctivitis/etiology[majr:noexp] OR conjunctivitis, allergic/etiology[majr:noexp] OR conjunctivitis, bacterial/etiology[majr:noexp] OR conjunctivitis, viral/etiology[majr:noexp] OR keratoconjunctivitis/etiology[majr:noexp])

Pathology/Physiology/Physiopathology: (conjunctivitis/pathology[majr:noexp] OR conjunctivitis/physiology[majr:noexp] OR conjunctivitis/physiopathology[majr:noexp] OR conjunctivitis, allergic/pathology[majr:noexp] OR conjunctivitis, allergic/physiopathology[majr:noexp] OR conjunctivitis, allergic/physiology[mh] OR conjunctivitis, bacterial/pathology[majr:noexp] OR conjunctivitis, bacterial/physiopathology[majr:noexp] OR conjunctivitis, bacterial/physiology[mh] OR conjunctivitis, viral/pathology[majr:noexp] OR conjunctivitis, viral/physiopathology[majr:noexp] OR conjunctivitis, viral/physiology[mh] OR keratoconjunctivitis/pathology[majr:noexp] OR keratoconjunctivitis/physiology[majr:noexp] OR keratoconjunctivitis/physiopathology[majr:noexp])

Cost of Illness: "conjunctivitis"[tiab] AND ("cost of illness"[MeSH Terms] OR "cost benefit analysis"[MeSH Terms])

Patient Values: conjunctivitis[tiab] AND (patient values[tiab] OR patient preferences[tiab])



From: Page MJ, McKenzie JE, Bossuyt PM, Boutron I, Hoffmann TC, Mulrow CD, et al. The PRISMA 2020 statement: an updated guideline for reporting systematic reviews. *BMJ* 2021;372:n71. doi: 10.1136/bmj.n71

For more information, visit: <http://www.prisma-statement.org/>

RELATED ACADEMY MATERIALS

Basic and Clinical Science Course

External Disease and Cornea (Section 8, 2023-2024)

Patient Education Brochure

Conjunctivitis (2023)

Preferred Practice Pattern® Guidelines – Free download available at www.aao.org/ppp.

Comprehensive Adult Medical Eye Evaluation (2020)

REFERENCES

1. Scottish Intercollegiate Guidelines Network (SIGN). *SIGN 50: A guideline developer's handbook*. Edinburgh: SIGN; 2015. (SIGN publication no. 50). [November 2015]. Available from url: <http://www.sign.ac.uk>. Accessed November 17, 2023.
2. Guyatt GH, Oxman AD, Vist GE, et al. GRADE: An emerging consensus on rating quality of evidence and strength of recommendations. *BMJ*. 2008;336:924-926.
3. GRADE Working Group. Organizations that have endorsed or that are using GRADE. <http://www.gradeworkinggroup.org/>. Accessed November 17, 2023.
4. Smith AF, Waycaster C. Estimate of the direct and indirect annual cost of bacterial conjunctivitis in the United States. *BMC Ophthalmol*. 2009;9:13.
5. Zegans ME, Sanchez PA, Likosky DS, et al. Clinical features, outcomes, and costs of a conjunctivitis outbreak caused by the ST448 strain of streptococcus pneumoniae. *Cornea*. 2009;28:503-509.
6. Rutala WA, Weber DJ. Healthcare infection control practices advisory committee (HICPAC). Guideline for disinfection and sterilization in healthcare facilities, 2008.
7. Junk AK, Chen PP, Lin SC, et al. Disinfection of tonometers: A report by the American Academy of Ophthalmology. *Ophthalmology*. 2017;124:1867-1875.
8. Mantelli F, Santos MS, Petitti T, et al. Systematic review and meta-analysis of randomised clinical trials on topical treatments for vernal keratoconjunctivitis. *Br J Ophthalmol*. 2007;91:1656-1661.
9. Rasmussen MLR, Schou MG, Bach-Holm D, et al. Comparative efficacy of medical treatments for vernal keratoconjunctivitis in children and young adults: A systematic review with network meta-analyses. *Acta Ophthalmol*. 2022;100:35-44.
10. Epling J. Bacterial conjunctivitis. *BMJ Clin Evid*. 2012;2012.
11. Kapoor VS, Evans JR, Vedula SS. Interventions for preventing ophthalmia neonatorum. *Cochrane Database Syst Rev*. 2020;9:CD001862.
12. Cornea Society and the American Academy of Ophthalmology. Recommendations for herpes zoster vaccine for patients 50 years of age and older. San Francisco, CA: American Academy of Ophthalmology; 2018. <https://www.aao.org/education/clinical-statement/recommendations-herpes-zoster-vaccine-patients-50-> Accessed November 17, 2023.
13. McCulley JP, Dougherty JM, Deneau DG. Classification of chronic blepharitis. *Ophthalmology*. 1982;89:1173-1180.
14. American Academy of Ophthalmology Cornea/External Disease Panel. Preferred practice pattern®. Dry eye syndrome. San Francisco, CA: American Academy of Ophthalmology; 2023. www.aao.org/ppp. Accessed November 17, 2023.
15. Chiang YP, Wang F, Javitt JC. Office visits to ophthalmologists and other physicians for eye care among the U.S. Population, 1990. *Public Health Rep*. 1995;110:147-153.
16. Miyazaki D, Fukagawa K, Okamoto S, et al. Epidemiological aspects of allergic conjunctivitis. *Allergol Int*. 2020;69:487-495.
17. Jalbert I, Golebiowski B. Environmental aeroallergens and allergic rhino-conjunctivitis. *Curr Opin Allergy Clin Immunol*. 2015;15:476-481.
18. Nkosi V, Wichmann J, Vuyi K. Mine dumps, wheeze, asthma, and rhinoconjunctivitis among adolescents in South Africa: Any association? *Int J Environ Health Res*. 2015;25:583-600.
19. Al-Wahaibi A, Zeka A. Health impacts from living near a major industrial park in Oman. *BMC Public Health*. 2015;15:524.
20. Shirinde J, Wichmann J, Vuyi K. Allergic rhinitis, rhinoconjunctivitis and hayfever symptoms among children are associated with frequency of truck traffic near residences: A cross sectional study. *Environ Health*. 2015;14:84.
21. Solis-Soto MT, Patino A, Nowak D, Radon K. Association between environmental factors and current asthma, rhinoconjunctivitis and eczema symptoms in school-aged children from Oropeza Province--Bolivia: A cross-sectional study. *Environ Health*. 2013;12:95.
22. Arita R. Validity of noninvasive meibography systems: Noncontact meibography equipped with a slit-lamp and a mobile pen-shaped meibograph. *Cornea*. 2013;32 Suppl 1:S65-70.
23. Garcia-Posadas L, Contreras-Ruiz L, Soriano-Romani L, et al. Conjunctival goblet cell function: Effect of contact lens wear and cytokines. *Eye Contact Lens*. 2016;42:83-90.

24. Singhal D, Sahay P, Maharana PK, et al. Vernal keratoconjunctivitis. *Surv Ophthalmol*. 2019;64:289-311.
25. Stagi S, Pucci N, di Grande L, et al. Increased prevalence of growth hormone deficiency in patients with vernal keratoconjunctivitis; an interesting new association. *Hormones (Athens)*. 2014;13:382-388.
26. Sacchetti M, Lambiase A, Moretti C, et al. Sex hormones in allergic conjunctivitis: Altered levels of circulating androgens and estrogens in children and adolescents with vernal keratoconjunctivitis. *J Immunol Res*. 2015;2015:945317.
27. Alemayehu AM, Yibekal BT, Fekadu SA. Prevalence of vernal keratoconjunctivitis and its associated factors among children in Gambella Town, Southwest Ethiopia, June 2018. *PLoS One*. 2019;14:e0215528.
28. Leonardi A, Lazzarini D, Motterle L, et al. Vernal keratoconjunctivitis-like disease in adults. *Am J Ophthalmol*. 2013;155:796-803.
29. Saboo US, Jain M, Reddy JC, Sangwan VS. Demographic and clinical profile of vernal keratoconjunctivitis at a tertiary eye care center in India. *Indian J Ophthalmol*. 2013;61:486-489.
30. Ibrahim OM, Matsumoto Y, Dogru M, et al. In vivo confocal microscopy evaluation of meibomian gland dysfunction in atopic-keratoconjunctivitis patients. *Ophthalmology*. 2012;119:1961-1968.
31. Jan RL, Weng SF, Wang JJ, et al. Association between atopic keratoconjunctivitis and the risk of recurrent corneal erosion. *Front Med (Lausanne)*. 2021;8:688355.
32. Sy H, Bielory L. Atopic keratoconjunctivitis. *Allergy Asthma Proc*. 2013;34:33-41.
33. Nelson JD. Superior limbic keratoconjunctivitis (SLK). *Eye (Lond)*. 1989;3 (Pt 2):180-189.
34. Cher I. Clinical features of superior limbic keroconjunctivitis in Australia. A probable association with thyrotoxicosis. *Arch Ophthalmol*. 1969;82:580-586.
35. Kadrmas EF, Bartley GB. Superior limbic keratoconjunctivitis. A prognostic sign for severe Graves ophthalmopathy. *Ophthalmology*. 1995;102:1472-1475.
36. Ahn H, Ji YW, Jun I, et al. Effects of meibomian gland dysfunction and aqueous deficiency on friction-related disease. *Ocul Surf*. 2022.
37. American Academy of Ophthalmology Cornea/External Disease Panel. Preferred practice pattern®. Blepharitis. San Francisco, CA: American Academy of Ophthalmology; 2023. www.aao.org/ppp. Accessed November 17, 2023.
38. Rodriguez-Garcia A, Gonzalez-Godinez S, Lopez-Rubio S. Blepharokeratoconjunctivitis in childhood: Corneal involvement and visual outcome. *Eye (Lond)*. 2016;30:438-446.
39. Vieira AC, Hofling-Lima AL, Mannis MJ. Ocular rosacea--a review. *Arq Bras Oftalmol*. 2012;75:363-369.
40. De Gregorio A, Cerini A, Scala A, et al. Floppy eyelid, an under-diagnosed syndrome: A review of demographics, pathogenesis, and treatment. *Ther Adv Ophthalmol*. 2021;13:25158414211059247.
41. Saidel MA, Paik JY, Garcia C, et al. Prevalence of sleep apnea syndrome and high-risk characteristics among keratoconus patients. *Cornea*. 2012;31:600-603.
42. Stern GA. *Focal points 2012 module: Chronic conjunctivitis, part 2*. San Francisco, CA: American Academy of Ophthalmology; 2012:3.
43. Turaka K, Penne RB, Rapuano CJ, et al. Giant fornix syndrome: A case series. *Ophthalm Plast Reconstr Surg*. 2012;28:4-6.
44. Rose GE. The giant fornix syndrome: An unrecognized cause of chronic, relapsing, grossly purulent conjunctivitis. *Ophthalmology*. 2004;111:1539-1545.
45. Wollenberg A, Beck LA, de Bruin Weller M, et al. Conjunctivitis in adult patients with moderate-to-severe atopic dermatitis: Results from five tralokinumab clinical trials. *Br J Dermatol*. 2022;186:453-465.
46. Aszodi N, Thurau S, Seegraber M, et al. Management of dupilumab-associated conjunctivitis in atopic dermatitis. *J Dtsch Dermatol Ges*. 2019;17:488-491.
47. Agnihotri G, Shi K, Lio PA. A clinician's guide to the recognition and management of dupilumab-associated conjunctivitis. *Drugs R D*. 2019;19:311-318.
48. Akinlade B, Guttman-Yassky E, de Bruin-Weller M, et al. Conjunctivitis in dupilumab clinical trials. *Br J Dermatol*. 2019;181:459-473.
49. Utine CA, Li G, Asbell P, et al. Ocular surface disease associated with dupilumab treatment for atopic diseases. *Ocul Surf*. 2021;19:151-156.
50. Bohner A, Topham C, Strunck J, et al. Dupilumab-associated ocular surface disease: Clinical characteristics, treatment, and follow-up. *Cornea*. 2021;40:584-589.
51. Nahum Y, Mimouni M, Livny E, et al. Dupilumab-induced ocular surface disease (DIOSD) in patients with atopic dermatitis: Clinical presentation, risk factors for development and outcomes of treatment with tacrolimus ointment. *Br J Ophthalmol*. 2020;104:776-779.
52. Hahn JM, Meisler DM, Lowder CY, et al. Cicatrizing conjunctivitis associated with paraneoplastic lichen planus. *Am J Ophthalmol*. 2000;129:98-99.

53. Ueta M. Genetic predisposition to Stevens-Johnson Syndrome with severe ocular surface complications. *Cornea*. 2015;34 Suppl 11:S158-165.
54. Manrique Lipa RK, de los Bueis AB, De los Rios JJ, Manrique Lipa RD. Sarcoidosis presenting as acute bulbar follicular conjunctivitis. *Clin Exp Optom*. 2010;93:363-365.
55. Dithmar S, Waring GO, 3rd, Goldblum TA, Grossniklaus HE. Conjunctival deposits as an initial manifestation of sarcoidosis. *Am J Ophthalmol*. 1999;128:361-362.
56. Geggel HS, Mensher JH. Cicatricial conjunctivitis in sarcoidosis: Recognition and treatment. *Ann Ophthalmol*. 1989;21:92-94.
57. Bullen CL, Liesegang TJ, McDonald TJ, DeRemee RA. Ocular complications of Wegener's granulomatosis. *Ophthalmology*. 1983;90:279-290.
58. Akova YA, Jabbur NS, Foster CS. Ocular presentation of polyarteritis nodosa. Clinical course and management with steroid and cytotoxic therapy. *Ophthalmology*. 1993;100:1775-1781.
59. Caster JC, Shetlar DJ, Pappolla MA, Yee RW. Microscopic polyangiitis with ocular involvement. *Arch Ophthalmol*. 1996;114:346-348.
60. Herbort CP, Rao NA, Mochizuki M, Members of Scientific Committee of First International Workshop on Ocular Sarcoidosis. International criteria for the diagnosis of ocular sarcoidosis: Results of the first international workshop on ocular sarcoidosis (IWOS). *Ocul Immunol Inflamm*. 2009;17:160-169.
61. Miserocchi E, Modorati G, Di Matteo F, et al. Visual outcome in ocular sarcoidosis: Retrospective evaluation of risk factors. *Eur J Ophthalmol*. 2011;21:802-810.
62. Grau RG. Drug-induced vasculitis: New insights and a changing lineup of suspects. *Curr Rheumatol Rep*. 2015;17:71.
63. Birnbaum AD, Rifkin LM. Sarcoidosis: Sex-dependent variations in presentation and management. *J Ophthalmol*. 2014;2014:236905.
64. Rao N, McLean J, Zimmerman L. Sebaceous carcinoma of the eyelid and caruncle: Correlation of clinicopathologic features with prognosis. In: Jakobiec F, ed. *Ocular and adnexal tumors*. Birmingham: Aesculapius, 1978.
65. Akpek EK, Polcharoen W, Chan R, Foster CS. Ocular surface neoplasia masquerading as chronic blepharoconjunctivitis. *Cornea*. 1999;18:282-288.
66. Shields CL, Shields JA, Carvalho C, et al. Conjunctival lymphoid tumors: Clinical analysis of 117 cases and relationship to systemic lymphoma. *Ophthalmology*. 2001;108:979-984.
67. McGrath LA, Ryan DA, Warriar SK, et al. Conjunctival lymphoma. *Eye (Lond)*. 2022.
68. de-Arriba-Palomero F, Salva-Palomeque T, de-Arriba-Palomero P, Arnalich-Montiel F. Epidemiology of pseudomembranous conjunctivitis in a tertiary hospital: A 2-year retrospective study. *Eur J Ophthalmol*. 2021;31:2275-2279.
69. Tsatsos M, MacGregor C, Athanasiadis I, et al. Herpes simplex virus keratitis: An update of the pathogenesis and current treatment with oral and topical antiviral agents. *Clin Exp Ophthalmol*. 2016;44:824-837.
70. Souza PM, Holland EJ, Huang AJ. Bilateral herpetic keratoconjunctivitis. *Ophthalmology*. 2003;110:493-496.
71. Kaykicioglu O, Kir E, Soyler M, et al. Ocular findings in a measles epidemic among young adults. *Ocul Immunol Inflamm*. 2000;8:59-62.
72. Pavlopoulos GP, Giannakos GI, Theodosiadis PG, et al. Rubeola keratitis: A photographic study of corneal lesions. *Cornea*. 2008;27:411-416.
73. North DP. Ocular complications of mumps. *Br J Ophthalmol*. 1953;37:99-101.
74. Hara J, Fujimoto F, Ishibashi T, et al. Ocular manifestations of the 1976 rubella epidemic in Japan. *Am J Ophthalmol*. 1979;87:642-645.
75. Rota PA, Moss WJ, Takeda M, et al. Measles. *Nat Rev Dis Primers*. 2016;2:16049.
76. Alba-Linero C, Rocha-de-Lossada C, Rachwani-Anil R, et al. Anterior segment involvement in Epstein-Barr virus: A review. *Acta Ophthalmol*. 2022;100:e1052-e1060.
77. Wong KW, D'Amico DJ, Hedges TR, 3rd, et al. Ocular involvement associated with chronic Epstein-Barr virus disease. *Arch Ophthalmol*. 1987;105:788-792.
78. Matoba AY. Ocular disease associated with Epstein-Barr virus infection. *Surv Ophthalmol*. 1990;35:145-150.
79. Singh S, Kumar A. Ocular manifestations of emerging flaviviruses and the blood-retinal barrier. *Viruses*. 2018;10.
80. Agrawal R, Oo HH, Balne PK, et al. Zika virus and the eye. *Ocul Immunol Inflamm*. 2018;26:654-659.
81. Labib BA, Chigbu DI. Pathogenesis and manifestations of zika virus-associated ocular diseases. *Trop Med Infect Dis*. 2022;7.

82. Mocanu V, Bhagwani D, Sharma A, et al. COVID-19 and the human eye: Conjunctivitis, a lone COVID-19 finding - a case-control study. *Med Princ Pract.* 2022;31:66-73.
83. Ho D, Low R, Tong L, et al. COVID-19 and the ocular surface: A review of transmission and manifestations. *Ocul Immunol Inflamm.* 2020;28:726-734.
84. Perez-Bartolome F, Sanchez-Quiros J. Ocular manifestations of SARS-COV-2: Literature review. *Arch Soc Esp Ophthalmol (Engl Ed).* 2021;96:32-40.
85. Layikh HA, Hashim ZA, Kadum AA. Conjunctivitis and other ocular findings in patients with COVID-19 infection. *Ann Saudi Med.* 2021;41:280-284.
86. Gandhi AP, Gupta PC, Padhi BK, et al. Ophthalmic manifestations of the monkeypox virus: A systematic review and meta-analysis. *Pathogens.* 2023;12.
87. Zong Y, Kamoi K, Zhang J, et al. Mpox (monkeypox) and the eye: Ocular manifestation, diagnosis, treatment and vaccination. *Viruses.* 2023;15.
88. Pazos M, Riera J, Moll-Udina A, et al. Characteristics and management of ocular involvement in individuals with monkeypox disease. *Ophthalmology.* 2023.
89. Hughes C, McCollum A, Pukuta E, et al. Ocular complications associated with acute monkeypox virus infection, DRC. *International Journal of Infectious Diseases.* 2014;21:276-277.
90. Tang XJ, He JT, Liu Q, et al. Severe ophthalmia neonatorum in Southwest China: A 5-year review of demographics, microbiological results, and risk factors. *Int Ophthalmol.* 2022.
91. Honkila M, Renko M, Pokka T, et al. Symptoms, signs and long-term prognosis of vertically transmitted chlamydia trachomatis infections. *Pediatr Infect Dis J.* 2018;37:930-933.
92. Dixon MK, Dayton CL, Anstead GM. Parinaud's oculoglandular syndrome: A case in an adult with flea-borne typhus and a review. *Trop Med Infect Dis.* 2020;5.
93. Tavares-Junior JW, Teles Junior JN, Magalhaes SC, et al. Parinaud syndrome due to confirmed neurotuberculosis in a lupus eritematosus systemic patient. *Eur J Ophthalmol.* 2022:11206721221098284.
94. Chiang WY, Liu TT, Huang WT, Kuo MT. Co-existing ligneous conjunctivitis and IgG4-related disease. *Indian J Ophthalmol.* 2016;64:532-534.
95. Shapiro AD, Menegatti M, Palla R, et al. An international registry of patients with plasminogen deficiency (history). *Haematologica.* 2020;105:554-561.
96. Pokroy R, Marcovich A. Self-inflicted (factitious) conjunctivitis. *Ophthalmology.* 2003;110:790-795.
97. Kapoor HK, Jaison SG, Chopra R, Kakkar N. Factitious keratoconjunctivitis. *Indian J Ophthalmol.* 2006;54:282-283.
98. Murthy VR, Matada R, Deshmukh AV, et al. An interesting case of factitious pseudomembranous conjunctivitis. *Indian J Ophthalmol.* 2019;67:1693-1694.
99. Orsoni JG, Rubino P, Pellistri I, et al. Factitious pseudo-membranous conjunctivitis in an adolescent boy. *Case Rep Ophthalmol.* 2011;2:69-72.
100. Imrie FR, Church WH. Factitious keratoconjunctivitis (not another case of ocular Munchausen's syndrome). *Eye (Lond).* 2003;17:256-258.
101. McCulley JP, Moore MB, Matoba AY. Mucus fishing syndrome. *Ophthalmology.* 1985;92:1262-1265.
102. Chalmers DA. Rosacea: Recognition and management for the primary care provider. *Nurse Pract.* 1997;22:18, 23-18, 30.
103. Chuck RS, Dunn SP, Flaxel CJ, et al. Comprehensive adult medical eye evaluation preferred practice pattern. *Ophthalmology.* 2021;128:P1-P29.
104. Rapoza PA, Quinn TC, Kiessling LA, et al. Assessment of neonatal conjunctivitis with a direct immunofluorescent monoclonal antibody stain for chlamydia. *JAMA.* 1986;255:3369-3373.
105. Inada N, Shoji J, Yamagami S. Infantile acute conjunctivitis induced by beta-lactamase-positive amoxicillin-clavulanate-resistant strain of haemophilus influenzae: A report of three cases. *Eye Contact Lens.* 2019;45:e11-e14.
106. Sambursky R, Tauber S, Schirra F, et al. The RPS adeno detector for diagnosing adenoviral conjunctivitis. *Ophthalmology.* 2006;113:1758-1764.
107. Kam KY, Ong HS, Bunce C, et al. Sensitivity and specificity of the adenoplus point-of-care system in detecting adenovirus in conjunctivitis patients at an ophthalmic emergency department: A diagnostic accuracy study. *Br J Ophthalmol.* 2015;99:1186-1189.
108. Udeh BL, Schneider JE, Ohsfeldt RL. Cost effectiveness of a point-of-care test for adenoviral conjunctivitis. *Am J Med Sci.* 2008;336:254-264.
109. Choi S, Moon SW, Shin JH, et al. Label-free biochemical analytic method for the early detection of adenoviral conjunctivitis using human tear biofluids. *Anal Chem.* 2014;86:11093-11099.
110. Dreyfuss JL, Regatieri CV, Coelho B, et al. Altered hyaluronic acid content in tear fluid of patients with adenoviral conjunctivitis. *An Acad Bras Cienc.* 2015;87:455-462.

111. Dutescu RM, Banasik P, Schildgen O, et al. Detection of coronavirus in tear samples of hospitalized patients with confirmed SARS-COV-2 from oropharyngeal swabs. *Cornea*. 2021;40:348-350.
112. Johnson RE, Newhall WJ, Papp JR, et al. Screening tests to detect *chlamydia trachomatis* and *neisseria gonorrhoeae* infections--2002. *MMWR Recomm Rep*. 2002;51 (No. RR-15):1-38.
113. Stenberg K, Herrmann B, Dannevig L, et al. Culture, ELISA and immunofluorescence tests for the diagnosis of conjunctivitis caused by *chlamydia trachomatis* in neonates and adults. *Apmis*. 1990;98:514-520.
114. Kowalski RP, Uhrin M, Karenchak LM, et al. Evaluation of the polymerase chain reaction test for detecting chlamydial DNA in adult chlamydial conjunctivitis. *Ophthalmology*. 1995;102:1016-1019.
115. Kessler HH, Pierer K, Stuenzner D, et al. Rapid detection of *chlamydia trachomatis* in conjunctival, pharyngeal, and urethral specimens with a new polymerase chain reaction assay. *Sex Transm Dis*. 1994;21:191-195.
116. Kowalski RP, Karenchak LM, Raju LV, Ismail N. The verification of nucleic acid amplification testing (Gen-Probe Aptima Assay) for *chlamydia trachomatis* from ocular samples. *Ophthalmology*. 2015;122:244-247.
117. De Smedt S, Wildner G, Kestelyn P. Vernal keratoconjunctivitis: An update. *Br J Ophthalmol*. 2013;97:9-14.
118. Bruschi G, Ghigloni DG, Osnaghi S, et al. Role of ocular cytology in vernal keratoconjunctivitis. *Immun Inflamm Dis*. 2020;8:3-7.
119. Wu M, Wang X, Han J, et al. Evaluation of the ocular surface characteristics and demodex infestation in paediatric and adult blepharokeratoconjunctivitis. *BMC Ophthalmol*. 2019;19:67.
120. Power WJ, Neves RA, Rodriguez A, et al. Increasing the diagnostic yield of conjunctival biopsy in patients with suspected ocular cicatricial pemphigoid. *Ophthalmology*. 1995;102:1158-1163.
121. Foster CS. Cicatricial pemphigoid. *Trans Am Ophthalmol Soc*. 1986;84:527-663.
122. Goldich Y, Ziai S, Artornsombudh P, et al. Characteristics of patients with ocular cicatricial pemphigoid referred to major tertiary hospital. *Can J Ophthalmol*. 2015;50:137-142.
123. Gilberg S, Tse D. Malignant eyelid tumors. *Ophthalmol Clin North Am*. 1992;5:261-285.
124. Pasadhika S, Rosenbaum JT. Ocular sarcoidosis. *Clin Chest Med*. 2015;36:669-683.
125. Leonardi A, Piliago F, Castegnaro A, et al. Allergic conjunctivitis: A cross-sectional study. *Clin Exp Allergy*. 2015;45:1118-1125.
126. Bielory L, Delgado L, Katelaris CH, et al. Icon: Diagnosis and management of allergic conjunctivitis. *Ann Allergy Asthma Immunol*. 2020;124:118-134.
127. Mimura T, Usui T, Yamagami S, et al. Relation between total tear IgE and severity of acute seasonal allergic conjunctivitis. *Curr Eye Res*. 2012;37:864-870.
128. Armentia A, Iglesias B, Iglesias D, et al. Component-resolved diagnostics in vernal conjunctivitis. *Ann Allergy Asthma Immunol*. 2015;115:446-450.
129. Kruse K, Gerwin E, Eichel A, et al. Conjunctival provocation tests: A predictive factor for patients' seasonal allergic rhinoconjunctivitis symptoms. *J Allergy Clin Immunol Pract*. 2015;3:381-386.
130. Yenigun A, Dadaci Z, Oncel M. Plasma vitamin D levels of patients with allergic rhino-conjunctivitis with positive skin prick test. *Am J Rhinol Allergy*. 2015;29:e46-49.
131. Dadaci Z, Borazan M, Kiyici A, Oncel Acir N. Plasma vitamin D and serum total immunoglobulin E levels in patients with seasonal allergic conjunctivitis. *Acta Ophthalmol*. 2014;92:e443-446.
132. Lierl MB. New developments in the treatment of pediatric allergic rhinitis and conjunctivitis. *Pediatr Ann*. 2014;43:e192-200.
133. Zicari AM, Cafarotti A, Occasi F, et al. Vitamin D levels in children affected by vernal keratoconjunctivitis. *Curr Med Res Opin*. 2017;33:269-274.
134. Bozkurt B, Artac H, Ozdemir H, et al. Serum vitamin D levels in children with vernal keratoconjunctivitis. *Ocul Immunol Inflamm*. 2016:1-5.
135. Rodrigues J, Kuruvilla ME, Vanijcharoenkarn K, et al. The spectrum of allergic ocular diseases. *Ann Allergy Asthma Immunol*. 2021;126:240-254.
136. Bignardi D, Comite P, Mori I, et al. Allergen-specific IgE: Comparison between skin prick test and serum assay in real life. *Allergol Select*. 2019;3:9-14.
137. Kavitha V, Heralgi MM, Aafreen S. Comparison of posterior corneal elevation in children with and without vernal keratoconjunctivitis using a new tomographer. *Indian J Ophthalmol*. 2021;69:2060-2063.
138. Feizi S, Javadi MA, Alemzadeh-Ansari M, et al. Management of corneal complications in vernal keratoconjunctivitis: A review. *Ocul Surf*. 2021;19:282-289.
139. Weng SF, Jan RL, Wang JJ, et al. Association between atopic keratoconjunctivitis and the risk of keratoconus. *Acta Ophthalmol*. 2021;99:e54-e61.

140. Zhang X, Huang F, Qiu J, et al. Corneal biomechanical properties in vernal keratoconjunctivitis and its subtypes: A preliminary study. *Int Ophthalmol*. 2023;43:2083-2090.
141. Al-Hayouti H, Daniel M, Hingorani M, et al. Meibography and corneal volume optical coherence tomography to quantify damage to ocular structures in children with blepharokeratoconjunctivitis. *Acta Ophthalmol*. 2019;97:e981-e986.
142. Tenzel RR. Comments on superior limbic filamentous keratitis: II. *Arch Ophthalmol*. 1968;79:508.
143. Theodore FH. Comments on findings of elevated protein-bound iodine in superior limbic keratoconjunctivitis: I. *Arch Ophthalmol*. 1968;79:508.
144. Wang P, Yu DJ, Feng G, et al. Is floppy eyelid syndrome more prevalent in obstructive sleep apnea syndrome patients? *J Ophthalmol*. 2016;2016:6980281.
145. Erekosima N, Suarez-Cuervo C, Ramanathan M, et al. Effectiveness of subcutaneous immunotherapy for allergic rhinoconjunctivitis and asthma: A systematic review. *Laryngoscope*. 2014;124:616-627.
146. Nurmatov U, Dhimi S, Arasi S, et al. Allergen immunotherapy for allergic rhinoconjunctivitis: A systematic overview of systematic reviews. *Clin Transl Allergy*. 2017;7:24.
147. Centers for disease control and prevention. Sexually transmitted diseases treatment guidelines, 2010. *MMWR Morb Mortal Wkly Rep*. 2010;59 (No. RR-12):55.
148. Isenberg SJ, Apt L, Wood M. A controlled trial of povidone-iodine as prophylaxis against ophthalmia neonatorum. *N Engl J Med*. 1995;332:562-566.
149. Isenberg SJ, Apt L, Yoshimori R, et al. Povidone-iodine for ophthalmia neonatorum prophylaxis. *Am J Ophthalmol*. 1994;118:701-706.
150. David M, Rumelt S, Weintraub Z. Efficacy comparison between povidone iodine 2.5% and tetracycline 1% in prevention of ophthalmia neonatorum. *Ophthalmology*. 2011;118:1454-1458.
151. Centers for Disease Control and Prevention. Vaccines and preventable diseases. Measles, mumps, rubella (MMR) vaccination: What everyone should know. www.cdc.gov/vaccines/vpd/mmr/public/index.html. Accessed November 17, 2023.
152. Knopf HL, Hierholzer JC. Clinical and immunologic responses in patients with viral keratoconjunctivitis. *Am J Ophthalmol*. 1975;80:661-672.
153. Warren D, Nelson KE, Farrar JA, et al. A large outbreak of epidemic keratoconjunctivitis: Problems in controlling nosocomial spread. *J Infect Dis*. 1989;160:938-943.
154. Buehler JW, Finton RJ, Goodman RA, et al. Epidemic keratoconjunctivitis: Report of an outbreak in an ophthalmology practice and recommendations for prevention. *Infect Control*. 1984;5:390-394.
155. Reilly S, Dhillon BJ, Nkanza KM, et al. Adenovirus type 8 keratoconjunctivitis--an outbreak and its treatment with topical human fibroblast interferon. *J Hyg (Lond)*. 1986;96:557-575.
156. Koo D, Bouvier B, Wesley M, et al. Epidemic keratoconjunctivitis in a university medical center ophthalmology clinic; need for re-evaluation of the design and disinfection of instruments. *Infect Control Hosp Epidemiol*. 1989;10:547-552.
157. Centers for Disease C, Prevention. Adenovirus-associated epidemic keratoconjunctivitis outbreaks--four states, 2008-2010. *MMWR Morb Mortal Wkly Rep*. 2013;62:637-641.
158. Stern ME, Beuerman RW, Fox RI, et al. The pathology of dry eye: The interaction between the ocular surface and lacrimal glands. *Cornea*. 1998;17:584-589.
159. Rutala WA, Peacock JE, Gergen MF, et al. Efficacy of hospital germicides against adenovirus 8, a common cause of epidemic keratoconjunctivitis in health care facilities. *Antimicrob Agents Chemother*. 2006;50:1419-1424.
160. Gordon YJ, Gordon RY, Romanowski E, Araullo-Cruz TP. Prolonged recovery of desiccated adenoviral serotypes 5, 8, and 19 from plastic and metal surfaces in vitro. *Ophthalmology*. 1993;100:1835-1839; discussion 1839-1840.
161. Nauheim RC, Romanowski EG, Araullo-Cruz T, et al. Prolonged recoverability of desiccated adenovirus type 19 from various surfaces. *Ophthalmology*. 1990;97:1450-1453.
162. Cillino S, Casuccio A, Giammanco GM, et al. Tonometers and infectious risk: Myth or reality? Efficacy of different disinfection regimens on tonometer tips. *Eye*. 2007;21:541-546.
163. Haag-Streit Diagnostics. Instructions for use. Cleaning and disinfection: Tonometer measuring prisms, contact glasses, and desinset.
164. Reichert Technologies. Ct100 contact tonometer user's guide.
165. Craven ER, Butler SL, McCulley JP, Luby JP. Applanation tonometer tip sterilization for adenovirus type 8. *Ophthalmology*. 1987;94:1538-1540.
166. Owen CG, Shah A, Henshaw K, et al. Topical treatments for seasonal allergic conjunctivitis: Systematic review and meta-analysis of efficacy and effectiveness. *Br J Gen Pract*. 2004;54:451-456.

167. Olopatadine for the treatment of allergic conjunctivitis: A review of the clinical efficacy, safety, and cost-effectiveness. Ottawa (ON)2016.
168. Castillo M, Scott NW, Mustafa MZ, et al. Topical antihistamines and mast cell stabilisers for treating seasonal and perennial allergic conjunctivitis. *Cochrane Database Syst Rev.* 2015;CD009566.
169. Kam KW, Chen LJ, Wat N, Young AL. Topical olopatadine in the treatment of allergic conjunctivitis: A systematic review and meta-analysis. *Ocul Immunol Inflamm.* 2017;25:663-677.
170. New drugs for allergic conjunctivitis. *Med Lett Drugs Ther.* 2000;42:39-40.
171. Abelson MB, Torkildsen GL, Williams JI, et al. Time to onset and duration of action of the antihistamine bepotastine besilate ophthalmic solutions 1.0% and 1.5% in allergic conjunctivitis: A phase III, single-center, prospective, randomized, double-masked, placebo-controlled, conjunctival allergen challenge assessment in adults and children. *Clin Ther.* 2009;31:1908-1921.
172. Borazan M, Karalezli A, Akova YA, et al. Efficacy of olopatadine HCl 0.1%, ketotifen fumarate 0.025%, epinastine HCl 0.05%, emedastine 0.05% and fluorometholone acetate 0.1% ophthalmic solutions for seasonal allergic conjunctivitis: A placebo-controlled environmental trial. *Acta Ophthalmol.* 2009;87:549-554.
173. Figus M, Fogagnolo P, Lazzeri S, et al. Treatment of allergic conjunctivitis: Results of a 1-month, single-masked randomized study. *Eur J Ophthalmol.* 2010;20:811-818.
174. Fujishima H, Fukagawa K, Tanaka M, et al. The effect of a combined therapy with a histamine H1 antagonist and a chemical mediator release inhibitor on allergic conjunctivitis. *Ophthalmologica.* 2008;222:232-239.
175. Macejko TT, Bergmann MT, Williams JI, et al. Multicenter clinical evaluation of bepotastine besilate ophthalmic solutions 1.0% and 1.5% to treat allergic conjunctivitis. *Am J Ophthalmol.* 2010;150:122-127.
176. Abelson MB, Shetty S, Korchak M, et al. Advances in pharmacotherapy for allergic conjunctivitis. *Expert Opin Pharmacother.* 2015;16:1219-1231.
177. Torkildsen GL, Williams JI, Gow JA, et al. Bepotastine besilate ophthalmic solution for the relief of nonocular symptoms provoked by conjunctival allergen challenge. *Ann Allergy Asthma Immunol.* 2010;105:57-64.
178. Bielory L. Ocular toxicity of systemic asthma and allergy treatments. *Curr Allergy Asthma Rep.* 2006;6:299-305.
179. La Rosa M, Lionetti E, Reibaldi M, et al. Allergic conjunctivitis: A comprehensive review of the literature. *Ital J Pediatr.* 2013;39:18.
180. Welch D, Ousler GW, 3rd, Nally LA, et al. Ocular drying associated with oral antihistamines (loratadine) in the normal population-an evaluation of exaggerated dose effect. *Adv Exp Med Biol.* 2002;506:1051-1055.
181. Erdinest N, Solomon A. Topical immunomodulators in the management of allergic eye diseases. *Curr Opin Allergy Clin Immunol.* 2014;14:457-463.
182. Wei Q, Le Q, Hong J, et al. In vivo confocal microscopy of meibomian glands and palpebral conjunctiva in vernal keratoconjunctivitis. *Indian J Ophthalmol.* 2015;63:327-330.
183. Wan KH, Chen LJ, Rong SS, et al. Topical cyclosporine in the treatment of allergic conjunctivitis: A meta-analysis. *Ophthalmology.* 2013;120:2197-2203.
184. Kimchi N, Bielory L. The allergic eye: Recommendations about pharmacotherapy and recent therapeutic agents. *Curr Opin Allergy Clin Immunol.* 2020;20:414-420.
185. Lin SY, Erekosima N, Kim JM, et al. Sublingual immunotherapy for the treatment of allergic rhinoconjunctivitis and asthma: A systematic review. *JAMA.* 2013;309:1278-1288.
186. Nelson H, Cartier S, Allen-Ramey F, et al. Network meta-analysis shows commercialized subcutaneous and sublingual grass products have comparable efficacy. *J Allergy Clin Immunol Pract.* 2015;3:256-266 e253.
187. Lin SY, Erekosima N, Suarez-Cuervo C, et al. Allergen-specific immunotherapy for the treatment of allergic rhinoconjunctivitis and/or asthma: Comparative effectiveness review. Rockville (MD)2013.
188. Yang J, Zhang L, Zhao Z, Liao S. Sublingual immunotherapy for pediatric allergic conjunctivitis: A meta-analysis of randomized controlled trials. *Int Forum Allergy Rhinol.* 2018;8:1253-1259.
189. Banerjee K, Mathie RT, Costelloe C, Howick J. Homeopathy for allergic rhinitis: A systematic review. *J Altern Complement Med.* 2017;23:426-444.
190. Di Bona D, Plaia A, Leto-Barone MS, et al. Efficacy of grass pollen allergen sublingual immunotherapy tablets for seasonal allergic rhinoconjunctivitis: A systematic review and meta-analysis. *JAMA Intern Med.* 2015;175:1301-1309.
191. Calderon MA, Penagos M, Sheikh A, et al. Sublingual immunotherapy for treating allergic conjunctivitis. *Cochrane Database Syst Rev.* 2011;CD007685.

192. Hoang MP, Seresirikachorn K, Chitsuthipakorn W, Snidvongs K. Intralymphatic immunotherapy for allergic rhinoconjunctivitis: A systematic review and meta-analysis. *Rhinology*. 2021;59:236-244.
193. Wu LQ, Chen X, Lou H, et al. Loteprednol etabonate in the treatment of allergic conjunctivitis: A meta-analysis. *Curr Med Res Opin*. 2015;31:1509-1518.
194. Sharma N, Rao K, Maharana PK, Vajpayee RB. Ocular allergy and keratoconus. *Indian J Ophthalmol*. 2013;61:407-409.
195. Shetty R, Sureka S, Kusumgar P, et al. Allergen-specific exposure associated with high immunoglobulin E and eye rubbing predisposes to progression of keratoconus. *Indian J Ophthalmol*. 2017;65:399-402.
196. Erratum: Allergen specific exposure associated with high immunoglobulin E and eye rubbing predisposes to progression of keratoconus. *Indian J Ophthalmol*. 2017;65:642-643.
197. Naderan M, Rajabi MT, Zarrinbakhsh P, Bakhshi A. Effect of allergic diseases on keratoconus severity. *Ocul Immunol Inflamm*. 2017;25:418-423.
198. American Academy of Ophthalmology Cornea/External Disease Panel. Preferred practice pattern® guidelines. Corneal ectasia. San Francisco, CA: American Academy of Ophthalmology; 2023. www.aao.org/ppp. Accessed November 17, 2023
199. Pucci N, Novembre E, Cianferoni A, et al. Efficacy and safety of cyclosporine eyedrops in vernal keratoconjunctivitis. *Ann Allergy Asthma Immunol*. 2002;89:298-303.
200. Kiliç A, Gürlü B. Topical 2% cyclosporine a in preservative-free artificial tears for the treatment of vernal keratoconjunctivitis. *Can J Ophthalmol*. 2006;41:693-698.
201. Ozcan AA, Ersoz TR, Dulger E. Management of severe allergic conjunctivitis with topical cyclosporin A 0.05% eyedrops. *Cornea*. 2007;26:1035-1038.
202. Akpek EK, Dart JK, Watson S, et al. A randomized trial of topical cyclosporin 0.05% in topical steroid-resistant atopic keratoconjunctivitis. *Ophthalmology*. 2004;111:476-482.
203. Daniell M, Constantinou M, Vu HT, Taylor HR. Randomised controlled trial of topical ciclosporin A in steroid dependent allergic conjunctivitis. *Br J Ophthalmol*. 2006;90:461-464.
204. Lambiase A, Leonardi A, Sacchetti M, et al. Topical cyclosporine prevents seasonal recurrences of vernal keratoconjunctivitis in a randomized, double-masked, controlled 2-year study. *J Allergy Clin Immunol*. 2011;128:896-897.
205. Oray M, Toker E. Tear cytokine levels in vernal keratoconjunctivitis: The effect of topical 0.05% cyclosporine A therapy. *Cornea*. 2013;32:1149-1154.
206. Leonardi A, Doan S, Amrane M, et al. A randomized, controlled trial of cyclosporine A cationic emulsion in pediatric vernal keratoconjunctivitis: The vektis study. *Ophthalmology*. 2019;126:671-681.
207. Vichyanond P, Kosrirukvongs P. Use of cyclosporine A and tacrolimus in treatment of vernal keratoconjunctivitis. *Curr Allergy Asthma Rep*. 2013;13:308-314.
208. Gonzalez-Lopez JJ, Lopez-Alcalde J, Morcillo Laiz R, et al. Topical cyclosporine for atopic keratoconjunctivitis. *Cochrane Database Syst Rev*. 2012:CD009078.
209. Zanjani H, Aminifard MN, Ghafourian A, et al. Comparative evaluation of tacrolimus versus interferon alpha-2b eye drops in the treatment of vernal keratoconjunctivitis: A randomized, double-masked study. *Cornea*. 2017;36:675-678.
210. Holsclaw DS, Whitcher JP, Wong IG, Margolis TP. Supratarsal injection of corticosteroid in the treatment of refractory vernal keratoconjunctivitis. *Am J Ophthalmol*. 1996;121:243-249.
211. Al-Amri AM. Long-term follow-up of tacrolimus ointment for treatment of atopic keratoconjunctivitis. *Am J Ophthalmol*. 2014;157:280-286.
212. Rikers SM, Holland GN, Drayton GE, et al. Topical tacrolimus treatment of atopic eyelid disease. *Am J Ophthalmol*. 2003;135:297-302.
213. Meurer M, Lubbe J, Kapp A, Schneider D. The role of pimecrolimus cream 1% (elidel) in managing adult atopic eczema. *Dermatology*. 2007;215 Suppl 1:18-26.
214. Eichenfield LF, Thaci D, de Prost Y, et al. Clinical management of atopic eczema with pimecrolimus cream 1% (elidel) in paediatric patients. *Dermatology*. 2007;215 Suppl 1:3-17.
215. Muller EG, Santos MSD, Freitas D, et al. Tacrolimus eye drops as monotherapy for vernal keratoconjunctivitis: A randomized controlled trial. *Arq Bras Oftalmol*. 2017;80:154-158.
216. Pucci N, Caputo R, di Grande L, et al. Tacrolimus vs. cyclosporine eyedrops in severe cyclosporine-resistant vernal keratoconjunctivitis: A randomized, comparative, double-blind, crossover study. *Pediatr Allergy Immunol*. 2015;26:256-261.
217. Ohashi Y, Ebihara N, Fujishima H, et al. A randomized, placebo-controlled clinical trial of tacrolimus ophthalmic suspension 0.1% in severe allergic conjunctivitis. *J Ocul Pharmacol Ther*. 2010;26:165-174.
218. Gane J, Buckley R. Leukotriene receptor antagonists in allergic eye disease: A systematic review and meta-analysis. *J Allergy Clin Immunol Pract*. 2013;1:65-74.

219. Chen JJ, Applebaum DS, Sun GS, Pflugfelder SC. Atopic keratoconjunctivitis: A review. *J Am Acad Dermatol*. 2014;70:569-575.
220. Kheirikhah A, Zavareh MK, Farzbod F, et al. Topical 0.005% tacrolimus eye drop for refractory vernal keratoconjunctivitis. *Eye (Lond)*. 2011;25:872-880.
221. Li A, Li S, Ruan F, Jie Y. Atopic keratoconjunctivitis: A diagnostic dilemma—a case report. *Medicine (Baltimore)*. 2018;97:e0372.
222. Kim SE, Nowak V, Quartilho A, et al. Systemic interventions for severe atopic and vernal keratoconjunctivitis in children and young people up to the age of 16 years. *Cochrane Database Syst Rev*. 2020;10:CD013298.
223. McNeill AM, Koo JY. "Unknown risks" of non-steroid topical medications for atopic dermatitis. *Int J Dermatol*. 2007;46:656-658.
224. Ormerod AD. Topical tacrolimus and pimecrolimus and the risk of cancer: How much cause for concern? *Br J Dermatol*. 2005;153:701-705.
225. Bhat P, Birnbaum AD. *Focal points 2015 module: Diagnosis and management of noninfectious corneal ulceration and melting*. San Francisco, CA: American Academy of Ophthalmology; 2015.
226. Arora R, Jain P, Gupta D, Goyal JL. Sterile keratitis after corneal collagen crosslinking in a child. *Cont Lens Anterior Eye*. 2012;35:233-235.
227. Perry HD, Doshi-Carnevale S, Donnenfeld ED, Kornstein HS. Topical cyclosporine 0.5% as a possible new treatment for superior limbic keratoconjunctivitis. *Ophthalmology*. 2003;110:1578-1581.
228. Lemp MA, Nichols KK. Blepharitis in the United States 2009: A survey-based perspective on prevalence and treatment. *Ocul Surf*. 2009;7:S1-S14.
229. Albiets J, Sanfilippo P, Troutbeck R, Lenton LM. Management of filamentary keratitis associated with aqueous-deficient dry eye. *Optom Vis Sci*. 2003;80:420-430.
230. Lahoti S, Weiss M, Johnson DA, Kheirikhah A. Superior limbic keratoconjunctivitis: A comprehensive review. *Surv Ophthalmol*. 2022;67:331-341.
231. Sun YC, Hsiao CH, Chen WL, et al. Conjunctival resection combined with tenon layer excision and the involvement of mast cells in superior limbic keratoconjunctivitis. *Am J Ophthalmol*. 2008;145:445-452.
232. Jeng BH, Halfpenny CP, Meisler DM, Stock EL. Management of focal limbal stem cell deficiency associated with soft contact lens wear. *Cornea*. 2011;30:18-23.
233. Kim BY, Riaz KM, Bakhtiari P, et al. Medically reversible limbal stem cell disease: Clinical features and management strategies. *Ophthalmology*. 2014;121:2053-2058.
234. Rossen J, Amram A, Milani B, et al. Contact lens-induced limbal stem cell deficiency. *Ocul Surf*. 2016;14:419-434.
235. Khurana S, Sharma N, Agarwal T, et al. Comparison of olopatadine and fluorometholone in contact lens-induced papillary conjunctivitis. *Eye Contact Lens*. 2010;36:210-214.
236. Diao H, She Z, Cao D, et al. Comparison of tacrolimus, fluorometholone, and saline in mild-to-moderate contact lens-induced papillary conjunctivitis. *Adv Ther*. 2012;29:645-653.
237. Schwartz LK, Gelender H, Forster RK. Chronic conjunctivitis associated with 'floppy eyelids'. *Arch Ophthalmol*. 1983;101:1884-1888.
238. Culbertson WW, Tseng SC. Corneal disorders in floppy eyelid syndrome. *Cornea*. 1994;13:33-42.
239. Compton CJ, Melson AT, Clark JD, et al. Combined medial canthopexy and lateral tarsal strip for floppy eyelid syndrome. *Am J Otolaryngol*. 2016;37:240-244.
240. Dutton JJ. Surgical management of floppy eyelid syndrome. *Am J Ophthalmol*. 1985;99:557-560.
241. Moore MB, Harrington J, McCulley JP. Floppy eyelid syndrome. Management including surgery. *Ophthalmology*. 1986;93:184-188.
242. Periman LM, Sires BS. Floppy eyelid syndrome: A modified surgical technique. *Ophthal Plast Reconstr Surg*. 2002;18:370-372.
243. Valenzuela AA, Sullivan TJ. Medial upper eyelid shortening to correct medial eyelid laxity in floppy eyelid syndrome: A new surgical approach. *Ophthal Plast Reconstr Surg*. 2005;21:259-263.
244. Karger RA, White WA, Park WC, et al. Prevalence of floppy eyelid syndrome in obstructive sleep apnea-hypopnea syndrome. *Ophthalmology*. 2006;113:1669-1674.
245. Leibovitch I, Selva D. Floppy eyelid syndrome: Clinical features and the association with obstructive sleep apnea. *Sleep Med*. 2006;7:117-122.
246. Ezra DG, Beaconsfield M, Sira M, et al. The associations of floppy eyelid syndrome: A case control study. *Ophthalmology*. 2010;117:831-838.
247. Chambe J, Laib S, Hubbard J, et al. Floppy eyelid syndrome is associated with obstructive sleep apnoea: A prospective study on 127 patients. *J Sleep Res*. 2012;21:308-315.

248. Turaka K, Penne RB, Rapuano CJ, et al. Giant fornix syndrome: A case series. *Ophthalmic Plast Reconstr Surg.* 2012;28:4-6.
249. Karim R, Mandal N, Tuft S. Management of giant fornix syndrome with irrigation with povidone-iodine. *BMJ Case Rep.* 2018;2018.
250. Taylor JB, Fintelmann RE, Jeng BH. Subconjunctival injections and povidone-iodine washings for the treatment of giant fornix syndrome. *Cornea.* 2011;30:479-480.
251. Sheikh A, Hurwitz B, van Schayck CP, et al. Antibiotics versus placebo for acute bacterial conjunctivitis. *Cochrane Database Syst Rev.* 2012;CD001211.
252. Paley GL, Lubniewski AJ, Reidy JJ, Farooq AV. Toxic keratoconjunctivitis. *Eye Contact Lens.* 2018;44 Suppl 1:S8-S15.
253. Ellwein LB, Urato CJ. Use of eye care and associated charges among the medicare population: 1991-1998. *Arch Ophthalmol.* 2002;120:804-811.
254. Saw VP, Dart JK, Rauz S, et al. Immunosuppressive therapy for ocular mucous membrane pemphigoid strategies and outcomes. *Ophthalmology.* 2008;115:253-261.
255. Wilkins MR, Dart JK. Mycophenolate mofetil for the treatment of severe inflammatory external eye diseases. *Br J Ophthalmol.* 2008;92:578-579.
256. Nottage JM, Hammersmith KM, Murchison AP, et al. Treatment of mucous membrane pemphigoid with mycophenolate mofetil. *Cornea.* 2013;32:810-815.
257. U.S. Food and Drug Administration Center for Drug Evaluation and Research. Allergan, inc. Aczone™ (dapson) gel, 5%. Nda 021794-s006. 2008:2.
258. Nguyen QD, Foster CS. Cicatricial pemphigoid: Diagnosis and treatment. *Int Ophthalmol Clin.* 1996;36:41-60.
259. Dragan L, Eng AM, Lam S, Persson T. Tetracycline and niacinamide: Treatment alternatives in ocular cicatricial pemphigoid. *Cutis.* 1999;63:181-183.
260. Doan S, Lerouic JF, Robin H, et al. Treatment of ocular cicatricial pemphigoid with sulfasalazine. *Ophthalmology.* 2001;108:1565-1568.
261. Srikumaran D, Akpek EK. Mucous membrane pemphigoid: Recent advances. *Curr Opin Ophthalmol.* 2012;23:523-527.
262. Doycheva D, Deuter C, Blumenstock G, et al. Long-term results of therapy with mycophenolate mofetil in ocular mucous membrane pemphigoid. *Ocul Immunol Inflamm.* 2011;19:431-438.
263. Foster CS, Ahmed AR. Intravenous immunoglobulin therapy for ocular cicatricial pemphigoid: A preliminary study. *Ophthalmology.* 1999;106:2136-2143.
264. Foster CS, Chang PY, Ahmed AR. Combination of rituximab and intravenous immunoglobulin for recalcitrant ocular cicatricial pemphigoid: A preliminary report. *Ophthalmology.* 2010;117:861-869.
265. Miserocchi E, Baltatzis S, Roque MR, et al. The effect of treatment and its related side effects in patients with severe ocular cicatricial pemphigoid. *Ophthalmology.* 2002;109:111-118.
266. Chan LS, Ahmed AR, Anhalt GJ, et al. The first international consensus on mucous membrane pemphigoid: Definition, diagnostic criteria, pathogenic factors, medical treatment, and prognostic indicators. *Arch Dermatol.* 2002;138:370-379.
267. Yaghoufi F, Nouri M, Abad JC, et al. Keratoprosthesis: Preoperative prognostic categories. *Cornea.* 2001;20:19-23.
268. Palioura S, Kim B, Dohlman CH, Chodosh J. The Boston keratoprosthesis type I in mucous membrane pemphigoid. *Cornea.* 2013;32:956-961.
269. Hart JW, Shiue LH, Shpall EJ, Alousi AM. Extracorporeal photopheresis in the treatment of graft-versus-host disease: Evidence and opinion. *Ther Adv Hematol.* 2013;4:320-334.
270. Robinson MR, Lee SS, Rubin BI, et al. Topical corticosteroid therapy for cicatricial conjunctivitis associated with chronic graft-versus-host disease. *Bone Marrow Transplant.* 2004;33:1031-1035.
271. Lelli GJ, Jr., Musch DC, Gupta A, et al. Ophthalmic cyclosporine use in ocular GVHD. *Cornea.* 2006;25:635-638.
272. Rao SN, Rao RD. Efficacy of topical cyclosporine 0.05% in the treatment of dry eye associated with graft versus host disease. *Cornea.* 2006;25:674-678.
273. Rocha EM, Pelegrino FS, de Paiva CS, et al. GVHD dry eyes treated with autologous serum tears. *Bone Marrow Transplant.* 2000;25:1101-1103.
274. Shikari H, Antin JH, Dana R. Ocular graft-versus-host disease: A review. *Surv Ophthalmol.* 2013;58:233-251.
275. Magro L, Gauthier J, Richet M, et al. Scleral lenses for severe chronic GVHD-related keratoconjunctivitis sicca: A retrospective study by the SFGM-TC. *Bone Marrow Transplant.* 2017;52:878-882.

276. Inamoto Y, Sun YC, Flowers ME, et al. Bandage soft contact lenses for ocular graft-versus-host disease. *Biol Blood Marrow Transplant*. 2015;21:2002-2007.
277. Iovieno A, Cimino L, Fontana L. Unilateral ocular pseudopemphigoid in a patient with glaucoma. *JAMA Ophthalmol*. 2015;133:e143483.
278. Gregory DG. New grading system and treatment guidelines for the acute ocular manifestations of Stevens-Johnson syndrome. *Ophthalmology*. 2016;123:1653-1658.
279. Kohanim S, Palioura S, Saeed HN, et al. Stevens-Johnson syndrome/toxic epidermal necrolysis--a comprehensive review and guide to therapy. I. Systemic disease. *Ocul Surf*. 2016;14:2-19.
280. Kohanim S, Palioura S, Saeed HN, et al. Acute and chronic ophthalmic involvement in Stevens-Johnson syndrome/toxic epidermal necrolysis - a comprehensive review and guide to therapy. II. Ophthalmic disease. *Ocul Surf*. 2016;14:168-188.
281. Jain R, Sharma N, Basu S, et al. Stevens-Johnson syndrome: The role of an ophthalmologist. *Surv Ophthalmol*. 2016;61:369-399.
282. Sharma N, Thenarasun SA, Kaur M, et al. Adjuvant role of amniotic membrane transplantation in acute ocular Stevens-Johnson syndrome: A randomized control trial. *Ophthalmology*. 2016;123:484-491.
283. Hsu M, Jayaram A, Verner R, et al. Indications and outcomes of amniotic membrane transplantation in the management of acute Stevens-Johnson syndrome and toxic epidermal necrolysis: A case-control study. *Cornea*. 2012;31:1394-1402.
284. Knackstedt T, Samie FH. Sebaceous carcinoma: A review of the scientific literature. *Curr Treat Options Oncol*. 2017;18:47.
285. Peksayar G, Altan-Yaycioglu R, Onal S. Excision and cryosurgery in the treatment of conjunctival malignant epithelial tumours. *Eye (Lond)*. 2003;17:228-232.
286. Wheeler M. Interferon alfa-2b injection. Current Drug Shortages: American Society of Health-System Pharmacists, 2022.
287. Galor A, Karp CL, Chhabra S, et al. Topical interferon alpha 2b eye-drops for treatment of ocular surface squamous neoplasia: A dose comparison study. *Br J Ophthalmol*. 2010;94:551-554.
288. Dawson CR, Hanna L, Wood TR, Despain R. Adenovirus type 8 keratoconjunctivitis in the United States. 3. Epidemiologic, clinical, and microbiologic features. *Am J Ophthalmol*. 1970;69:473-480.
289. Ford E, Nelson KE, Warren D. Epidemiology of epidemic keratoconjunctivitis. *Epidemiol Rev*. 1987;9:244-261.
290. Kuo IC, Espinosa C. Five-year trends in adenoviral conjunctivitis in employees of one medical center. *Infect Control Hosp Epidemiol*. 2018;39:1080-1085.
291. Romanowski EG, Yates KA, Gordon YJ. Topical corticosteroids of limited potency promote adenovirus replication in the Ad5/NZW rabbit ocular model. *Cornea*. 2002;21:289-291.
292. Liu SH, Hawkins BS, Ng SM, et al. Topical pharmacologic interventions versus placebo for epidemic keratoconjunctivitis. *Cochrane Database Syst Rev*. 2022;3:CD013520.
293. Tabbara KF, Jarade EF. Ganciclovir effects in adenoviral keratoconjunctivitis [abstract 3111-b253] arvo. 2001;42:S579.
294. Okumus S, Coskun E, Tatar MG, et al. Cyclosporine A 0.05% eye drops for the treatment of subepithelial infiltrates after epidemic keratoconjunctivitis. *BMC Ophthalmol*. 2012;12:42.
295. Gouider D, Khallouli A, Maalej A, et al. Corticosteroids versus cyclosporine for subepithelial infiltrates secondary to epidemic keratoconjunctivitis: A prospective randomized double-blind study. *Cornea*. 2021;40:726-732.
296. Campos M, Takahashi R, Tanaka H, et al. Inflammation-related scarring after photorefractive keratectomy. *Cornea*. 1998;17:607-610.
297. Croxtall JD. Ganciclovir ophthalmic gel 0.15%: In acute herpetic keratitis (dendritic ulcers). *Drugs*. 2011;71:603-610.
298. Wilhelmus KR. Antiviral treatment and other therapeutic interventions for herpes simplex virus epithelial keratitis. *Cochrane Database Syst Rev*. 2015;1:CD002898.
299. Kaufman HE, Haw WH. Ganciclovir ophthalmic gel 0.15%: Safety and efficacy of a new treatment for herpes simplex keratitis. *Curr Eye Res*. 2012;37:654-660.
300. Carter SB, Cohen EJ. Development of herpes simplex virus infectious epithelial keratitis during oral acyclovir therapy and response to topical antivirals. *Cornea*. 2016;35:692-695.
301. Rudnick CM, Hoekzema GS. Neonatal herpes simplex virus infections. *Am Fam Physician*. 2002;65:1138-1142.
302. Matoba A. Ocular viral infections. *Pediatr Infect Dis*. 1984;3:358-368.
303. Li JY. Herpes zoster ophthalmicus: Acute keratitis. *Curr Opin Ophthalmol*. 2018;29:328-333.
304. Ritterband DC, Friedberg DN. Virus infections of the eye. *Rev Med Virol*. 1998;8:187-201.

305. Colin J, Prisant O, Cochener B, et al. Comparison of the efficacy and safety of valaciclovir and acyclovir for the treatment of herpes zoster ophthalmicus. *Ophthalmology*. 2000;107:1507-1511.
306. Tying SK. Efficacy of famciclovir in the treatment of herpes zoster. *Semin Dermatol*. 1996;15:27-31.
307. Szeto SK, Chan TC, Wong RL, et al. Prevalence of ocular manifestations and visual outcomes in patients with herpes zoster ophthalmicus. *Cornea*. 2017;36:338-342.
308. Kaufman HE. Treatment of viral diseases of the cornea and external eye. *Prog Retin Eye Res*. 2000;19:69-85.
309. Charteris DG, Bonshek RE, Tullo AB. Ophthalmic molluscum contagiosum: Clinical and immunopathological features. *Br J Ophthalmol*. 1995;79:476-481.
310. Ohnsman CM. Exclusion of students with conjunctivitis from school: Policies of state departments of health. *J Pediatr Ophthalmol Strabismus*. 2007;44:101-105.
311. Isenberg SJ, Apt L, Valenton M, et al. A controlled trial of povidone-iodine to treat infectious conjunctivitis in children. *Am J Ophthalmol*. 2002;134:681-688.
312. Isenberg SJ, Apt L, Valenton M, et al. Prospective, randomized clinical trial of povidone-iodine 1.25% solution versus topical antibiotics for treatment of bacterial keratitis. *Am J Ophthalmol*. 2017;176:244-253.
313. Freidlin J, Acharya N, Lietman TM, et al. Spectrum of eye disease caused by methicillin-resistant *staphylococcus aureus*. *Am J Ophthalmol*. 2007;144:313-315.
314. Cavuoto K, Zutshi D, Karp CL, et al. Update on bacterial conjunctivitis in South Florida. *Ophthalmology*. 2008;115:51-56.
315. Klevens RM, Morrison MA, Nadle J, et al. Invasive methicillin-resistant *staphylococcus aureus* infections in the united states. *JAMA*. 2007;298:1763-1771.
316. Avdic E, Cosgrove SE. Management and control strategies for community-associated methicillin-resistant *staphylococcus aureus*. *Expert Opin Pharmacother*. 2008;9:1463-1479.
317. Marangon FB, Miller D, Muallem MS, et al. Ciprofloxacin and levofloxacin resistance among methicillin-sensitive *staphylococcus aureus* isolates from keratitis and conjunctivitis. *Am J Ophthalmol*. 2004;137:453-458.
318. Chen CJ, Starr CE. Epidemiology of gram-negative conjunctivitis in neonatal intensive care unit patients. *Am J Ophthalmol*. 2008;145:966-970.
319. American Academy of Ophthalmology Cornea/External Disease Panel. Preferred practice pattern® guidelines. Bacterial keratitis. San Francisco, CA: American Academy of Ophthalmology; 2023. www.aao.org/ppp.
320. Block SL. Etiologic and therapeutic pitfalls of newborn conjunctivitis. *Pediatr Ann*. 2012;41:310-313.
321. Jabs DA, Rosenbaum JT, Foster CS, et al. Guidelines for the use of immunosuppressive drugs in patients with ocular inflammatory disorders: Recommendations of an expert panel. *Am J Ophthalmol*. 2000;130:492-513.
322. Suhler EB, Smith JR, Wertheim MS, et al. A prospective trial of infliximab therapy for refractory uveitis: Preliminary safety and efficacy outcomes. *Arch Ophthalmol*. 2005;123:903-912.
323. Jayne DR, Lockwood CM. Pooled intravenous immunoglobulin in the management of systemic vasculitis. *Adv Exp Med Biol*. 1993;336:469-472.
324. Kraft J, Lieb W, Zeitler P, Schuster V. Ligneous conjunctivitis in a girl with severe type I plasminogen deficiency. *Graefes Arch Clin Exp Ophthalmol*. 2000;238:797-800.
325. Watts P, Suresh P, Mezer E, et al. Effective treatment of ligneous conjunctivitis with topical plasminogen. *Am J Ophthalmol*. 2002;133:451-455.
326. Kuonen A, Vaudaux J, Hamedani M, et al. Ligneous conjunctivitis in a young patient with homozygous K19E plasminogen gene mutation: A diagnostic and therapeutic challenge. *Klin Monbl Augenheilkd*. 2013;230:346-348.
327. Leonardi A, Castegnaro A, Valerio AL, Lazzarini D. Epidemiology of allergic conjunctivitis: Clinical appearance and treatment patterns in a population-based study. *Curr Opin Allergy Clin Immunol*. 2015;15:482-488.
328. Azari AA, Barney NP. Conjunctivitis: A systematic review of diagnosis and treatment. *JAMA*. 2013;310:1721-1729.
329. Vazirani J, Shukla S, Chhawchharia R, et al. Allergic conjunctivitis in children: Current understanding and future perspectives. *Curr Opin Allergy Clin Immunol*. 2020;20:507-515.
330. Petersen KD, Kronborg C, Gyrd-Hansen D, et al. Quality of life in rhinoconjunctivitis assessed with generic and disease-specific questionnaires. *Allergy*. 2008;63:284-291.
331. Virchow JC, Kay S, Demoly P, et al. Impact of ocular symptoms on quality of life (QoL), work productivity and resource utilisation in allergic rhinitis patients--an observational, cross sectional study in four countries in Europe. *J Med Econ*. 2011;14:305-314.

332. Palmares J, Delgado L, Cidade M, et al. Allergic conjunctivitis: A national cross-sectional study of clinical characteristics and quality of life. *Eur J Ophthalmol*. 2010;20:257-264.
333. Smith AF, Pitt AD, Rodriguez AE, et al. The economic and quality of life impact of seasonal allergic conjunctivitis in a Spanish setting. *Ophthalmic Epidemiol*. 2005;12:233-242.
334. Civelek E, Yavuz ST, Boz AB, et al. Epidemiology and burden of rhinitis and rhinoconjunctivitis in 9- to 11-year-old children. *Am J Rhinol Allergy*. 2010;24:364-370.
335. Blaiss MS. Allergic rhinoconjunctivitis: Burden of disease. *Allergy Asthma Proc*. 2007;28:393-397.
336. Bielory L, Skoner DP, Blaiss MS, et al. Ocular and nasal allergy symptom burden in America: The allergies, immunotherapy, and rhinoconjunctivitis (AIRS) surveys. *Allergy Asthma Proc*. 2014;35:211-218.
337. Uphoff E, Cabieses B, Pinart M, et al. A systematic review of socioeconomic position in relation to asthma and allergic diseases. *Eur Respir J*. 2015;46:364-374.
338. Chen YH, Lin CL, Bau DT, Hung YC. Risk of allergic conjunctivitis in patients with type 1 diabetes mellitus: A population-based retrospective cohort study. *BMJ Open*. 2017;7:e015795.
339. Bielory L, Syed BA. Pharmacoeconomics of anterior ocular inflammatory disease. *Curr Opin Allergy Clin Immunol*. 2013;13:537-542.
340. Khan RS, Rizvi S, Syed BA, Bielory L. Current market trends in anterior ocular inflammatory disease landscape. *Curr Opin Allergy Clin Immunol*. 2019;19:503-509.
341. Pitt AD, Smith AF, Lindsell L, et al. Economic and quality-of-life impact of seasonal allergic conjunctivitis in Oxfordshire. *Ophthalmic Epidemiol*. 2004;11:17-33.
342. De Smedt S, Nkurikiye J, Fonteyne Y, et al. Vernal keratoconjunctivitis in school children in Rwanda and its association with socio-economic status: A population-based survey. *Am J Trop Med Hyg*. 2011;85:711-717.
343. De Smedt SK, Nkurikiye J, Fonteyne YS, et al. Vernal keratoconjunctivitis in school children in Rwanda: Clinical presentation, impact on school attendance, and access to medical care. *Ophthalmology*. 2012;119:1766-1772.
344. Shekhawat NS, Shtein RM, Blachley TS, Stein JD. Antibiotic prescription fills for acute conjunctivitis among enrollees in a large United States managed care network. *Ophthalmology*. 2017;124:1099-1107.
345. Piednoir E, Bureau-Chalot F, Merle C, et al. Direct costs associated with a nosocomial outbreak of adenoviral conjunctivitis infection in a long-term care institution. *Am J Infect Control*. 2002;30:407-410.
346. Angueyra MF, Marccone DN, Escarra F, et al. Direct costs and clinical impact of adenovirus genotype 8 conjunctivitis outbreak in a neonatology unit. *Infect Control Hosp Epidemiol*. 2021;42:142-148.
347. Nanji AA, Moon CS, Galor A, et al. Surgical versus medical treatment of ocular surface squamous neoplasia: A comparison of recurrences and complications. *Ophthalmology*. 2014;121:994-1000.
348. Sturges A, Butt AL, Lai JE, Chodosh J. Topical interferon or surgical excision for the management of primary ocular surface squamous neoplasia. *Ophthalmology*. 2008;115:1297-1302, 1302 e1291.
349. Al Bayyat G, Arreaza-Kaufman D, Venkateswaran N, et al. Update on pharmacotherapy for ocular surface squamous neoplasia. *Eye Vis (Lond)*. 2019;6:24.
350. Saffra NA, Emborgo TS, Iacob CE, Kirsch DS. Cost-effective treatment of ocular surface squamous neoplasia for an undocumented and uninsured New York City patient: A case report. *J Med Case Rep*. 2020;14:174.
351. Feenstra RP, Tseng SC. Comparison of fluorescein and rose bengal staining. *Ophthalmology*. 1992;99:605-617.
352. Stroop WG, Chen TM, Chodosh J, et al. PCR assessment of HSV-1 corneal infection in animals treated with rose bengal and lissamine green b. *Invest Ophthalmol Vis Sci*. 2000;41:2096-2102.
353. Manning FJ, Wehrly SR, Foulks GN. Patient tolerance and ocular surface staining characteristics of lissamine green versus rose bengal. *Ophthalmology*. 1995;102:1953-1957.
354. Pflugfelder SC, Tseng SC, Yoshino K, et al. Correlation of goblet cell density and mucosal epithelial membrane mucin expression with rose bengal staining in patients with ocular irritation. *Ophthalmology*. 1997;104:223-235.
355. Farris RL, Gilbard JP, Stuchell RN, Mandel ID. Diagnostic tests in keratoconjunctivitis sicca. *CLAO J*. 1983;9:23-28.