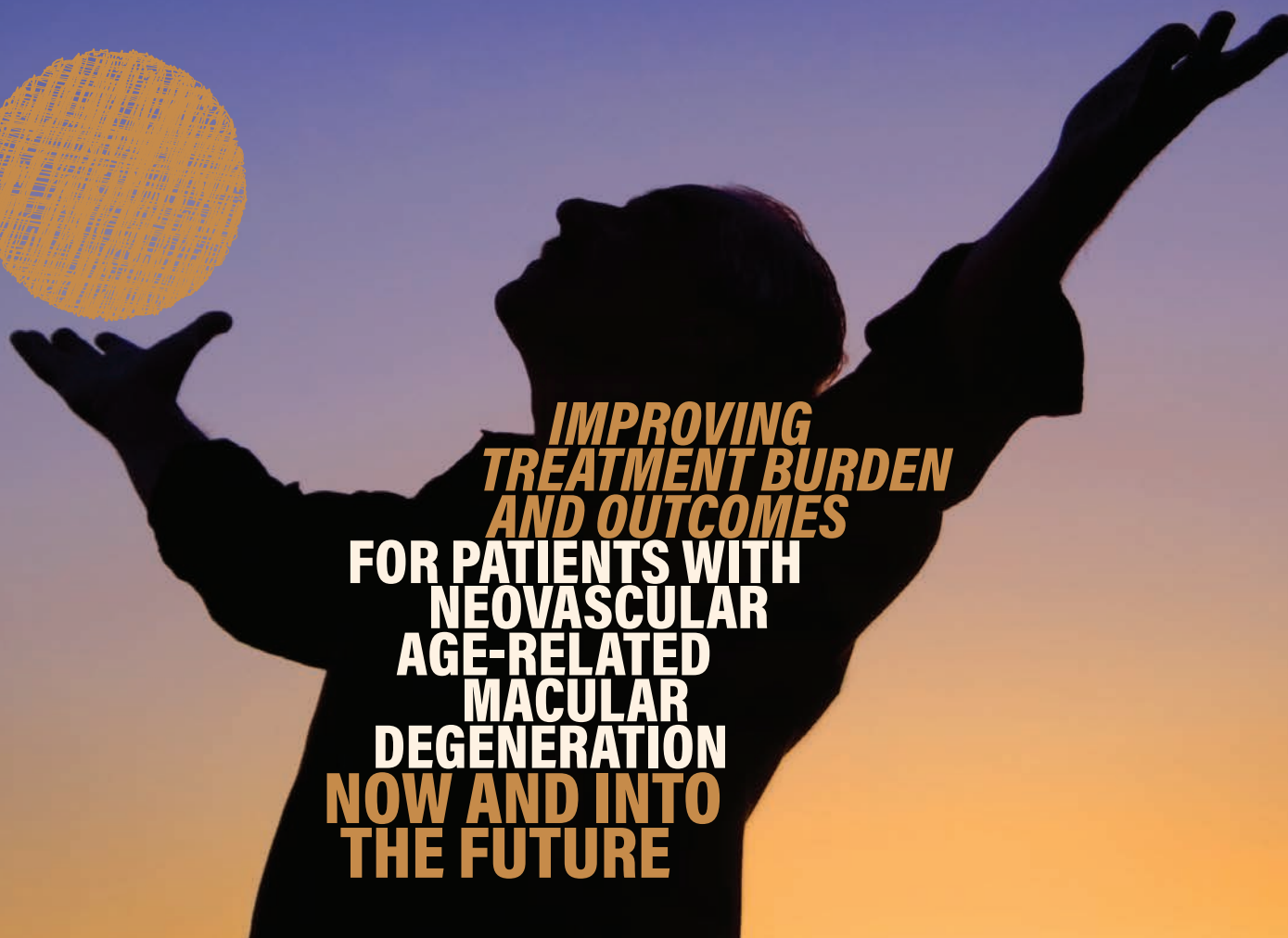


CME Monograph

VISIT [HTTPS://TINYURL.COM/NAMDCME](https://tinyurl.com/namdcme) FOR
ONLINE TESTING AND INSTANT CME CERTIFICATE.

EARN CREDITS
★ CME ★



**IMPROVING
TREATMENT BURDEN
AND OUTCOMES
FOR PATIENTS WITH
NEOVASCULAR
AGE-RELATED
MACULAR
DEGENERATION
NOW AND INTO
THE FUTURE**

FACULTY

NANCY M. HOLEKAMP, MD (CHAIR)
PRAVIN U. DUGEL, MD
BARUCH D. KUPPERMANN, MD, PhD
CARL D. REGILLO, MD



This continuing medical education activity is jointly provided by
New York Eye and Ear Infirmary of Mount Sinai and MedEdicus LLC.

Original Release: March 1, 2020
Expiration: March 31, 2021



This continuing medical education activity is supported through an
unrestricted educational grant from Novartis Pharmaceuticals Corporation.

Distributed with EyeNet

LEARNING METHOD AND MEDIUM

This educational activity consists of a supplement and ten (10) study questions. The participant should, in order, read the learning objectives contained at the beginning of this supplement, read the supplement, answer all questions in the post test, and complete the Activity Evaluation/Credit Request form. To receive credit for this activity, please follow the instructions provided on the post test and Activity Evaluation/Credit Request form. This educational activity should take a maximum of 1.5 hours to complete.

ACTIVITY DESCRIPTION

It is estimated that by 2030, 3.7 million people in the United States will have advanced age-related macular degeneration (AMD), including neovascular AMD (nAMD). The standard of care for nAMD is monthly anti-vascular endothelial growth factor (VEGF) injections, but a growing body of real-world studies indicates that patients do not receive the same number of injections or achieve comparable visual acuity outcomes as do subjects in hallmark clinical trials, likely because of the significant treatment burden associated with monthly injections. To address this unmet need, several clinical trials are ongoing to investigate new treatment strategies and agents for nAMD that reduce treatment burden. Earlier detection of nAMD is one strategy to reduce the functional burden of nAMD through preservation of visual acuity. For active disease, several novel approaches designed to increase treatment response and longevity are under investigation. These include a small molecular weight anti-VEGF, a bispecific VEGF/angiotensin 2-antagonizing antibody, a VEGF-antagonizing DARPIn (designed ankyrin repeat protein) molecule, and an implantable device that continuously releases an approved anti-VEGF therapy. Prior to US Food and Drug Administration approval of these innovative treatments, clinicians can harness the latest data on the consequences of persistent fluid to tailor retreatment strategies using approved anti-VEGF treatments, thereby reducing treatment burden while maximizing visual outcomes. The desired results of this educational activity are for retina specialists and other ophthalmologists to use evidence-based preventive, diagnostic, and treatment strategies for nAMD that minimize treatment burden while maximizing vision and quality-of-life outcomes for patients now and as new treatments emerge.

TARGET AUDIENCE

This educational activity is intended for retina specialists and other ophthalmologists who treat patients with nAMD.

LEARNING OBJECTIVES

Upon completion of this activity, participants will be better able to:

- Design strategies to identify nAMD as soon as possible after symptom onset
- Discuss the molecular basis for differentiating current and emerging treatments for nAMD
- Examine clinical trial data for approved and emerging treatments for nAMD
- Develop individualized disease activity assessment and retreatment plans for patients with nAMD

ACCREDITATION STATEMENT



This activity has been planned and implemented in accordance with the accreditation requirements and policies of the Accreditation Council for Continuing Medical Education (ACCME) through the joint providership of **New York Eye and Ear Infirmary of Mount Sinai** and **MedEdicus LLC**. The **New York Eye and Ear Infirmary of Mount Sinai** is accredited by the ACCME to provide continuing medical education for physicians.

AMA CREDIT DESIGNATION STATEMENT

The **New York Eye and Ear Infirmary of Mount Sinai** designates this enduring material for a maximum of 1.5 *AMA PRA Category 1 Credits™*. Physicians should claim only the credit commensurate with the extent of their participation in the activity.

GRANTOR STATEMENT

This continuing medical education activity is supported through an unrestricted educational grant from Novartis Pharmaceuticals Corporation.

DISCLOSURE POLICY STATEMENT

It is the policy of **New York Eye and Ear Infirmary of Mount Sinai** that the faculty and anyone in a position to control activity content disclose any real or apparent conflicts of interest relating to the topics of the educational activity in which they are participating. They are also required to disclose discussions of unlabeled/unapproved uses of drugs or devices during their presentations.

New York Eye and Ear Infirmary of Mount Sinai is committed to providing its learners with quality CME activities and related materials that promote improvements in healthcare and not the proprietary interests of a commercial interest and, thus, has established policies and procedures in place that identify and resolve all conflicts of interest prior to the execution or release of its educational activities. Full disclosure of faculty/planners and their commercial relationships, if any, follows.

DISCLOSURES

Pravin U. Dugel, MD, had a financial agreement or affiliation during the past year with the following commercial interests in the form of *Consultant/Advisory Board*: Abbott Medical Optics; Abfero Pharmaceuticals Inc; Acucela Inc; Aerie Pharmaceuticals, Inc; Aerie Therapeutics; Alcon; Alimera Sciences; Allergan; Amgen Inc; Annidis Corporation; Arctic Vision Ltd; ArcticDX Inc; AsclepIX; Avalanche Biotechnologies, Inc; Bausch & Lomb Incorporated; Beyoetics Surgical Inc; BioBridge Global; Boehringer Ingelheim International GmbH; CDR-Life Inc; Chengdu Kanghong Biotechnology Co Ltd; Clearside Biomedical, Inc; Daiichi Sankyo Company, Limited; EyePoint Pharmaceuticals; F. Hoffmann-La Roche Ltd; Gemini Therapeutics; Genentech, Inc; Glaukos Corporation; GrayBug, Inc; Ionis Pharmaceuticals, Inc; Irenix Medical, Inc; IVERIC bio; jCyte; Kodiak Sciences Inc; Lutronic; Lux Biosciences Inc; MacuSight, Inc; Merck & Co., Inc; Nan Fung Group;

NeoVista Inc; Neurotech Pharmaceuticals; Novartis Pharmaceuticals Corporation; Oculus; Omeros Corporation; Opthea; Optovue, Incorporated; Ora, Inc; Oxurion NV; PanOptica; Pieris; QLT Inc; Regeneron Pharmaceuticals, Inc; Regenxbio Inc; ReNeuron Group PLC; Retinagenix; Santen Inc; SciFluor Life Sciences, Inc; Shire; Spark Therapeutics, Inc; Stealth BioTherapeutics Inc; Topcon Medical Systems, Inc; TrueVision; and Zeiss; *Ownership Interest (Stock options, or other holdings, excluding diversified mutual funds)*: Aerie Therapeutics; Allegro Ophthalmics, LLC; Arctic Vision Ltd; ArcticDX Inc; Clearside Biomedical, Inc; GrayBug, Inc; Irenix Medical, Inc; IVERIC bio; Nan Fung Group; Oculus; PanOptica; SciFluor Life Sciences, Inc; and TrueVision.

Nancy M. Holekamp, MD, had a financial agreement or affiliation during the past year with the following commercial interests in the form of *Consultant/Advisory Board*: Allergan; Clearside Biomedical, Inc; Gemini Therapeutics; Genentech, Inc; Lineage Cell Therapeutics, Inc; Novartis Pharmaceuticals Corporation; Regeneron Pharmaceuticals, Inc; and Viewpoint Therapeutics; *Contracted Research*: Gemini Therapeutics; Genentech, Inc; Gyroscope; and Notal Vision, Inc; *Honoraria from promotional, advertising or non-CME services received directly from commercial interests or their Agents (eg, Speakers Bureaus)*: Allergan; Genentech, Inc; Novartis Pharmaceuticals Corporation; Regeneron Pharmaceuticals, Inc; and Spark Therapeutics, Inc; *Ownership Interest (Stock options, or other holdings, excluding diversified mutual funds)*: Katalyst Healthcares & Life Sciences.

Baruch D. Kuppermann, MD, PhD, had a financial agreement or affiliation during the past year with the following commercial interests in the form of *Consultant/Advisory Board*: Alcon; Alimera Sciences; Allegro Ophthalmics, LLC; Allergan; Apellis Pharmaceuticals; Cell Care Therapeutics; Eyedaptic Inc; Galimedix Therapeutics, Inc; Genentech, Inc; Glaukos Corporation; Interface Biologics, Inc; IVERIC bio; jCyte; Novartis Pharmaceuticals Corporation; Regeneron Pharmaceuticals, Inc; and Re-Vana Therapeutics; *Contracted Research*: Alcon; Alimera Sciences; Allegro Ophthalmics, LLC; Allergan; Apellis Pharmaceuticals; Genentech, Inc; Ionis Pharmaceuticals, Inc; jCyte; Novartis Pharmaceuticals Corporation; Oxurion NV; and Regeneron Pharmaceuticals, Inc; *Honoraria from promotional, advertising or non-CME services received directly from commercial interests or their Agents (eg, Speakers Bureaus)*: Allergan; and Optovue, Incorporated.

Carl D. Regillo, MD, had a financial agreement or affiliation during the past year with the following commercial interests in the form of *Consultant/Advisory Board*: Allegro Ophthalmics, LLC; Allergan; Genentech, Inc; Ionis Pharmaceuticals, Inc; Kodiak Sciences Inc; Novartis Pharmaceuticals Corporation; and Shire; *Contracted Research*: Allergan; Apellis Pharmaceuticals; Astellas Pharma US, Inc; Genentech, Inc; IVERIC bio; Kodiak Sciences Inc; Novartis Pharmaceuticals Corporation; and Regeneron Pharmaceuticals, Inc.

NEW YORK EYE AND EAR INFIRMARY OF MOUNT SINAI PEER REVIEW DISCLOSURE

Gennady Landa, MD, has no relevant commercial relationships to disclose.

EDITORIAL SUPPORT DISCLOSURES

Erika Langsfeld, PhD; Cynthia Tornallyay, RD, MBA, CHCP; Kimberly Corbin, CHCP; Barbara Aubel; and Michelle Ong have no relevant commercial relationships to disclose.

Tony Realini, MD, had a financial agreement or affiliation during the past year with the following commercial interests in the form of *Consultant/Advisory Board*: Aerie Pharmaceuticals, Inc; iSTAR; New World Medical, Inc; and Notal Vision.

DISCLOSURE ATTESTATION

The contributing physicians listed above have attested to the following:

- 1) that the relationships/affiliations noted will not bias or otherwise influence their involvement in this activity;
- 2) that practice recommendations given relevant to the companies with whom they have relationships/affiliations will be supported by the best available evidence or, absent evidence, will be consistent with generally accepted medical practice; and
- 3) that all reasonable clinical alternatives will be discussed when making practice recommendations.

OFF-LABEL DISCUSSION

This CME activity includes discussion of unlabeled and/or investigative uses of drugs. Please refer to the official prescribing information for each drug discussed in this activity for FDA-approved dosing, indications, and warnings.

New York Eye and Ear Infirmary of Mount Sinai Privacy & Confidentiality Policies
<https://www.nyee.edu/education/cme>

CME Provider Contact Information

For questions about this activity, call 212-870-8127.

TO OBTAIN AMA PRA CATEGORY 1 CREDIT™

To obtain *AMA PRA Category 1 Credit™* for this activity, read the material in its entirety and consult referenced sources as necessary. Please take this post test and evaluation online by going to <https://tinyurl.com/namdcme>. Upon passing, you will receive your certificate immediately. You must score 70% or higher to receive credit for this activity, and may take the test up to 2 times. Upon registering and successfully completing the post test, your certificate will be made available online and you can print it or file it.

DISCLAIMER

The views and opinions expressed in this educational activity are those of the faculty and do not necessarily represent the views of **New York Eye and Ear Infirmary of Mount Sinai, MedEdicus LLC**, Novartis Pharmaceuticals Corporation, *EyeNet*, or the American Academy of Ophthalmology.

FACULTY

NANCY M. HOLEKAMP, MD (CHAIR)

Professor of Clinical Ophthalmology
Washington University School of Medicine
Director, Retina Services
Pepose Vision Institute
St Louis, Missouri

PRAVIN U. DUGEL, MD

Managing Partner
Retinal Consultants of Arizona
Retinal Research Institute
Phoenix, Arizona
Clinical Professor
Roski Eye Institute
Keck School of Medicine
University of Southern California
Los Angeles, California

BARUCH D. KUPPERMANN, MD, PhD

Roger F. Steinert Endowed Professor
Chair, Department of Ophthalmology
Director, Gavin Herbert Eye Institute
University of California, Irvine
Irvine, California

CARL D. REGILLO, MD

Director, Retina Service
Wills Eye Hospital
Professor of Ophthalmology
Thomas Jefferson University
Philadelphia, Pennsylvania

CME REVIEWER FOR NEW YORK EYE AND EAR INFIRMARY OF MOUNT SINAI

GENNADY LANDA, MD

Associate Professor of Ophthalmology
Icahn School of Medicine at Mount Sinai
Director of Retina Service
Associate Director of Vitreoretinal Fellowship
Medical Director of Tribeca Office
Vitreoretinal Specialist and
Attending Surgeon
Department of Ophthalmology
New York Eye and Ear Infirmary of
Mount Sinai
New York, New York

This CME activity is copyrighted to
MedEdicus LLC 2020. All rights reserved. 199

IMPROVING TREATMENT BURDEN AND OUTCOMES FOR PATIENTS WITH NEOVASCULAR AGE-RELATED MACULAR DEGENERATION NOW AND INTO THE FUTURE

INTRODUCTION

Age-related macular degeneration (AMD) is the leading cause of blindness in people aged > 50 years,¹ accounting for 8.7% of all legal blindness worldwide.² One of the main causes of severe visual loss in AMD is the development of choroidal neovascularization (CNV) heralding progression to exudative or the neovascular form of AMD (nAMD). The development of AMD takes a significant toll on quality of life.³ Moderate AMD (visual acuity [VA] of 20/50 to 20/100) can cause a 32% decrease in the average patient's quality of life, similar to that associated with severe cardiac angina or a fractured hip. Severe AMD (VA of 20/200 or worse) can cause a 53% decrease in quality of life, more than that of dialysis, and very severe AMD (VA 20/800 or worse) can cause a 60% decrease in the quality of life of the average patient with AMD, similar to that experienced with end-stage prostate cancer or a severe stroke that leaves a person bedridden, incontinent, and requiring constant nursing care. Treatment with intravitreal injections of agents that inhibit vascular endothelial growth factor (VEGF) might improve VA by 3 lines or more in 30% to 40% of people with nAMD and might prevent deterioration of VA in more than 90% of patients.^{4,5} Despite the availability of effective therapy, real-world clinical outcomes are limited by late detection of disease and an onerous treatment burden that limits the provision of optimal care to many patients. In this educational activity, a panel of retina specialists will identify unmet needs in current nAMD practice patterns and review new and emerging treatment strategies to fulfill these needs.

UNMET NEEDS IN AGE-RELATED MACULAR DEGENERATION

Nancy M. Holekamp, MD

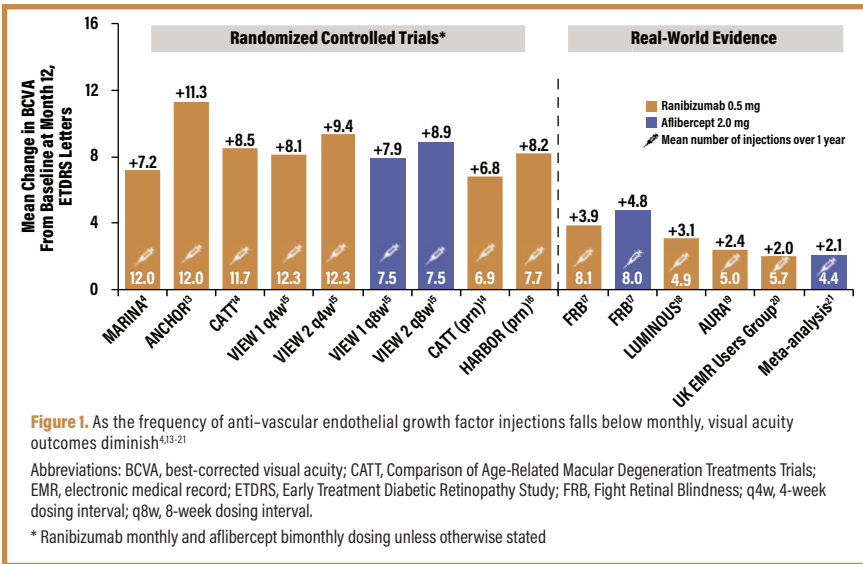
The advent of therapies to inhibit the actions of VEGF has transformed the management of nAMD and has given many patients stabilization and improvement of vision. Several unmet needs, however, remain to further challenge our ability to provide optimal care for patients with nAMD. These include better strategies for detecting nAMD before the decline of VA and improvements in our therapeutic approach to minimize the significant treatment burden associated with this disease.

Early Diagnosis

Early diagnosis of nAMD is essential for optimizing VA outcomes given that studies have demonstrated that VA at the time of diagnosis is the best predictor of treatment success and final VA.^{6,7} Studies also show, however, that diagnosis of most eyes with nAMD occurs once substantial VA has already been lost, and only 14% to 36% of eyes are diagnosed with nAMD when VA is 20/40 or better.⁷⁻¹⁰ In an analysis of real-world data from the American Academy of Ophthalmology IRIS® (Intelligent Research in Sight) Registry, the mean VA at the time of nAMD diagnosis among more than 162,000 eyes was 20/83.^{11,12} Although one might believe that the increased surveillance following first-eye diagnosis might lead to significantly earlier detection of second-eye involvement, the IRIS Registry analysis suggested otherwise, with mean VA in first- and second-diagnosed eyes of 20/85 and 20/79, respectively. Thus, the ability to diagnose nAMD earlier, while central VA is still preserved, is an unmet need that would significantly improve treatment outcomes.

Reduction of Treatment Burden

The phase 3 registry studies of the anti-VEGF agents ranibizumab and aflibercept evaluated monthly or bimonthly treatment regimens, whereas many subsequent studies—recognizing the tremendous burden monthly therapy requirements placed on patients and their families—have evaluated less frequent dosing intervals.^{4,13-21} Unfortunately, as can be seen in **Figure 1**, reducing the frequency of anti-VEGF injections also reduces the efficacy of therapy, with smaller mean gains in VA when less than monthly regimens are used.^{4,13-21} In the international AURA study, VA gains in the first year of therapy diminished significantly in the second year as the frequency of injections also declined.¹⁹ Thus, the ability to achieve the VA gains derived from monthly or



lesions (**Figures 2A and 2B**) feature flat vessel proliferation under the RPE, with localized fusiform serous or fibrovascular pigment epithelial detachments. Type 2 CNV lesions (**Figures 2C-2F**) have neovascular tissue proliferating above the RPE level, disrupting the inner-outer segment junction and creating cystic intraretinal spaces. Type 3 CNV lesions (**Figures 2G and 2H**) are characterized by retinal angiomatous proliferation lesions, with intraretinal neovascularization and cystic spaces.

OCT angiography (OCT-A) represents another key advance in the OCT technology platform. OCT-A uses amplitude or phase decorrelation technology to detect red blood cell movement and to visualize blood vessels at various levels of the retina and choroid. As opposed to fluorescein angiography (FA) or indocyanine green (ICG) angiography, OCT-A reveals the vessels themselves and enables more accurate identification and evaluation of the morphology of the neovascular complex (**Figure 3**).²⁸⁻³⁰

OCT-A allows even earlier detection of CNV development compared with conventional OCT devices.²⁸ In a recent study, CNV type 1 lesions were detected far more frequently by OCT-A than by FA: 95% of 22 eyes vs only 29% of 17 eyes, respectively.³¹ Fluorescein angiography remains useful in differentiating the CNV and non-CNV components of nAMD lesions and distinguishing between classic and occult lesion types. ICG angiography, which uses ICG dye rather than fluorescein to better visualize the choroidal circulation, is helpful in the diagnosis of polypoidal choroidal vasculopathy and retinal angiomatous proliferation lesions.

Fundus autofluorescence (FAF) is useful in the imaging of eyes with dry AMD, specifically those with geographic atrophy (GA) lesions. FAF is capable of visualizing the naturally or pathologically occurring fluorophores in the retina, mainly lipofuscin. Because of its ability to delineate GA with superior contrast to color fundus photography, FAF has been used extensively in non-nAMD studies. Specific qualitative patterns of hyperautofluorescence and hypoautofluorescence were suggested to correlate with the growth rates of GA.³²

Complementary to these office-based technologies for early detection of nAMD are several home-based tools. In patients with maculopathies, subjective symptoms often precede objective signs, so home monitoring between routine visits is essential for early diagnosis. The most common home-based tool is the Amsler grid, which evaluates the central 20° of a visual field.³³ Traditionally, this

every-8-week treatment with less frequent treatment is an unmet need that would greatly improve the lives of patients with nAMD, their caregivers, and their health care providers.

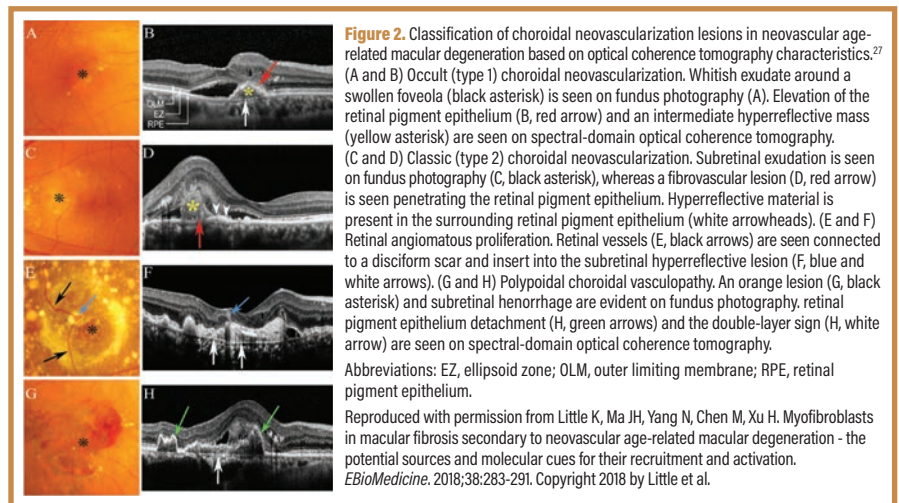
TECHNIQUES TO IDENTIFY EARLY AND PROGRESSING AGE-RELATED MACULAR DEGENERATION

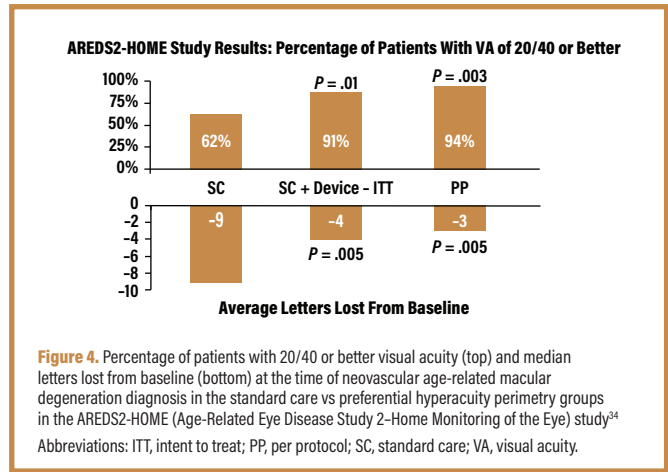
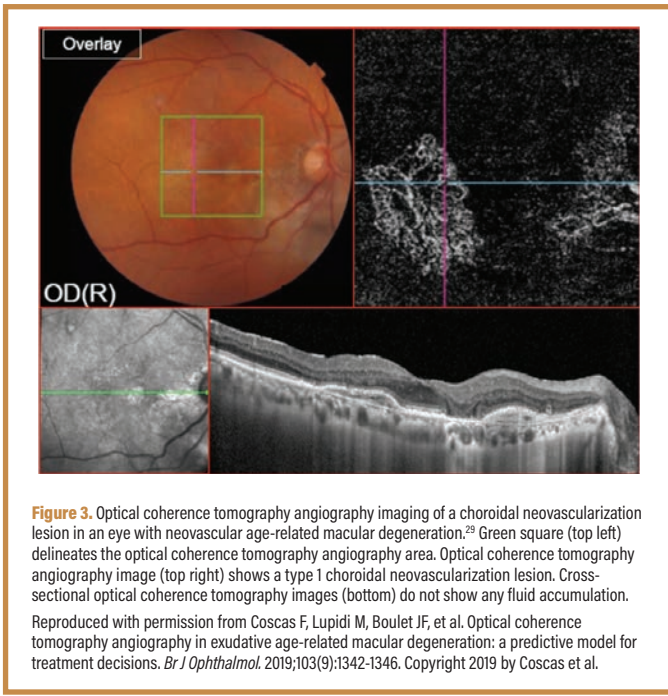
Baruch D. Kuppermann, MD, PhD

It cannot be stated too often that early detection is critical for optimizing VA outcomes in eyes with nAMD. In addition to the studies cited previously that demonstrated early VA diagnosis predicts treatment success,^{6,7} the original phase 3 registry trials of ranibizumab—MARINA and ANCHOR—demonstrated that the earlier or more immature a CNV lesion is, the better the expected final VA outcome.^{22,23} Further, VA improvement with anti-VEGF therapy is most likely if therapy is begun within 1 month of detecting visual symptoms.²⁴

What is the current approach to early detection of conversion from dry AMD to nAMD? In general, a combined approach includes symptom detection by patients—whether spontaneous or through regular at-home monitoring with the Amsler grid—and regular office examination and testing for at-risk eyes, such as those with intermediate AMD. Office testing most often consists of optical coherence tomography (OCT), an imaging modality that—as has anti-VEGF therapy—has transformed the evaluation and management of AMD.

A pooled analysis of the performance of OCT in detecting CNV in eyes with AMD demonstrated 85% sensitivity and 48% specificity.²⁵ This means that 85% of eyes with CNV will be detected by OCT; conversely, OCT will also be positive in approximately half of eyes without CNV. Given the consequences of missing CNV, the low specificity is a reasonable trade-off for the high sensitivity. New approaches to the analysis of OCT data signals seek to improve the technology's diagnostic accuracy. Biomarkers such as the area, volume, height, and reflectivity of drusen, the retinal pigment epithelium (RPE), and the RPE-drusen complex are under evaluation.²⁶ OCT findings are redefining the classification of nAMD lesions, as shown in **Figure 2**.²⁷ Type 1 CNV





has been a paper-based handout that patients can place on the refrigerator or bathroom mirror and use daily to assess for changes in metamorphopsia. Modern smartphones offer applications featuring the Amsler grid, making it even more accessible. However, variable sensitivity and the lack of quantifiable measures of visual field defects make the Amsler grid more suitable for monitoring progression than for lesions of new onset.

More recently, preferential hyperacuity perimetry (PHP) has emerged as a clinically useful tool for early nAMD detection. Hyperacuity (also termed vernier acuity) is defined as the ability to perceive a difference in the relative spatial localization of ≥ 2 visual stimuli. Elevation of the RPE and/or neurosensory retina—both possible occurrences in advanced AMD—causes a shift in the regular position of photoreceptors. It is hypothesized that such a shift causes an object to be perceived at a location different from its true location in space. This perceived shift is recorded by PHP. A PHP-based home device is available and has been evaluated in a randomized clinical trial (AREDS2-HOME [Age-Related Eye Disease Study 2-Home Monitoring of the Eye]) in patients with large drusen, no nAMD lesions, and VA of 20/60 or better.³⁴ More than 1500 patients participated and were assigned to monitoring for conversion to nAMD with standard care (Amsler, routine in-office testing) or the PHP device used daily at home. After a mean follow-up of 1.4 years, significantly more lesions (51 vs 31) were detected by the PHP device than by standard care, a finding so impactful that the study's Data and Safety Monitoring Committee halted the study early. PHP detected conversion to nAMD earlier than did standard care, with VA at the time of diagnosis being 5.6 letters better in the PHP group than in the standard care group ($P = .005$) and 94% of 35 eyes (vs only 62% of 30 eyes) having VA of 20/40 or better at diagnosis ($P = .003$) (Figure 4).³⁴ This is substantially better than the 14% to 36% of eyes with VA of 20/40 or better at the time of nAMD diagnosis reported in prior studies.⁷⁻¹⁰ Furthermore, CNV lesions detected by PHP were smaller than those detected by standard care (median lesion size: 0.23 vs 0.7 disc areas, respectively), a difference that trended toward significance ($P = .051$).³⁵ Other home-monitoring tools, such as a smartphone application that monitors VA and Amsler changes, and another based on shape-discrimination hyperacuity, are available as well, although they have not been rigorously studied in published trials.³³

Because AMD—and specifically the risk of nAMD—has a genetic component, first-degree relatives of patients with AMD are also at risk of AMD-related vision loss.³⁶ Some genes convey a risk of AMD, but not necessarily progression to nAMD, whereas other genes, specifically *CFH* and *ARMS2*, have been significantly associated with AMD progression.³⁷ Early AMD diagnosis of at-risk patients would facilitate early diagnosis of sight-threatening nAMD lesions, but the role of genetic testing in the adult children of patients with AMD remains an unresolved issue. Currently, the best approach is regular, routine eye examinations to screen for AMD as well as other eye conditions associated with aging, such as glaucoma and cataract.³⁸

THE MOST PROMISING DRUGS IN RETINA 2020

Pravin U. Dugel, MD

The anti-VEGF-A agents bevacizumab, ranibizumab, and aflibercept have transformed the management of AMD and other retinal vascular diseases since their emergence into ophthalmology approximately 15 years ago. We are now on the cusp of a new wave of innovation that might further expand our treatment options, improve outcomes, and reduce treatment burden for our patients with nAMD.

Brolucizumab—a new anti-VEGF-A inhibitor that is a single-chain antibody fragment—was approved by the US Food and Drug Administration in October 2019 for the treatment of nAMD.³⁹ Notably, the drug was approved for dosing as infrequently as every 8 to 12 weeks after 3 monthly loading doses.⁴⁰ Brolucizumab was evaluated in 2 phase 3 clinical trials: HAWK and HARRIER.⁴¹ Collectively, these studies enrolled more than 1800 patients with treatment-naïve nAMD who were randomized to receive brolucizumab 3 mg (HAWK only) or 6 mg (both HAWK and HARRIER) monthly for 3 months and then every 8 weeks if disease activity was present, or 12 weeks if not; or aflibercept 2 mg every 8 weeks after 3 monthly loading doses. The primary outcome was the change in best-corrected VA (BCVA) from baseline to week 48; a noninferiority analysis was planned. The investigators reported that in both HAWK and HARRIER, mean BCVA changes from baseline with the 2 drugs were similar (and statistically noninferior), despite most patients in the brolucizumab arms being treated every 12 weeks as opposed to every 8 weeks in the aflibercept arm. There was no meaningful difference between the 2 brolucizumab doses (Figure 5).⁴¹ At week 16, significantly reduced central subfield thickness (CST) was observed with brolucizumab 6 mg vs aflibercept in both studies ($P < .001$). At week 48, significantly reduced CST was observed for both brolucizumab dosing groups ($P < .001$). In both studies, fewer patients on brolucizumab 6 mg ($n = 360$ in HAWK and $n = 370$ in HARRIER) had intraretinal and/or subretinal fluid at weeks 16 (35%-36% fewer) and 48 (31%-41% fewer) compared with aflibercept.

Adverse events were similar among the groups.⁴¹ Common adverse events were injection-related events, such as conjunctival hemorrhage and eye pain; disease-related events, such as reduced VA; and drug-related events, such as vitreous floaters. Extended follow-up through 96 weeks confirmed the early results, with noninferior VA improvements and superior CST reductions with brolicuzumab 6 mg maintained through 2 years of follow-up.⁴² The superior drying effect and durability of brolicuzumab over aflibercept might be related to its small molecular weight and high molar equivalent dose; at a dose of 6 mg, its equivalent molar dose is approximately 12 times greater than that of aflibercept and approximately 20 times greater than that of bevacizumab and ranibizumab (Figure 6).⁴³⁻⁴⁷

Several other promising drugs are in late-stage clinical development. Conbercept is a novel recombinant fusion protein that inhibits VEGF. In a randomized phase 3 trial of conbercept 0.5 mg (n = 81) vs sham injections (n = 43), eyes treated with 3 monthly loading doses of conbercept gained an average of 9.2 letters vs 2.0 letters in the sham group ($P < .001$) by month 3.⁴⁸ Thereafter, both groups received quarterly injections of conbercept 0.5 mg. The visual gains at 3 months were maintained through 12 months in the conbercept initial group (mean, 10.0 letters), and the sham initial group derived comparable benefit after crossover to conbercept (8.8 letters at month 12; $P = .64$). The most common ocular adverse events were associated with intravitreal injections, such as conjunctival hemorrhage and increased intraocular pressure. Unfortunately, no head-to-head comparisons with other anti-VEGF agents were incorporated into this study,⁴⁸ although a phase 3 comparison with aflibercept is under way (PANDA trials).^{49,50}

Abicipar pegol (abicipar) is another next-generation anti-VEGF agent in development. This molecule is a DARPin (designed ankyrin repeat protein), which is a recombinant protein derived from natural ankyrin proteins and consists of multiple repeat motifs that provide both molecular stability and a large target interaction surface.⁵¹ Abicipar has a smaller molecular weight,⁵² higher target binding affinity,⁵³ and longer ocular half-life than ranibizumab.⁵³ The half-life of abicipar is approximately 2 weeks in human eyes with diabetic macular edema.⁵³ Together, these attributes might account for abicipar's extended durability for the treatment of nAMD vs traditional anti-VEGF therapies. In a randomized phase 2 study (REACH), 64 patients with nAMD received either 3 monthly doses of abicipar 1 or 2 mg or 5 monthly injections of ranibizumab 0.5 mg.⁵² At week 20–4 weeks after the last dose of ranibizumab and 12 weeks after the last dose of abicipar—mean VA gains were 8.2, 10.0, and 5.3 letters in the abicipar 1 mg, abicipar 2 mg, and ranibizumab arms, respectively. Two-year data from a pair of phase 3 studies—CEDAR and SEQUOIA—have been reported but not yet published.⁵⁴ In these studies, patients received either abicipar 2 mg every 8 or 12 weeks or ranibizumab every 4 weeks for 104 weeks. The primary outcome—stable vision at 52 weeks—was achieved in > 90% of study participants and was comparable among the groups (Table). Mean VA gains at 2 years were 7.8 letters in the 8-week abicipar group, 6.1 letters in the 12-week abicipar group, and 8.5 letters in the ranibizumab group. These differences were not significant. It should be noted, however, that

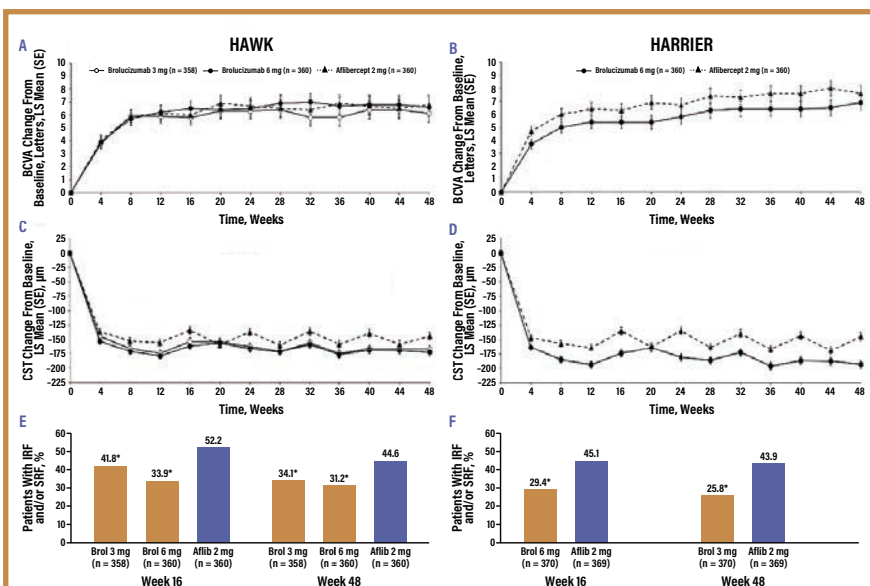


Figure 5. Outcomes at 48 weeks in the phase 3 HAWK and HARRIER trials of brolicuzumab vs aflibercept.⁴¹ Visual acuity (A and B) and central subfield thickness (C and D) over time in the HAWK and HARRIER studies, respectively. (E and F) Percentage of patients with subretinal and/or intraretinal fluid at weeks 16 and 48 of study.

Abbreviations: Aflib, aflibercept; BCVA, best-corrected visual acuity; Broli, brolicuzumab; CST, central subfield thickness; IRF, intraretinal fluid; LS, least squares; SE, standard error; SRF, subretinal fluid.

* 1-sided P values vs aflibercept < .005

Reproduced with permission from Dugel PU, Koh A, Ogura Y, et al; HAWK and HARRIER Study Investigators. HAWK and HARRIER: phase 3, multicenter, randomized, double-masked trials of brolicuzumab for neovascular age-related macular degeneration. *Ophthalmology*. 2020;127(1):72-84. Copyright 2019 by the American Academy of Ophthalmology.

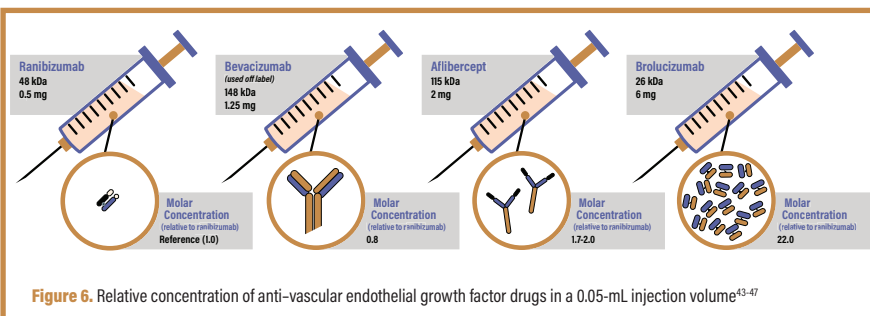


Figure 6. Relative concentration of anti-vascular endothelial growth factor drugs in a 0.05-mL injection volume.⁴³⁻⁴⁷

Table. Primary Outcome Data in the CEDAR and SEQUOIA Trials⁵⁴

Trial	Treatment	n	Patients With Stable Vision* at Week 52, %
CEDAR	Abicipar 2 mg every 8 weeks	265	91.7
	Abicipar 2 mg every 12 weeks	262	91.2
	Ranibizumab 0.5 mg every 4 weeks	290	95.5
SEQUOIA	Abicipar 2 mg every 8 weeks	267	94.8
	Ranibizumab 0.5 mg every 4 weeks	299	96.0

* Stable vision defined as a loss of < 15 Early Treatment Diabetic Retinopathy Study letters compared with baseline

the similar outcomes in the abicipar 12-week group and the ranibizumab 4-week group were accomplished with 10 vs 25 injections, respectively, over 2 years. Central retinal thickness was comparable between the abicipar and ranibizumab arms through 104 weeks.⁵⁵

Ocular adverse events were similar between groups, with the exception of intraocular inflammation, which was observed in approximately 15% of abicipar-treated eyes in both studies.⁵⁴ The manufacturing process of abicipar was subsequently modified and tested in the open-label MAPLE trial (n = 123)⁵⁶; ocular inflammation

was then observed in 8.9% of abicipar-treated patients, a decrease of approximately 40% from prior studies.

In an effort to further extend the interval between retreatments, a port delivery system (PDS) for ranibizumab is under development. This implant, placed transsclerally for subconjunctival access and intravitreal delivery, is a refillable, passive, diffusion-controlled sustained delivery system that can be refilled in minimally invasive fashion in an office-based procedure. In a phase 2 randomized trial (LADDER), 220 patients with nAMD received the device loaded with 1 of 3 doses of ranibizumab (10, 40, or 100 mg/mL) or monthly injections of ranibizumab 0.5 mg.⁵⁷ The median time to first refill of the implant (indicated when BCVA decreased or when OCT central field thickness [CFT] increased by prespecified amounts) was 8.7, 13.0, and 15.0 months in the 10-, 40-, and 100-mg/mL arms, respectively. At month 9 (the primary efficacy end point time point), mean VA gain in the 100-mg/mL group (+5.0 letters) was comparable to that achieved with 9 monthly injections of ranibizumab (+3.9 letters). At 9 and 18 months, CFT was comparable across the groups.^{57,58} After optimization of the surgical implant procedure, the vitreous hemorrhage rate was 4.5% in 157 PDS-treated patients, with no evidence of device obstruction/blockage. Cataracts (7.3%) and conjunctival blebs (3.35%) developed in some of the 179 PDS-treated patients. A phase 3 trial comparing the port delivery system to ranibizumab injections (Archway) is ongoing.⁵⁹

Faricimab, a bispecific monoclonal antibody designed to inhibit both VEGF and angiopoietin-2, is also in development. Angiopoietin-1 constitutively activates Tie2 in health, maintaining vascular integrity and averting inflammation. In disease, angiopoietin-2 is upregulated and is a weak agonist (effectively an antagonist) of Tie2 activation. Faricimab has 2 Fab arms that simultaneously inhibit VEGF-A and angiopoietin-2. Modifications to the Fc region suppress effector function to reduce the potential for inflammation and to facilitate systemic clearance for improved safety.⁶⁰ In the phase 2 AVENUE and STAIRWAY trials, noninferiority of faricimab dosed every 4 or 8 weeks in AVENUE and every 12 or 16 weeks in STAIRWAY to monthly ranibizumab was demonstrated for VA and central retinal thickness.^{61,62} There were no statistically significant differences between groups for BCVA and comparable reductions in CFT. The safety of faricimab was comparable to that of ranibizumab.⁶³ Two phase 3 studies (TENAYA and LUCERNE) are currently ongoing.^{64,65}

In summary, newly available and investigational agents as well as novel delivery systems for existing agents offer the possibility of outcomes at least as good as those seen with currently available anti-VEGF-A therapies and substantial reductions in treatment burden. As more of these treatment options complete clinical development and are available for clinical use, patients and their caregivers will benefit from less intensive therapy.

OPTIMIZING INDIVIDUALIZED DOSING STRATEGIES FOR NEOVASCULAR AGE-RELATED MACULAR DEGENERATION

Carl D. Regillo, MD

The goal of nAMD therapy is to achieve and maintain the best possible VA. We know from clinical trials that monthly or every-other-monthly injections of anti-VEGF agents can preserve initial VA gains well through 2 years. A review of major published phase 3 anti-VEGF trials compellingly demonstrates that injection frequency correlates with 12-month VA outcomes.⁶⁶ We extrapolate that continued therapy beyond 2 years should maintain these gains indefinitely, unless macular atrophy intervenes. However, in routine clinical practice, very few patients receive monthly or every-other-monthly injections over the long term, largely because of the excessive treatment burden imposed by doing so. For some patients, this can result in loss of initial visual gains, as was seen in the later years of CATT (Comparison of Age-Related Macular Degeneration Treatments Trials), when injection rates dropped to

4 to 5 per year.⁶⁷ For others, such frequent injections are not required to maintain their improved VA. Although the nature of clinical trials requires some degree of treatment standardization, the ultimate goal of patient-centered medical practice is to individualize therapy to the specific needs of each patient, avoiding both undertreatment and overtreatment over time.

Strategies for increasing the between-injection interval have included as-needed and treat-and-extend (TAE) approaches. The as-needed approach was statistically not noninferior to monthly injections in CATT because it is a reactive approach that requires clinical worsening with recurrence of exudation before retreatment.⁶⁸ This might be akin to a rescue strategy, allowing the macula to become reimpaird before each successive retreatment, and there might be permanent damage to the macular tissues from this constant cycle of exudative reactivation and rescue.⁴² The TAE approach, on the other hand, seeks to identify the optimal between-injection interval needed to maintain macular health and optimal outcomes for individual patients. Following monthly loading doses to achieve optimal VA and to minimize exudative features, the treatment interval is gradually increased—typically in 2-week increments—until clinical worsening (as determined by VA or OCT) is observed, after which the preceding interval (the longest associated without disease activity) becomes the standard interval for the given patient. Because treatment requirements can diminish with time, it is reasonable to rechallenge with extension after 6 to 12 months of stability at the current interval to better individualize and fine-tune the treatment plan. This strategy minimizes recurrences, setbacks, overtreatment, and overall burden and maximizes safety, all while being cost effective and minimizing drug use, office visits, and testing.⁶⁹

A large retrospective analysis of long-term TAE therapy for nAMD with bevacizumab or ranibizumab from the Wills Eye Hospital demonstrated that VA outcomes were comparable to those reported in phase 3 trials, but with far fewer injections over a 3-year period.⁷⁰ A prospective study (ATLAS [Aflibercept Treat and Extend for Less Frequent Administration Study]) of TAE therapy with aflibercept in 40 treatment-naïve patients with nAMD showed similar results, with 75% of 31 patients requiring treatments no more often than every 8 weeks and 38% requiring treatments no more often than every 12 weeks.⁷¹

A prospective, randomized trial (TREN-AMD) compared a TAE strategy (no less frequently than every 12 weeks) with monthly ranibizumab 0.5 mg in 60 treatment-naïve eyes with nAMD.⁷² Monthly loading doses (a minimum of 3) were given until the macula was dry, after which TAE was initiated. After 2 years, mean VA gains were similar in the monthly and TAE groups (10.5 vs 8.7 letters, respectively; $P = .64$), with significantly fewer injections in the TAE group (mean 18.6 vs 25.5, $P < .001$) (Figure 7).⁷² The mean maximum extension duration was 8.5 weeks, with 14 patients (47%) tolerating extensions in excess of 8 weeks and 11 patients (37%) tolerating extensions to 11 or 12 weeks between injections. Among eyes that achieved a dry macula and then demonstrated fluid upon extension, the interval at which the fluid recurred was generally the maximum interval tolerated subsequently (only 27% of 26 eyes receiving TAE ultimately tolerated a longer extension than the interval at which fluid first recurred), suggesting that rechallenge might not successfully increase the interval in most patients. Similar larger controlled studies (TREND [Treat and Extend]⁷³ and CANTREAT [Canadian Treat-and-Extend Analysis Trial With Ranibizumab]⁷⁴) have confirmed these findings, with 62% of 323 eyes and 69% of 287 eyes, respectively, tolerating ranibizumab extension intervals of ≥ 8 weeks.

These 4 prospective studies validate the TAE approach, demonstrating that intervals of ≥ 8 weeks are viable for approximately one-half to two-thirds of patients using our current anti-VEGF agents once initial macular drying is achieved.⁷¹⁻⁷⁴ Emerging drugs in the clinical pipeline discussed previously might have longer durations of action, permitting even greater extensions between retreatments.

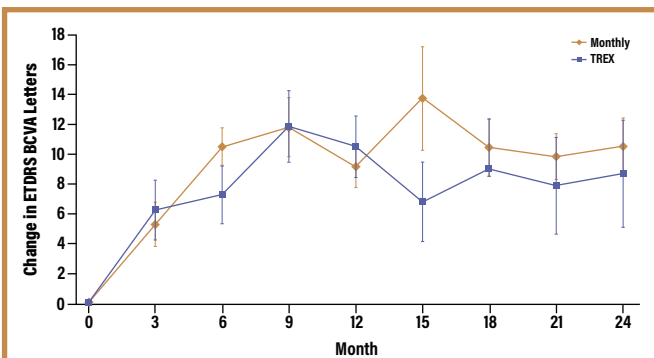


Figure 7. Two-year visual acuity outcomes of the TRES-AMD trial comparison of monthly vs treat-and-extend ranibizumab therapy.⁷² Abbreviations: AMD, age-related macular degeneration; BCVA, best-corrected visual acuity; ETDRS, Early Treatment Diabetic Retinopathy Study; TRES, treat-and-extend. Reproduced with permission from Wykoff CC, Croft DE, Brown DM, et al; TRES-AMD Study Group. Prospective trial of treat-and-extend versus monthly dosing for neovascular age-related macular degeneration: TRES-AMD 1-year results. *Ophthalmology*. 2015;122(12):2514-2522. Copyright 2015 by the American Academy of Ophthalmology.

Ultimately, however, visual gains might be limited by persistent fluid and progressive macular atrophy over time in some eyes. In the long-term CATT study, 83% of 555 eyes had persistent fluid at 5 years, albeit with a relatively low (4-5/year) injection frequency in later years.⁶⁷ Unfortunately, in the real world, injections at relatively low rates of 4 or so per year are common.^{18,66,75,76} As we are learning, the specific location of the persistent macular fluid matters because it could have implications for individualizing treatment. In a 5-year analysis of data from CATT, intraretinal fluid had a much greater negative effect on VA outcomes than subretinal or sub-RPE fluid, particularly when involving the fovea.⁷⁷ Also, variability of retinal fluid over time—as the macula dries out and becomes edematous again—was also a predictor of VA in the HAWK and HARRIER brolocizumab trials, suggesting, as discussed previously, that a cycle of macular reinjury and rescue provides suboptimal results compared with maintaining macular dryness over time.⁴² This is in contrast to a recent analysis of HARBOR trial data showing that persistent subretinal fluid was associated with better BCVA outcomes than complete fluid resolution, a counterintuitive finding that will require further investigation to understand more fully.⁷⁸ When confronted with persistent exudation in eyes with nAMD, our options are to intensify current treatment (higher retreatment frequency), switch to an alternate agent, extend and observe to see if the fluid worsens or remains stable, or consider additional imaging, such as FA or ICG angiography to rule out polypoidal choroidal vasculopathy (which might respond well to the addition of photodynamic therapy) or OCT-A to confirm that CNV is the cause of the edema.

The following section presents a series of cases meant to represent common patient scenarios encountered in the ophthalmology practice. Each case includes a discussion by faculty to identify and underscore the integration of emerging data and treatments into clinical practice.

CASE 1: EARLY DIAGNOSIS OF NEOVASCULAR AGE-RELATED MACULAR DEGENERATION BY HOME TESTING

From the Files of Nancy M. Holekamp, MD (Courtesy of Nadia Waheed, MD)

An 84-year-old woman was under care for bilateral dry AMD with pigment alterations of the RPE. Her VA was 20/20 OU. She was prescribed home PHP testing. Six months later, her left eye developed a small change in the metamorphopsia map that triggered an alert leading to an in-office evaluation, during which OCT revealed a new CNV lesion (**Figure 8**). She was asymptomatic, with a VA of 20/20.

She commenced anti-VEGF therapy with 3 monthly loading doses, was quickly extended to 12 weeks, but developed persistent fluid. She was adjusted to an 8-week interval. Despite some persistent subretinal fluid, she maintained a VA of 20/30 through 18 months.

Dr Holekamp: The PHP is a great device for our patients to use at home, but it is not easy for some patients. It requires a baseline VA of 20/60 or better to perform. For the right patients, it is very effective at picking up early disease that is otherwise asymptomatic and sometimes is not even detected on an Amsler grid.

Dr Kuppermann: The technology is conceptually appealing. We are trying to find technologies that are equivalent but easier to use.

Dr Holekamp: The same company that developed the PHP is also working on a home OCT device for self-testing.^{79,80} Imagine our patients obtaining their own OCT every morning and calling us when there is a problem. One of the first things they have to do is validate the artificial intelligence algorithm that is going to analyze the OCT and detect whether or not a signal should be sent to the clinician to come in for a visit.

Dr Regillo: This case is a good example of how well patients can do visually with early detection of CNV. The PHP device has been shown in a clinical trial to detect CNV earlier, when the VA is still relatively good, compared with conventional Amsler grid use. The case also demonstrates that small amounts of stable subretinal fluid can be relatively well tolerated by some patients.

CASE 2: NEW-ONSET NEOVASCULAR AGE-RELATED MACULAR DEGENERATION WITH GOOD RESPONSE TO THERAPY

From the Files of Carl D. Regillo, MD

A 77-year-old woman presented with metamorphopsia in the left eye of 3 weeks' duration. On examination, supplemented with both FA and OCT, she had nAMD with a CNV and subretinal fluid (**Figure 9**). Her VA at presentation was 20/60. She received 2 monthly doses of aflibercept 2 mg, resulting in a dry macula, and VA improved to 20/30.

Dr Regillo: Given that the macula is dry after 2 loading doses, should we give the third monthly loading dose in 4 weeks or begin extending now?

Dr Holekamp: I typically give all 3 monthly loading doses before extending.

Dr Regillo: I will consider extending before the third dose if the response is robust, as in this case. I elected against the third monthly loading dose and extended to 6 weeks, at which time the macula remained dry and the VA was preserved at 20/30. However, upon extending to 8 weeks, the fluid recurred and the VA dropped to 20/50. I re-treated and reverted to a 6-week interval, at which time the macula was once again dry and VA was 20/30. Would you have maintained the 8-week interval and tolerated the small amount of fluid seen at that visit?

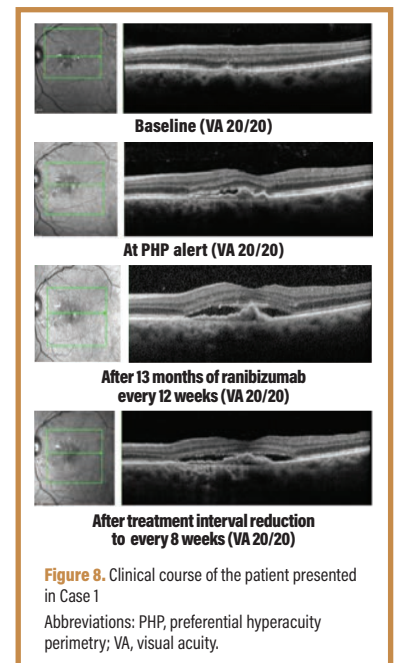


Figure 8. Clinical course of the patient presented in Case 1. Abbreviations: PHP, preferential hyperacuity perimetry; VA, visual acuity.

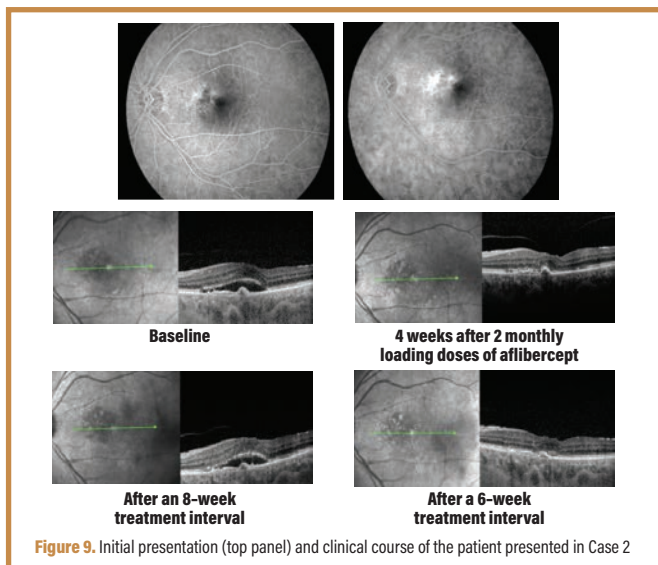


Figure 9. Initial presentation (top panel) and clinical course of the patient presented in Case 2

Dr Holekamp: In this case, the VA decline, rather than the recurrent fluid, is of concern. I would have done as you did.

Dr Dugel: I do not tolerate fluid and treat aggressively when fluid is present. I know that some eyes tolerate a small amount of fluid well over long periods, but I prefer to eliminate all fluid whenever I can and restore the macula to its normal physiologic state.

Dr Regillo: Would you keep this patient fixed at 6 weeks going forward or would you try to re-extend?

Dr Dugel: As Dr Holekamp pointed out, the decline in VA with the 8-week interval indicates that this patient is optimally seen at 6 weeks. I would be very reluctant to extend this patient further when she is doing this well.

Dr Regillo: Would you re-challenge the patient at some point?

Dr Kuppermann: I would do exactly what has been done. I do not necessarily do 3 injections. Once the lesion shows no fluid on OCT images, I start extending, but I do challenge the patient after approximately 6 to 12 months to confirm that ongoing injections are warranted.

Dr Regillo: That is what I do as well. After approximately 6 months to a year, if the patient is doing well, I will often rechallenge by extending the visit interval. I am mindful, however, that I might trigger a recurrence, and ultimately our goal as clinicians is to minimize recurrences because a recurrence can represent a setback, and setbacks are not always completely recoverable.

CASE 3: TREAT-AND-EXTEND IN THE PRESENCE OF PERSISTENT FLUID

From the Files of Carl D. Regillo, MD

Two patients presented. Both received anti-VEGF therapy for 6 to 12 months. Neither patient ever achieved an entirely dry macula. The first patient (**Figures 10A and 10B**) stabilized and was extended from 4 to 6 weeks, but then had recurrence of fluid, so the interval was reduced back to 4 weeks without much improvement. The second patient (**Figures 10C and 10D**) had a small amount of persistent fluid despite ongoing treatments every 4 weeks. Because VA and OCT images were stable, treatment was extended to 6 weeks, and subretinal fluid and VA slightly worsened.

Dr Regillo: What is the appropriate next step for each of these patients with recurrent fluid?

Dr Holekamp: Both cases deserve to stay at 4 weeks because there is some subretinal fluid even at 4 weeks. We would like to eliminate all fluid in every eye, but this is not always possible. We have to

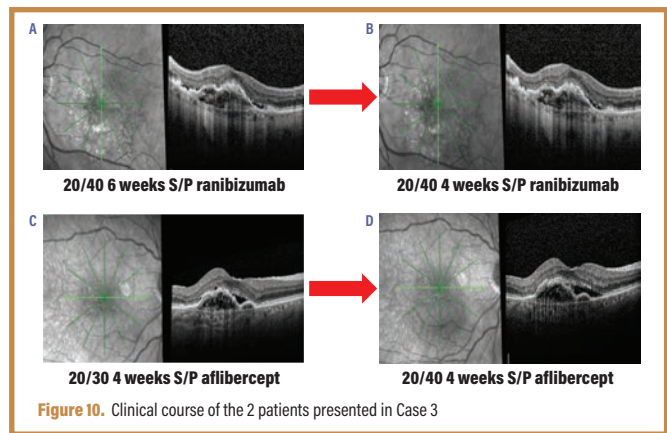


Figure 10. Clinical course of the 2 patients presented in Case 3

balance the costs of doing so against the patient's clinical course. Sometimes you cannot eliminate all the fluid, even with monthly injections, and a small amount of fluid might be well tolerated so long as therapy continues. While fluid is never good, a little bit is not always bad if it is well tolerated and if the cost of eliminating it is high. If the fluid and VA are stable, I would continue every 4 weeks. If it worsens, I would consider either a shorter interval or perhaps a different drug. In the future, this might be a patient in whom I would try a more potent medication or perhaps a sustained drug delivery system to provide continuous therapy rather than intermittent, pulsatile therapy as we do now.

Dr Regillo: Brolucizumab has just been approved.³⁹ In clinical trials, brolucizumab dried the macula more effectively than did aflibercept,⁴¹ and aflibercept dried the macula perhaps more effectively than did ranibizumab, although not significantly so.¹⁵ Is this a patient in whom you would consider treating with brolucizumab?

Dr Kuppermann: At this point, if we are 6 to 12 months into therapy with persistent fluid, I would consider switching. There is not much evidence that switching helps, but early clinical data with brolucizumab suggest that it might have a greater drying effect and greater durability.⁴¹ Of course, we have to be aware that our initial clinical experience with this new drug will potentially suffer from selection bias because we are likely to switch our treatment-resistant cases initially.

Dr Regillo: This will be similar to our integration of aflibercept into clinical practice. We commonly switched the eyes that were suboptimal responders to ranibizumab or bevacizumab.

Dr Holekamp: I am intrigued by the relationship between OCT variability and visual outcomes seen in the brolucizumab HAWK and HARRIER trials.⁴² Is this a drug or a disease effect?

Dr Dugel: This is a disease control effect that is, in these 2 important analyses, agnostic of the drug used and based only on the effect of reducing OCT fluctuations.⁴² A similar effect has been shown in CATT⁶⁸ and IVAN⁶¹ with ranibizumab and bevacizumab and in HAWK and HARRIER with brolucizumab and aflibercept.⁴² Maintaining a dry macula over time provides better long-term VA outcomes than repeatedly rescuing it from disease progression, in other words, allowing for fluctuations.

CASE 4: NEW CHOROIDAL NEOVASCULARIZATION DETECTED BY OPTICAL COHERENCE TOMOGRAPHY ANGIOGRAPHY

From the Files of Baruch D. Kuppermann, MD, PhD (Courtesy of Nadia Waheed, MD)

A 67-year-old woman with dry AMD and VA of 20/20 in both eyes presented for routine follow-up and was found to have an asymptomatic CNV complex in 1 eye on OCT-A (**Figure 11**). No fluid was noted on the OCT images until late in the sequence of images.

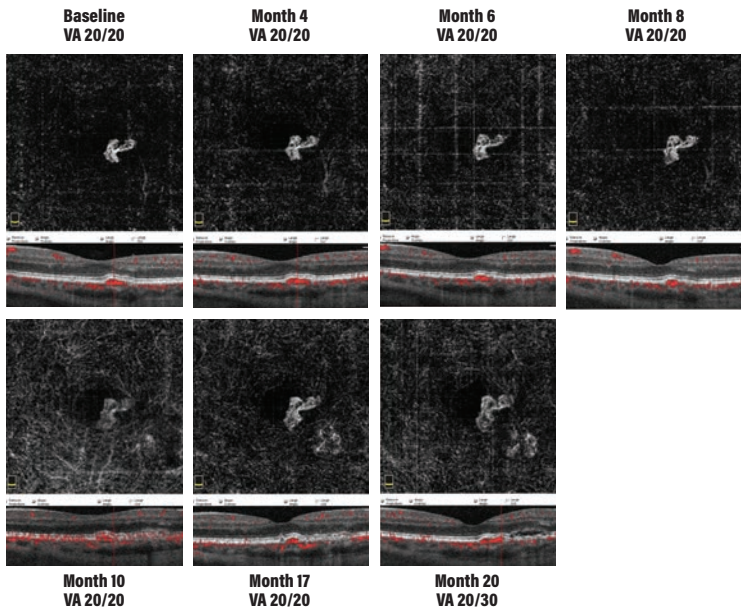


Figure 11. Optical coherence tomography angiography images (top) and optical coherence tomography images (bottom) of the patient presented in Case 4
Abbreviation: VA, visual acuity.

Dr Kuppermann: In the absence of fluid, should this lesion be treated?

Dr Dugel: We do not know at this point whether these lesions should be treated or not. One possibility is that they represent CNV that is the body's natural wound-healing process. More precisely, we do not know if these vessels represent an appropriate wound-healing response or are a harbinger to an eventual pathologic response. Because of this, all we can do is observe such patients closely.

Dr Regillo: This lesion would be undetected without OCT-A, so we do not know how common such lesions are. There might be a higher risk of conversion to exudative CNV; therefore, eyes with such lesions should be watched perhaps more closely than those without lesions.

Dr Kuppermann: This lesion remained quite stable for approximately 18 months, after which some subretinal fluid was seen on the OCT images. Anti-VEGF therapy was initiated at that point, stabilizing the disease.

TAKE-HOME POINTS

- Early detection and prompt treatment of nAMD provides the best visual outcomes
- Monitoring of dry AMD can be achieved in the office or at home. Diligent monitoring can detect recent conversion before irreversible vision loss occurs.
- The burden of treatment for nAMD is considerable. Modified dosing strategies, including TAE, have equivalent efficacy to standard dosing, with reduced injection frequency.
- Clinical trials have demonstrated that newly approved and emerging agents have comparable efficacy and safety to those of classic anti-VEGF therapies, but with fewer injections

REFERENCES

1. Prevent Blindness. AMD (age-related macular degeneration). <http://preventblindness.org/AMD-age-related-macular-degeneration>. Accessed December 3, 2019.
2. Resnikoff S, Pascolini D, Etya'ale D, et al. Global data on visual impairment in the year 2002. *Bull World Health Organ*. 2004;82(11):844-851.
3. Brown GC, Brown MM, Sharma S, et al. The burden of age-related macular degeneration: a value-based medicine analysis. *Trans Am Ophthalmol Soc*. 2005;103:173-184.
4. Rosenfeld PJ, Brown DM, Heier JS, et al; MARINA Study Group. Ranibizumab for neovascular age-related macular degeneration. *N Engl J Med*. 2006;355(14):1419-1431.
5. Brown DM, Kaiser PK, Michels M, et al; ANCHOR Study Group. Ranibizumab versus verteporfin for neovascular age-related macular degeneration. *N Engl J Med*. 2006;355(14):1432-1444.
6. Rao P, Lum F, Wood K, et al. Real-world vision in age-related macular degeneration patients treated with single anti-VEGF drug type for 1 year in the IRIS Registry. *Ophthalmology*. 2018;125(4):522-528.
7. Ying GS, Huang J, Maguire MG, et al; Comparison of Age-Related Macular Degeneration Treatments Trials Research Group. Baseline predictors for one-year visual outcomes with ranibizumab or bevacizumab for neovascular age-related macular degeneration. *Ophthalmology*. 2013;120(1):122-129.
8. Olsen TW, Feng X, Kasper TJ, Rath PP, Steuer ER. Fluorescein angiographic lesion type frequency in neovascular age-related macular degeneration. *Ophthalmology*. 2004;111(2):250-255.
9. Acharya N, Lois N, Townend J, Zaher S, Gallagher M, Gavin M. Socio-economic deprivation and visual acuity at presentation in exudative age-related macular degeneration. *Br J Ophthalmol*. 2009;93(5):627-629.
10. Fong DS, Custis P, Howes J, Hsu JW. Intravitreal bevacizumab and ranibizumab for age-related macular degeneration: a multicenter, retrospective study. *Ophthalmology*. 2010;117(2):298-302.
11. Ho AC. In pursuit of an earlier diagnosis. *Retina Today*. 2018; May/June:48-50.
12. Ho AC. Retrospective analysis of real-world disease detection and visual acuity outcomes in patients with dry AMD converting to wet AMD using the AAO IRIS registry database. Paper presented at: 2018 American Society of Cataract and Refractive Surgery Annual Meeting; April 13-17, 2018; Washington, DC.
13. Brown DM, Michels M, Kaiser PK, Heier JS, Sy JP, lanchuev T; ANCHOR Study Group. Ranibizumab versus verteporfin photodynamic therapy for neovascular age-related macular degeneration: two-year results of the ANCHOR study. *Ophthalmology*. 2009;116(11):57-65.e5.
14. Martin DF, Maguire MG, Ying GS, Grunwald JE, Fine SL, Jaffe GJ; CATT Research Group. Ranibizumab and bevacizumab for neovascular age-related macular degeneration. *N Engl J Med*. 2011;364(20):1897-1908.
15. Heier JS, Brown DM, Chong V, et al; VIEW 1 and VIEW 2 Study Groups. Intravitreal aflibercept (VEGF trap-eye) in wet age-related macular degeneration. *Ophthalmology*. 2012;119(12):2537-2548.
16. Ho AC, Busbee BG, Regillo CD, et al; HARBOR Study Group. Twenty-four-month efficacy and safety of 0.5 mg or 2.0 mg ranibizumab in patients with subfoveal neovascular age-related macular degeneration. *Ophthalmology*. 2014;121(11):2181-2192.
17. Gillies MC, Nguyen V, Daien V, Arnold JJ, Morlet N, Barthelmes D. Twelve-month outcomes of ranibizumab vs. aflibercept for neovascular age-related macular degeneration: data from an observational study. *Ophthalmology*. 2016;123(12):2545-2553.
18. Holz FG, Bandello F, Gillies M, et al; LUMINOUS Steering Committee. Safety of ranibizumab in routine clinical practice: 1-year retrospective pooled analysis of four European neovascular AMD registries within the LUMINOUS programme. *Br J Ophthalmol*. 2013;97(9):1161-1167.
19. Holz FG, Tadayoni R, Beatty S, et al. Multi-country real-life experience of anti-vascular endothelial growth factor therapy for wet age-related macular degeneration. *Br J Ophthalmol*. 2015;99(2):220-226.
20. Writing Committee for the UK Age-Related Macular Degeneration EMR Users Group. The neovascular age-related macular degeneration database: multicenter study of 92 976 ranibizumab injections: report 1: visual acuity. *Ophthalmology*. 2014;121(5):1092-1101.
21. Kim LN, Mehta H, Barthelmes D, Nguyen V, Gillies MC. Metaanalysis of real-world outcomes of intravitreal ranibizumab for the treatment of neovascular age-related macular degeneration. *Retina*. 2016;36(8):1418-1431.
22. Kaiser PK, Brown DM, Zhang K, et al. Ranibizumab for predominantly classic neovascular age-related macular degeneration: subgroup analysis of first-year ANCHOR results. *Am J Ophthalmol*. 2007;144(6):850-857.

23. Boyer DS, Antoszyk AN, Awh CC, Bhisitkul RB, Shapiro H, Acharya NR; MARINA Study Group. Subgroup analysis of the MARINA study of ranibizumab in neovascular age-related macular degeneration. *Ophthalmology*. 2007;114(2):246-252.
24. Rauch R, Weingessel B, Maca SM, Vecsei-Marlovits PV. Time to first treatment: the significance of early treatment of exudative age-related macular degeneration. *Retina*. 2012;32(7):1260-1264.
25. Mowatt G, Hernández R, Castillo M, et al. Optical coherence tomography for the diagnosis, monitoring and guiding of treatment for neovascular age-related macular degeneration: a systematic review and economic evaluation. *Health Technol Assess*. 2014;18(69):1-254.
26. Folgar FA, Yuan EL, Sevilla MB, et al; Age Related Eye Disease Study 2 Ancillary Spectral-Domain Optical Coherence Tomography Study Group. Drusen volume and retinal pigment epithelium abnormal thinning volume predict 2-year progression of age-related macular degeneration. *Ophthalmology*. 2016;123(1):39-50.e1.
27. Little K, Ma JH, Yang N, Chen M, Xu H. Myofibroblasts in macular fibrosis secondary to neovascular age-related macular degeneration - the potential sources and molecular cues for their recruitment and activation. *EBioMedicine*. 2018;38:283-291.
28. Bandello F, Souied EH, Querques G, eds. *OCT Angiography in Retinal and Macular Diseases*. Basel, Switzerland: S. Karger AG; 2016.
29. Coscas F, Lupidi M, Boulet JF, et al. Optical coherence tomography angiography in exudative age-related macular degeneration: a predictive model for treatment decisions. *Br J Ophthalmol*. 2019;103(9):1342-1346.
30. Iafe NA, Phasukkijwatana N, Sarraf D. Optical coherence tomography angiography of type 1 neovascularization in age-related macular degeneration. *Dev Ophthalmol*. 2016;56:45-51.
31. Dansingani KK, Balaratnasingam C, Klufas MA, Sarraf D, Freund KB. Optical coherence tomography angiography of shallow irregular pigment epithelial detachments in pachychoroid spectrum disease. *Am J Ophthalmol*. 2015;160(6):1243-1254.e2.
32. Jeong YJ, Hong IH, Chung JK, Kim KL, Kim HK, Park SP. Predictors for the progression of geographic atrophy in patients with age-related macular degeneration: fundus autofluorescence study with modified fundus camera. *Eye (Lond)*. 2014;28(2):209-218.
33. Schwartz R, Loewenstein A. Early detection of age related macular degeneration: current status. *Int J Retina Vitreous*. 2015;1:20.
34. Chew EY, Clemons TE, Bressler SB, et al; AREDS2-HOME Study Research Group. Randomized trial of a home monitoring system for early detection of choroidal neovascularization home monitoring of the Eye (HOME) study. *Ophthalmology*. 2014;121(2):535-544.
35. Domalpally A, Clemons TE, Bressler SB, et al. Imaging characteristics of choroidal neovascular lesions in the AREDS2-HOME Study: report number 4. *Ophthalmol Retina*. 2019;3(4):326-335.
36. Seddon JM, Silver RE, Kwong M, Rosner B. Risk prediction for progression of macular degeneration: 10 common and rare genetic variants, demographic, environmental, and macular covariates. *Invest Ophthalmol Vis Sci*. 2015;56(4):2192-2202.
37. Chew EY, Klein ML, Clemons TE, et al; Age-Related Eye Disease Study Research Group. No clinically significant association between CFH and ARMS2 genotypes and response to nutritional supplements: AREDS report number 38. *Ophthalmology*. 2014;121(11):2173-2180.
38. AAO Hoskins Center for Quality Eye Care. Frequency of ocular examinations - 2015. <https://www.aao.org/clinical-statement/frequency-of-ocular-examinations>. Published March 2015. Accessed December 3, 2019.
39. Center for Drug Evaluation and Research. Approval package for application number 7611250r1gs000. US Food and Drug Administration Web site. https://www.accessdata.fda.gov/drugsatfda_docs/nda/2019/7611250r1gs000Approv.pdf. Published October 7, 2019. Accessed January 24, 2020.
40. Beovu [package insert]. East Hanover, NJ: Novartis Pharmaceuticals Corporation; 2019.
41. Dugel PU, Koh A, Ogura Y, et al; HAWK and HARRIER Study Investigators. HAWK and HARRIER: phase 3, multicenter, randomized, double-masked trials of brolicizumab for neovascular age-related macular degeneration. *Ophthalmology*. 2020;127(1):72-84.
42. Holz FG, Dugel P, Jhaveri C, et al. Visual and expanded anatomical outcomes for brolicizumab versus aflibercept in patients with neovascular AMD: 96 week data from HAWK and HARRIER. Paper presented at: 19th Euretina Congress; September 5-8, 2019; Paris, France.
43. Yannuzzi NA, Freund KB. Brolicizumab: evidence to date in the treatment of neovascular age-related macular degeneration. *Clin Ophthalmol*. 2019;13:1323-1329.
44. Tietz J, Spohn G, Schmid G, et al. Affinity and potency of RTH258 (ESBA1008), a novel inhibitor of vascular endothelial growth factor A for the treatment of retinal disorders. *Invest Ophthalmol Vis Sci*. 2015;56(7):1501.
45. Dugel PU, Jaffe GJ, Sallstig P, et al. Brolicizumab versus aflibercept in participants with neovascular age-related macular degeneration: a randomized trial. *Ophthalmology*. 2017;124(9):1296-1304.
46. Semeraro F, Morescalchi F, Duse S, Parmegiani F, Gambicorti E, Costagliola C. Aflibercept in wet AMD: specific role and optimal use. *Drug Des Devel Ther*. 2013;7:711-722.
47. Escher D, Schmidt A, Steiner P, Maurer P, Weissgerber G. Single-chain antibody fragments in ophthalmology. Paper presented at: 15th EURETINA Congress; September 17-20, 2015; Nice, France.
48. Liu K, Song Y, Xu G, et al; PHOENIX Study Group. Conbercept for treatment of neovascular age-related macular degeneration: results of the randomized phase 3 PHOENIX study. *Am J Ophthalmol*. 2019;197:156-167.
49. Chengdu Kanghong Biotech Co, Ltd. Efficacy and safety trial of conbercept intravitreal injection for neovascular age-related macular degeneration (PANDA-1). ClinicalTrials.gov Web site. <https://clinicaltrials.gov/ct2/show/NCT03577899>. Updated October 10, 2018. Accessed December 5, 2019.
50. Chengdu Kanghong Biotech Co, Ltd. Efficacy and safety trial of conbercept intravitreal injection for neovascular age-related macular degeneration (PANDA-2). ClinicalTrials.gov Web site. <https://clinicaltrials.gov/ct2/show/NCT03630952>. Updated March 5, 2019. Accessed December 11, 2019.
51. Smithwick E, Stewart MW. Designed ankyrin repeat proteins: a look at their evolving use in medicine with a focus on the treatment of chorioretinal vascular disorders. *Antiinflamm Antiallergy Agents Med Chem*. 2017;16(1):33-45.
52. Callanan D, Kunimoto D, Maturi RK, et al. Double-masked, randomized, phase 2 evaluation of abicipar pegol (an anti-VEGF DARPIn therapeutic) in neovascular age-related macular degeneration [published online ahead of print November 9, 2018]. *J Ocul Pharmacol Ther*. doi:10.1089/jop.2018.0062.
53. Campochiaro PA, Channa R, Berger BB, et al. Treatment of diabetic macular edema with a designed ankyrin repeat protein that binds vascular endothelial growth factor: a phase I/II study. *Am J Ophthalmol*. 2013;155(4):697-704.
54. Khurana RN. Safety and efficacy of abicipar in patients with neovascular age-related macular degeneration. Paper presented at: 2018 Annual Meeting of the American Academy of Ophthalmology; October 27-30, 2018; Chicago, IL.
55. Khurana R. Abicipar for neovascular age-related macular degeneration: two-year results from CEDAR and SEQUOIA phase 3 clinical trials. Paper presented at: 2019 Annual Meeting of the American Academy of Ophthalmology; October 12-15, 2019; San Francisco, CA.
56. PRNewswire. Allergan and Molecular Partners announce topline safety results from MAPLE study of abicipar pegol [press release]. <https://www.prnewswire.com/news-releases/allergan-and-molecular-partners-announce-topline-safety-results-from-maple-study-of-abicipar-pegol-300822353.html>. Published April 2, 2019. Accessed December 5, 2019.
57. Campochiaro PA, Marcus DM, Awh CC, et al. The port delivery system with ranibizumab for neovascular age-related macular degeneration: results from the randomized phase 2 Ladder clinical trial. *Ophthalmology*. 2019;126(8):1141-1154.
58. Awh C. LADDER trial of the port delivery system with ranibizumab: initial study results. Paper presented at: 36th Annual Meeting of the American Society of Retina Specialists; July 20-25, 2018; Vancouver, Canada.
59. Hoffmann-La Roche. A phase III study to evaluate the port delivery system implant with ranibizumab compared with monthly ranibizumab injections in participants with wet age-related macular degeneration (Archway). ClinicalTrials.gov Web site. <https://clinicaltrials.gov/ct2/show/NCT03677934>. Updated January 7, 2020. Accessed January 23, 2020.
60. Regula JT, Lundh von Leitner P, Foxton R, et al. Targeting key angiogenic pathways with a bispecific CrossMAb optimized for neovascular eye diseases. *EMBO Mol Med*. 2016;11(5).
61. Dugel P. Anti-VEGF/anti-angiopoietin-2 bispecific antibody RG7716 in neovascular age-related macular degeneration. Paper presented at: 51st Annual Meeting of The Retina Society; September 12-15, 2018; San Francisco, CA.
62. Khanani AM, et al. Simultaneous inhibition of VEGF and Ang-2 with faricimab in neovascular AMD: STAIRWAY phase 2 results. Paper presented at: 2018 Annual Meeting of the American Academy of Ophthalmology; October 27-30, 2018; Chicago, IL.
63. Danzig C, Quezada Ruiz C, Basu K, et al. Efficacy and safety of faricimab every 16 or 12 weeks for neovascular age-related macular degeneration: STAIRWAY phase 2 results. Poster presented at: The Association for Research in Vision and Ophthalmology 2019 Annual Meeting; April 27-May 2, 2019; Vancouver, Canada.
64. Hoffmann-La Roche. A study to evaluate the efficacy and safety of faricimab in participants with neovascular age-related macular degeneration (TENAYA). ClinicalTrials.gov Web site. <https://clinicaltrials.gov/ct2/show/NCT03823287>. Updated December 2, 2019. Accessed December 5, 2019.
65. Hoffmann-La Roche. A study to evaluate the efficacy and safety of faricimab in participants with neovascular age-related macular degeneration (LUCERNE). ClinicalTrials.gov Web site. <https://clinicaltrials.gov/ct2/show/NCT03823300>. Updated November 28, 2019. Accessed December 5, 2019.
66. Holekamp NM, Liu Y, Yeh WS, et al. Clinical utilization of anti-VEGF agents and disease monitoring in neovascular age-related macular degeneration. *Am J Ophthalmol*. 2014;157(4):825-833.e1.
67. Maguire MG, Martin DF, Ying GS, et al; Comparison of Age-Related Macular Degeneration Treatments Trials (CATT) Research Group. Five-year outcomes with anti-vascular endothelial growth factor treatment of neovascular age-related macular degeneration: the Comparison of Age-Related Macular Degeneration Treatments Trials. *Ophthalmology*. 2016;123(8):1751-1761.
68. Martin DF, Maguire MG, Fine SL, et al; Comparison of Age-Related Macular Degeneration Treatments Trials (CATT) Research Group. Ranibizumab and bevacizumab for treatment of neovascular age-related macular degeneration: two-year results. *Ophthalmology*. 2012;119(7):1388-1398.
69. Spaide R. Ranibizumab according to need: a treatment for age-related macular degeneration. *Am J Ophthalmol*. 2007;143(4):679-680.
70. Rayess N, Houston SK 3rd, Gupta OP, Ho AC, Regillo CD. Treatment outcomes after 3 years in neovascular age-related macular degeneration using a treat-and-extend regimen. *Am J Ophthalmol*. 2015;159(1):3-8.e1.
71. DeCros F, Reed D, Adam MK, et al. Treat-and-extend therapy using aflibercept for neovascular age-related macular degeneration: a prospective clinical trial. *Am J Ophthalmol*. 2017;180:142-150.
72. Wykoff CC, Ou WC, Brown DM, et al; TREX-AMD Study Group. Randomized trial of treat-and-extend versus monthly dosing for neovascular age-related macular degeneration: 2-year results of the TREX-AMD study. *Ophthalmol Retina*. 2017;1(4):314-321.
73. Silva R, Berta A, Larsen M, Macfadden W, Feller C, Monés J; TREND Study Group. Treat-and-extend versus monthly regimen in neovascular age-related macular degeneration: results with ranibizumab from the TREND study. *Ophthalmology*. 2018;125(1):57-65.
74. Kertes PJ, Galic IJ, Greve M, et al. Canadian Treat-and-Extend Analysis Trial With Ranibizumab in patients with neovascular age-related macular disease: one-year results of the randomized Canadian Treat-and-Extend Analysis Trial With Ranibizumab study. *Ophthalmology*. 2019;126(6):841-848.
75. Lad EM, Hammill BG, Qualls LG, Wang F, Cousins SW, Curtis LH. Anti-VEGF treatment patterns for neovascular age-related macular degeneration among Medicare beneficiaries. *Am J Ophthalmol*. 2014;158(3):537-543.e2.
76. Kiss S, Liu Y, Brown J, et al. Clinical monitoring of patients with age-related macular degeneration treated with intravitreal bevacizumab or ranibizumab. *Ophthalmic Surg Lasers Imaging Retina*. 2014;45(4):285-291.
77. Jaffe GJ, Ying GS, Toth CA, et al; Comparison of Age-Related Macular Degeneration Treatments Trials Research Group. Macular morphology and visual acuity in year five of the Comparison of Age-Related Macular Degeneration Treatments Trials. *Ophthalmology*. 2019;126(2):252-260.
78. Saddy SR, Ghanekar A, Hill L, Gune S. Relationship between sub retinal fluid (SRF) and vision outcomes in eyes with neovascular age-related macular degeneration (nAMD) in the HARBOR trial. Abstract presented at: The Association for Research in Vision and Ophthalmology 2019 Annual Meeting; April 27-May 2, 2019; Vancouver, Canada.
79. Notal Vision, Ltd. Notal Vision announces FDA grants breakthrough device designation for pioneering patient-operated home optical coherence tomography (OCT) system [press release]. <https://notalvision.com/assets/press-releases/Notal-Vision-Announces-FDA-Grants-Breakthrough-Device-Designation-for-Pioneering-Patient-Operated-Home-Optical-Coherence-Tomography-OC-T-System.pdf>. Published December 3, 2018. Accessed December 5, 2019.
80. Notal Vision Ltd. NOTAL-OCT V.2.5 vs commercial OCT in AMD patients. ClinicalTrials.gov Web site. <https://clinicaltrials.gov/ct2/show/NCT03969303>. Updated July 1, 2019. Accessed December 5, 2019.
81. Chakravarthy U, Harding SP, Rogers CA, et al; IVAN Study Investigators. Ranibizumab versus bevacizumab to treat neovascular age-related macular degeneration: one-year findings from the IVAN randomized trial. *Ophthalmology*. 2012;119(7):1399-1411.



CME POST TEST QUESTIONS

To obtain *AMA PRA Category 1 Credit™* for this activity, complete the CME Post Test and course evaluation **online** at <https://tinyurl.com/namdcme>. (Paper submissions cannot be processed.) Upon successful completion of the post test and evaluation, you will be able to generate an instant certificate of credit.

See detailed instructions at **To Obtain AMA PRA Category 1 Credit™** on page 2.

- Which of the following technologies was shown to enable more frequent detection of CNV when VA was 20/40 or better vs conventional home use of Amsler grid?
 - Home PHP
 - ICG angiography
 - Mobile device Amsler grid
 - FAF
- By which mechanism is brolicizumab thought to increase the durability of response vs traditional anti-VEGF agents?
 - Higher relative molar concentration
 - Targeting the angiopoietin pathway
 - Continuous drug delivery
 - Targeting multiple angiogenic pathways
- By which mechanism is abicipar pegol thought to increase the durability of response vs traditional anti-VEGF agents?
 - Targeting additional VEGF-binding domains
 - Targeting multiple angiogenic pathways
 - Extended intraocular half-life
 - Continuous drug delivery
- Which of the following agents was shown to reduce intraretinal and/or subretinal fluid significantly better than its comparator among patients completing 2 years of study?
 - Abicipar pegol
 - Brolicizumab
 - Conbercept
 - Ranibizumab PDS
- A 78-year-old man treated with monthly ranibizumab for nAMD for 4 months reports difficulty arranging travel and would like to skip his next injection. His VA is 20/30, central retinal thickness has reduced by 80% from baseline, and a small amount of intraretinal fluid remains. According to recent TAE and fluid studies in nAMD, when can the interval of treatment for this patient be safely extended?
 - After 4 months of continuous anti-VEGF treatment
 - After 1 year of continuous anti-VEGF treatment
 - Once all neovascularization has resolved
 - Once intraretinal fluid has resolved
- Which of the following imaging technologies reveals retinal and choroidal vessels and enables evaluation of the neovascular complex in CNV lesions in eyes with nAMD?
 - FA
 - ICG angiography
 - Spectral-domain OCT
 - OCT-A
- A patient with nAMD has undergone 3 monthly loading doses of anti-VEGF therapy, with a dry macula and VA of 20/25. She lives 250 miles from the office and has transportation issues. Which of the following is the best next step?
 - Switch to a different anti-VEGF agent to avoid tolerance
 - Observe to see if stability can be maintained without further treatment
 - Continue monthly injections for at least 2 years
 - Begin extending visits by 2 weeks to determine her maximal extension interval
- Which of the following is least likely to affect long-term VA outcomes in nAMD?
 - Early diagnosis
 - Small lesion size at diagnosis
 - Number of large drusen present in the macula
 - Good VA at the time of diagnosis
- Which is a component of treatment burden in AMD?
 - Frequency of anti-VEGF injections
 - Frequency of office visits
 - Time and expense incurred by caregivers who accompany the patient to office visits
 - All the above contribute to treatment burden
- A patient with nAMD undergoes 3 monthly anti-VEGF loading doses, and then begins TAE dosing. Her macula is dry at the 6- and 8-week intervals but not at the 10-week interval, and her VA has dropped by 2 lines. What is the best next course of action according to the TAE approach to therapy?
 - Re-treat and return in 4 weeks
 - Re-treat and return in 6 weeks
 - Re-treat and return in 8 weeks
 - Re-treat and return in 10 weeks