



AMERICAN ACADEMY  
OF OPHTHALMOLOGY®

Protecting Sight. Empowering Lives.®

# Diabetic Retinopathy Preferred Practice Pattern®

Secretary for Quality of Care:  
Timothy W. Olsen, MD

Academy Staff:  
Ali Al-Rajhi, PhD, MPH  
Andre Ambrus, MLIS  
Meghan Daly  
Flora C. Lum, MD

Medical Editor: Susan Garratt

Approved by: Board of Trustees  
September 7, 2019

© 2019 American Academy of Ophthalmology®  
All rights reserved

AMERICAN ACADEMY OF OPHTHALMOLOGY and PREFERRED PRACTICE PATTERN are registered trademarks of the American Academy of Ophthalmology. All other trademarks are the property of their respective owners.

Preferred Practice Pattern® guidelines are developed by the Academy's H. Dunbar Hoskins Jr., MD Center for Quality Eye Care without any external financial support. Authors and reviewers of the guidelines are volunteers and do not receive any financial compensation for their contributions to the documents. The guidelines are externally reviewed by experts and stakeholders before publication.

Correspondence:  
Ali A. Al-Rajhi, PhD, MPH American Academy of Ophthalmology, P. O. Box 7424, San Francisco, CA 94120-7424. E-mail: [aalrajhi@aao.org](mailto:aalrajhi@aao.org).

# RETINA/VITREOUS PREFERRED PRACTICE PATTERN® DEVELOPMENT PROCESS AND PARTICIPANTS

The **Retina/Vitreous Preferred Practice Pattern® Panel** members wrote the Diabetic Retinopathy Preferred Practice Pattern® (PPP) guidelines. The PPP Panel members discussed and reviewed successive drafts of the document, meeting in person twice and conducting other review by e-mail discussion, to develop a consensus over the final version of the document.

## **Retina/Vitreous Preferred Practice Pattern Panel 2018–2019**

Steven T. Bailey, MD, Retina Society Representative

Amani Fawzi, MD, Macula Society Representative

Jennifer I. Lim, MD

Ron A. Adelman, MD, MPH, MBA, FACS

Gurunadh A. Vemulakonda, MD, American Society of Retina Specialists Representative

Gui-shang Ying, MD, PhD, Methodologist

Christina J. Flaxel, MD, Chair

*We thank our partners, the Cochrane Eyes and Vision US Satellite (CEV@US), for identifying reliable systematic reviews that we cite and discuss in support of the PPP recommendations.*

**The Preferred Practice Patterns Committee members reviewed and discussed the document during a meeting in June 2019. The document was edited in response to the discussion and comments.**

## **Preferred Practice Patterns Committee 2019**

Robert S. Feder, MD, Chair

Roy S. Chuck, MD, PhD

Steven P. Dunn, MD

Christina J. Flaxel, MD

Steven J. Gedde, MD

Francis S. Mah, MD

Randall J. Olson, MD

David K. Wallace, MD, MPH

David C. Musch, PhD, MPH, Methodologist

The Diabetic Retinopathy PPP was then sent for review to additional internal and external groups and individuals in July 2019. All those returning comments were required to provide disclosure of relevant relationships with industry to have their comments considered (indicated with an asterisk below). Members of the Retina/Vitreous Preferred Practice Pattern Panel reviewed and discussed these comments and determined revisions to the document.

## FINANCIAL DISCLOSURES

In compliance with the Council of Medical Specialty Societies' Code for Interactions with Companies (available at [www.cmss.org/codeforinteractions.aspx](http://www.cmss.org/codeforinteractions.aspx)), relevant relationships with industry are listed. The Academy has Relationship with Industry Procedures to comply with the Code (available at <http://one.aao.org/CE/PracticeGuidelines/PPP.aspx>). A majority (88%) of the members of the Retina/Vitreous Preferred Practice Pattern Panel 2018–2019 had no financial relationship to disclose.

### Retina/Vitreous Preferred Practice Pattern Panel 2018–2019

Christina J. Flaxel, MD: No financial relationships to disclose  
 Ron A. Adelman, MD, MPH, MBA, FACS: No financial relationships to disclose  
 Steven T. Bailey, MD: No financial relationships to disclose  
 Amani Fawzi, MD: No financial relationships to disclose  
 Jennifer I. Lim, MD: Alcon Laboratories, Genentech, Kodiak Sciences, EyePoint Pharmaceuticals—Consultant/Advisor; Genentech—Lecture Fees  
 Gurunadh A. Vemulakonda, MD: No financial relationships to disclose  
 Gui-shang Ying, MD, PhD: No financial relationships to disclose

### Preferred Practice Patterns Committee 2019

Robert S. Feder, MD, Chair: No financial relationships to disclose  
 Roy S. Chuck, MD, PhD: Novartis, Shire—Consultant/Advisor  
 Steven P. Dunn, MD: No financial relationships to disclose  
 Christina J. Flaxel, MD: No financial relationships to disclose  
 Steven J. Gedde, MD: No financial relationships to disclose  
 Francis S. Mah, MD: Aerie Pharmaceuticals, Bausch + Lomb, EyePoint Pharmaceuticals, Novartis, Ocular Therapeutix, Shire, Sun Pharma—Consultant/Advisor; Bausch + Lomb, Novartis, Shire, Sun Pharma—Lecture Fees  
 Randall J. Olson, MD: No financial disclosures  
 David K. Wallace, MD, MPH: No financial disclosures  
 David C. Musch, PhD, MPH, Methodologist, IRIDEX, Notal Vision—Consultant/Advisor

### Secretary for Quality of Care

Timothy W. Olsen, MD: No financial relationships to disclose

### Academy Staff

Ali Al-Rajhi, PhD, MPH: No financial relationships to disclose  
 Andre Ambrus, MLIS: No financial relationships to disclose  
 Meghan Daly: No financial relationships to disclose  
 Flora C. Lum, MD: No financial relationships to disclose

The disclosures of relevant relationships to industry of other reviewers of the document from January to October 2019 are available online at [www.aao.org/ppp](http://www.aao.org/ppp).

## TABLE OF CONTENTS

<b>OBJECTIVES OF PREFERRED PRACTICE PATTERN GUIDELINES</b> .....	P72
<b>METHODS AND KEY TO RATINGS</b> .....	P73
<b>HIGHLIGHTED FINDINGS AND RECOMMENDATIONS FOR CARE</b> .....	P74
<b>INTRODUCTION</b> .....	P75
Disease Definition .....	P75
Patient Population .....	P75
Clinical Objectives .....	P75
<b>BACKGROUND</b> .....	P76
Introduction .....	P76
Prevalence of Diabetes .....	P76
Prevalence of Diabetic Retinopathy .....	P77
Risk Factors .....	P78
Natural History .....	P80
<b>CARE PROCESS</b> .....	P83
Patient Outcome Criteria .....	P84
Diagnosis .....	P84
History .....	P84
Examination .....	P84
Examination Schedule .....	P85
Ancillary Tests .....	P86
Management .....	P89
Prevention of Diabetic Retinopathy .....	P89
Early Detection of Diabetic Retinopathy .....	P90
Medical and Surgical Management .....	P91
Follow-up Evaluation .....	P104
Provider and Setting .....	P104
Counseling and Referral .....	P104
Socioeconomic Considerations .....	P105
<b>APPENDIX 1. QUALITY OF OPHTHALMIC CARE CORE CRITERIA</b> .....	P106
<b>APPENDIX 2. INTERNATIONAL STATISTICAL CLASSIFICATION OF DISEASES AND RELATED HEALTH PROBLEMS (ICD) CODES</b> .....	P108
<b>APPENDIX 3. MAJOR STUDY RESULTS</b> .....	P110
<b>APPENDIX 4. GLYCEMIC CONTROL</b> .....	P119
<b>APPENDIX 5. CLASSIFICATION OF DIABETIC RETINOPATHY IN THE EARLY TREATMENT OF DIABETIC RETINOPATHY STUDY</b> .....	P123
<b>GLOSSARY</b> .....	P124
<b>LITERATURE SEARCHES FOR THIS PPP</b> .....	P129
<b>RELATED ACADEMY MATERIALS</b> .....	P130
<b>REFERENCES</b> .....	P131

### Background:

Diabetic retinopathy is a leading cause of visual impairment in working-age adults worldwide. Duration of diabetes is a major risk factor associated with the development of diabetic retinopathy. Due to the disproportionately large number of patients with type 2 diabetes, this group comprises a larger proportion of the disease burden in patients with visual impairment from diabetic retinopathy compared to patients with type 1 diabetes. The recommendations of this Preferred Practice Pattern are based on Cochrane-identified reliable systematic reviews.

### Rationale for treatment:

Both clinical trials and epidemiological studies have shown that the two key modifiable risk factors associated with developing diabetic retinopathy are blood sugar and blood pressure control. Maintaining near-normal glucose levels and near-normal blood pressure lowers the risk of retinopathy developing and/or progressing.

### Care Process:

The care process for diabetic retinopathy includes a medical history, a regular ophthalmologic examination or screening of high-quality retinal photographs of patients who have not had previous treatment for diabetic retinopathy or other eye disease, and regular follow-up. The goal of treatment is to improve or stabilize visual function, improve vision-related quality of life; and, through close communication with the patient's primary care physician achieve optimal control of blood glucose, blood pressure and other metabolic risk factors.

The initial examination for a patient with diabetes mellitus includes all features of the comprehensive adult medical eye evaluation, with particular attention to those aspects relevant to diabetic retinopathy. The examination schedule is detailed in this Preferred Practice Pattern for patients diagnosed with type 1 or type 2 diabetes. Additionally, ancillary tests (e.g., fundus photography, OCT, and FA) to clinical examinations may enhance patient care.

Management options for diabetic retinopathy includes following a healthy diet and lifestyle, medical management, timely ophthalmic evaluation, and treatment under the care of an ophthalmologist. Cost-effective treatments with laser, anti-VEGF agents, or intravitreal corticosteroids may also be considered. Because patients with diabetes may be under the care of multiple practitioners, effective communication and care coordination is necessary to optimize care.

# OBJECTIVES OF PREFERRED PRACTICE PATTERN® GUIDELINES

As a service to its members and the public, the American Academy of Ophthalmology has developed a series of Preferred Practice Pattern® guidelines that **identify characteristics and components of quality eye care**. Appendix 1 describes the core criteria of quality eye care.

The Preferred Practice Pattern® guidelines are based on the best available scientific data as interpreted by panels of knowledgeable health professionals. In some instances, such as when results of carefully conducted clinical trials are available, the data are particularly persuasive and provide clear guidance. In other instances, the panels have to rely on their collective judgment and evaluation of available evidence.

**These documents provide guidance for the pattern of practice, not for the care of a particular individual.** While they should generally meet the needs of most patients, they cannot possibly best meet the needs of all patients. Adherence to these PPPs will not ensure a successful outcome in every situation. These practice patterns should not be deemed inclusive of all proper methods of care or exclusive of other methods of care reasonably directed at obtaining the best results. It may be necessary to approach different patients' needs in different ways. The physician must make the ultimate judgment about the propriety of the care of a particular patient in light of all of the circumstances presented by that patient. The American Academy of Ophthalmology is available to assist members in resolving ethical dilemmas that arise in the course of ophthalmic practice.

**Preferred Practice Pattern® guidelines are not medical standards to be adhered to in all individual situations.** The Academy specifically disclaims any and all liability for injury or other damages of any kind, from negligence or otherwise, for any and all claims that may arise out of the use of any recommendations or other information contained herein.

References to certain drugs, instruments, and other products are made for illustrative purposes only and are not intended to constitute an endorsement of such. Such material may include information on applications that are not considered community standard, that reflect indications not included in approved U.S. Food and Drug Administration (FDA) labeling, or that are approved for use only in restricted research settings. The FDA has stated that it is the responsibility of the physician to determine the FDA status of each drug or device he or she wishes to use, and to use them with appropriate patient consent in compliance with applicable law.

Innovation in medicine is essential to ensure the future health of the American public, and the Academy encourages the development of new diagnostic and therapeutic methods that will improve eye care. It is essential to recognize that true medical excellence is achieved only when the patients' needs are the foremost consideration.

All Preferred Practice Pattern® guidelines are reviewed by their parent panel annually or earlier if developments warrant and updated accordingly. To ensure that all PPPs are current, each is valid for 5 years from the approved by date unless superseded by a revision. Preferred Practice Pattern guidelines are funded by the Academy without commercial support. Authors and reviewers of PPPs are volunteers and do not receive any financial compensation for their contributions to the documents. The PPPs are externally reviewed by experts and stakeholders, including consumer representatives, before publication. The PPPs are developed in compliance with the Council of Medical Specialty Societies' Code for Interactions with Companies. The Academy has Relationship with Industry Procedures (available at [www.aao.org/about-preferred-practice-patterns](http://www.aao.org/about-preferred-practice-patterns)) to comply with the Code.

Appendix 2 contains the International Statistical Classification of Diseases and Related Health Problems (ICD) codes for the disease entities that this PPP covers. The intended users of the Diabetic Retinopathy PPP are ophthalmologists.

## METHODS AND KEY TO RATINGS

Preferred Practice Pattern® guidelines should be clinically relevant and specific enough to provide useful information to practitioners. Where evidence exists to support a recommendation for care, the recommendation should be given an explicit rating that shows the strength of evidence. To accomplish these aims, methods from the Scottish Intercollegiate Guideline Network<sup>1</sup> (SIGN) and the Grading of Recommendations Assessment, Development and Evaluation<sup>2</sup> (GRADE) group are used. GRADE is a systematic approach to grading the strength of the total body of evidence that is available to support recommendations on a specific clinical management issue. Organizations that have adopted GRADE include SIGN, the World Health Organization, the Agency for Healthcare Research and Policy, and the American College of Physicians.<sup>3</sup>

- ◆ All studies used to form a recommendation for care are graded for strength of evidence individually, and that grade is listed with the study citation.
- ◆ To rate individual studies, a scale based on SIGN<sup>1</sup> is used. The definitions and levels of evidence to rate individual studies are as follows:

I++	High-quality meta-analyses, systematic reviews of randomized controlled trials (RCTs), or RCTs with a very low risk of bias
I+	Well-conducted meta-analyses, systematic reviews of RCTs, or RCTs with a low risk of bias
I-	Meta-analyses, systematic reviews of RCTs, or RCTs with a high risk of bias
II++	High-quality systematic reviews of case-control or cohort studies High-quality case-control or cohort studies with a very low risk of confounding or bias and a high probability that the relationship is causal
II+	Well-conducted case-control or cohort studies with a low risk of confounding or bias and a moderate probability that the relationship is causal
II-	Case-control or cohort studies with a high risk of confounding or bias and a significant risk that the relationship is not causal
III	Nonanalytic studies (e.g., case reports, case series)

- ◆ Recommendations for care are formed based on the body of the evidence. The body of evidence quality ratings are defined by GRADE<sup>2</sup> as follows:

Good quality	Further research is very unlikely to change our confidence in the estimate of effect
Moderate quality	Further research is likely to have an important impact on our confidence in the estimate of effect and may change the estimate
Insufficient quality	Further research is very likely to have an important impact on our confidence in the estimate of effect and is likely to change the estimate Any estimate of effect is very uncertain

- ◆ Key recommendations for care are defined by GRADE<sup>2</sup> as follows:

Strong recommendation	Used when the desirable effects of an intervention clearly outweigh the undesirable effects or clearly do not
Discretionary recommendation	Used when the trade-offs are less certain—either because of low-quality evidence or because evidence suggests that desirable and undesirable effects are closely balanced

- ◆ The Highlighted Findings and Recommendations for Care section lists points determined by the PPP Panel to be of particular importance to vision and quality of life outcomes.
- ◆ All recommendations for care in this PPP were rated using the system described above. Ratings are embedded throughout the PPP main text in italics.
- ◆ Literature searches to update the PPP were undertaken in April 2018 and June 2019 in PubMed and the Cochrane Library. Complete details of the literature searches are available online at [www.aao.org/ppp](http://www.aao.org/ppp).



## HIGHLIGHTED FINDINGS AND RECOMMENDATIONS FOR CARE

---

The prevalence of diabetes is increasing with increasing industrialization and globalization. Consequently, the prevalence of diabetic retinopathy and vision-threatening diabetic retinopathy is also expected to increase. Only about 60% of people with diabetes have recommended yearly screenings for diabetic retinopathy. Referral to an ophthalmologist is required when there is any evidence of diabetic retinopathy.

---

People with type 1 diabetes should have annual screenings for diabetic retinopathy beginning 5 years after the onset of their disease, whereas those with type 2 diabetes should have a prompt screening at the time of diagnosis and at least yearly screenings thereafter.

---

Maintaining control of glucose and blood pressure lowers the risk of retinopathy developing and/or progressing, so patients should be informed of the importance of maintaining good levels of glycosylated hemoglobin, and blood pressure.

---

Patients with diabetes may use aspirin for other medical indications (as antiplatelet therapy) without an adverse effect on their risk of diabetic retinopathy.

---

Women with diabetes who become pregnant should be examined early and closely in the course of the pregnancy because the disease can progress rapidly. However, an eye examination is not required when gestational diabetes occurs during pregnancy. Patients with diabetes have an accelerated rate of diabetic retinopathy progression during puberty and should be followed more closely.

---

Intravitreal anti-vascular endothelial growth factor (anti-VEGF) agents are effective in the treatment of center-involved diabetic macular edema with vision loss. At this time, laser photocoagulation surgery remains the preferred treatment for non-center-involved diabetic macular edema and pan-retinal photocoagulation (PRP) surgery remains the mainstay treatment for proliferative diabetic retinopathy (PDR).

---

# INTRODUCTION

## DISEASE DEFINITION

Diabetic retinopathy is a common complication in type 1 and type 2 diabetes. Diabetic retinopathy is the ocular manifestation of end-organ damage in diabetes mellitus.<sup>4</sup> Diabetic retinopathy has been classically considered as a microvascular disease of the retina. However, growing evidence suggests that retinal neurodegeneration is an early event in the pathogenesis of diabetic retinopathy, which could contribute to the development of microvascular abnormalities.<sup>5</sup> Although defects in neurosensory function have been demonstrated in patients with diabetes mellitus prior to the onset of vascular lesions, the most common early clinically visible manifestations of diabetic retinopathy include microaneurysm formation and intraretinal hemorrhages. Microvascular damage leads to retinal capillary nonperfusion, cotton wool spots, an increased number of hemorrhages, venous abnormalities, and intraretinal microvascular abnormalities (IRMA). During this stage, increased vasopermeability can result in retinal thickening (edema) and/or exudates that may lead to a loss in central visual acuity. The proliferative stage results in proliferation of new vessels on the disc, retina, and iris, and in the filtration angle. These new vessels then lead to traction retinal detachments and neovascular glaucoma, respectively. Vision can be substantially impaired in this stage as a result of capillary nonperfusion or edema in the macula, vitreous hemorrhage, and distortion or traction retinal detachment.

A description of the fundus findings in various stages of diabetic retinopathy is included in the Natural History section, and important terms are defined in the Glossary.

## PATIENT POPULATION

The patient population includes all patients with diabetes mellitus.

## CLINICAL OBJECTIVES

- ◆ Identify patients at risk of developing diabetic retinopathy
- ◆ Encourage a collaborative approach between the patient, the primary care physician, and subspecialists in the management of the patient's systemic disorder, with specific attention to control of blood sugar (hemoglobin A<sub>1c</sub> [HbA<sub>1c</sub>]), blood pressure, serum lipids, body weight, and the management of renal disease, coronary artery disease,<sup>6</sup> and neuropathy
- ◆ Encourage and provide lifelong monitoring of retinopathy progression
- ◆ Treat patients with visual loss or those at risk for visual loss from diabetic retinopathy
- ◆ Minimize the side effects of treatment that might adversely affect the patient's vision and/or vision-related quality of life
- ◆ Provide or refer for visual rehabilitation services when a patient has visual impairment from the disease

- ◆ Refer for ophthalmological follow-up for potentially reversible vision loss such as cataracts, glaucoma, or refractive changes
- ◆ Develop new technologies for telemedicine improvement

## BACKGROUND

### INTRODUCTION

In the United States, an estimated three out of five people with diabetes have one or more of the complications associated with the disease.<sup>7</sup> Two main forms of diabetes mellitus are recognized. Type 1, previously called juvenile-onset or insulin-dependent diabetes, is characterized by cellular-mediated autoimmune destruction of the beta cells in the pancreas and usually leads to severe insulin deficiency. Type 2 diabetes was previously referred to as adult-onset or noninsulin-dependent diabetes. Type 2 is characterized by a range of disease from insulin resistance with relative insulin deficiency to predominately an insulin secretory defect combined with insulin resistance. Type 2 patients usually have a relative rather than an absolute insulin deficiency; they may take insulin, yet typically do not need insulin for survival. Many patients with type 2 diabetes are obese, and obesity itself causes relative insulin resistance. Between 90% and 95% of all patients with diabetes have type 2 diabetes.<sup>8</sup> Because of the disproportionately large number of patients with type 2 diabetes, this group comprises a larger proportion of the disease burden in patients with visual impairment from diabetic retinopathy, even though type 1 diabetes is associated with more frequent and more severe ocular complications.<sup>9,10</sup>

### Prevalence of Diabetes

An estimated 100 million Americans aged 18 years and older have either been diagnosed with diabetes or are prediabetic, according to a 2015 report by the Centers for Disease Control and Prevention (CDC). As reported by the CDC, 30.3 million Americans 18 or older have diabetes (9.4% of people in this age group),<sup>11</sup> and about one-quarter are not aware that they have the disease.<sup>12</sup> An additional 79 million persons have impaired fasting blood glucose levels (based on both fasting blood glucose levels and HbA<sub>1c</sub> levels).<sup>12</sup> In 2015, an estimated 1.5 million new cases of diabetes were diagnosed among people aged 18 and older.<sup>11</sup>

Rates of diagnosed diabetes increased with age: among individuals 18 to 44 years old, 4% had diabetes; among those 45 to 64 years old, 17% had diabetes; and among those 65 and older, 25% had diabetes. Rates of diagnosed diabetes were higher among Native Americans and Alaskan Natives (15.1%), non-Hispanic blacks (12.7%), and Hispanics (12.1%) compared with Asians (8.0%) and non-Hispanic whites (7.4%).<sup>11</sup>

Rates of prediabetes (HbA<sub>1c</sub> levels between 5.7% and 6.4%) are also increasing.<sup>13</sup> It is estimated that 33.9% of US adults 18 or older (84.1 million people) have prediabetes based on their fasting glucose or HbA<sub>1c</sub> level. Nearly half (48.3%) of adults 65 or older had prediabetes.<sup>11</sup>

Age-adjusted incidence of diabetes was two times higher for people with less than a high school education (10.4/1000 persons) compared with those with more than a high school education (5.3/1000 persons) from 2013 to 2015. Rates of diabetes and prediabetes are similarly high among children and adolescents (younger than 20).<sup>7</sup> Compared with members of other US racial and ethnic groups, non-Hispanic whites had the highest rate of new cases of type 1 diabetes. Among children and adolescents aged 10 to 19, U.S. minority populations had higher rates of new cases of type 2 diabetes compared with non-Hispanic whites.

The 2015 CDC report notes a higher prevalence of diabetes among American Indians/Alaska Natives (15.1%), non-Hispanic blacks (12.7%), and people of Hispanic ethnicity (12.1%) than among non-Hispanic whites (7.4%) and Asians (8.0%) among adults aged 18 years or older.<sup>11</sup> Americans of African descent or Hispanic ethnicity have a disproportionately high prevalence of diabetes compared with Americans of European descent (12.6%, 11.8%, 7.0%, respectively), whereas Asian Americans have only a slightly higher prevalence (8.4%).<sup>12</sup> Native Americans and Alaskan Natives had an approximate diabetes prevalence of 6.4 per 1000 in 1990 and increased to 9.3 per 1000 in 1998 (approximately 45% increase) in children and young adults under the age of 35 years.<sup>14,15</sup> Other research suggests a high prevalence of diabetes in Asia.<sup>16,17</sup>

According to estimates based on data from the U.S. Census Bureau, approximately one-third of Americans are at risk of developing diabetes mellitus during their lifetime.<sup>18</sup> With increasing industrialization and globalization, there is a concomitant increasing prevalence of diabetes that is leading to a worldwide epidemic.<sup>19</sup> An alarming increase in the frequency of type 2 diabetes in the pediatric age group has been noted in several countries,<sup>10,20-24</sup> including in the United States, and has been associated with the increased frequency of childhood obesity.<sup>25</sup> Diabetes is one of the most common diseases in school-aged children. Clearly, these trends predict an increase in the number of individuals with diabetes as well as the associated increased costs for health care and the burdens of disability associated with diabetes and its complications. In addition, there is evidence suggesting that diabetes develops at earlier ages and carries a higher incidence of complications among ethnic minorities.<sup>26-28</sup>

## Prevalence of Diabetic Retinopathy

Diabetic retinopathy is a leading cause of new cases of legal blindness among working-age Americans and represents a leading cause of blindness in this age group worldwide.<sup>29</sup> The prevalence rate for retinopathy for all adults with diabetes aged 40 and older in the United States is 28.5% (4.2 million people); worldwide, the prevalence rate has been estimated at 34.6% (93 million people).<sup>30,31</sup> An estimate of the prevalence rate for vision-threatening diabetic retinopathy in the United States is 4.4% (0.7 million people). Worldwide, this prevalence rate has been estimated at 10.2% (28 million people).<sup>30,31</sup> Assuming a similar prevalence of diabetes mellitus, the projected prevalence of individuals with any diabetic

retinopathy in the United States by the year 2020 is 6 million persons, and 1.34 million persons will have vision-threatening diabetic retinopathy.

The prevalence of diabetic retinopathy increases with increasing duration of disease. In the United States, the prevalence is predicted to increase as the incidence and duration of diabetes in the population increases. More than 50% of worldwide visual impairment or blindness from diabetic retinopathy is estimated to exist in the Asia-Pacific region (51% of all those with blindness due to diabetic retinopathy globally [n=424,400], and 56% of those with visual impairment). Prevalence rates of diabetic retinopathy in patients with diabetes range from 10% in India to 43% in Indonesia.<sup>32</sup>

The Chinese American Study has found slightly lower prevalence rates of diabetic retinopathy in Chinese American than in Latino type 2 patients (35.8% in Chinese Americans vs. 42.0% in Latinos). Increasing duration of diabetes was associated with higher probability of diabetic retinopathy in Latinos than Chinese Americans, even after controlling for other known predictors.<sup>33</sup>

## RISK FACTORS

Duration of diabetes is a major risk factor associated with the development of diabetic retinopathy. After 5 years, approximately 25% of type 1 patients will have retinopathy. After 10 years, almost 60% will have retinopathy, and after 15 years, 80% will have retinopathy.<sup>34,35</sup> In the Wisconsin Epidemiologic Study of Diabetic Retinopathy (WESDR) for patients 30 and younger, proliferative diabetic retinopathy (PDR), the most vision-threatening form of the disease, was present in approximately 50% of type 1 patients who had the disease for 20 years.<sup>36</sup> In the Los Angeles Latino Eye Study (LALES) and in Proyecto VER (Vision, Evaluation and Research), 18% of participants with diabetes of more than 15 years' duration had PDR, and there was no difference in the percentage with PDR between those with type 1 and type 2 diabetes.<sup>35,37</sup> In the recent Singapore Eye Disease Study, independent risk factors for any diabetic retinopathy included Indian ethnicity, diabetes duration, HbA<sub>1c</sub>, serum glucose, and systolic blood pressure.<sup>38</sup> Diastolic blood pressure, total cholesterol, and low-density lipoprotein cholesterol were associated with lower odds of any diabetic retinopathy. In a study of First Nations people in Canada, HbA<sub>1c</sub> and systolic blood pressure were found to be independent predictors of 2-step progression of diabetic retinopathy (hazard ratio, 1.42;  $P<0.0001$ ) and systolic blood pressure (hazard ratio, 1.24 per 10 mm Hg;  $P=0.009$ ).<sup>39</sup>

Of type 2 patients over the age of 30 who have a known duration of diabetes of less than 5 years, 40% of those patients taking insulin and 24% of those not taking insulin have retinopathy. These rates increase to 84% and 53%, respectively, when the duration of diabetes has been documented for up to 19 years.<sup>40</sup> Proliferative diabetic retinopathy develops in 2% of type 2 patients who have diabetes for less than 5 years and in 25% of patients who have diabetes for 25 years or more.<sup>40</sup> Comparisons of information from WESDR and more recent population-based studies such as Proyecto VER and

LALES may reflect differences in blood glucose and hypertension management that have occurred over time.

Blood sugar and blood pressure control are the key modifiable risk factors associated with the development of diabetic retinopathy.<sup>41</sup> Support for this association is based on both clinical trials and epidemiologic studies.<sup>42-49</sup> There is general agreement that duration of diabetes and severity of hyperglycemia are the major risk factors for developing retinopathy.<sup>41,50-53</sup> Once retinopathy is present, duration of diabetes appears to be a less important factor than glycemic control in forecasting progression from earlier to later stages of retinopathy.<sup>54,55</sup> It is recommended that a HbA<sub>1c</sub> of 7% or lower is the target for glycemic control in most patients, whereas in selected patients, there may be some benefit to setting a lower target of 6.5%.<sup>56</sup> In fact, an increase in HbA<sub>1c</sub> corresponds to an increased risk of diabetic macular edema (DME).<sup>57</sup>

Treatment of hypertension remains important, although the benefits of intensive management of hypertension is inconclusive.<sup>58,59</sup> Large studies have suggested that management of serum lipids may reduce retinopathy progression and the need for treatment.<sup>60-64</sup> There is less agreement among studies concerning the importance of other factors such as age, type of diabetes, clotting factors, renal disease, physical inactivity, inflammatory biomarkers, and use of angiotensin-converting enzyme inhibitors.<sup>54,61,65-69</sup> Many of these factors are associated with substantial cardiovascular morbidity and mortality and other complications associated with diabetes. Thus, ophthalmologists should encourage patients with diabetes to be as compliant as possible with therapy of all medical aspects of their disease.<sup>70,71</sup>

More recently, lipid-lowering agents have shown a positive effect on slowing progression of diabetic retinopathy. In a recent meta-analysis, lipid-lowering agents showed a protective effect on diabetic retinopathy progression and suggest a possible reduced risk of developing DME. Despite this, there was no effect on visual acuity or on the presence of hard exudates.<sup>72</sup>

There is conflicting evidence that genetics and epigenetic factors may explain differences in progression rates of diabetic retinopathy between groups of individuals with similar duration of diabetes or HbA<sub>1c</sub> levels. A study found that mitochondrial genetic haplogroups modify the risk for progression of disease despite similar HbA<sub>1c</sub> level and duration of diabetes. For patients with haplogroup H, longer diabetes duration and increasing HbA<sub>1c</sub> level were significant risk factors for PDR ( $P=0.0001$  and  $P=0.011$ , respectively). However, for patients with haplogroup UK, neither diabetes duration nor HbA<sub>1c</sub> level was a significant risk factor for PDR.<sup>73</sup> A larger more recent study looking at the same haplotypes failed to show that association.<sup>74</sup>

Another genetic study evaluated patients with type 2 diabetes who were carriers of the HMGA1 rs139876191 variant. Patients with this variant had a significantly lower risk of developing PDR compared with noncarrier diabetic patients.<sup>75</sup> It is believed that the HMGA1 rs139876191 variant confers protection by downregulating the expression of vascular endothelial growth factor A in diabetic retinopathy.

Metabolic syndrome refers to a group of risk factors that increases the risk for developing heart disease, diabetes, and stroke.<sup>76</sup> Metabolic syndrome has also been found to be associated with microvascular and macrovascular disease in a study of patients with type 2 diabetes. More patients with metabolic syndrome had higher rates of albuminuria (40.8% vs 21.8%;  $P<0.001$ ), retinopathy (37.9% vs 28.6%;  $P<0.001$ ), coronary artery disease (19.4% vs 11.6%;  $P<0.001$ ), cerebrovascular disease (5.8% vs 3.2%;  $P=0.014$ ), and an ankle-brachial index of less than 0.9 or of 1.3 or higher (6.1% vs 3.0%;  $P=0.015$ ).<sup>77</sup> There was also a trend for stepwise increases in albuminuria, retinopathy, coronary artery disease, cerebrovascular disease, and peripheral artery disease corresponding to the number of metabolic syndrome components (all  $P$  for trend  $<0.05$ ). Screening programs for metabolic syndrome may therefore be helpful in finding patients at higher risk for progression.

In a recent study of 50,254 eyes, baseline features and level of nonproliferative diabetic retinopathy (NPDR) were associated with 5-year progression to PDR.<sup>78</sup> Eyes with IRMA had an increased hazard ratio of developing PDR (hazard ratio, 1.77;  $P=0.0013$ ) compared with eyes with venous beading, and eyes with 4-quadrant dot-blot hemorrhages had higher risk for developing vitreous hemorrhage (hazard ratio, 3.84;  $P=0.0095$ ).<sup>78,79</sup> For eyes with PDR, the Diabetic Retinopathy Clinical Research Network (DRCR.net) Protocol S study found that worse baseline levels of PDR were associated with an increased risk of PDR progressing, regardless of treatment with anti-vascular endothelial growth factor (anti-VEGF) or panretinal photocoagulation (PRP) (64% [high-risk PDR or worse] vs 23% [moderate PDR or better]; hazard ratio, 3.97;  $P<0.001$ ). In the PRP group, eyes receiving pattern scan versus conventional single-spot PRP were at higher risk for worsening PDR (60% vs 39%; hazard ratio, 2.04;  $P=0.008$ ), regardless of the number of spots placed.<sup>79</sup>

## NATURAL HISTORY

Diabetic retinopathy progresses in an orderly fashion from mild to more severe stages when there is not appropriate intervention. It is important to recognize the stages when treatment may be most beneficial. Several decades of clinical research have provided excellent data on the natural course of the disease and on treatment strategies that are 90% effective in preventing the occurrence of severe vision loss.<sup>80</sup> The outcomes of key clinical trials form a solid foundation in support of treating diabetic retinopathy. The results of these studies are summarized in Appendices 3 and 4. Major studies include the following (see Glossary):

- ◆ Diabetes Control and Complications Trial (DCCT)<sup>44,81,82</sup>
- ◆ Follow-up study to the DCCT titled Epidemiology of Diabetes Interventions and Complications (EDIC)<sup>43,45,62,83,84</sup>
- ◆ Diabetic Retinopathy Study (DRS)<sup>85,86</sup>
- ◆ Early Treatment Diabetic Retinopathy Study (ETDRS)<sup>87-89</sup>
- ◆ Diabetic Retinopathy Vitrectomy Study (DRVS)<sup>90</sup>
- ◆ Wisconsin Epidemiologic Study of Diabetic Retinopathy (WESDR)<sup>91</sup>
- ◆ Fenofibrate Intervention and Event Lowering in Diabetes (FIELD) study<sup>92</sup>

- ◆ Action to Control Cardiovascular Risk in Diabetes (ACCORD) trial<sup>93</sup>
- ◆ Diabetic Retinopathy Clinical Research Network (DRCR.net) Protocol I, S, and T studies<sup>94-96</sup>
- ◆ United Kingdom Prospective Diabetes Study (UKPDS)<sup>46,58,97</sup>

The nonproliferative stages of diabetic retinopathy are characterized by retinal vascular related abnormalities such as microaneurysms, intraretinal hemorrhages, venous dilation, and cotton wool spots. Increased retinal vascular permeability that occurs at these or later stages of retinopathy may result in retinal thickening (edema) and lipid deposits (hard exudates). Clinically significant macular edema (CSME) is a term commonly used to describe retinal thickening and/or adjacent hard exudates that either involve the center of the macula or threaten to involve it. Patients with CSME should be considered for prompt treatment, particularly when the center of the macula is already involved or if retinal thickening and/or hard exudates are very close to the center (see Care Process). Clinically significant macular edema can be divided into center-involved and non-center-involved macular edema. (See Glossary.)

As diabetic retinopathy progresses, there is a gradual closure of retinal vessels that results in impaired perfusion and retinal ischemia. Signs of increasing ischemia include venous abnormalities (e.g., dilation, beading, loops), IRMA, and more severe and extensive vascular leakage characterized by increasing retinal hemorrhages and exudation. When these signs progress beyond certain defined thresholds, severe NPDR is diagnosed (see Table 1). Such patients should be considered candidates for treatment with panretinal (scatter) photocoagulation (see Care Process).

**TABLE 1 DIABETIC RETINOPATHY DISEASE SEVERITY SCALE AND INTERNATIONAL CLINICAL DIABETIC RETINOPATHY DISEASE SEVERITY SCALE**

Disease Severity Level	Findings Observable upon Dilated Ophthalmoscopy
No apparent retinopathy	No abnormalities
Mild NPDR (see Glossary)	Microaneurysms only
Moderate NPDR (see Glossary)	More than just microaneurysms but less than severe NPDR
Severe NPDR	
U.S. definition	Any of the following (4-2-1 rule) and no signs of proliferative retinopathy: <ul style="list-style-type: none"> <li>• Severe intraretinal hemorrhages and microaneurysms in each of <b>4</b> quadrants</li> <li>• Definite venous beading in <b>2</b> or more quadrants</li> <li>• Moderate IRMA in <b>1</b> or more quadrants</li> </ul>
International definition	Any of the following and no signs of proliferative retinopathy: <ul style="list-style-type: none"> <li>• More than 20 intraretinal hemorrhages in each of <b>4</b> quadrants</li> <li>• Definite venous beading in <b>2</b> or more quadrants</li> <li>• Prominent IRMA in <b>1</b> or more quadrants</li> </ul>
PDR	One or both of the following: <ul style="list-style-type: none"> <li>• Neovascularization</li> <li>• Vitreous/preretinal hemorrhage</li> </ul>

IRMA = intraretinal microvascular abnormalities; NPDR = nonproliferative diabetic retinopathy; PDR = proliferative diabetic retinopathy

NOTES:

- Any patient with two or more of the characteristics of severe NPDR is considered to have very severe NPDR.



- PDR may be classified as high-risk and non-high-risk. See Table 6 for more information.

Adapted with permission from Wilkinson CP, Ferris FL III, Klein RE, et al. Proposed international clinical diabetic retinopathy and diabetic macular edema disease severity scales. *Ophthalmology* 2003;110:1679

The more advanced stage, PDR, is characterized by the onset of neovascularization at the inner surface of the retina and into the vitreous induced by more global retinal ischemia. New vessels on or near the optic disc (NVD) and new vessels elsewhere in the retina are prone to bleed, resulting in vitreous hemorrhage. These new vessels may undergo fibrosis and contraction; this and other fibrous proliferation may result in epiretinal membrane formation, vitreoretinal traction, retinal tears, and retinal detachments. When new vessels are accompanied by vitreous hemorrhage, or when NVD occupy greater than or equal to about one-quarter to one-third disc area, even in the absence of vitreous hemorrhage, PDR is considered high-risk. (See Glossary.) Neovascular glaucoma can result from new vessels growing on the iris and anterior chamber angle structures. Patients with neovascular glaucoma or high-risk PDR should receive prompt PRP, and their treating ophthalmologist could also consider initiating anti-VEGF therapy (see Care Process and Glossary).

Table 1 classifies diabetic retinopathy by severity based on clinical findings. The ETDRS classification (Appendix 5) has clinical significance because risk of diabetic retinopathy progression is associated with increasing severity level.<sup>87,88,98,99</sup> A higher risk of incident DME in eyes with more severe levels of baseline NPDR has been reported.<sup>100,101</sup>

A study of 2240 youths (21 or younger) with type 1 diabetes and 1768 youths with type 2 diabetes evaluated the rates of diabetic retinopathy development between type 1 and type 2 diabetics.<sup>102</sup> Rates of developing diabetic retinopathy were 20.1% for type 1 and 7.2% for type 2 over a median follow-up time of 3.2 and 3.1 years, respectively. Survival curves demonstrated that type 1 patients developed diabetic retinopathy faster than type 2 youths ( $P<0.0001$ ). The hazard for diabetic retinopathy increases with increasing HbA<sub>1c</sub>.

## CARE PROCESS

The care process for diabetic retinopathy includes a medical history, a regular ophthalmologic examination or screening of high-quality retinal photographs of patients who have not had previous treatment for diabetic retinopathy or other eye disease, and regular follow-up. The purpose of an effective screening program is to determine who needs to be referred to an ophthalmologist for close follow-up and possible treatment, and who may simply be screened annually. Early detection of retinopathy depends on educating patients who have diabetes, as well as their family, friends, and health care providers, about the importance of regular eye examination even though the patient may be asymptomatic. In lay terms, patients must be informed that they may have good vision and no ocular symptoms but that they may still have significant disease that needs treatment. They should be educated that early treatment works best and that is why they need to return for an annual eye examination, even when their vision is good. Individuals with type 2 diabetes mellitus without diabetic retinopathy should be encouraged to have an annual dilated eye examination to detect the onset of diabetic retinopathy.<sup>34,40,103-120</sup> Individuals with type 1 diabetes mellitus without diabetic retinopathy should have annual dilated eye examinations beginning 5 years after the onset of diabetes.<sup>34,121</sup> The recommended timing of the first ophthalmic examination and subsequent follow-up examinations for patients with diabetes is listed in Table 2 and described in the Management section.

**TABLE 2 RECOMMENDED EYE EXAMINATIONS FOR PATIENTS WITH DIABETES MELLITUS AND NO DIABETIC RETINOPATHY**

Diabetes Type	Recommended Initial Evaluation	Recommended Follow-up*
Type 1 <sup>†</sup>	5 years after diagnosis <sup>34</sup>	Yearly <sup>34</sup>
Type 2 <sup>†</sup>	At time of diagnosis <sup>40,122</sup>	Yearly <sup>40,122</sup>
Pregnancy <sup>‡</sup> (type 1 or type 2)	Soon after conception and early in the first trimester <sup>123-125</sup>	<ul style="list-style-type: none"> <li>• No retinopathy to mild or moderate NPDR: every 3–12 months<sup>123-125</sup></li> <li>• Severe NPDR or worse: every 1–3 months<sup>123-125</sup></li> </ul>

NPDR = nonproliferative diabetic retinopathy

\* Abnormal findings may dictate frequent follow-up examinations.

<sup>†</sup> Pubertal patients require increased vigilance due to increased risk of progression

<sup>‡</sup> Women who develop gestational diabetes do not require an eye examination during pregnancy and do not appear to be at increased risk for diabetic retinopathy during pregnancy.

\*\*

Maintaining near-normal glucose levels and near-normal blood pressure lowers the risk of retinopathy developing and/or progressing,<sup>43,44,46,58,126</sup> so patients should be informed of the importance of maintaining good glycosylated hemoglobin levels, serum lipids, and blood pressure. Aspirin may be used by diabetic patients for other medical indications without concern that the aspirin therapy will worsen diabetic retinopathy or worsen a vitreous hemorrhage should it occur.<sup>127,128</sup>

## PATIENT OUTCOME CRITERIA

Patient outcome criteria include the following:

- ◆ Improvement or stabilization of visual function
- ◆ Improvement or stabilization of vision-related quality of life
- ◆ Optimal control of blood glucose, blood pressure, and other risk factors through close communication with the patient's primary care physician on the status of the diabetic retinopathy and the need for optimal metabolic control

## DIAGNOSIS

The initial examination for a patient with diabetes mellitus includes all features of the comprehensive adult medical eye evaluation,<sup>129</sup> with particular attention to those aspects relevant to diabetic retinopathy.

### History

An initial history should consider the following elements:

- ◆ Duration of diabetes<sup>34,54,130</sup>
- ◆ Past glycemic control (HbA<sub>1c</sub>)<sup>54,82,130</sup>
- ◆ Medications
- ◆ Medical history (e.g., obesity, renal disease,<sup>34,40</sup> systemic hypertension,<sup>34,40</sup> serum lipid levels,<sup>131</sup> pregnancy,<sup>123,124</sup> neuropathy)
- ◆ Ocular history (e.g., trauma, other eye diseases, ocular injections, surgery, including retinal laser treatment and refractive surgery)

### Examination

The initial examination should include the following elements:

- ◆ Visual acuity<sup>132</sup>
- ◆ Slit-lamp biomicroscopy
- ◆ Intraocular pressure (IOP)
- ◆ Gonioscopy before dilation, when indicated. Iris neovascularization is best recognized prior to dilation. When neovascularization of the iris is present or suspected, or if the IOP is elevated, undilated gonioscopy can be used to detect neovascularization in the anterior chamber angle.
- ◆ Pupillary assessment for optic nerve dysfunction
- ◆ Thorough funduscopy, including stereoscopic examination of the posterior pole<sup>89</sup>
- ◆ Examination of the peripheral retina and vitreous

A dilated pupil is preferred to ensure optimal examination of the retina, because only 50% of eyes are correctly classified for the presence and severity of retinopathy through undilated pupils.<sup>133</sup> Slit-lamp biomicroscopy is the recommended method to evaluate retinopathy in the

posterior pole and midperipheral retina with a 90D or 78D lens.<sup>89</sup> Examination of the peripheral retina is best performed using indirect ophthalmoscopy or slit-lamp biomicroscopy.

Because treatment is effective in reducing the risk of visual loss, a detailed examination is indicated to assess for the following features that often lead to visual impairment:

- ◆ Macular edema
- ◆ Signs of severe NPDR (extensive retinal hemorrhages/microaneurysms, venous beading, and IRMA)
- ◆ Optic nerve head neovascularization and/or neovascularization elsewhere
- ◆ Vitreous or preretinal hemorrhage

## Examination Schedule

### Type 1 Diabetes

Many studies of patients with type 1 diabetes have reported a direct relationship between the prevalence and severity of retinopathy and the duration of diabetes.<sup>40,134,135</sup> The development of vision-threatening retinopathy is rare in children prior to puberty.<sup>134,136</sup> Among patients with type 1 diabetes, substantial retinopathy may become apparent as early as 6 to 7 years after onset of the disease.<sup>34</sup> Ophthalmic examinations are recommended beginning 5 years after the diagnosis of type 1 diabetes and annually thereafter, which will detect the vast majority of type 1 patients who require therapy.<sup>34,121</sup> Patient education about the visual impact of early glucose control is important and should begin with the onset of disease.

### Type 2 Diabetes

The time of onset of type 2 diabetes is often difficult to determine and may precede the diagnosis by a number of years.<sup>137</sup> Up to 3% of patients whose diabetes is first diagnosed at age 30 or later will have CSME or high-risk features at the time of the initial diagnosis of diabetes.<sup>34</sup> About 30% of patients will have some manifestation of diabetic retinopathy at diagnosis. Therefore, the patient should be referred for ophthalmologic evaluation at the time of diagnosis.<sup>40,122</sup>

### Diabetes Associated with Pregnancy

Diabetic retinopathy can worsen during pregnancy due to the physiologic changes of pregnancy itself or changes in overall metabolic control.<sup>123-125</sup> Patients with diabetes who plan to become pregnant should have an ophthalmologic examination prior to pregnancy and counseled about the risk of development and/or progression of diabetic retinopathy. The obstetrician or primary care physician should carefully guide the management of the pregnant patient with diabetes' blood glucose, blood pressure, as well as other issues related to pregnancy.<sup>123-125</sup> During the first trimester, an eye examination should be performed with repeat and follow-up visits scheduled, depending on the severity of

retinopathy. (See Table 2.) Women who develop gestational diabetes<sup>138</sup> do not require an eye examination during pregnancy and do not appear to be at increased risk for diabetic retinopathy during pregnancy.

After the examination, the ophthalmologist should discuss the results and their implications with the patient. Both eyes should be classified according to the categories of diabetic retinopathy and macular edema discussed in the Natural History and Treatment sections. Each category has an inherent risk for progression and is dependent upon adherence to overall diabetes control. Thus, the diagnostic category, combined with the level of diabetes control, determines the timing for both the intervention and follow-up examination.

### **Diabetes in Puberty**

Patients with diabetes have an accelerated rate of diabetic retinopathy progression during puberty. This relative risk has been reported to be 4.8 in pubescent patients compared with their prepubescent counterparts despite similar durations of diabetes mellitus.<sup>121</sup>

## **Ancillary Tests**

If used appropriately, a number of tests ancillary to the clinical examination may enhance patient care. The most common tests include the following:

- ◆ Color and red-free fundus photography
- ◆ Optical coherence tomography (OCT)
- ◆ Fluorescein angiography (FA)
- ◆ OCT angiography<sup>139-142</sup>
- ◆ B-scan ultrasonography

### **Color Fundus Photography**

Fundus photography (with or without pupillary dilation) is a reproducible technique for detecting diabetic retinopathy and has been used in large clinical research studies. Fundus photography is also useful for documenting the severity of the diabetes, the presence of new vessels elsewhere in the retina and NVD, the response to treatment, and the need for additional treatment at future visits.

### **Optical Coherence Tomography**

Optical coherence tomography provides high-resolution imaging of the vitreoretinal interface, neurosensory retina, and subretinal space. It can be used to quantify retinal thickness, monitor macular edema, identify vitreomacular traction, and detect other forms of macular disease in patients with DME.<sup>143-148</sup> (See Table 3.) Large clinical trials testing anti-VEGF treatment have utilized OCT rather than stereoscopic photographs or clinical examination to evaluate and follow macular edema status because it allows an objective, accurate assessment of the amount and location of retinal thickening.<sup>94,149-153</sup> In clinical practice, decisions are often based on OCT findings. For example, the decision to treat with

anti-VEGF injections, change therapeutic agents (e.g., intraocular corticosteroids), initiate laser treatment, or even consider vitrectomy surgery is often based in part on OCT findings. Nevertheless, retinal thickness, even when measured by OCT, is not always consistently correlated with visual acuity.<sup>154,155</sup> Optical coherence tomography can demonstrate the microstructural changes secondary to ischemia. Loss of inner retinal layers at the fovea with high-resolution spectral-domain OCT has been shown to correlate with vision loss in eyes with diabetic macular ischemia.

**TABLE 3 USE OF OPTICAL COHERENCE TOMOGRAPHY FOR DIABETIC RETINOPATHY**

Situation	Usually	Occasionally
To evaluate unexplained visual acuity loss	●	
To detect, quantify and monitor DME	●	
To identify areas of vitreomacular traction	●	
To evaluate patients with difficult and/or questionable examinations for DME	●	
To investigate other causes of macular swelling		●
To screen a patient with no or minimal diabetic retinopathy		●

DME = diabetic macular edema

### Fluorescein Angiography

Routine FA is not indicated as a part of the regular examination of patients with diabetes. Clinical examination, OCT, and/or FA are used in the diagnosis of macular edema and PDR. As the use of anti-VEGF agents and intraocular corticosteroids has increased for the treatment of macular edema, the use of focal laser surgery has decreased. Therefore, the need for angiography that localizes leaking microaneurysms or areas of capillary dropout has also declined.

Nevertheless, FA is useful to differentiate diabetic macular swelling from other macular disease or for a patient with unexplained vision loss. (See Table 4.) Angiography can identify macular capillary nonperfusion<sup>156</sup> appearing as enlargement of the foveal avascular zone or anywhere in the macular region as an explanation for vision loss that is unresponsive to therapy. Fluorescein angiography may also detect areas of untreated retinal capillary nonperfusion that could explain persistent retinal or disc neovascularization after previous scatter laser surgery. Advances in widefield FA have shown improved detection of peripheral ischemia and peripheral lesions, including neovascularization that may not be clinically apparent.<sup>157</sup> Thus, FA remains a valuable tool, and facilities for conducting FA should be available to physicians who diagnose and treat patients with diabetic retinopathy.

**TABLE 4 USE OF FLUORESCEIN ANGIOGRAPHY FOR DIABETIC RETINOPATHY**

Situation	Usually	Occasionally	Never
To guide laser treatment of CSME	•		
To evaluate unexplained visual loss	•		
To identify suspected but clinically obscure retinal neovascularization	•		
To rule out other causes of macular swelling		•	
To identify large areas of capillary nonperfusion		•	
To evaluate patients with difficult and/or questionable examinations for DME		•	
To screen a patient with no or minimal diabetic retinopathy			•

CSME = clinically significant macular edema; DME = diabetic macular edema

An ophthalmologist who orders FA must be aware of the potential risks associated with the procedure, because severe medical complications may occur, including death in about 1/200,000 patients.<sup>158</sup> Each angiography facility should have in place an emergency care plan and a clear protocol to minimize the risks and to manage complications. Fluorescein dye crosses the placenta into the fetal circulation,<sup>159</sup> but detrimental effects of fluorescein dye on a fetus have not been documented.

### Optical Coherence Tomography Angiography

The use of OCT angiography (OCTA) has added a new perspective on our understanding of diabetic retinopathy. Although the technology is FDA approved, the guidelines and indications for use during screening and management of diabetic retinopathy are currently evolving. The major advances offered by OCTA have been its noninvasive nature and the ability to visualize depth-resolved, capillary-level abnormalities in the three retinal plexuses, offering a much more quantitative assessment of macular ischemia.<sup>139-142,160-163</sup> Even though the technology is very effective at revealing vascular abnormalities, including neovascularization on the surface of the retina and optic nerve, it is not capable of visualizing leakage, which could be construed as possible limitation, though it permits a much better unperturbed view of the underlying ischemia.<sup>164,165</sup> Using this technique preclinical microvascular changes can be detected,<sup>166</sup> regions of macular nonperfusion can be quantified, where studies have shown that nonperfusion correlates to severity of diabetic retinopathy,<sup>140,162</sup> and retinal neovascular tissue can be identified.<sup>167,168</sup> The current limitations include projection artifacts and the lack of consensus on segmentation algorithms.<sup>169,170</sup> They should also include a reduced field of view, which limits the view of peripheral retinal ischemia and neovascularization unless the clinicians use image montages.<sup>171-173</sup>

### Ultrasonography

Ultrasonography is an extremely valuable diagnostic tool that enables assessment of the status of the retina in the presence of a vitreous hemorrhage or other media opacity. It can be used to assess the amount of vitreous hemorrhage and to define the extent and severity of vitreoretinal traction and diagnose diabetic retinal detachments in the setting of media opacity.

## MANAGEMENT

Untreated diabetic retinopathy and its accompanying visual loss result in a substantial economic burden on patients, their family and society. Treatment with laser, anti-VEGF agents, or intravitreal corticosteroids is cost-effective for managing diabetic retinopathy to varying degrees.<sup>174,175</sup> Choice of laser, individual anti-VEGF agents, or approved intravitreal corticosteroids should be individually tailored based on discussion between the patient and physician.

Management of diabetic retinopathy includes following a healthy diet and lifestyle, medical management, timely ophthalmic evaluation, and treatment under the care of an ophthalmologist. Because patients with diabetes may be under the care of multiple practitioners, effective communication and care coordination is necessary to optimize care.<sup>176</sup> Physicians and patients need to be educated and informed of the need for ophthalmic referral and routine surveillance. Finally, patients need to understand that current treatments often require multiple visits and evaluations over time for adequate delivery of therapeutic effect.

### Prevention of Diabetic Retinopathy

A healthy diet and lifestyle that includes exercise and weight control may decrease the risk of developing diabetes in some patients.<sup>177,178</sup> The visual complications of diabetes mellitus can at least be moderated by a healthy lifestyle; however, diabetes complications simply cannot be prevented in all cases.

The DCCT showed that the development and progression of diabetic retinopathy in patients with type 1 diabetes can be delayed when the HbA<sub>1c</sub> is optimized.<sup>44</sup> (See Appendix 4.) Establishing a close partnership between the ophthalmologist and the primary care physician is an important step to ensure optimal patient care. Furthermore, it is important to help educate patients with diabetes as well as their primary care physician about the ophthalmologic implications of controlling blood glucose (as monitored by HbA<sub>1c</sub>) to as near normal as is safely possible. Results from multiple studies have demonstrated the value of controlling blood glucose, serum lipid levels, and blood pressure in patients with type 2 diabetes. (See Appendix 4 for further information.)

The ETDRS found that aspirin therapy at a dose of 650 mg per day does not slow the progression of diabetic retinopathy.<sup>127</sup> Also, any aspirin therapy did not cause more severe, more frequent, or longer-lasting vitreous hemorrhages in patients with PDR.<sup>128</sup> As such, aspirin appears to be neither helpful nor harmful in the management of diabetic retinopathy. Therefore,



no recommended changes in medically administered aspirin therapy are indicated in the setting of diabetic retinal disease.

## Early Detection of Diabetic Retinopathy

Diabetic retinopathy may be asymptomatic for years, even at an advanced stage, so screening, using new technologies such as telemedicine, is essential to identify, monitor, and guide the treatment of disease. When visual complications occur, treatment preserves visual function and is believed to yield a substantial cost savings when compared with the direct costs for individuals disabled by vision loss (see Socioeconomic Considerations section). According to the National Committee for Quality Assurance's Health Plan Employers Data Information Set System, national monitoring of quality data has shown a slow but definite trend toward improving rates of screening examinations.<sup>179</sup> Still, screening rates remain lower than ideal in spite of evidence supporting the effectiveness of treatment. Physicians who care for patients with diabetes, and patients themselves, need to be educated about indications for ophthalmologic referral. (See Table 5.)

**TABLE 5 INITIAL MANAGEMENT RECOMMENDATIONS FOR PATIENTS WITH DIABETES**

Severity of Retinopathy	Presence of Macular Edema	Follow-up (Months)	Panretinal Photocoagulation (Scatter) Laser	Focal and/or Grid Laser*	Intravitreal Anti-VEGF Therapy
Normal or minimal NPDR	No	12	No	No	No
Mild NPDR	No	12	No	No	No
	NCI-DME	3-6	No	Sometimes	No
	CI-DME <sup>†</sup>	1*	No	Rarely	Usually
Moderate NPDR	No	6-12 <sup>†</sup>	No	No	No
	NCI-DME	3-6	No	Sometimes	Rarely
	CI-DME <sup>†</sup>	1*	No	Rarely	Usually
Severe NPDR	No	3-4	Sometimes	No	Sometimes
	NCI-DME	2-4	Sometimes	Sometimes	Sometimes
	CI-DME <sup>†</sup>	1*	Sometimes	Rarely	Usually
Non-high-risk PDR	No	3-4	Sometimes	No	Sometimes
	NCI-DME	2-4	Sometimes	Sometimes	Sometimes
	CI-DME <sup>†</sup>	1*	Sometimes	Sometimes	Usually
High-risk PDR	No	2-4	Recommended	No	Sometimes <sup>95,188</sup>
	NCI-DME	2-4	Recommended	Sometimes	Sometimes
	CI-DME <sup>†</sup>	1*	Recommended	Sometimes	Usually

Anti-VEGF = anti-vascular endothelial growth factor; CI-DME = center-involved diabetic macular edema; NCI-DME = noncenter-involved diabetic macular edema; NPDR = nonproliferative diabetic retinopathy; PDR = proliferative diabetic retinopathy

\* Adjunctive treatments that may be considered include intravitreal corticosteroids or anti-VEGF agents (off-label use, except aflibercept and ranibizumab). Data from the Diabetic Retinopathy Clinical Research Network in 2011 demonstrated that, at 2 years of follow-up, intravitreal ranibizumab with prompt or deferred laser resulted in greater visual acuity gain and intravitreal triamcinolone acetonide plus laser also resulted in greater visual gain in pseudophakic eyes compared with laser alone.<sup>189</sup> Individuals receiving the intravitreal injections of anti-VEGF agents may be re-examined as early as 1 month following injection.

<sup>†</sup> For patients with good visual acuity (20/25 or better) and CI-DME, there is no difference between observation plus aflibercept if visual acuity decreases, focal laser plus aflibercept if visual acuity decreases,

or anti-VEGF treatment. It is appropriate to defer treatment until visual acuity is worse than 20/25.<sup>190</sup> Exceptions include hypertension or fluid retention associated with heart failure, renal failure, pregnancy, or any other causes that may aggravate macular edema. Deferral of photocoagulation for a brief period of medical treatment may be considered in these cases.<sup>191</sup> Also, deferral of NCI-DME treatment is an option if visual acuity is excellent (better than 20/32), close follow-up is possible, and the patient understands the risks.

† Or at shorter intervals if signs approaching those of severe NPDR appear.

Analyses from two clinical trials show that treatment for diabetic retinopathy may be 90% effective in preventing severe vision loss (visual acuity <5/200) using current therapeutic treatment strategies.<sup>80</sup> Although effective treatment is available, fewer patients with diabetes are referred by their primary care physicians for ophthalmic care than would be expected according to guidelines by the American Diabetes Association and the American Academy of Ophthalmology.<sup>180</sup> In two community-based studies, 43% to 65% of participants had not received a dilated eye examination at the time of enrollment.<sup>181,182</sup>

The purpose of an effective screening program for diabetic retinopathy is to determine who needs to be referred to an ophthalmologist for close follow-up and possible treatment and who may simply be screened annually. Some studies have shown that screening programs using digital retinal images taken with or without dilation may enable early detection of diabetic retinopathy along with an appropriate referral.<sup>103-113</sup> Optical coherence tomography appears to be an effective and sensitive imaging tool for detecting DME as long as there are no other causes for cystoid macular edema.<sup>147,183</sup> (*I+*, *Good quality*, *Strong recommendation*)

Studies have found a positive association between participating in a photographic screening program and subsequent adherence to receiving recommended comprehensive dilated eye examinations by a clinician.<sup>114,115</sup> Of course, such screening programs are more relevant when access to ophthalmic care is limited.<sup>116-119</sup> Screening programs should follow established guidelines.<sup>120</sup> Given the known gap in accessibility of direct ophthalmologic screening, retinal imaging screening programs may help increase the chances that at-risk individuals will be promptly referred for more detailed evaluation and management.

## Medical and Surgical Management

Management recommendations for patients with diabetes are described according to severity of the retinopathy as well as the presence and type of DME. Diabetic macular edema should be classified as either center-involved (CI-DME) or noncenter-involved DME (NCI-DME).

Follow-up recommendations and treatment options based on severity of disease are summarized in Table 5. Diabetic macular edema can be present in all stages of diabetic retinopathy.

Clinicians need to consider certain treatment interactions when deciding treatment options. For example, DME can worsen following PRP for PDR.<sup>184</sup> There have been case reports of idiosyncratic macular edema that is temporally associated with use of the glitazone class of oral antihyperglycemic agents.<sup>185,186</sup> Alternatively, the severity of diabetic retinopathy can improve in eyes receiving treatment with anti-VEGF treatment for DME.<sup>95,187</sup> Table 5 provides guidance

for managing of patients with diabetes; however, individual patient needs may vary. Table 6 summarizes the side effects and complications associated with currently available treatments.

### **Diabetic Macular Edema**

Historically, CSME is defined by the ETDRS to include any of the following features:

- ◆ Thickening of the retina at or within 500  $\mu\text{m}$  of the center of the macula
- ◆ Hard exudates at or within 500  $\mu\text{m}$  of the center of the macula, when associated with adjacent retinal thickening. (This criteria does not apply to residual hard exudates that remain after successful treatment of prior retinal thickening.)
- ◆ A zone or zones of retinal thickening 1 disc area or larger, where any portion of the thickening is within 1 disc diameter of the center of the macula

Because the risk of visual loss is greatest if macular edema is at the center of the macula DME is now subdivided as either center involved (CI-DME) or noncenter-involved (NCI-DME). OCT is the best way to detect and quantitate CI-DME and recent clinical trials have required CI-DME as inclusion criteria. A Diabetic Retinopathy Clinical Research Network (DRCR.net) study determined a reasonable clinical threshold for CI-DME was a central macular thickness 2 standard deviations above the normative study population of diabetics without macular edema.<sup>192</sup> Changes in central macular thickness measurements based on OCT is a useful marker for assessing response to treatment. Treating ophthalmologists should be familiar with relevant studies and techniques as described in the ETDRS, trials under the guidance of the DRCR.net Protocol trial,<sup>94</sup> and other studies involving anti-VEGF treatment.<sup>89,156</sup>

### ***Treatment Deferral***

Patients commonly present with good visual acuity despite the presence of CI-DME. An estimated 40% of eyes with DME in the ETDRS had visual acuity of 20/20 or better.<sup>193</sup> Studies that have demonstrated the benefit of anti-VEGF therapy for CI-DME required visual acuity loss (20/32 or worse).<sup>151,194,195</sup> DRCR Protocol V found that in eyes with CI-DME and visual acuity of 20/25 or better, there was no difference in visual acuity loss in eyes treated with aflibercept, focal laser photocoagulation with aflibercept if visual acuity decreased per criteria, or observation with aflibercept if visual acuity decreased per criteria.<sup>190</sup> The visual criteria for adding aflibercept to the laser or observation strategy were a decrease from baseline by at least 10 letters ( $\geq 2$  lines on an eye chart) at any one visit or by 5 to 9 letters (1 to 2 lines) at two consecutive visits. After 2 years, all three strategies resulted in mean visual acuity of 20/20 and the central subfield thickness on OCT did not significantly change compared with baseline. In eyes with good visual acuity and CI-DME, treatment is reasonably deferred until the visual acuity is affected (20/30 or worse). These patients should be examined every 2 to 4 months.<sup>89</sup>

### ***Anti-Vascular Endothelial Growth Factor Therapy***

Multiple, high quality clinical trials have demonstrated that anti-VEGF therapy is more effective in improving vision in CI-DME than monotherapy with focal laser treatment, supplanting it as the first-line therapy.<sup>89,94,150,156,187,189,196-201</sup> With a monthly or a protocol-driven strategy such as DRCR.net studies with anti-VEGF, eyes with vision worse than 20/32 or worse due to CI-DME gained around 2 lines of vision at 2 years compared with stabilization of vision with focal treatment alone. This was demonstrated with ranibizumab, bevacizumab, and aflibercept. A significant portion of patients in these trials (30%-46%) underwent focal laser treatment. The timing of the laser—deferred or prompt—did not affect the outcome. DRCR Protocol T, a head-to-head trial comparing bevacizumab, ranibizumab, and aflibercept, demonstrated effectiveness for all three agents with comparable safety profile in eyes with CI-DME. For eyes with visual acuity of 20/40 or better, the visual gains were similar between the three groups. In eyes with visual acuity of 20/50 or worse, mean visual acuity gains were 18.3, 13.3 and 16.1 letters for aflibercept, bevacizumab, ranibizumab, respectively at 2 years, with a statistically significant difference only found between aflibercept and bevacizumab groups. In the second year, the average number of injections decreased to about half of the number in the first year. Over 2 years, the percentage of eyes undergoing focal laser for persistent edema was 41%, 64%, and 52% for aflibercept, bevacizumab, and ranibizumab groups, respectively (all pairwise comparisons were  $P < 0.05$ ).

The DRCR protocol for CI-DME starts with monthly injections for 4 to 6 months initially, then allows for holding treatment if there is no improvement in vision or central macular thickness, or if 20/20 vision and/or resolution of macular edema has been achieved. If there is worsening vision or central macular thickness on subsequent visits, injection is resumed. If consecutive visits do not require treatment, the follow up interval is doubled up to 4 months. This approach has been demonstrated to reduce the number of injections while delivering excellent visual acuity gains.

An alternative approach to reducing the injection burden is treat-and-extend, whereby the interval between visits is adjusted based on the treatment response. A recent prospective trial showed that this approach is comparable in visual and anatomic results at 2 years to monthly dosing with fewer injections.<sup>202</sup>

The DRCR.net Protocol T demonstrated that anti-VEGF therapy using either bevacizumab, ranibizumab, or aflibercept is effective treatment for CI-DME.<sup>96</sup> The 2-year results did not reveal a statistical difference among the three drugs in serious adverse events and all three treatments provided substantial visual acuity improvement. In eyes with visual acuity of 20/40 or better, there were no visual acuity differences between treatment regimens. In eyes 20/50 or worse, aflibercept was superior to

ranibizumab and bevacizumab at year 1. However, at year 2, the mean visual acuity in the aflibercept group was superior only to the bevacizumab group.<sup>155</sup>

The visual acuity gain and reduction in macular thickness following administration of combined intravitreal ranibizumab, with prompt or deferred laser surgery, had better outcomes than laser alone after 2 years of follow-up.<sup>189</sup> Appendix 3 summarizes the results of several studies that have demonstrated the benefit of different anti-VEGF agents for CI-DME. Based on these studies, anti-VEGF therapy is the initial treatment choice for CI-DME, with possible subsequent focal laser treatment for persistent edema. The Ranibizumab for Edema of the Macula in Diabetes-2 (READ-2) study involved 126 patients randomized to either anti-VEGF therapy (in this case ranibizumab alone), laser alone, or focal/grid laser combined with anti-VEGF therapy. (See Glossary.) The group that received anti-VEGF therapy alone or with laser treatment did better than the group treated with laser alone.<sup>203</sup> The DRCR.net Protocol I also showed that anti-VEGF with either prompt or deferred laser photocoagulation surgery was better than either laser alone or laser combined with triamcinolone acetate.<sup>94</sup> (See Glossary.) Prompt laser demonstrated no additional benefit. During the 2 years of the RISE and RIDE trials, approximately 30% of patients were treated with focal laser.<sup>187</sup> In the DRCR.net Protocol I, 46% of patients were treated with laser for persistent CI-DME prior to the 3-year visit.<sup>94</sup> In this study, after 6 months of treatment, as-needed protocol was followed, and the number of injections decreased in years 2 and 3 while visual acuity remained stable. It is possible that focal laser for persistent macular edema despite anti-VEGF treatment may reduce the number of injections. The studies above used ranibizumab, whereas the Bevacizumab or Laser Treatment in the Management of Diabetic Macular Edema (BOLT) study showed favorable outcomes for bevacizumab over macular laser treatment in eyes with CI-DME.<sup>204</sup> (See Glossary.) The DME and VEGF Trap-Eye: Investigation of Clinical Impact (DA VINCI) study demonstrated better outcomes using aflibercept over laser treatment for CI-DME.<sup>195</sup> (See Glossary.) A meta-analysis provided additional evidence that both ranibizumab and aflibercept have superior efficacy for DME treatment compared with conventional laser.<sup>205</sup> (*I++*, *Good Quality, Strong Recommendation*) The YOSEMITE and RHINE studies showed that patients receiving faricimab-svoa for DME dosed at every 8 weeks demonstrated non-inferior visual acuity gains to aflibercept dosed every 8 weeks. Faricimab-svoa was approved on January 28, 2022 by the FDA. Vabysmo (faricimab-svoa), a humanized bispecific monoclonal antibody for intravitreal (IVT) use that acts through dual inhibition of both angiopoietin-2 (ANG-2) and vascular endothelial growth factor A (VEGF-A), for the treatment of patients with DME.\*

\*See: Wykoff CC, Abreu F, Adamis AP, et al. Efficacy, durability, and safety of intravitreal faricimab with extended dosing up to every 16 weeks in patients with diabetic macular oedema (YOSEMITE and RHINE): two randomized, double-masked, phase 3 trials. *Lancet*. 2022.

The most serious complication of anti-VEGF injections is infectious endophthalmitis with rates between 0.019% and 0.09% in clinical trial settings.<sup>206</sup> The use of topical povidone iodine is recommended for intravitreal injections as its non-use has been reported to have an unacceptably high risk of endophthalmitis. The use of routine antibiotic eye drops is not recommended before or following intravitreal injection procedures, because it does not decrease the risk of endophthalmitis.<sup>207</sup> Other complications, such as cataract formation, and sustained elevated IOP are rare.<sup>208-210</sup> Individuals receiving the intravitreal injections of anti-VEGF agents may be examined at 1 month following therapy (See Table 5). Systematic adverse events, particularly thromboembolic events, have been considered a potential side effect of anti-VEGF treatment. An additional meta-analysis suggests there may be a modest increased risk of death and cerebrovascular events in patients receiving monthly therapy for two years.<sup>211</sup> (See Table 7.). However, a 2018 Cochrane systematic review has reported that there is “moderate certainty evidence” of safety of anti-VEGF injections and as of 2019 no studies have shown a definite increased risk.<sup>212</sup> (*I+, Moderate quality, Strong recommendation*)

### ***Laser Photocoagulation***

The ETDRS demonstrated that focal laser photocoagulation reduces the risk of moderate vision loss in eyes with CSME.<sup>85,213,214</sup> The DRCR.net Protocols B and I demonstrated a beneficial treatment effect of focal laser treatment for CI-DME. The role of anti-VEGF in NCI-DME has not been studied, and the focal/grid laser treatment option is recommended in this scenario. A modified ETDRS laser treatment is currently recommended; it includes a less intense laser treatment, has greater spacing than for a grid, directly targets microaneurysms, and avoids foveal vasculature within at least 500  $\mu\text{m}$  of the center of the macula.<sup>215</sup> A recent Cochrane systematic review concluded that laser photocoagulation reduces the changes of visual loss and increases those of partial to complete resolution of DME compared to no intervention at 1-3 years.<sup>216</sup> (*I, Moderate quality, Strong recommendation*) Preoperatively, the ophthalmologist should discuss with the patient the side effects and risks of treatment.<sup>89,156</sup> Fluorescein angiography prior to laser surgery for CSME can be helpful for identifying leaking microaneurysms in areas of thickened retina. Fluorescein angiography is also useful for detecting capillary dropout and pathologic enlargement of the foveal avascular zone, information that may be useful when planning focal laser treatment.<sup>89</sup> Optical coherence tomography angiography can detect capillary drop out and enlarged an foveal avascular zone; however, it does not reveal leakage. A posttreatment evaluation should be scheduled within 3 to 4 months of laser surgery.<sup>89</sup> Rarely, focal laser photocoagulation surgery may induce subretinal fibrosis with choroidal neovascularization, a complication that may be associated with permanent central vision loss.<sup>217-219</sup> Other than choroidal neovascularization, the most important factor associated with the development of subretinal fibrosis includes both the more severe levels of subretinal hard exudates and elevated serum lipids prior to laser photocoagulation surgery.<sup>220</sup>

### ***Steroids for Diabetic Macular Edema***

Several studies have evaluated the use of intravitreal administration of short- and long-acting corticosteroids for the treatment of DME. Topical corticosteroids and periocular steroid injection demonstrated no significant benefit.<sup>221</sup> The role of intravitreal triamcinolone acetonide was compared with focal laser photocoagulation surgery.

retinal thickness at 4 months, yet by 24 months those patients randomized to focal/grid laser photocoagulation surgery had better mean visual acuity. Of the triamcinolone group, half of phakic eyes underwent cataract surgery within 2 years and about 30% of eyes developed elevated IOP above 10 mm Hg compared with baseline.<sup>222</sup> At 3 years, these results were largely unchanged.<sup>223</sup> A subsequent study showed that pseudophakic eyes treated with the combination of the intravitreal triamcinolone acetonide and focal laser had visual gains similar to eyes treated with anti-VEGF agents.<sup>224</sup> The sustained-release dexamethasone implant for treatment naïve CI-DME improved visual acuity compared with sham treatment. In this study, the mean number of treatments was four to five injections over 3 years' time.<sup>225</sup> The fluocinolone acetonide implant for DME treatment study revealed improved visual acuity relative to sham at 3 years. At three years, 75% of patients were treated with only one implant. Rates of cataract extraction of phakic eyes was 74.9% with an implant versus 23.1% for sham. Rates of incisional glaucoma surgery were 3.7% versus 0.5% for sham at 2 years.<sup>226</sup>

The DRCR.net phase II, randomized clinical trial evaluated the role of combination anti-VEGF treatment with intravitreal dexamethasone in a sustained-release drug delivery system to eyes with persistent CI-DME after at least three anti-VEGF injections in the previous 20 weeks.<sup>227</sup> The addition of the dexamethasone implant reduced central macular thickness; however there was no benefit in visual acuity. Pseudophakic eyes improved by 3 letters, but there was insufficient power to be confident of this effect.

A Cochrane systematic review concluded that a combination of steroid with anti-VEGF did not provide additional benefit to anti-VEGF monotherapy.<sup>228</sup> (*I, Moderate quality, Strong recommendation*) However, the evidence base for this conclusion was rated as low-certainty given the relative paucity of studies with long-term follow-up.<sup>228</sup> Multiple studies consistently found that corticosteroids carry higher risk for cataract and elevated IOP compared with anti-VEGF therapy (See Table 6).<sup>189,197</sup>

Studies of intravitreal corticosteroids for DME have evaluated them as first-line agents only. Because of their side-effect profile, including cataract progression and elevated IOP, they are generally used as second-line agents for DME, especially for phakic patients. To date, no large randomized clinical trial has evaluated the use of intravitreal corticosteroid injection as a rescue treatment for eyes with persistent DME after anti-VEGF injection therapy.

### ***Other Treatments***

When substantial vitreomacular traction is present, pars plana vitrectomy may improve visual acuity in selected patients who have diffuse CSME that is unresponsive to previous macular laser photocoagulation surgery and/or anti-VEGF therapy.<sup>229-231</sup> The



DRCR.net Protocol D found that 38% of eyes with DME and vitreomacular traction had improved visual acuity, whereas 22% of eyes experienced visual acuity loss. However, the value of vitrectomy in CSME is difficult to study in a randomized clinical trial, as there are many variables that affect visual acuity. (See DRCR.net Protocol D.<sup>232</sup>) Because the majority of studies evaluating vitrectomy for DME precede the use of anti-VEGF treatment, it is difficult to determine the role of vitrectomy with concomitant anti-VEGF treatment.

Some authors have suggested that micropulse laser induces less damage to the macula.<sup>233</sup> A recent meta-analysis found no difference in visual acuity with conventional laser photocoagulation surgery compared with subthreshold diode micropulse laser photocoagulation surgery.<sup>234</sup>

A Cochrane systematic review did not find any randomized controlled clinical trials evaluating use of NSAIDS for DME.<sup>235</sup>

**TABLE 6** SIDE EFFECTS AND COMPLICATIONS OF TREATMENT FOR DIABETIC RETINOPATHY

Treatment	Side Effect/Complication
Focal laser photocoagulation surgery for DME	<ul style="list-style-type: none"> <li>• Possible transient initial decrease in central vision</li> <li>• Paracentral scotomas if laser burns have been placed close to the fovea, especially large or confluent burns<sup>236</sup></li> <li>• Permanent central scotoma from inadvertent foveal burns</li> <li>• Expansion of laser scar area (over many years)</li> <li>• Choroidal neovascularization and subretinal fibrosis</li> </ul>
Panretinal photocoagulation (scatter) for severe NPDR or PDR	<ul style="list-style-type: none"> <li>• Transient central vision loss from macular edema<sup>32</sup></li> <li>• Peripheral visual field constriction with delayed dark adaptation</li> <li>• Vitreous hemorrhage if neovascularization is present</li> <li>• Reduced or compromised accommodation<sup>237</sup></li> <li>• Pupillary dilation (mydriasis)</li> </ul>
Vitrectomy	<ul style="list-style-type: none"> <li>• Vitreous hemorrhage<sup>238,239</sup></li> <li>• Retinal tear or detachment<sup>240</sup></li> <li>• Vision loss<sup>240,241</sup></li> <li>• Infectious endophthalmitis<sup>242</sup></li> <li>• Cataract<sup>243</sup></li> </ul>
Intravitreal injections	<ul style="list-style-type: none"> <li>• Ocular hemorrhage</li> <li>• Elevated IOP (i.e., corticosteroids)<sup>244,245</sup></li> <li>• Infectious endophthalmitis</li> <li>• Noninfectious inflammatory reactions</li> <li>• Possible systemic effect from intravitreal medication<sup>211</sup></li> <li>• Increased retinal traction</li> <li>• Cataract<sup>244,245</sup></li> </ul>

DME = diabetic macular edema; IOP = intraocular pressure; NPDR = nonproliferative diabetic retinopathy; PDR = proliferative diabetic retinopathy

## Treatment and Prevention of Proliferative Diabetic Retinopathy

### *Normal or Minimal NPDR*

The patient with a normal retinal examination or with rare microaneurysms should be re-examined annually,<sup>34</sup> because within 1 year 5% to 10% of patients without retinopathy will develop diabetic retinopathy. Existing retinopathy will worsen by a similar percentage.<sup>65,66,81</sup>

### *Mild to Moderate NPDR without Macular Edema*

Patients with retinal microaneurysms and occasional blot hemorrhages or hard exudates should be re-examined within 6 to 12 months, because disease progression is common.<sup>65</sup> In The Wisconsin Epidemiologic Study of Diabetic Retinopathy, the natural history of type 1 diabetic patients suggests that approximately 16% of patients with mild retinopathy (hard exudates and microaneurysms only) will progress to proliferative stages within 4 years.<sup>65</sup>

For patients with mild NPDR, the 4-year incidence of either CSME or macular edema that is not clinically significant is approximately 12%. For moderate NPDR, the risk increases to 23% for patients with either type 1 or 2 diabetes.<sup>132</sup> For patients undergoing anti-VEGF treatment, the clinically observed level of retinopathy may become consistent with mild to moderate retinopathy. Especially when anti-VEGF treatment is stopped because edema is well controlled, and the patient had previously been noted to have a higher level of retinopathy, a closer follow-up of retinopathy may be necessary, as the progression of disease may be higher in those patients.

### ***Severe NPDR and Non-High-Risk PDR***

The DRS demonstrated that eyes with severe NPDR and non-high-risk PDR had a reduced risk of severe vision loss with PRP but suggested that a deferral of photocoagulation is reasonable until high-risk characteristics develop.<sup>246</sup> The ETDRS showed that although deferral of PRP until high-risk characteristics develop, especially in eyes with DME, early PRP could be considered, especially for eyes with very severe NPDR and non-high risk PDR, who have close to a 50% risk of progressing to high-risk PDR within 1 year. Very severe NPDR is defined as an eye with 2 or more of the 4-2-1 characteristics summarized in Table 1.

Severe NPDR and non-high-risk PDR are discussed together because ETDRS data showed that they have a similar clinical course and subsequent recommendations for treatment are similar. The study demonstrated that the risk of progression to proliferative disease was high, with 45% of patients with very severe NPDR, 46% of patients with moderate PDR, 22% of patients with mild PDR, and 15% of patients with severe NPDR developing PDR within 1 year.<sup>132</sup> Therefore, these patients should be re-examined within 2 to 4 months.<sup>1,132</sup> Refer to Table 1 for the definition of severe NPDR and very severe NPDR.

### ***High-Risk PDR***

The presence of any three of the following four features characterizes DRS high-risk PDR.<sup>85,86</sup>

- ◆ Neovascularization (at any location)
- ◆ Neovascularization at or near the optic disc (see standard photograph 10A in Glossary)
- ◆ At least moderate neovascularization, defined as:
  - New vessels within 1 disc diameter of the optic nerve head that are larger than one-quarter to one-third disc area in size
  - New vessels elsewhere that are at least one-half disc area in size

- Vitreous or preretinal hemorrhage

The DRS showed that the risk of severe visual loss among patients with high-risk PDR is high and is reduced substantially by PRP. (See Glossary) Most patients with high-risk PDR should receive PRP expeditiously, as it usually induces regression of retinal neovascularization.<sup>85,247</sup>

The DRCR.net study Protocol S that examined patients with PDR primarily has demonstrated that a series of anti-VEGF injections (ranibizumab was used in this protocol) is noninferior to PRP at 2 years.<sup>95</sup> The patients undergoing anti-VEGF injections were less likely to have worsening macular edema or to have peripheral vision loss as measured by automated visual field testing compared with the PRP group. However, when patients with PDR undergoing anti-VEGF injections are lost to follow up, their visual and anatomic outcomes are inferior to those who received PRP.<sup>248</sup> Therefore, the decision to choose anti-VEGF over PRP must be made cautiously with a careful consideration of patient-related factors. The anti-VEGF injection alone could be considered for patients with reliable follow-up.

Additional PRP or anti-VEGF therapy should be considered in situations involving the following:

- ◆ Failure of the neovascularization to regress
- ◆ Increasing neovascularization of the retina or iris
- ◆ New vitreous hemorrhage
- ◆ New areas of neovascularization

In cases of involutinal PDR, vitreous hemorrhage may occur due to vitreous traction on involuted neovascularization. These eyes may not necessarily require additional PRP, especially in the absence of venous dilation. Pars plana vitrectomy should be considered for patients with PDR and vitreous opacities interfering with vision or treatment, severe fibrovascular proliferation, and traction retinal detachment that is threatening or involving the macula.<sup>90,249-251</sup> The value of early pars plana vitrectomy increases with the increasing severity of neovascularization. (See Appendix 3.) The role of anti-VEGFs in these later stages of proliferative retinopathy is under investigation.

### ***Laser Treatment***

Panretinal photocoagulation has been demonstrated to reduce the risk of severe vision loss in PDR and severe NPDR. The ETDRS protocol for full PRP included 1200 to 1600 spots of moderate burns of 0.1 second duration that is a one-half burn width apart and at least 2 disc diameters from the fovea out to the equator.<sup>132</sup> If laser surgery is elected, full PRP is a proven treatment approach. Partial or limited PRP treatment is not

recommended.<sup>85</sup> Fluorescein angiography does not usually need to be performed to apply the PRP effectively.

Additional analyses of visual outcome in ETDRS patients with severe NPDR to non-high-risk PDR suggest that the recommendation to consider PRP before the development of high-risk PDR is particularly appropriate for patients with type 2 diabetes. The risk of severe vision loss or vitrectomy was reduced by 50% (2.5% vs. 5%;  $P=0.0001$ ) in patients with type 2 diabetes who were treated early when compared with deferral PRP until high-risk PDR developed.<sup>1</sup> For patients with type 1 diabetes, the timing of the PRP depends on the patient's compliance with follow-up and the status and response to treatment of the fellow eye. For both patients with type 1 and type 2 diabetes, impending or recent cataract surgery or pregnancy may increase the risk of progression and may influence the decision to perform PRP.

The goal of PRP is to reduce the risk of vision loss. Preoperatively, the ophthalmologist should assess for the presence of macular edema, discuss side effects of treatment and risks of visual loss with the patient, and obtain informed consent.<sup>213,214</sup> This technique has been fully described<sup>85,213</sup> and the results are summarized in Appendix 3.

The results of clinical trials suggest that PRP is to be performed on eyes with CSME; focal photocoagulation and/or anti-VEGF therapy prior to or concomitant with PRP should be performed when there is evidence that PRP may exacerbate macular edema and increase the rate of moderate visual loss (i.e., doubling of the visual angle) compared with untreated control eyes.<sup>132</sup> (See Glossary.) However, PRP should not be delayed when PDR is at the high-risk stage (i.e., if NVD is extensive or vitreous/preretinal hemorrhage has occurred recently). In such cases, anti-VEGF therapy and PRP may be performed concomitantly. For patients who have concurrent CI-DME, combined anti-VEGF therapy and PRP at the first treatment session should be considered (Table 6).

### ***Anti-Vascular Endothelial Growth Factor Therapy***

The DRCR.net Protocol S was a randomized controlled trial that compared PRP with ranibizumab in patients primarily with PDR with and without DME, and approximately 11% had mild to severe NPDR.<sup>252</sup> The patients received ranibizumab monthly for 6 months, unless complete neovascular regression was obtained at 4 months, followed by treatment as needed based on a specific protocol for evaluating the presence and/or activity of retinal neovascularization.<sup>253</sup> The study concluded that ranibizumab resulted in not more than 5 letters worse visual acuity than PRP at 2 years. The ranibizumab group seemed to have better average visual acuity, less visual field loss, fewer vitrectomies, and fewer new developments of DME-related vision loss. However, the ranibizumab group had a higher number of treatments and visits than the group

receiving PRP.<sup>254</sup> Patient compliance is a major concern for management of patients with PDR. An additional study demonstrated that aflibercept is similar to PRP for treatment of PDR and may have superior visual acuity outcomes in eyes without CI-DME at 1 year.<sup>255</sup> A follow-up of patients from the RIDE and RISE studies found that more patients receiving ranibizumab treatment had a 2-step or 3-step or more improvement in diabetic retinopathy compared with the sham crossover group at a median level of moderate NPDR. (See Glossary.)<sup>256</sup> It is not yet known whether anti-VEGF treatment would benefit patients with severe NPDR for whom PRP is considered.

A key clinical consideration for determining the use of anti-VEGF versus PRP is the reliability of patient follow-up. A recent analysis found that over a 4-year period, 22% of patients with PDR under treatment with anti-VEGF injections were lost to follow-up.<sup>248</sup> Further studies are required to determine the long-term implications of using anti-VEGF agents alone.<sup>188</sup> Recent reports raise into question the implications of using anti-VEGF therapy in PDR patients and the severe consequences of such a decision and a higher rate of NVG.<sup>257</sup> The clinical indications for use in patients with moderate or mild NPDR are unknown and also depend on other factors such as systemic blood glucose control and compliance with follow-up examinations. Clinical judgment is important for guiding therapy.

Although some studies have reported evidence for the beneficial use of anti-VEGF for treating vitreous hemorrhage,<sup>258</sup> a DRCR trial found no difference between anti-VEGF and intravitreal saline injection.<sup>259</sup> Following anti-VEGF injection, cases with severe PDR may develop traction or pre-existing traction may progress.<sup>260</sup> However, Protocol S showed that there was no statistically significant difference between rates of tractional retinal detachment in PRP compared with anti-VEGF.<sup>254</sup>

Several anti-VEGF studies have also found a significant difference in the rates of 2-step and 3-step improvements in severity of diabetic retinopathy between eyes receiving anti-VEGF and control eyes. The DRCR.net has shown that in the short-term, anti-VEGF treatment lowers the risk of progression to PDR.<sup>261,262</sup> In the DRCR.net Protocol T year 1, of the 423 NPDR eyes, 44 of 141 (31.2%) treated with aflibercept, 29 of 131 (22.1%) with bevacizumab, and 57 of 151 (37.7%) with ranibizumab had improvement of diabetic retinopathy severity. The adjusted difference for aflibercept versus bevacizumab was 11.7% (95% CI, 2.9%–20.6%;  $P=0.004$ ), for ranibizumab versus bevacizumab was 8.9% (95% CI, 1.7%–16.1%;  $P=0.01$ ), and for aflibercept versus ranibizumab was 2.9% (95% CI, -5.7% to 11.4%;  $P=0.51$ ). At year 2, despite fewer injections of an anti-VEGF drug given to these eyes, 25% of the aflibercept group, 22% of the bevacizumab group, and 21% of the ranibizumab group showed diabetic

retinopathy improvement. Rates of worsening retinopathy were uniformly low for all three drugs.

In the RIDE and RISE trials, approximately 11% of ranibizumab-treated eyes showed progression of diabetic retinopathy compared with 34% of sham-treated eyes at 2 years.<sup>263</sup> The percentage of eyes with worsening diabetic retinopathy by 2 steps or more (Table 5) was significantly greater for the sham-treated eyes than the ranibizumab-treated eyes. Post hoc analysis of RIDE and RISE trials revealed that ranibizumab treatment improved diabetic retinopathy severity in all subsets. The greatest improvement occurred in eyes with a baseline of moderately severe to severe NPDR.<sup>264</sup>

In the VIVID and VISTA trials, eyes treated with aflibercept (every 4 or 8 weeks) for DME had a significantly higher chance of a 2-step (Table 5) improvement in the Diabetic Retinopathy Severity Scale score compared with eyes treated with laser control. (See Glossary). In the VIVID trial, the improvement was 29.3% and 32.6%, respectively, versus 8.2% ( $P < 0.0004$  for every 4 weeks and  $P < 0.0001$  for every 8 weeks), and in the VISTA trial, the improvement was 37.0% and 37.1%, respectively, versus 15.6% ( $P < 0.0001$  for both aflibercept vs control comparisons).<sup>265</sup>

### ***Other Treatments***

Vitrectomy surgery typically is reserved for cases with persistent disease activity despite medical management with anti-VEGF or PRP, or if disease is unamenable to medical management alone. Typical indications for vitrectomy include:

- Nonclearing vitreous hemorrhage
- Tractional retinal detachment threatening the macula
- Combined rhegmatogenous and tractional retinal detachment
- Dense pre-macular subhyaloid hemorrhage

The DRVS demonstrated improved outcomes if vitrectomy for vitreous hemorrhage is done within 1 to 6 months of onset compared with later vitrectomy at 1 year.<sup>266,267</sup> Vitreous hemorrhage should be followed with serial ultrasounds to evaluate for possible retinal tear, tractional retinal detachment that threatens the macula, or rhegmatogenous retinal detachment. Recent advances, including endolaser and small-gauge instruments have improved outcomes and decreased adverse events.<sup>268</sup> One meta-analysis suggested that pre-operative anti-VEGF treatment reduces the duration of surgery, the number of retinal breaks, and the amount of intra-operative bleeding.<sup>269</sup> (*I+*, *Moderate quality*, *Strong recommendation*) A Cochrane systematic review suggested pre-operative or intra-operative bevacizumab may reduce the incidence of post-operative vitreous hemorrhage.<sup>270,271</sup> (*I+*, *Moderate quality*, *Strong recommendation*)

## Follow-Up Evaluation

The follow-up evaluation includes a history and examination.

### History

A follow-up history should include changes in the following:

- ◆ Symptoms
- ◆ Systemic status (pregnancy, blood pressure, serum lipids, renal status)
- ◆ Glycemic status (HbA<sub>1c</sub>)<sup>54,82,130</sup>
- ◆ Other treatments such as dialysis and fenofibrates

### Examination

A follow-up examination should include the following elements:

- ◆ Visual acuity<sup>132</sup>
- ◆ Slit-lamp biomicroscopy with iris examination<sup>272</sup>
- ◆ IOP
- ◆ Gonioscopy (preferably before dilation when iris neovascularization is suspected or if IOP is elevated)<sup>272</sup>
- ◆ Stereoscopic examination of the posterior pole after dilation of the pupils<sup>89</sup>
- ◆ OCT imaging, when appropriate
- ◆ Peripheral retina and vitreous examination, when indicated<sup>88</sup>

Recommended intervals for follow-up are given in Table 5.

## PROVIDER AND SETTING

Although the ophthalmologist will perform most of the examination and all surgery, certain aspects of examination may be performed by trained individuals under the ophthalmologist's supervision and review. Because of the complexities of the diagnosis and treatment for diabetic retinopathy, the ophthalmologist caring for patients with this condition should be familiar with the specific recommendations of relevant clinical trials.<sup>45,94,131,132,151,195,203,204,214,246,273-279</sup>

## COUNSELING AND REFERRAL

The ophthalmologist should refer patients with diabetes to a primary care physician for appropriate management of their systemic condition and should communicate examination results to the physician managing the patient's ongoing diabetes care. An Eye MD Examination Report Form is available from the American Academy of Ophthalmology.<sup>280</sup>

Some patients with diabetic retinopathy will lose substantial vision despite being treated according to the recommendations in this document.<sup>1</sup> Patients whose conditions fail to respond to surgery and those for whom further treatment is unavailable should be provided with professional support and offered referral for counseling, vision rehabilitation, or social services as appropriate.<sup>281</sup> Vision



rehabilitation improves functional ability,<sup>282</sup> and so patients with functionally limiting postoperative visual impairment should be referred for vision rehabilitation and social services.<sup>281</sup> More information on vision rehabilitation, including materials for patients, is available at [www.aao.org/low-vision-and-vision-rehab](http://www.aao.org/low-vision-and-vision-rehab).

## SOCIOECONOMIC CONSIDERATIONS

In the era before anti-VEGF treatment, an analysis of medical and economic effects of diabetic retinopathy control predicted that over their lifetime, 72% of patients with type 1 diabetes would eventually develop PDR requiring PRP and that 42% would develop macular edema.<sup>283</sup> If treatments are delivered as recommended in the clinical trials, the model predicted a cost of \$966 per person-year of vision saved for patients with PDR and \$1,120 per person-year of central visual acuity saved for patients with macular edema. These costs are less than the cost of a year of Social Security disability payments for patients disabled by vision loss. Therefore, treatment yields a substantial savings compared with the direct cost to society of untreated PDR in a type 1 diabetic patient.<sup>284</sup> The indirect costs in lost productivity and human suffering are even greater.

Another analysis estimated that screening and treatment of eye disease in patients with diabetes costs, on average, \$3,190 per quality-adjusted life year (QALY) saved.<sup>285</sup> For patients with type 1 diabetes, it costs \$1996 per QALY saved; for patients with type 2 diabetes who use insulin, it costs \$2,933 per QALY saved; and for patients with type 2 diabetes who do not use insulin, it costs \$3,530 per QALY saved. Insofar as patients with type 2 diabetes not using insulin represent the largest subset of the patient population, most of the economic benefits of screening and treatment are realized among these patients.

A 2013 cost-effectiveness analysis of various interventions for DME evaluated the cost-effectiveness of anti-VEGF therapies for CSME. Compared with laser alone, the incremental cost-effectiveness of laser plus bevacizumab is \$11,138 per QALY and thus seems to confer the greatest value among the various treatment options for CSME.<sup>286</sup> By comparison, the cost-utility of laser photocoagulation surgery for DME is \$3,101 per QALY,<sup>287</sup> whereas laser photocoagulation surgery for extrafoveal choroidal neovascularization is \$23,640 per QALY.<sup>288</sup> <sup>174</sup> Finally, a cost-utility analysis of detection and treatment of diabetic retinopathy in patients with type 1 and type 2 diabetes demonstrates that provision of recommended ophthalmic care would reduce the prevalence of blindness by 52% and that the direct costs of care would be less than the losses in productivity and the costs of facilities provided for disability.<sup>289</sup>

# APPENDIX 1. QUALITY OF OPHTHALMIC CARE CORE CRITERIA

*Providing quality care  
is the physician's foremost ethical obligation, and is  
the basis of public trust in physicians.  
AMA Board of Trustees, 1986*

Quality ophthalmic care is provided in a manner and with the skill that is consistent with the best interests of the patient. The discussion that follows characterizes the core elements of such care.

The ophthalmologist is first and foremost a physician. As such, the ophthalmologist demonstrates compassion and concern for the individual, and utilizes the science and art of medicine to help alleviate patient fear and suffering. The ophthalmologist strives to develop and maintain clinical skills at the highest feasible level, consistent with the needs of patients, through training and continuing education. The ophthalmologist evaluates those skills and medical knowledge in relation to the needs of the patient and responds accordingly. The ophthalmologist also ensures that needy patients receive necessary care directly or through referral to appropriate persons and facilities that will provide such care, and he or she supports activities that promote health and prevent disease and disability.

The ophthalmologist recognizes that disease places patients in a disadvantaged, dependent state. The ophthalmologist respects the dignity and integrity of his or her patients, and does not exploit their vulnerability.

Quality ophthalmic care has the following optimal attributes, among others.

- ◆ The essence of quality care is a meaningful partnership relationship between patient and physician. The ophthalmologist strives to communicate effectively with his or her patients, listening carefully to their needs and concerns. In turn, the ophthalmologist educates his or her patients about the nature and prognosis of their condition and about proper and appropriate therapeutic modalities. This is to ensure their meaningful participation (appropriate to their unique physical, intellectual, and emotional state) in decisions affecting their management and care, to improve their motivation and compliance with the agreed plan of treatment, and to help alleviate their fears and concerns.
- ◆ The ophthalmologist uses his or her best judgment in choosing and timing appropriate diagnostic and therapeutic modalities as well as the frequency of evaluation and follow-up, with due regard to the urgency and nature of the patient's condition and unique needs and desires.
- ◆ The ophthalmologist carries out only those procedures for which he or she is adequately trained, experienced, and competent, or, when necessary, is assisted by someone who is, depending on the urgency of the problem and availability and accessibility of alternative providers.
- ◆ Patients are assured access to, and continuity of, needed and appropriate ophthalmic care, which can be described as follows.
  - ◆ The ophthalmologist treats patients with due regard to timeliness, appropriateness, and his or her own ability to provide such care.
  - ◆ The operating ophthalmologist makes adequate provision for appropriate pre- and postoperative patient care.
  - ◆ When the ophthalmologist is unavailable for his or her patient, he or she provides appropriate alternate ophthalmic care, with adequate mechanisms for informing patients of the existence of such care and procedures for obtaining it.
  - ◆ The ophthalmologist refers patients to other ophthalmologists and eye care providers based on the timeliness and appropriateness of such referral, the patient's needs, the competence and qualifications of the person to whom the referral is made, and access and availability.

- ◆ The ophthalmologist seeks appropriate consultation with due regard to the nature of the ocular or other medical or surgical problem. Consultants are suggested for their skill, competence, and accessibility. They receive as complete and accurate an accounting of the problem as necessary to provide efficient and effective advice or intervention, and in turn they respond in an adequate and timely manner. The ophthalmologist maintains complete and accurate medical records.
- ◆ On appropriate request, the ophthalmologist provides a full and accurate rendering of the patient's records in his or her possession.
- ◆ The ophthalmologist reviews the results of consultations and laboratory tests in a timely and effective manner and takes appropriate actions.
- ◆ The ophthalmologist and those who assist in providing care identify themselves and their profession.
- ◆ For patients whose conditions fail to respond to treatment and for whom further treatment is unavailable, the ophthalmologist provides proper professional support, counseling, rehabilitative and social services, and referral as appropriate and accessible.
- ◆ Prior to therapeutic or invasive diagnostic procedures, the ophthalmologist becomes appropriately conversant with the patient's condition by collecting pertinent historical information and performing relevant preoperative examinations. Additionally, he or she enables the patient to reach a fully informed decision by providing an accurate and truthful explanation of the diagnosis; the nature, purpose, risks, benefits, and probability of success of the proposed treatment and of alternative treatment; and the risks and benefits of no treatment.
- ◆ The ophthalmologist adopts new technology (e.g., drugs, devices, surgical techniques) in judicious fashion, appropriate to the cost and potential benefit relative to existing alternatives and to its demonstrated safety and efficacy.
- ◆ The ophthalmologist enhances the quality of care he or she provides by periodically reviewing and assessing his or her personal performance in relation to established standards, and by revising or altering his or her practices and techniques appropriately.
- ◆ The ophthalmologist improves ophthalmic care by communicating to colleagues, through appropriate professional channels, knowledge gained through clinical research and practice. This includes alerting colleagues of instances of unusual or unexpected rates of complications and problems related to new drugs, devices, or procedures.
- ◆ The ophthalmologist provides care in suitably staffed and equipped facilities adequate to deal with potential ocular and systemic complications requiring immediate attention.
- ◆ The ophthalmologist also provides ophthalmic care in a manner that is cost effective without unacceptably compromising accepted standards of quality.

Reviewed by: Council  
Approved by: Board of Trustees  
October 12, 1988

2<sup>nd</sup> Printing: January 1991

3<sup>rd</sup> Printing: August 2001

4<sup>th</sup> Printing: July 2005

## APPENDIX 2. INTERNATIONAL STATISTICAL CLASSIFICATION OF DISEASES AND RELATED HEALTH PROBLEMS (ICD) CODES

Diabetic retinopathy, which includes entities with the following ICD-9 and ICD-10 classifications (see Glossary):

	ICD-9 CM	ICD-10 CM
Diabetic retinopathy:		
Background	362.01	<ul style="list-style-type: none"> <li>• E10.311 Type 1 with macular edema</li> <li>• E10.319 Type 1 without macular edema</li> <li>• E11.311 Type 2 with macular edema</li> <li>• E11.319 Type 2 without macular edema</li> <li>• E13.311 other specified types of diabetes mellitus with unspecified diabetic retinopathy with macular edema</li> <li>• E13.319 other specified types of diabetes mellitus with unspecified diabetic retinopathy without macular edema</li> </ul>
Proliferative	362.02	<ul style="list-style-type: none"> <li>• E10.351 Type 1 with macular edema</li> <li>• E10.359 Type 1 without macular edema</li> <li>• E11.351 Type 2 with macular edema</li> <li>• E11.359 Type 2 without macular edema</li> <li>• E13.351 other specified diabetes mellitus with proliferative diabetic retinopathy with macular edema</li> <li>• E13.359 other specified diabetes mellitus with proliferative diabetic retinopathy without macular edema</li> </ul>
Nonproliferative, NOS	362.03	<ul style="list-style-type: none"> <li>• E10.321 Type 1 with macular edema</li> <li>• E10.329 Type 1 without macular edema</li> <li>• E11.321 Type 2 with macular edema</li> <li>• E11.329 Type 2 without macular edema</li> <li>• E13.321 other specified types of diabetes mellitus with mild nonproliferative diabetic retinopathy with macular edema</li> <li>• E13.329 other specified types of diabetes mellitus with mild nonproliferative diabetic retinopathy without macular edema</li> </ul>
Nonproliferative, mild	362.04	
Nonproliferative, moderate	362.05	<ul style="list-style-type: none"> <li>• E10.331 Type 1 with macular edema</li> <li>• E10.339 Type 1 without macular edema</li> <li>• E11.331 Type 2 with macular edema</li> <li>• E11.339 Type 2 without macular edema</li> <li>• E13.331 other specified types of diabetes mellitus with moderate nonproliferative diabetic retinopathy with macular edema</li> <li>• E13.339 other specified types of diabetes mellitus with moderate nonproliferative diabetic retinopathy without macular edema</li> </ul>

	ICD-9 CM	ICD-10 CM
Diabetic retinopathy (continued):		
Nonproliferative, severe	362.06	<ul style="list-style-type: none"> <li>• E10.341 Type 1 with macular edema</li> <li>• E10.349 Type 1 without macular edema</li> <li>• E11.341 Type 2 with macular edema</li> <li>• E11.349 Type 2 without macular edema</li> <li>• E13.341 other specified types of diabetes mellitus with severe nonproliferative diabetic retinopathy with macular edema</li> <li>• E13.349 other specified types of diabetes mellitus with severe nonproliferative diabetic retinopathy without macular edema</li> </ul>
Diabetic macular edema	362.07	<ul style="list-style-type: none"> <li>• E10.321 Type 1 mild nonproliferative diabetic retinopathy</li> <li>• E10.331 Type 1 moderate nonproliferative diabetic retinopathy</li> <li>• E10.341 Type 1 severe nonproliferative diabetic retinopathy</li> <li>• E10.351 Type 1 proliferative diabetic retinopathy</li> <li>• E11.321 Type 2 mild nonproliferative diabetic retinopathy</li> <li>• E11.331 Type 2 moderate nonproliferative diabetic retinopathy</li> <li>• E11.341 Type 2 severe nonproliferative diabetic retinopathy</li> <li>• E11.351 Type 2 proliferative diabetic retinopathy</li> <li>• E13.321 other specified diabetes mellitus with mild nonproliferative diabetic retinopathy</li> <li>• E13.331 other specified diabetes mellitus with moderate nonproliferative diabetic retinopathy</li> </ul>

ICD = International Classification of Diseases; CM = Clinical Modification used in the United States; NOS = not otherwise specified

Additional information:

- Certain ICD-10 CM categories have applicable 6<sup>th</sup> characters. In the diabetic retinopathy series, indicate “with or without” macular edema. Laterality indicators are not required in this series.
  - 1 = with macular edema
  - 9 = without macular edema
- For bilateral sites, the final character of the codes in the ICD-10 CM indicates laterality. If no bilateral code is provided and the condition is bilateral, separate codes for both the left and right side should be assigned. Unspecified codes should be used only when there is no other code option available.

## APPENDIX 3. MAJOR STUDY RESULTS

### DIABETIC RETINOPATHY STUDY (1972–1979)

The Diabetic Retinopathy Study (DRS) was designed to investigate the value of laser photocoagulation surgery for patients with severe nonproliferative diabetic retinopathy (NPDR) and proliferative diabetic retinopathy (PDR).<sup>85</sup> The results are shown in Table A4-1.

**TABLE A3-1 VISUAL OUTCOME FOR LASER PHOTOCOAGULATION FROM THE DIABETIC RETINOPATHY STUDY**

Baseline Severity of Retinopathy	Duration of Follow-up (Years)	Control Patients (% with Severe Visual Loss)	Treated Patients (% with Severe Visual Loss)
Severe nonproliferative	2	3	3
	4	13	4
Mild proliferative	2	7	3
	4	21	7
High-risk proliferative	2	26	11
	4	44	20

NOTE: Severe visual loss was defined as worse than 5/200 visual acuity at two or more consecutive completed visits (scheduled at 4-month intervals).

### WISCONSIN EPIDEMIOLOGIC STUDY OF DIABETIC RETINOPATHY (1979)

The Wisconsin Epidemiologic Study of Diabetic Retinopathy (WESDR) began in 1979. It was initially funded by the National Eye Institute, which is part of the National Institutes of Health. The purpose of the WESDR is to describe the frequency and incidence of complications associated with diabetes (eye complications such as diabetic retinopathy and visual loss, kidney complications such as diabetic nephropathy, and amputations), and to identify risk factors (such as poor glycemic control, smoking, and high blood pressure) that may contribute to the development of these complications.<sup>91</sup>

### EARLY TREATMENT DIABETIC RETINOPATHY STUDY (1985–1990)

The Early Treatment Diabetic Retinopathy Study (ETDRS) investigated the value of photocoagulation surgery for patients with NPDR or PDR without high-risk characteristics.<sup>89,132</sup> The results for eyes with macular edema are shown in Table A4-2. Visual loss was defined as at least doubling of the visual angle (e.g., 20/20 to 20/40, or 20/50 to 20/100).

**TABLE A3-2 VISUAL OUTCOME FOR LASER PHOTOCOAGULATION TREATMENT FROM THE EARLY TREATMENT DIABETIC RETINOPATHY STUDY**

Extent of Macular Edema	Duration of Follow-up (Years)	Control Patients (% with Visual Loss)	Treated Patients (% with Visual Loss)
CSME (center of macula not involved)	1	8	1
	2	16	6
	3	22	13
CSME (center of macula involved)	1	13	8
	2	24	9
	3	33	14

CSME = clinically significant macular edema

NOTE: Visual loss was defined as at least doubling of the visual angle.

### Results of Early Scatter Laser Treatment in ETDRS

In eyes with NPDR or non-high-risk PDR, early panretinal photocoagulation (PRP) was compared with deferral of photocoagulation, and although there was a beneficial treatment effect, the outlook for maintaining vision was good in both groups. The 5-year rates of severe visual loss or vitrectomy ranged from 2% to 6% in eyes assigned to early photocoagulation and from 4% to 10% in eyes assigned to deferral. Early PRP was associated with side effects (small decreases in visual acuity and visual field) in some eyes, and the ETDRS concluded that deferral of photocoagulation was preferable at least until retinopathy was approaching the high-risk stage. Eyes approaching that stage had a 50% risk of reaching it within 12 to 18 months. Eyes in this category had very severe NPDR or non-high-risk PDR characterized by NVD less than one-quarter to one-third disc area and/or NVE, without vitreous or preretinal hemorrhage.

Recent additional analyses of visual outcome in ETDRS patients with severe NPDR to non-high-risk PDR suggest that the recommendation to consider PRP before the development of high-risk PDR is particularly appropriate for patients with type 2 diabetes.<sup>1</sup> The risk of severe vision loss or vitrectomy was reduced by 50% in patients who were treated early compared with those who deferred treatment until high-risk PDR developed.

For patients with type 1 diabetes, the timing of the PRP will depend on the compliance with follow-up, status and response to treatment of the fellow eye, impending cataract surgery, and/or pregnancy status.

### DIABETIC RETINOPATHY VITRECTOMY STUDY (1983-1987)

The Diabetic Retinopathy Vitrectomy Study (DRVS) investigated the role of vitrectomy in managing eyes with very severe PDR.<sup>90,249-251</sup> The benefit of early vitrectomy for severe vitreous hemorrhage (defined as hemorrhage obscuring the macula or major retinal vessels for 3 disc diameters from the macular center) was seen in type 1 patients, but no such advantage was found in type 2 patients, who did not benefit from earlier surgery. Early vitrectomy was beneficial among patients with visual acuity of 5/200 or worse and severe vitreous hemorrhage with reduced vision for at least 1 month and

without previous treatment or complications such as retinal detachment or neovascularization of the iris. Overall, at 2 years after surgery, 25% of the early vitrectomy group and 15% of the deferral group had visual acuity of 20/40 or better. The advantage was most pronounced in patients with type 1 diabetes (36% vs. 12% for early vitrectomy versus deferral of vitrectomy, respectively) and was not statistically significant for patients with type 2 diabetes.

The DRVS showed that early vitrectomy was beneficial for patients with visual acuity of 20/400 or better plus 1 of the following: (1) severe neovascularization and fibrous proliferation; (2) fibrous proliferation and moderate vitreous hemorrhage; or (3) moderate neovascularization, severe fibrous proliferation, and moderate vitreous hemorrhage. Among such patients, 44% with early vitrectomy and 28% in the observation group had visual acuity of 20/40 or better at 4 years of follow-up.

The results of the DRVS should be interpreted in light of subsequent advances in vitreoretinal surgery, such as the introduction of small-gauge vitrectomy technology, endoscopic and indirect ophthalmoscopic laser photocoagulation surgery, and advanced instrumentation. The use of long-acting intraocular gases such as sulfur hexafluoride (SF<sub>6</sub>) and perfluoropropane (C<sub>3</sub>F<sub>8</sub>), the use of viscodissection, and the use of heavier-than-water liquids such as perfluoro-octane are advances in vitreoretinal surgery that developed after the DRVS. Thus, the results may actually be better than those reported in the DRVS.<sup>239,290</sup> Early vitrectomy should be considered for selected patients with type 2 diabetes, particularly those in whom severe vitreous hemorrhage prohibits laser therapy photocoagulation of active neovascularization.

## **FENOFIBRATE INTERVENTION AND EVENT LOWERING IN DIABETES (FIELD) STUDY (2005)**

The FIELD study was a randomized controlled trial that evaluated long-term fenofibrate therapy for the reduction of cardiovascular events in 9795 patients with type 2 diabetes mellitus. Fenofibrate did not significantly reduce the risk of the primary outcome of coronary events. It did reduce total cardiovascular events, mainly due to fewer nonfatal myocardial infarctions and revascularizations.

The higher rate of starting statin therapy in patients allocated to receive placebo might have masked a moderately larger treatment benefit.

## **DIABETIC RETINOPATHY CLINICAL RESEARCH NETWORK (DRCR.NET) (2002–PRESENT)**

The Diabetic Retinopathy Clinical Research Network (DRCR.net) is a collaborative network dedicated to facilitating multicenter clinical research of diabetic retinopathy, diabetic macular edema (DME), and associated conditions. The DRCR.net supports the identification, design, and implementation of multicenter clinical research initiatives focused on diabetes-induced retinal disorders. Principal emphasis is placed on clinical trials, but epidemiologic outcomes and other research may be supported as well.



The DRCR.net was formed in 2002 and currently includes over 115 participating sites (offices) with over 400 physicians throughout the United States. The DRCR.net is funded by the National Eye Institute (NEI), which is a part of the National Institutes of Health, the branch of government that funds medical research.

The DRCR.net has completed multiple clinical trials evaluating the role of anti-vascular endothelial growth factor (anti-VEGF), laser treatment, and corticosteroids in DME, anti-VEGF efficacy in PDR and vitreous hemorrhage, and even diabetes education effectiveness on DME (See Table A3-3). Most importantly, DRCR.net Protocol T (Comparative Effectiveness Study of Intravitreal Aflibercept, Bevacizumab, and Ranibizumab for Diabetic Macular Edema) compared the effectiveness of ranibizumab, aflibercept, and bevacizumab in the treatment of DME.<sup>96</sup> This study found that all three drugs resulted in improvement in visual acuity at 1 year with similar safety profiles. However, the mean visual acuity using aflibercept was better for eyes with visual acuity of 20/50 or worse at 1 year. At 2 years, the mean visual acuity in the aflibercept was no longer superior to ranibizumab, although it remained superior to bevacizumab.

Another important treatment comparison was done in Protocol I: Intravitreal Ranibizumab for Diabetic Macular Edema with Prompt vs. Deferred Laser Treatment. Three-year results were reported in 2012. The study utilized ranibizumab monthly until improvement no longer occurred (with resumption if the condition worsened) and random assignment to focal/grid laser treatment promptly or deferred ( $\geq 24$  weeks). The 3-year results suggest that focal/grid laser treatment at the initiation of intravitreal ranibizumab is no better, and possibly worse for vision outcomes, than deferring laser treatment for  $\geq 24$  weeks in eyes with DME involving the fovea and with vision impairment.<sup>94</sup>

A previous publication from Protocol I results confirmed the 1-year results that intravitreal ranibizumab with prompt or deferred laser was more effective through 2 years compared with prompt laser alone for the treatment of DME involving the central macula. Laser was not associated with endophthalmitis, the rare but potentially devastating complication of injecting ranibizumab. In pseudophakic eyes, results with intravitreal triamcinolone plus prompt laser appeared similar to results in the ranibizumab arms and were more effective than laser alone, but the triamcinolone plus prompt laser arm had an increased risk of IOP elevation.<sup>189</sup>

Most recently, the DRCR.net Protocol S evaluated the effects of anti-VEGF versus PRP.<sup>291</sup> In a randomized, multicenter, noninferiority trial, 394 eyes of 305 adults with PDR were randomized to receive either PRP or anti-VEGF therapy. Ranibizumab 0.5 mg was given at baseline and as frequently as every 4 weeks based on a structured retreatment design. Eyes in both groups were allowed ranibizumab if DME was present. In eyes with PDR, ranibizumab was not inferior to PRP in terms of visual acuity outcomes at 2 years. Mean visual acuity improvement was +2.8 letters for ranibizumab and +0.2 letters for PRP-treated eyes ( $P < 0.001$ ). When the totality of the visual acuity data was included (area under the curve analysis), eyes given ranibizumab had overall better visual acuity outcomes than eyes treated with PRP. There was less mean reduction in peripheral visual field

(-23 dB vs. -422 dB;  $P<0.001$ ) with ranibizumab than with PRP treatment. The rates for vitrectomy were more frequent (15% vs. 4%;  $P<0.001$ ), and DME development was more frequent (28% vs. 9%;  $P<0.001$ ) in the PRP group than in the ranibizumab group. Moreover, rates of active neovascularization or rates of regression of neovascularization were similar between the two groups.

**TABLE A3-3 DIABETIC RETINOPATHY CLINICAL RESEARCH NETWORK STUDIES**

Protocol	Study Name	End Date	Study Conclusions
A	A Pilot Study of Laser Photocoagulation for Diabetic Macular Edema	01/31/2009	In eyes with DME, an MMG photocoagulation technique was less effective at reducing OCT-measured retinal thickening over 12 months than the standard focal photocoagulation technique modified from the ETDRS.
B	A Randomized Control Trial Comparing Intravitreal Triamcinolone Acetonide and Laser Photocoagulation for Diabetic Macular Edema	10/03/2008	Over 2 years, focal/grid photocoagulation for center-involved DME was more effective and had fewer adverse effects than 1-mg or 4-mg doses of preservative-free intravitreal triamcinolone.
C	Temporal Variation in Optical Coherence Tomography Measurements of Retinal Thickening in Diabetic Macular Edema	05/20/2005	Although retinal thickening decreases slightly over the day on average, most eyes with DME have little meaningful change in OCT CST or visual acuity between the hours of 8 AM and 4 PM. A change in CST>11% is likely to be real.
D	Evaluation of Vitrectomy for Diabetic Macular Edema Study	02/26/2009	Vitrectomy reduces retinal thickening in most eyes with DME and vitreomacular traction. Although visual acuity outcomes improved by 10 or more letters in 38% of eyes, 22% lost 10 or more letters after vitrectomy
E	A Pilot Study of Peribulbar Triamcinolone Acetonide for Diabetic Macular Edema	11/01/2007	In cases of DME where the patient has good visual acuity, peribulbar triamcinolone, with or without focal photocoagulation, is unlikely to be of substantial benefit.
F	An Observational Study of the Development of Diabetic Macular Edema Following Scatter Laser Photocoagulation	01/31/2008	Clinically meaningful differences in OCT thickness or visual acuity are not substantially different when PRP is applied in 1 sitting compared with 4 sittings.
G	Subclinical Diabetic Macular Edema Study	04/22/2009	Approximately one-quarter to one-half of eyes diagnosed with subclinical DME will progress to more definite thickening or be judged to need treatment for DME within 2 years. Because CST is greater in men than in women, studies involving comparisons of retinal thickness to expected norms should consider different mean values for men and women.
H	A Phase 2 Evaluation of Anti-VEGF Therapy for Diabetic Macular Edema: Bevacizumab (Avastin)	02/29/2008	Intravitreal bevacizumab can reduce DME in some eyes, but this preliminary study was not designed to definitively determine whether the treatment was beneficial.

I	Intravitreal Ranibizumab or Triamcinolone Acetonide in Combination with Laser Photocoagulation for Diabetic Macular Edema	12/31/2013	At 2 years, intravitreal ranibizumab with prompt or deferred ( $\geq 24$ weeks) focal/grid laser photocoagulation is more effective in increasing visual acuity compared with focal/grid laser treatment alone or intravitreal triamcinolone with laser photocoagulation for the treatment of center-involved DME. Focal/grid laser treatment at the initiation of intravitreal ranibizumab is no better, and possibly worse, for vision outcomes than deferring laser treatment for 24 weeks or more in eyes with center-involved DME with vision impairment.
J	Intravitreal Ranibizumab or Triamcinolone Acetonide as Adjunctive Treatment to Panretinal Photocoagulation for Proliferative Diabetic Retinopathy	07/07/2010	The addition of 1 intravitreal triamcinolone injection or 2 intravitreal ranibizumab injections in eyes receiving focal/grid laser photocoagulation for DME and PRP is associated with better visual acuity outcomes and decreased macular edema by 14 weeks.
K	The Course of Response to Focal Photocoagulation for Diabetic Macular Edema	06/19/2008	Eyes that demonstrate a definite reduction in, but not complete resolution of, central DME at 16 weeks after focal/grid laser photocoagulation have a 23%-63% likelihood of continuing to improve without additional treatment.
L	Evaluation of Visual Acuity Measurements in Eyes with Diabetic Macular Edema	11/06/2010	Across nationwide sites using a variety of autorefractors, visual acuity tended to be worse and more variable with autorefraction than manual refraction, suggesting that autorefraction is not a good substitute for manual refraction for clinical trials with improved visual acuity outcomes as a primary endpoint.
M	Effect of Diabetes Education During Retinal Ophthalmology Visits on Diabetes Control	12/31/2014	Use of a personalized intervention at ophthalmology visits, including HbA <sub>1c</sub> measurement and counseling about the importance of glycemic control in reducing diabetic complications was not effective in improving HbA <sub>1c</sub> levels.
N	An Evaluation of Intravitreal Ranibizumab for Vitreous Hemorrhage Due to Proliferative Diabetic Retinopathy	12/21/2012	Intravitreal ranibizumab versus saline did result in significantly different rates of vitrectomy by 16 weeks in eyes with vitreous hemorrhage from PDR. However, ranibizumab treatment resulted in improved short-term secondary outcomes including visual acuity improvement, increased panretinal photocoagulation completion rates, and reductions in recurrent vitreous hemorrhage.
O	Comparison of Time-Domain OCT and Spectral-Domain OCT Retinal Thickness Measurement in Diabetic Macular Edema	01/31/2013	This study of eyes with no to minimal nonproliferative diabetic retinopathy developed conversion equations to transform CST values obtained on a spectral-domain OCT to a time-domain OCT scale for group comparisons. In addition, values were established for machine and gender-specific thresholds to determine DME presence in diabetic eyes.

P	A Pilot Study in Individuals with Center-Involved DME Undergoing Cataract Surgery	11/12/2010	This small, observational study of eyes with DME undergoing cataract surgery revealed only a small percentage of eyes experienced substantial visual acuity loss or definitive worsening of DME after surgery.
Q	An Observational Study in Individuals with Diabetic Retinopathy without Center-Involved DME Undergoing Cataract Surgery	05/19/2011	A history of DME treatment and presence of non-center-involved DME are risk factors for development of center-involved DME after cataract surgery in eyes with diabetic retinopathy and no center-involved DME prior to surgery.
R	A Phase II Evaluation of Topical NSAIDs in Eyes with Non Central Involved DME	12/18/2013	At 1-year follow-up in eyes with non-center-involved DME, this study did not identify a difference between the effect of topical nepafenac 0.1% and placebo drops on OCT parameters or visual acuity.
S	Prompt Panretinal Photocoagulation versus Intravitreal Ranibizumab with Deferred Panretinal Photocoagulation for Proliferative Diabetic Retinopathy	--	Ranibizumab injections are an effective alternative to panretinal photocoagulation in treating PDR. At 2 years, visual acuity outcomes were noninferior to ranibizumab, while average visual acuity over the 2-year period was better and there was less peripheral field loss, reduced rates of DME onset, and fewer eyes that underwent vitrectomy.
T	A Comparative Effectiveness Study of Intravitreal Aflibercept, Bevacizumab and Ranibizumab for Diabetic Macular Edema	10/18/2018	The 2-year clinical trial compared 3 drugs used to treat DME and found that gains in vision were greater for participants receiving the drug aflibercept than for those receiving bevacizumab, but only among participants starting treatment with 20/50 or worse visual acuity. At 1 year, aflibercept had superior gains to ranibizumab in this vision subgroup; however, a difference could not be identified at 2 years. The 3 drugs yielded similar gains in vision for patients with 20/32 or 20/40 visual acuity at the start of treatment.
U	Short-term Evaluation of Combination Corticosteroid + Anti-VEGF Treatment for Persistent Central-Involved Diabetic Macular Edema Following Anti-VEGF Therapy	06/01/2017	In eyes with persistent DME and visual impairment despite previous anti-VEGF therapy, the dexamethasone + ranibizumab group experienced greater reduction of DME but no greater improvement in vision than sham + ranibizumab group over 6 months.

CST = central subfield thickness; DME = diabetic macular edema; ETDRS = Early Treatment Diabetic Retinopathy Study; HbA<sub>1c</sub> = hemoglobin A<sub>1c</sub>; MMG = modified macular grid; OCT = optical coherence tomography; PDR = proliferative diabetic retinopathy  
 Data from Diabetic Retinopathy Clinical Research Network (DRCR.net) website; [www.drcr.net](http://www.drcr.net). Accessed March 15, 2018.

(Adapted with permission from the American Academy of Ophthalmology Basic and Clinical Science Course Subcommittee. Basic and Clinical Science Course. Retina and Vitreous: Section 12, 2018-2019. San Francisco, CA: American Academy of Ophthalmology; 2018)

## **STUDY OF RANIBIZUMAB INJECTION IN SUBJECTS WITH CLINICALLY SIGNIFICANT DIABETIC MACULAR EDEMA WITH CENTER INVOLVEMENT SECONDARY TO DIABETES MELLITUS (RISE AND RIDE)**

The RISE and RIDE trials were parallel phase III multicenter double-masked sham injection–controlled randomized studies conducted at private and university-based retina specialty clinics in the United States and South America. (See Glossary.)

The phase III results for both studies were published in 2012. The studies utilized monthly intravitreal ranibizumab (0.5 or 0.3 mg) or sham injections, with macular laser available if needed. The study concluded that ranibizumab rapidly and sustainably improved vision, reduced the risk of further vision loss, and improved macular edema in patients with DME, with low rates of ocular and nonocular side effects.<sup>187</sup>

## **RANIBIZUMAB FOR EDEMA OF THE MACULA IN DIABETES (READ-2)**

READ-2 was a phase II multicenter randomized controlled trial that compared 0.5 mg injections of ranibizumab versus focal laser treatment over 2 years in patients with type 1 or type 2 diabetes mellitus and DME. Patients randomized to one arm of the trial received ranibizumab at baseline, and at 1, 3 and 5 months after baseline; a second arm received laser treatment at baseline and at 3 months (if needed); the third arm received both ranibizumab and laser treatment at baseline and 3 months. From month 5, all subjects received ranibizumab every 2 months and/or maintenance laser treatment every 3 months.

At 24 months, differences between the groups were not statistically significant, and all groups experienced improved visual acuity. Patients receiving combined ranibizumab and laser treatment required fewer injections than patients receiving ranibizumab alone.<sup>203</sup>

## **BEVACIZUMAB OR LASER THERAPY (BOLT) STUDY**

BOLT was a phase II 2-year randomized controlled trial that compared intravitreal 1.25 mg bevacizumab injections and focal laser treatment in patients with persistent DME and visual impairment. Bevacizumab patients received an injection every 6 weeks, whereas laser patients were treated every 4 weeks.

At 2 years, visual acuity results were substantially better in the bevacizumab group compared with the laser group, with significant differences in the proportions of patients gaining 10 letters and 15 letters. No patients lost 10 or more letters in the bevacizumab group, compared with 14% of patients treated with laser.<sup>204</sup>

## DIABETIC MACULAR EDEMA AND VASCULAR ENDOTHELIAL GROWTH FACTOR TRAP-EYE: VIVID AND VISTA

These studies compared the efficacy and safety of intravitreal aflibercept injection (IAI) with macular laser photocoagulation surgery for DME. Visual improvement were observed in the IAI treatment regimens over laser control at 52, 100 and 148 weeks. Incidence of adverse events was consistent with the known safety profile of IAI.<sup>292</sup>

### COMPARISON OF DRUGS

The DRCR.net compared the efficacy and safety of bevacizumab, ranibizumab, and aflibercept in a multicentered, randomized clinical trial.<sup>152</sup> At the primary endpoint at 1 year, the mean change in vision was greater for aflibercept than for either of the other two drugs. However, the mean visual acuity changes were dependent on the baseline visual acuity. For eyes with milder visual acuity loss, the drugs resulted in similar visual outcomes (8.0 with aflibercept, 7.5 with bevacizumab, and 8.3 with ranibizumab;  $P>0.50$  for each pairwise comparison). However, for eyes with 20/50 or worse vision, the mean visual acuity in eyes treated with aflibercept had greater improvements in vision (18.9 with aflibercept, 11.8 with bevacizumab, and 14.2 with ranibizumab;  $P<0.001$  for aflibercept vs. bevacizumab,  $P=0.003$  for aflibercept vs. ranibizumab, and  $P=0.21$  for ranibizumab vs. bevacizumab). There were no significant differences in rates of adverse events. However, at 2 years, the mean visual acuity results were similar for ranibizumab and aflibercept, although aflibercept results remained significantly better than bevacizumab results. There was a slightly higher rate of Antiplatelet Trialists' Collaboration (APTC) events with ranibizumab compared with the other two drugs at the 2-year endpoint. All three drugs improved visual acuity at 2 years, and the number of injections decreased in year 2 compared to year 1.

## APPENDIX 4. GLYCEMIC CONTROL

The Diabetes Control and Complications Trial (DCCT) was a multicenter, randomized controlled trial designed to study the connection between glycemic control and retinal, renal, and neurologic complications of type 1 diabetes mellitus. Published results from this trial demonstrated that improved blood sugar control can delay the onset and slow the progression of diabetic retinopathy, nephropathy, and neuropathy in type 1 patients.<sup>81</sup> The DCCT showed a strong exponential relationship between the risk of diabetic retinopathy and the mean HbA<sub>1c</sub> level. For each 10% decrease in the HbA<sub>1c</sub> (e.g., from 9% to 8.1%), there was a 39% decrease in the risk of progression of retinopathy over the range of HbA<sub>1c</sub> values. There was no glycemic threshold when the risk of retinopathy was eliminated above the nondiabetic range of HbA<sub>1c</sub> (4% to 6.05%).

After 6.5 years of follow-up, the DCCT ended, and all patients were encouraged to pursue strict control of blood sugar. Most of these patients are being followed in the Epidemiology of Diabetes Interventions and Complications (EDIC) study, which includes 95% of the DCCT subjects. A total of 1294 to 1335 patients have been examined annually in the EDIC study. Further progression of diabetic retinopathy during the first 4 years of the EDIC study was 66% to 77% less in the former intensive treatment group than in the former conventional treatment group.<sup>43</sup> The benefit persisted even at 7 years. This benefit included an effect on severe diabetic retinopathy, including severe nonproliferative diabetic retinopathy (NPDR), proliferative diabetic retinopathy (PDR), clinically significant macular edema, and the need for focal/grid or panretinal laser photocoagulation surgery.<sup>45</sup> The decrease in HbA<sub>1c</sub> from 9% to approximately 8% did not drastically reduce the progression of diabetic retinopathy in the former conventional treatment group, nor did the increase in HbA<sub>1c</sub> from approximately 7% to approximately 8% drastically accelerate diabetic retinopathy in the former intensive treatment group.<sup>43</sup> Thus, it takes time for improvements in control to negate the long-lasting effects of prior prolonged hyperglycemia, and once the biological effects of prolonged improved control are manifest, the benefits are long-lasting. Furthermore, the total glycemic exposure of the patient (i.e., degree and duration) determines the degree of retinopathy observed at any one time.

A positive relationship between the 4-year incidence and progression of retinopathy and glycosylated hemoglobin remains after controlling for other risk factors, such as duration of diabetes and severity of retinopathy at a baseline examination.<sup>65,66,130</sup> Extrapolation of pathologic and clinical experience strongly suggests that poor levels of control contribute to microangiopathy, including retinopathy.<sup>293</sup> The development of PDR parallels an increased risk of nephropathy, myocardial infarction, and/or cerebral vascular accidents.

Although good glycemic control is advised, there is some evidence that rapid improvement of long-standing poor control may increase the risk of retinopathy progression over the first year for some patients. About 10% of type 1 patients who had initial retinopathy at the beginning of the DCCT had increased retinopathy progression.<sup>294</sup> Specifically, there may be a transient increase in the number of cotton wool spots seen on retinal examination. Frequent ophthalmologic monitoring is important when diabetic patients are being brought under better metabolic control.<sup>294</sup>



In the DCCT there was a threefold increase in severe hypoglycemic events and excess weight gain among patients using intensive treatment regimens. Increased risk of hypoglycemia is a consequence of strict blood glucose control. Irregular food intake, failure to check blood glucose before planned or unplanned vigorous exercise or before operating a motor vehicle, and excess alcohol are risk factors for hypoglycemia. Diabetes mellitus education and regular reinforcement should be provided by diabetes nurses and dietitian educators and may help minimize the risk of hypoglycemia.

The United Kingdom Prospective Diabetes Study (UKPDS),<sup>46,126</sup> a randomized controlled clinical trial of blood glucose control, enrolled 3867 patients with newly diagnosed type 2 diabetes. Intensive blood glucose control by either the sulfonylureas or insulin decreased the risk of microvascular complications but not the risk of macrovascular disease. There were no adverse effects of the individual drugs on the cardiovascular outcome. In this study, there was a 29% reduction in the need for retinal photocoagulation in the group that had intensive glucose therapy compared with those that had conventional treatment (relative risk, 0.71; 95% confidence interval, 0.53–0.96;  $P=0.003$ ).

The ACCORD (Action to Control Cardiovascular Risk in Diabetes) study ([www.accordtrial.org](http://www.accordtrial.org)) was a large clinical trial of adults with established type 2 diabetes who are at especially high risk of cardiovascular disease (CVD). Type 2 diabetes increases the risk of a number of complications, especially CVD, which is the leading cause of early death in people with diabetes.

The ACCORD study consisted primarily of three clinical trials that tested treatment approaches to determine the best ways to decrease the high rate of major CVD events—heart attack, stroke, or death from CVD—among people with type 2 diabetes who are at especially high risk of having such a CVD event. These three treatment approaches were intensive lowering of blood sugar levels compared with a more standard blood sugar treatment; intensive lowering of blood pressure compared with standard blood pressure treatment; and treatment of multiple blood lipids with two drugs—a fibrate plus a statin—compared with one drug, a statin alone.<sup>295</sup>

The study began enrolling participants in 2001 and took place in 77 clinical sites across the United States and Canada. A total of 10,251 adults with established type 2 diabetes participated in ACCORD. At enrollment, study participants were between age 40 and 79 (average age 62), had diabetes for an average of 10 years, and were at especially high risk for CVD events because they already had pre-existing CVD, evidence of subclinical CVD, or at least two CVD risk factors in addition to type 2 diabetes. The other CVD risk factors could be high low-density lipoprotein cholesterol, high blood pressure, smoking, or obesity.

The primary outcome measure for all three trials was the first occurrence after randomization of a major CVD event, specifically nonfatal heart attack, nonfatal stroke, or CVD death. Secondary outcomes include total mortality (death), microvascular outcomes (e.g., eye, kidney, and nerve complications), health-related quality of life, and cost-effectiveness.

All three ACCORD clinical trials have ended. The National Heart, Lung, and Blood Institute (NHLBI) stopped the intensive blood sugar lowering strategy in 2008 due to safety concerns. Participants in the intensive blood sugar treatment strategy group were transitioned to the standard treatment strategy. The blood



pressure and lipid treatment trials continued until the planned end of the study in 2009. In its regular review of the available study data, the ACCORD Data and Safety Monitoring Board (DSMB) noticed an unexpected increase in total deaths from any cause among participants who had been randomly (by chance) assigned to the intensive lowering of blood sugar levels group compared with those assigned to the standard blood sugar treatment group. The data analyses showed that over an average of 3.5 years of treatment (ranging from about 2 years to about 7 years), 257 participants in the intensive group died compared with 203 in the standard group—a difference of 54 deaths, or an excess of about 3 deaths per 1,000 participants treated for a year. This translates to a statistically significant 22% higher rate of death in the intensive group than in the standard group.

There was a trend toward lower (10% lower) rate of primary outcome events, primarily nonfatal heart attacks, in the intensive group compared with the standard treatment group. However, the DSMB recommended discontinuing intensive blood sugar treatment because the harm of the intensive strategy outweighed the potential benefit. The NHLBI accepted the DSMB's recommendation and decided to transition all participants to the standard blood sugar strategy.

The results of the blood sugar trial were published in 2008.<sup>296</sup> There was no significant difference in the primary study outcome between the intensive and standard blood pressure treatment groups. The primary outcome was the time to first occurrence after randomization of a heart attack, a stroke, or a cardiovascular death. Thus, the primary hypothesis of the ACCORD BP trial was not supported. There was, however, a significant reduction in the rate of strokes, although the numbers were relatively small. This reduction in stroke was consistent with previous blood pressure lowering trials. Overall, however, the findings from the ACCORD blood pressure trial suggest that, on average, the standard treatment for lowering blood pressure was just as good as the intensive lowering treatment for cardiovascular outcomes.

The results of the lipid<sup>297</sup> and the blood pressure<sup>298</sup> trials were published in 2010. Overall, the fibrate and the placebo groups did not differ in the rates of the combined outcome of heart attacks, strokes, or cardiovascular death. The results, however, suggest that men may benefit from this treatment, but there was a trend toward more cardiovascular problems in women receiving the combination therapy compared with those who received statins only. Also, the group of patients who at the start of the trial had the lowest level of high-density lipoprotein (HDL) cholesterol combined with the highest level of triglycerides (which represented only 17% of the ACCORD participants) may have benefitted from this combined drug treatment.

More recently, the American College of Physicians published their glycemic control guidance statement to guide clinicians in selecting targets for pharmacologic treatment of type 2 diabetes based on the AGREE II (Appraisal of Guidelines for Research and Evaluation II) instrument, which was used to evaluate the guidelines.<sup>299</sup> The National Guideline Clearinghouse and the Guidelines International Network library were searched (May 2017) for national guidelines published in English that addressed HbA<sub>1c</sub> targets for treating type 2 diabetes in nonpregnant outpatient adults. The investigators also identified guidelines from the National Institute for Health and Care Excellence and the Institute for Clinical Systems Improvement. In addition, four commonly used guidelines were reviewed from the American Association of Clinical Endocrinologists and the American College of Endocrinology, the American Diabetes Association, the

Scottish Intercollegiate Guidelines Network, and the US Department of Veterans Affairs and Department of Defense. They found that the ideal target that optimally balances benefits and harms remains uncertain. Their four guidance statements emphasize the importance of personalizing the glycemic goals in patients with type 2 diabetes on the basis of the benefits/harms balance of pharmacotherapy, patient preference, and life expectancy. They suggest an HbA<sub>1c</sub> goal range of 7% to 8% for most patients. These authors also recognized the studies that showed that more intensive glycemic control likely requires a long time to manifest. Thus, more stringent targets may be appropriate for patients who have a long life expectancy (>15 years). Further, most of the guidelines noted that a target in the lower end of the range (7%) applied best to patients with newly diagnosed diabetes and those without substantial diabetes-related complications.

# APPENDIX 5. CLASSIFICATION OF DIABETIC RETINOPATHY IN THE EARLY TREATMENT OF DIABETIC RETINOPATHY STUDY

The Early Treatment of Diabetic Retinopathy Study (ETDRS) classification of diabetic retinopathy and definitions of macular edema are in Tables A6-1.

**TABLE A5-1 CLASSIFICATION OF DIABETIC RETINOPATHY IN THE EARLY TREATMENT OF DIABETIC RETINOPATHY STUDY**

<b>Disease Severity Level</b>	<b>Findings Observable upon Dilated Ophthalmoscopy</b>
Mild nonproliferative retinopathy	At least 1 microaneurysm, and definition not met for moderate nonproliferative retinopathy, severe nonproliferative retinopathy, early proliferative retinopathy, or high-risk proliferative retinopathy (see below)
Moderate nonproliferative retinopathy	Hemorrhages and/or microaneurysms $\geq$ standard photograph 2A*; and/or soft exudates, venous beading, or intraretinal microvascular abnormalities definitely present; and definition not met for severe nonproliferative retinopathy, early proliferative retinopathy, or high-risk proliferative retinopathy (see below)
Severe nonproliferative retinopathy	Cotton wool spots, venous beading, and intraretinal microvascular abnormalities all definitely present in at least two of fields 4 through 7; or 2 of the preceding 3 lesions present in at least two of fields 4 through 7 and hemorrhages and microaneurysms present in these 4 fields, $\geq$ standard photo 2A in at least one of them; or intraretinal microvascular abnormalities present in each of fields 4 through 7 and $\geq$ standard photograph 8A in at least two of them; and definition not met for early proliferative retinopathy or high-risk proliferative retinopathy (see below)
Early proliferative retinopathy (i.e., proliferative retinopathy without Diabetic Retinopathy Study high-risk characteristics) (see Glossary)	New vessels; definition not met for high-risk proliferative retinopathy (see below)
High-risk proliferative retinopathy (i.e., proliferative retinopathy with Diabetic Retinopathy Study high-risk characteristics) (see Glossary)	New vessels on or within 1 disc diameter of the optic disc $\geq$ standard photograph 10A* (about one-quarter to one-third disc area), with or without vitreous or preretinal hemorrhage; or vitreous and/or preretinal hemorrhage accompanied by new vessels, either new vessels at the optic disc $<$ standard photograph 10A or new vessels elsewhere $\geq$ one-quarter disc area

Adapted with permission from the Early Treatment Diabetic Retinopathy Study Research Group. Early Treatment Diabetic Retinopathy Study design and baseline patient characteristics: ETDRS report number 7. Ophthalmology 1991;98:742.

\* Early Treatment Diabetic Retinopathy Study Research Group. Grading diabetic retinopathy from stereoscopic color fundus photographs--an extension of the modified Airlie House classification: ETDRS report number 10. Ophthalmology 1991;98:786-806

# GLOSSARY

**Action to Control Cardiovascular Risk in Diabetes (ACCORD) trial:** A large multicenter clinical trial that evaluated intensive control of blood sugar, intensive control of blood pressure, and statin therapy (with or without fibrate treatment) for the prevention of cardiovascular disease events among high-risk patients with type 2 diabetes.

**ACCORD:** See Action to Control Cardiovascular Risk in Diabetes trial.

**Anti-VEGF:** See Anti-vascular endothelial growth factor.

**Anti-vascular endothelial growth factor (anti-VEGF):** Substances that inhibit the action of vascular endothelial growth factor protein.

**Bevacizumab or Laser Treatment (BOLT) study:** A randomized trial that evaluated intravitreal bevacizumab or conventional laser treatment for center-involved DME

**BOLT:** See Bevacizumab or Laser Treatment study.

**Clinically significant macular edema (CSME):** Retinal thickening at or within 500  $\mu\text{m}$  of the center of the macula; and/or hard exudates at or within 500  $\mu\text{m}$  of the center of the macula, if associated with thickening of the adjacent retina; and/or a zone or zones of retinal thickening 1 disc area in size, any part of which is within 1 disc diameter of the center of the macula.

**CSME:** See Clinically significant macular edema.

**ci-CSME:** Center-involved CSME.

**DA VINCI:** See DME and VEGF Trap-Eye: Investigation of Clinical Impact study.

**DCCT:** See Diabetes Control and Complications Trial.

**Diabetes Control and Complications Trial (DCCT):** A multicenter, randomized, controlled trial designed to study the connection between glycemic control and retinal, renal, and neurologic complications of type 1 diabetes mellitus. (See Appendix 5.)

**Diabetes mellitus:** According to the American Diabetes Association Expert Committee on the Diagnosis and Classification of Diabetes Mellitus, the criteria for the diagnosis of diabetes mellitus are as follows.

- ◆ Fasting plasma glucose equal to or exceeding 126 mg/dL (7.0 mmol/L). Fasting is defined as no caloric intake for at least 8 hours.
- or
- ◆ Symptoms of hyperglycemia and a casual plasma glucose concentration equal to or exceeding 200 mg/dL (11.1 mmol/L). “Casual” is defined as any time of day without regard to time since last meal. The classic symptoms of hyperglycemia include polyuria, polydipsia, and unexplained weight loss.
- or
- ◆ A plasma glucose measurement at 2 hours postload equal to or exceeding 200 mg/dL (11.1 mmol/L) during an oral glucose tolerance test. The test should be performed as described by the World Health Organization, using a glucose load containing the equivalent of 75 g anhydrous glucose dissolved in water. However, the expert committee has recommended against oral glucose tolerance testing for routine clinical use. (Source: Report of the Expert Committee on the Diagnosis and Classification of Diabetes Mellitus. Diabetes Care 2008;31 (suppl):55-60.)

**Diabetic macular edema:** The accumulation of fluid in the macula due to leaky blood vessels.

**Diabetic Retinopathy Clinical Research Network (DRCR.net):** A multicenter trial that is evaluating different treatment modalities for diabetic retinopathy.

**Diabetic Retinopathy Study (DRS):** A study designed to investigate the value of xenon arc and argon photocoagulation surgery for patients with severe NPDR and PDR. (See Appendix 4.)

**Diabetic Retinopathy Vitrectomy Study (DRVS):** A study that investigated the role of vitrectomy in managing eyes with very severe PDR. (See Appendix 4.)

**DME:** See Diabetic macular edema.

**DME and VEGF Trap-Eye: Investigation of Clinical Impact (DA VINCI) study:** A randomized trial of the use of aflibercept for DME.

**DRCR.net:** See Diabetic Retinopathy Clinical Research Network.

**DRS:** See Diabetic Retinopathy Study.

**DRVS:** See Diabetic Retinopathy Vitrectomy Study.

**Early Treatment Diabetic Retinopathy Study (ETDRS):** A study that investigated the value of photocoagulation surgery for patients with NPDR or PDR who did not have high-risk characteristics. (See Appendix 4.)

**Early proliferative diabetic retinopathy** (i.e., proliferative retinopathy without DRS high-risk characteristics): New vessels that do not meet the criteria of high-risk proliferative retinopathy.

**EDIC:** See Epidemiology of Diabetes Interventions and Complications study.

**Epidemiology of Diabetes Interventions and Complications (EDIC) study:** An observational study following 95% of the DCCT subjects. (See Appendix 5.)

**ETDRS:** See Early Treatment Diabetic Retinopathy Study.

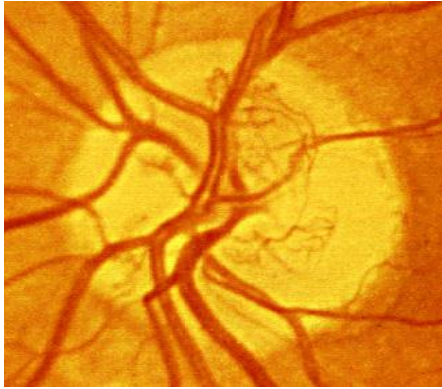
**Fenofibrate Intervention and Event Lowering in Diabetes (FIELD) study:** A large randomized controlled type 2 diabetes mellitus.

**FIELD study:** See Fenofibrate Intervention and Event Lowering in Diabetes study.

**Focal photocoagulation:** A laser technique directed to abnormal blood vessels with specific areas of focal leakage (i.e., microaneurysms) to reduce chronic fluid leakage in patients with macular edema.

**Grid photocoagulation:** A laser technique in which a grid pattern of scatter burns is applied in areas of diffuse macular edema and nonperfusion. Typically, fluorescein angiograms of these areas show a diffuse pattern rather than focal leakage.

**High-risk proliferative diabetic retinopathy (PDR):** New vessels on or within 1 disc diameter of the optic disc equaling or exceeding standard photograph 10A (about one-quarter to one-third disc area), with or without vitreous or preretinal hemorrhage; or vitreous and/or preretinal hemorrhage accompanied by new vessels either on the optic disc less than standard photograph 10A or new vessels elsewhere equaling or exceeding one-quarter disc area.



**Standard photograph 10A** defines the lower border of moderate NVD. NVD covers approximately one-third the area of the standard disc. This extent of NVD alone would constitute PDR with high-risk characteristics.

Reprinted with permission from the Early Treatment Diabetic Retinopathy Study Research Group. Grading diabetic retinopathy from stereoscopic color fundus photographs--an extension of the modified Airie House classification: ETDRS report number 10. *Ophthalmology* 1991;98:786-806.

**ICD-9:** International Statistical Classification of Diseases and Related Health Problems, Ninth Edition.

**ICD-10:** International Statistical Classification of Diseases and Related Health Problems, Tenth Edition.

**Intraretinal microvascular abnormalities (IRMA):** Tortuous intraretinal vascular segments, varying in caliber from barely visible to 31  $\mu\text{m}$  in diameter (one-quarter the width of a major vein at the disc margin); they occasionally can be larger. Intraretinal microvascular abnormalities may be difficult to distinguish from neovascularization.

**IRMA:** See Intraretinal microvascular abnormalities.

**Macular edema:** Thickening of the retina within 1 or 2 disc diameters of the center of the macula. (See Clinically significant macular edema.) Any other thickening of the macula not within this area is non-CSME.

**Mild nonproliferative diabetic retinopathy (NPDR):** At least 1 microaneurysm and less than moderate nonproliferative diabetic retinopathy.

**Moderate nonproliferative diabetic retinopathy (NPDR):** Hemorrhages and/or microaneurysms greater than standard photograph 2A, and/or soft exudates, venous beading, or IRMA present but less than severe nonproliferative retinopathy.

**Moderate visual loss:** The loss of 15 or more letters on the ETDRS visual acuity chart, or doubling of the visual angle (e.g., 20/20 to 20/40, or 20/50 to 20/100).

**nci-CSME:** Non-center-involved CSME.

**New vessels at the optic disc (NVD):** New vessels at the optic disc; neovascularization on or within 1 disc diameter of the optic disc.

**New vessels elsewhere in the retina:** New vessels elsewhere in the retina; neovascularization elsewhere in the retina and greater than 1 disc diameter from the optic disc margin.

**New vessels on the iris:** New vessels on the iris; neovascularization of the iris.

**Nonproliferative diabetic retinopathy (NPDR):** The phases of diabetic retinopathy with no evidence of retinal neovascularization.

**NPDR:** See Nonproliferative diabetic retinopathy.

**NVD:** See New vessels at the optic disc.

**OCT:** See Optical coherence tomography.

**Optical coherence tomography (OCT):** A diagnostic test using low energy lasers that takes a cross-section image of the retina, Used mostly to determine if there are membranes on the surface of the macula or fluid within or beneath it.

**Panretinal photocoagulation:** A type of laser surgery used for patients with PDR. The surgery is delivered in a scatter pattern throughout the peripheral fundus and is intended to lead to a regression of neovascularization.

**PDR:** See Proliferative diabetic retinopathy.

**Proliferative diabetic retinopathy (PDR):** Advanced disease characterized by NVD and/or new vessels elsewhere in the retina.

**Quality-adjusted life year (QALY):** A measure of health outcome that assigns to each year of a patient's life a weight (ranging from 0 to 1) corresponding to the health-related quality of life during that year, such that a value of 1 indicates a year of optimal health and a value of 0 indicates a year in a health state judged equivalent to death.

**QALY:** See Quality adjusted life year.

**Ranibizumab for Edema of the mAcula in Diabetes (READ-2) study:** A prospective multicenter randomized controlled trial that compared 0.5 mg ranibizumab and laser photocoagulation surgery for the treatment of DME.

**READ-2:** See Ranibizumab for Edema of the mAcula in Diabetes study.

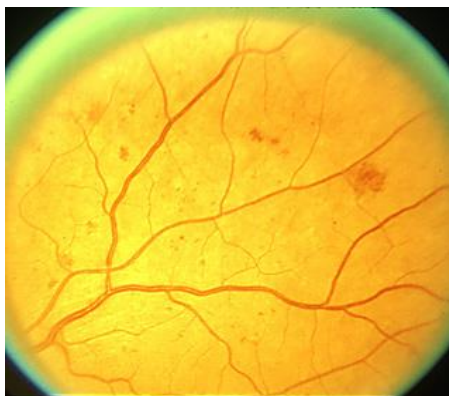**Retinal hard exudate:** Protein and lipid accumulation within the retina.

**RIDE:** A study of ranibizumab injection in subjects with CSME with center-involvement secondary to diabetes mellitus.

**RISE:** A study of ranibizumab injection in subjects with clinically significant macular edema with center-involvement secondary to diabetes mellitus.

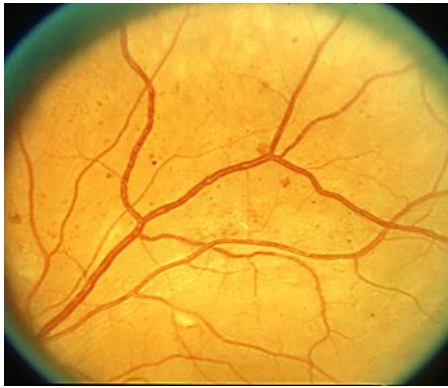**Scatter photocoagulation:** See Panretinal photocoagulation.

**Severe nonproliferative diabetic retinopathy (NPDR):** Using the 4-2-1 rule, the presence of at least one of the following features: (1) severe intraretinal hemorrhages and microaneurysms, equaling or exceeding standard photograph 2A, present in 4 quadrants; (2) venous beading in 2 or more quadrants (standard photograph 6A); or (3) moderate IRMA equaling or exceeding standard photograph 8A in 1 or more quadrants.

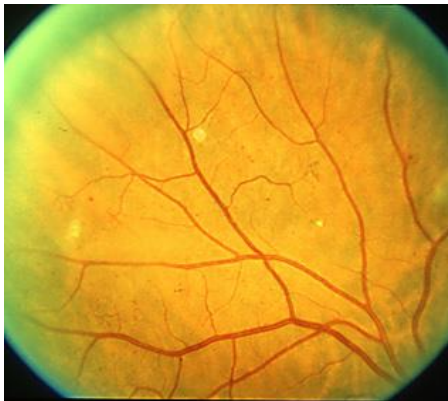

**Standard photograph 2A**, the standard for hemorrhages/microaneurysms. Eyes with severe NPDR have this degree of severity of hemorrhages and microaneurysms in all 4 midperipheral quadrants.





**Standard photograph 6A**, less severe of two standards for venous beading. Two main branches of the superior temporal vein show beading that is definite but not severe.



**Standard photograph 8A**, the standard for moderate IRMA. Patients with severe NPDR have moderate IRMA of at least this severity in at least 1 quadrant.

Reprinted with permission from the Early Treatment Diabetic Retinopathy Study Research Group. Grading diabetic retinopathy from stereoscopic color fundus photographs--an extension of the modified Airlie House classification: ETDRS report number 10. *Ophthalmology* 1991;98:786-806.

**Severe visual loss:** Occurrence of visual acuity worse than 5/200 at any two consecutive visits scheduled at 4-month intervals.

**UKPDS:** See United Kingdom Prospective Diabetes Study.

**United Kingdom Prospective Diabetes Study (UKPDS):** A randomized controlled clinical trial of blood glucose control in patients with newly diagnosed type 2 diabetes. (See Appendix 5.)

**VIVID:** A randomized, double masked, active controlled, Phase III study of the efficacy and safety of repeated doses of intravitreal VEGF Trap-Eye in subjects with DME.

**VISTA:** A randomized, double masked, active controlled, Phase III study of the efficacy and safety of intravitreal administration of VEGF Trap-Eye in patients with DME.

**WESDR:** See Wisconsin Epidemiologic Study of Diabetic Retinopathy

**Wisconsin Epidemiologic Study of Diabetic Retinopathy:** A large epidemiologic study of complications associated with diabetes and of risk factors associated with those complications



## LITERATURE SEARCHES FOR THIS PPP

Literature searches of the PubMed and Cochrane databases were conducted in April 2018; the search strategies are provided at [www.aaofpp.org](http://www.aaofpp.org). Specific limited update searches were conducted after June 2019.

("Diabetic Retinopathy/epidemiology"[Mesh] OR "Diabetic Retinopathy/ethnology"[Mesh])

("Diabetic Retinopathy"[Mesh] AND ("Risk Factors"[Mesh])

"Diabetic Retinopathy"[Mesh] AND "natural history"[tiab]

"Diabetic Retinopathy/diagnosis"[Mesh]

"Diabetic Retinopathy/therapy"[Mesh]

"Diabetic Retinopathy"[Mesh] AND (((("Drug Therapy, Combination"[Mesh] OR "Drug Combinations"[Mesh]) OR "Combined Modality Therapy"[Mesh]) OR (combination[tiab] OR combined[tiab]))

"Diabetic Retinopathy"[Mesh] AND "Cost of Illness"[Mesh]

((("Diabetic Retinopathy"[Mesh] OR ("diabetic"[All Fields] AND "retinopathy") OR "diabetic retinopathy") AND "Cost-Benefit Analysis"[Mesh])) OR ("Diabetic Retinopathy/economics"[Mesh]

("Diabetic Retinopathy/therapy"[Mesh] AND ("Quality of Life"[Mesh]

"Diabetic Retinopathy"[Mesh] AND (("Quality of Life"[Mesh] NOT ("therapy"[Subheading] OR "therapy"[All Fields] OR "treatment" OR "therapeutics"[MeSH Terms] OR "therapeutics"))

"Diabetic Retinopathy/genetics"[Mesh]

"Diabetic Retinopathy"[Mesh] AND (Guideline[ptyp]

## RELATED ACADEMY MATERIALS

### Basic and Clinical Science Course

Retina and Vitreous (Section 12, 2019–2020)

### Clinical Statements –

Free download available at <http://one.aao.org/guidelines-browse?filter=clinicalstatement>.

Frequency of Ocular Examinations (2015)

International Clinical Classification System for Diabetic Retinopathy and Diabetic Macular Edema (2012)

Screening for Diabetic Retinopathy (2014)

Telemedicine for Ophthalmology Information Statement (2018)

Verifying the Source of Compounded Bevacizumab for Intravitreal Injections (2012)

### Focal Points

Retinal Optical Coherence Tomography (2014)

Update on the Management of Diabetic Retinopathy (2011)

### Ophthalmic Technology Assessment –

Published in *Ophthalmology*, which is distributed free to Academy members; links to full text available at [www.aao.org/ota](http://www.aao.org/ota).

Anti-VEGF Pharmacotherapy for Diabetic Macular Edema (2012)

Clinical Models and Algorithms for the Prediction of Retinopathy of Prematurity (2016)

Current Role of Cryotherapy in Retinopathy of Prematurity (2012)

Laser Scanning Imaging for Macular Disease (2007; reviewed for currency 2012)

Single Field Fundus Photography for Diabetic Retinopathy Screening (2004; reviewed for currency 2010)

### Patient Education

Diabetic Retinopathy Brochure (2014)

Diabetic Retinopathy Brochure (Spanish: Retinopatía Diabética) (2014)

EyeSmart® What is Diabetic Retinopathy? Available at:

[www.geteyesmart.org/eyesmart/diseases/diabetic-retinopathy/index.cfm](http://www.geteyesmart.org/eyesmart/diseases/diabetic-retinopathy/index.cfm)

Preferred Practice Pattern® Guidelines – Free download available at [www.aao.org/ppp](http://www.aao.org/ppp).

Comprehensive Adult Medical Evaluation (2015)

To order any of these products, except for the free materials, please contact the Academy's Customer Service at 866.561.8558 (U.S. only) or 415.561.8540 or [www.aao.org/store](http://www.aao.org/store)

## REFERENCES

1. Ferris F. Early photocoagulation in patients with either type I or type II diabetes. *Trans Am Ophthalmol Soc.* 1996;94:505-537.
2. Guyatt GH, Oxman AD, Vist GE, et al. GRADE: an emerging consensus on rating quality of evidence and strength of recommendations. *BMJ.* 2008;336(7650):924-926.
3. GRADE Working Group. Organizations that have endorsed or that are using GRADE. <http://www.gradeworkinggroup.org/>. Accessed September 2019.
4. Shah AR, Gardner TW. Diabetic retinopathy: research to clinical practice. *Clin Diabetes Endocrinol.* 2017;3:9.
5. Abcouwer SF, Gardner TW. Diabetic retinopathy: loss of neuroretinal adaptation to the diabetic metabolic environment. *Ann N Y Acad Sci.* 2014;1311:174-190.
6. Kawasaki R, Tanaka S, Abe S, et al. Japan Diabetes Complications Study Group. Risk of cardiovascular diseases is increased even with mild diabetic retinopathy: the Japan Diabetes Complications Study. *Ophthalmology.* 2013;120(3):574-582.
7. American Association of Clinical Endocrinologists. State of diabetes complications in America: a comprehensive report issued by the American Association of Clinical Endocrinologists. Available at: [http://multivu.prnewswire.com/mnr/AACE/2007/docs/Diabetes\\_Complications\\_Report.pdf](http://multivu.prnewswire.com/mnr/AACE/2007/docs/Diabetes_Complications_Report.pdf). Accessed September 2019.
8. American Diabetes Association. Diagnosis and classification of diabetes mellitus. *Diabetes Care.* 2010;33 Suppl 1:S62-69.
9. Klein R, Klein BE, Moss SE. Visual impairment in diabetes. *Ophthalmology.* 1984;91(1):1-9.
10. Eppens MC, Craig ME, Cusumano J, et al. Prevalence of diabetes complications in adolescents with type 2 compared with type 1 diabetes. *Diabetes Care.* 2006;29(6):1300-1306.
11. Centers for Disease Control and Prevention. National diabetes statistics report, 2017. Available at: <https://www.cdc.gov/diabetes/pdfs/data/statistics/national-diabetes-statistics-report.pdf>. Accessed September 2019.
12. Cowie CC, Rust KF, Byrd-Holt DD, et al. Prevalence of diabetes and impaired fasting glucose in adults in the U.S. population: National Health And Nutrition Examination Survey 1999-2002. *Diabetes Care.* 2006;29(6):1263-1268.
13. Diagnosing Diabetes and Learning about Prediabetes. 2014; <http://www.diabetes.org/diabetes-basics/diagnosis/>. Accessed September 2019.
14. Acton KJ, Burrows NR, Moore K, Querec L, Geiss LS, Engelgau MM. Trends in diabetes prevalence among American Indian and Alaska native children, adolescents, and young adults. *Am J Public Health.* 2002;92(9):1485-1490.
15. Centers for Disease Control and Prevention. Prevalence of diagnosed diabetes among American Indians/Alaskan Natives--United States, 1996. *MMWR Morb Mortal Wkly Rep.* 1998;47(42):901-904.
16. Liu L, Wu X, Geng J, Yuan Z, Shan Z, Chen L. Prevalence of diabetic retinopathy in mainland China: a meta-analysis. *PLoS One.* 2012;7(9):e45264.
17. Namperumalsamy P, Kim R, Vignesh TP, et al. Prevalence and risk factors for diabetic retinopathy: a population-based assessment from Theni District, south India. *Br J Ophthalmol.* 2009;93(4):429-434.
18. Narayan KM, Boyle JP, Thompson TJ, Sorensen SW, Williamson DF. Lifetime risk for diabetes mellitus in the United States. *JAMA.* 2003;290(14):1884-1890.
19. Danaei G, Finucane MM, Lu Y, et al. National, regional, and global trends in fasting plasma glucose and diabetes prevalence since 1980: systematic analysis of health examination surveys and epidemiological studies with 370 country-years and 2.7 million participants. *Lancet.* 2011;378(9785):31-40.
20. Pinhas-Hamiel O, Zeitler P. The global spread of type 2 diabetes mellitus in children and adolescents. *J Pediatr.* 2005;146(5):693-700.
21. Urakami T, Kubota S, Nitadori Y, Harada K, Owada M, Kitagawa T. Annual incidence and clinical characteristics of type 2 diabetes in children as detected by urine glucose screening in the Tokyo metropolitan area. *Diabetes Care.* 2005;28(8):1876-1881.

22. Wei JN, Sung FC, Lin CC, Lin RS, Chiang CC, Chuang LM. National surveillance for type 2 diabetes mellitus in Taiwanese children. *JAMA*. 2003;290(10):1345-1350.
23. Fagot-Campagna A, Pettitt DJ, Engelgau MM, et al. Type 2 diabetes among North American children and adolescents: an epidemiologic review and a public health perspective. *J Pediatr*. 2000;136(5):664-672.
24. McMahon SK, Haynes A, Ratnam N, et al. Increase in type 2 diabetes in children and adolescents in Western Australia. *Med J Aust*. 2004;180(9):459-461.
25. Kaufman FR. Type 2 diabetes mellitus in children and youth: a new epidemic. *J Pediatr Endocrinol Metab*. 2002;15 Suppl 2:737-744.
26. Harris MI, Flegal KM, Cowie CC, et al. Prevalence of diabetes, impaired fasting glucose, and impaired glucose tolerance in U.S. adults. The Third National Health and Nutrition Examination Survey, 1988-1994. *Diabetes Care*. 1998;21(4):518-524.
27. Harris MI, Klein R, Cowie CC, Rowland M, Byrd-Holt DD. Is the risk of diabetic retinopathy greater in non-Hispanic blacks and Mexican Americans than in non-Hispanic whites with type 2 diabetes? A U.S. population study. *Diabetes Care*. 1998;21(8):1230-1235.
28. Geiss LS, Cowie CC. Type 2 diabetes and persons at high risk of diabetes. In: Narayan KM, Williams D, Gregg EW, Cowie CC, eds. *Diabetes Public Health: From Data to Policy*. New York: Oxford University Press, Inc.; 2011:15-32.
29. Klein BE. Overview of epidemiologic studies of diabetic retinopathy. *Ophthalmic Epidemiol*. 2007;14(4):179-183.
30. Kempen JH, O'Colmain BJ, Leske MC, et al. The prevalence of diabetic retinopathy among adults in the United States. *Arch Ophthalmol*. 2004;122(4):552-563.
31. Zhang X, Saaddine JB, Chou CF, et al. Prevalence of diabetic retinopathy in the United States, 2005-2008. *JAMA*. 2010;304(6):649-656.
32. Chua J, Lim CXY, Wong TY, Sabanayagam C. Diabetic retinopathy in the Asia-Pacific. *Asia Pac J Ophthalmol (Phila)*. 2018;7(1):3-16.
33. Stram DA, Jiang X, Varma R, et al. Factors associated with prevalent diabetic retinopathy in Chinese Americans: the Chinese American Eye Study. *Ophthalmol Retina*. 2018;2(2):96-105.
34. Klein R, Klein BE, Moss SE, Davis MD, DeMets DL. The Wisconsin Epidemiologic Study of Diabetic Retinopathy. II. Prevalence and risk of diabetic retinopathy when age at diagnosis is less than 30 years. *Arch Ophthalmol*. 1984;102(4):520-526.
35. Varma R, Torres M, Pena F, Klein R, Azen SP. Prevalence of diabetic retinopathy in adult Latinos: the Los Angeles Latino eye study. *Ophthalmology*. 2004;111(7):1298-1306.
36. Hirai FE, Knudtson MD, Klein BE, Klein R. Clinically significant macular edema and survival in type 1 and type 2 diabetes. *Am J Ophthalmol*. 2008;145(4):700-706.
37. West SK, Klein R, Rodriguez J, et al. Diabetes and diabetic retinopathy in a Mexican-American population: Proyecto VER. *Diabetes Care*. 2001;24(7):1204-1209.
38. Tan GS, Gan A, Sabanayagam C, et al. Ethnic differences in the prevalence and risk factors of diabetic retinopathy: the Singapore Epidemiology of Eye Diseases study. *Ophthalmology*. 2018;125(4):529-536.
39. Rudnisky CJ, Wong BK, Virani H, Tennant MTS. Risk factors for progression of diabetic retinopathy in Alberta First Nations communities. *Can J Ophthalmol*. 2017;52 Suppl 1:S19-S29.
40. Klein R, Klein BE, Moss SE, Davis MD, DeMets DL. The Wisconsin Epidemiologic Study of Diabetic Retinopathy. III. Prevalence and risk of diabetic retinopathy when age at diagnosis is 30 or more years. *Arch Ophthalmol*. 1984;102(4):527-532.
41. Xie X, Atkins E, Lv J, et al. Effects of intensive blood pressure lowering on cardiovascular and renal outcomes: updated systematic review and meta-analysis. *Lancet*. 2016;387(10017):435-443.
42. Diabetes Control and Complications Trial Research Group. Progression of retinopathy with intensive versus conventional treatment in the Diabetes Control and Complications Trial. *Ophthalmology*. 1995;102(4):647-661.
43. Diabetes Control and Complications Trial/Epidemiology of Diabetes Interventions and Complications Research Group. Retinopathy and nephropathy in patients with type 1 diabetes four years after a trial of intensive therapy. *N Engl J Med*. 2000;342(6):381-389.
44. Diabetes Control and Complications Trial Research Group. The relationship of glycemic exposure (HbA1c) to the risk of development and progression of retinopathy in the Diabetes Control and Complications Trial. *Diabetes*. 1995;44(8):968-983.

45. Writing Team for the Diabetes Control and Complications Trial/Epidemiology of Diabetes Interventions and Complications Research Group. Effect of intensive therapy on the microvascular complications of type 1 diabetes mellitus. *JAMA*. 2002;287(19):2563-2569.
46. UK Prospective Diabetes Study (UKPDS) Group. Intensive blood-glucose control with sulphonylureas or insulin compared with conventional treatment and risk of complications in patients with type 2 diabetes (UKPDS 33). *Lancet*. 1998;352(9131):837-853.
47. Kohner EM, Stratton IM, Aldington SJ, Holman RR, Matthews DR. Relationship between the severity of retinopathy and progression to photocoagulation in patients with Type 2 diabetes mellitus in the UKPDS (UKPDS 52). *Diabet Med*. 2001;18(3):178-184.
48. Wong TY, Liew G, Tapp RJ, et al. Relation between fasting glucose and retinopathy for diagnosis of diabetes: three population-based cross-sectional studies. *Lancet*. 2008;371(9614):736-743.
49. White NH, Sun W, Cleary PA, et al. Prolonged effect of intensive therapy on the risk of retinopathy complications in patients with type 1 diabetes mellitus: 10 years after the Diabetes Control and Complications Trial. *Arch Ophthalmol*. 2008;126(12):1707-1715.
50. Buehler AM, Cavalcanti AB, Berwanger O, et al. Effect of tight blood glucose control versus conventional control in patients with type 2 diabetes mellitus: a systematic review with meta-analysis of randomized controlled trials. *Cardiovasc Ther*. 2013;31(3):147-160.
51. Do DV, Wang X, Vedula SS, et al. Blood pressure control for diabetic retinopathy. *Cochrane Database Syst Rev*. 2015;1:CD006127.
52. Fullerton B, Jeitler K, Seitz M, Horvath K, Berghold A, Siebenhofer A. Intensive glucose control versus conventional glucose control for type 1 diabetes mellitus. *Cochrane Database Syst Rev*. 2014(2):CD009122.
53. Virk SA, Donaghue KC, Wong TY, Craig ME. Interventions for Diabetic Retinopathy in Type 1 Diabetes: Systematic Review and Meta-Analysis. *Am J Ophthalmol*. 2015;160(5):1055-1064 e1054.
54. Davis MD, Fisher MR, Gangnon RE, et al. Risk factors for high-risk proliferative diabetic retinopathy and severe visual loss: Early Treatment Diabetic Retinopathy Study report number 18. *Invest Ophthalmol Vis Sci*. 1998;39(2):233-252.
55. Kilpatrick ES, Rigby AS, Atkin SL, Frier BM. Does severe hypoglycaemia influence microvascular complications in Type 1 diabetes? An analysis of the Diabetes Control and Complications Trial database. *Diabet Med*. 2012;29(9):1195-1198.
56. American Diabetes Association. Standards of medical care in diabetes--2013. *Diabetes Care*. 2013;36 Suppl 1:S11-66.
57. Varma R, Bressler NM, Doan QV, et al. Prevalence of and risk factors for diabetic macular edema in the United States. *JAMA Ophthalmol*. 2014;132(11):1334-1340.
58. UK Prospective Diabetes Study Group. Tight blood pressure control and risk of macrovascular and microvascular complications in type 2 diabetes: UKPDS 38. *BMJ*. 1998;317(7160):703-713.
59. Snow V, Weiss KB, Mottur-Pilson C. The evidence base for tight blood pressure control in the management of type 2 diabetes mellitus. *Ann Intern Med*. 2003;138(7):587-592.
60. van Leiden HA, Dekker JM, Moll AC, et al. Blood pressure, lipids, and obesity are associated with retinopathy: The Hoorn Study. *Diabetes Care*. 2002;25(8):1320-1325.
61. Klein R, Sharrett AR, Klein BE, et al. The association of atherosclerosis, vascular risk factors, and retinopathy in adults with diabetes: the atherosclerosis risk in communities study. *Ophthalmology*. 2002;109(7):1225-1234.
62. Lyons TJ, Jenkins AJ, Zheng D, et al. Diabetic retinopathy and serum lipoprotein subclasses in the DCCT/EDIC cohort. *Invest Ophthalmol Vis Sci*. 2004;45(3):910-918.
63. Lopes-Virella MF, Baker NL, Hunt KJ, Lyons TJ, Jenkins AJ, Virella G. High concentrations of AGE-LDL and oxidized LDL in circulating immune complexes are associated with progression of retinopathy in type 1 diabetes. *Diabetes Care*. 2012;35(6):1333-1340.
64. Kang EY, Chen TH, Garg SJ, et al. Association of Statin Therapy With Prevention of Vision-Threatening Diabetic Retinopathy. *JAMA Ophthalmol*. 2019.
65. Klein R, Klein BE, Moss SE, Davis MD, DeMets DL. The Wisconsin Epidemiologic Study of Diabetic Retinopathy. IX. Four-year incidence and progression of diabetic retinopathy when age at diagnosis is less than 30 years. *Arch Ophthalmol*. 1989;107(2):237-243.
66. Klein R, Klein BE, Moss SE, Davis MD, DeMets DL. The Wisconsin Epidemiologic Study of Diabetic Retinopathy. X. Four-year incidence and progression of diabetic retinopathy when age at diagnosis is 30 years or more. *Arch Ophthalmol*. 1989;107(2):244-249.



67. Kriska AM, LaPorte RE, Patrick SL, Kuller LH, Orchard TJ. The association of physical activity and diabetic complications in individuals with insulin-dependent diabetes mellitus: the Epidemiology of Diabetes Complications Study--VII. *J Clin Epidemiol*. 1991;44(11):1207-1214.
68. Muni RH, Kohly RP, Lee EQ, Manson JE, Semba RD, Schaumberg DA. Prospective study of inflammatory biomarkers and risk of diabetic retinopathy in the diabetes control and complications trial. *JAMA Ophthalmol*. 2013;131(4):514-521.
69. Sumamo E, Ha C, Korownyk C, Vandermeer B, Dryden DM. In: *Lifestyle Interventions for Four Conditions: Type 2 Diabetes, Metabolic Syndrome, Breast Cancer, and Prostate Cancer*. Rockville (MD)2011.
70. American Diabetes Association. Standards of medical care in diabetes--2008. *Diabetes Care*. 2008;31 Suppl 1:S12-54.
71. Mohamed Q, Gillies MC, Wong TY. Management of diabetic retinopathy: a systematic review. *JAMA*. 2007;298(8):902-916.
72. Shi R, Zhao L, Wang F, et al. Effects of lipid-lowering agents on diabetic retinopathy: a Meta-analysis and systematic review. *Int J Ophthalmol*. 2018;11(2):287-295.
73. Mitchell SL, Neining AC, Bruce CN, et al. Mitochondrial haplogroups modify the effect of diabetes duration and HbA1c on proliferative diabetic retinopathy risk in patients with type 2 diabetes. *Invest Ophthalmol Vis Sci*. 2017;58(14):6481-6488.
74. Liu E, Kaidonis G, Gillies MC, et al. Mitochondrial haplogroups are not associated with diabetic retinopathy in a large Australian and British Caucasian sample. *Nature Research Scientific Reports*. 2019;9(612).
75. Chiefari E, Ventura V, Capula C, et al. A polymorphism of HMGA1 protects against proliferative diabetic retinopathy by impairing HMGA1-induced VEGFA expression. *Sci Rep*. 2016;6:39429.
76. Grundy SM, Brewer HB, Jr., Cleeman JI, et al. Definition of metabolic syndrome: Report of the National Heart, Lung, and Blood Institute/American Heart Association conference on scientific issues related to definition. *Circulation*. 2004;109(3):433-438.
77. Lee MY, Hsiao PJ, Huang JC, Hsu WH, Chen SC, Shin SJ. Association between metabolic syndrome and microvascular and macrovascular disease in type 2 diabetic mellitus. *Am J Med Sci*. 2018;355(4):342-349.
78. Lee CS, Lee AY, Baughman D, et al. The United Kingdom Diabetic Retinopathy Electronic Medical Record Users Group: Report 3: Baseline retinopathy and clinical features predict progression of diabetic retinopathy. *Am J Ophthalmol*. 2017;180:64-71.
79. Bressler SB, Beaulieu WT, Glassman AR, et al. Factors associated with worsening proliferative diabetic retinopathy in eyes treated with panretinal photocoagulation or ranibizumab. *Ophthalmology*. 2017;124(4):431-439.
80. Ferris FL, III. How effective are treatments for diabetic retinopathy? *JAMA*. 1993;269(10):1290-1291.
81. Diabetes Control and Complications Trial Research Group. The effect of intensive treatment of diabetes on the development and progression of long-term complications in insulin-dependent diabetes mellitus. *N Engl J Med*. 1993;329(14):977-986.
82. Diabetes Control and Complications Trial Research Group. The effect of intensive diabetes treatment on the progression of diabetic retinopathy in insulin-dependent diabetes mellitus: the Diabetes Control and Complications Trial. *Arch Ophthalmol*. 1995;113(1):36-51.
83. Epidemiology of Diabetes Interventions and Complications (EDIC) Research Group. Epidemiology of Diabetes Interventions and Complications (EDIC): design, implementation, and preliminary results of a long-term follow-up of the Diabetes Control and Complications Trial cohort. *Diabetes Care*. 1999;22(1):99-111.
84. Diabetes Control and Complications Trial/Epidemiology of Diabetes Interventions and Complications (DCCT/EDIC) Research Group. Modern-day clinical course of type 1 diabetes mellitus after 30 years' duration: the diabetes control and complications trial/epidemiology of diabetes interventions and complications and Pittsburgh Epidemiology of Diabetes complications experience (1983-2005). *Arch Intern Med*. 2009;169(14):1307-1316.
85. Diabetic Retinopathy Study Research Group. Indications for photocoagulation treatment of diabetic retinopathy: Diabetic Retinopathy Study report number 14. *Int Ophthalmol Clin*. 1987;27(4):239-253.
86. Diabetic Retinopathy Study Research Group. Photocoagulation treatment of proliferative diabetic retinopathy: the second report of Diabetic Retinopathy Study findings. *Ophthalmology*. 1978;85(1):82-106.

87. Early Treatment Diabetic Retinopathy Study Research Group. Grading diabetic retinopathy from stereoscopic color fundus photographs--an extension of the modified Airlie House classification: ETDRS report number 10. *Ophthalmology*. 1991;98(5 Suppl):786-806.
88. Early Treatment Diabetic Retinopathy Study Research Group. Fundus photographic risk factors for progression of diabetic retinopathy: ETDRS report number 12. *Ophthalmology*. 1991;98(5 Suppl):823-833.
89. Early Treatment Diabetic Retinopathy Study Research Group. Photocoagulation for diabetic macular edema: Early Treatment Diabetic Retinopathy Study report number 1. *Arch Ophthalmol*. 1985;103(12):1796-1806.
90. Diabetic Retinopathy Vitrectomy Study Research Group. Early vitrectomy for severe vitreous hemorrhage in diabetic retinopathy: four-year results of a randomized trial--Diabetic Retinopathy Vitrectomy Study report 5. *Arch Ophthalmol*. 1990;108(7):958-964.
91. Klein R, Klein BE, Moss SE, Cruickshanks KJ. The Wisconsin Epidemiologic Study of diabetic retinopathy. XIV. Ten-year incidence and progression of diabetic retinopathy. *Arch Ophthalmol*. 1994;112(9):1217-1228.
92. Scott R, Best J, Forder P, et al. FIELD Study Investigators. Fenofibrate Intervention and Event Lowering in Diabetes (FIELD) study: baseline characteristics and short-term effects of fenofibrate [ISRCTN64783481]. *Cardiovasc Diabetol*. 2005;4:13.
93. Goff DC, Jr., Gerstein HC, Ginsberg HN, et al. ACCORD Study Group. Prevention of cardiovascular disease in persons with type 2 diabetes mellitus: current knowledge and rationale for the Action to Control Cardiovascular Risk in Diabetes (ACCORD) trial. *Am J Cardiol*. 2007;99(12A):4i-20i.
94. Diabetic Retinopathy Clinical Research Network, Elman MJ, Qin H, et al. Intravitreal ranibizumab for diabetic macular edema with prompt versus deferred laser treatment: three-year randomized trial results. *Ophthalmology*. 2012;119(11):2312-2318.
95. Writing Committee for the Diabetic Retinopathy Clinical Research Network. Panretinal photocoagulation vs intravitreal ranibizumab for proliferative diabetic retinopathy: a randomized clinical trial. *JAMA*. 2015;314(20):2137-2146.
96. Diabetic Retinopathy Clinical Research Network. Aflibercept, bevacizumab, or ranibizumab for diabetic macular edema. *N Engl J Med*. 2015;372(13):1193-1203.
97. UK Prospective Diabetes Study (UKPDS) Group. Effect of intensive blood-glucose control with metformin on complications in overweight patients with type 2 diabetes (UKPDS 34). *Lancet*. 1998;352(9131):854-865.
98. Early Treatment Diabetic Retinopathy Study Research Group. Fluorescein angiographic risk factors for progression of diabetic retinopathy: ETDRS report number 13. *Ophthalmology*. 1991;98(5 Suppl):834-840.
99. Early Treatment Diabetic Retinopathy Study Research Group. Classification of diabetic retinopathy from fluorescein angiograms: ETDRS report number 11. *Ophthalmology*. 1991;98(5 Suppl):807-822.
100. Klein R, Klein BE, Moss SE, Cruickshanks KJ. The Wisconsin Epidemiologic Study of Diabetic Retinopathy: XVII. The 14-year incidence and progression of diabetic retinopathy and associated risk factors in type 1 diabetes. *Ophthalmology*. 1998;105(10):1801-1815.
101. Klein R, Moss SE, Klein BE, Davis MD, DeMets DL. The Wisconsin epidemiologic study of diabetic retinopathy. XI. The incidence of macular edema. *Ophthalmology*. 1989;96(10):1501-1510.
102. Wang SY, Andrews CA, Herman WH, Gardner TW, Stein JD. Incidence and risk factors for developing diabetic retinopathy among youths with type 1 or type 2 diabetes throughout the United States. *Ophthalmology*. 2017;124(4):424-430.
103. Williams GA, Scott IU, Haller JA, Maguire AM, Marcus D, McDonald HR. Single-field fundus photography for diabetic retinopathy screening: a report by the American Academy of Ophthalmology. *Ophthalmology*. 2004;111(5):1055-1062.
104. Lin DY, Blumenkranz MS, Brothers RJ, Grosvenor DM. The sensitivity and specificity of single-field nonmydriatic monochromatic digital fundus photography with remote image interpretation for diabetic retinopathy screening: a comparison with ophthalmoscopy and standardized mydriatic color photography. *Am J Ophthalmol*. 2002;134(2):204-213.
105. Larsen N, Godt J, Grunkin M, Lund-Andersen H, Larsen M. Automated detection of diabetic retinopathy in a fundus photographic screening population. *Invest Ophthalmol Vis Sci*. 2003;44(2):767-771.
106. Leese GP, Ellis JD, Morris AD, Ellingford A. Does direct ophthalmoscopy improve retinal screening for diabetic eye disease by retinal photography? *Diabet Med*. 2002;19(10):867-869.

107. Ahmed J, Ward TP, Bursell SE, Aiello LM, Cavallerano JD, Vigersky RA. The sensitivity and specificity of nonmydriatic digital stereoscopic retinal imaging in detecting diabetic retinopathy. *Diabetes Care*. 2006;29(10):2205-2209.
108. Velez R, Haffner S, Stern MP, Vanheuveren WAJ. Ophthalmologist vs retinal photographs in screening for diabetic retinopathy. *Clinical Research*. 1987;35(3):A363.
109. Pugh JA, Jacobson JM, Van Heuven WA, et al. Screening for diabetic retinopathy. The wide-angle retinal camera. *Diabetes Care*. 1993;16(6):889-895.
110. Lawrence MG. The accuracy of digital-video retinal imaging to screen for diabetic retinopathy: an analysis of two digital-video retinal imaging systems using standard stereoscopic seven-field photography and dilated clinical examination as reference standards. *Trans Am Ophthalmol Soc*. 2004;102:321-340.
111. Abramoff MD, Folk JC, Han DP, et al. Automated analysis of retinal images for detection of referable diabetic retinopathy. *JAMA Ophthalmol*. 2013;131(3):351-357.
112. Rudnisky CJ, Hinz BJ, Tennant MT, de Leon AR, Greve MD. High-resolution stereoscopic digital fundus photography versus contact lens biomicroscopy for the detection of clinically significant macular edema. *Ophthalmology*. 2002;109(2):267-274.
113. Cavallerano JD, Aiello LP, Cavallerano AA, et al. Nonmydriatic digital imaging alternative for annual retinal examination in persons with previously documented no or mild diabetic retinopathy. *Am J Ophthalmol*. 2005;140(4):667-673.
114. Fonda SJ, Bursell SE, Lewis DG, Garren J, Hock K, Cavallerano J. The relationship of a diabetes telehealth eye care program to standard eye care and change in diabetes health outcomes. *Telemed J E Health*. 2007;13(6):635-644.
115. Conlin PR, Fisch BM, Cavallerano AA, Cavallerano JD, Bursell SE, Aiello LM. Nonmydriatic teleretinal imaging improves adherence to annual eye examinations in patients with diabetes. *J Rehabil Res Dev*. 2006;43(6):733-740.
116. Diamond JP, McKinnon M, Barry C, et al. Non-mydriatic fundus photography: a viable alternative to fundoscopy for identification of diabetic retinopathy in an Aboriginal population in rural Western Australia? *Aust N Z J Ophthalmol*. 1998;26(2):109-115.
117. Klein R, Klein BE. Screening for diabetic retinopathy, revisited. *Am J Ophthalmol*. 2002;134(2):261-263.
118. Maberley D, Walker H, Koushik A, Cruess A. Screening for diabetic retinopathy in James Bay, Ontario: a cost-effectiveness analysis. *CMAJ*. 2003;168(2):160-164.
119. Farley TF, Mandava N, Prall FR, Carsky C. Accuracy of primary care clinicians in screening for diabetic retinopathy using single-image retinal photography. *Ann Fam Med*. 2008;6(5):428-434.
120. Li HK, Horton M, Bursell SE, et al. Telehealth practice recommendations for diabetic retinopathy, second edition. *Telemed J E Health*. 2011;17(10):814-837.
121. Lueder GT, Silverstein J. American Academy of Pediatrics Section on Ophthalmology and Section on Endocrinology. Screening for retinopathy in the pediatric patient with type 1 diabetes mellitus. *Pediatrics*. 2005;116(1):270-273. Reaffirmed 2014.
122. Diabetes Prevention Program Research Group. The prevalence of retinopathy in impaired glucose tolerance and recent-onset diabetes in the Diabetes Prevention Program. *Diabet Med*. 2007;24(2):137-144.
123. Klein BE, Moss SE, Klein R. Effect of pregnancy on progression of diabetic retinopathy. *Diabetes Care*. 1990;13(1):34-40.
124. Chew EY, Mills JL, Metzger BE, et al. Metabolic control and progression of retinopathy. The Diabetes in Early Pregnancy Study. National Institute of Child Health and Human Development Diabetes in Early Pregnancy Study. *Diabetes Care*. 1995;18(5):631-637.
125. Diabetes Control and Complications Trial Research Group. Effect of pregnancy on microvascular complications in the diabetes control and complications trial. *Diabetes Care*. 2000;23(8):1084-1091.
126. UK Prospective Diabetes Study (UKPDS). VIII. Study design, progress and performance. *Diabetologia*. 1991;34(12):877-890.
127. Early Treatment Diabetic Retinopathy Study Research Group. Effects of aspirin treatment on diabetic retinopathy: ETDRS report number 8. *Ophthalmology*. 1991;98(5 Suppl):757-765.
128. Chew EY, Klein ML, Murphy RP, Remaley NA, Ferris FL, III. Effects of aspirin on vitreous/preretinal hemorrhage in patients with diabetes mellitus: Early Treatment Diabetic Retinopathy Study report number 20. *Arch Ophthalmol*. 1995;113(1):52-55.



129. Eye Disease Case-Control Study Group. Risk factors for idiopathic rhegmatogenous retinal detachment. *Am J Epidemiol.* 1993;137(7):749-757.
130. Klein R, Klein BE, Moss SE, Davis MD, DeMets DL. Glycosylated hemoglobin predicts the incidence and progression of diabetic retinopathy. *JAMA.* 1988;260(19):2864-2871.
131. Chew EY, Klein ML, Ferris FL, III, et al. Association of elevated serum lipid levels with retinal hard exudate in diabetic retinopathy: Early Treatment Diabetic Retinopathy Study (ETDRS) report 22. *Arch Ophthalmol.* 1996;114(9):1079-1084.
132. Early Treatment Diabetic Retinopathy Study Research Group. Early photocoagulation for diabetic retinopathy: ETDRS report number 9. *Ophthalmology.* 1991;98(5 Suppl):766-785.
133. Klein R, Klein BE, Neider MW, Hubbard LD, Meuer SM, Brothers RJ. Diabetic retinopathy as detected using ophthalmoscopy, a nonmydriatic camera and a standard fundus camera. *Ophthalmology.* 1985;92(4):485-491.
134. Klein R, Klein BE, Moss SE, Davis MD, DeMets DL. Retinopathy in young-onset diabetic patients. *Diabetes Care.* 1985;8(4):311-315.
135. Frank RN, Hoffman WH, Podgor MJ, et al. Retinopathy in juvenile-onset diabetes of short duration. *Ophthalmology.* 1980;87(1):1-9.
136. Krolewski AS, Warram JH, Rand LI, Christlieb AR, Busick EJ, Kahn CR. Risk of proliferative diabetic retinopathy in juvenile-onset type I diabetes: a 40-yr follow-up study. *Diabetes Care.* 1986;9(5):443-452.
137. Klein R, Klein BE, Moss SE. Epidemiology of proliferative diabetic retinopathy. *Diabetes Care.* 1992;15(12):1875-1891.
138. Gunderson EP, Lewis CE, Tsai AL, et al. A 20-year prospective study of childbearing and incidence of diabetes in young women, controlling for glycemia before conception: the Coronary Artery Risk Development in Young Adults (CARDIA) Study. *Diabetes.* 2007;56(12):2990-2996.
139. Hirano T, Kitahara J, Toriyama Y, Kasamatsu H, Murata T, Sadda S. Quantifying vascular density and morphology using different swept-source optical coherence tomography angiographic scan patterns in diabetic retinopathy. *Br J Ophthalmol.* 2018.
140. Nesper PL, Roberts PK, Onishi AC, et al. Quantifying microvascular abnormalities with increasing severity of diabetic retinopathy using optical coherence tomography angiography. *Invest Ophthalmol Vis Sci.* 2017;58(6):BIO307-BIO315.
141. Onishi AC, Nesper PL, Roberts PK, et al. Importance of considering the middle capillary plexus on OCT angiography in diabetic retinopathy. *Invest Ophthalmol Vis Sci.* 2018;59(5):2167-2176.
142. Samara WA, Shahlaee A, Adam MK, et al. Quantification of diabetic macular ischemia using optical coherence tomography angiography and its relationship with visual acuity. *Ophthalmology.* 2017;124(2):235-244.
143. Kaiser PK, Riemann CD, Sears JE, Lewis H. Macular traction detachment and diabetic macular edema associated with posterior hyaloidal traction. *Am J Ophthalmol.* 2001;131(1):44-49.
144. Martidis A, Duker JS, Greenberg PB, et al. Intravitreal triamcinolone for refractory diabetic macular edema. *Ophthalmology.* 2002;109(5):920-927.
145. Strom C, Sander B, Larsen N, Larsen M, Lund-Andersen H. Diabetic macular edema assessed with optical coherence tomography and stereo fundus photography. *Invest Ophthalmol Vis Sci.* 2002;43(1):241-245.
146. McDonald HR, Williams GA, Scott IU, Haller JA, Maguire AM, Marcus DM. Laser scanning imaging for macular disease: a report by the American Academy of Ophthalmology. *Ophthalmology.* 2007;114(6):1221-1228.
147. Virgili G, Menchini F, Dimastrogiovanni AF, et al. Optical coherence tomography versus stereoscopic fundus photography or biomicroscopy for diagnosing diabetic macular edema: a systematic review. *Invest Ophthalmol Vis Sci.* 2007;48(11):4963-4973.
148. Bressler NM, Edwards AR, Antoszyk AN, et al. Retinal thickness on Stratus optical coherence tomography in people with diabetes and minimal or no diabetic retinopathy. *Am J Ophthalmol.* 2008;145(5):894-901.
149. Davis MD, Bressler SB, Aiello LP, et al. Comparison of time-domain OCT and fundus photographic assessments of retinal thickening in eyes with diabetic macular edema. *Invest Ophthalmol Vis Sci.* 2008;49(5):1745-1752.
150. Do DV, Nguyen QD, Khwaja AA, et al. READ-2 Study Group. Ranibizumab for edema of the macula in diabetes study: 3-year outcomes and the need for prolonged frequent treatment. *JAMA Ophthalmol.* 2013;131(2):139-145.

151. Brown DM, Nguyen QD, Marcus DM, et al. RIDE and RISE Research Group. Long-term outcomes of ranibizumab therapy for diabetic macular edema: the 36-month results from two phase III trials: RISE and RIDE. *Ophthalmology*. 2013;120(10):2013-2022.
152. Wells JA, Glassman AR, Ayala AR, et al. Aflibercept, bevacizumab, or ranibizumab for diabetic macular edema: two-year results from a comparative effectiveness randomized clinical trial. *Ophthalmology*. 2016;123(6):1351-1359.
153. Dhoot DS, Baker K, Saroj N, et al. Baseline factors affecting changes in diabetic retinopathy severity scale score after intravitreal aflibercept or laser for diabetic macular edema: post hoc analyses from VISTA and VIVID. *Ophthalmology*. 2018;125(1):51-56.
154. Browning DJ, Glassman AR, Aiello LP, et al. Relationship between optical coherence tomography-measured central retinal thickness and visual acuity in diabetic macular edema. *Ophthalmology*. 2007;114(3):525-536.
155. Browning DJ, Apte RS, Bressler SB, et al. Association of the extent of diabetic macular edema as assessed by optical coherence tomography with visual acuity and retinal outcome variables. *Retina*. 2009;29(3):300-305.
156. Early Treatment Diabetic Retinopathy Study Research Group. Focal photocoagulation treatment of diabetic macular edema. Relationship of treatment effect to fluorescein angiographic and other retinal characteristics at baseline: ETDRS report number 19. *Arch Ophthalmol*. 1995;113(9):1144-1155.
157. Silva PS, Dela Cruz AJ, Ledesma MG, et al. Diabetic Retinopathy Severity and Peripheral Lesions Are Associated with Nonperfusion on Ultrawide Field Angiography. *Ophthalmology*. 2015;122(12):2465-2472.
158. Yannuzzi LA, Rohrer KT, Tindel LJ, et al. Fluorescein angiography complication survey. *Ophthalmology*. 1986;93(5):611-617.
159. Sunness JS. The pregnant woman's eye. *Surv Ophthalmol*. 1988;32(4):219-238.
160. Kim AY, Chu Z, Shahidzadeh A, Wang RK, Puliafito CA, Kashani AH. Quantifying microvascular density and morphology in diabetic retinopathy using spectral-domain optical coherence tomography angiography. *Invest Ophthalmol Vis Sci*. 2016;57(9):OCT362-370.
161. Lu Y, Simonett JM, Wang J, et al. Evaluation of automatically quantified foveal avascular zone metrics for diagnosis of diabetic retinopathy using optical coherence tomography angiography. *Invest Ophthalmol Vis Sci*. 2018;59(6):2212-2221.
162. Hwang TS, Zhang M, Bhavsar K, et al. Visualization of 3 distinct retinal plexuses by projection-resolved optical coherence tomography angiography in diabetic retinopathy. *JAMA Ophthalmol*. 2016;134(12):1411-1419.
163. Ashraf M, Nesper PL, Jampo L, Yu F, Fawzi AA. Statistical model of optical coherence tomography angiography parameters that correlate with severity of diabetic retinopathy. *Invest Ophthalmol Vis Sci*. 2018: In press.
164. Hwang TS, Jia Y, Gao SS, et al. Optical coherence tomography angiography features of diabetic retinopathy. *Retina*. 2015;35(11):2371-2376.
165. Couturier A, Mane V, Bonnin S, et al. Capillary plexus anomalies in diabetic retinopathy on optical coherence tomography angiography. *Retina*. 2015;35(11):2384-2391.
166. Vujosevic S, Muraca A, Alkabes M, et al. Early microvascular and neural changes in patients with type 1 and type 2 diabetes mellitus without clinical signs of diabetic retinopathy. *Retina*. 2017:[Epub ahead of print].
167. Russell JF, Shi Y, Hinkle JW, et al. Longitudinal Wide Field Swept Source OCT Angiography of Neovascularization in Proliferative Diabetic Retinopathy After Panretinal Photocoagulation. *Ophthalmology*. 2018.
168. Ishibazawa A, Nagaoka T, Yokota H, et al. Characteristics of Retinal Neovascularization in Proliferative Diabetic Retinopathy Imaged by Optical Coherence Tomography Angiography. *Invest Ophthalmol Vis Sci*. 2016;57(14):6247-6255.
169. Spaide RF, Fujimoto JG, Waheed NK. Image artifacts in optical coherence tomography angiography. *Retina*. 2015;35(11):2163-2180.
170. Fawzi AA. Consensus on OCT angiography nomenclature: Do we need to develop and learn a new language? *JAMA Ophthalmol*. 2018: In press.
171. Hirano T, Kakihara S, Toriyama Y, Nittala MG, Murata T, Sadda S. Wide-field en face swept-source optical coherence tomography angiography using extended field imaging in diabetic retinopathy. *Br J Ophthalmol*. 2017:[Epub ahead of print].

172. Sawada O, Ichiyama Y, Obata S, et al. Comparison between wide-angle OCT angiography and ultra-wide field fluorescein angiography for detecting non-perfusion areas and retinal neovascularization in eyes with diabetic retinopathy. *Graefes Arch Clin Exp Ophthalmol*. 2018;256(7):1275-1280.
173. Schaal KB, Munk MR, Wyssmueller I, Berger LE, Zinkernagel MS, Wolf S. Vascular Abnormalities in diabetic retinopathy assessed with swept-source optical coherence tomography angiography widefield imaging. *Retina*. 2017:[Epub ahead of print].
174. Hutton DW, Stein JD, Bressler NM, et al. Cost-effectiveness of Intravitreal Ranibizumab Compared With Panretinal Photocoagulation for Proliferative Diabetic Retinopathy: Secondary Analysis From a Diabetic Retinopathy Clinical Research Network Randomized Clinical Trial. *JAMA Ophthalmol*. 2017;135(6):576-584.
175. Ross EL, Hutton DW, Stein JD, et al. Cost-effectiveness of Aflibercept, Bevacizumab, and Ranibizumab for Diabetic Macular Edema Treatment: Analysis From the Diabetic Retinopathy Clinical Research Network Comparative Effectiveness Trial. *JAMA Ophthalmol*. 2016;134(8):888-896.
176. National Diabetes Education Program. *Redesigning the Health Care Team: Diabetes Prevention and Lifelong Management*. Bethesda, MD: CreateSpace Publishing; 2014.
177. Tuomilehto J, Lindstrom J, Eriksson JG, et al. Prevention of type 2 diabetes mellitus by changes in lifestyle among subjects with impaired glucose tolerance. *N Engl J Med*. 2001;344(18):1343-1350.
178. Knowler WC, Barrett-Connor E, Fowler SE, et al. Reduction in the incidence of type 2 diabetes with lifestyle intervention or metformin. *N Engl J Med*. 2002;346(6):393-403.
179. Assurance NCfQ. State of Health Care Quality Report. 2017. <https://www.ncqa.org/report-cards/health-plans/state-of-health-care-quality-report/>. Accessed September 2019.
180. Kraft SK, Marrero DG, Lazaridis EN, Fineberg N, Qiu C, Clark CM, Jr. Primary care physicians' practice patterns and diabetic retinopathy: current levels of care. *Arch Fam Med*. 1997;6(1):29-37.
181. Paz SH, Varma R, Klein R, Wu J, Azen SP. Los Angeles Latino Eye Study Group. Noncompliance with vision care guidelines in Latinos with type 2 diabetes mellitus: the Los Angeles Latino Eye Study. *Ophthalmology*. 2006;113(8):1372-1377.
182. National Committee for Quality Assurance. Improving quality and patient experience: the state of health care quality 2013. 2013:53. Available at: [www.ncqa.org/Portals/0/Newsroom/SOHC/2013/SOHC-web\\_version\\_report.pdf](http://www.ncqa.org/Portals/0/Newsroom/SOHC/2013/SOHC-web_version_report.pdf). Accessed September 2019.
183. Glassman AR, Beck RW, Browning DJ, Danis RP, Kollman C. Comparison of optical coherence tomography in diabetic macular edema, with and without reading center manual grading from a clinical trials perspective. *Invest Ophthalmol Vis Sci*. 2009;50(2):560-566.
184. Diabetic Retinopathy Clinical Research N, Brucker AJ, Qin H, et al. Observational study of the development of diabetic macular edema following panretinal (scatter) photocoagulation given in 1 or 4 sittings. *Arch Ophthalmol*. 2009;127(2):132-140.
185. Colucciello M. Vision loss due to macular edema induced by rosiglitazone treatment of diabetes mellitus. *Arch Ophthalmol*. 2005;123(9):1273-1275.
186. Ryan EH, Jr., Han DP, Ramsay RC, et al. Diabetic macular edema associated with glitazone use. *Retina*. 2006;26(5):562-570.
187. Nguyen QD, Brown DM, Marcus DM, et al. Ranibizumab for diabetic macular edema: results from 2 phase III randomized trials: RISE and RIDE. *Ophthalmology*. 2012;119(4):789-801.
188. Olsen TW. Anti-VEGF pharmacotherapy as an alternative to panretinal laser photocoagulation for proliferative diabetic retinopathy. *JAMA*. 2015;314(20):2135-2136.
189. Elman MJ, Bressler NM, Qin H, et al. Diabetic Retinopathy Clinical Research Network. Expanded 2-year follow-up of ranibizumab plus prompt or deferred laser or triamcinolone plus prompt laser for diabetic macular edema. *Ophthalmology*. 2011;118(4):609-614.
190. Baker CW, Glassman AR, Beaulieu WT, et al. Effect of Initial Management With Aflibercept vs Laser Photocoagulation vs Observation on Vision Loss Among Patients With Diabetic Macular Edema Involving the Center of the Macula and Good Visual Acuity: A Randomized Clinical Trial. *JAMA*. 2019.
191. Early Treatment Diabetic Retinopathy Study Research Group. Photocoagulation for diabetic macular edema: Early Treatment Diabetic Retinopathy Study report number 4. *Int Ophthalmol Clin*. 1987;27(4):265-272.
192. Chalam KV, Bressler SB, Edwards AR, et al. Retinal thickness in people with diabetes and minimal or no diabetic retinopathy: Heidelberg Spectralis optical coherence tomography. *Invest Ophthalmol Vis Sci*. 2012;53(13):8154-8161.

193. Early Treatment Diabetic Retinopathy Study Research Group. Early Treatment Diabetic Retinopathy Study design and baseline patient characteristics: ETDRS report number 7. *Ophthalmology*. 1991;98(5 Suppl):741-756.
194. Diabetic Retinopathy Clinical Research N, Elman MJ, Aiello LP, et al. Randomized trial evaluating ranibizumab plus prompt or deferred laser or triamcinolone plus prompt laser for diabetic macular edema. *Ophthalmology*. 2010;117(6):1064-1077 e1035.
195. Do DV, Nguyen QD, Boyer D, et al. DA VINCI Study Group. One-year outcomes of the DA VINCI Study of VEGF Trap-Eye in eyes with diabetic macular edema. *Ophthalmology*. 2012;119(8):1658-1665.
196. Diabetic Retinopathy Clinical Research Network, Googe J, Brucker AJ, Bressler NM, et al. Randomized trial evaluating short-term effects of intravitreal ranibizumab or triamcinolone acetate on macular edema after focal/grid laser for diabetic macular edema in eyes also receiving panretinal photocoagulation. *Retina*. 2011;31(6):1009-1027.
197. Diabetic Retinopathy Clinical Research Network, Elman MJ, Aiello LP, Beck RW, et al. Randomized trial evaluating ranibizumab plus prompt or deferred laser or triamcinolone plus prompt laser for diabetic macular edema. *Ophthalmology*. 2010;117(6):1064-1077.
198. Ho AC, Scott IU, Kim SJ, et al. Anti-vascular endothelial growth factor pharmacotherapy for diabetic macular edema: a report by the American Academy of Ophthalmology. *Ophthalmology*. 2012;119(10):2179-2188.
199. Mitchell P, Bandello F, Schmidt-Erfurth U, et al. RESTORE Study Group. The RESTORE study: ranibizumab monotherapy or combined with laser versus laser monotherapy for diabetic macular edema. *Ophthalmology*. 2011;118(4):615-625.
200. Thomas BJ, Shienbaum G, Boyer DS, Flynn HW, Jr. Evolving strategies in the management of diabetic macular edema: clinical trials and current management. *Can J Ophthalmol*. 2013;48(1):22-30.
201. US Food and Drug Administration, Center for Drug Evaluation and Research. Lucentis (ranibizumab injection). BLA 25156. Available at: [www.accessdata.fda.gov/drugsatfda\\_docs/label/2012/125156s0069s0076lbl.pdf](http://www.accessdata.fda.gov/drugsatfda_docs/label/2012/125156s0069s0076lbl.pdf). Accessed September 2019.
202. Payne JF, Wykoff CC, Clark WL, et al. Randomized Trial of Treat and Extend Ranibizumab With and Without Navigated Laser Versus Monthly Dosing for Diabetic Macular Edema: TREX-DME 2-Year Outcomes. *Am J Ophthalmol*. 2019;202:91-99.
203. Nguyen QD, Shah SM, Khwaja AA, et al. READ-2 Study Group. Two-year outcomes of the ranibizumab for edema of the macula in diabetes (READ-2) study. *Ophthalmology*. 2010;117(11):2146-2151.
204. Rajendram R, Fraser-Bell S, Kaines A, et al. A 2-year prospective randomized controlled trial of intravitreal bevacizumab or laser therapy (BOLT) in the management of diabetic macular edema: 24-month data: report 3. *Arch Ophthalmol*. 2012;130(8):972-979.
205. Regnier S, Malcolm W, Allen F, Wright J, Bezlyak V. Efficacy of anti-VEGF and laser photocoagulation in the treatment of visual impairment due to diabetic macular edema: a systematic review and network meta-analysis. *PLoS One*. 2014;9(7):e102309.
206. Lau PE, Jenkins KS, Layton CJ. Current Evidence for the Prevention of Endophthalmitis in Anti-VEGF Intravitreal Injections. *J Ophthalmol*. 2018;2018:8567912.
207. Parke DW, II, Coleman AL, Rich WL, III, Lum F. Choosing Wisely: five ideas that physicians and patients can discuss. *Ophthalmology*. 2013;120(3):443-444.
208. Eadie BD, Etminan M, Carleton BC, Maberley DA, Mikelberg FS. Association of Repeated Intravitreal Bevacizumab Injections With Risk for Glaucoma Surgery. *JAMA Ophthalmol*. 2017;135(4):363-368.
209. Kahook MY, Ammar DA. In vitro effects of antivascular endothelial growth factors on cultured human trabecular meshwork cells. *J Glaucoma*. 2010;19(7):437-441.
210. Yannuzzi NA, Patel SN, Bhavsar KV, Sugiguchi F, Freund KB. Predictors of sustained intraocular pressure elevation in eyes receiving intravitreal anti-vascular endothelial growth factor therapy. *Am J Ophthalmol*. 2014;158(2):319-327 e312.
211. Avery RL, Gordon GM. Systemic Safety of Prolonged Monthly Anti-Vascular Endothelial Growth Factor Therapy for Diabetic Macular Edema: A Systematic Review and Meta-analysis. *JAMA Ophthalmol*. 2016;134(1):21-29.



212. Virgili G, Parravano M, Evans JR, Gordon I, Lucenteforte E. Anti-vascular endothelial growth factor for diabetic macular oedema: a network meta-analysis. *Cochrane Database Syst Rev*. 2018;10:CD007419.
213. Early Treatment Diabetic Retinopathy Study Research Group. Techniques for scatter and local photocoagulation treatment of diabetic retinopathy: Early Treatment Diabetic Retinopathy Study report number 3. *Int Ophthalmol Clin*. 1987;27(4):254-264.
214. Early Treatment Diabetic Retinopathy Study Research Group. Treatment techniques and clinical guidelines for photocoagulation of diabetic macular edema. Early Treatment Diabetic Retinopathy Study report number 2. *Ophthalmology*. 1987;94(7):761-774.
215. Fong DS, Strauber SF, Aiello LP, et al. Comparison of the modified Early Treatment Diabetic Retinopathy Study and mild macular grid laser photocoagulation strategies for diabetic macular edema. *Arch Ophthalmol*. 2007;125(4):469-480.
216. Jorge EC, Jorge EN, Botelho M, Farat JG, Virgili G, El Dib R. Monotherapy laser photocoagulation for diabetic macular oedema. *Cochrane Database Syst Rev*. 2018;10:CD010859.
217. Guyer DR, D'Amico DJ, Smith CW. Subretinal fibrosis after laser photocoagulation for diabetic macular edema. *Am J Ophthalmol*. 1992;113(6):652-656.
218. Han DP, Mieler WF, Burton TC. Submacular fibrosis after photocoagulation for diabetic macular edema. *Am J Ophthalmol*. 1992;113(5):513-521.
219. Fong DS, Segal PP, Myers F, Ferris FL, Hubbard LD, Davis MD. Early Treatment Diabetic Retinopathy Study Research Group. Subretinal fibrosis in diabetic macular edema: ETDRS report no. 23. *Arch Ophthalmol*. 1997;115(7):873-877.
220. Lewis H, Schachat AP, Haimann MH, et al. Choroidal neovascularization after laser photocoagulation for diabetic macular edema. *Ophthalmology*. 1990;97(4):503-510; discussion 510-501.
221. Diabetic Retinopathy Clinical Research Network, Chew E, Strauber S, et al. Randomized trial of peribulbar triamcinolone acetonide with and without focal photocoagulation for mild diabetic macular edema: a pilot study. *Ophthalmology*. 2007;114(6):1190-1196.
222. Diabetic Retinopathy Clinical Research Network. A randomized trial comparing intravitreal triamcinolone acetonide and focal/grid photocoagulation for diabetic macular edema. *Ophthalmology*. 2008;115(9):1447-1459.
223. Diabetic Retinopathy Clinical Research Network. Three-year follow-up of a randomized trial comparing focal/grid photocoagulation and intravitreal triamcinolone for diabetic macular edema. *Arch Ophthalmol*. 2009;127(3):245-251.
224. Diabetic Retinopathy Clinical Research N, Elman MJ, Qin H, et al. Intravitreal ranibizumab for diabetic macular edema with prompt versus deferred laser treatment: three-year randomized trial results. *Ophthalmology*. 2012;119(11):2312-2318.
225. Boyer DS, Yoon YH, Belfort R, Jr., et al. Three-year, randomized, sham-controlled trial of dexamethasone intravitreal implant in patients with diabetic macular edema. *Ophthalmology*. 2014;121(10):1904-1914.
226. Campochiaro PA, Brown DM, Pearson A, et al. Long-term benefit of sustained-delivery fluocinolone acetonide vitreous inserts for diabetic macular edema. *Ophthalmology*. 2011;118(4):626-635 e622.
227. Maturi RK, Glassman AR, Liu D, et al. Effect of adding dexamethasone to continued ranibizumab treatment in patients with persistent diabetic macular edema: a DRCR Network phase 2 randomized clinical trial. *JAMA Ophthalmol*. 2018;136(1):29-38.
228. Mehta H, Hennings C, Gillies MC, Nguyen V, Campaign A, Fraser-Bell S. Anti-vascular endothelial growth factor combined with intravitreal steroids for diabetic macular oedema. *Cochrane Database Syst Rev*. 2018;4:CD011599.
229. Massin P, Duguid G, Erginay A, Haouchine B, Gaudric A. Optical coherence tomography for evaluating diabetic macular edema before and after vitrectomy. *Am J Ophthalmol*. 2003;135(2):169-177.
230. Otani T, Kishi S. A controlled study of vitrectomy for diabetic macular edema. *Am J Ophthalmol*. 2002;134(2):214-219.
231. Yamamoto T, Hitani K, Tsukahara I, et al. Early postoperative retinal thickness changes and complications after vitrectomy for diabetic macular edema. *Am J Ophthalmol*. 2003;135(1):14-19.
232. Diabetic Retinopathy Clinical Research Network Writing Committee, Haller JA, Qin H, Apte RS, et al. Vitrectomy outcomes in eyes with diabetic macular edema and vitreomacular traction. *Ophthalmology*. 2010;117(6):1087-1093.

233. Luttrull JK, Dorin G. Subthreshold diode micropulse laser photocoagulation (SDM) as invisible retinal phototherapy for diabetic macular edema: a review. *Curr Diabetes Rev.* 2012;8(4):274-284.
234. Wu Y, Ai P, Ai Z, Xu G. Subthreshold diode micropulse laser versus conventional laser photocoagulation monotherapy or combined with anti-VEGF therapy for diabetic macular edema: A Bayesian network meta-analysis. *Biomed Pharmacother.* 2018;97:293-299.
235. Sahoo S, Barua A, Myint KT, Haq A, Abas AB, Nair NS. Topical non-steroidal anti-inflammatory agents for diabetic cystoid macular oedema. *Cochrane Database Syst Rev.* 2015(2):CD010009.
236. Schatz H, Madeira D, McDonald HR, Johnson RN. Progressive enlargement of laser scars following grid laser photocoagulation for diffuse diabetic macular edema. *Arch Ophthalmol.* 1991;109(11):1549-1551.
237. Braun CI, Benson WE, Remaley NA, Chew EY, Ferris FL, III. Accommodative amplitudes in the Early Treatment Diabetic Retinopathy Study. *Retina.* 1995;15(4):275-281.
238. Novak MA, Rice TA, Michels RG, Auer C. Vitreous hemorrhage after vitrectomy for diabetic retinopathy. *Ophthalmology.* 1984;91(12):1485-1489.
239. Gupta B, Sivaprasad S, Wong R, et al. Visual and anatomical outcomes following vitrectomy for complications of diabetic retinopathy: the DRIVE UK study. *Eye (Lond).* 2012;26(4):510-516.
240. Schachat AP, Oyakawa RT, Michels RG, Rice TA. Complications of vitreous surgery for diabetic retinopathy. II. Postoperative complications. *Ophthalmology.* 1983;90(5):522-530.
241. Aaberg TM, Van Horn DL. Late complications of pars plana vitreous surgery. *Ophthalmology.* 1978;85(2):126-140.
242. Chu KM, Chen TT, Lee PY. Clinical results of pars plana vitrectomy in posterior-segment disorders. *Ann Ophthalmol.* 1985;17(11):686-693.
243. Chew EY, Benson WE, Remaley NA, et al. Results after lens extraction in patients with diabetic retinopathy: Early Treatment Diabetic Retinopathy Study report number 25. *Arch Ophthalmol.* 1999;117(12):1600-1606.
244. Gillies MC, Sutter FK, Simpson JM, Larsson J, Ali H, Zhu M. Intravitreal triamcinolone for refractory diabetic macular edema: two-year results of a double-masked, placebo-controlled, randomized clinical trial. *Ophthalmology.* 2006;113(9):1533-1538.
245. Chieh JJ, Roth DB, Liu M, et al. Intravitreal triamcinolone acetonide for diabetic macular edema. *Retina.* 2005;25(7):828-834.
246. Diabetic Retinopathy Study Research Group. Photocoagulation treatment of proliferative diabetic retinopathy: clinical application of Diabetic Retinopathy Study (DRS) findings, DRS report number 8. *Ophthalmology.* 1981;88(7):583-600.
247. Diabetic Retinopathy Study Research Group. Four risk factors for severe visual loss in diabetic retinopathy: the third report from the Diabetic Retinopathy Study. *Arch Ophthalmol.* 1979;97(4):654-655.
248. Obeid A, Gao X, Ali FS, et al. Loss to follow-up in patients with proliferative diabetic retinopathy after panretinal photocoagulation or intravitreal anti-VEGF injections. *Ophthalmology.* 2018:[Epub ahead of print].
249. Diabetic Retinopathy Vitrectomy Study Research Group. Early vitrectomy for severe vitreous hemorrhage in diabetic retinopathy: two-year results of a randomized trial--Diabetic Retinopathy Vitrectomy Study report 2. *Arch Ophthalmol.* 1985;103(11):1644-1652.
250. Diabetic Retinopathy Vitrectomy Study Research Group. Early vitrectomy for severe proliferative diabetic retinopathy in eyes with useful vision: clinical application of results of a randomized trial--Diabetic Retinopathy Vitrectomy Study report 4. *Ophthalmology.* 1988;95(10):1321-1334.
251. Diabetic Retinopathy Vitrectomy Study Research Group. Early vitrectomy for severe proliferative diabetic retinopathy in eyes with useful vision: results of a randomized trial--Diabetic Retinopathy Vitrectomy Study report 3. *Ophthalmology.* 1988;95(10):1307-1320.
252. Writing Committee for the Diabetic Retinopathy Clinical Research N, Gross JG, Glassman AR, et al. Panretinal Photocoagulation vs Intravitreal Ranibizumab for Proliferative Diabetic Retinopathy: A Randomized Clinical Trial. *JAMA.* 2015;314(20):2137-2146.
253. Sun JK, Glassman AR, Beaulieu WT, et al. Rationale and Application of the Protocol S Anti-Vascular Endothelial Growth Factor Algorithm for Proliferative Diabetic Retinopathy. *Ophthalmology.* 2018.
254. Gross JG, Glassman AR, Liu D, et al. Five-Year Outcomes of Panretinal Photocoagulation vs Intravitreal Ranibizumab for Proliferative Diabetic Retinopathy: A Randomized Clinical Trial. *JAMA Ophthalmol.* 2018;136(10):1138-1148.

255. Sivaprasad S, Prevost AT, Vasconcelos JC, et al. Clinical efficacy of intravitreal aflibercept versus panretinal photocoagulation for best corrected visual acuity in patients with proliferative diabetic retinopathy at 52 weeks (CLARITY): a multicentre, single-blinded, randomised, controlled, phase 2b, non-inferiority trial. *Lancet*. 2017;389(10085):2193-2203.
256. Ip MS, Domalpally A, Sun JK, Ehrlich JS. Long-term effects of therapy with ranibizumab on diabetic retinopathy severity and baseline risk factors for worsening retinopathy. *Ophthalmology*. 2015;122(2):367-374.
257. Obeid A, Su D, Patel SN, et al. Outcomes of Eyes Lost to Follow-up with Proliferative Diabetic Retinopathy That Received Panretinal Photocoagulation versus Intravitreal Anti-Vascular Endothelial Growth Factor. *Ophthalmology*. 2019;126(3):407-413.
258. Parikh RN, Traband A, Kolomeyer AM, et al. Intravitreal Bevacizumab for the Treatment of Vitreous Hemorrhage Due to Proliferative Diabetic Retinopathy. *Am J Ophthalmol*. 2017;176:194-202.
259. Diabetic Retinopathy Clinical Research N. Randomized clinical trial evaluating intravitreal ranibizumab or saline for vitreous hemorrhage from proliferative diabetic retinopathy. *JAMA Ophthalmol*. 2013;131(3):283-293.
260. Arevalo JF, Maia M, Flynn HW, Jr., et al. Tractional retinal detachment following intravitreal bevacizumab (Avastin) in patients with severe proliferative diabetic retinopathy. *Br J Ophthalmol*. 2008;92(2):213-216.
261. Bressler SB, Qin H, Melia M, et al. Exploratory analysis of the effect of intravitreal ranibizumab or triamcinolone on worsening of diabetic retinopathy in a randomized clinical trial. *JAMA Ophthalmol*. 2013;131(8):1033-1040.
262. Bressler SB, Liu D, Glassman AR, et al. Change in diabetic retinopathy through 2 years: secondary analysis of a randomized clinical trial comparing aflibercept, bevacizumab, and ranibizumab. *JAMA Ophthalmol*. 2017;135(6):558-568.
263. Ip MS, Domalpally A, Hopkins JJ, Wong P, Ehrlich JS. Long-term effects of ranibizumab on diabetic retinopathy severity and progression. *Arch Ophthalmol*. 2012;130(9):1145-1152.
264. Wykoff CC, Eichenbaum DA, Roth DB, Hill L, Fung AE, Haskova Z. Ranibizumab Induces Regression of Diabetic Retinopathy in Most Patients at High Risk of Progression to Proliferative Diabetic Retinopathy. *Ophthalmology Retina*. 2018.
265. Brown DM, Schmidt-Erfurth U, Do DV, et al. Intravitreal aflibercept for diabetic macular edema: 100-week results from the VISTA and VIVID studies. *Ophthalmology*. 2015;122(10):2044-2052.
266. Early vitrectomy for severe vitreous hemorrhage in diabetic retinopathy. Two-year results of a randomized trial. Diabetic Retinopathy Vitrectomy Study report 2. The Diabetic Retinopathy Vitrectomy Study Research Group. *Arch Ophthalmol*. 1985;103(11):1644-1652.
267. Early vitrectomy for severe proliferative diabetic retinopathy in eyes with useful vision. Results of a randomized trial--Diabetic Retinopathy Vitrectomy Study Report 3. The Diabetic Retinopathy Vitrectomy Study Research Group. *Ophthalmology*. 1988;95(10):1307-1320.
268. Recchia FM, Scott IU, Brown GC, Brown MM, Ho AC, Ip MS. Small-gauge pars plana vitrectomy: a report by the American Academy of Ophthalmology. *Ophthalmology*. 2010;117(9):1851-1857.
269. Simunovic MP, Maberley DA. ANTI-VASCULAR ENDOTHELIAL GROWTH FACTOR THERAPY FOR PROLIFERATIVE DIABETIC RETINOPATHY: A Systematic Review and Meta-Analysis. *Retina*. 2015;35(10):1931-1942.
270. Zhao XY, Xia S, Chen YX. Antivascular endothelial growth factor agents pretreatment before vitrectomy for complicated proliferative diabetic retinopathy: a meta-analysis of randomised controlled trials. *Br J Ophthalmol*. 2018;102(8):1077-1085.
271. Smith JM, Steel DH. Anti-vascular endothelial growth factor for prevention of postoperative vitreous cavity haemorrhage after vitrectomy for proliferative diabetic retinopathy. *Cochrane Database Syst Rev*. 2015(8):CD008214.
272. Jacobson DR, Murphy RP, Rosenthal AR. The treatment of angle neovascularization with panretinal photocoagulation. *Ophthalmology*. 1979;86(7):1270-1277.
273. Fong DS, Ferris FL, III, Davis MD, Chew EY. Early Treatment Diabetic Retinopathy Study Research Group. Causes of severe visual loss in the early treatment diabetic retinopathy study: ETDRS report no. 24. *Am J Ophthalmol*. 1999;127(2):137-141.
274. Sivaprasad S, Crosby-Nwaobi R, Heng LZ, Peto T, Michaelides M, Hykin P. Injection frequency and response to bevacizumab monotherapy for diabetic macular oedema (BOLT report 5). *Br J Ophthalmol*. 2013;97(9):1177-1180.
275. Turner RC. The U.K. Prospective Diabetes Study. A review. *Diabetes Care*. 1998;21 Suppl 3:C35-38.

276. Nathan DM, Bayless M, Cleary P, et al. DCCT/EDIC Research Group. Diabetes control and complications trial/epidemiology of diabetes interventions and complications study at 30 years: advances and contributions. *Diabetes*. 2013;62(12):3976-3986.
277. Ismail-Beigi F, Craven T, Banerji MA, et al. ACCORD Trial Group. Effect of intensive treatment of hyperglycaemia on microvascular outcomes in type 2 diabetes: an analysis of the ACCORD randomised trial. *Lancet*. 2010;376(9739):419-430. Erratum in: *Lancet* 2010;2376:1466.
278. Bressler SB, Qin H, Melia M, et al. Diabetic Retinopathy Clinical Research Network. Exploratory analysis of the effect of intravitreal ranibizumab or triamcinolone on worsening of diabetic retinopathy in a randomized clinical trial. *JAMA Ophthalmol*. 2013;131(8):1033-1040.
279. Diabetic Retinopathy Clinical Research Network Authors/Writing Committee. Macular edema after cataract surgery in eyes without preoperative central-involved diabetic macular edema. *JAMA Ophthalmol*. 2013;131(7):870-879.
280. Benson WE, Morse PH, Nantawan P. Late complications following cryotherapy of lattice degeneration. *Am J Ophthalmol*. 1977;84(4):514-516.
281. Fontenot JL, Bona MD, Kaleem MA, et al. Vision Rehabilitation Preferred Practice Pattern®. *Ophthalmology*. 2018;125(1):P228-P278.
282. Stelmack JA, Tang XC, Reda DJ, Rinne S, Mancil RM, Massof RW. LOVIT Study Group. Outcomes of the Veterans Affairs Low Vision Intervention Trial (LOVIT). *Arch Ophthalmol*. 2008;126(5):608-617.
283. Javitt JC, Canner JK, Sommer A. Cost effectiveness of current approaches to the control of retinopathy in type I diabetics. *Ophthalmology*. 1989;96(2):255-264.
284. Javitt JC, Aiello LP, Bassi LJ, Chiang YP, Canner JK. Detecting and treating retinopathy in patients with type I diabetes mellitus. Savings associated with improved implementation of current guidelines. American Academy of Ophthalmology. *Ophthalmology*. 1991;98(10):1565-1573; discussion 1574.
285. Javitt JC, Aiello LP. Cost-effectiveness of detecting and treating diabetic retinopathy. *Ann Intern Med*. 1996;124(1 Pt 2):164-169.
286. Stein JD, Newman-Casey PA, Kim DD, Nwanyanwu KH, Johnson MW, Hutton DW. Cost-effectiveness of various interventions for newly diagnosed diabetic macular edema. *Ophthalmology*. 2013;120(9):1835-1842.
287. Sharma S, Brown GC, Brown MM, Hollands H, Shah GK. The cost-effectiveness of grid laser photocoagulation for the treatment of diabetic macular edema: results of a patient-based cost-utility analysis. *Curr Opin Ophthalmol*. 2000;11(3):175-179.
288. Busbee BG, Brown MM, Brown GC, Sharma S. CME review: a cost-utility analysis of laser photocoagulation for extrafoveal choroidal neovascularization. *Retina*. 2003;23(3):279-287.
289. Crijns H, Casparie AF, Hendrikse F. Continuous computer simulation analysis of the cost-effectiveness of screening and treating diabetic retinopathy. *Int J Technol Assess Health Care*. 1999;15(1):198-206.
290. Ho T, Smiddy WE, Flynn HW, Jr. Vitrectomy in the management of diabetic eye disease. *Surv Ophthalmol*. 1992;37(3):190-202.
291. Writing Committee for the Diabetic Retinopathy Clinical Research Network, Gross JG, Glassman AR, et al. Panretinal photocoagulation vs intravitreal ranibizumab for proliferative diabetic retinopathy: a randomized clinical trial. *JAMA*. 2015;314(20):2137-2146.
292. Heier JS, Korobelnik JF, Brown DM, et al. Intravitreal Aflibercept for Diabetic Macular Edema: 148-Week Results from the VISTA and VIVID Studies. *Ophthalmology*. 2016;123(11):2376-2385.
293. Klein R. Hyperglycemia and microvascular and macrovascular disease in diabetes. *Diabetes Care*. 1995;18(2):258-268.
294. Diabetes Control and Complications Trial Research Group. Early worsening of diabetic retinopathy in the Diabetes Control and Complications Trial. *Arch Ophthalmol*. 1998;116(7):874-886.
295. ACCORD Study Group. Action to Control Cardiovascular Risk in Diabetes (ACCORD) trial: design and methods. *Am J Cardiol*. 2007;99(12A):21i-33i.
296. Action to Control Cardiovascular Risk in Diabetes Study Group. Effects of intensive glucose lowering in type 2 diabetes. *N Engl J Med*. 2008;358(24):2545-2559.
297. ACCORD Study Group. Effects of combination lipid therapy in type 2 diabetes mellitus. *N Engl J Med*. 2010;362(17):1563-1574. Erratum in: *N Engl J Med* 2010;1362:1748.
298. ACCORD Study Group. Effects of intensive blood-pressure control in type 2 diabetes mellitus. *N Engl J Med*. 2010;362(17):1575-1585.



299. Qaseem A, Wilt TJ, Kansagara D, et al. Hemoglobin A1c targets for glycemic control with pharmacologic therapy for nonpregnant adults with type 2 diabetes mellitus: a guidance statement update from the american college of physicians. *Ann Intern Med.* 2018;168(8):569-576.