

ICD-10-CM PHYSICIAN TREE

DIABETES  
TYPE 1

Retinopathy?

**E10.9**

Type 1 DM  
without Comp.  
No laterality

Proliferative?

Severity?

Mild <sup>2</sup>

Moderate <sup>3</sup>

Severe <sup>4</sup>

Macular  
Edema?

Macular  
Edema?

Macular  
Edema?

**E10.321**

Type 1 DM  
Mild with  
ME

**E10.329**

Type 1 DM  
Mild without  
ME

**E10.331**

Type 1 DM  
Mod. with  
ME

**E10.339**

Type 1 DM  
Mod. without  
ME

**E10.341**

Type 1 DM  
Sev. with  
ME

**E10.349**

Type 1 DM Sev.  
without  
ME

E10.3			
RETINOPATHY	STAGE	EDEMA	LATERALITY
2 mild	1 with	1 right	
3 moderate	9 without	2 left	
4 severe		3 bilateral	
5 PDR			

Scribe | Physician Tip: **THINK** —  
TYPE | RETINOPATHY | SEVERITY | EDEMA

**Severity Scale**

MILD = microaneurysms only

MODERATE = more than just micro-  
aneurysms but less than severe NPDR

SEVERE = Any of the following  
(4-2-1 rule) and no signs  
of proliferative retinopathy:

- Severe intraretinal hemorrhages and microaneurysms in each of four quadrants
- Definite venous beading in two or more quadrants
- Moderate IRMA in one or more quadrants

PDR = one or both of the following:  
neovascularization or vitreous/  
pre-retinal hemorrhage

**E10.351**

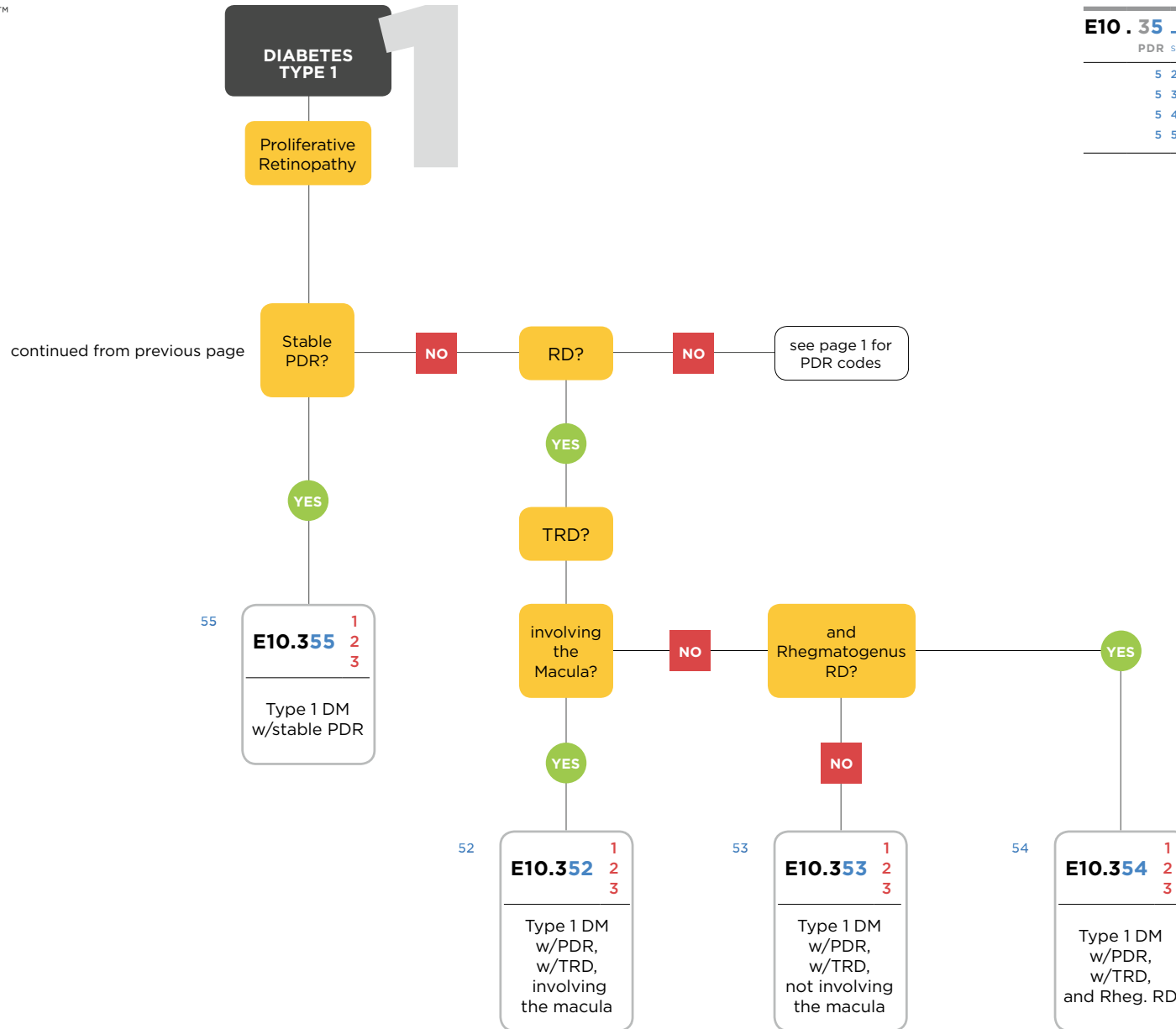
Type 1 DM  
with Prolif.  
with ME

**E10.359**

Type 1 DM  
with Prolif.  
without ME

chart continues

E10.35		
PDR	STAGE	LATERALITY
5	2 TRD invol. macula	1 right
5	3 TRD NOT invol. macula	2 left
5	4 comb. TRD & Rheg RD	3 bilateral
5	5 Stable PDR	



NOTES:  
**R73.03** Prediabetes  
**O24.415** Gestational diabetes mellitus in pregnancy, controlled by oral hypoglycemic drugs

ICD-10-CM PHYSICIAN TREE

DIABETES  
TYPE 2



E11.3			
RETINOPATHY	STAGE	EDEMA	LATERALITY
2 mild	1 with	1 right	
3 moderate	9 without	2 left	
4 severe		3 bilateral	
5 PDR			

Scribe | Physician Tip: **THINK** —  
TYPE | RETINOPATHY | SEVERITY | EDEMA

**Severity Scale**

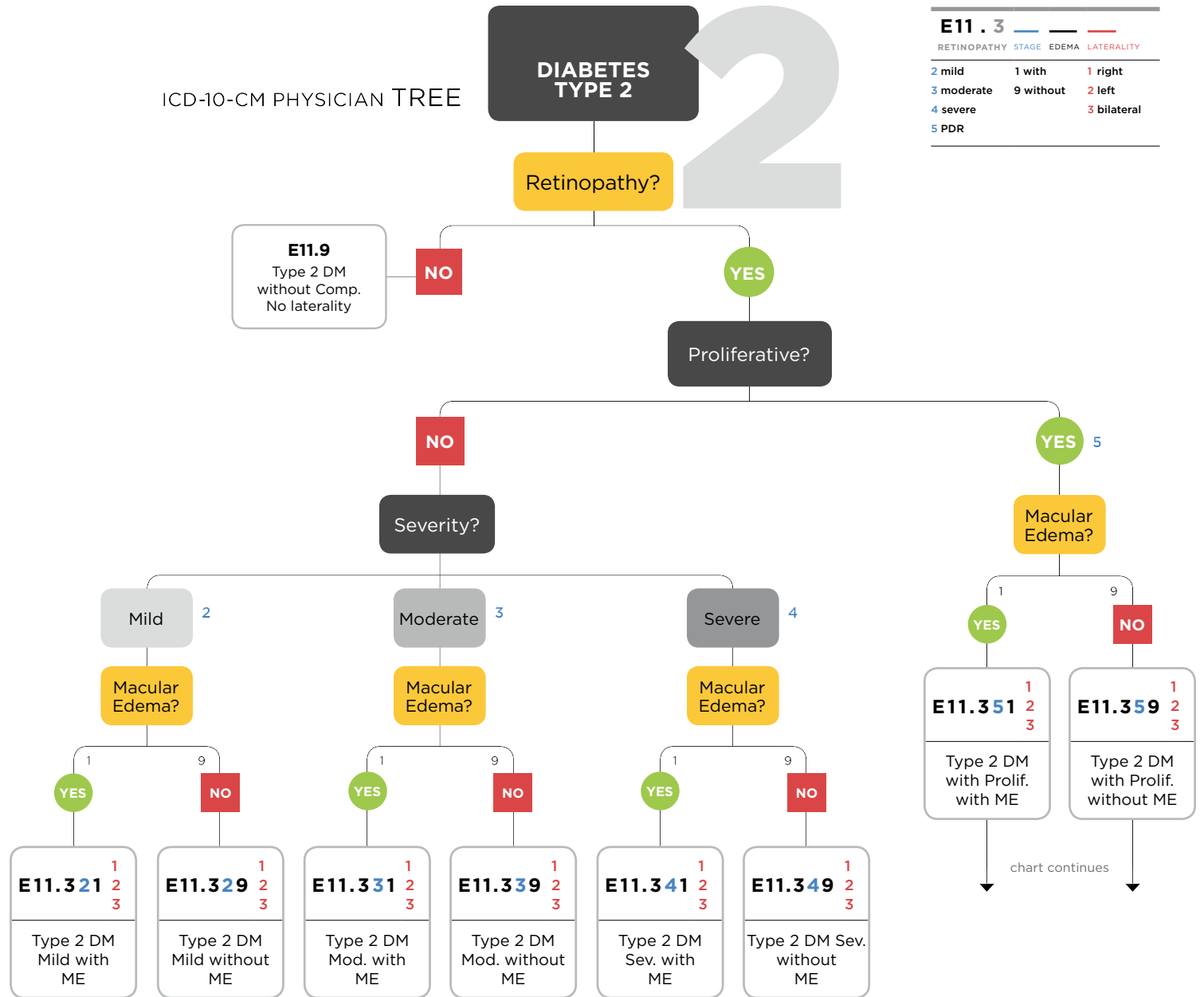
MILD = microaneurysms only

MODERATE = more than just micro-  
aneurysms but less than severe NPDR

SEVERE = Any of the following  
(4-2-1 rule) and no signs  
of proliferative retinopathy:

- Severe intraretinal hemorrhages and microaneurysms in each of four quadrants
- Definite venous beading in two or more quadrants
- Moderate IRMA in one or more quadrants

PDR = one or both of the following:  
neovascularization or vitreous/  
pre-retinal hemorrhage



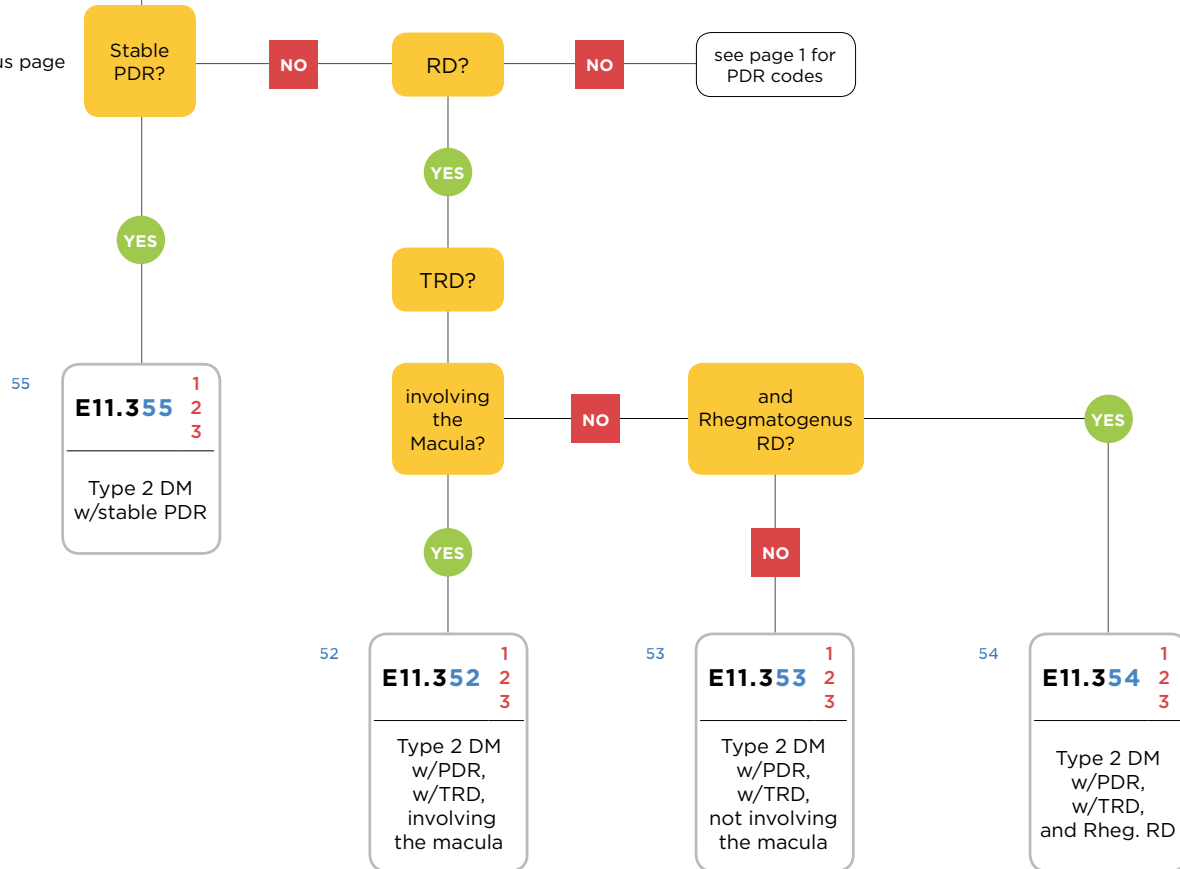
**DIABETES  
TYPE 2**

Proliferative  
Retinopathy

**E11.35**

PDR	STAGE	LATERALITY
5	2 TRD invol. macula	1 right
5	3 TRD NOT invol. macula	2 left
5	4 comb. TRD & Rheg RD	3 bilateral
5	5 Stable PDR	

continued from previous page



NOTES:  
**R73.03** Prediabetes  
**O24.415** Gestational diabetes mellitus in pregnancy, controlled by oral hypoglycemic drugs