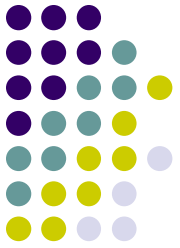

Q

Abusive Head Trauma (AHT)

- AHT was formerly known as

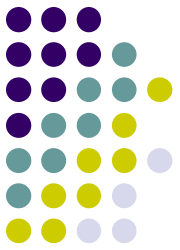three words



A

Abusive Head Trauma (AHT)

- AHT was formerly known as *shaken baby syndrome*



Q

Abusive Head Trauma (AHT)

- AHT was formerly known as *shaken baby syndrome*



What is the classic scenario that results in AHT?

A

Abusive Head Trauma (AHT)

- AHT was formerly known as *shaken baby syndrome*

What is the classic scenario that results in AHT?

An adult, out of frustration/anger, violently shakes an infant who is crying inconsolably



Abusive Head Trauma (AHT)

- AHT was formerly known as *shaken baby syndrome*

★ Typical **victim age** is inconsistent between the *BCSC* books: ★

- *Peds*: 'Usually younger than 1 year , most often younger than 5 years'
- *Retina*: 'Almost always younger than 1 year; frequently younger than 6 months'

(No question—proceed when ready)



Q

Abusive Head Trauma (AHT)



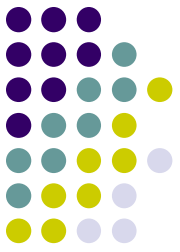- AHT was formerly known as *shaken baby syndrome*

★ Typical **victim age** is inconsistent between the *BCSC* books: ★

- *Peds*: 'Usually younger than 1 year , most often younger than 5 years'
- *Retina*: 'Almost always younger than 1 year; frequently younger than 6 months'
- Anterior segment/lid exam is usually unremarkable? jacked up?

A

Abusive Head Trauma (AHT)



- AHT was formerly known as *shaken baby syndrome*

★ Typical **victim age** is inconsistent between the *BCSC* books: ★

- *Peds*: 'Usually younger than 1 year , most often younger than 5 years'
- *Retina*: 'Almost always younger than 1 year; frequently younger than 6 months'
- Anterior segment/lid exam is usually **unremarkable**

Q

Abusive Head Trauma (AHT)



- AHT was formerly known as *shaken baby syndrome*

★ Typical **victim age** is inconsistent between the *BCSC* books: ★

- *Peds*: 'Usually younger than 1 year , most often younger than 5 years'
- *Retina*: 'Almost always younger than 1 year; frequently younger than 6 months'
- Anterior segment/lid exam is usually **unremarkable**
- Retinal hemorrhages in AHT:
 - ...are strongly associated with SDH vs SAH and often with SDH vs SAH

A

Abusive Head Trauma (AHT)

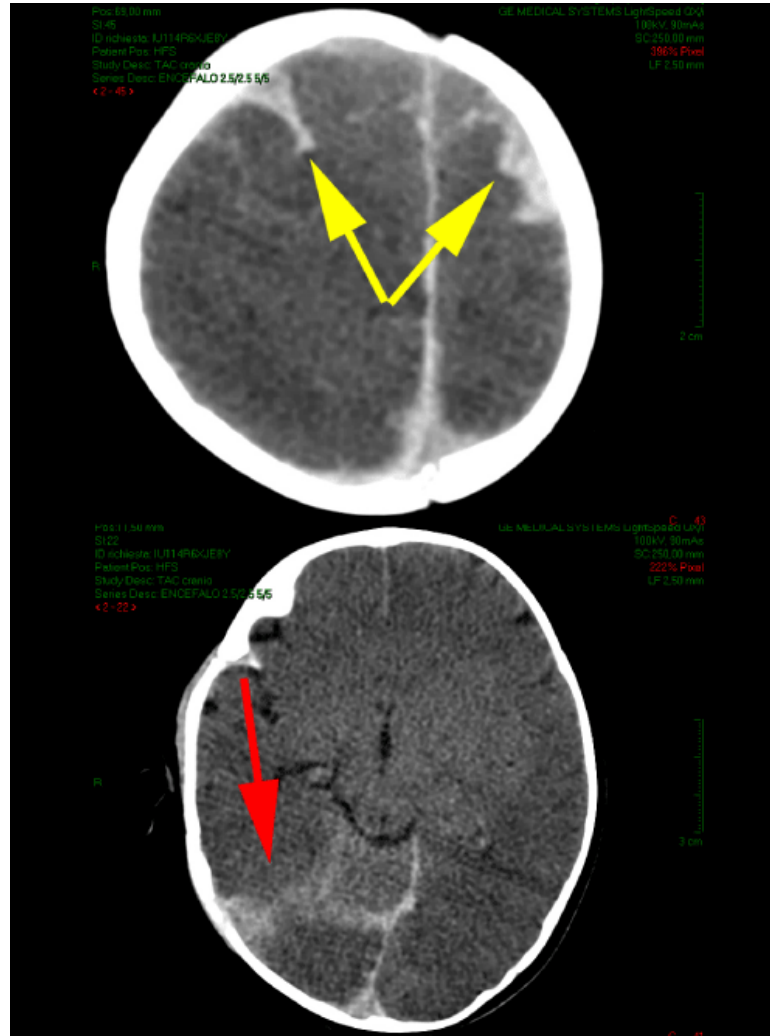


- AHT was formerly known as *shaken baby syndrome*

★ Typical **victim age** is inconsistent between the *BCSC* books: ★

- *Peds*: 'Usually younger than 1 year , most often younger than 5 years'
- *Retina*: 'Almost always younger than 1 year; frequently younger than 6 months'
- Anterior segment/lid exam is usually **unremarkable**
- Retinal hemorrhages in AHT:
 - ...are strongly associated with **SDH** and often with **SAH**

Abusive Head Trauma (AHT)



AHT: SDH/SAH

Q

Abusive Head Trauma (AHT)



- AHT was formerly known as *shaken baby syndrome*

★ Typical **victim age** is inconsistent between the *BCSC* books: ★

- *Peds*: 'Usually younger than 1 year , most often younger than 5 years'
- *Retina*: 'Almost always younger than 1 year; frequently younger than 6 months'
- Anterior segment/lid exam is usually **unremarkable**
- Retinal hemorrhages in AHT:
 - ...are strongly associated with **SDH** and often with **SAH**
 - ...can be associated with traumatic structural retina problem

A

Abusive Head Trauma (AHT)

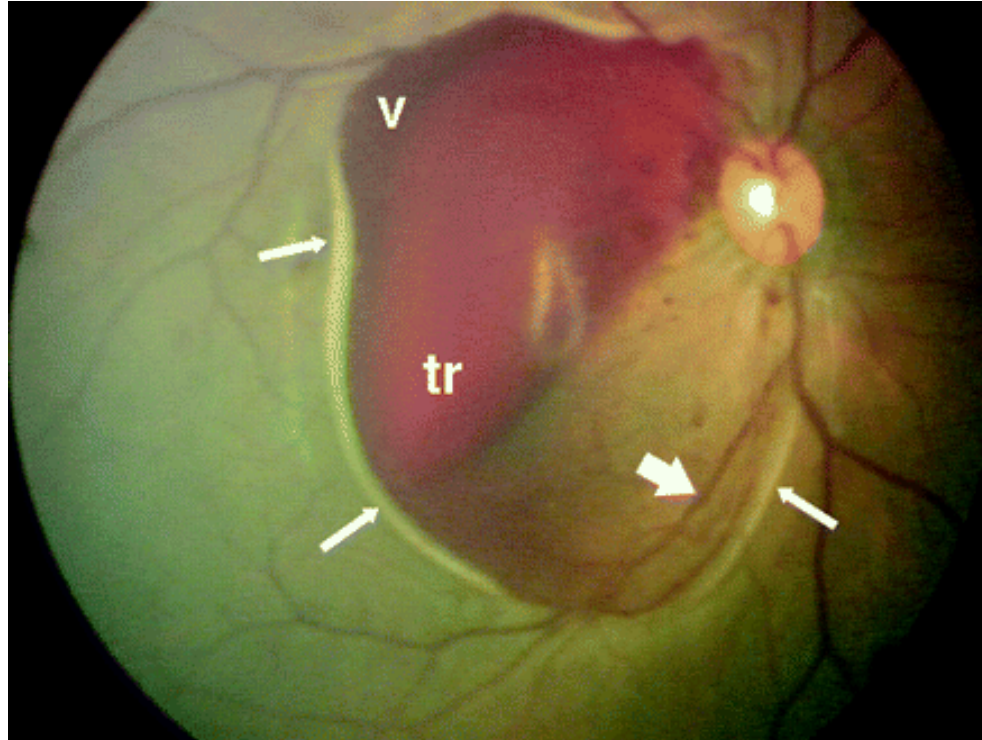


- AHT was formerly known as *shaken baby syndrome*

★ Typical **victim age** is inconsistent between the *BCSC* books: ★

- *Peds*: 'Usually younger than 1 year , most often younger than 5 years'
- *Retina*: 'Almost always younger than 1 year; frequently younger than 6 months'
- Anterior segment/lid exam is usually **unremarkable**
- Retinal hemorrhages in AHT:
 - ...are strongly associated with **SDH** and often with **SAH**
 - ...can be associated with traumatic **retinoschisis**

Abusive Head Trauma (AHT)



Traumatic retinoschisis of the macula in AHT. Arrows indicate the retinal fold at the edge of schisis with underlying hypopigmentation; **tr**, blood within the schisis cavity; **v**, blood escaping from the schisis cavity into the vitreous. Note the blood vessel (thick, short arrow) traveling from the optic nerve up onto the surface of the elevated schisis cavity and then down.

AHT: Retinoschisis

Abusive Head Trauma (AHT)



- AHT was formerly known as *shaken baby syndrome*

★ Typical **victim age** is inconsistent between the *BCSC* books: ★

- *Peds*: 'Usually younger than 1 year , most often younger than 5 years'
- *Retina*: 'Almost always younger than 1 year; frequently younger than 6 months'
- Anterior segment/lid exam is usually **unremarkable**
- Retinal hemorrhages in AHT:
 - ...are strongly associated with **SDH** and often with **SAH**
 - ...can be associated with traumatic **retinoschisis**

★ **Natural hx of hemorrhages** is also inconsistent between *BCSC* books: ★

- *Peds*: 'Persist for weeks to months'
- *Retina*: 'Can resolve very rapidly'

(No question—proceed when ready)

Q

Abusive Head Trauma (AHT)



● AHT was formerly known as *shaken baby syndrome*

★ Typical *victim age* is inconsistent between the *BCSC* books:

● *Peds*: 'Usually younger than 1 year'

● *Retina*: 'Almost always younger than 1 year'

● Anterior segment/lid exam is usually normal

● **Retinal hemorrhages in AHT:**

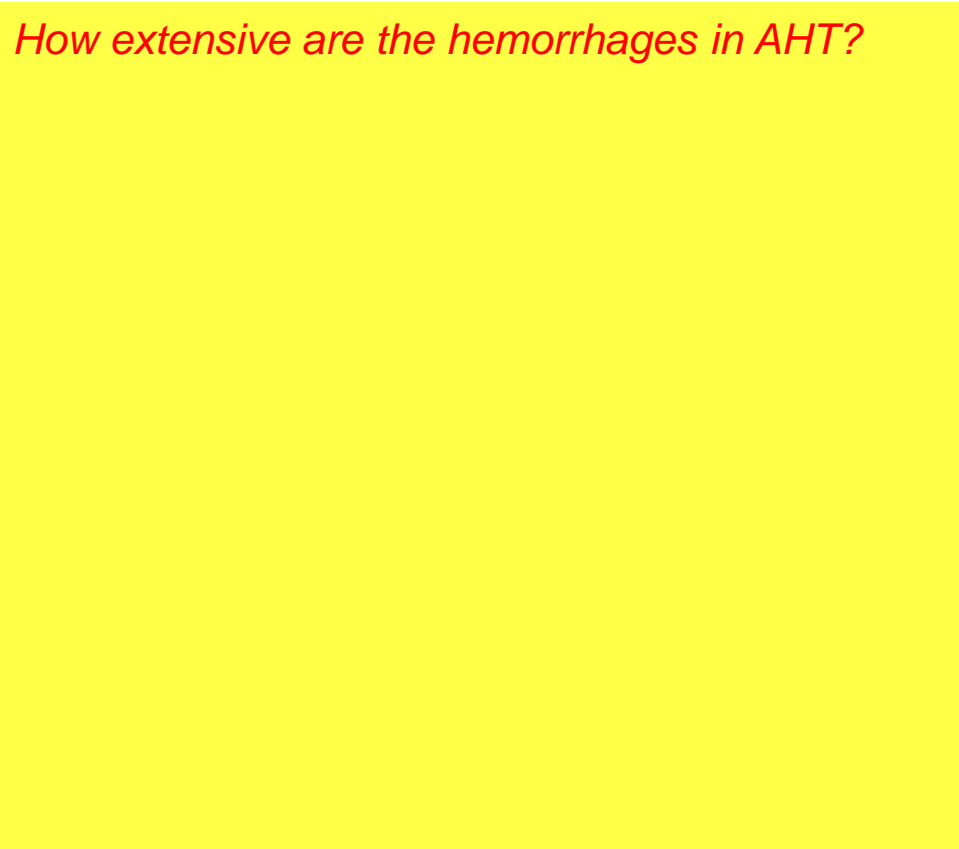
● ...are strongly associated with *S*

● ...can be associated with trauma

★ *Natural hx of hemorrhages* is as follows:

▪ *Peds*: 'Persist for weeks to months'

▪ *Retina*: 'Can resolve very rapidly'



How extensive are the hemorrhages in AHT?

A

Abusive Head Trauma (AHT)



- AHT was formerly known as *shaken baby syndrome*

★ Typical *victim age* is inconsistent between the *BCSC* books:

- *Peds*: 'Usually younger than 1 year'
- *Retina*: 'Almost always younger than 1 year'

How extensive are the hemorrhages in AHT?

Very extensive--too numerous to count

- Anterior segment/lid exam is usually normal

- **Retinal hemorrhages in AHT:**

- ...are strongly associated with *Shaken Baby Syndrome*
- ...can be associated with trauma

★ *Natural hx of hemorrhages* is as follows:

- *Peds*: 'Persist for weeks to months'
- *Retina*: 'Can resolve very rapidly'

Q

Abusive Head Trauma (AHT)



● AHT was formerly known as *shaken baby syndrome*

★ Typical *victim age* is inconsistent between the *BCSC* books:

- *Peds*: 'Usually younger than 1 year'
- *Retina*: 'Almost always younger than 1 year'

How extensive are the hemorrhages in AHT?

Very extensive--too numerous to count

● Anterior segment/lid exam is usually normal

Which layers of the retina are involved?

● **Retinal hemorrhages in AHT:**

- ...are strongly associated with *S*
- ...can be associated with trauma

★ *Natural hx of hemorrhages* is as follows:

- *Peds*: 'Persist for weeks to months'
- *Retina*: 'Can resolve very rapidly'

A

Abusive Head Trauma (AHT)



- AHT was formerly known as *shaken baby syndrome*

★ Typical *victim age* is inconsistent between the *BCSC* books:

- *Peds*: 'Usually younger than 1 year'
- *Retina*: 'Almost always younger than 1 year'

How extensive are the hemorrhages in AHT?

Very extensive--too numerous to count

- Anterior segment/lid exam is usually normal

Which layers of the retina are involved?

All layers

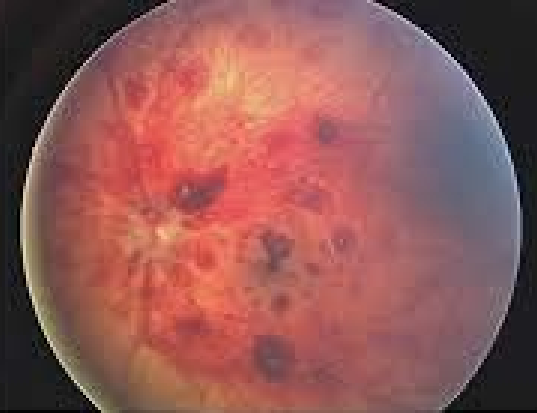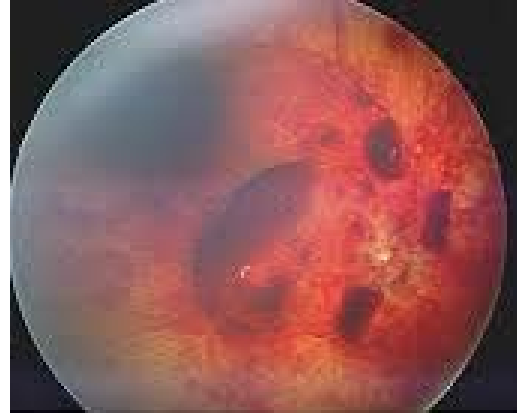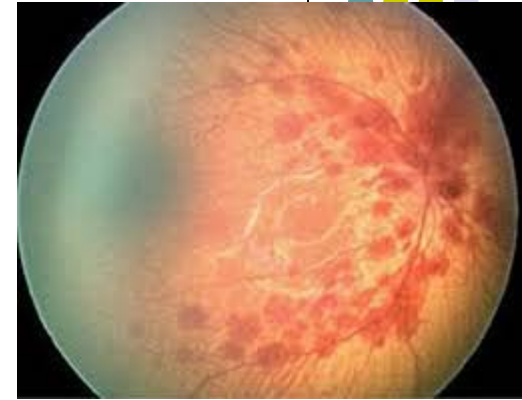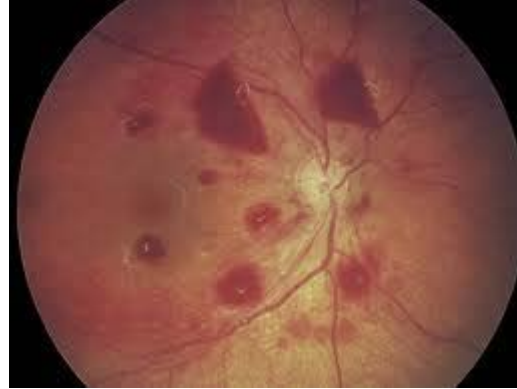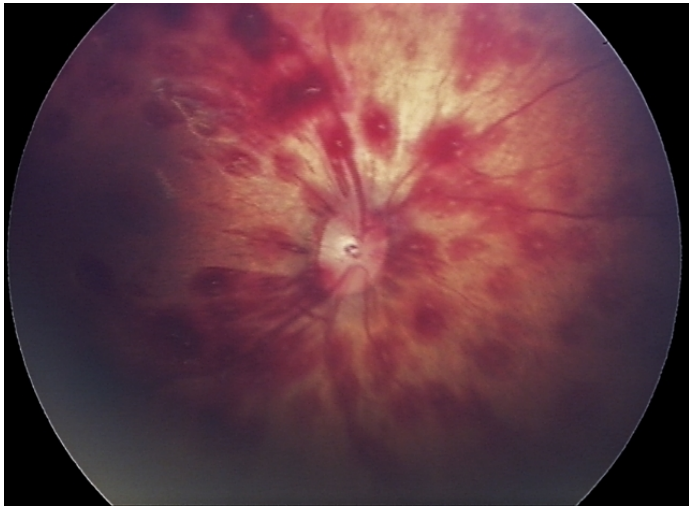
- **Retinal hemorrhages in AHT:**

- ...are strongly associated with *S*
- ...can be associated with trauma

★ *Natural hx of hemorrhages* is a

- *Peds*: 'Persist for weeks to months'
- *Retina*: 'Can resolve very rapidly'

Abusive Head Trauma (AHT)



AHT: Retinal hemorrhages at all levels

Q

Abusive Head Trauma (AHT)



● AHT was formerly known as *shaken baby syndrome*

★ Typical *victim age* is inconsistent between the *BCSC* books:

- *Peds*: 'Usually younger than 1 year'
- *Retina*: 'Almost always younger than 1 year'

How extensive are the hemorrhages in AHT?

Very extensive--too numerous to count

● Anterior segment/lid exam is usually normal

Which layers of the retina are involved?

All layers

● **Retinal hemorrhages in AHT:**

- ...are strongly associated with *Shaken Baby Syndrome*
- ...can be associated with trauma

Where in the eye are they located?

★ *Natural hx of hemorrhages* is as follows:

- *Peds*: 'Persist for weeks to months'
- *Retina*: 'Can resolve very rapidly'

A

Abusive Head Trauma (AHT)



- AHT was formerly known as *shaken baby syndrome*

★ Typical *victim age* is inconsistent between the *BCSC* books:

- *Peds*: 'Usually younger than 1 year'
- *Retina*: 'Almost always younger than 1 year'

How extensive are the hemorrhages in AHT?

Very extensive--too numerous to count

- Anterior segment/lid exam is usually normal

Which layers of the retina are involved?

All layers

- **Retinal hemorrhages in AHT:**

- ...are strongly associated with *S*
- ...can be associated with trauma

Where in the eye are they located?

Always in the posterior pole, but often extending well into the periphery

★ *Natural hx of hemorrhages* is as follows:

- *Peds*: 'Persist for weeks to months'
- *Retina*: 'Can resolve very rapidly'

Q

Abusive Head Trauma (AHT)



AHT was formerly known as *shaken baby syndrome*

★ Typical *victim age* is inconsistent between the *BCSC* books:

- *Peds*: 'Usually younger than 1 year'
- *Retina*: 'Almost always younger than 1 year'
- Anterior segment/lid exam is usually normal
- **Retinal hemorrhages in AHT:**
 - ...are strongly associated with *Shaken Baby Syndrome*
 - ...can be associated with trauma

How extensive are the hemorrhages in AHT?

Very extensive--too numerous to count

Which layers of the retina are involved?

All layers

Where in the eye are they located?

Always in the posterior pole, but often extending well into the periphery

Are the unilateral, or bilateral?

★ *Natural hx of hemorrhages* is as follows:

- *Peds*: 'Persist for weeks to months'
- *Retina*: 'Can resolve very rapidly'

A

Abusive Head Trauma (AHT)



- AHT was formerly known as *shaken baby syndrome*

★ Typical *victim age* is inconsistent between the *BCSC* books:

- *Peds*: 'Usually younger than 1 year'
- *Retina*: 'Almost always younger than 1 year'

How extensive are the hemorrhages in AHT?

Very extensive--too numerous to count

- Anterior segment/lid exam is usually normal

Which layers of the retina are involved?

All layers

- **Retinal hemorrhages in AHT:**

- ...are strongly associated with *Shaken Baby Syndrome*
- ...can be associated with trauma

Where in the eye are they located?

Always in the posterior pole, but often extending well into the periphery

★ *Natural hx of hemorrhages* is as follows:

- *Peds*: 'Persist for weeks to months'
- *Retina*: 'Can resolve very rapidly'

Are the unilateral, or bilateral?

Usually bilateral, can be either

Q

Abusive Head Trauma (AHT)



AHT was formerly known as *shaken baby syndrome*

★ Typical *victim age* is inconsistent between the *BCSC* books:

- *Peds*: 'Usually younger than 1 year'
- *Retina*: 'Almost always younger than 1 year'
- Anterior segment/lid exam is usually normal
- **Retinal hemorrhages in AHT:**
 - ...are strongly associated with AHT
 - ...can be associated with trauma

How extensive are the hemorrhages in AHT?

Very extensive--too numerous to count

Which layers of the retina are involved?

All layers

Where in the eye are they located?

Always in the posterior pole, but often extending well into the periphery

Are the unilateral, or bilateral?

Usually bilateral, can be either

Can the heme reach the vitreous, resulting in an apparent vitreous hemorrhage?

★ *Natural hx of hemorrhages* is as follows:

- *Peds*: 'Persist for weeks to months'
- *Retina*: 'Can resolve very rapidly'

A

Abusive Head Trauma (AHT)



● AHT was formerly known as *shaken baby syndrome*

★ Typical *victim age* is inconsistent between the *BCSC* books:

- *Peds*: 'Usually younger than 1 year'
- *Retina*: 'Almost always younger than 1 year'

How extensive are the hemorrhages in AHT?

Very extensive--too numerous to count

● Anterior segment/lid exam is usually normal

Which layers of the retina are involved?

All layers

● **Retinal hemorrhages in AHT:**

- ...are strongly associated with *Shaken Baby Syndrome*
- ...can be associated with trauma

Where in the eye are they located?

Always in the posterior pole, but often extending well into the periphery

★ *Natural hx of hemorrhages* is as follows:

- *Peds*: 'Persist for weeks to months'
- *Retina*: 'Can resolve very rapidly'

Are the unilateral, or bilateral?

Usually bilateral, can be either

Can the heme reach the vitreous, resulting in an apparent vitreous hemorrhage?

Yes

Q

Abusive Head Trauma (AHT)



- AHT was formerly known as *shaken baby syndrome*

★ Typical **victim age** is inconsistent between the *BCSC* books: ★

- *Peds*: 'Usually younger than 1 year , most often younger than 5 years'
- *Retina*: 'Almost always younger than 1 year; frequently younger than 6 months'
- Anterior segment/lid exam is usually **unremarkable**
- Retinal hemorrhages in AHT:
 - ...are strongly associated with **SDH** and often with **SAH**
 - ...can be associated with traumatic **retinoschisis**

★ **Natural hx of hemorrhages** is also inconsistent between *BCSC* books: ★

- *Peds*: 'Persist for weeks to months'
- *Retina*: 'Can resolve very rapidly'
- Retinal hemorrhages associated with...
 - ...**CPR** are

rare vs common

, and

how extensive?

A

Abusive Head Trauma (AHT)



- AHT was formerly known as *shaken baby syndrome*

★ Typical **victim age** is inconsistent between the *BCSC* books: ★

- *Peds*: 'Usually younger than 1 year , most often younger than 5 years'
- *Retina*: 'Almost always younger than 1 year; frequently younger than 6 months'
- Anterior segment/lid exam is usually **unremarkable**
- Retinal hemorrhages in AHT:
 - ...are strongly associated with **SDH** and often with **SAH**
 - ...can be associated with traumatic **retinoschisis**

★ **Natural hx of hemorrhages** is also inconsistent between *BCSC* books: ★

- *Peds*: 'Persist for weeks to months'
- *Retina*: 'Can resolve very rapidly'
- Retinal hemorrhages associated with...
 - ...**CPR** are **rare** , and **never extensive**

Q

Abusive Head Trauma (AHT)



- AHT was formerly known as *shaken baby syndrome*

★ Typical **victim age** is inconsistent between the *BCSC* books: ★

- *Peds*: 'Usually younger than 1 year , most often younger than 5 years'
- *Retina*: 'Almost always younger than 1 year; frequently younger than 6 months'
- Anterior segment/lid exam is usually **unremarkable**
- Retinal hemorrhages in AHT:
 - ...are strongly associated with **SDH** and often with **SAH**
 - ...can be associated with traumatic **retinoschisis**

★ **Natural hx of hemorrhages** is also inconsistent between *BCSC* books: ★

- *Peds*: 'Persist for weeks to months'
- *Retina*: 'Can resolve very rapidly'
- Retinal hemorrhages associated with...
 - ...**CPR** are **rare** , and **never extensive**
 - ...**birth** are

rare vs common

 , but resolve by age

A

Abusive Head Trauma (AHT)



- AHT was formerly known as *shaken baby syndrome*

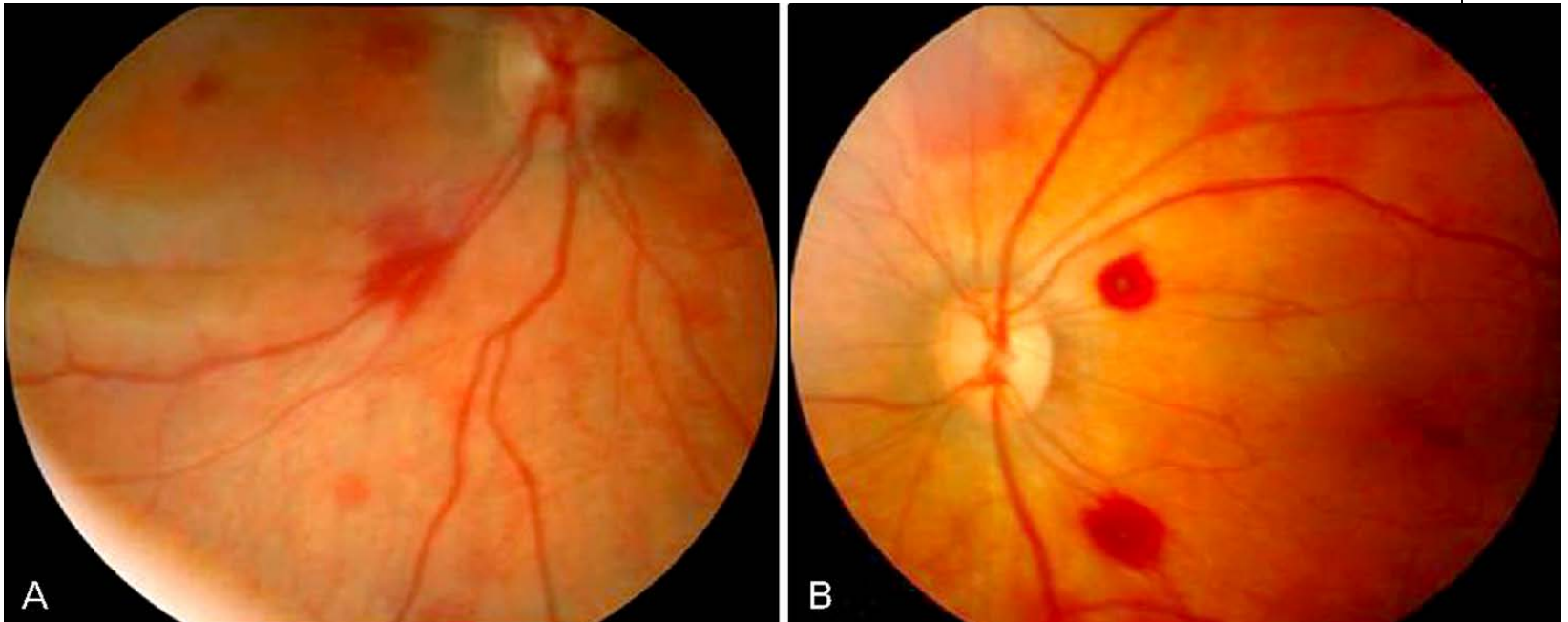

★ Typical **victim age** is inconsistent between the *BCSC* books: ★

- *Peds*: 'Usually younger than 1 year , most often younger than 5 years'
- *Retina*: 'Almost always younger than 1 year; frequently younger than 6 months'
- Anterior segment/lid exam is usually **unremarkable**
- Retinal hemorrhages in AHT:
 - ...are strongly associated with **SDH** and often with **SAH**
 - ...can be associated with traumatic **retinoschisis**

★ **Natural hx of hemorrhages** is also inconsistent between *BCSC* books: ★

- *Peds*: 'Persist for weeks to months'
- *Retina*: 'Can resolve very rapidly'
- Retinal hemorrhages associated with...
 - ...**CPR** are **rare** , and **never extensive**
 - ...**birth** are **common** , but resolve by age **1 month**

Abusive Head Trauma (AHT)



Fundus photographs of retinal hemorrhages in neonates that had a history of birth asphyxia and amniotic fluid aspiration

Retinal hemorrhages after birth trauma

Q

Abusive Head Trauma (AHT)



- AHT was formerly known as *shaken baby syndrome*

★ Typical **victim age** is inconsistent between the *BCSC* books: ★

- *Peds*: 'Usually younger than 1 year , most often younger than 5 years'
- *Retina*: 'Almost always younger than 1 year; frequently younger than 6 months'
- Anterior segment/lid exam is usually **unremarkable**
- Retinal hemorrhages in AHT:
 - ...are strongly associated with **SDH** and often with **SAH**
 - ...can be associated with traumatic **retinoschisis**

★ **Natural hx of hemorrhages** is also inconsistent between *BCSC* books: ★

- *Peds*: 'Persist for weeks to months'
- *Retina*: 'Can resolve very rapidly'
- Retinal hemorrhages associated with...
 - ...**CPR** are **rare** , and **never extensive**
 - ...**birth** are **common** , but resolve by age **1 month**
 - ...**severe head trauma** are how extensive?

A

Abusive Head Trauma (AHT)



- AHT was formerly known as *shaken baby syndrome*

★ Typical **victim age** is inconsistent between the *BCSC* books: ★

- *Peds*: 'Usually younger than 1 year , most often younger than 5 years'
- *Retina*: 'Almost always younger than 1 year; frequently younger than 6 months'
- Anterior segment/lid exam is usually **unremarkable**
- Retinal hemorrhages in AHT:
 - ...are strongly associated with **SDH** and often with **SAH**
 - ...can be associated with traumatic **retinoschisis**

★ **Natural hx of hemorrhages** is also inconsistent between *BCSC* books: ★

- *Peds*: 'Persist for weeks to months'
- *Retina*: 'Can resolve very rapidly'
- Retinal hemorrhages associated with...
 - ...**CPR** are **rare** , and **never extensive**
 - ...**birth** are **common** , but resolve by age **1 month**
 - ...**severe head trauma** are **never extensive**

Q

Abusive Head Trauma (AHT)



- AHT was formerly known as *shaken baby syndrome*

★ Typical **victim age** is inconsistent between the *BCSC* books: ★

- *Peds*: 'Usually younger than 1 year , most often younger than 5 years'
- *Retina*: 'Almost always younger than 1 year; frequently younger than 6 months'
- Anterior segment/lid exam is usually **unremarkable**
- Retinal hemorrhages in AHT:
 - ...are strongly associated with **SDH** and often with **SAH**
 - ...can be associated with traumatic **retinoschisis**

★ **Natural hx of hemorrhages** is also inconsistent between *BCSC* books: ★

- *Peds*: 'Persist for weeks to months'
- *Retina*: 'Can resolve very rapidly'
- Retinal hemorrhages associated with...
 - ...**CPR** are **rare** , and **never extensive**
 - ...**birth** are **common** , but resolve by age **1 month**
 - ...**severe head trauma** are **never extensive**
- | |
|--------------------|
| proportion (range) |
|--------------------|

 of AHT victims will succumb to their injuries

A

Abusive Head Trauma (AHT)



- AHT was formerly known as *shaken baby syndrome*

★ Typical **victim age** is inconsistent between the *BCSC* books: ★

- *Peds*: 'Usually younger than 1 year , most often younger than 5 years'
- *Retina*: 'Almost always younger than 1 year; frequently younger than 6 months'
- Anterior segment/lid exam is usually **unremarkable**
- Retinal hemorrhages in AHT:
 - ...are strongly associated with **SDH** and often with **SAH**
 - ...can be associated with traumatic **retinoschisis**

★ **Natural hx of hemorrhages** is also inconsistent between *BCSC* books: ★

- *Peds*: 'Persist for weeks to months'
- *Retina*: 'Can resolve very rapidly'
- Retinal hemorrhages associated with...
 - ...**CPR** are **rare** , and **never extensive**
 - ...**birth** are **common** , but resolve by age **1 month**
 - ...**severe head trauma** are **never extensive**
- **1/4 to 1/3** of AHT victims will succumb to their injuries

Abusive Head Trauma (AHT)



- AHT was formerly known as *shaken baby syndrome*

★ Typical **victim age** is inconsistent between the *BCSC* books: ★

- *Peds*: 'Usually younger than 1 year , most often younger than 5 years'
- *Retina*: 'Almost always younger than 1 year; frequently younger than 6 months'
- Anterior segment/lid exam is usually **unremarkable**
- Retinal hemorrhages in AHT:
 - ...are strongly associated with **SDH** and often with **SAH**
 - ...can be associated with traumatic **retinoschisis**

★ **Natural hx of hemorrhages** is also inconsistent between *BCSC* books: ★

- *Peds*: 'Persist for weeks to months'
- *Retina*: 'Can resolve very rapidly'
- Retinal hemorrhages associated with...
 - ...**CPR** are **rare** , and **never extensive**
 - ...**birth** are **common** , but resolve by age **1 month**
 - ...**severe head trauma** are **never extensive**
- **1/4 to 1/3** of AHT victims will succumb to their injuries
 - Survivors often have lifelong cognitive/motor deficits 2ndry to neurotrauma

(No question—proceed when ready)

Q

Abusive Head Trauma (AHT)



- AHT was formerly known as *shaken baby syndrome*

★ Typical **victim age** is inconsistent between the *BCSC* books: ★

- *Peds*: 'Usually younger than 1 year , most often younger than 5 years'
- *Retina*: 'Almost always younger than 1 year; frequently younger than 6 months'
- Anterior segment/lid exam is usually **unremarkable**
- Retinal hemorrhages in AHT:
 - ...are strongly associated with **SDH** and often with **SAH**
 - ...can be associated with traumatic **retinoschisis**

★ **Natural hx of hemorrhages** is also inconsistent between *BCSC* books: ★

- *Peds*: 'Persist for weeks to months'
- *Retina*: 'Can resolve very rapidly'
- Retinal hemorrhages associated with...
 - ...**CPR** are **rare** , and **never extensive**
 - ...**birth** are **common** , but resolve by age **1 month**
 - ...**severe head trauma** are **never extensive**
- **1/4 to 1/3** of AHT victims will succumb to their injuries
 - Survivors often have lifelong cognitive/motor deficits 2ndry to neurotrauma
 - Vision loss usually structure in nature

A

Abusive Head Trauma (AHT)



- AHT was formerly known as *shaken baby syndrome*

★ Typical **victim age** is inconsistent between the *BCSC* books: ★

- *Peds*: 'Usually younger than 1 year , most often younger than 5 years'
- *Retina*: 'Almost always younger than 1 year; frequently younger than 6 months'
- Anterior segment/lid exam is usually **unremarkable**
- Retinal hemorrhages in AHT:
 - ...are strongly associated with **SDH** and often with **SAH**
 - ...can be associated with traumatic **retinoschisis**

★ **Natural hx of hemorrhages** is also inconsistent between *BCSC* books: ★

- *Peds*: 'Persist for weeks to months'
- *Retina*: 'Can resolve very rapidly'
- Retinal hemorrhages associated with...
 - ...**CPR** are **rare** , and **never extensive**
 - ...**birth** are **common** , but resolve by age **1 month**
 - ...**severe head trauma** are **never extensive**
- **1/4 to 1/3** of AHT victims will succumb to their injuries
 - Survivors often have lifelong cognitive/motor deficits 2ndry to neurotrauma
 - Vision loss usually **cortical** in nature

Q

Abusive Head Trauma (AHT)



- AHT was formerly known as *shaken baby syndrome*
- ★ Typical **victim age** is inconsistent between the *BCSC* books:
 - *Peds*: 'Usually younger than 1 year , most often younger than 5 years'
 - *Retina*: 'Almost always younger than 1 year; frequently younger than 6 months'
- Anterior segment/lid exam is usually unremarkable
- Retinal hemorrhages
 - ...are stereotypical
 - ...can be extensive
- ★ **Natural** retinal hemorrhages
 - *Peds*: common
 - *Retina*: common
- Retinal hemorrhages associated with...
 - ...**CPR** are rare , and never extensive
 - ...**birth** are common , but resolve by age 1 month
 - ...**severe head trauma** are never extensive
- 1/4 to 1/3 of AHT victims will succumb to their injuries
 - Survivors often have lifelong cognitive/motor deficits 2ndry to neurotrauma
 - Vision loss usually cortical in nature

If you see an infant with retinal hemorrhages, what conditions must be considered before diagnosing AHT?

books:



A

Abusive Head Trauma (AHT)



- AHT was formerly known as *shaken baby syndrome*

★ Typical **victim age** is inconsistent between the *BCSC* books:

- *Peds*: 'Usually younger than 1 year , most often younger than 5 years'
- *Retina*: 'Almost always younger than 1 year; frequently younger than 6 months'

- Anterior segment/lid exam is usually unremarkable

- Retinal hemorrhages
- If you see an infant with retinal hemorrhages, what conditions must be considered before diagnosing AHT?*

- ...are strong
 - ...can be
- ★ **Natural**
- *Peds*:
 - Leukemia
 - Anemia
 - HTN
 - Elevated intracranial pressure
 - *Retina*:
 - Meningitis
 - ROP

books:

- Retinal hemorrhages associated with...

- ...**CPR** are rare , and never extensive
- ...**birth** are common , but resolve by age 1 month
- ...**severe head trauma** are never extensive

- 1/4 to 1/3 of AHT victims will succumb to their injuries

- Survivors often have lifelong cognitive/motor deficits 2ndry to neurotrauma
- Vision loss usually cortical in nature