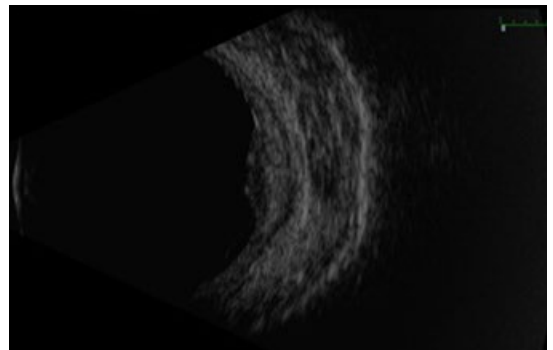
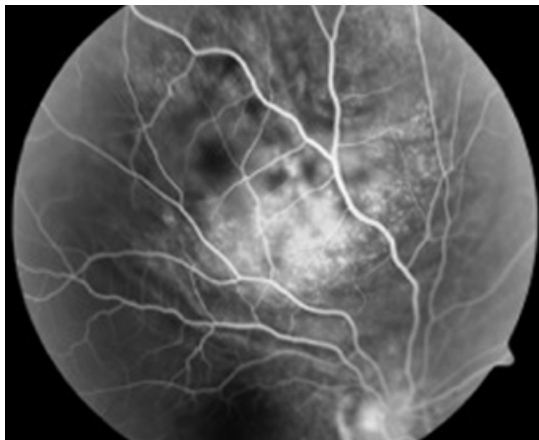
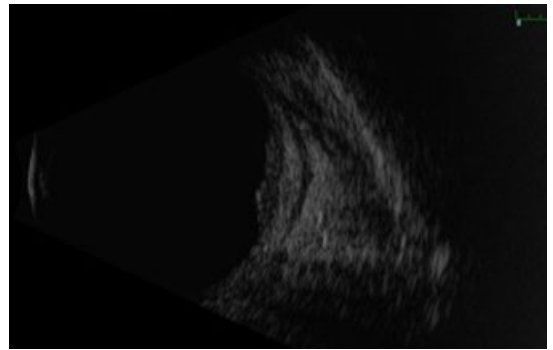
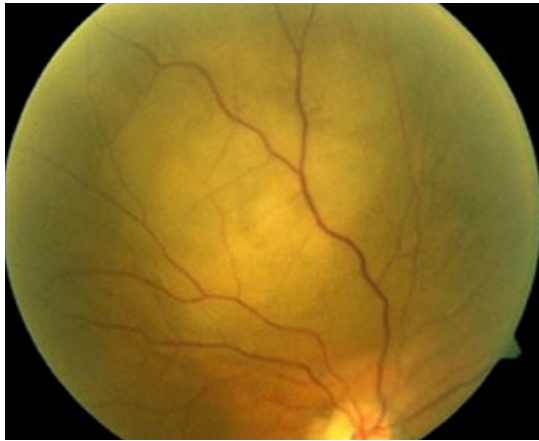

MYSTERY IMAGE  
**BLINK**



**WHAT IS THIS MONTH'S MYSTERY CONDITION?**  
Join the conversation at [aao.org/eyenet](http://aao.org/eyenet), where you can post a comment on this image.

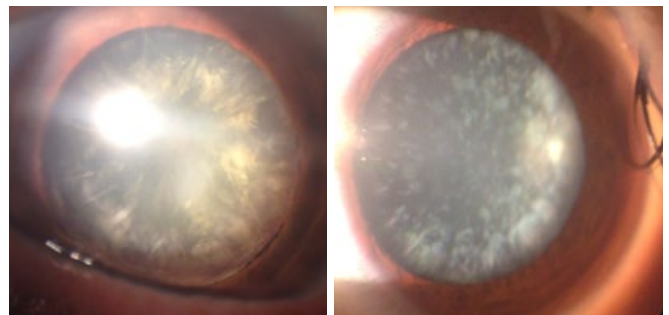
Peter R. Pavan, MD, University of South Florida Eye Institute, Morsani College of Medicine, Tampa, Fla.

LAST MONTH'S BLINK

## Metabolic Cataract: A Presenting Sign of Uncontrolled Diabetes Mellitus

**A** 55-year-old taxi driver with hypertension and dyslipidemia presented to our clinic with blurred vision in his left eye that had been deteriorating for the past 2 months and was interfering with his work. On examination, visual acuity in his left eye was counting fingers at 5 ft and 20/100 in the right. He had advanced bilateral cortical and posterior subcapsular cataracts in both eyes. During routine blood tests prior to surgery, fasting serum glucose measured 212 mg/dL with hemoglobin A<sub>1c</sub> of 9.7%. The patient was subsequently diagnosed with diabetes mellitus (DM) and started on sitagliptin/metformin 50/1,000 mg and glimepiride 2 mg. Cataract surgeries were unremarkable, and the patient's vision improved to 20/20 bilaterally.

Early diagnosis of DM can be challenging. Blurred vision and visual loss commonly present as initial symptoms.<sup>1,2</sup> Although acute diabetic cataracts are rarely encountered in clinical prac-



tice today, a young adult with rapidly maturing bilateral cortical cataracts should have a diabetic workup.

1 Gong J et al. *Br J Gen Pract.* 2014;64(629):614-615.

2 Koffler M et al. *Isr J Med Sci.* 1990;26(7):393-394.

WRITTEN BY **ASAF ACHIRON, MD**, THE EDITH WOLFSON MEDICAL CENTER, HOLON, ISRAEL, AND **URI AVIV, MD**, SACKLER SCHOOL OF MEDICINE, TEL AVIV UNIVERSITY, ISRAEL. PHOTO BY **DR. ACHIRON**.