



AMERICAN ACADEMY
OF OPHTHALMOLOGY®

Protecting Sight. Empowering Lives.®

Primary Angle-Closure Disease Preferred Practice Pattern®

Secretary for Quality of Care
Timothy W. Olsen, MD

Academy Staff
Ali Al-Rajhi, PhD, MPH
Andre Ambrus, MLIS
Meghan Daly
Flora C. Lum, MD

Medical Editor: Susan Garratt

Approved by: Board of Trustees
September 12, 2020

Copyright © 2020 American Academy of Ophthalmology®
All rights reserved

AMERICAN ACADEMY OF OPHTHALMOLOGY and PREFERRED PRACTICE PATTERN are registered trademarks of the American Academy of Ophthalmology. All other trademarks are the property of their respective owners.

Preferred Practice Pattern® guidelines are developed by the Academy's H. Dunbar Hoskins Jr., MD Center for Quality Eye Care without any external financial support. Authors and reviewers of the guidelines are volunteers and do not receive any financial compensation for their contributions to the documents. The guidelines are externally reviewed by experts and stakeholders before publication.

GLAUCOMA PREFERRED PRACTICE PATTERN® DEVELOPMENT PROCESS AND PARTICIPANTS

The **Glaucoma Preferred Practice Pattern® Panel** members wrote the Primary Angle Closure Disease Preferred Practice Pattern® guidelines (PPP). The PPP Panel members discussed and reviewed successive drafts of the document, meeting in person twice and conducting other review by e-mail discussion, to develop a consensus over the final version of the document.

Glaucoma Preferred Practice Pattern Panel 2019-2020

Steven J. Gedde, MD, Chair

Philip P. Chen, MD

Kelly W. Muir, MD

Kateki Vinod, MD

John T. Lind, MD

Martha M. Wright, MD, American Glaucoma Society Representative

Tianjing Li, MD, MHS, PhD, Consultant, Cochrane Eyes and Vision US Project

Steven L. Mansberger, MD, MPH, Methodologist

We thank our partner, the Cochrane Eyes and Vision US Project, for identifying reliable systematic reviews that we cite and discuss in support of the PPP recommendations.

The Preferred Practice Patterns Committee members reviewed and discussed the document during a meeting in May 2020. The document was edited in response to the discussion and comments.

Preferred Practice Patterns Committee 2020

Roy S. Chuck, MD, PhD, Chair

Steven P. Dunn, MD

Christina J. Flaxel, MD

Steven J. Gedde, MD

Francis S. Mah, MD

Kevin M. Miller, MD

James P. Tweeten, MD

David K. Wallace, MD, MPH

David C. Musch, PhD, MPH, Methodologist

The Primary Angle Closure Disease PPP was then sent for review to additional internal and external groups and individuals in June 2020. All those who returned comments were required to provide disclosure of relevant relationships with industry to have their comments considered (indicated with an asterisk below). Members of the PPP Panel reviewed and discussed these comments and determined revisions to the document.

Academy Reviewers

Board of Trustees and Committee of Secretaries*

Council*

General Counsel*

Ophthalmic Technology Assessment Committee

Glaucoma Panel*

Basic and Clinical Science Course Section 10

Subcommittee

Practicing Ophthalmologists Advisory Committee for Education

Invited Reviewers

American College of Surgeons

American Glaucoma Society

American Ophthalmological Society

Association for Research in Vision and Ophthalmology

Association of University Professors in Ophthalmology*

Consumer Reports Health Choices

Canadian Ophthalmological Society*

European Glaucoma Society*

International Council of Ophthalmology

International Society of Glaucoma Surgery

International Society of Refractive Surgery

National Eye Institute*

National Medical Association, Section on Ophthalmology

North American Neuro-Ophthalmology Society*

Outpatient Ophthalmic Surgery Society

World Glaucoma Association*

Women in Ophthalmology*

Wallace L.M. Alward, MD*

Ta Chen Chang, MD

FINANCIAL DISCLOSURES

In compliance with the Council of Medical Specialty Societies' Code for Interactions with Companies (available at <https://cmss.org/code-signers-pdf/>), relevant relationships with industry are listed. The Academy has Relationship with Industry Procedures to comply with the Code (available at www.aao.org/about-preferred-practice-patterns). A majority (75%) of the members of the Glaucoma Preferred Practice Pattern Panel 2019-2020 had no related financial relationship to disclose.

Glaucoma Preferred Practice Pattern Panel 2019-2020

Steven J. Gedde, MD: No financial relationships to disclose
 Philip P. Chen, MD: Allergan—Consultant/Advisor
 John T. Lind, MD: Aerie Pharmaceuticals,
 Allergan—Consultant/Advisor; Aerie Pharmaceuticals,
 Allergan—Lecture Fees, Perrigo—Grant Support
 Kelly W. Muir, MD: No financial relationships to disclose
 Kateki Vinod, MD: No financial relationships to disclose
 Martha M. Wright, MD: No financial relationships to disclose
 Tianjing Li, MD, MHS, PhD: No financial relationships to disclose
 Steven L. Mansberger, MD, MPH: No financial relationships to disclose

Preferred Practice Patterns Committee 2020

Roy S. Chuck, MD, PhD, Chair: No financial relationships to disclose
 Steven P. Dunn, MD: No financial relationships to disclose
 Christina J. Flaxel, MD: No financial relationships to disclose
 Steven J. Gedde, MD: No financial relationships to disclose
 Francis S. Mah, MD: Abbott Medical Optics Inc., Alcon Laboratories, Allergan, Bausch + Lomb, EyePoint, Kala Pharmaceuticals, Novartis Pharmaceuticals, Ocular Science, Ocular Therapeutix, Omeros Corporation—Consultant/Advisor; Abbott Medical Optics Inc., Bausch + Lomb, Novartis Pharmaceuticals—Lecture Fees; Abbott Medical Optics Inc., Ocular Therapeutix—Grant Support, Ocular Science—Equity Owner
 Kevin M. Miller, MD: Alcon Laboratories, Johnson & Johnson Vision—Consultant/Advisor
 James P. Tweeten, MD: No financial relationships to disclose
 David K. Wallace, MD, MPH: No financial relationships to disclose
 David C. Musch, PhD, MPH, Methodologist: No financial relationships to disclose

Secretary for Quality of Care

Timothy W. Olsen, MD: No financial relationships to disclose

Academy Staff

Ali Al-Rajhi, PhD, MPH: No financial relationships to disclose
 Andre Ambrus, MLIS: No financial relationships to disclose
 Meghan Daly: No financial relationships to disclose
 Flora C. Lum, MD: No financial relationships to disclose
 Susan Garratt: No financial relationships to disclose

The disclosures of relevant relationships to industry of other reviewers of the document from January to October 2020 are available online at www.aao.org/ppp.

TABLE OF CONTENTS

OBJECTIVES OF PREFERRED PRACTICE PATTERN GUIDELINES	P36
METHODS AND KEY TO RATINGS	P37
HIGHLIGHTED FINDINGS AND RECOMMENDATIONS FOR CARE	P38
INTRODUCTION	P39
Disease Definition.....	P39
Disease Classification and Clinical Findings Characteristic of Primary Angle-Closure Disease	P39
Primary Angle-Closure Suspect.....	P39
Primary Angle Closure and Primary Angle-Closure Glaucoma	P40
Acute Angle-Closure Crisis	P40
Plateau Iris Configuration and Syndrome	P40
Patient Population	P40
Clinical Objectives.....	P40
BACKGROUND	P42
Prevalence.....	P42
Risk Factors	P43
Demographic Characteristics	P43
Ocular Features	P43
Natural History	P43
CARE PROCESS	P43
Patient Outcome Criteria.....	P43
Diagnosis	P43
History	P44
Physical Examination.....	P44
Diagnostic Testing	P46
Differential Diagnosis.....	P50
Management.....	P50
Goals	P50
Primary Angle-Closure Suspect.....	P50
Primary Angle Closure and Primary Angle-Closure Glaucoma	P51
Surgery and Postoperative Care.....	P51
Acute Angle-Closure Crisis	P52
Plateau Iris Configuration and Syndrome.....	P54
Follow-up Evaluation.....	P55
Provider and Setting.....	P55
Counseling and Referral	P55
Socioeconomic Considerations	P55
APPENDIX 1. QUALITY OF OPHTHALMIC CARE CORE CRITERIA	P57
APPENDIX 2. INTERNATIONAL STATISTICAL CLASSIFICATION OF DISEASES AND RELATED HEALTH PROBLEMS (ICD) CODES	P59
APPENDIX 3. ALGORITHM FOR THE MANAGEMENT OF PATIENTS WITH ACUTE ANGLE-CLOSURE CRISIS	P60
APPENDIX 4. LITERATURE SEARCHES FOR THIS PPP	P61
RELATED ACADEMY MATERIALS	P61
REFERENCES	P62

Primary Angle Closure Disease Preferred Practice Pattern®**Background:**

Primary angle closure disease (PACD) is classified into several groups. Primary angle closure suspect is defined as ≥ 180 degrees of iridotrabecular contact (ITC) without intraocular pressure (IOP) elevation, peripheral anterior synechiae (PAS), or optic nerve damage. An eye with ≥ 180 degrees of ITC and elevated IOP or PAS is categorized as primary angle closure, and the additional presence of glaucomatous optic neuropathy indicates primary angle closure glaucoma. Acute angle-closure crisis (AACC) represents a sudden, marked IOP elevation with complete ITC. Plateau iris configuration is defined as a narrow angle due to an anteriorly positioned ciliary body with a deep central anterior chamber, and plateau iris syndrome is persistent ITC after laser peripheral iridotomy (LPI). Although 90% of cases of AACC present unilaterally, PACD is generally bilateral. Risk factors for PACD include Asian descent, hyperopia, older age, female gender, short axial length, and thick and anteriorly positioned crystalline lens.

Rationale for Treatment:

Pupillary block is involved in the pathogenesis of PACD in most cases, and is resolved with LPI. Patients experiencing AACC should receive medical treatment to lower the IOP, and LPI should subsequently be performed in both eyes. Lens extraction has also been shown to be an effective treatment in some patients with primary angle closure and primary angle closure glaucoma.

Care Process:

The goals of managing patients with PACD are to reverse or prevent angle closure and to control IOP to prevent glaucomatous optic nerve damage. Dark-room dynamic gonioscopy should be performed to diagnose PACD and verify improvement in angle configuration following treatment. Ultrasound biomicroscopy and anterior segment optical coherence tomography can also aid in the diagnosis of PACD.

OBJECTIVES OF PREFERRED PRACTICE PATTERN® GUIDELINES

As a service to its members and the public, the American Academy of Ophthalmology has developed a series of Preferred Practice Pattern® guidelines that **identify characteristics and components of quality eye care**. Appendix 1 describes the core criteria of quality eye care.

The Preferred Practice Pattern® guidelines are based on the best available scientific data as interpreted by panels of knowledgeable health professionals. In some instances, such as when results of carefully conducted clinical trials are available, the data are particularly persuasive and provide clear guidance. In other instances, the panels have to rely on their collective judgment and evaluation of available evidence.

These documents provide guidance for the pattern of practice, not for the care of a particular individual. While they should generally meet the needs of most patients, they cannot possibly best meet the needs of all patients. Adherence to these PPPs will not ensure a successful outcome in every situation. These practice patterns should not be deemed inclusive of all proper methods of care or exclusive of other methods of care reasonably directed at obtaining the best results. It may be necessary to approach different patients' needs in different ways. The physician must make the ultimate judgment about the propriety of the care of a particular patient in light of all of the circumstances presented by that patient. The American Academy of Ophthalmology is available to assist members in resolving ethical dilemmas that arise in the course of ophthalmic practice.

Preferred Practice Pattern® guidelines are not medical standards to be adhered to in all individual situations. The Academy specifically disclaims any and all liability for injury or other damages of any kind, from negligence or otherwise, for any and all claims that may arise out of the use of any recommendations or other information contained herein.

References to certain drugs, instruments, and other products are made for illustrative purposes only and are not intended to constitute an endorsement of such. Such material may include information on applications that are not considered community standard, that reflect indications not included in approved U.S. Food and Drug Administration (FDA) labeling, or that are approved for use only in restricted research settings. The FDA has stated that it is the responsibility of the physician to determine the FDA status of each drug or device he or she wishes to use, and to use them with appropriate patient consent in compliance with applicable law.

Innovation in medicine is essential to ensure the future health of the American public, and the Academy encourages the development of new diagnostic and therapeutic methods that will improve eye care. It is essential to recognize that true medical excellence is achieved only when the patients' needs are the foremost consideration.

All Preferred Practice Pattern® guidelines are reviewed by their parent panel annually or earlier if developments warrant and updated accordingly. To ensure that all PPPs are current, each is valid for 5 years from the "approved by" date unless superseded by a revision. Preferred Practice Pattern guidelines are funded by the Academy without commercial support. Authors and reviewers of PPPs are volunteers and do not receive any financial compensation for their contributions to the documents. The PPPs are externally reviewed by experts and stakeholders, including consumer representatives, before publication. The PPPs are developed in compliance with the Council of Medical Specialty Societies' Code for Interactions with Companies. The Academy has Relationship with Industry Procedures (available at www.aao.org/about-preferred-practice-patterns) to comply with the Code.

Appendix 2 contains the International Statistical Classification of Diseases and Related Health Problems (ICD) codes for the disease entities that this PPP covers. Appendix 3 has an algorithm for the management of patients with acute angle-closure crisis (AACC). The intended users of the Primary Angle Closure PPP are ophthalmologists.

METHODS AND KEY TO RATINGS

Preferred Practice Pattern® guidelines should be clinically relevant and specific enough to provide useful information to practitioners. Where evidence exists to support a recommendation for care, the recommendation should be given an explicit rating that shows the strength of evidence. To accomplish these aims, methods from the Scottish Intercollegiate Guideline Network¹ (SIGN) and the Grading of Recommendations Assessment, Development and Evaluation² (GRADE) group are used. GRADE is a systematic approach to grading the strength of the total body of evidence that is available to support recommendations on a specific clinical management issue. Organizations that have adopted GRADE include SIGN, the World Health Organization, the Agency for Healthcare Research and Policy, and the American College of Physicians.³

- ◆ All studies used to form a recommendation for care are graded for strength of evidence individually, and that grade is listed with the study citation.
- ◆ To rate individual studies, a scale based on SIGN¹ is used. The definitions and levels of evidence to rate individual studies are as follows:

I++	High-quality meta-analyses, systematic reviews of randomized controlled trials (RCTs), or RCTs with a very low risk of bias
I+	Well-conducted meta-analyses, systematic reviews of RCTs, or RCTs with a low risk of bias
I-	Meta-analyses, systematic reviews of RCTs, or RCTs with a high risk of bias
II++	High-quality systematic reviews of case-control or cohort studies High-quality case-control or cohort studies with a very low risk of confounding or bias and a high probability that the relationship is causal
II+	Well-conducted case-control or cohort studies with a low risk of confounding or bias and a moderate probability that the relationship is causal
II-	Case-control or cohort studies with a high risk of confounding or bias and a significant risk that the relationship is not causal
III	Nonanalytic studies (e.g., case reports, case series)

- ◆ Recommendations for care are formed based on the body of the evidence. The body of evidence quality ratings are defined by GRADE² as follows:

Good quality	Further research is very unlikely to change our confidence in the estimate of effect
Moderate quality	Further research is likely to have an important impact on our confidence in the estimate of effect and may change the estimate
Insufficient quality	Further research is very likely to have an important impact on our confidence in the estimate of effect and is likely to change the estimate Any estimate of effect is very uncertain

- ◆ Key recommendations for care are defined by GRADE² as follows:

Strong recommendation	Used when the desirable effects of an intervention clearly outweigh the undesirable effects or clearly do not
Discretionary recommendation	Used when the trade-offs are less certain—either because of low-quality evidence or because evidence suggests that desirable and undesirable effects are closely balanced

- ◆ The Highlighted Findings and Recommendations for Care section lists points determined by the PPP Panel to be of particular importance to vision and quality of life outcomes.
- ◆ All recommendations for care in this PPP were rated using the system described above. Ratings are embedded throughout the PPP main text in italics.
- ◆ Literature searches to update the PPP were undertaken in March 2019 and June 2020 in the PubMed and Cochrane databases. Complete details of the literature searches are available in Appendix 4.

HIGHLIGHTED FINDINGS AND RECOMMENDATIONS FOR CARE

Understanding the current disease definition is important in the management of the primary angle-closure disease (PACD) spectrum. Modern classification includes:

- ◆ Primary angle-closure suspect (PACS): ≥ 180 degrees iridotrabecular contact (ITC), normal intraocular pressure (IOP), and no optic nerve damage
 - ◆ Primary angle closure (PAC): ≥ 180 degrees ITC with peripheral anterior synechiae (PAS) or elevated IOP but no optic neuropathy
 - ◆ Primary angle-closure glaucoma (PACG): ≥ 180 degrees ITC with PAS, elevated IOP, and optic neuropathy
 - ◆ Acute angle-closure crisis (AACC): occluded angle with symptomatic high IOP
 - ◆ Plateau iris configuration: narrow angle due to an anteriorly positioned ciliary body, with deep central anterior chamber
 - ◆ Plateau iris syndrome: narrow angle due to an anteriorly positioned ciliary body, with deep central anterior chamber, and any ITC persisting after patent peripheral iridotomy
-

Common risk factors for PACD include Asian descent, hyperopia, older age, female gender, short axial length, and thick and anteriorly positioned crystalline lens.

Dark-room dynamic gonioscopy should be performed to diagnose PACD and to verify improvement in angle configuration following treatment. Ultrasound biomicroscopy (UBM) and anterior segment optical coherence tomography (AS-OCT) can also aid in the diagnosis of angle closure, but only UBM and dynamic gonioscopy can identify the etiology of plateau iris.

The clinical signs and symptoms of AACC include pressure-induced corneal edema (experienced as blurred vision and occasionally as halos around lights), a mid-dilated pupil, vascular congestion (i.e., conjunctival and episcleral), eye pain, headache, and nausea/vomiting.

Patients experiencing AACC should receive medical treatment, including aqueous suppressants, parasympathomimetics, and osmotic agents, if necessary, to lower the IOP acutely and relieve symptoms. This should be followed by laser iridotomy or iridectomy. After addressing the episode of AACC, it is important to perform laser iridotomy in the fellow eye when indicated.

Lens extraction is an effective treatment for some patients with PAC and PACG.

INTRODUCTION

DISEASE DEFINITION

Primary angle-closure disease (PACD) is appositional or synechial closure of the anterior chamber angle. Experts now recognize multiple mechanisms for PACD. Pupillary block is a key element in the pathogenesis of most instances of PACD.⁴⁻⁶ The pressure in the posterior chamber is higher than in the anterior chamber due to impairment of aqueous humor flow from the posterior chamber at the pupil, causing an anterior bowing of the iris that crowds the angle in predisposed eyes. Additional mechanisms that contribute to PACD include the relative position and thickness of the ciliary body, the location of the iris insertion into the ciliary body, and the volume of the iris. Certain anatomical features can increase this pressure disparity between the two chambers (e.g., pupil dilation and the crystalline lens size, shape, position, and thickening with age), which then results in iris apposition to the anterior chamber angle structures. In a minority of cases, this can happen acutely, resulting in acute angle-closure crisis (AACC).

Prolonged or repeated contact of the peripheral iris with the trabecular meshwork may lead to functional damage of the trabecular meshwork and the development of peripheral anterior synechiae (PAS). Primary angle-closure disease may not initially be associated with elevated intraocular pressure (IOP) or glaucomatous optic neuropathy, and it may occur in either an acute or chronic form. Secondary forms of angle closure can also occur (e.g., iridocorneal endothelial syndrome, inflammation, or neovascularization). This Preferred Practice Pattern (PPP) focuses on PACD, and the management of other secondary forms of angle closure glaucoma (e.g., neovascular glaucoma) is not discussed.

DISEASE CLASSIFICATION AND CLINICAL FINDINGS CHARACTERISTIC OF ANGLE CLOSURE

Primary angle-closure disease is generally bilateral, although 90% of AACC are unilateral.^{7, 8} Patients with PACD and those at risk may be categorized as follows (see Table 1):

TABLE 1 CLINICAL FINDINGS THAT DEFINE PATIENTS SEEN WITH PRIMARY ANGLE-CLOSURE DISEASE

	Primary Angle-Closure Suspect	Primary Angle Closure	Primary Angle-Closure Glaucoma
≥180 degrees ITC	Present	Present	Present
Elevated IOP or PAS	Absent	Present	Present
Optic nerve damage	Absent	Absent	Present

IOP = intraocular pressure; ITC = iridotrabecular contact; PAS = peripheral anterior synechiae

Primary Angle-Closure Suspect

Iridotrabecular contact (ITC), as observed on gonioscopy without compression, is defined as the iris appearing to touch the anterior chamber angle at the posterior pigmented trabecular meshwork or more anterior structures. The extent of iridotrabecular contact required to diagnose an eye as having PACD has been the subject of debate. Consensus suggests that a person with 180 degrees or more of ITC on dark-room gonioscopy is at risk of primary angle-closure glaucoma (PACG) or an AACC.^{9, 10} An eye with this amount or more of ITC, no PAS, and normal IOP is considered a primary angle-closure suspect (PACS).⁹ A study conducted in southern India found that about one in four untreated PACS subjects in this population developed elevation in IOP or PAS over 5 years.^{11, 12} However, a large prospective population-

based study in Zhongshan, China found only 4% of PACS eyes reached the same endpoint over 6 years.¹³ Further longitudinal studies in diverse ethnorracial populations are needed.

Primary Angle Closure and Primary Angle-Closure Glaucoma

Any eye that has at least 180 degrees of ITC and an elevated IOP or PAS with no secondary cause for the PAS is classified as having PAC. The presence of high IOP and/or PAS suggests that ITC noted during gonioscopy may cause permanent histopathologic changes to the eye.¹⁴ When glaucomatous optic neuropathy is present (as defined in the Primary Open-Angle Glaucoma PPP¹⁵), the eye has progressed from PAC to PACG. Eyes with intermittent PACG may have normal IOP between episodes of elevated IOP that cause optic neuropathy.¹⁶

Acute Angle-Closure Crisis

If the anterior chamber angle is obstructed suddenly, the IOP can rise rapidly to high levels. The characteristic clinical signs and symptoms include pressure-induced corneal edema (experienced as blurred vision and occasionally as halos around lights), a mid-dilated pupil, lens opacities (glaucomflecken), vascular congestion (i.e., conjunctival and episcleral), eye pain, headache, and nausea/vomiting. This condition is considered an AACC and may be self-limited or may recur. Untreated, this entity may cause permanent vision loss or blindness. The fellow eye is also at high risk of AACC.

Plateau Iris Configuration and Syndrome

Plateau iris configuration refers to eyes that have a gonioscopic appearance of the peripheral iris closely apposed to the angle despite a deep central anterior chamber.^{17, 18} The etiology, anterior rotation of the ciliary body, can be discerned using dynamic gonioscopy or ultrasound biomicroscopy (UBM) but not anterior segment optical coherence tomography (AS-OCT). Nearly one-third of PAC eyes treated with iridotomy have an angle that retains substantial ITC.¹⁹⁻²³ On pupil dilation, eyes with plateau iris configuration do not have a substantial increase in IOP. Although no longitudinal study has shown that these eyes have a higher long-term risk to develop PACG than eyes whose angles widen more after iridotomy, the prevalence of plateau iris in one population-based study (8% of occludable angles)²⁴ compared with that among eyes with PACG (32%–37%)²⁵⁻²⁷ implies that plateau iris does increase the risk of developing PACG. Eyes with plateau iris syndrome may have recurrent high IOP after iridotomy or even after cataract extraction.^{28, 29}

PATIENT POPULATION

The patient population includes individuals of all ages, most of whom are adults older than 50 years with risk factors that include abnormally high transpupillary resistance to aqueous humor movement, most often in association with pupillary block.

CLINICAL OBJECTIVES

- ◆ Identify patients who currently have or are at risk of developing PACG or AACC by using gonioscopy
- ◆ Successfully manage AACC
- ◆ Prevent or reverse angle closure by using laser iridotomy, and iridoplasty when indicated. Incisional iridectomy may be required to alleviate pupillary block, in rare cases.
- ◆ Confirm by repeat gonioscopy that the angle is open after intervention. If not open, consider lens extraction or incisional glaucoma surgery when laser and medical therapy does not alleviate IOP elevation.
- ◆ Identify and manage patients with chronic IOP elevation that persists after iridotomy or iridoplasty
- ◆ Evaluate the fellow eye for evidence of angle closure or an anatomically narrow angle in AACC and perform a prophylactic iridotomy when indicated

Primary Angle-Closure Disease PPP

- ◆ Educate the patient and care giver(s) about the characteristics of the disease and involve them in the patient's management. Also, encourage the patient to inform genetically related family members that they may be at risk of angle closure and should be evaluated.

BACKGROUND

PREVALENCE

Considerable differences exist in the prevalence of angle closure among ethnoracial groups, with highest rates in Inuit,³⁰⁻³² Chinese,^{24, 33-36} and other Asian³⁷⁻⁴⁵ populations; and lower rates in populations of African and African-derived origin⁴⁶⁻⁴⁸ and European and European-derived origin⁴⁹⁻⁵⁷ (see Table 2). In some Asian populations, PACG may account for nearly as many cases of glaucoma as open-angle glaucoma.^{37, 58, 59} Worldwide, 0.7% of people over 40 are estimated to have angle-closure glaucoma⁵⁹; in 2013, this represented 20.2 million people, with most (15.5 million) in Asia.⁶⁰ The prevalence is expected to increase by 50% in 2040, and over 5 million of the 32 million people projected to have PACG could become blind from the disease. Overall, PACG is a large cause of blindness worldwide.

TABLE 2 PREVALENCE OF ANGLE CLOSURE

Population	Location	Study N	Reported Prevalence (%)
Inuit	Alaskan Inuit ³⁰	1673	3.8 (age >40)
	Alaskan Inuit ³¹	1686	2.65 (age >40)
	East Greenlandic Inuit ³²	79	2.5 (age ≥40)
Chinese	Taiwan ³³	562	3.0 (age ≥40)
	Guangzhou ³⁴	1504	1.5 (age ≥50)
	Beijing ³⁵	4451	1.2 (age ≥40)
	Singapore ³⁶	1232	1.1 (age 40–79)
Other Asian	Burma ³⁷	2076	2.5 (age ≥40)
	South Africa* ³⁸	987	2.30 (age ≥40)
	Mongolia ²⁴	942	1.4 (age ≥40)
	Thailand ⁴⁰	790	0.9 (age ≥50)
	Southern India ⁴¹	3934	0.87 (age ≥40)
	Southern India ⁴²	5150	0.5 (age ≥40)
	Bangladesh ⁴³	2347	0.4 (age ≥40)
	Japan ⁴⁴	8126	0.34 (age ≥40)
Hispanic	Arizona, U.S. ⁶¹	4774	0.10 (age >40)
	Japan ⁴⁵	3021	0.6 (age ≥40)
African and African-derived	Baltimore, U.S. ⁴⁶	5308	0.6 (age ≥40)
	Tanzania ⁴⁷	3268	0.58 (age ≥40)
	Temba, South Africa ⁴⁸	839	0.50 (age ≥40)
European and European-derived	Italy ⁴⁹	4297	0.60 (age >40)
	Blue Mountains, Australia ⁵⁰	3654	0.27 (age ≥49)
	Bedford, U.K. ⁵¹	5941	0.17 (age >40)
	Ireland ⁵²	2186	0.09 (age ≥50)
	Wales, U.K. ⁵³	4231	0.09 (age ≥40–75)
	Melbourne, Australia ⁵⁴	3271	0.06 (age ≥40)
	Beaver Dam, U.S. ⁵⁵	4926	0.04 (age ≥43)
	Rotterdam ⁵⁶	3062	0 (age ≥55)
Sweden ⁵⁷	1963	0 (age 55–69)	

NOTE: The studies reporting prevalence used different definitions of disease; therefore, these rates are not directly comparable.

* Population in study is of mixed-race ancestry, mainly from Southeast Asia, but there was some African and white admixture.

RISK FACTORS

The following demographic and ocular factors have been implicated as risk factors for the presence of PACD.

Demographic Characteristics

- ◆ Family history of angle closure^{62, 63}
- ◆ Older age^{7, 24, 57}
- ◆ Female gender^{7, 64}
- ◆ Chinese, Vietnamese, Pakistani, or Inuit descent^{24, 32, 65-68}

Ocular Features

- ◆ Hyperopia⁶⁹⁻⁷¹
- ◆ Shallow peripheral anterior chamber depth^{8, 69, 71-77}
- ◆ Shallow central anterior chamber depth^{71, 78-82}
- ◆ Steep corneal curvature⁸³
- ◆ Thick crystalline lens^{71, 84}
- ◆ Short axial length^{71, 84, 85}
- ◆ Anterior position of the ciliary body, as in plateau iris^{17, 18}
- ◆ Anterior lens position⁸⁶

NATURAL HISTORY

Glaucomatous optic neuropathy can develop rapidly if patients with high IOP from unilateral AACC do not receive treatment.⁸⁷ Also, untreated fellow phakic eyes are at increased risk for developing acute angle closure.^{88, 89} Following AACC, the retinal nerve fiber layer thickness increases in the first few days, returns to an average thickness at approximately 1 month, and develops decreased thickness at 3 months.⁹⁰ This occurs from axonal swelling, resolution of axonal swelling, and eventual axonal atrophy.⁸⁷ In one study examining patients for 4 to 10 years following an AACC event,⁹¹ 18% of eyes were blind, of which 50% were blind from glaucoma. Fifty-eight percent of eyes had visual acuity worse than 20/40. Thus, AACC (and subsequent PACG) creates significant visual morbidity with progressive vision loss that may result in unilateral and bilateral blindness.

CARE PROCESS

PATIENT OUTCOME CRITERIA

- ◆ Preservation of visual function
- ◆ Maintenance of quality of life
- ◆ Reduction of the risk of AACC

DIAGNOSIS

Patients may or may not have symptoms of PACD. Primary angle-closure suspect is a diagnosis based on the presence of ITC on gonioscopy only, without elevated IOP or PAS and no optic nerve damage. Primary angle closure is based on a combination of the presence of ITC on gonioscopy with either elevated IOP or PAS, but no glaucomatous optic neuropathy.⁹

Patients may be asymptomatic when presenting for routine eye care, or they may present with sudden onset of symptoms and signs typical of AACC (such as pain, nausea, redness, congestion, decreased vision, corneal edema, very high IOP). The initial history and ophthalmic examination includes the components of the comprehensive adult medical eye evaluation,⁹² with special attention to those elements that specifically bear on primary and secondary causes of angle closure (see below).

History

The patient with PACD should be asked about previous symptoms of intermittent angle closure (e.g., blurred vision, halos around lights, eye pain, headache, eye redness). These symptoms may occur spontaneously or with pharmacologic stress, such as ingestion or transdermal absorption of anticholinergics or installation of mydriatic eye drops.^{64, 93} Review of the patient's family history may identify a relative with AACC.^{62, 63, 94-96} The ophthalmologist should also inquire about the use of systemic medications that may cause ciliary body edema and angle narrowing (e.g., sulfonamides,⁹⁷ including topiramate⁹⁸) and drugs with adrenergic or anticholinergic effects (e.g., ipratropium bromide and salbutamol-containing inhalers, phenothiazines).^{93, 99, 100}

Physical Examination

Components of the physical examination that are particularly relevant for the diagnosis and management of PACD are as follows.

Refractive status

Hyperopic eyes and eyes with short axial length regardless of refractive status, especially in older phakic patients, have narrower anterior chamber angles⁶⁹ and are at increased risk of PACD.⁷⁰ Assessment of actual refractive status by retinoscopy or manifest refraction in the AACC eye may be postponed until a subsequent visit. It is appropriate to determine the presence of hyperopia by measuring the eyeglass power or refracting the fellow eye. Care should be taken to elicit previous medical history, including past refractive surgery (i.e., LASIK for hyperopia).

Pupil examination

- ◆ Size and shape (may be mid-dilated, asymmetric, or oval in the involved eye during or following an AACC)
- ◆ Reactivity (may be poor during an AACC or nonreactive following an AACC)
- ◆ Relative afferent pupillary defect (may be present with asymmetric optic nerve damage or be due to elevated IOP)

Slit-lamp biomicroscopy

- ◆ Conjunctival hyperemia (in acute cases)
- ◆ Central and peripheral anterior chamber depth narrowing^{101, 102}
- ◆ Anterior chamber inflammation suggestive of a recent or current attack
- ◆ Corneal swelling. (Microcystic edema and stromal edema are common in acute cases.)
- ◆ Small corneal diameter (indicative of a smaller eye at greater risk for PACD)
- ◆ Iris abnormalities, including diffuse or focal atrophy, posterior synechiae, abnormal pupillary function, irregular pupil shape, and a mid-dilated pupil (suggestive of a recent or current attack)
- ◆ Lens changes, including cataract, anterior lens position, and glaukomflecken (patchy, localized, anterior subcapsular lens opacities) (see Figure 1)
- ◆ Corneal endothelial cell loss¹⁰³⁻¹⁰⁶

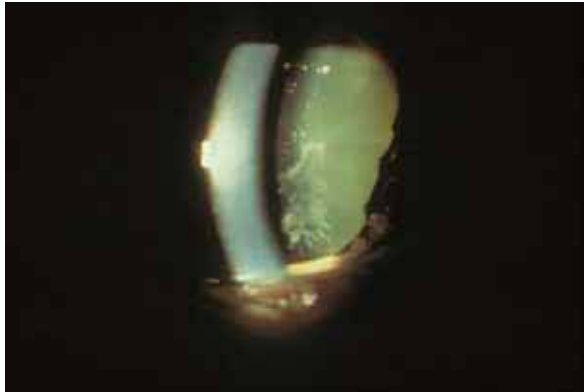


FIGURE 1. Glaukomflecken located in the anterior subcapsular lens.

Adapted with permission from Alward WLM and Longmuir RA, Color Atlas of Gonioscopy. 2008 American Academy of Ophthalmology, page 57, Figure 8-8.

Intraocular pressure measurement

Intraocular pressure is measured in each eye by Goldmann applanation tonometry. Measuring central corneal thickness should be postponed until resolution of an AACC.¹⁰⁷

Gonioscopy

Gonioscopy of both eyes should be performed on all patients in whom PACD is suspected to evaluate the angle anatomy, including the presence of ITC and/or PAS, and plateau iris configuration.¹⁰⁸ Compression (indentation) gonioscopy with a four-mirror or similar lens is particularly helpful to determine if visible appositional closure is actually permanent synechial closure and, if so, the extent of such PAS. Gonioscopy should be performed in a dark room with a bright, short (approximately 1 mm in length) beam that does not pass through the pupil to avoid inducing pupillary constriction, which can widen the angle.¹⁰⁹ Waiting for 10 seconds after placement of the gonioscopy lens allows the pupil to resume its resting state and may demonstrate pupillary block configuration when it reaches a mid-dilated position. A useful technique to examine a narrow anterior chamber angle is to have the patient look slightly towards the mirror of the gonioprism into which the examiner is looking. The gonioscopy lens may also be used to examine the optic disc through the central portion of the lens.

Gonioscopic visualization of the angle may be impaired secondary to corneal edema in the setting of AACC. Topical glycerin may be used to clear the cornea to obtain a better view. (See www.gonioscopy.org for discussion of the techniques of gonioscopy.)

Other components of the initial evaluation

Although a dilated examination may not be advisable for patients with ITC, an attempt should be made to optimally evaluate the fundus and optic nerve head clinically by using the direct ophthalmoscope or the slit-lamp biomicroscope with an indirect lens (e.g., 78-diopter or 90-diopter lens), the central portion of the gonioscopy lens, or by imaging the retina and optic nerve with photography using a nonmydriatic camera through an undilated pupil. In many cases, it may also be possible to obtain OCT imaging of the optic nerves through an undilated pupil to ascertain and document the status of the optic nerve. For patients with suspected PACD, pupil dilation should be done with caution. As appropriate, these patients should be warned about signs and symptoms until an iridotomy has been performed, since dilation can precipitate AACC.⁶⁴ However, if dilation is deemed essential (e.g., for suspected retinal pathology), cautious dilation can be performed. If AACC is

precipitated by dilation in the clinic, it can be successfully managed during the encounter (see section on Management). Once an iridotomy has been performed, a dilated examination of the retina and optic nerve can be done for more complete documentation of the optic nerve head and retinal nerve fiber layer. (See Primary Open-Angle Glaucoma PPP for a detailed description of the evaluation.¹⁵)

Diagnostic Testing

Diagnostic testing that may be used to further evaluate patients with PACD includes the following:

- ◆ Anterior segment imaging
- ◆ Ocular biometry
- ◆ Provocative testing

Anterior segment imaging

Anterior segment imaging may be a useful adjunct to gonioscopy and is particularly helpful when the ability to perform gonioscopy is precluded by corneal disease or poor patient cooperation. Anterior segment optical coherence tomography can be used to characterize the angle qualitatively and quantitatively. Quantitative characteristics, available from software included with AS-OCT machines, include angle opening depth, trabecular-iris space area and angle recess area,¹¹⁰ iridotrabecular contact index,¹¹¹ lens vault,¹¹² and iris volume.¹¹²

Although AS-OCT can be very useful, it has limitations in evaluating the angle. Neither the posterior aspect of the iris nor the ciliary body are well imaged with AS-OCT, reducing the utility of AS-OCT in evaluating plateau iris configuration or ciliary body abnormalities. Isolated PAS or small tufts of neovascularization may be missed if not in the plane imaged by AS-OCT. Patchy pigment throughout the angle (indicative of intermittent ITC) would also not be recorded in AS-OCT. Swept source OCT offers a clear advantage over time domain OCT in this regard.¹¹³ However, even swept source OCT demonstrates only moderate agreement with gonioscopy assessment of angle closure.¹¹⁴ The quantitative measurements made possible by AS-OCT and the ability to repeat these measurements over time may lead to a better understanding of the natural history and prognosis of angle closure. For example, increased iris volume as measured by AS-OCT is associated with increased risk of persistent angle closure (by gonioscopic view) following laser iridotomy.¹¹²

Ultrasound biomicroscopy provides better characterization of the posterior iris and ciliary body compared with AS-OCT.¹¹⁵ Although UBM is more operator dependent and time consuming than AS-OCT, UBM is a better imaging modality than AS-OCT for identifying plateau iris configuration or characterizing the position of the ciliary body.²⁶

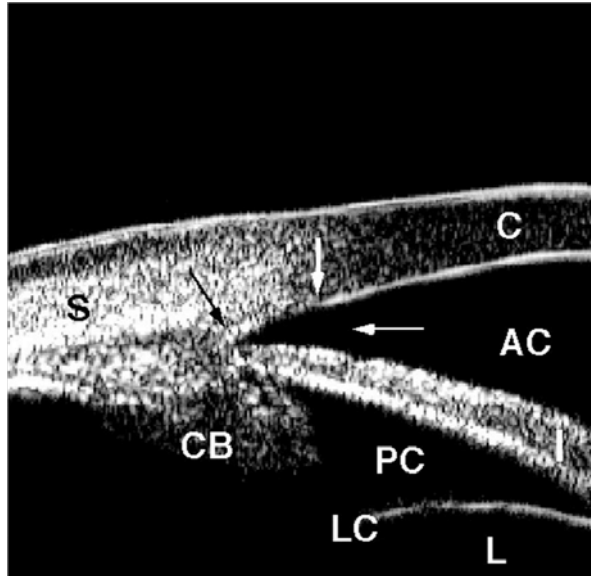


FIGURE 2 Normal-angle anatomy by ultrasound biomicroscopy.

AC = anterior chamber; C = cornea; CB = ciliary body with ciliary processes at tip; I = iris; L = lens; LC = lens capsule; PC = posterior chamber; S = sclera; black arrow = scleral spur; thick white arrow = Schwalbe's line; thin white arrow = angle recess or approach

Courtesy of Pat-Michael Palmiero, MD. Adapted with permission from the American Academy of Ophthalmology Knowledge Base Glaucoma Panel. Practicing Ophthalmologists Learning System 2014–2016. Glaucoma review outline. Diagnostic tests: ultrasound biomicroscopy.

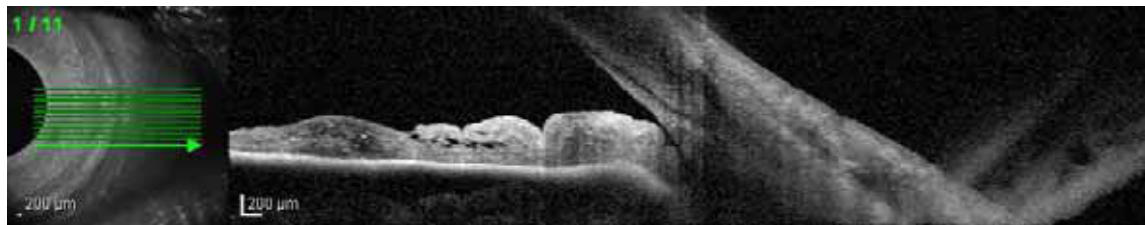

FIGURE 3. Anterior segment optical coherence tomography image of a narrow angle. Courtesy of Sanjay Asrani, MD.

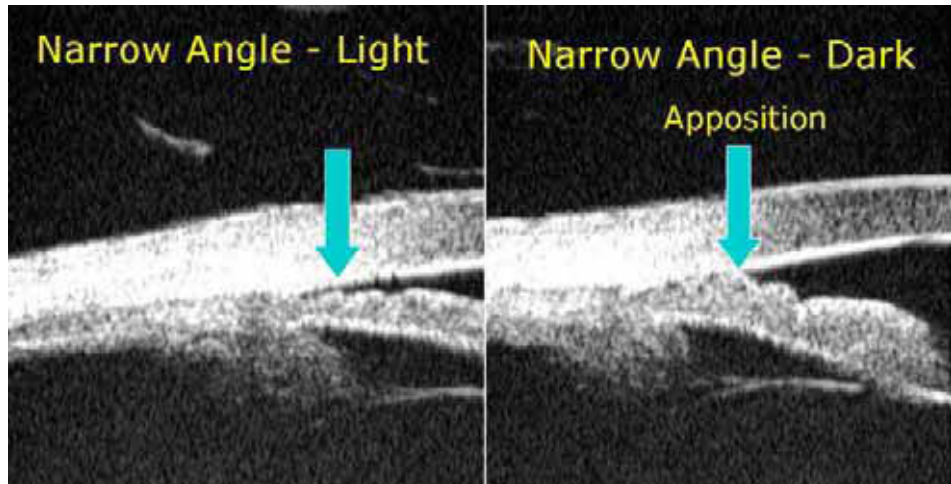


FIGURE 4. Comparative ultrasound biomicroscopy images of a narrow, occludable angle seen to be barely open in the light (left) and appositionally closed in the dark (right), denoted by arrow.

Courtesy of Pat-Michael Palmiero, MD. Adapted with permission from the American Academy of Ophthalmology Knowledge Base Glaucoma Panel. Practicing Ophthalmologists Learning System 2014–2016. Glaucoma review outline. Diagnostic tests: ultrasound biomicroscopy.

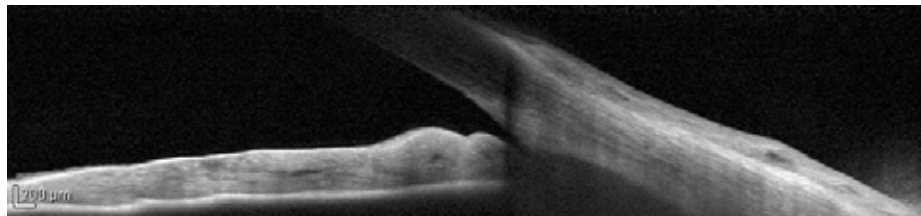


FIGURE 5a. Anterior segment optical coherence tomography image showing a narrow-angle pre-laser peripheral iridotomy. Courtesy of Michele C. Lim, MD.

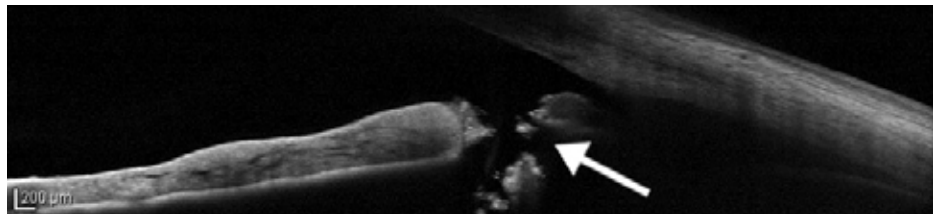


FIGURE 5b. Anterior segment optical coherence tomography image showing a narrow-angle post-laser peripheral iridotomy. Arrow indicates iridotomy. Courtesy of Michele C. Lim, MD.

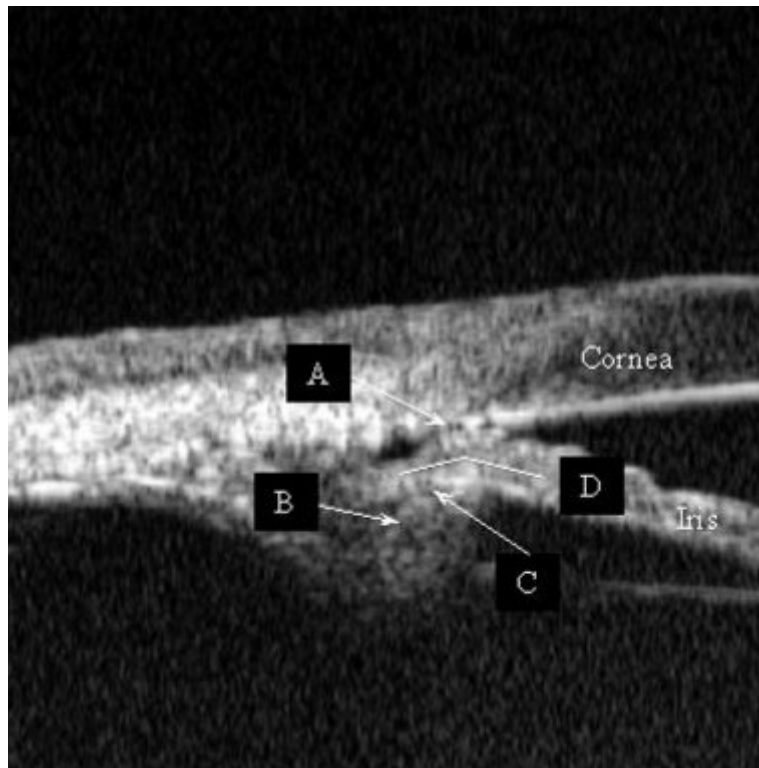


FIGURE 6. Ultrasound biomicroscopy image of a quadrant showing plateau iris after laser peripheral iridotomy. Features shown: (A) irido-angle touch, (B) anteriorly rotated ciliary process, (C) absent ciliary sulcus, and (D) iris angulation.

Adapted with permission from Kumar RS, Baskaran M, Chew PT, et al. Prevalence of plateau iris in primary angle closure suspects an ultrasound biomicroscopy study. *Ophthalmology*. 2008;115(3):430-434.

Ocular biometry

A clinician may consider ocular biometry in angle closure to determine axial length and intraocular lens power for cataract surgery. A short axial length may indicate nanophthalmos. Nanophthalmos is a small but otherwise normal eye with an axial length <20.0 mm. Other signs of nanophthalmos may include a small horizontal corneal diameter (<11.0 mm) and high hyperopia. Clinicians should diagnose nanophthalmos prior to incisional surgery to avoid complications such as anterior chamber shallowing and aqueous misdirection. Intraoperative maneuvers include scleral windows,¹¹⁶⁻¹¹⁸ decompressing the vitreous pharmacologically with mannitol or mechanically with vitrectomy, and/or using cohesive viscoelastics to avoid anterior chamber shallowing.

Provocative testing

Careful gonioscopic examination and synthesis of the clinical findings have largely replaced the use of provocative tests (such as dark-room prone positioning and pre- and postdilation IOP measurement) to make therapeutic decisions for patients at risk for PAC. In the Zhongshan Angle Closure Prevention (ZAP) trial, a single-center, randomized controlled trial of laser peripheral iridotomy for PACS, dark-room prone provocative testing was performed, comparing pre-test IOP to IOP measured after 15 minutes in a dark room with the participant in the prone position. No potential participants experienced IOP elevation with prone-dark testing.¹³

Differential Diagnosis

Because PACS and PAC tend to be bilateral, the observation of a wide open angle in the fellow eye suggests a diagnosis other than PACD. Other entities that cause secondary angle closure and that may be unilateral or bilateral can be classified as follows:

- ◆ Secondary pupillary block
 - ◆ Uveitis causing a secluded pupil
 - ◆ Lens-related disorders (e.g., ectopia lentis or a malpositioned intraocular lens)
 - ◆ Pupillary block due to vitreous prolapse
- ◆ Anterior pulling mechanism
 - ◆ Neovascularization of the iris
 - ◆ Epithelial or fibrous ingrowth
 - ◆ Descemetization of the anterior chamber angle, as in iridocorneal endothelial syndrome
 - ◆ Contracture of inflammatory precipitates
 - ◆ Axenfeld-Rieger syndrome
 - ◆ PAS following anterior segment surgery
- ◆ Posterior pushing mechanism
 - ◆ Retinal conditions leading to the forward shift of the lens-iris diaphragm
 - Ciliary body edema and/or uveal effusion secondary to:
 - Central retinal vein occlusion
 - Panretinal photocoagulation
 - Placement of a scleral buckle
 - Medication (e.g., topiramate, sulfonamides)
 - Intraocular gas or silicone oil with forward displacement of the lens-iris diaphragm
 - Persistent fetal vasculature
 - Chronic serous choroidal detachment
 - Hemorrhagic choroidal detachment (suprachoroidal hemorrhage)
 - Intraocular tumors (mass effect or direct angle invasion)
 - Retinopathy of prematurity
 - ◆ Aqueous misdirection (malignant glaucoma)

MANAGEMENT

Goals

The goals of managing a patient with PACD are as follows:

- ◆ Reverse or prevent the angle-closure process
- ◆ Control IOP
- ◆ Prevent damage to the optic nerve

Primary Angle-Closure Suspect

A large population-based, randomized clinical trial in Zhongshan, China has recently shown the benefit of iridotomy for PACS, with a 50% reduction in risk for development of PAC over 6 years. However, the rarity of progression (4%) to PAC led the authors to conclude that laser peripheral iridotomy (LPI) was not justified in similar populations.¹³ Observational studies suggest that the majority of patients with PACS will not develop either PAC or PACG.^{12, 119} Yet historically, the relative safety of LPI has resulted in its wider prophylactic use for the prevention of AACC and PACG. In patients with PACS, iridotomy may be considered to reduce the risk of developing angle closure. Alternatively, patients with ITC may be followed

for the development of IOP elevation, evidence of progressive narrowing, or synechial angle closure, since iridotomy can be associated, rarely, with bothersome postoperative glare and/or diplopia. Other rare complications of LPI include progression of cataract and the development of posterior synechiae.

Other factors that may influence the decision to perform prophylactic laser iridotomy in PACS include the following:

- ◆ Medication is required that may provoke pupillary block
- ◆ Symptoms are present that suggest prior intermittent AACC
- ◆ The patient's health status or occupation/avocation makes it difficult to access immediate ophthalmic care (e.g., the patient resides in a nursing home facility, travels frequently to developing parts of the world, works on a merchant vessel), or if the patient is poorly compliant with follow-up
- ◆ There is a need for frequent dilated eye examinations (e.g., macular degeneration or diabetic retinopathy evaluations)

Patients with PACS who have not had an iridotomy should be warned that they are at risk for AACC and that certain medicines (e.g., over-the-counter decongestants, cold and flu medications, allergy medications, and sleeping aids as well as prescription psychoactive and motion-sickness medication, all of which may have anticholinergic properties) could cause pupil dilation and induce AACC.⁶⁴ They should also be informed about the symptoms of AACC and instructed to notify their ophthalmologist immediately if symptoms occur.¹¹⁹ Some PACS patients develop increased IOP and eventually require topical ocular hypotensive agents despite LPI.^{13, 120, 121}

Primary Angle Closure and Primary Angle-Closure Glaucoma

Patients with PAC may have elevated IOP as a result of a chronic compromise of aqueous outflow due to appositional or synechial angle closure, or from damage to the trabecular meshwork after previous intermittent AACC. Although some authors advocate that iridotomy is indicated for all eyes with PAC or PACG,^{9, 122} other reports indicate that PACG eyes with advanced optic nerve damage and extensive PAS (>180 degrees) may benefit less from LPI,¹²³ particularly if lens extraction is being considered. Laser iridotomy may be performed using a thermal and/or Nd:YAG laser.

Complications of laser iridotomy include increased IOP; laser burn to the cornea, lens, or retina; late-onset corneal edema; the development of posterior synechiae; hyphema; iritis; and the development of ocular light-induced visual disturbance. Light-induced visual disturbance may result from the prismatic effect of the tear film at the eyelid margin or from the shutter effect of the eyelid partially covering an iridotomy that is adjacent to the eyelid margin and either not fully covered by the eyelid or not fully exposed at the 3 or 9 o'clock position. Some authors have reported a reduced risk of light-induced visual disturbance with horizontal placement of the iridotomy.¹²⁴ However, other randomized trials have shown no difference in light-induced visual disturbance symptoms between temporal and superior placement, or between superior quadrant LPI location with full, partial, or no eyelid coverage of the iridotomy.^{125, 126}

A recent multicenter, randomized clinical trial, Effectiveness in Angle-closure Glaucoma of Lens Extraction (EAGLE),¹²⁷ showed that clear lens extraction provided greater IOP control and quality of life benefit for PAC patients with elevated IOP and PACG patients compared with standard care with LPI.¹²⁷ Therefore, cataract (or clear lens) extraction could be considered for management of PAC and PACG (see section on Lens extraction for angle closure, below).

Surgery and Postoperative Care

The ophthalmologist who performs the laser iridotomy or incisional iridectomy has the following responsibilities:

- ◆ Obtain informed consent from the patient or the patient's surrogate decision maker after discussing the risks, benefits, and expected outcomes of surgery¹²⁸

- ◆ Ensure that the preoperative evaluation confirms the need for surgery¹²⁸
- ◆ Consider the preoperative use of a parasympathomimetic to facilitate LPI
- ◆ Use topical ocular hypotensive agents perioperatively to prevent sudden IOP elevation, particularly for patients who have severe disease¹²⁹
- ◆ Ensure the patency of the iridotomy by directly visualizing fluid flow of aqueous and pigment from the posterior to the anterior chamber. Visualization of a red reflex alone is insufficient to confirm patency.
- ◆ Enlarge the iridotomy as necessary to achieve diameter of at least 100 microns¹³⁰
- ◆ Perform at least one IOP check immediately prior to surgery and within 30 minutes to 2 hours following laser surgery^{129, 131-133}
- ◆ Prescribe topical corticosteroids in the postoperative period
- ◆ Ensure that the patient receives adequate postoperative care¹³⁴

Follow-up evaluations in the days and weeks after surgery should include the following elements:

- ◆ Confirm the patency of the iridotomy by visualizing zonules, the anterior lens capsule, or ciliary processes
- ◆ Measure IOP
- ◆ Perform dark-room gonioscopy with compression/indentation to assess the extent of PAS if it was not performed immediately following the iridotomy
- ◆ Examine the fundus as clinically indicated

Following LPI for PACD, persistent or progressive elevations of IOP and complications may occur for several reasons:

- ◆ Trabecular damage or formation of PAS may have occurred during iridocorneal apposition.
- ◆ If the iridotomy becomes occluded, pupillary block may recur, and repeat iridotomy is indicated. Retreatment with laser surgery or a surgical iridectomy may be needed.
- ◆ Factors other than pupillary block may lead to angle closure and may have gone unrecognized until after the iridotomy. These include plateau iris syndrome, phacomorphic angle closure, and secondary causes of angle closure (see Differential Diagnosis section).
- ◆ Angle closure may be superimposed on pre-existing open-angle glaucoma or on another cause of IOP elevation, such as pseudoexfoliation syndrome.¹³⁵⁻¹³⁸

Additional treatment of PAC or PACG after the component of pupillary block has been alleviated by iridotomy is directed at lowering IOP to prevent or retard pressure-induced optic nerve damage and is similar to the treatment of primary open-angle glaucoma.¹⁵ Reopening an appositionally closed angle by laser iridoplasty or a synechially closed angle with goniosynechialysis may improve aqueous outflow, especially when it is performed within 6 to 12 months of an AACC.¹³⁹⁻¹⁴²

Additional management for elevated IOP that threatens the optic nerve is the same as for primary open-angle glaucoma (see Primary Open-Angle Glaucoma PPP¹⁵). It includes chronic topical ocular hypotensive agents, incisional surgery, and, rarely, laser trabeculoplasty if, in the judgment of the treating ophthalmologist, sufficiently open trabecular meshwork exists following LPI to expect a reasonable IOP reduction.¹⁴³⁻¹⁴⁵ In addition, a growing body of evidence indicates that cataract extraction alone may lead to substantial IOP lowering in some PAC and PACG patients and can be considered as an option for treatment.^{127, 146-163}

Acute Angle-Closure Crisis

Acute attack management

The initial treatment of AACC is aimed at lowering IOP to relieve the acute symptoms and potentially harmful high IOP. Several methods have been studied, including medical therapy alone, LPI (if the iris can be visualized and the procedure can be performed),

peripheral laser iridoplasty, and paracentesis.¹⁶⁴⁻¹⁶⁶ However, most patients are treated acutely with medications.

In AACC, medical therapy is usually initiated first to lower the IOP to reduce pain and to clear corneal edema. Iridotomy should then be performed as soon as possible.⁹ Iridotomy (or iridectomy) allows aqueous to bypass the pupillary block and eliminates the pressure gradient between the posterior and anterior chambers.

Medical therapy includes some or all of the following, taking into consideration medical conditions that may represent contraindications to treatment with specific agents:¹⁶⁷

- ◆ Topical beta-adrenergic antagonists^{168, 169}
- ◆ Topical alpha₂-adrenergic agonists¹⁶⁸
- ◆ Topical, oral, or intravenous carbonic anhydrase inhibitors¹⁶⁹
- ◆ Topical parasympathomimetics^{169, 170}
- ◆ Oral or intravenous hyperosmotic agents

Agents that suppress aqueous humor formation (beta-adrenergic antagonists, carbonic anhydrase inhibitors) may be ineffective initially, because they may have decreased ability to reduce aqueous formation if the ciliary body is ischemic. The configuration of the iris becomes less bowed with pupillary constriction, therefore treatment using parasympathomimetics may open the angle; however, pressure-induced ischemia of the pupillary sphincter makes the pupil unresponsive to miotic therapy when the IOP is markedly elevated. Parasympathomimetic treatment may be ineffective in cases of secondary pupillary block due to intraocular gas, oil, or vitreous, or if the intraocular lens or crystalline lens is blocking the pupil. In these cases, mydriatics may be more effective. Systemic hyperosmotic agents may need to be used to achieve a rapid decrease in IOP in the setting of AACC. Corneal indentation performed with a four-mirror gonioscopic lens, cotton-tipped applicator, or tip of a muscle hook may help break pupillary block.¹⁷¹

Laser iridotomy is the preferred surgical treatment because it has a favorable risk-benefit ratio.^{19, 172, 173} Iridotomy relieves pupillary block and can prevent or retard the formation of PAS. Iridotomy can also result in significant angle widening and iris-profile flattening.¹⁷⁴⁻¹⁷⁶ Timely treatment may prevent damage to the optic nerve, trabecular meshwork, iris, lens, and cornea. If an iridotomy cannot be performed due to iris congestion or corneal edema, the cornea may sometimes be cleared with topical hyperosmotic agents, anterior chamber paracentesis, or iridoplasty.¹⁷⁷⁻¹⁸⁵ Once the attack is broken, it is usually possible to perform a definitive laser iridotomy immediately or soon afterward.

When laser iridotomy is not possible or if the AACC cannot be medically broken, LPI (even with a cloudy cornea),¹⁸⁴ paracentesis,^{166, 186} and incisional iridectomy remain effective alternatives. When incisional iridectomy is required and extensive synechial closure is recognized or suspected, simultaneous primary filtering surgery may be considered. Concurrent glaucomatous cupping of the optic disc often indicates a prolonged chronic course before the onset of acute symptoms, and filtering surgery can be considered, especially if the presence of considerable PAS is confirmed on gonioscopy. Filtering surgery in eyes with unbroken AACC has a high risk of anterior chamber shallowing postoperatively, related to the development of aqueous misdirection, choroidal effusions, or aqueous hyposecretion.^{187, 188} Other treatments for AACC unresponsive to conventional treatment include primary phacoemulsification¹⁵⁸ and cyclophotocoagulation.¹⁸⁹ A 2019 Cochrane Systematic Review identified only one ongoing study that met inclusion criteria comparing phacoemulsification with endocyclophotocoagulation to phacoemulsification alone in patients with PACG, and no completed studies. Thus, the selection of cyclophotocoagulation over other procedures should be left to the discretion of the treating ophthalmologist, in consultation with the individual patient.¹⁹⁰ (*I, Insufficient Quality, Discretionary Recommendation*)

Fellow-eye management

The fellow eye of a patient with AACC should be evaluated, because it is at high risk for a similar event. The fellow eye should be scheduled for a prophylactic LPI promptly if the chamber angle is anatomically narrow, since approximately half of fellow eyes of acute angle-closure patients can develop AACCs within 5 years.^{88, 89, 119, 122, 191-193} These attacks can occur within days of presentation and, therefore, an ophthalmologist should consider LPI in the fellow eye as soon as possible. Chronic parasympathomimetic therapy is not an appropriate alternative, either for prophylaxis of the fellow eye or for treatment of established angle closure, and it is not a substitute for iridotomy. About 40% of fellow eyes treated with parasympathomimetics can develop an AACC within 5 years, and many eyes with PACD can develop progressive formation of synechial angle closure with miotic use.^{89, 193} Prophylactic LPIs are effective in preventing AACC in the fellow eye,¹⁹² although one study found that 53% of fellow eyes developed PACG after almost 6 years of follow-up, even after prophylactic LPI was performed.¹⁹⁴

Lens extraction for angle closure

Numerous studies document that lens extraction significantly widens the anterior chamber angle in eyes that have PACD.¹⁴⁶⁻¹⁵⁰ In prospective and retrospective studies, cataract surgery also has been shown to lower postoperative medication requirements and decrease complications compared with iridectomy, iridotomy, or trabeculectomy for PACG¹⁵²⁻¹⁶² and AACC.¹⁶³ Although lens extraction with or without goniosynechialysis¹⁹⁵⁻¹⁹⁷ can substantially lower IOP, it has been documented that cataract extraction alone does not result in as low an IOP as cataract surgery combined with trabeculectomy.¹⁹⁸ The risks and benefits of different procedures in eyes with angle closure should be considered when determining the most appropriate surgery.

In patients with AACC, phacoemulsification performed soon after initial medical reduction of IOP is effective in maintaining IOP control and reducing the need for glaucoma medications.^{158, 163, 199} However, cataract surgery in AACC eyes may have greater risk of operative complications due to the small dimensions of the anterior chamber and the tendency for choroidal expansion.

The EAGLE Study has recently shown the effectiveness of clear lens extraction with intraocular lens implantation for the treatment of PAC with elevated IOP (≥ 30 mm Hg at diagnosis) and PACG.¹²⁷ This study found clear lens extraction to be superior to LPI for IOP control in PAC with elevated IOP and PACG; in addition, patients had better quality of life scores. Treatment with phacoemulsification was estimated to be cost-effective at 3 years and cost saving by 10 years in the United Kingdom.²⁰⁰

Plateau Iris Configuration and Syndrome

The success of prophylactic laser iridoplasty after laser iridotomy to prevent PACG and AACC in eyes with plateau iris has been reported in a case series.²⁰¹ However, a 2012 Cochrane review found no randomized controlled trials to provide evidence to support the use of this procedure in these eyes.²⁰² Given the lack of convincing evidence in the literature for prophylactic use of iridoplasty in these patients, and since iridoplasty can be painful for the patient and may cause inflammation, the decision of whether to observe or treat these eyes is left to the judgment of the treating ophthalmologist (*I-, Moderate Quality, Strong Recommendation*). Eyes with plateau iris syndrome that experience recurrent high IOP associated with a closed angle on gonioscopy after iridotomy should undergo further therapy. Additional treatment could include iridoplasty, chronic parasympathomimetic therapy, or other surgical procedures, including cataract or clear lens extraction, although lens surgery does not guarantee that AACC will not occur.⁹ Two recent small case series studies indicate that endoscopic cycloplasty can address the ciliary process configuration and may improve IOP control in plateau iris patients.^{203, 204} However, this procedure was combined with cataract extraction in these reports, and no studies have compared cataract extraction with and without endoscopic cycloplasty in this patient population.

Follow-up Evaluation

The recommendations for follow-up evaluations after iridotomy for angle closure apply to ongoing management of PACD and not to visits for other purposes. Following LPI, patients may have an open anterior chamber angle or an anterior chamber angle with a combination of open sectors with areas occluded by PAS. With or without glaucomatous optic neuropathy, patients with a residual open angle or a combination of open angle and some PAS should be followed at appropriate intervals to check for increasing PAS.⁹ Special attention should be given to repeat gonioscopy to determine interval changes such as increased extent of PAS or development of secondary angle closure from cataract progression and increased lens thickness. Subsequent follow-up intervals depend on the clinical findings and judgment of the treating ophthalmologist.

If IOP remains elevated long term and the patient develops PAC or PACG, then ongoing medical therapy to lower IOP may become necessary. In such a situation, follow-up procedures and intervals would be dictated by the same principles outlined in the Primary Open-Angle Glaucoma PPP. As in primary open-angle glaucoma, adherence to medical therapy may be handicapped when patients run out of medication, due to inadvertent drop wastage or inability to properly instill eyedrops, before they are permitted to refill their prescription. One study found this was more likely for patients who self-administered eyedrop medications when visual acuity was worse than 20/70 in either eye.²⁰⁵ However, according to a 2010 directive, patients with Medicare insurance may now refill their medication after they have completed at least 70% of the month, or approximately 21 days of therapy.²⁰⁶

PROVIDER AND SETTING

The performance of certain diagnostic procedures (e.g., tonometry, perimetry, pachymetry, anterior segment imaging, optic disc imaging, and photography) may be delegated to appropriately trained and supervised personnel. However, the interpretation of results and medical and surgical management of disease require the medical training, clinical judgment, and experience of the ophthalmologist. Most diagnostic and therapeutic procedures can be undertaken safely on an outpatient basis. Hospitalization may be indicated for intensive treatment of an AACC so that patients can be monitored closely after surgical procedures associated with a high risk of serious short-term postoperative complications. It may also be indicated for patients who have experienced surgical complications or for patients who have special medical or social needs.

COUNSELING AND REFERRAL

If the diagnosis or management of PACD is in question or is refractory to treatment, consultation with or referral to an ophthalmologist with special training or experience in managing these conditions may be indicated. Patients with substantial visual impairment or blindness may benefit from appropriate vision rehabilitation and social services. More information on vision rehabilitation, including materials for patients, is available at www.aoa.org/smart-sight-low-vision.

SOCIOECONOMIC CONSIDERATIONS

At the individual patient level, research has demonstrated that glaucomatous vision loss can have a dramatic impact on a patient's well-being. Patients with glaucoma may struggle with daily activities such as reading, walking, and driving.²⁰⁷ Performance of these activities deteriorates with worsening of glaucoma severity and when both eyes are affected. Studies have reported that patients with glaucoma are three times more likely to experience falls and six times more likely to be involved in motor vehicle collisions compared with controls.²⁰⁸ Quality of life is affected for patients with all stages of glaucoma, even those with early disease.²⁰⁹

The costs of managing a chronic disease like glaucoma can be broken down into direct medical costs, direct nonmedical costs, and indirect costs. Direct costs include costs of visits to eye care providers, ancillary testing, and medical and surgical interventions. One study estimated that nearly \$3 billion USD per year is spent on the direct medical costs for all forms of glaucoma.²¹⁰ Direct nonmedical

costs (e.g., costs for transportation to appointments and nursing home care) and indirect costs (e.g., loss of productivity of the patient or caregivers) can be more difficult to quantify but are substantial. Using California Medicare claims data and Markov modeling, one study estimated that the average direct and indirect medical costs for patients with glaucoma are \$1688 higher over a lifetime than for other patients without this condition.²¹¹

Costs of glaucoma are impacted by disease severity and type of glaucoma. One study determined the average annual direct medical costs for patients with early glaucoma, advanced glaucoma, and end-stage glaucoma were \$623, \$1915, and \$2511, respectively.²¹² Among patients with early glaucoma, most of the costs of care are for medications.²¹³ For those with advanced disease, indirect costs such as costs for home health care and rehabilitation predominate.^{214, 215} A study of enrollees in Medicare using 2009 claims data compared mean payments per beneficiary for those with open-angle glaucoma versus angle-closure glaucoma. The study found the mean payment for angle-closure glaucoma beneficiaries was significantly higher (\$303 compared with \$263 USD). The higher costs in the study were driven by mean greater use of laser surgery in the angle-closure beneficiary group.²¹⁶

When considering the economic burden of glaucoma, it is important to appreciate that glaucoma affects a disproportionately large number of racial minorities. In fact, glaucoma is the leading cause of blindness among African Americans, and studies have demonstrated greater risk of glaucoma among Latinos and Asian Americans relative to non-Hispanic whites as well. Various studies have noted disparities in utilization of eye care services among racial minorities. Studies have demonstrated that African Americans are somewhat less likely to undergo examinations for glaucoma relative to whites,^{217, 218} have lower rates of undergoing visual field testing relative to whites in the year before glaucoma surgery,²¹⁹ and have lower rates of using of medical and surgical interventions for glaucoma.²²⁰ A more recent study found that despite possessing health insurance, Latinos were significantly less likely to undergo monitoring for glaucoma relative to whites.²²¹ In the care of patients with glaucoma and at risk for glaucoma, it will be important to ensure that racial minorities and socioeconomically disadvantaged patients have adequate access to eye care services and receive care that is in line with recommended clinical practice guidelines.

APPENDIX 1. QUALITY OF OPHTHALMIC CARE CORE CRITERIA

*Providing quality care
is the physician's foremost ethical obligation, and is
the basis of public trust in physicians.
AMA Board of Trustees, 1986*

Quality ophthalmic care is provided in a manner and with the skill that is consistent with the best interests of the patient. The discussion that follows characterizes the core elements of such care.

The ophthalmologist is first and foremost a physician. As such, the ophthalmologist demonstrates compassion and concern for the individual, and utilizes the science and art of medicine to help alleviate patient fear and suffering. The ophthalmologist strives to develop and maintain clinical skills at the highest feasible level, consistent with the needs of patients, through training and continuing education. The ophthalmologist evaluates those skills and medical knowledge in relation to the needs of the patient and responds accordingly. The ophthalmologist also ensures that needy patients receive necessary care directly or through referral to appropriate persons and facilities that will provide such care, and he or she supports activities that promote health and prevent disease and disability.

The ophthalmologist recognizes that disease places patients in a disadvantaged, dependent state. The ophthalmologist respects the dignity and integrity of his or her patients and does not exploit their vulnerability.

Quality ophthalmic care has the following optimal attributes, among others.

- ◆ The essence of quality care is a meaningful partnership relationship between patient and physician. The ophthalmologist strives to communicate effectively with his or her patients, listening carefully to their needs and concerns. In turn, the ophthalmologist educates his or her patients about the nature and prognosis of their condition and about proper and appropriate therapeutic modalities. This is to ensure their meaningful participation (appropriate to their unique physical, intellectual, and emotional state) in decisions affecting their management and care, to improve their motivation and compliance with the agreed plan of treatment, and to help alleviate their fears and concerns.
- ◆ The ophthalmologist uses his or her best judgment in choosing and timing appropriate diagnostic and therapeutic modalities as well as the frequency of evaluation and follow-up, with due regard to the urgency and nature of the patient's condition and unique needs and desires.
- ◆ The ophthalmologist carries out only those procedures for which he or she is adequately trained, experienced, and competent, or, when necessary, is assisted by someone who is, depending on the urgency of the problem and availability and accessibility of alternative providers.
- ◆ Patients are assured access to, and continuity of, needed and appropriate ophthalmic care, which can be described as follows.
 - ◆ The ophthalmologist treats patients with due regard to timeliness, appropriateness, and his or her own ability to provide such care.
 - ◆ The operating ophthalmologist makes adequate provision for appropriate pre- and postoperative patient care.
 - ◆ When the ophthalmologist is unavailable for his or her patient, he or she provides appropriate alternate ophthalmic care, with adequate mechanisms for informing patients of the existence of such care and procedures for obtaining it.
 - ◆ The ophthalmologist refers patients to other ophthalmologists and eye care providers based on the timeliness and appropriateness of such referral, the patient's needs, the competence and qualifications of the person to whom the referral is made, and access and availability.

- ◆ The ophthalmologist seeks appropriate consultation with due regard to the nature of the ocular or other medical or surgical problem. Consultants are suggested for their skill, competence, and accessibility. They receive as complete and accurate an accounting of the problem as necessary to provide efficient and effective advice or intervention, and in turn they respond in an adequate and timely manner. The ophthalmologist maintains complete and accurate medical records.
- ◆ On appropriate request, the ophthalmologist provides a full and accurate rendering of the patient's records in his or her possession.
- ◆ The ophthalmologist reviews the results of consultations and laboratory tests in a timely and effective manner and takes appropriate actions.
- ◆ The ophthalmologist and those who assist in providing care identify themselves and their profession.
- ◆ For patients whose conditions fail to respond to treatment and for whom further treatment is unavailable, the ophthalmologist provides proper professional support, counseling, rehabilitative and social services, and referral as appropriate and accessible.
- ◆ Prior to therapeutic or invasive diagnostic procedures, the ophthalmologist becomes appropriately conversant with the patient's condition by collecting pertinent historical information and performing relevant preoperative examinations. Additionally, he or she enables the patient to reach a fully informed decision by providing an accurate and truthful explanation of the diagnosis; the nature, purpose, risks, benefits, and probability of success of the proposed treatment and of alternative treatment; and the risks and benefits of no treatment.
- ◆ The ophthalmologist adopts new technology (e.g., drugs, devices, surgical techniques) in judicious fashion, appropriate to the cost and potential benefit relative to existing alternatives and to its demonstrated safety and efficacy.
- ◆ The ophthalmologist enhances the quality of care he or she provides by periodically reviewing and assessing his or her personal performance in relation to established standards, and by revising or altering his or her practices and techniques appropriately.
- ◆ The ophthalmologist improves ophthalmic care by communicating to colleagues, through appropriate professional channels, knowledge gained through clinical research and practice. This includes alerting colleagues of instances of unusual or unexpected rates of complications and problems related to new drugs, devices, or procedures.
- ◆ The ophthalmologist provides care in suitably staffed and equipped facilities adequate to deal with potential ocular and systemic complications requiring immediate attention.
- ◆ The ophthalmologist also provides ophthalmic care in a manner that is cost effective without unacceptably compromising accepted standards of quality.

Reviewed by: Council

Approved by: Board of Trustees

October 12, 1988

2nd Printing: January 1991

3rd Printing: August 2001

4th Printing: July 2005

APPENDIX 2. INTERNATIONAL STATISTICAL CLASSIFICATION OF DISEASES AND RELATED HEALTH

Primary angle-closure disease includes the entity of primary angle-closure glaucoma and related entities with the following ICD-10 classifications:

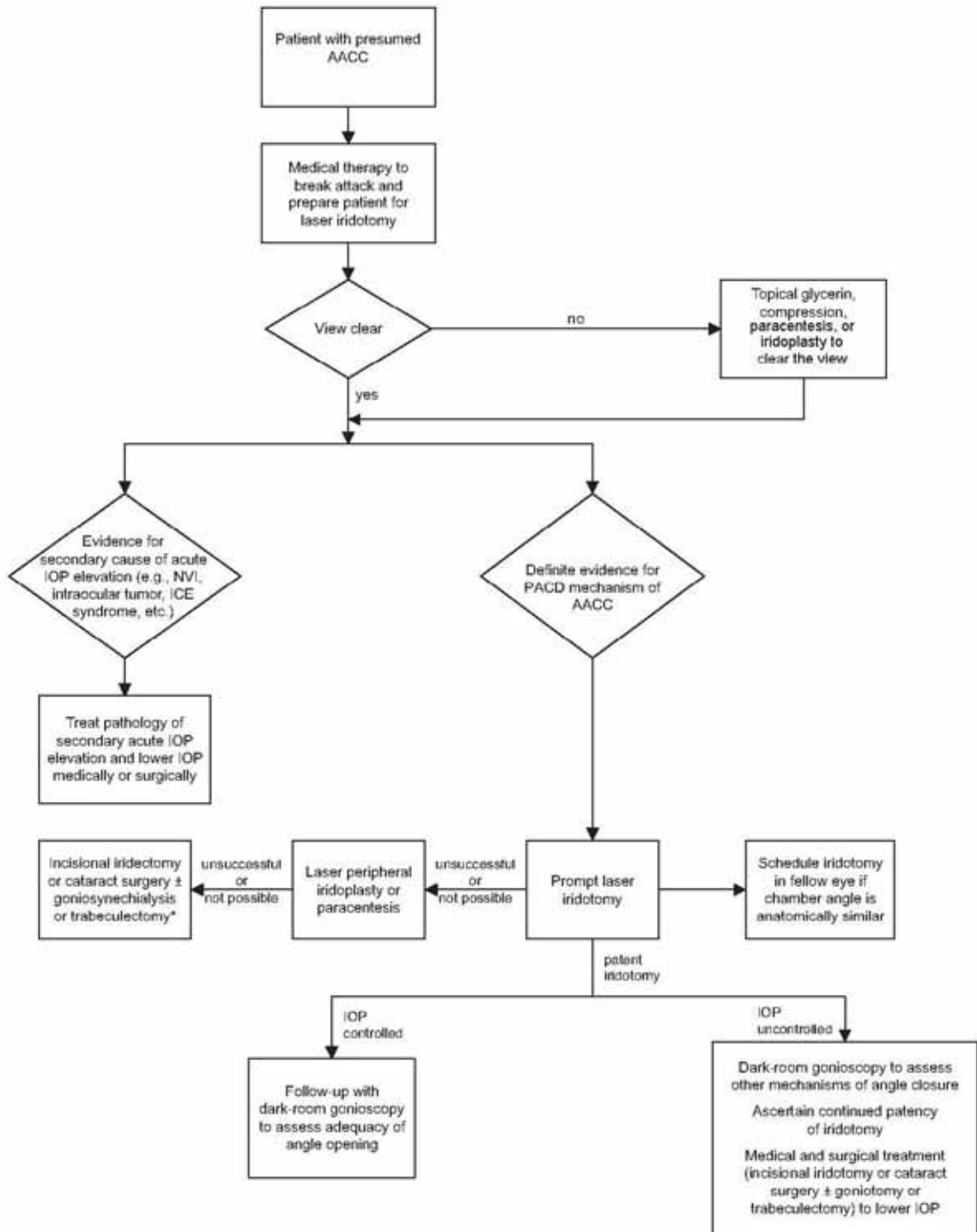
	ICD-10 CM
Primary angle-closure glaucoma (PACG)	H40.20X-
Acute angle-closure glaucoma (AACC)	H40.211 H40.212 H40.213
Intermittent angle closure (PAC or PACG)	H40.231 H40.232 H40.233
Chronic angle-closure glaucoma (PACG)	H40.221- H40.222- H40.223-
Residual stage of angle-closure glaucoma	H40.241 H40.242 H40.243
Anatomical narrow angle (PACS)	H40.031 H40.032 H40.033
Plateau iris syndrome	H21.82
Primary angle closure (PAC) without glaucoma damage	H40.061 H40.062 H40.063

AACC = acute angle-closure crisis; PAC = primary angle closure; PACG = primary angle-closure glaucoma; CM = Clinical Modification used in the United States; (-) = 0, stage unspecified; 1, mild stage; 2, moderate stage; 3, severe stage; 4, indeterminate stage; PACS = primary angle-closure suspect

Additional information for ICD-10 codes:

- Certain ICD-10 CM categories have applicable 7th characters. The applicable 7th character is required for all codes within the category, or as the notes in the Tabular List instruct. The 7th character must always be the 7th character in the data field. If a code that requires a 7th character is not 6 characters, a placeholder X must be used to fill in the empty characters.
- For bilateral sites, the final character of the codes in the ICD-10 CM indicates laterality. If no bilateral code is provided and the condition is bilateral, separate codes for both the left and right side should be assigned. Unspecified codes should be used only when there is no other code option available.
- When the diagnosis code specifies laterality, regardless of which digit it is found in (i.e., 4th digit, 5th digit, or 6th digit):
 - Right is always 1
 - Left is always 2
 - Bilateral is always 3

APPENDIX 3. ALGORITHM FOR THE MANAGEMENT OF PATIENTS WITH ACUTE ANGLE-CLOSURE CRISIS



AACC = acute angle-closure crisis, ICE = iridocorneal endothelial, IOP = intraocular pressure NVI = neovascularization of the iris, PACD = primary angle closure disease

* Indicated for extensive synechial closure or optic nerve damage.

APPENDIX 4. LITERATURE SEARCHES FOR THIS PPP

Literature searches of the PubMed and Cochrane databases were conducted in March 2019; the search strategies are provided at www.aao.org/ppp. Specific limited update searches were conducted after June 2020.

("Cataract Extraction"[Mesh] OR "cataract surgery" OR "cataract surgical" OR cataract* OR lensectomy) AND ("Glaucoma, Angle-Closure"[Mesh] OR "angle closure")

("Cataract"[Mesh] OR cataract*) AND (("laser iridotomy" OR (laser[tiab] AND iridotomy*[tiab]))

("Lasers"[Mesh] OR "Laser Therapy"[Mesh] OR "Lasers, Solid-State"[Mesh] OR laser OR lasers OR laser's OR YAG) AND (iridotomy OR iridotomies) AND occlusion

"Glaucoma, Angle-Closure"[mh] = 384 refs

("Lasers"[Mesh] OR "Laser Therapy"[Mesh] OR "Lasers, Solid-State"[Mesh] OR laser* OR YAG) AND iridotomy AND occlu*

RELATED ACADEMY MATERIALS

Basic and Clinical Science Course Glaucoma (Section 10, 2019–2020)

Ophthalmic Technology Assessment – Free downloads available at www.aaojournal.org/content/OphthalmicTechnologyAssessment.

Swept-Source OCT for Evaluating the Lamina Cribrosa OTA (2019)

The Effect of Anti-Vascular Endothelial Growth Factor Agents on Intraocular Pressure and Glaucoma OTA (2019)

Spectral-Domain OCT: Helping the Clinician Diagnose Glaucoma OTA (2018)

Laser Peripheral Iridotomy in Primary Angle Closure OTA (2018)

Disinfection of Tonometers OTA (2017)

The Effect of Phacoemulsification on Intraocular Pressure in Glaucoma Patients OTA (2015)

Patient Education

Glaucoma Brochure (2020) (also available in Spanish)

Glaucoma Patient Education Video Collection (2015)

Laser Iridotomy Brochure (2019)

Eye Drops Brochure (2019)

Glaucoma Drainage Implant Brochure (2019)

Laser Iridotomy Brochure (2019)

Laser Trabeculoplasty Brochure (2019)

Trabeculectomy Brochure (2020)

Preferred Practice Pattern® Guidelines – Free downloads available at www.aao.org/ppp.

Comprehensive Adult Medical Eye Evaluation (2020)

Primary Open-Angle Glaucoma Suspect (2020)

Vision Rehabilitation for Adults (2017)

Focal Points

Optical Coherence Tomography in Glaucoma Diagnosis (2017)

Update on Pseudoexfoliative Glaucoma (2019)

Surgical Management of Angle Closure Glaucoma (2018)

Clinical Applications of Major Glaucoma Trials (2018)

Microinvasive Glaucoma Surgery and Cataract Surgery Synergy (2018)

REFERENCES

1. Scottish Intercollegiate Guidelines Network (SIGN). SIGN 50: A guideline developer's handbook. Edinburgh: SIGN; 2015. (SIGN publication no. 50). [November 2015]. Available at: www.sign.ac.uk. Accessed November 2020.
2. Guyatt GH, Oxman AD, Vist GE, et al. Grade: An emerging consensus on rating quality of evidence and strength of recommendations. *BMJ*. 2008;336:924-926.
3. GRADE working group. Organizations that have endorsed or that are using grade. Available at: www.gradeworkinggroup.org/. Accessed November 2020.
4. Anderson DR, Jin JC, Wright MM. The physiologic characteristics of relative pupillary block. *Am J Ophthalmol*. 1991;111:344-350.
5. Tiedeman JS. A physical analysis of the factors that determine the contour of the iris. *Am J Ophthalmol*. 1991;111:338-343.
6. Jin JC, Anderson DR. The effect of iridotomy on iris contour. *Am J Ophthalmol*. 1990;110:260-263.
7. Seah SK, Foster PJ, Chew PT, et al. Incidence of acute primary angle-closure glaucoma in Singapore. An island-wide survey. *Arch Ophthalmol*. 1997;115:1436-1440.
8. Friedman DS, Gazzard G, Foster P, et al. Ultrasonographic biomicroscopy, scheinpflug photography, and novel provocative tests in contralateral eyes of Chinese patients initially seen with acute angle closure. *Arch Ophthalmol*. 2003;121:633-642.
9. Weinreb RN, Friedman DS, eds. Angle closure and angle closure glaucoma: Reports and consensus statements of the 3rd global AIGS consensus meeting on angle closure glaucoma. The Netherlands: Kugler Publications, 2006.
10. Leung CK, Cheung CY, Li H, et al. Dynamic analysis of dark-light changes of the anterior chamber angle with anterior segment OCT. *Invest Ophthalmol Vis Sci*. 2007;48:4116-4122.
11. Thomas R, Parikh R, Muliyl J, Kumar RS. Five-year risk of progression of primary angle closure to primary angle closure glaucoma: A population-based study. *Acta Ophthalmol Scand*. 2003;81:480-485.
12. Thomas R, George R, Parikh R, et al. Five year risk of progression of primary angle closure suspects to primary angle closure: A population based study. *Br J Ophthalmol*. 2003;87:450-454.
13. He M, Jiang Y, Huang S, et al. Laser peripheral iridotomy for the prevention of angle closure: A single-centre, randomised controlled trial. *Lancet*. 2019;393:1609-1618.
14. Hamanaka T, Kasahara K, Takemura T. Histopathology of the trabecular meshwork and schlemm's canal in primary angle-closure glaucoma. *Invest Ophthalmol Vis Sci*. 2011;52:8849-8861.
15. American Academy of Ophthalmology Glaucoma Panel. Preferred Practice Pattern® Guidelines. Primary open-angle glaucoma. San Francisco, CA: American Academy of Ophthalmology, 2015.
16. Lowe RF. Clinical types of primary angle closure glaucoma. *Aust N Z J Ophthalmol*. 1988;16:245-250.
17. Pavlin CJ, Ritch R, Foster FS. Ultrasound biomicroscopy in plateau iris syndrome. *Am J Ophthalmol*. 1992;113:390-395.
18. Ritch R. Plateau iris is caused by abnormally positioned ciliary processes. *J Glaucoma*. 1992;1:23-26.
19. Quigley HA. Long-term follow-up of laser iridotomy. *Ophthalmology*. 1981;88:218-224.
20. He M, Friedman DS, Ge J, et al. Laser peripheral iridotomy in primary angle-closure suspects: Biometric and gonioscopic outcomes: The Liwan eye study. *Ophthalmology*. 2007;114:494-500.
21. He M, Friedman DS, Ge J, et al. Laser peripheral iridotomy in eyes with narrow drainage angles: Ultrasound biomicroscopy outcomes. The Liwan eye study. *Ophthalmology*. 2007;114:1513-1519.
22. Kumar RS, Tantisevi V, Wong MH, et al. Plateau iris in asian subjects with primary angle closure glaucoma. *Arch Ophthalmol*. 2009;127:1269-1272.
23. Kumar G, Bali SJ, Panda A, et al. Prevalence of plateau iris configuration in primary angle closure glaucoma using ultrasound biomicroscopy in the Indian population. *Indian J Ophthalmol*. 2012;60:175-178.
24. Foster PJ, Baasanhu J, Alsbirk PH, et al. Glaucoma in mongolia. A population-based survey in Hovsgol province, Northern Mongolia. *Arch Ophthalmol*. 1996;114:1235-1241.
25. Kumar RS, Baskaran M, Chew PT, et al. Prevalence of plateau iris in primary angle closure suspects an ultrasound biomicroscopy study. *Ophthalmology*. 2008;115:430-434.
26. Mansoori T, Sarvepally VK, Balakrishna N. Plateau iris in primary angle closure glaucoma: An ultrasound biomicroscopy study. *J Glaucoma*. 2016;25:e82-86.

27. Verma S, Nongpiur ME, Oo HH, et al. Plateau iris distribution across anterior segment optical coherence tomography defined subgroups of subjects with primary angle closure glaucoma. *Invest Ophthalmol Vis Sci.* 2017;58:5093-5097.
28. Choy BN, Chan JC, Chien CP, Lai JS. Recurrent acute angle-closure attack due to plateau iris syndrome after cataract extraction with or without argon laser peripheral iridoplasty: A case report. *BMC Ophthalmol.* 2016;16:64.
29. Tran HV, Liebmann JM, Ritch R. Iridociliary apposition in plateau iris syndrome persists after cataract extraction. *Am J Ophthalmol.* 2003;135:40-43.
30. Van Rens GH, Arkell SM, Charlton W, Doesburg W. Primary angle-closure glaucoma among Alaskan Eskimos. *Doc Ophthalmol.* 1988;70:265-276.
31. Arkell SM, Lightman DA, Sommer A, et al. The prevalence of glaucoma among Eskimos of northwest Alaska. *Arch Ophthalmol.* 1987;105:482-485.
32. Bourne RR, Sorensen KE, Klauber A, et al. Glaucoma in East Greenlandic Inuit--a population survey in Ittoqqortoormiit (Scoresbysund). *Acta Ophthalmol Scand.* 2001;79:462-467.
33. Congdon NG, Quigley HA, Hung PT, et al. Screening techniques for angle-closure glaucoma in rural Taiwan. *Acta Ophthalmol Scand.* 1996;74:113-119.
34. He M, Foster PJ, Ge J, et al. Prevalence and clinical characteristics of glaucoma in adult Chinese: A population-based study in Liwan district, Guangzhou. *Invest Ophthalmol Vis Sci.* 2006;47:2782-2788.
35. Xu L, Zhang L, Xia CR, et al. The prevalence and its effective factors of primary angle-closure glaucoma in defined populations of rural and urban in Beijing [in Chinese]. *Zhonghua Yan Ke Za Zhi.* 2005;41:8-14.
36. Foster PJ, Oen FT, Machin D, et al. The prevalence of glaucoma in Chinese residents of Singapore: A cross-sectional population survey of the Tanjong Pagar district. *Arch Ophthalmol.* 2000;118:1105-1111.
37. Casson RJ, Newland HS, Muecke J, et al. Prevalence of glaucoma in rural Myanmar: The Meiktila eye study. *Br J Ophthalmol.* 2007;91:710-714.
38. Salmon JF, Mermoud A, Ivey A, et al. The prevalence of primary angle closure glaucoma and open angle glaucoma in Mamre, Western Cape, South Africa. *Arch Ophthalmol.* 1993;111:1263-1269.
39. Dandona L, Dandona R, Mandal P, et al. Angle-closure glaucoma in an urban population in Southern India. The Andhra Pradesh eye disease study. *Ophthalmology.* 2000;107:1710-1716.
40. Bourne RR, Sukdom P, Foster PJ, et al. Prevalence of glaucoma in Thailand: A population based survey in Rom Klao district, Bangkok. *Br J Ophthalmol.* 2003;87:1069-1074.
41. Vijaya L, George R, Arvind H, et al. Prevalence of angle-closure disease in a rural Southern Indian population. *Arch Ophthalmol.* 2006;124:403-409.
42. Ramakrishnan R, Nirmalan PK, Krishnadas R, et al. Glaucoma in a rural population of Southern India: The Aravind comprehensive eye survey. *Ophthalmology.* 2003;110:1484-1490.
43. Rahman MM, Rahman N, Foster PJ, et al. The prevalence of glaucoma in Bangladesh: A population based survey in Dhaka division. *Br J Ophthalmol.* 2004;88:1493-1497.
44. Shiose Y, Kitazawa Y, Tsukahara S, et al. Epidemiology of glaucoma in Japan--a nationwide glaucoma survey. *Jpn J Ophthalmol.* 1991;35:133-155.
45. Yamamoto T, Iwase A, Araie M, et al. The Tajimi study report 2: Prevalence of primary angle closure and secondary glaucoma in a Japanese population. *Ophthalmology.* 2005;112:1661-1669.
46. Tielsch JM, Katz J, Singh K, et al. A population-based evaluation of glaucoma screening: The Baltimore eye survey. *Am J Epidemiol.* 1991;134:1102-1110.
47. Buhmann RR, Quigley HA, Barron Y, et al. Prevalence of glaucoma in a rural East African population. *Invest Ophthalmol Vis Sci.* 2000;41:40-48.
48. Rotchford AP, Kirwan JF, Muller MA, et al. Temba glaucoma study: A population-based cross-sectional survey in urban South Africa. *Ophthalmology.* 2003;110:376-382.
49. Bonomi L, Marchini G, Marraffa M, et al. Prevalence of glaucoma and intraocular pressure distribution in a defined population. The Egna-Neumarkt study. *Ophthalmology.* 1998;105:209-215.
50. Mitchell P, Smith W, Attebo K, Healey PR. Prevalence of open-angle glaucoma in Australia. The Blue Mountains eye study. *Ophthalmology.* 1996;103:1661-1669.
51. Bankes JL, Perkins ES, Tsoulakis S, Wright JE. Bedford glaucoma survey. *Br Med J.* 1968;1:791-796.
52. Coffey M, Reidy A, Wormald R, et al. Prevalence of glaucoma in the west of Ireland. *Br J Ophthalmol.* 1993;77:17-21.
53. Hollows FC, Graham PA. Intra-ocular pressure, glaucoma, and glaucoma suspects in a defined population. *Br J Ophthalmol.* 1966;50:570-586.
54. Wensor MD, McCarty CA, Stanislavsky YL, et al. The prevalence of glaucoma in the Melbourne visual impairment project. *Ophthalmology.* 1998;105:733-739.

55. Klein BE, Klein R, Sponsel WE, et al. Prevalence of glaucoma. The Beaver Dam eye study. *Ophthalmology*. 1992;99:1499-1504.
56. Dielemans I, Vingerling JR, Wolfs RC, et al. The prevalence of primary open-angle glaucoma in a population-based study in the Netherlands: The Rotterdam study. *Ophthalmology*. 1994;101:1851-1855.
57. Bengtsson B. The prevalence of glaucoma. *Br J Ophthalmol*. 1981;65:46-49.
58. Foster PJ, Johnson GJ. Glaucoma in China: How big is the problem? *Br J Ophthalmol*. 2001;85:1277-1282.
59. Quigley HA, Broman AT. The number of people with glaucoma worldwide in 2010 and 2020. *Br J Ophthalmol*. 2006;90:262-267.
60. Tham YC, Li X, Wong TY, et al. Global prevalence of glaucoma and projections of glaucoma burden through 2040: A systematic review and meta-analysis. *Ophthalmology*. 2014;121:2081-2090.
61. Quigley HA, West SK, Rodriguez J, et al. The prevalence of glaucoma in a population-based study of Hispanic subjects: Proyecto ver. *Arch Ophthalmol*. 2001;119:1819-1826.
62. Leighton DA. Survey of the first-degree relatives of glaucoma patients. *Trans Ophthalmol Soc U K*. 1976;96:28-32.
63. Perkins ES. Family studies in glaucoma. *Br J Ophthalmol*. 1974;58:529-535.
64. Wolfs RC, Grobbee DE, Hofman A, de Jong PT. Risk of acute angle-closure glaucoma after diagnostic mydriasis in nonselected subjects: The Rotterdam study. *Invest Ophthalmol Vis Sci*. 1997;38:2683-2687.
65. Congdon N, Wang F, Tielsch JM. Issues in the epidemiology and population-based screening of primary angle-closure glaucoma. *Surv Ophthalmol*. 1992;36:411-423.
66. Nguyen N, Mora JS, Gaffney MM, et al. A high prevalence of occludable angles in a Vietnamese population. *Ophthalmology*. 1996;103:1426-1431.
67. Lai JS, Liu DT, Tham CC, et al. Epidemiology of acute primary angle-closure glaucoma in the Hong Kong Chinese population: Prospective study. *Hong Kong Med J*. 2001;7:118-123.
68. Stein JD, Kim DS, Niziol LM, et al. Differences in rates of glaucoma among Asian Americans and other racial groups, and among various Asian ethnic groups. *Ophthalmology*. 2011;118:1031-1037.
69. Van Herick W, Shaffer RN, Schwartz A. Estimation of width of angle of anterior chamber. Incidence and significance of the narrow angle. *Am J Ophthalmol*. 1969;68:626-629.
70. Lowe RF. Aetiology of the anatomical basis for primary angle-closure glaucoma. Biometrical comparisons between normal eyes and eyes with primary angle-closure glaucoma. *Br J Ophthalmol*. 1970;54:161-169.
71. Lavanya R, Foster PJ, Sakata LM, et al. Screening for narrow angles in the Singapore population: Evaluation of new noncontact screening methods. *Ophthalmology*. 2008;115:1720-1727.
72. Wojciechowski R, Congdon N, Anninger W, Teo Broman A. Age, gender, biometry, refractive error, and the anterior chamber angle among Alaskan Eskimos. *Ophthalmology*. 2003;110:365-375.
73. Lee DA, Brubaker RF, Ilstrup DM. Anterior chamber dimensions in patients with narrow angles and angle-closure glaucoma. *Arch Ophthalmol*. 1984;102:46-50.
74. Wishart PK, Batterbury M. Ocular hypertension: Correlation of anterior chamber angle width and risk of progression to glaucoma. *Eye (Lond)*. 1992;6 (Pt 3):248-256.
75. Lowe RF. Primary angle-closure glaucoma. Inheritance and environment. *Br J Ophthalmol*. 1972;56:13-20.
76. Alsbirk PH. Anatomical risk factors in primary angle-closure glaucoma. A ten year follow up survey based on limbal and axial anterior chamber depths in a high risk population. *Int Ophthalmol*. 1992;16:265-272.
77. Salmon JF, Swanevelder SA, Donald M. The dimensions of eyes with chronic angle-closure glaucoma. *J Glaucoma*. 1994;3:237-243.
78. Alsbirk PH. Anterior chamber depth and primary angle-closure glaucoma. I. An epidemiologic study in Greenland Eskimos. *Acta Ophthalmol (Copenh)*. 1975;53:89-104.
79. Kurita N, Mayama C, Tomidokoro A, et al. Potential of the pentacam in screening for primary angle closure and primary angle closure suspect. *J Glaucoma*. 2009;18:506-512.
80. He M, Huang W, Zheng Y, et al. Anterior chamber depth in elderly Chinese: The Liwan eye study. *Ophthalmology*. 2008;115:1286-1290.
81. Xu L, Cao WF, Wang YX, et al. Anterior chamber depth and chamber angle and their associations with ocular and general parameters: The Beijing eye study. *Am J Ophthalmol*. 2008;145:929-936.
82. Aung T, Nolan WP, Machin D, et al. Anterior chamber depth and the risk of primary angle closure in 2 East Asian populations. *Arch Ophthalmol*. 2005;123:527-532.

83. Sihota R, Lakshmaiah NC, Agarwal HC, et al. Ocular parameters in the subgroups of angle closure glaucoma. *Clin Experiment Ophthalmol*. 2000;28:253-258.
84. George R, Paul PG, Baskaran M, et al. Ocular biometry in occludable angles and angle closure glaucoma: A population based survey. *Br J Ophthalmol*. 2003;87:399-402.
85. Lavanya R, Wong TY, Friedman DS, et al. Determinants of angle closure in older Singaporeans. *Arch Ophthalmol*. 2008;126:686-691.
86. Suwan Y, Jiamsawad S, Tantraworasin A, et al. Qualitative and quantitative evaluation of acute angle-closure mechanisms. *BMC Ophthalmol*. 2017;17:246.
87. Aung T, Husain R, Gazzard G, et al. Changes in retinal nerve fiber layer thickness after acute primary angle closure. *Ophthalmology*. 2004;111:1475-1479.
88. Bain WE. The fellow eye in acute closed-angle glaucoma. *Br J Ophthalmol*. 1957;41:193-199.
89. Lowe RF. Acute angle-closure glaucoma. The second eye: An analysis of 200 cases. *Br J Ophthalmol*. 1962;46:641-650.
90. Liu X, Li M, Zhong YM, et al. Damage patterns of retinal nerve fiber layer in acute and chronic intraocular pressure elevation in primary angle closure glaucoma. *Int J Ophthalmol*. 2010;3:152-157.
91. Aung T, Friedman DS, Chew PT, et al. Long-term outcomes in asians after acute primary angle closure. *Ophthalmology*. 2004;111:1464-1469.
92. American Academy of Ophthalmology Preferred Practice Patterns Committee. Preferred Practice Pattern[®] Guidelines. Comprehensive adult medical eye evaluation. San Francisco, CA: American Academy of Ophthalmology; 2020. Available at www.aao.org/ppp. Accessed November 2020.
93. Subak-Sharpe I, Low S, Nolan W, Foster PJ. Pharmacological and environmental factors in primary angle-closure glaucoma. *Br Med Bull*. 2010;93:125-143.
94. Salmon JF. Predisposing factors for chronic angle-closure glaucoma. *Prog Retin Eye Res*. 1999;18:121-132.
95. Amerasinghe N, Zhang J, Thalamuthu A, et al. The heritability and sibling risk of angle closure in Asians. *Ophthalmology*. 2011;118:480-485.
96. Kong X, Chen Y, Chen X, Sun X. Influence of family history as a risk factor on primary angle closure and primary open angle glaucoma in a Chinese population. *Ophthalmic Epidemiol*. 2011;18:226-232.
97. Panday VA, Rhee DJ. Review of sulfonamide-induced acute myopia and acute bilateral angle-closure glaucoma. *Compr Ophthalmol Update*. 2007;8:271-276.
98. Fraunfelder FW, Fraunfelder FT, Keates EU. Topiramate-associated acute, bilateral, secondary angle-closure glaucoma. *Ophthalmology*. 2004;111:109-111.
99. Talluto D, Feith M, Allee S. Simultaneous angle closure in twins. *J Glaucoma*. 1998;7:68-69.
100. Li J, Tripathi RC, Tripathi BJ. Drug-induced ocular disorders. *Drug Saf*. 2008;31:127-141.
101. Alonso RS, Ambrosio Junior R, Paranhos Junior A, et al. Glaucoma anterior chamber morphometry based on optical Scheimpflug images. *Arq Bras Oftalmol*. 2010;73:497-500.
102. Henzan IM, Tomidokoro A, Uejo C, et al. Comparison of ultrasound biomicroscopic configurations among primary angle closure, its suspects, and nonoccludable angles: The Kumejima study. *Am J Ophthalmol*. 2011;151:1065-1073.
103. Setala K. Corneal endothelial cell density after an attack of acute glaucoma. *Acta Ophthalmol (Copenh)*. 1979;57:1004-1013.
104. Olsen T. The endothelial cell damage in acute glaucoma. On the corneal thickness response to intraocular pressure. *Acta Ophthalmol (Copenh)*. 1980;58:257-266.
105. Bigar F, Witmer R. Corneal endothelial changes in primary acute angle-closure glaucoma. *Ophthalmology*. 1982;89:596-599.
106. Markowitz SN, Morin JD. The endothelium in primary angle-closure glaucoma. *Am J Ophthalmol*. 1984;98:103-104.
107. Aghaian E, Choe JE, Lin S, Stamper RL. Central corneal thickness of Caucasians, Chinese, Hispanics, Filipinos, African Americans, and Japanese in a glaucoma clinic. *Ophthalmology*. 2004;111:2211-2219.
108. Bhargava SK, Leighton DA, Phillips CI. Early angle-closure glaucoma. Distribution of iridotrabecular contact and response to pilocarpine. *Arch Ophthalmol*. 1973;89:369-372.
109. Gazzard G, Foster PJ, Friedman DS, et al. Light to dark physiological variation in iridotrabecular angle width. *Br J Ophthalmol* 2004 Video http://bj.o.bmj.com/content/suppl/2004/10/22/88.11.DC1/88_11_report.full.
110. Jiang Y, Chang DS, Zhu H, et al. Longitudinal changes of angle configuration in primary angle-closure suspects: The Zhongshan angle-closure prevention trial. *Ophthalmology*. 2014;121:1699-1705.
111. Cho HK, Ahn D, Kee C. Evaluation of circumferential angle closure using iridotrabecular contact index after laser iridotomy by swept-source optical coherence tomography. *Acta Ophthalmol*. 2017;95:e190-e196.

112. Baskaran M, Yang E, Trikha S, et al. Residual angle closure one year after laser peripheral iridotomy in primary angle closure suspects. *Am J Ophthalmol*. 2017;183:111-117.
113. Liu S, Yu M, Ye C, et al. Anterior chamber angle imaging with swept-source optical coherence tomography: An investigation on variability of angle measurement. *Invest Ophthalmol Vis Sci*. 2011;52:8598-8603.
114. Porporato N, Baskaran M, Tun TA, et al. Understanding diagnostic disagreement in angle closure assessment between anterior segment optical coherence tomography and gonioscopy. *Br J Ophthalmol*. 2020;104:795-799.
115. Dada T, Gadia R, Sharma A, et al. Ultrasound biomicroscopy in glaucoma. *Surv Ophthalmol*. 2011;56:433-450.
116. Carricondo PC, Andrade T, Prasov L, et al. Nanophthalmos: A review of the clinical spectrum and genetics. *J Ophthalmol*. 2018;2018:2735465.
117. Rajendrababu S, Babu N, Sinha S, et al. A randomized controlled trial comparing outcomes of cataract surgery in nanophthalmos with and without prophylactic sclerostomy. *Am J Ophthalmol*. 2017;183:125-133.
118. Lemos JA, Rodrigues P, Resende RA, et al. Cataract surgery in patients with nanophthalmos: Results and complications. *Eur J Ophthalmol*. 2016;26:103-106.
119. Wilensky JT, Kaufman PL, Frohlichstein D, et al. Follow-up of angle-closure glaucoma suspects. *Am J Ophthalmol*. 1993;115:338-346.
120. Blondeau P, Jaworski L, Turcotte PC. Follow-up of angle closure glaucoma suspects after laser iridotomy in Caucasians with normal intraocular pressure at diagnosis. *Can J Ophthalmol*. 2011;46:247-253.
121. Ramani KK, Mani B, George RJ, Lingam V. Follow-up of primary angle closure suspects after laser peripheral iridotomy using ultrasound biomicroscopy and a-scan biometry for a period of 2 years. *J Glaucoma*. 2009;18:521-527.
122. Saw SM, Gazzard G, Friedman DS. Interventions for angle-closure glaucoma: An evidence-based update. *Ophthalmology*. 2003;110:1869-1878.
123. Radhakrishnan S, Chen PP, Junk AK, et al. Laser peripheral iridotomy in primary angle closure: A report by the American Academy of Ophthalmology. *Ophthalmology*. 2018;125:1110-1120.
124. Vera V, Naqi A, Belovay GW, et al. Dysphotopsia after temporal versus superior laser peripheral iridotomy: A prospective randomized paired eye trial. *Am J Ophthalmol*. 2014;157:929-935.
125. Congdon N, Yan X, Friedman DS, et al. Visual symptoms and retinal straylight after laser peripheral iridotomy: The Zhongshan angle-closure prevention trial. *Ophthalmology*. 2012;119:1375-1382.
126. Srinivasan K, Zebardast N, Krishnamurthy P, et al. Comparison of new visual disturbances after superior versus nasal/temporal laser peripheral iridotomy: A prospective randomized trial. *Ophthalmology*. 2018;125:345-351.
127. Azuara-Blanco A, Burr J, Ramsay C, et al. Effectiveness of early lens extraction for the treatment of primary angle-closure glaucoma (EAGLE): A randomised controlled trial. *Lancet*. 2016;388:1389-1397.
128. American Academy of Ophthalmology. Policy statement. Preoperative assessment: Responsibilities of the Ophthalmologist. San Francisco, CA: American Academy of Ophthalmology; 2012. Available at: www.aao.org/about/policies. Accessed November 2020.
129. Robin AL, Pollack IP, deFaller JM. Effects of topical ALO 2145 (p-aminoclonidine hydrochloride) on the acute intraocular pressure rise after argon laser iridotomy. *Arch Ophthalmol*. 1987;105:1208-1211.
130. Bochmann F, Johnson Z, Atta HR, Azuara-Blanco A. Increasing the size of a small peripheral iridotomy widens the anterior chamber angle: An ultrasound biomicroscopy study. *Klin Monbl Augenheilkd*. 2008;225:349-352.
131. Jiang Y, Chang DS, Foster PJ, et al. Immediate changes in intraocular pressure after laser peripheral iridotomy in primary angle-closure suspects. *Ophthalmology*. 2012;119:283-288.
132. Rosenblatt MA, Luntz MH. Intraocular pressure rise after argon laser trabeculoplasty. *Br J Ophthalmol*. 1987;71:772-775.
133. Barnes SD, Campagna JA, Dirks MS, Doe EA. Control of intraocular pressure elevations after argon laser trabeculoplasty: Comparison of brimonidine 0.2% to apraclonidine 1.0%. *Ophthalmology*. 1999;106:2033-2037.
134. American Academy of Ophthalmology. Policy statement. An ophthalmologist's duties concerning postoperative care. San Francisco, CA: American Academy of Ophthalmology; 2012. Available at: www.aao.org/about/policies. Accessed November 2020.
135. Ritch R. Exfoliation syndrome and occludable angles. *Trans Am Ophthalmol Soc*. 1994;92:845-944.
136. Gross FJ, Tingey D, Epstein DL. Increased prevalence of occludable angles and angle-closure glaucoma in patients with pseudoexfoliation. *Am J Ophthalmol*. 1994;117:333-336.

137. Brusini P, Tosoni C, Miani P. Increased prevalence of occludable angles and angle-closure glaucoma in patients with pseudoexfoliation. *Am J Ophthalmol.* 1994;118:540.
138. Franks WA, Miller MH, Hitchings RA, Jeffrey MN. Secondary angle closure in association with pseudoexfoliation of the lens capsule. *Acta Ophthalmol (Copenh).* 1990;68:350-352.
139. Campbell DG, Vela A. Modern goniosynechialysis for the treatment of synechial angle-closure glaucoma. *Ophthalmology.* 1984;91:1052-1060.
140. Shingleton BJ, Chang MA, Bellows AR, Thomas JV. Surgical goniosynechialysis for angle-closure glaucoma. *Ophthalmology.* 1990;97:551-556.
141. Tanihara H, Nishiwaki K, Nagata M. Surgical results and complications of goniosynechialysis. *Graefes Arch Clin Exp Ophthalmol.* 1992;230:309-313.
142. Wand M. Argon laser gonioplasty for synechial angle closure. *Arch Ophthalmol.* 1992;110:363-367.
143. Ali Aljasim L, Owaidhah O, Edward DP. Selective laser trabeculoplasty in primary angle-closure glaucoma after laser peripheral iridotomy: A case-control study. *J Glaucoma.* 2016;25:e253-258.
144. Ho CL, Lai JS, Aquino MV, et al. Selective laser trabeculoplasty for primary angle closure with persistently elevated intraocular pressure after iridotomy. *J Glaucoma.* 2009;18:563-566.
145. Narayanaswamy A, Leung CK, Istiantoro DV, et al. Efficacy of selective laser trabeculoplasty in primary angle-closure glaucoma: A randomized clinical trial. *JAMA Ophthalmol.* 2015;133:206-212.
146. Steuhl KP, Marahrens P, Frohn C, Frohn A. Intraocular pressure and anterior chamber depth before and after extracapsular cataract extraction with posterior chamber lens implantation. *Ophthalmic Surg.* 1992;23:233-237.
147. Yang CH, Hung PT. Intraocular lens position and anterior chamber angle changes after cataract extraction in eyes with primary angle-closure glaucoma. *J Cataract Refract Surg.* 1997;23:1109-1113.
148. Hayashi K, Hayashi H, Nakao F, Hayashi F. Changes in anterior chamber angle width and depth after intraocular lens implantation in eyes with glaucoma. *Ophthalmology.* 2000;107:698-703.
149. Tham CC, Lai JS, Lam DS. Changes in ac angle width and depth after IOL implantation in eyes with glaucoma. *Ophthalmology.* 2001;108:428-429.
150. Greve EL. Primary angle closure glaucoma: Extracapsular cataract extraction or filtering procedure? *Int Ophthalmol.* 1988;12:157-162.
151. Keenan TD, Salmon JF, Yeates D, Goldacre M. Trends in rates of primary angle closure glaucoma and cataract surgery in England from 1968 to 2004. *J Glaucoma.* 2009;18:201-205.
152. Wishart PK, Atkinson PL. Extracapsular cataract extraction and posterior chamber lens implantation in patients with primary chronic angle-closure glaucoma: Effect on intraocular pressure control. *Eye.* 1989;3 (Pt 6):706-712.
153. Gunning FP, Greve EL. Uncontrolled primary angle closure glaucoma: Results of early intercapsular cataract extraction and posterior chamber lens implantation. *Int Ophthalmol.* 1991;15:237-247.
154. Acton J, Salmon JF, Scholtz R. Extracapsular cataract extraction with posterior chamber lens implantation in primary angle-closure glaucoma. *J Cataract Refract Surg.* 1997;23:930-934.
155. Gunning FP, Greve EL. Lens extraction for uncontrolled angle-closure glaucoma: Long-term follow-up. *J Cataract Refract Surg.* 1998;24:1347-1356.
156. Roberts TV, Francis IC, Lertusumitkul S, et al. Primary phacoemulsification for uncontrolled angle-closure glaucoma. *J Cataract Refract Surg.* 2000;26:1012-1016.
157. Hayashi K, Hayashi H, Nakao F, Hayashi F. Effect of cataract surgery on intraocular pressure control in glaucoma patients. *J Cataract Refract Surg.* 2001;27:1779-1786.
158. Jacobi PC, Dietlein TS, Luke C, et al. Primary phacoemulsification and intraocular lens implantation for acute angle-closure glaucoma. *Ophthalmology.* 2002;109:1597-1603.
159. Khokar K, Pangtey M. Phacoemulsification in filtered chronic angle closure glaucoma eyes. *Clin Experiment Ophthalmol.* 2002;30:256-260.
160. Ming Zhi Z, Lim AS, Yin Wong T. A pilot study of lens extraction in the management of acute primary angle-closure glaucoma. *Am J Ophthalmol.* 2003;135:534-536.
161. Kubota T, Toguri I, Onizuka N, Matsuura T. Phacoemulsification and intraocular lens implantation for angle closure glaucoma after the relief of pupillary block. *Ophthalmologica.* 2003;217:325-328.
162. Shams PN, Foster PJ. Clinical outcomes after lens extraction for visually significant cataract in eyes with primary angle closure. *J Glaucoma.* 2012;21:545-550.
163. Lam DS, Leung DY, Tham CC, et al. Randomized trial of early phacoemulsification versus peripheral iridotomy to prevent intraocular pressure rise after acute primary angle closure. *Ophthalmology.* 2008;115:1134-1140.

164. Lai JS, Tham CC, Chua JK, et al. To compare argon laser peripheral iridoplasty (ALPI) against systemic medications in treatment of acute primary angle-closure: Mid-term results. *Eye (Lond)*. 2006;20:309-314.
165. Lam DS, Tham CC, Lai JS, Leung DY. Current approaches to the management of acute primary angle closure. *Curr Opin Ophthalmol*. 2007;18:146-151.
166. Lam DS, Chua JK, Tham CC, Lai JS. Efficacy and safety of immediate anterior chamber paracentesis in the treatment of acute primary angle-closure glaucoma: A pilot study. *Ophthalmology*. 2002;109:64-70.
167. Ritch R, Lowe RF. Angle-closure glaucoma: Therapeutic overview. In: Ritch R, Shields MB, Krupin T, eds. *The glaucomas*. St. Louis: CV Mosby Co, 1996.
168. Aung T, Oen F, Wong H-T, et al. Randomised controlled trial comparing the effect of brimonidine and timolol on visual field loss after acute primary angle closure. *Br J Ophthalmol*. 2004;88:88-94.
169. Choong YF, Irfan S, Menage MJ. Acute angle closure glaucoma: An evaluation of a protocol for acute treatment. *Eye (Lond)*. 1999;13 (Pt 5):613-616.
170. Koyabashi H, Koyabashi K, Kiryu J, Kondo T. Pilocarpine induces an increase in the anterior chamber angular width in eyes with narrow angles. *Br J Ophthalmol*. 1999;83:553-558.
171. Anderson DR. Corneal indentation to relieve acute angle-closure glaucoma. *Am J Ophthalmol*. 1979;88:1091-1093.
172. American Academy of Ophthalmology Committee on Ophthalmic Procedures Assessment. Laser peripheral iridotomy for pupillary-block glaucoma. American Academy of Ophthalmology. *Ophthalmology*. 1994;101:1749-1758.
173. Robin AL, Pollack IP. Argon laser peripheral iridotomies in the treatment of primary angle closure glaucoma. Long-term follow-up. *Arch Ophthalmol*. 1982;100:919-923.
174. Ang GS, Wells AP. Changes in caucasian eyes after laser peripheral iridotomy: An anterior segment optical coherence tomography study. *Clin Experiment Ophthalmol*. 2010;38:778-785.
175. Athanasiadis Y, de Wit D, Patel A, Sharma A. Reply to Yip et al: The potential complications from intraocular surgery, though, are greater than those from LPI. *Eye (Lond)*. 2011;25:254-255; author reply 255-256.
176. How AC, Baskaran M, Kumar RS, et al. Changes in anterior segment morphology after laser peripheral iridotomy: An anterior segment optical coherence tomography study. *Ophthalmology*. 2012;119:1383-1387.
177. Boey PY, Singhal S, Perera SA, Aung T. Conventional and emerging treatments in the management of acute primary angle closure. *Clin Ophthalmol*. 2012;6:417-424.
178. Ritch R. Argon laser peripheral iridoplasty: An overview. *J Glaucoma*. 1992;1:206-213.
179. Shin DH. Argon laser iris photocoagulation to relieve acute angle-closure glaucoma. *Am J Ophthalmol*. 1982;93:348-350.
180. Ritch R. Argon laser treatment for medically unresponsive attacks of angle-closure glaucoma. *Am J Ophthalmol*. 1982;94:197-204.
181. Lai JS, Tham CC, Lam DS. Limited argon laser peripheral iridoplasty as immediate treatment for an acute attack of primary angle closure glaucoma: A preliminary study. *Eye*. 1999;13 (Pt 1):26-30.
182. Lam DS, Lai JS, Tham CC. Immediate argon laser peripheral iridoplasty as treatment for acute attack of primary angle-closure glaucoma: A preliminary study. *Ophthalmology*. 1998;105:2231-2236.
183. Tham CC, Lai JS, Lam DS. Immediate argon laser peripheral iridoplasty for acute attack of PACG (addendum to previous report). *Ophthalmology*. 1999;106:1042-1043.
184. Lam DS, Lai JS, Tham CC, et al. Argon laser peripheral iridoplasty versus conventional systemic medical therapy in treatment of acute primary angle-closure glaucoma : A prospective, randomized, controlled trial. *Ophthalmology*. 2002;109:1591-1596.
185. Lai JS, Tham CC, Lam DS. The efficacy and safety of combined phacoemulsification, intraocular lens implantation, and limited goniosynechialysis, followed by diode laser peripheral iridoplasty, in the treatment of cataract and chronic angle-closure glaucoma. *J Glaucoma*. 2001;10:309-315.
186. Yang X, Su W, Wang M, et al. Effect of anterior chamber paracentesis on initial treatment of acute angle closure. *Can J Ophthalmol*. 2013;48:553-558.
187. Aung T, Tow SL, Yap EY, et al. Trabeculectomy for acute primary angle closure. *Ophthalmology*. 2000;107:1298-1302.
188. Chen YH, Lu DW, Cheng JH, et al. Trabeculectomy in patients with primary angle-closure glaucoma. *J Glaucoma*. 2009;18:679-683.
189. Manna A, Foster P, Papadopoulos M, Nolan W. Cyclodiode laser in the treatment of acute angle closure. *Eye (Lond)*. 2012;26:742-745.
190. Toth M, Shah A, Hu K, et al. Endoscopic cyclophotocoagulation (ECP) for open angle glaucoma and primary angle closure. *Cochrane Database Syst Rev*. 2019;2:CD012741.

191. Edwards RS. Behaviour of the fellow eye in acute angle-closure glaucoma. *Br J Ophthalmol*. 1982;66:576-579.
192. Ang LP, Aung T, Chew PT. Acute primary angle closure in an asian population: Long-term outcome of the fellow eye after prophylactic laser peripheral iridotomy. *Ophthalmology*. 2000;107:2092-2096.
193. Snow JT. Value of prophylactic peripheral iridectomy on the second eye in angle-closure glaucoma. *Trans Ophthalmol Soc U K*. 1977;97:189-191.
194. Fea AM, Dallorto L, Lavia C, et al. Long-term outcomes after acute primary angle closure of Caucasian chronic angle closure glaucoma patients. *Clin Exp Ophthalmol*. 2018;46:232-239.
195. Harasymowycz PJ, Papamatheakis DG, Ahmed I, et al. Phacoemulsification and goniosynechialysis in the management of unresponsive primary angle closure. *J Glaucoma*. 2005;14:186-189.
196. Matsumura M, Ido W, Shirakam Y, Zoizumi K. Treatment of primary closed angle glaucoma with cataract by lysis of peripheral anterior synechiae and intraocular lens implantation. *Jpn J Clin Ophthalmol*. 1991;45:1567-1569.
197. Teekhasaene C, Ritch R. Combined phacoemulsification and goniosynechialysis for uncontrolled chronic angle-closure glaucoma after acute angle-closure glaucoma. *Ophthalmology*. 1999;106:669-674; discussion 674-665.
198. Tham CC, Kwong YY, Leung DY, et al. Phacoemulsification versus combined phacotrabeculectomy in medically uncontrolled chronic angle closure glaucoma with cataracts. *Ophthalmology*. 2009;116:725-731.
199. Chen PP, Lin SC, Junk AK, et al. The effect of phacoemulsification on intraocular pressure in glaucoma patients: A report by the American Academy of Ophthalmology. *Ophthalmology*. 2015;122:1294-1307.
200. Javanbakht M, Azuara-Blanco A, Burr JM, et al. Early lens extraction with intraocular lens implantation for the treatment of primary angle closure glaucoma: An economic evaluation based on data from the EAGLE trial. *BMJ Open*. 2017;7:e013254.
201. Ritch R, Tham CC, Lam DS. Long-term success of argon laser peripheral iridoplasty in the management of plateau iris syndrome. *Ophthalmology*. 2004;111:104-108.
202. Ng WS, Ang GS, Azuara-Blanco A. Laser peripheral iridoplasty for angle-closure. *Cochrane Database of Syst Rev* 2012, issue 2. Art. No.: Cd006746. Doi: 10.1002/14651858.Cd006746.Pub3.
203. Francis BA, Pouw A, Jenkins D, et al. Endoscopic cycloplasty (ECPL) and lens extraction in the treatment of severe plateau iris syndrome. *J Glaucoma*. 2016;25:e128-133.
204. Hollander DA, Pennesi ME, Alvarado JA. Management of plateau iris syndrome with cataract extraction and endoscopic cyclophotocoagulation. *Exp Eye Res*. 2017;158:190-194.
205. Moore DB, Walton C, Moeller KL, et al. Prevalence of self-reported early glaucoma eye drop bottle exhaustion and associated risk factors: A patient survey. *BMC Ophthalmol*. 2014;14:79.
206. Department of Health & Human Services Centers for Medicare & Medicaid services. Early refill edits on topical ophthalmic products [memorandum]. June 2, 2010.
207. Ramulu P. Glaucoma and disability: Which tasks are affected, and at what stage of disease? *Curr Opin Ophthalmol*. 2009;20:92-98.
208. Haymes SA, Leblanc RP, Nicoleta MT, et al. Risk of falls and motor vehicle collisions in glaucoma. *Invest Ophthalmol Vis Sci*. 2007;48:1149-1155.
209. McKean-Cowdin R, Varma R, Wu J, et al. Severity of visual field loss and health-related quality of life. *Am J Ophthalmol*. 2007;143:1013-1023.
210. Rein DB, Zhang P, Wirth KE, et al. The economic burden of major adult visual disorders in the United States. *Arch Ophthalmol*. 2006;124:1754-1760.
211. Kymes SM, Plotzke MR, Li JZ, et al. The increased cost of medical services for people diagnosed with primary open-angle glaucoma: A decision analytic approach. *Am J Ophthalmol*. 2010;150:74-81.
212. Lee PP, Walt JG, Doyle JJ, et al. A multicenter, retrospective pilot study of resource use and costs associated with severity of disease in glaucoma. *Arch Ophthalmol*. 2006;124:12-19.
213. Lindblom B, Nordmann JP, Sellem E, et al. A multicentre, retrospective study of resource utilization and costs associated with glaucoma management in France and Sweden. *Acta Ophthalmol Scand*. 2006;84:74-83.
214. Poulsen PB, Buchholz P, Walt JG, et al. Cost-analysis of glaucoma-related blindness in Europe. *International Congress Series*. 2005;1292:262-266.
215. Thygesen J, Aagren M, Arnavielle S, et al. Late-stage, primary open-angle glaucoma in Europe: Social and health care maintenance costs and quality of life of patients from 4 countries. *Curr Med Res Opin*. 2008;24:1763-1770.
216. Quigley HA, Cassard SD, Gower EW, et al. The cost of glaucoma care provided to medicare beneficiaries from 2002 to 2009. *Ophthalmology*. 2013;120:2249-2257.

217. Sloan FA, Brown DS, Carlisle ES, et al. Monitoring visual status: Why patients do or do not comply with practice guidelines. *Health Serv Res.* 2004;39:1429-1448.
218. Wang F, Javitt JC, Tielsch JM. Racial variations in treatment for glaucoma and cataract among medicare recipients. *Ophthalmic Epidemiol.* 1997;4:89-100.
219. Coleman AL, Yu F, Rowe S. Visual field testing in glaucoma medicare beneficiaries before surgery. *Ophthalmology.* 2005;112:401-406.
220. Devgan U, Yu F, Kim E, Coleman AL. Surgical undertreatment of glaucoma in Black beneficiaries of medicare. *Arch Ophthalmol.* 2000;118:253-256.
221. Stein JD, Talwar N, Laverne AM, et al. Racial disparities in the use of ancillary testing to evaluate individuals with open-angle glaucoma. *Arch Ophthalmol.* 2012;130:1579-1588.