



AMERICAN ACADEMY
OF OPHTHALMOLOGY®

EyeNet Selections

Retina 2018

Recent Articles From
EyeNet® Magazine




Protecting Sight. Empowering Lives.®

EYLEA[®]
(aflibercept) Injection



The Support You Need, When You Need It

EYLEA4U[®] helps eligible patients access EYLEA whether they are uninsured, lack coverage, or need help with their out-of-pocket costs.



How do we help ensure your patients are paying the lowest out-of-pocket cost for EYLEA? Simple: EYLEA4U. EYLEA4U helps patients access EYLEA with the enhanced EYLEA Co-Pay Card, referrals to co-pay assistance foundations, and our Patient Assistance Program.

IN-PERSON, ONLINE, OR BY PHONE.
Call 1-855-EYLEA4U (1-855-395-3248), Option 4, or visit www.EYLEA4U.com/OM

EYLEA and EYLEA4U are registered trademarks of Regeneron Pharmaceuticals, Inc.


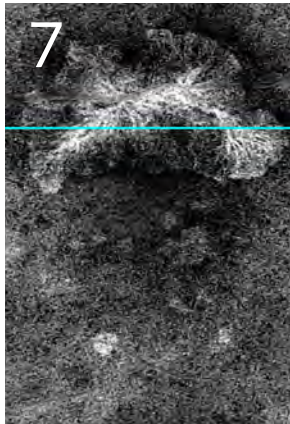
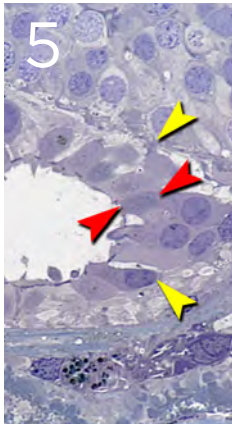

REGENERON

© 2017, Regeneron Pharmaceuticals, Inc. All rights reserved.
777 Old Saw Mill River Road, Tarrytown, NY 10591

09/2017
US-LEA-13910

EyeNet Selections CONTENTS

REPRINTS FOR
RETINA AT AAO 2018
CHICAGO



FEATURE

14-20 Inherited Retinal Diseases

A new drug for Leber congenital amaurosis holds hope for improved vision for some IRD patients. Peek inside an IRD clinic to see whether, when, and how to do genetic testing.

Originally published in May 2018.

CLINICAL INSIGHTS

5-6 Outer Retinal Tubulation

Outer retinal tubulation: a hallmark of neurodegeneration.

Originally published in January 2018.

7-9 Dry AMD

How OCT-A may change the management of dry AMD.

Originally published in April 2018.

11-13 Ophthalmic Pearls

Review the risk factors, diagnosis, and management of central retinal vein occlusion.

Originally published in January 2018.

COVER ILLUSTRATION

Alfred T. Kamajian



AMERICAN ACADEMY
OF OPHTHALMOLOGY®
Protecting Sight. Empowering Lives.

COPYRIGHT © 2018, American Academy of Ophthalmology, Inc.* All rights reserved. No part of this publication may be reproduced without written permission from the publisher. **Disclaimer.** The ideas and opinions expressed in *EyeNet* are those of the authors, and do not necessarily reflect any position of the editors, the publisher, or the American Academy of Ophthalmology. Because this publication provides information on the latest developments in ophthalmology, articles may include information on drug or device applications that are not considered community standard, or that reflect indications not included in approved FDA labeling. Such ideas are provided as information and education only so that practitioners

may be aware of alternative methods of the practice of medicine. Information in this publication should not be considered endorsement, promotion, or in any other way encouragement for the use of any particular procedure, technique, device, or product. *EyeNet*, its editors, the publisher, or the Academy in no event will be liable for any injury and/or damages arising out of any decision made or action taken or not taken in reliance on information contained herein. American Academy of Ophthalmic Executives®, EyeSmart®, EyeWiki®, IRIS® Registry, MIPS QCDR measures, and ONE® Network are trademarks of the American Academy of Ophthalmology®. All other trademarks are the property of their respective owners.

DISCLOSURE KEY. Financial interests are indicated by the following abbreviations: C = Consultant/Advisor; E = Employee; L = Speakers bureau; O = Equity owner; P = Patents/Royalty; S = Grant support. For definitions of each category, see aao.org/eyenet/disclosures.



EyeNet Corporate Lunches

EyeNet® Magazine helps you make the most of your time at AAO 2018 by bringing you free corporate educational program lunches* onsite at McCormick Place.

Room E353c, Lakeside

McCormick Place

Check-in and Lunch Pickup

12:15-12:30 p.m. Lunches are provided on a first-come basis.

Program

12:30-1:30 p.m.

Programs

Saturday, Oct. 27 Diabetic Eye Disease: Clinical Challenges and Practical Tips for Multidisciplinary Disease Management

Speakers: Robert Busch, MD (endocrinologist), John W. Kitchens, MD

Presented by Regeneron Pharmaceuticals, and designed for U.S. retina specialists.

Sunday, Oct. 28 INSiGHTS AT AAO: A Spotlight on Dry Eye Treatment

Speakers: Eric D. Donnenfeld, MD, Edward J. Holland, MD, Terry Kim, MD

Presented by Shire

Monday, Oct. 29 Cataract Surgery: Life is Beautiful When the Pupil Behaves

Speakers: Eric D. Donnenfeld, MD, Cynthia A. Matossian, MD, FACS, Steven M. Silverstein, MD, Denise M. Visco, MD, Keith A. Walter, MD

Presented by Omeros Corporation, and designed for U.S. cataract surgeons.

Check aao.org/eyenet/corporate-events for updated program information.

* These programs are non-CME and are developed independently by industry. They are not affiliated with the official program of AAO 2018 or Subspecialty Day. By attending a lunch, you may be subject to reporting under the Physician Payment Sunshine Act.

Outer Retinal Tubulation: Sign of Neurodegeneration

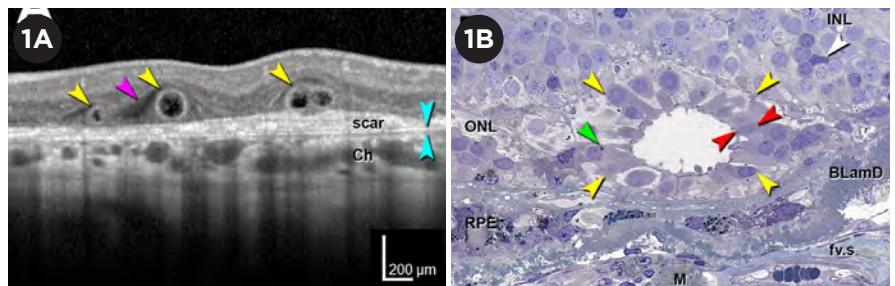
If you use high-resolution imaging to guide treatment of retinal diseases, the most important thing to know about outer retinal tubulation (ORT) structures is that they commonly appear in cross-sectional images as features that look somewhat like intraretinal cysts—but aren't.

The tubular structures in ORT-affected eyes appear on high-resolution, spectral-domain ocular coherence tomography (SD-OCT) B-scans as well-defined circular or ovoid areas of hyporeflectivity, surrounded by a hyperreflective band, said K. Bailey Freund, MD, who coauthored the first clinical description of ORT.¹

“If you did not know that these lesions existed, particularly if you were using the older time-domain OCT devices, you could easily confuse them with cysts or subretinal fluid,” said Dr. Freund, who practices in New York City. “And if you were using a treatment regimen that was guided by presence or absence of fluid, you could end up giving intravitreal injections to an eye that really didn't need them.”

Many Roads Lead to ORT

Despite this narrow clinical utility, ORT has garnered increasing attention over the last several years because of the realization that tubulations in the outer



ORT ON OCT. (1A) Representative SD-OCT B-scan of 3 ORT cross-sections (yellow arrowheads) in an 81-year-old woman with neovascular AMD. Two closed ORT structures are evident on the left, and a branching tubulation can be seen on the right. A hyporeflective wedge (pink arrowhead) and Bruch membrane (cyan arrowhead) are also evident. (1B) High-resolution histology section of degenerate cones in ORT, at 1.5 mm from the fovea, in a different 81-year-old woman with neovascular AMD. Cone lipofuscin (green arrowheads), mitochondria in outer fiber (red arrowheads), Müller cell body (white arrowhead), and ORT cross-sections (yellow arrowheads) are indicated. BLamD = basal laminar deposit; Ch = choroid; fv.s = fibrovascular scar; INL and ONL = inner and outer nuclear layer; M = lipid-containing macrophage; RPE = entombed and melanotic retinal pigment epithelium.

nuclear layer represent a common neurodegenerative pathway in a variety of retinal diseases. These include neovascular age-related macular degeneration (AMD); geographic atrophy (GA) secondary to AMD and other disorders; inherited retinal diseases, particularly choroideremia; and mitochondrial diseases.²

Prognostic value. In all of these conditions, the presence of ORT structures indicates disorganized outer retinal layers, irreversible photoreceptor damage, and a worse visual prognosis, Dr. Freund said. “Most people would consider ORT a sign that, at least in

that one particular area of the macula, you're not going to be able to recover visual function,” he said.

A better understanding of the ORT process eventually might yield clues about how to stop photoreceptors from dying, said Glenn J. Jaffe, MD, at Duke Eye Center in Durham, North Carolina. In treatment trials, a biomarker like ORT might prove valuable for excluding prospective participants unlikely to regain vision, he said.

“The hope would be that we could help preserve people's vision if we can prevent the degeneration of the photoreceptors,” Dr. Jaffe said. “Whether it's with a neurotrophic agent or some other type of treatment, we are becoming more aware that we need to be able to prevent the loss of the photo-

Originally published in January 2018.

BY LINDA ROACH, CONTRIBUTING WRITER, INTERVIEWING CHRISTINE A. CURCIO, PHD, K. BAILEY FREUND, MD, AND GLENN J. JAFFE, MD.

receptors in these diseases.”

Clues from CATT. Dr. Jaffe said he became interested in ORT because of what he observed during the Comparison Age-related Macular Degeneration Treatment Trials (CATT).³ “We were the OCT reading center for CATT, and while we were looking at the images I started to notice that ORT [structures] were becoming more frequent as the study went on. So we looked at the percentages and found that by 5 years, about 1 in 5 patients had this characteristic appearance,” Dr. Jaffe said.

Genesis of Tubulation

The tubules characteristic of ORT are the retina’s heroic yet last-ditch attempt to protect localized areas of macular cone photoreceptors from the failure of the underlying retinal pigment epithelium (RPE), said Christine A. Curcio, PhD, at the University of Alabama at Birmingham.

“What ORT lesions have in common with each other is that the RPE is dying or is gone. These are responses of retina cells to the extreme stress of this detachment,” Dr. Curcio said.

In 1996, her research group published the first histological descriptions of photoreceptors surviving in mysterious interconnected tubes in the maculas of eyes with neovascular AMD.⁴ It wasn’t until 2009 that Dr. Freund and his colleagues, using SD-OCT images, published the first clinically oriented paper about “a peculiar outer retinal morphologic change occurring in a variety of advanced degenerative retinal disorders.”¹

Since those publications, Drs. Curcio and Freund have worked together to correlate high-resolution histopathology in donor eyes with eye-tracked OCT images of living eyes, in order to understand the ORT process.^{2,5}

Gliosis implicated. Their overall conclusion: Tubulation is a protective gliotic response—ultimately futile—triggered by activated Müller cells, Dr. Curcio said. “The Müller cells are trying to take care of the remaining photoreceptor cells. They are protecting them from the failure of the RPE and all the problems in the RPE/Bruch membrane complex.”

Dr. Freund agreed. “It’s the Müller cells that are driving this process, and in the very late stage of tubulation you only have Müller cells and no surviving cones,” he said.

Rolling up the photoreceptors. As described recently by Dolz-Marco et al.,² ORT occurs when the external limiting membrane (ELM), which is normally a thin horizontal reflective line made by Müller cells and photoreceptors, begins “circling the wagons.” The ELM descends toward Bruch membrane and gradually begins scrolling the at-risk photoreceptors into a tubular structure. Depending on the stage of development, the outer band can appear in cross-section as flat, J-shaped, or partially (or fully) curved back on itself.

Both the inner and outer segments of the scrolled photoreceptors initially point radially into the lumen delineated by the ELM,² and these can be seen as a reflective fringe around the hyporeflexive lumen (dark on the OCT).

As ORT progresses, the lumen becomes uniformly hyporeflexive as the outer segments degenerate and the inner segments are pulled back across the ELM. Remnants of the numerous mitochondria in the inner segments migrate into the cell body of the degenerating cells, accounting for the reflectivity of the outer band of ORT.

In their study of 38 eyes with pre-existing ORT, Dolz-Marco et al. found that the mean time for new tubules to form was 14.9 months.² It is unknown how long the end-stage ORT lesions persist in the retina, but in clinical experience they commonly are stable through at least 3 years of follow-up.⁶

Serpentine patterns on OCT. En face OCT scans of ORT-affected maculas reveal the tubules snaking in various patterns across the retina. “A branching or pseudodendritic pattern is observed mainly in association with neovascularization, whereas a singular tube may line the border of GA. Interestingly, analysis of ORT over time has shown fluctuations in ORT volume in cross-sectional SD-OCT scans, even while the ORT footprint seen with en face imaging remains constant,” Dolz-Marco et al. wrote.²

What about GA? In a subgroup of affected patients in the Geographic Atrophy Treatment Evaluation (GATE) trial, ORT was present in 65% of eyes in the atrophic region and in 26% of eyes in the junctional zone.⁷ But there is disagreement over what this means, Dr. Jaffe said.

“It’s a little bit unclear” as to how well the presence of ORT predicts GA progression, he said. “In one of the publications that we’ve done, we found that it was associated with more rapid progression. But at least one other group [led by Srinivas Sadda, MD, at the University of Southern California] has reported not seeing that.”⁸

Attention to the different stages of ORT, which were not appreciated at the time of these prior studies, might help solve this discrepancy in future studies, Dr. Freund’s group suggested.²

1 Zweifel SA et al. *Arch Ophthalmol.* 2009;127(12):1596-1602.

2 Dolz-Marco R et al. *Ophthalmology.* 2017;124(9):1353-1367.

3 Lee JY et al. *Ophthalmology.* 2014;121(12):2423-2431.

4 Curcio CA et al. *Invest Ophthalmol Vis Sci.* 1996;37(7):1236-1249.

5 Litts KM et al. *Invest Ophthalmol Vis Sci.* 2016;57(6):2647-2656.

6 Jung JJ, Freund KB. *Arch Ophthalmol.* 2012;130(12):1618-1619.

7 Moussa K et al. *Retina.* 2013;33(8):1590-1599.

8 Hariri A et al. *Ophthalmology.* 2015;122(2):407-413.

Dr. Curcio is professor of ophthalmology and director of the AMD Histopathology Lab at the University of Alabama at Birmingham. *Relevant financial disclosures:* Heidelberg Engineering: S.

Dr. Freund practices at Vitreous Retina Macula Consultants of New York and is clinical professor of ophthalmology at the New York University School of Medicine in New York City. *Relevant financial disclosures:* Heidelberg Engineering: C; Optovue: C; Spark Therapeutics: C.

Dr. Jaffe is the Robert Machemer Professor of Ophthalmology and chief of the Vitreoretinal Division at Duke University and director of the Duke Reading Center at the Duke Eye Center in Durham, N.C. *Relevant financial disclosures:* Heidelberg Engineering: C.

See the disclosure key, page 3. For full disclosures, view this article at aao.org/eyenet.

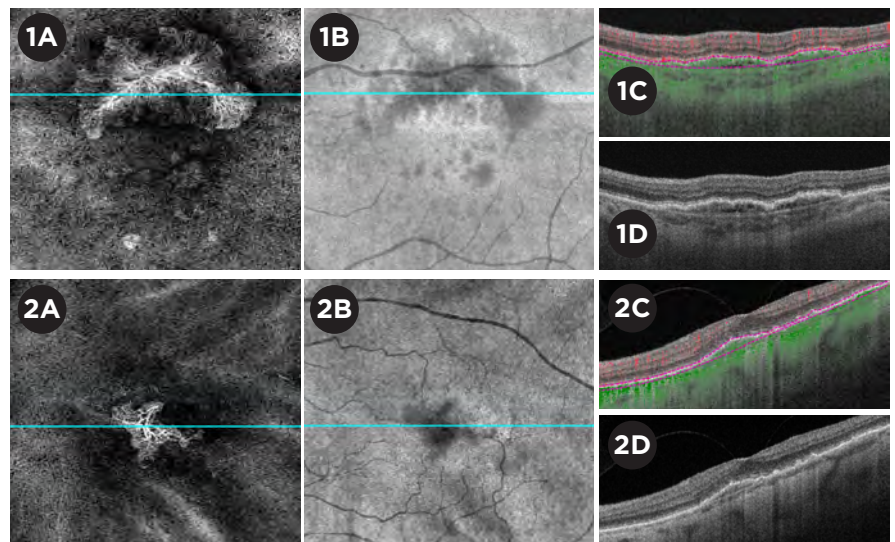
OCT-A: A Path to Earlier Diagnosis of Dry AMD

In 2015, optical coherence tomography angiography (OCT-A) became commercially available as a way to noninvasively image the microvasculature of the retina and choroid. Today, no one disputes that OCT-A produces stunning images. But can it provide new clinical—not just confirmatory—value for the management of dry age-related macular degeneration (AMD)?

That's a question that Philip J. Rosenfeld, MD, PhD, at the Bascom Palmer Eye Institute, frequently fields from his colleagues. Although OCT-A doesn't appear to improve the management of wet AMD, he said, this imaging modality does have the potential to change the way retina specialists manage dry AMD in clinical practice, and it can identify patients who are at high risk of converting to wet AMD.

Insights Garnered From OCT-A

“OCT-A, especially swept source, gives you the ability to see subclinical neovascular complexes and the choriocapillaris, the vascular layer under the retinal pigment epithelium (RPE), which couldn't previously be visualized in living humans,” said Dr. Rosenfeld. In fact, this technology has allowed retina specialists to identify a whole



TWO EXAMPLES. (A) Subclinical nonexudative type 1 neovascularization detected by SS-OCT-A. 6 x 6 mm en face SS-OCT-A flow image from a slab extending from the retinal pigment epithelium to Bruch's membrane (BM) following removal of the retinal vessel projection artifacts. (B) 6 x 6 mm en face structural image produced from the same slab as A. The area of hyporeflectivity corresponds to the type 1 neovascularization in panel A. (C) SS-OCT-A B-scan with flow corresponding to the horizontal line in A and B, with purple segmentation lines defining the RPE-BM slab. Retinal flow is depicted in red and choroidal flow is in green. (D) SS-OCT-A B-scan as in panel C without superimposed flow or segmentation lines.

new category of AMD—nonexudative neovascular AMD, he said.

Loss of the choriocapillaris. These patients “have a loss of the choriocapillaris underlying the atrophy as well in the area surrounding the atrophy,” said Nadia K. Waheed, MD, MPH, at Tufts University School of Medicine. “We're still in the preliminary stages of under-

standing exactly what that means.” Dr. Rosenfeld added that it's not known whether the loss of the choriocapillaris precedes loss of vision in AMD or vice versa. “A major focus moving forward is to understand how these changes affect the natural history of AMD.”

Subclinical choroidal neovascularization. The ability to visualize subclinical choroidal neovascularization (CNV) in dry AMD patients is important, said Dr. Waheed. She noted that in a recent study¹ by Dr. Rosenfeld's group, “Patients with subclinical CNV

Originally published in April 2018.

BY ANNIE STUART, CONTRIBUTING WRITER, INTERVIEWING ELEONORA M. LAD, MD, PHD, PHILIP J. ROSENFELD, MD, PHD, AND NADIA K. WAHEED, MD, MPH.

followed for a year were shown to have a 15-fold higher risk of exudation compared with AMD eyes without it.”

In this study, swept-source (SS) OCT-A allowed the researchers to monitor disease status in eyes with intermediate dry AMD or geographic atrophy (GA), with wet AMD in the fellow eye. Within a year, wet AMD developed in 24% of eyes with—and in 5.4% of eyes without—subclinical CNV detected by SS-OCT-A.¹

Being able to spot subclinical CNV long before exudation appears is the most valuable application of OCT-A, said Dr. Rosenfeld. “You need to know who among your dry AMD patients has a ticking time bomb in the back of their eyes.”

Eleonora M. Lad, MD, PhD, at the Duke University School of Medicine, also believes that the identification of this subset of patients at high-risk for exudation will lead to improved visual outcomes and a better prognosis through earlier treatment.

SD-OCT-A versus SS-OCT-A. Both spectral-domain (SD) and SS-OCT-A can be used to visualize changes in dry AMD, but SD-OCT-A is slower with a shorter wavelength, and SS-OCT-A is faster with a longer wavelength, said Dr. Waheed, which provides better penetration into the choriocapillaris.

Dr. Lad added that devices using SS-OCT-A are associated with better definition of choroidal vasculature changes, for example, the general decrease in choriocapillaris flow reported in dry AMD that typically extends beyond the borders of areas of atrophy.²

If a patient has geographic atrophy, structural SD-OCT-A can provide the volume of drusen and show the area of atrophy, she said. “You can get exactly the same information from the en face OCT as you can from fundus autofluorescence and color fundus photos, and you can additionally check the B-scans for fluid. Although it is not as good as SS-OCT-A in detecting asymptomatic CNV, it still does a reasonably good job.”

Although SS-OCT-A is a boutique imaging strategy mostly used for research at a cost approximately twice that of SD-OCT-A, said Dr. Waheed,

Translating AMD Research Into Clinical Benefits

“We still need to demonstrate the clinical usefulness of OCT angiography in improving AMD patient outcomes,” said Dr. Rosenfeld, adding that he expects that this technology will be a valuable research tool for helping better understand and diagnose the disease.

Understanding natural history. Two 2-year natural history studies are currently following AMD patients who have a wide range of disease severity, said Dr. Rosenfeld. IMPACT focuses on intermediate AMD, where the main feature is intermediate AMD, primarily with drusen, and SWAGGER focuses on the later form of nonexudative AMD, where the primary manifestation is geographic atrophy. “The researchers are using SS-OCT-A to intensively image patients using different scan patterns repeated multiple times,” he said. “We will also average the scans to achieve even better image quality and resolution.”

Identifying surrogate endpoints. Researchers also hope to identify clinical study surrogate endpoints that correlate well with endpoints of GA, a slowly developing disease, said Dr. Waheed. This would allow researchers to test whether drugs are effective at an earlier stage and make it possible to run shorter, smaller trials, added Dr. Rosenfeld.

The ongoing Duke natural history trial on early-intermediate AMD, led by Dr. Lad; the upcoming AMD Ryan Initiative Study; and the international MACUSTAR study are all investigating surrogate clinical study endpoints for use in earlier stages of dry AMD.

Improving the OCT-A technology. Under the auspices of the Advanced Retinal Imaging (ARI) Network, which was organized by Zeiss, a global consortium of clinical researchers is testing software and hardware upgrades and sharing cases and testing algorithms via a web portal, said Dr. Rosenfeld. The research program will eventually be expanded to 200 sites.

Developing a risk assessment tool. Studying a patient subset of the Age-Related Eye Disease Study (AREDS) 2, researchers at Duke, led by Cynthia Toth, MD, developed a novel risk-assessment model for progression to color photograph-visible GA over a period up to 5 years.¹ The model is based on age and SD-OCT-A segmentation, drusen characteristics, and retinal pathology. “With future validation, I think it will be very helpful as a clinical tool, as a research tool to simplify SD-OCT-A grading, and to inform industry and pharmaceutical companies on how to design future studies for GA,” said Dr. Lad.

¹ Sleiman K et al. *Ophthalmology*. 2017;124(12):1764-1777.

SS-OCT-A is starting to gain traction now in clinical practices. The cost will likely change as the technology gets cheaper and faster, she said.

Clinical Use of OCT-A for Dry AMD

“OCT-A gives you multimodal imaging using a single imaging modality,” said Dr. Rosenfeld. “With a single scan, you can get both structural and flow information, and the 2 types of images can be superimposed.” Dr. Waheed added that it’s one of the best ways of monitoring the size and direction of GA,

both in clinical practice and in clinical trials.

Observe. “OCT-A will change the way we screen patients with dry AMD because it gives us the ability to detect early changes and stratify patients into higher and lower risk groups,” said Dr. Waheed. “We can identify patients with subclinical neovascularization and put them into a program with closer observation,” said Dr. Rosenfeld. This involves both more frequent clinical observation and home monitoring. “We have always instructed patients on how to test their vision at home, but now

we encourage patients with subclinical neovascularization to increase their vigilance since we can't yet predict whether and when the abnormal neovascularization will leak."

Home monitoring can be done with a phone app called DigiSight or with Notal Vision's ForeseeHome, which is covered by Medicare, said Dr. Rosenfeld. Both technologies allow the doctor to see how often patients check their vision. Although the Amsler grid is unreliable, patients may also check their vision with it every day, he said.

Drs. Rosenfeld, Lad, and Waheed see most patients with dry AMD about every 6 months to a year. But if a patient has subclinical CNV, they scan them every 2-3 months to see how the lesions are progressing.

Treat with caution. Drs. Waheed and Lad do not begin treating these high-risk patients with anti-vascular endothelial growth factor (VEGF) therapy unless they develop subretinal fluid and active exudation, as well as a leak on fluorescein angiography (FA). "Robust data show that treatment helps only once exudation develops," said Dr. Waheed.

Dr. Rosenfeld agrees with this conservative approach—only treating symptomatic exudation. That's because good vision in the presence of CNV may indicate that neovascularization provides beneficial nutritional support to the RPE and photoreceptors, he said. "Although anti-VEGF therapy suppresses exudation and preserves vision," he said, "there's an ongoing controversy about whether anti-VEGF therapy promotes the formation of geographic atrophy. If it does, then it probably accelerates atrophy by accelerating the disappearance of the neovascularization." If you begin treatment as soon as subclinical CNV is detected, he said, it begs the question: How would you know when to stop? Only after atrophy arises?

In other words, the definition of treatable neovascular AMD has not yet been rewritten to incorporate OCT-A's findings of nonexudative neovascularization, added Dr. Lad.

Continue to monitor. Another important point for clinicians to remem-

ber? Growth of neovascularization does not correlate with exudation, said Dr. Rosenfeld. "These patients can do well without treatment, and then the disease will usually progress to atrophy. OCT-A can be used to follow the progression to GA. It gives you all the information you need to follow the life cycle of AMD."

OCT-A Scanning Tips

Invest some time. Learning OCT-A requires hands-on training, said Dr. Rosenfeld, as well as time to simply sit and play with the equipment. "There's definitely a learning curve, but once you get the hang of it, it will become second nature," he said.

"An OCT-A scan takes just a few seconds longer, but the real time comes in the interpretation of the scan," he said, adding that this investment of time is outweighed by benefits over dye-based angiography: noninvasiveness, safety, speed, and more valuable information.

Dr. Waheed noted that it really is worth learning OCT-A for your patients, as it can help you figure out the risk of progression, especially for those with atrophy.

Choose the scan size. OCT-A allows you to do different scan sizes, said Dr. Rosenfeld, and you choose the scan size based on the extent of the disease. With a SD instrument, you can do a 3 mm × 3 mm, 6 mm × 6 mm, or 8 mm × 8 mm scan, he said. With SS-OCT-A, there is a choice of scan sizes from 3 mm × 3 mm up to 12 mm × 12 mm or 15 mm × 9 mm. Automated montage capability can extend the field of view out to 60 degrees or larger. "With all these scans, I can see all the pathology in AMD," said Dr. Rosenfeld.

Scrutinize key areas. With OCT-A technology, you can look at various depths, said Dr. Lad, and you must first decide the level where you're most likely to see the pathology. The segmentation levels that are most important to review for AMD are the deep—or avascular—retina and the choriocapillaris, said Dr. Waheed. "If you see something there, you worry about neovascularization."

Look at a structural-flow overlay. "The other thing I always like to look at is the structural B-scan with a flow

overlay," said Dr. Waheed. This can help confirm the presence of subclinical neovascularization in patients with nonexudative disease.

Check density. "I also like to look at the overall density of the choriocapillaris, especially on the margins of the geographic atrophy because that tells me how much damage there is," said Dr. Waheed.

Beware of artifacts. Motion artifacts are much less of a problem today due to physical tracking and software-based artifact removal tools, said Dr. Waheed. "However, it can still happen if the patient has poor fixation and a lot of GA," she said. Although projection artifacts have become less common thanks to software designed to remove them, if you see something that looks like neovascularization, double-check that you're not looking at projection artifacts, she said.

Recognize patterns. There is a pathological phenomenon in patients with GA that can sometimes be confusing, said Dr. Waheed. "When patients lose their choriocapillaris, larger vessels migrate upward into the area of the choriocapillaris. These can be confused with CNV." A lot of this interpretation requires pattern recognition, agreed Dr. Lad. "You have to know what the abnormal and normal vessels look like on indocyanine green angiography to identify the suspicious vascular structure."

1 de Oliveira Dias JR et al. *Ophthalmology*. 2018; 125(2):255-266.

2 Choi W et al. *Ophthalmology*. 2015;122(12): 2532-2544.

Dr. Lad is associate professor of ophthalmology at Duke University School of Medicine, in Durham, N.C. *Relevant financial disclosures:* None.

Dr. Rosenfeld is professor of ophthalmology at the Bascom Palmer Eye Institute, University of Miami Miller School of Medicine, in Miami. *Relevant financial disclosures:* Carl Zeiss Meditec: C,S.

Dr. Waheed is associate professor of ophthalmology at Tufts University School of Medicine in Boston. *Relevant financial disclosures:* Carl Zeiss Meditec: S; Nidek: S; Optovue: C,L.


See the disclosure key, page 3. For full disclosures, view this article at aao.org/eyenet.

EYLEA[®]
(aflibercept) Injection



The Support You Need, When You Need It

EYLEA4U[®] helps eligible patients access EYLEA whether they are uninsured, lack coverage, or need help with their out-of-pocket costs.



How do we help ensure your patients are paying the lowest out-of-pocket cost for EYLEA? Simple: EYLEA4U. EYLEA4U helps patients access EYLEA with the enhanced EYLEA Co-Pay Card, referrals to co-pay assistance foundations, and our Patient Assistance Program.

IN-PERSON, ONLINE, OR BY PHONE.

Call 1-855-EYLEA4U (1-855-395-3248), Option 4, or visit www.EYLEA4U.com/OM

EYLEA and EYLEA4U are registered trademarks of Regeneron Pharmaceuticals, Inc.

REGENERON

© 2017, Regeneron Pharmaceuticals, Inc. All rights reserved.
777 Old Saw Mill River Road, Tarrytown, NY 10591

09/2017
US-LEA-13910

Diagnosis and Management of Central Retinal Vein Occlusion

Retinal vein occlusion (RVO) has a prevalence of 0.5%, making it the second most-common retinal vascular disorder after diabetic retinopathy.¹ RVO is classified according to the anatomic level of the occlusion, with 3 major distinct entities:

- Central retinal vein occlusion (CRVO): occlusion of the central retinal vein at the level of, or posterior to, the lamina cribrosa (Fig. 1)
- Hemiretinal vein occlusion (HRVO): occlusion at the disc, involving either the superior or inferior hemiretina
- Branch retinal vein occlusion (BRVO): occlusion of a tributary vein, typically at the site of an arteriovenous crossing; thought to be caused by compression from an overlying atherosclerotic arteriole

This article will focus on diagnosis and management of CRVO.

Risk Factors

Systemic disorders. Systemic risk factors for CRVO include increasing age, diabetes mellitus, and hypertension. In selected cases, hypercoagulable states, including hyperhomocysteinemia and factor V Leiden mutation, or local vessel factors such as vasculitis are also associated with increased risk of CRVO. And cases have been reported of other systemic conditions possibly associated with the

development of CRVO.

Ocular conditions. Open-angle glaucoma is a major ocular risk factor for CRVO.

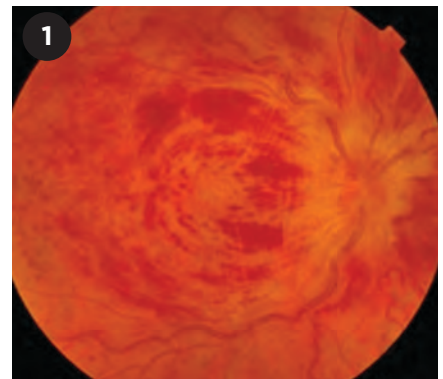
In addition, individuals with CRVO in 1 eye are at higher risk of developing CRVO in the fellow eye.² In the Central Vein Occlusion Study (CVOS), 4% of patients presented with bilateral CRVO at study enrollment, and a further 5% had evidence of previous CRVO in the fellow eye at baseline. In the remaining subjects, 1.4% developed CRVO in the fellow eye during 3 years of follow-up.

Other ocular risk factors include retrobulbar external compression of the central retinal vein, as occurs in thyroid orbitopathy, or compression by intra-orbital space-occupying lesions.

Clinical Presentation

Patients with CRVO typically present with a history of unilateral acute, painless visual loss. Visual impairment may be severe, ranging from better than 20/40 to worse than 20/200. A relative afferent pupillary defect may be present in the affected eye.

Fundus findings. Dilated fundus examination reveals unilateral disc swelling with peripapillary intraretinal hemorrhages, dilated tortuous veins, and intraretinal dot, blot, and flame hemorrhages in all quadrants, resulting in the classic “blood and thunder” fundus appearance (Fig. 1). The macula may be edematous.



ACUTE CRVO. Classic “blood and thunder” fundus appearance of a patient presenting acutely with central retinal vein occlusion of the right eye.

In less severe cases, disc swelling may be absent. In subacute or late presentations in which disc swelling has resolved (with or without collateral vessel formation), the flame-shaped hemorrhages clear first, leaving deeper dot/blot hemorrhages that may be difficult to distinguish from a severe microangiopathic retinopathy such as diabetic retinopathy (Fig. 2). Fluorescein angiography (FA) may help to confirm the diagnosis of CRVO.

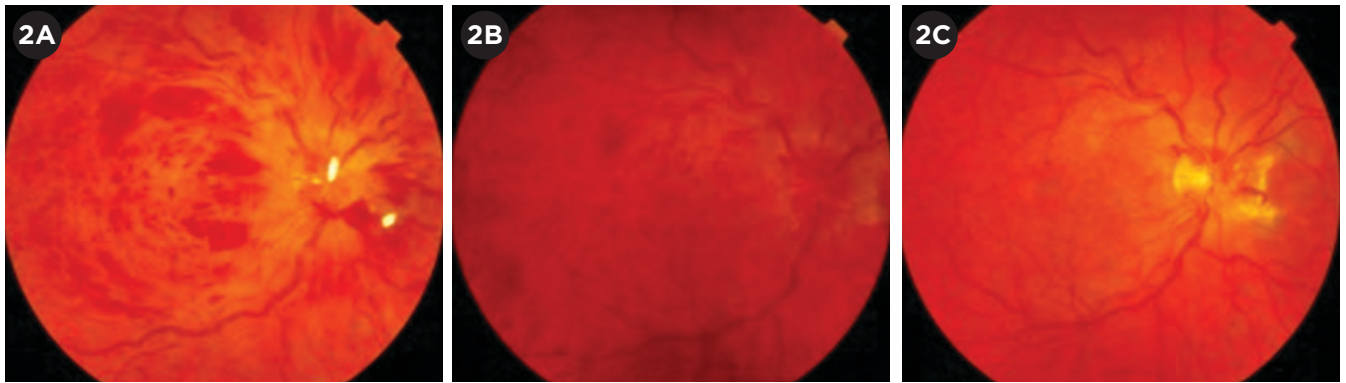
Other key aspects. As part of the examination, the clinician should note the intraocular pressure and cup-to-disc ratio, which may suggest concurrent glaucoma, as well as any sequelae, such as rubeosis iridis. Undilated gonioscopic examination is important to rule out neovascularization of the angles.

Types of CRVO

CRVO may be divided into 2 major subtypes: ischemic and nonischemic.

Originally published in January 2018.

BY **SIEHYEAN KIEW, MD**, AND **DANIEL S.W. TING, MD, PHD**. EDITED BY **SHARON FEKRAT, MD**, AND **INGRID U. SCOTT, MD, MPH**.



Ischemic. The CVOS investigators defined ischemic CRVO as evidence of more than 10 disc areas of capillary nonperfusion on 7-field fundus FA (although investigators are reassessing this definition in light of recent advances in widefield angiography).

Ischemic CRVO may be identified by the following characteristics:

- Poor visual acuity (>90% had VA of <20/200)
- Presence of a relative afferent pupillary defect in the affected eye
- Presence of extensive dark, deep intraretinal hemorrhages
- Presence of multiple cotton-wool spots
- Greater than 10 disc areas of retinal capillary nonperfusion on 7-field FA
- Reduced b-wave amplitude, reduced b:a ratio, and prolonged b-wave implicit time on electroretinography

In ischemic CRVO, visual acuity remains poor, often decreasing further over time. Causes of visual loss include chronic macular edema, macular ischemia, peripheral/global ischemia with secondary vitreous hemorrhage, and neovascular glaucoma.

Approximately 23% of eyes with ischemic CRVO develop iris neovascularization over 15 months; in the CVOS, 44% of eyes that presented with vision worse than 20/200 subsequently developed iris neovascularization.² Some patients may develop retinal neovascularization.

Nonischemic. In the CVOS, 34% of eyes that initially presented with nonischemic CRVO underwent conversion to an ischemic perfusion status over 3 years²; conversion is heralded by rapid visual deterioration in the affected eye. Sudden decrease in visual acuity

CHANGES OVER TIME. Same eye as shown in Fig. 1 at (2A) 1 month, (2B) 4 months, and (2C) 1 year following initial presentation, demonstrating evolution of the clinical picture. Disc edema resolves first, then the flame hemorrhages, and finally the dot and blot hemorrhages, with development of collateral vessels at the optic disc.

in a patient with existing nonischemic CRVO should, therefore, prompt further assessment for development of ischemic CRVO.

Of the eyes that remained nonischemic, approximately 30% showed resolution of macular edema within 15 months. Occurrence of subsequent neovascular complications is rare in nonischemic eyes.

Workup

A thorough initial workup can provide useful information to guide clinical decision making.

Optical coherence tomography.

OCT is useful to confirm and quantify the severity of macular edema, assess the integrity of the ellipsoid zone/photoreceptor layers, and monitor response to treatment. In clinical practice, OCT measurements often guide treatment decisions.

Fluorescein angiography.

Features of CRVO on FA include delayed arm-to-retina time, prolonged arteriovenous transit time (markedly so in ischemic CRVO), late staining along vessel walls, capillary dropout with pruning of the vessels in areas of ischemia, and late leakage in a petaloid pattern in the presence of macular edema (Fig. 3).

Clinically, FA allows evaluation of the extent of capillary nonperfusion and the degree of macular ischemia and enables differentiation between collateral vessels and new vessels.

Systemic. Systemic evaluation is

often performed in patients with CRVO and is directed by the patient's age, coexisting risk factors, and medical history. Assessment should be performed in conjunction with an internist, as patients with RVO may be at higher risk of cardiovascular disease and cerebrovascular accidents.

There are no clear guidelines on systemic testing, but it generally begins with a dilated funduscopic examination in clinic, along with a detailed medical history to identify risk factors; further assessment includes blood pressure and serum glucose, complete blood count, and erythrocyte sedimentation rate. In young patients without clear risk factors, additional testing should be considered to exclude a hematologic or vasculitic etiology.

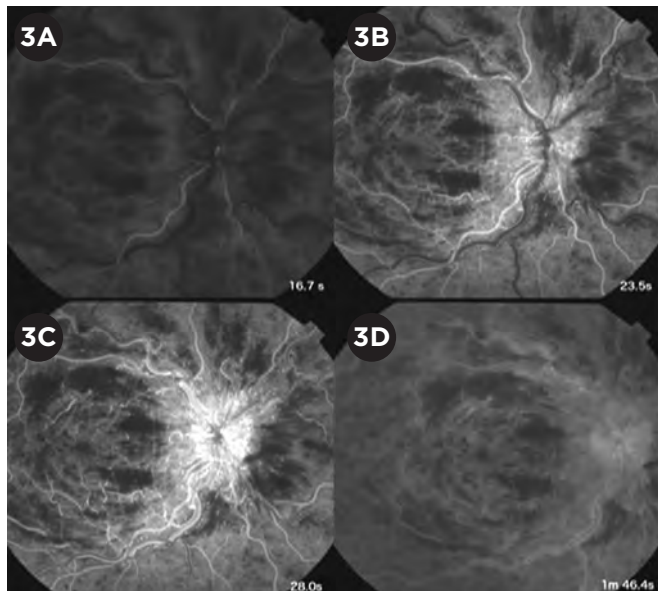
Treatment

All patients should optimize control of systemic risk factors, with the help of their internist. Management of the ocular manifestations may be divided into the following areas.

Macular edema. Both laser and medical therapies have been used in the treatment of macular edema.

Laser. Studies assessing grid-pattern laser photocoagulation for treatment of macular edema in CRVO showed anatomic improvement without improvement in visual acuity.²

Anti-vascular endothelial growth factor. Intravitreal anti-VEGF therapy is currently the gold standard of treatment for macular edema associated



FLUORESCEIN FINDINGS. FA at 4 time points shows (3A) masking from intraretinal hemorrhages, (3B) delayed arteriovenous transit time, (3C) leakage at the swollen optic disc, and (3D) late staining of the vessel walls.

with CRVO. There is increasing evidence that anti-VEGF therapy results in lower risk of visual loss, higher rates of visual gains, greater reduction in central retinal thickness, and reduced risk of progression to iris neovascularization.

For example, the CRUISE study reported that intravitreal ranibizumab significantly improved best-corrected visual acuity (BCVA) at 6 and 12 months compared with sham injections. In the open-label extension HORIZON trial, the eyes initially treated with sham and subsequently treated with ranibizumab showed improvement in BCVA but did not catch up to the visual outcomes attained by the group that received ranibizumab at enrollment. This finding suggests that delaying treatment for macular edema has adverse effects on visual outcomes.

Aflibercept, a VEGF-trap molecule, has also been shown to improve BCVA compared with sham and laser treatment in the COPERNICUS and GALILEO trials.

More recently, SCORE2, a randomized noninferiority trial including eyes with CRVO or HRVO, demonstrated that bevacizumab was noninferior to aflibercept in terms of visual acuity gain at month 6 compared to baseline

(mean improvement of 18.6 vs. 18.9 ETDRS letters, respectively).³

Corticosteroids. Corticosteroids reduce retinal capillary permeability and inhibit the expression and metabolic pathway of VEGF. The SCORE-CRVO trial demonstrated that intravitreal triamcinolone acetonide was superior to observation for visual loss associated with CRVO-related macular edema.

The GENEVA trial evaluated the use of a sustained-release intravitreal dexamethasone implant (Ozurdex) and demonstrated improvements in visual acuity and macular thickness compared with both sham and laser-treated groups.

More recently, the Clinical Efficacy and Safety of Ranibizumab Versus Dexamethasone for Central Retinal Vein Occlusion (COMRADE C) trial compared intravitreal ranibizumab 0.5 mg (monthly for at least 3 months, followed by as-needed dosing) to a single injection of Ozurdex. This trial reported similar efficacy between ranibizumab and Ozurdex but found a higher incidence of adverse effects in the group receiving Ozurdex.

Retinal ischemia. Current evidence recommends regular monitoring of patients with ischemic CRVO for development of iris or angle neovascularization, for which panretinal laser photocoagulation (PRP) remains the mainstay of treatment.

There is currently no evidence to recommend prophylactic treatment prior to the development of new vessels. However, in circumstances where regular follow-up is impractical and the degree of ischemia is severe (high risk of progression to neovascularization), prophylactic PRP may be appropriate.

Anti-VEGF agents are antiangiogenic and may be useful adjuncts to PRP in the management of patients with CRVO and associated anterior segment neovascularization, particularly when the view of the fundus is not sufficiently clear to permit adequate PRP.

Venous outflow. A number of alternative therapies focused on improving retinal blood flow have been described. These include the use of antiplatelet agents (e.g., ticlopidine),⁴ hemodilution,⁵ and thrombolytic agents delivered systemically, intravitreally, or directly into a retinal vein during pars plana vitrectomy.

Techniques to alleviate a possible compartment syndrome, with optic nerve sheath decompression through an orbital approach or radial optic neurotomy via a pars plana approach, have been tried. However, these are no longer used because of their limited benefit and significant risks.

Creation of a laser chorioretinal venous anastomosis (L-CRA) to bypass the occluded central retinal vein has been reported to be beneficial in nonischemic CRVO, with improvement in visual acuity and reduced rates of ischemic progression,⁶ but less so in eyes with the ischemic type of disease. The failure of anastomosis was most likely due to endothelial cell damage secondary to ischemia.⁷

1 Klein R et al. *Arch Ophthalmol.* 2008;126(4):513-518.

2 Central Vein Occlusion Study Group. *Arch Ophthalmol.* 1997;115(4):486-491. [Erratum in *Arch Ophthalmol.* 1997;115(10):1275.]

3 Scott IU et al. *JAMA.* 2017;317(20):2072-2087.


4 Yamamoto T et al. *Am J Ophthalmol.* 2004;138(5):809-817.

5 Wolf S et al. *Graefes Arch Clin Exp Ophthalmol.* 1994;32(1):33-39.

6 McAllister IL et al. *Ophthalmology.* 2010;117(5):954-965.

7 Kwok AK et al. *Br J Ophthalmol.* 2003;87(8):1043-1044.

Dr. Kiew is an ophthalmology resident at the Singapore National Eye Centre. Dr. Ting is an associate consultant at the Singapore National Eye Centre and assistant professor at Duke-National University Singapore. *Relevant financial disclosures: None.*



Inherited Retinal Disease

REDEFINING PATIENT CARE

The first gene therapy approved for a small subset of IRD patients puts the profession on the cusp of a new era in genetics. Peek inside an IRD clinic to learn whether, when, and how to do genetic testing.

By Annie Stuart, Contributing Writer

AT THE END OF 2017, THE U.S. FOOD and Drug Administration (FDA) approved Luxturna (voretigene neparvovec-rzyl), the first gene therapy for an inherited retinal disease (IRD). “Patients with Leber congenital amaurosis due to mutations in the *RPE65* gene now have hope that their progressive blindness can be arrested,” said Alan E. Kimura, MD, MPH, at Colorado Retina Associates in Denver.

This step is remarkable, he said, not only for establishing the scientific principles of successful gene therapy, but also for attracting greater financial capital to develop subsequent marketable gene therapies for IRDs. But that’s not all. It reveals what can be accomplished when previously fragmented silos of human activity integrate to achieve an aspirational goal, said Dr. Kimura. “And it likely heralds the dawn of a new role for ophthalmologists, working collaboratively to deliver care to people with inherited retinal diseases in our communities.”

Common patient experience. To date, however, the experience of a patient with a rare disease such as an IRD has often been punishing, said Dr. Kimura. “They may end up seeing multiple doctors, receiving several misdiagnoses, and spending a lot of their own money for testing.” But worse, he said, is getting to an ophthalmologist who lacks knowledge about IRDs and doesn’t know where to

refer the patient for a proper diagnostic evaluation. “Too many patients report, ‘The doctor said I am going to go blind and walked out the exam room door.’”

Benign neglect? Misdiagnosis or mismanagement of these patients isn’t intentional; instead, it’s largely due to a lack of awareness in the ophthalmic community, said Christine N. Kay, MD, at Vitreoretinal Associates in Gainesville, Florida. “The field has grown so much in the last 10 years that doctors might not have the most up-to-date information to share with their patients.”

Find the specialists. For MDs who don’t know what to do for these patients, it’s important to reach out to specialists who can pick the right tests, interpret the results, and answer patient questions, said Josie Kagey, a certified genetic counselor who worked with Dr. Kimura’s practice until recently. “Patients need to be guided to physicians and genetic counselors experienced in treating IRDs.”

First Step: Specialized IRD Testing

“I was born with nanophthalmos,” said 20-year-old Seth Bynum, who was referred to Dr. Kimura’s practice, Colorado Retina Associates, in the spring of 2017. “I’ve lived my whole life going to eye clinics, and I grew up accepting that,” he said. “The best I’ve ever seen was close to 20/20 with

Originally published in May 2018.

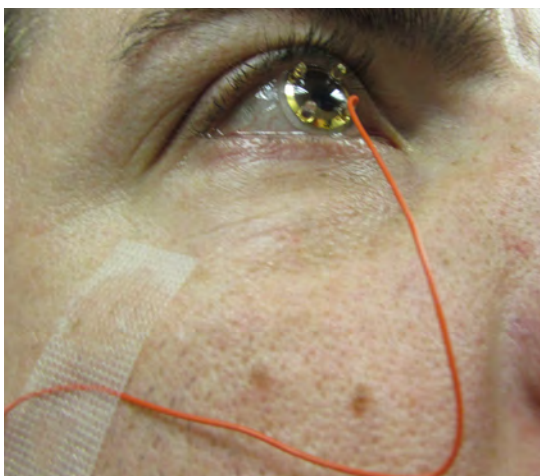really strong corrective lenses. But recently, I was diagnosed with retinitis pigmentosa (RP) and am now at about 20/80.”

First contact. Patients like Mr. Bynum first make contact with Colorado Retina Associates’ ocular genetics coordinator, Andy Humes, who runs the eye lab, conducts specialized IRD testing, and helps facilitate genetic testing by sending out test kits and receiving results.

Because of the variety and rarity of IRDs, there’s nothing “typical” about these patients. Diagnosis can be elusive. Some have subtle conditions previously masquerading as cobblestone degeneration or early macular degeneration, for example, so a diagnosis of IRD can come as quite a surprise, said Mr. Humes. “Before patients come in, I may spend 30 minutes to 3 hours talking with them on the phone, explaining some of the implications of testing.” For example, test results will not legally affect employment.

Specialized IRD testing. Dr. Kimura emphasizes the importance of first confirming a phenotype to home in on the type of genetic testing needed. “Although it is expensive and used infrequently in most practices, specialized diagnostic equipment, including electroretinograms (ERGs) and full-field perimetry, is integral to establishing a good clinical diagnosis,” he said. “For this reason, patients are often referred into regional testing centers across the country.”

The Foundation Fighting Blindness (FFB) just designated Colorado Retina Associates as one of more than a dozen IRD testing sites across the country. FFB, as well as other offices or members of the community, refer about 50 new IRD patients annually to Colorado Retina Associates, which has seen IRD patients from 7 different states, said Mr. Humes.



ERG. Electroretinography is one of the many specialized tests conducted at Colorado Retina Associates for patients with inherited retinal diseases.

Patients are scheduled for time-consuming specialized tests a couple of weeks in advance of seeing Dr. Kimura for an exam. “Visual fields are important because retinal dystrophies present so differently,” said Mr. Humes. “Monitoring whole retina function, ERGs provide a signal of the eye much like an EKG provides a signal of the heart.” As it involves dilation, electrodes, gold-plated contact lenses, and bright lights, an ERG is no picnic for the patients, he added.

Other testing. “You can also use imaging and other tests, such as OCT (optical coherence tomography) and visual acuity, to give you clues that the cones are more involved,” said John W. Kitchens, MD, at Retina Associates of Kentucky in Lexington. “As far as a rod-mediated process, autofluorescence and peripheral visual fields will help.” Imaging is also incredibly helpful for patients and their families who may never have previously seen what their inherited retinal process looks like, he said.

Scheduling New Patients

The pace and rhythm of an IRD clinic is much different from that of a high-throughput clinic of established macular degeneration and diabetic patients.

The new IRD patients who are typically referred to Dr. Kitchens’ practice often have a preexisting diagnosis of a hereditary cone or rod disorder. “That gives us the opportunity to schedule them at a time when I’ll have more time to talk with them upfront. Last patient in the morning or last patient in the afternoon are good places for these patients, who may take 3 to 4 times as long as a patient with diabetic retinopathy or a macular hole, for example.”

It can be challenging to break unexpected news to patients, who need different information and levels of support at different ages, said Mr. Humes. To allow undivided time for discussions like these, Dr. Kimura schedules his IRD patients into half-day clinics devoted exclusively to the needs of IRD patients.

Medical and family history. Dr. Kimura takes a medical history and performs a standard clinical eye exam. Then, said Ms. Kagey, “I would have my conversation with the patients. I start with a targeted family history, asking about siblings, children, and other family members.” This information, she said, lets you “get a picture of where this patient is on his or her journey.”

Building rapport along the way, Ms. Kagey begins to assess which patients need more education or support to grapple with a serious diagnosis. “There are so many places where these patients can fall out of the system—where they can get lost

or misdirected—and so I think a key piece of a genetic counselor’s work is being that safety net,” she said.

Taking a thorough family history also helps better direct genetic testing and develop your differential, said Ms. Kagey. She cited the example of a patient who years earlier had pursued about \$800 in testing for X-linked RP. “We drew his family tree and found male-to-male transmission of RP, which made it impossible for his RP to be X-linked. Helping him choose the right testing could have saved him a lot of money.”

Genetic Testing—More Important Than Before

“In the past, we couldn’t do much for patients with IRDs, so knowing a patient’s genetic defect was more academic,” said Dr. Kitchens. “Now we’re entering an era where, although it’s still limited, we’re starting to have options that will undoubtedly grow in the future.”

When Dr. Kimura first saw Mr. Bynum, he suspected that he had a rare form of RP due to his nanophthalmos, so he recommended genetic testing to confirm. “Within 4 months, Mr. Bynum had

What Gene Therapy May Mean for the Future

The FDA approval of Luxturna gives hope to patients with IRDs, said Dr. Kitchens. “If this is successful for a devastating condition such as *RPE65*-mediated blindness, then less severe conditions may respond even better.”

The data on Luxturna. Colleagues who participated in the Luxturna trials call this a game changer, said Dr. Kitchens. “Patients have a 200% to 300% improvement in their field of vision. This isn’t just a marginal benefit—it’s functionally relevant and life changing for patients.”

Dr. Kay is personally calling all her patients with *RPE65* Leber congenital amaurosis (LCA) who don’t have significant vision loss and advising them to get treated—and not wait for other trials. “Having delved into the 3-year follow-up data on Luxturna, I am convinced of both its safety and efficacy,” she said.

Excitement mixed with realism. At the same time, Dr. Kay clarifies with other patients that only one FDA-approved gene therapy is currently available and that their likelihood of having this form of LCA is very low. The prevalence of *RPE65* mutation-asso-

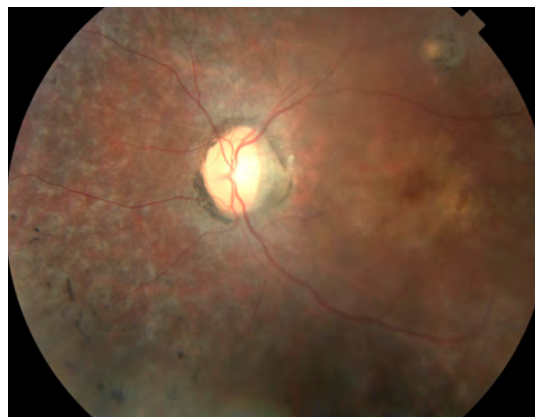
ciated retinal dystrophy is thought to be approximately 1/200,000.

Finding trials. When there’s a

strong suspicion of a genetic disease or a confirmed genetic diagnosis, Dr. Kitchens typically checks Clinicaltrials.gov to see whether any appropriate drug or gene therapy trials are available and then refers the patient for an evaluation. It’s important to help patients discern which trials are not legitimate, added Ms. Kagey, especially those that require fees to participate. Dr. Kimura and staff have also found the FFB website and events to be a great source of information about trials.

Not a one-stop shop.

Gene therapy is not an easy fix for all IRD problems, said Dr. Kay. “For example, with a prevalence of 1 in 4,000, RP is the most common type of inherited retinal dystrophy, but it is caused by hundreds of genes, so developing replacement-based gene therapies for all genetic forms of RP would be challenging. There’s less we can offer these patients



LCA. Luxturna, the new gene therapy for IRD patients with mutations in both copies of the *RPE65* gene, holds hope for future IRD treatments.

right now from a gene therapy standpoint.”

Other areas of research. However, optogenetics is an example of a therapeutic field that may someday be able to address multiple retinal conditions, even where significant visual loss has already occurred, said Dr. Kay. This form of treatment uses light and gene therapy but is not dependent upon a specific genotype, as it doesn’t replace a missing or mutant gene. Optogenetics involves reprogramming healthy inner retinal cells to function like photoreceptors.

And, although human clinical trials are still in very early phases, the field of stem cell therapy holds some promise for the future, she said.

a molecular diagnosis and family genetic counseling,” said Mr. Humes, “something that could have taken upward of 5 years and thousands of dollars in the past.”

Who should be tested? After the initial testing and exam, it’s important to equip patients with enough information to decide whether to do genetic testing. To prepare for prospective clinical trials and treatment, and to inform patients and subsequent generations about their risk of passing on the disease, Dr. Kimura strongly recommends genetic testing for most—if not all—of his IRD patients.

Dr. Kay does not think testing is mandatory for every patient with an IRD but recommends it for most patients. “I would say it absolutely is necessary for pediatric patients with a diagnosis of an IRD and anybody with an X-linked or autosomal dominant disease because of the importance of genetic counseling within families. It is also

absolutely mandatory to perform genetic testing if the diagnosis is Leber congenital amaurosis or early onset retinitis pigmentosa, given the recent FDA approval of Luxturna for *RPE65*-associated retinal degeneration.”

In addition, Dr. Kay recommends testing for anyone who may be a candidate for a current gene or drug clinical trial, such as patients suspected of having choroideremia, Stargardt disease, X-linked RP, X-linked retinoschisis, Usher syndrome, or achromatopsia.

The kids are all right? When a parent is diagnosed with an IRD, often their first question is, “Are my kids affected?” What follows is a discussion about whether to test seemingly unaffected minors, said Ms. Kagey. “Are they at a point in their lives where they have the capacity to process this information? Or should we wait until later? The general guideline is not to test unaffected minors.” However, she said, a 16-year-old might

IRD Resources for Doctors and Patients

For doctors and patients who want to learn more, a wealth of information exists.

Education for clinicians.

For each of the past several years, Dr. Kay has taught a course with several international and domestic faculty at the annual meetings of the Academy and the American Society of Retina Specialists. The instruction course provides information about IRDs, genetic testing, and gene therapy updates. In addition, Dr. Kay wrote a comprehensive overview titled “Logistics of Genetic Testing: An Overview for Retina Specialists” discussing the how-tos of genetic testing in a clinical setting.¹

Genetic testing services.

Commercial labs that offer comprehensive retina dystrophy panels, said Dr. Kay, include Baylor Genetics, Blueprint Genetics, GeneDx, Molecular Vision Lab, and PreventionGenetics. In addition, some universities and nonprofit labs, such as the Carver Nonprofit Genetic

Testing Laboratory at the University of Iowa, offer testing.

Genetic counseling services.

The website of the National Society of Genetic Counselors has a tool for finding genetic counselors in your area, said Ms. Kagey. “And online resources that provide telephone genetic counseling, such as InformedDNA, are good options for those who don’t have local access to genetic counselors.”

Registries. In addition to My Retina Tracker, the National Institute of Health’s Genetic Testing Registry is a central location for providers to voluntarily submit information about genetic tests.

Other websites. A variety of websites, including the following, provide more insights about IRDs:

- NEI’s **eyeGene** (The National Ophthalmic Disease Genotyping and Phenotyping Network) facilitates research into the causes and mechanisms of rare IRDs and works

to accelerate development of treatments.

- **Foundation Fighting Blindness** was founded by families of loved ones with IRDs; today, it is the leading private funder of retinal disease research. To date, its support has helped researchers identify more than 250 genes linked to retinal disease and has helped launch 20 clinical trials.

- The **National Organization for Rare Disorders** is a patient advocacy organization dedicated to individuals with rare diseases and the organizations that serve them.

- **Online Mendelian Inheritance in Man** is an online catalog of human genes and genetic disorders, including IRDs with syndromic conditions.

- **Low vision resources.** The Academy offers resources for physicians working with low vision patients at aao.org/low-vision-and-vision-rehab.

¹ Kay C. *Retinal Physician*. 2017; 14:55-58.

benefit from testing, for example, because it might help direct career choices.

Advise and consent. As part of the consent process, it's important to infuse realism into the discussion and inform patients that not every test finds every mutation, said Ms. Kagey. "There are 20,000 genes in the human body, and we are only testing some of them. We don't always find an answer."

On the other hand, testing can spring surprises on everyone involved. "Years ago, we tested one gene at a time," said Ms. Kagey. "Now, with the advent of next-generation sequencing, we can sequence multiple genes on a chip and may uncover a gene we hadn't suspected—possibly one associated with a genetic syndrome." This means that, out of the blue, a patient could not only be grappling with an IRD diagnosis, but also be asked to undergo a scan to check for kidney involvement, she explained.

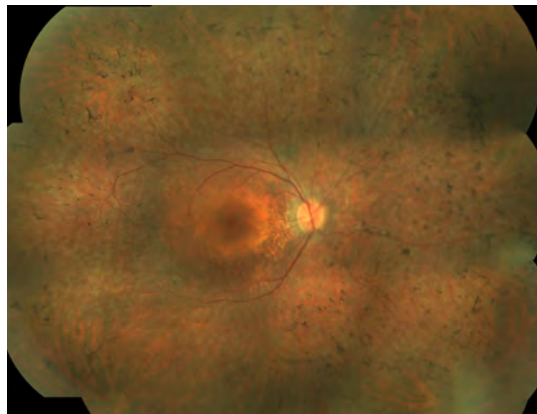
A tale of 2 sisters. Sometimes, however, the ability to do genetic testing can have strikingly positive consequences. Dr. Kitchens recounts meeting a 40-year-old patient with RP, who also had severe hearing loss but thought it was due to a viral infection she'd acquired as a child. While taking a family history, Dr. Kitchens learned that another sister was also blind and deaf. Genetic testing subsequently confirmed that both sisters had Usher syndrome. "Even though we couldn't do anything for the RP part of the syndrome," he said, "the sisters could get cochlear implants and hear again."

How to pay for genetic testing. First, you can help patients investigate whether there's a way to get genetic testing for free. The FFB is supporting genetic testing and counseling for ophthalmic practices that are members of the My Retina Tracker registry. "I am now able to offer these patients free, very accurate, grant-funded genetic testing typically with a 6-week turnaround," said Dr. Kay.

Today, a genetic panel of 180 to 250 genes costs somewhere between \$1,500 and \$2,500, said Ms. Kagey, but insurance coverage is "all over the map." Sometimes that cost is eaten up by huge deductibles, for example, or there's a 20% copay. "That's why finding a lab that works with the patient's insurance is so important," she said. "If necessary, you can follow up with a second lab that conducts testing utilizing a different methodology."

Who Counsels Patients?

"At Retina Associates of Kentucky, we do some of the rudimentary pretest counseling, draw the blood or collect saliva samples, and send samples



CAUSATION. A classic case of retinitis pigmentosa caused by a mutation in the PRPF31 gene.

out for testing," said Dr. Kitchens.

In-house certified genetic counselor. With more than 250 genes implicated in inherited retinal dystrophies, the genetic landscape is vast, said Ms. Kagey. "When you run that many genes, you are going to get background noise. A certified genetic counselor helps patients sort through the ambiguity of genetic testing—explaining which genetic changes mean something and which may be disease-causing but are something we've never seen before."

Posttest counseling also helps patients navigate the emotional landscape of a molecular diagnosis, said Ms. Kagey. For example, parent studies can confirm the cause of the IRD, but results are often accompanied by guilt. "We help parents process these emotions," she said. "Having a space for families to voice these emotions is critical for adapting to a new diagnosis."

Physician input. Dr. Kay spends many evenings calling patients from home to counsel them about their genetic results. She describes the genetic components, the demographics of the disease, the prognosis, and whether a relevant clinical trial is available—offering to help patients navigate their options. "I tell my patients that they will also get ocular genetic testing through InformedDNA, which is an ocular genetic testing telecounseling service."

Local resources. Dr. Kitchens prefers having someone local do the genetic counseling. "We typically use the University of Kentucky, where they have a geneticist and genetic counselors on staff," he said.

In Denver, however, getting appointments with local genetic counselors is not as expeditious or easy for patients to access as online resources, said Mr. Humes. Now that Ms. Kagey is no longer working with Colorado Retina Associates, Dr. Kimura prefers making use of the services provided by InformedDNA.

Patient Care in the Absence of Tx

Genetic testing isn't the end of the road. But without a treatment to offer, doctors tend to pull away from patients, said Dr. Kimura. Yet, there is much that physicians can do to help, he said.

Low vision resources. Of course, low vision resources are an important part of the continuum of care. Mr. Bynum's vision has changed for the worse recently, said Mr. Humes, so he's at a point in his life where these services can be of great use. (The Academy offers low vision resources at aao.org/low-vision-and-vision-rehab.)

Social services. Dr. Kimura has also integrated social services into the traditional clinical model of care, and he said that patients seem to find it very valuable, although not currently reimbursable. "These services can help patients manage a range of challenges, from school to driving, employment, family, and concerns about risks to the next generation."

Local services. Helping patients find local resources where they can connect with others like them is also invaluable, said Mr. Humes. "These patients often form a close-knit community, taking advantage of social events and peer-to-peer counseling." Mr. Humes recently referred a long-time IRD patient to a newly diagnosed patient, who found the connection quite helpful. Likewise, Mr. Bynum was inspired after he met another person born with RP who was able to navigate working in an office.

One of Dr. Kimura's patients is exploring an entrepreneurial idea to create a rideshare service similar to Lyft and Uber but specifically tailored for the blind. Mr. Bynum expressed excitement about the prospects of a service like this because he voluntarily stopped driving due to the risks. But it's taken a toll. "Transportation and freedom are big things to learn to let go of," he said, adding that he also lost his job (which involved climbing telephone poles) due to hazards related to his vision loss.

Data registries. Registries are another helpful aspect of care. Hosted by the FFB, My Retina Tracker empowers patients who have their genetic information, said Ms. Kagey.

Online data registries like My Retina Tracker are a platform for patients to voluntarily and securely share their genetic information, making it easier for qualified researchers to find patients with a given IRD and known molecular diagnosis, said Dr. Kimura. "From this enriched pool of patients with an accurate diagnosis of a specific molecular defect, scientists and clinicians can work together to drive toward the next gene therapy," said Dr. Kimura.

Mr. Bynum said that being on My Retina Tracker has taken a weight off his shoulders. "You'll always have the feeling that if a clinical trial starts up, you'll be considered for participation because you're right where all the doctors are looking."

MEET THE EXPERTS

SETH BYNUM Patient at Colorado Retina Associates in Denver. *Relevant financial disclosures: None.*

ANDY HUMES Ocular genetics coordinator at Colorado Retina Associates in Denver. *Relevant financial disclosures: None.*

JOSIE KAGEY Certified genetic counselor formerly with Colorado Retina Associates in Denver. *Relevant financial disclosures: None.*

CHRISTINE N. KAY, MD Vitreoretinal specialist at Vitreoretinal Associates in Gainesville, Fla. *Relevant financial disclosures: Spark*


Therapeutics: C; AGTC: S; Foundation Fighting Blindness: S.

JOHN W. KITCHENS, MD Vitreoretinal specialist at Retina Associates of Kentucky in Lexington. *Relevant financial disclosures: None.*

ALAN E. KIMURA, MD, MPH Vitreoretinal specialist at Colorado Retina Associates and clinical associate professor of ophthalmology at the University of Colorado Health Sciences Center, both in Denver. *Relevant financial disclosures: None.*

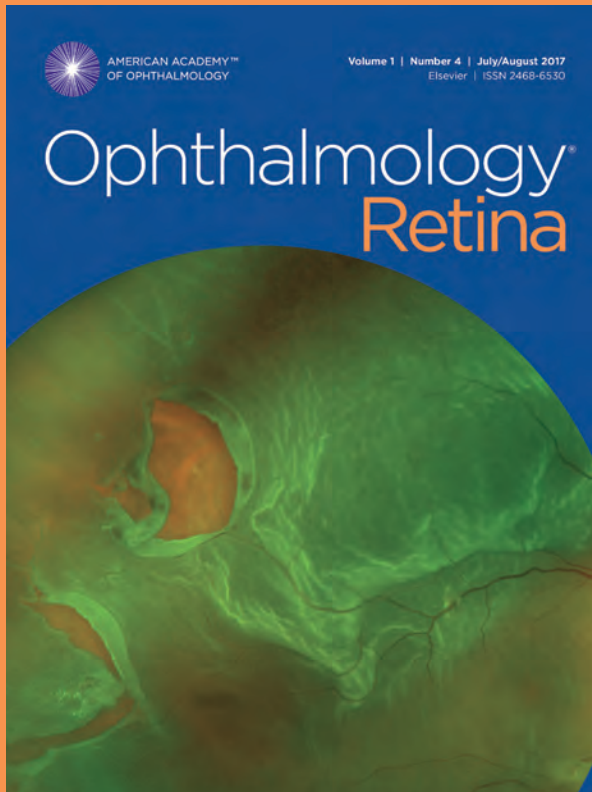


See financial disclosure key, page 3. For full disclosures, view this article at aao.org/eyenet.



AMERICAN ACADEMY
OF OPHTHALMOLOGY®

Ophthalmology® *Retina*




Subspecialty research
from the world's leading
ophthalmic journal

Ophthalmology® *Retina* from the American Academy of Ophthalmology is a new scientific publication focused exclusively on retina-related eye diseases and conditions. Stay on top of the growing volume of high-quality retina research and learn about advances in medical drug treatment, surgery, technology and science.

Subscribe:
aao.org/store

Submit your paper:
aao.org/retinajournal



AMERICAN ACADEMY
OF OPHTHALMOLOGY®



Enjoy AAO 2018 All Year-Round

AAO 2018 Meetings
on Demand

Watch your favorite presentations again or see what you missed with AAO 2018 Meetings on Demand.

Choose from eight Subspecialty Day meetings or the AAOE Program; or save when you buy the complete package, which includes highlights from AAO 2018.

SAVE 10%

When you purchase this product during AAO 2018 at the Academy Resource Center, booth 508, or in the Grand Concourse, Level 3.

aao.org/store



BRIEF SUMMARY—Please see the EYLEA package insert for full Prescribing Information.

1 INDICATIONS AND USAGE

EYLEA is a vascular endothelial growth factor (VEGF) inhibitor indicated for the treatment of:

Neovascular (Wet) Age-Related Macular Degeneration (AMD); Macular Edema Following Retinal Vein Occlusion (RVO); Diabetic Macular Edema (DME); Diabetic Retinopathy (DR) in Patients with DME

4 CONTRAINDICATIONS

4.1 Ocular or Periorcular Infections

EYLEA is contraindicated in patients with ocular or periorcular infections.

4.2 Active Intraocular Inflammation

EYLEA is contraindicated in patients with active intraocular inflammation.

4.3 Hypersensitivity

EYLEA is contraindicated in patients with known hypersensitivity to aflibercept or any of the excipients in EYLEA. Hypersensitivity reactions may manifest as rash, pruritus, urticaria, severe anaphylactic/anaphylactoid reactions, or severe intraocular inflammation.

5 WARNINGS AND PRECAUTIONS

5.1 Endophthalmitis and Retinal Detachments. Intravitreal injections, including those with EYLEA, have been associated with endophthalmitis and retinal detachments [see *Adverse Reactions (6.1)*]. Proper aseptic injection technique must always be used when administering EYLEA. Patients should be instructed to report any symptoms suggestive of endophthalmitis or retinal detachment without delay and should be managed appropriately [see *Dosage and Administration (2.7)* and *Patient Counseling Information (17)*].

5.2 Increase in Intraocular Pressure. Acute increases in intraocular pressure have been seen within 60 minutes of intravitreal injection, including with EYLEA [see *Adverse Reactions (6.1)*]. Sustained increases in intraocular pressure have also been reported after repeated intravitreal dosing with vascular endothelial growth factor (VEGF) inhibitors. Intraocular pressure and the perfusion of the optic nerve head should be monitored and managed appropriately [see *Dosage and Administration (2.7)*].

5.3 Thromboembolic Events. There is a potential risk of arterial thromboembolic events (ATEs) following intravitreal use of VEGF inhibitors, including EYLEA. ATEs are defined as nonfatal stroke, nonfatal myocardial infarction, or vascular death (including deaths of unknown cause). The incidence of reported thromboembolic events in wet AMD studies during the first year was 1.8% (32 out of 1824) in the combined group of patients treated with EYLEA. The incidence in the DME studies from baseline to week 52 was 3.3% (19 out of 578) in the combined group of patients treated with EYLEA compared with 2.8% (8 out of 287) in the control group; from baseline to week 100, the incidence was 6.4% (37 out of 578) in the combined group of patients treated with EYLEA compared with 4.2% (12 out of 287) in the control group. There were no reported thromboembolic events in the patients treated with EYLEA in the first six months of the RVO studies.

6 ADVERSE REACTIONS

The following potentially serious adverse reactions are described elsewhere in the labeling:

- Hypersensitivity [see *Contraindications (4.3)*]
- Endophthalmitis and retinal detachments [see *Warnings and Precautions (5.1)*]
- Increase in intraocular pressure [see *Warnings and Precautions (5.2)*]
- Thromboembolic events [see *Warnings and Precautions (5.3)*]

6.1 Clinical Trials Experience. Because clinical trials are conducted under widely varying conditions, adverse reaction rates observed in the clinical trials of a drug cannot be directly compared to rates in other clinical trials of the same or another drug and may not reflect the rates observed in practice.

A total of 2711 patients treated with EYLEA constituted the safety population in seven phase 3 studies. Among those, 2110 patients were treated with the recommended dose of 2 mg. Serious adverse reactions related to the injection procedure have occurred in <0.1% of intravitreal injections with EYLEA including endophthalmitis and retinal detachment. The most common adverse reactions (≥5%) reported in patients receiving EYLEA were conjunctival hemorrhage, eye pain, cataract, vitreous floaters, intraocular pressure increased, and vitreous detachment.

Neovascular (Wet) Age-Related Macular Degeneration (AMD). The data described below reflect exposure to EYLEA in 1824 patients with wet AMD, including 1223 patients treated with the 2-mg dose, in 2 double-masked, active-controlled clinical studies (VIEW1 and VIEW2) for 12 months.

Table 1: Most Common Adverse Reactions (≥1%) in Wet AMD Studies

| Adverse Reactions | EYLEA (N=1824) | Active Control (ranibizumab) (N=595) |
|--|----------------|--------------------------------------|
| Conjunctival hemorrhage | 25% | 28% |
| Eye pain | 9% | 9% |
| Cataract | 7% | 7% |
| Vitreous detachment | 6% | 6% |
| Vitreous floaters | 6% | 7% |
| Intraocular pressure increased | 5% | 7% |
| Ocular hyperemia | 4% | 8% |
| Corneal epithelium defect | 4% | 5% |
| Detachment of the retinal pigment epithelium | 3% | 3% |
| Injection site pain | 3% | 3% |
| Foreign body sensation in eyes | 3% | 4% |
| Lacrimation increased | 3% | 1% |
| Vision blurred | 2% | 2% |
| Intraocular inflammation | 2% | 3% |
| Retinal pigment epithelium tear | 2% | 1% |
| Injection site hemorrhage | 1% | 2% |
| Eyelid edema | 1% | 2% |
| Corneal edema | 1% | 1% |

Less common serious adverse reactions reported in <1% of the patients treated with EYLEA were hypersensitivity, retinal detachment, retinal tear, and endophthalmitis.

Macular Edema Following Retinal Vein Occlusion (RVO). The data described below reflect 6 months exposure to EYLEA with a monthly 2 mg dose in 218 patients following CRVO in 2 clinical studies (COPERNICUS and GALILEO) and 91 patients following BRVO in one clinical study (VIBRANT).

Table 2: Most Common Adverse Reactions (≥1%) in RVO Studies

| Adverse Reactions | CRVO | | BRVO | |
|--------------------------------|---------------|-----------------|--------------|----------------|
| | EYLEA (N=218) | Control (N=142) | EYLEA (N=91) | Control (N=92) |
| Eye pain | 13% | 5% | 4% | 5% |
| Conjunctival hemorrhage | 12% | 11% | 20% | 4% |
| Intraocular pressure increased | 8% | 6% | 2% | 0% |
| Corneal epithelium defect | 5% | 4% | 2% | 0% |
| Vitreous floaters | 5% | 1% | 1% | 0% |
| Ocular hyperemia | 5% | 3% | 2% | 2% |
| Foreign body sensation in eyes | 3% | 5% | 3% | 0% |
| Vitreous detachment | 3% | 4% | 2% | 0% |
| Lacrimation increased | 3% | 4% | 3% | 0% |
| Injection site pain | 3% | 1% | 1% | 0% |
| Vision blurred | 1% | <1% | 1% | 1% |
| Intraocular inflammation | 1% | 1% | 0% | 0% |
| Cataract | <1% | 1% | 5% | 0% |
| Eyelid edema | <1% | 1% | 1% | 0% |

Less common adverse reactions reported in <1% of the patients treated with EYLEA in the CRVO studies were corneal edema, retinal tear, hypersensitivity, and endophthalmitis.

Diabetic Macular Edema (DME). The data described below reflect exposure to EYLEA in 578 patients with DME treated with the 2-mg dose in 2 double-masked, controlled clinical studies (VIVID and VISTA) from baseline to week 52 and from baseline to week 100.

Table 3: Most Common Adverse Reactions (≥1%) in DME Studies

| Adverse Reactions | Baseline to Week 52 | | Baseline to Week 100 | |
|--------------------------------|---------------------|-----------------|----------------------|-----------------|
| | EYLEA (N=578) | Control (N=287) | EYLEA (N=578) | Control (N=287) |
| Conjunctival hemorrhage | 28% | 17% | 31% | 21% |
| Eye pain | 9% | 6% | 11% | 9% |
| Cataract | 8% | 9% | 19% | 17% |
| Vitreous floaters | 6% | 3% | 8% | 6% |
| Corneal epithelium defect | 5% | 3% | 7% | 5% |
| Intraocular pressure increased | 5% | 3% | 9% | 5% |
| Ocular hyperemia | 5% | 6% | 5% | 6% |
| Vitreous detachment | 3% | 3% | 8% | 6% |
| Foreign body sensation in eyes | 3% | 3% | 3% | 3% |
| Lacrimation increased | 3% | 2% | 4% | 2% |
| Vision blurred | 2% | 2% | 3% | 4% |
| Intraocular inflammation | 2% | <1% | 3% | 1% |
| Injection site pain | 2% | <1% | 2% | <1% |
| Eyelid edema | <1% | 1% | 2% | 1% |

Less common adverse reactions reported in <1% of the patients treated with EYLEA were hypersensitivity, retinal detachment, retinal tear, corneal edema, and injection site hemorrhage.

6.2 Immunogenicity. As with all therapeutic proteins, there is a potential for an immune response in patients treated with EYLEA. The immunogenicity of EYLEA was evaluated in serum samples. The immunogenicity data reflect the percentage of patients whose test results were considered positive for antibodies to EYLEA in immunoassays. The detection of an immune response is highly dependent on the sensitivity and specificity of the assays used, sample handling, timing of sample collection, concomitant medications, and underlying disease. For these reasons, comparison of the incidence of antibodies to EYLEA with the incidence of antibodies to other products may be misleading.

In the wet AMD, RVO, and DME studies, the pre-treatment incidence of immunoreactivity to EYLEA was approximately 1% to 3% across treatment groups. After dosing with EYLEA for 24-100 weeks, antibodies to EYLEA were detected in a similar percentage range of patients. There were no differences in efficacy or safety between patients with or without immunoreactivity.

8 USE IN SPECIFIC POPULATIONS

8.1 Pregnancy

Risk Summary

Adequate and well-controlled studies with EYLEA have not been conducted in pregnant women. Aflibercept produced adverse embryofetal effects in rabbits, including external, visceral, and skeletal malformations. A fetal No Observed Adverse Effect Level (NOAEL) was not identified. At the lowest dose shown to produce adverse embryofetal effects, systemic exposures (based on AUC for free aflibercept) were approximately 6 times higher than AUC values observed in humans after a single intravitreal treatment at the recommended clinical dose [see *Animal Data*].

Animal reproduction studies are not always predictive of human response, and it is not known whether EYLEA can cause fetal harm when administered to a pregnant woman. Based on the anti-VEGF mechanism of action for aflibercept [see *Clinical Pharmacology (12.1)*], treatment with EYLEA may pose a risk to human embryofetal development. EYLEA should be used during pregnancy only if the potential benefit justifies the potential risk to the fetus.

All pregnancies have a background risk of birth defect, loss, or other adverse outcomes. The background risk of major birth defects and miscarriage for the indicated population is unknown. In the U.S. general population, the estimated background risk of major birth defects and miscarriage in clinically recognized pregnancies is 2-4% and 15-20%, respectively.

Data

Animal Data

In two embryofetal development studies, aflibercept produced adverse embryofetal effects when administered every three days during organogenesis to pregnant rabbits at intravenous doses ≥3 mg per kg, or every six days during organogenesis at subcutaneous doses ≥0.1 mg per kg.

Adverse embryofetal effects included increased incidences of postimplantation loss and fetal malformations, including anasarca, umbilical hernia, diaphragmatic hernia, gastroschisis, cleft palate, ectrodactyly, intestinal atresia, spina bifida, encephalomenoencephaly, heart and major vessel defects, and skeletal malformations (fused vertebrae, sternbrae, and ribs; supernumerary vertebral arches and ribs; and incomplete ossification). The maternal No Observed Adverse Effect Level (NOAEL) in these studies was 3 mg per kg. Aflibercept produced fetal malformations at all doses assessed in rabbits and the fetal NOAEL was not identified. At the lowest dose shown to produce adverse embryofetal effects in rabbits (0.1 mg per kg), systemic exposure (AUC) of free aflibercept was approximately 6 times higher than systemic exposure (AUC) observed in humans after a single intravitreal dose of 2 mg.

8.2 Lactation

Risk Summary

There is no information regarding the presence of aflibercept in human milk, the effects of the drug on the breastfed infant, or the effects of the drug on milk production/excretion. Because many drugs are excreted in human milk, and because the potential for absorption and harm to infant growth and development exists, EYLEA is not recommended during breastfeeding.

The developmental and health benefits of breastfeeding should be considered along with the mother's clinical need for EYLEA and any potential adverse effects on the breastfed child from EYLEA.

8.3 Females and Males of Reproductive Potential

Contraception

Females of reproductive potential are advised to use effective contraception prior to the initial dose, during treatment, and for at least 3 months after the last intravitreal injection of EYLEA.

Infertility

There are no data regarding the effects of EYLEA on human fertility. Aflibercept adversely affected female and male reproductive systems in cynomolgus monkeys when administered by intravenous injection at a dose approximately 1500 times higher than the systemic level observed humans with an intravitreal dose of 2 mg. A No Observed Adverse Effect Level (NOAEL) was not identified. These findings were reversible within 20 weeks after cessation of treatment [see *Nonclinical Toxicology (13.1)*].

8.4 Pediatric Use. The safety and effectiveness of EYLEA in pediatric patients have not been established.

8.5 Geriatric Use. In the clinical studies, approximately 76% (2049/2701) of patients randomized to treatment with EYLEA were ≥65 years of age and approximately 46% (1250/2701) were ≥75 years of age. No significant differences in efficacy or safety were seen with increasing age in these studies.

17 PATIENT COUNSELING INFORMATION

In the days following EYLEA administration, patients are at risk of developing endophthalmitis or retinal detachment. If the eye becomes red, sensitive to light, painful, or develops a change in vision, advise patients to seek immediate care from an ophthalmologist [see *Warnings and Precautions (5.1)*].

Patients may experience temporary visual disturbances after an intravitreal injection with EYLEA and the associated eye examinations [see *Adverse Reactions (6)*]. Advise patients not to drive or use machinery until visual function has recovered sufficiently.

Manufactured by:
Regeneron Pharmaceuticals, Inc.
777 Old Saw Mill River Road
Tarrytown, NY 10591

Issue Date: June 2017
Initial U.S. Approval: 2011

Based on the May 2017 EYLEA® (aflibercept) Injection full Prescribing Information.

EYLEA is a registered trademark of Regeneron Pharmaceuticals, Inc.
© 2017, Regeneron Pharmaceuticals, Inc. All rights reserved.

REGENERON



POWER TO PREVAIL

As demonstrated in phase 3 clinical trials evaluating BCVA,* as measured by ETDRS letters, in patients with Wet AMD, Macular Edema following RVO, DME, and by ETDRS-DRSS[†] in DR in Patients with DME,¹ as well as your clinical experience

Start with EYLEA for proven efficacy outcomes¹

AMD = Age-related Macular Degeneration; DME = Diabetic Macular Edema; DR = Diabetic Retinopathy.

INDICATIONS AND IMPORTANT SAFETY INFORMATION

INDICATIONS

- EYLEA[®] (aflibercept) Injection is indicated for the treatment of patients with Neovascular (Wet) Age-related Macular Degeneration (AMD), Macular Edema following Retinal Vein Occlusion (RVO), Diabetic Macular Edema (DME), and Diabetic Retinopathy (DR) in Patients with DME.

CONTRAINDICATIONS

- EYLEA[®] (aflibercept) Injection is contraindicated in patients with ocular or periocular infections, active intraocular inflammation, or known hypersensitivity to aflibercept or to any of the excipients in EYLEA.

WARNINGS AND PRECAUTIONS

- Intravitreal injections, including those with EYLEA, have been associated with endophthalmitis and retinal detachments. Proper aseptic injection technique must always be used when administering EYLEA. Patients should be instructed to report any symptoms suggestive of endophthalmitis or retinal detachment without delay and should be managed appropriately. Intraocular inflammation has been reported with the use of EYLEA.
- Acute increases in intraocular pressure have been seen within 60 minutes of intravitreal injection, including with EYLEA. Sustained increases in intraocular pressure have also been reported after repeated intravitreal dosing with VEGF inhibitors. Intraocular pressure and the perfusion of the optic nerve head should be monitored and managed appropriately.
- There is a potential risk of arterial thromboembolic events (ATEs) following intravitreal use of VEGF inhibitors, including EYLEA. ATEs are defined as nonfatal stroke, nonfatal myocardial infarction, or vascular death (including deaths of unknown cause). The incidence of reported thromboembolic events in wet AMD studies during the first year was 1.8% (32 out of 1824) in the combined group of patients treated with EYLEA. The incidence in the DME studies from baseline to week 52 was 3.3% (19 out of 578) in the combined group of patients treated with EYLEA compared with 2.8% (8 out of 287) in the control group; from baseline to week 100, the incidence was 6.4% (37 out of 578) in the combined group of patients treated with EYLEA compared with 4.2% (12 out of 287) in the control group. There were no reported thromboembolic events in the patients treated with EYLEA in the first six months of the RVO studies.

ADVERSE REACTIONS

- Serious adverse reactions related to the injection procedure have occurred in <0.1% of intravitreal injections with EYLEA including endophthalmitis and retinal detachment.
- The most common adverse reactions (≥5%) reported in patients receiving EYLEA were conjunctival hemorrhage, eye pain, cataract, vitreous floaters, intraocular pressure increased, and vitreous detachment.

Please see adjacent Brief Summary.

*Best-corrected visual acuity.

[†]Early Treatment Diabetic Retinopathy Study–Diabetic Retinopathy Severity Scale: an established grading scale for measuring the severity of DR.

Reference: 1. EYLEA[®] (aflibercept) Injection full U.S. Prescribing Information. Regeneron Pharmaceuticals, Inc. May 2017.

EYLEA is a registered trademark of Regeneron Pharmaceuticals, Inc.

REGENERON