


Q

## Diffuse Unilateral Subacute Neuroretinitis


- *What category of bug is implicated in DUSN?*



A

## Diffuse Unilateral Subacute Neuroretinitis

- *What category of bug is implicated in DUSN?*  
The nematode




Q

## Diffuse Unilateral Subacute Neuroretinitis

- *What category of bug is implicated in DUSN?*  
The **nematode**

*What is the common/colloquial name for the nematode?*




# A

## Diffuse Unilateral Subacute Neuroretinitis


- *What category of bug is implicated in DUSN?*  
The **nematode**

*What is the common/colloquial name for the nematode?*  
The roundworm



# Q


## Diffuse Unilateral Subacute Neuroretinitis



- *What category of bug is implicated in DUSN?*  
The nematode
- *Which three nematodes are implicated most often in DUSN?*
  - 1)
  - 2)
  - 3)

# A


## Diffuse Unilateral Subacute Neuroretinitis



- *What category of bug is implicated in DUSN?*  
The nematode
- *Which three nematodes are implicated most often in DUSN?*
  - 1) *Baylisascaris*
  - 2) *Ancylostoma*
  - 3) *Toxocara*

# Q


## Diffuse Unilateral Subacute Neuroretinitis



- *What category of bug is implicated in DUSN?*  
The nematode
- *Which three nematodes are implicated most often in DUSN? Which is the most common cause?*
  - 1) *Baylisascaris?*
  - 2) *Ancylostoma?*
  - 3) *Toxocara?*

# A

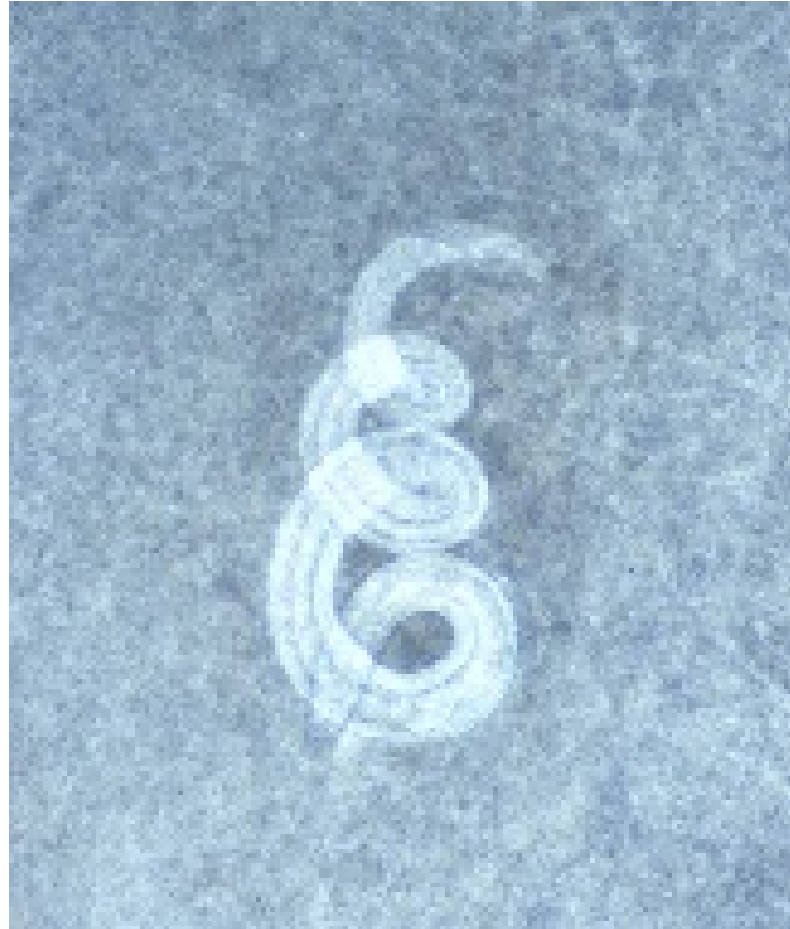
## Diffuse Unilateral Subacute Neuroretinitis



- *What category of bug is implicated in DUSN?*  
The nematode
- *Which three nematodes are implicated most often in DUSN? Which is the most common cause?*
  - 1) *Baylisascaris—most common*
  - 2) *Ancylostoma*
  - 3) *Toxocara*




## Diffuse Unilateral Subacute Neuroretinitis



*Baylisascaris procyonis* (the raccoon roundworm)

# Q


## Diffuse Unilateral Subacute Neuroretinitis



- *What category of bug is implicated in DUSN?*  
The nematode
- *Which three nematodes are implicated most often in DUSN? Which is the most common cause?*
  - 1) *Baylisascaris—most common*
  - 2) *Ancylostoma*
  - 3) *Toxocara*
- *What is the infectious load in DUSN, ie, how many worms are typically involved?*

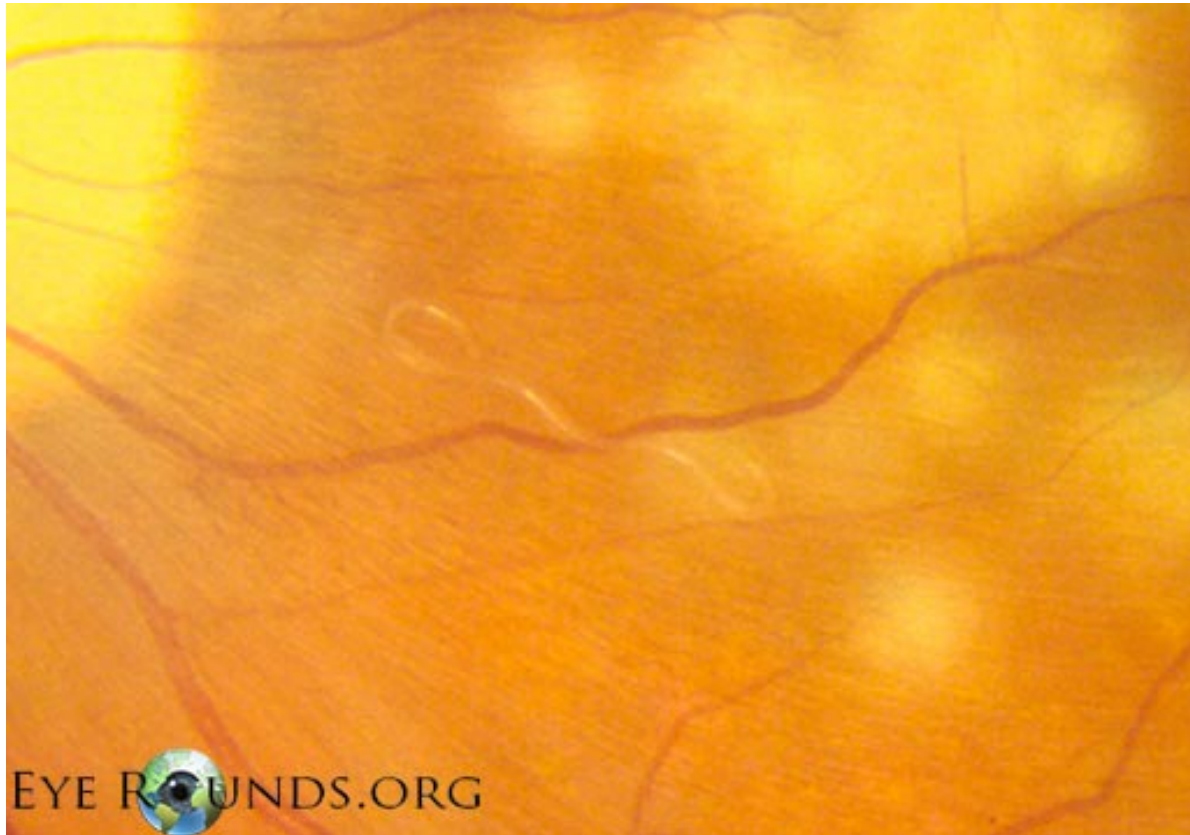

# A

## Diffuse Unilateral Subacute Neuroretinitis



- *What category of bug is implicated in DUSN?*  
The nematode
- *Which three nematodes are implicated most often in DUSN? Which is the most common cause?*
  - 1) *Baylisascaris—most common*
  - 2) *Ancylostoma*
  - 3) *Toxocara*
- *What is the infectious load in DUSN, ie, how many worms are typically involved? One—there's a single worm in there*

## Diffuse Unilateral Subacute Neuroretinitis



*DUSN*

# Q


## Diffuse Unilateral Subacute Neuroretinitis



- *What category of bug is implicated in DUSN?*  
The nematode
- *Which three nematodes are implicated most often in DUSN? Which is the most common cause?*
  - 1) *Baylisascaris—most common*
  - 2) *Ancylostoma*
  - 3) *Toxocara*
- *What is the infectious load in DUSN, ie, how many worms are typically involved?* One—there's a single worm in there
- *How is DUSN treated?*

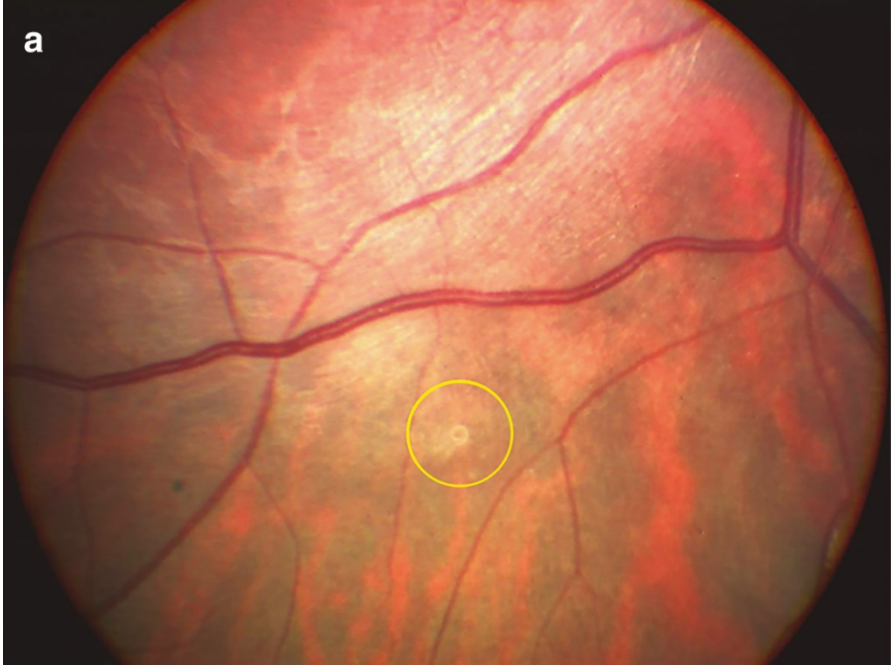

# A

## Diffuse Unilateral Subacute Neuroretinitis

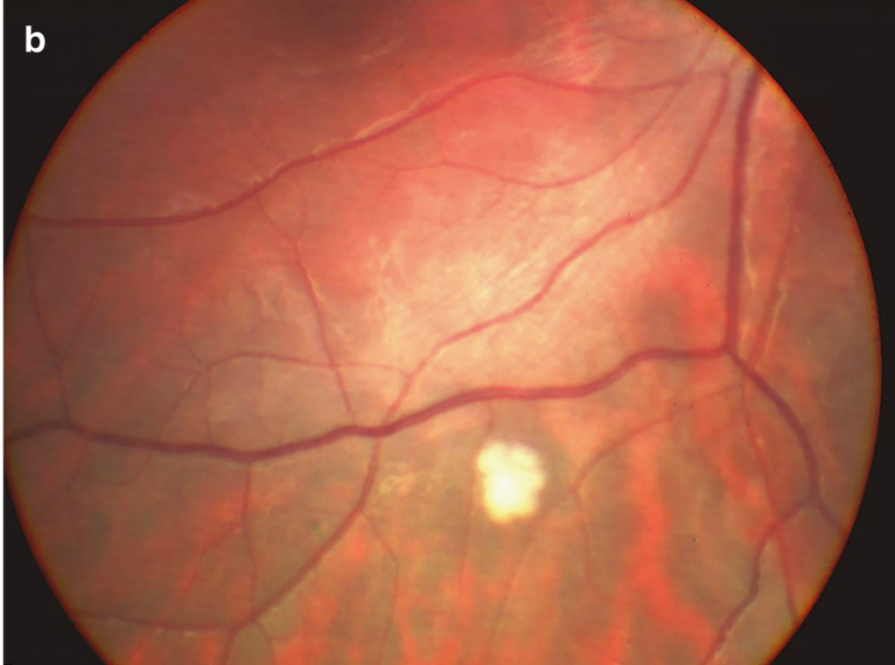

- *What category of bug is implicated in DUSN?*  
The nematode
- *Which three nematodes are implicated most often in DUSN? Which is the most common cause?*
  - 1) *Baylisascaris—most common*
  - 2) *Ancylostoma*
  - 3) *Toxocara*
- *What is the infectious load in DUSN, ie, how many worms are typically involved?* One—there's a single worm in there
- *How is DUSN treated?* Laser the subretinal critter (if you can find it)

# Diffuse Unilateral Subacute Neuroretinitis



Worm




Fried worm s/p laser

*DUSN*

# Q

## Diffuse Unilateral Subacute Neuroretinitis



- *What category of bug is implicated in DUSN?*  
The nematode
- *Which three nematodes are implicated most often in DUSN? Which is the most common cause?*
  - 1) *Baylisascaris*—most common
  - 2) *Ancylostoma*


*What are the odds regarding being able to locate the worm?*

- *How is DUSN treated? Laser the subretinal center (if you can find it)*



# A

## Diffuse Unilateral Subacute Neuroretinitis



- *What category of bug is implicated in DUSN?*  
The nematode
- *Which three nematodes are implicated most often in DUSN? Which is the most common cause?*
  - 1) *Baylisascaris*—most common

2) *Ancylostoma*


*What are the odds regarding being able to locate the worm?*

About 50:50

- *How is DUSN treated? Laser the subretinal center (if you can find it)*

# Q

## Diffuse Unilateral Subacute Neuroretinitis



- *What category of bug is implicated in DUSN?*  
The nematode
- *Which three nematodes are implicated most often in DUSN? Which is the most common cause?*

1) *Baylisascaris*—most common

2) *Ancylostoma*

*What are the odds regarding being able to locate the worm?*

About 50:50


*You strongly suspect DUSN—but can't find a worm. How should you proceed?*

*...y worms  
...m in there*

- *How is DUSN treated? Laser the subretinal center (if you can find it)*

# A

## Diffuse Unilateral Subacute Neuroretinitis



- *What category of bug is implicated in DUSN?*  
The nematode
- *Which three nematodes are implicated most often in DUSN? Which is the most common cause?*  
1) *Baylisascaris*—most common

2) *Anoxylostoma*

*What are the odds regarding being able to locate the worm?*

About 50:50

*You strongly suspect DUSN—but can't find a worm. How should you proceed?* *by worms*


Consider a short-but-intense course of systemic antihelminthic therapy—it *m in there*  
may immobilize the worm, thereby rendering it easier to find

- *How is DUSN treated? Laser the subretinal center (if you can find it)*

Q

## Diffuse Unilateral Subacute Neuroretinitis


- *Who is the typical DUSN pt?*



# A


## Diffuse Unilateral Subacute Neuroretinitis

- *Who is the typical DUSN pt?* An otherwise healthy adolescent or young adult



# Q


## Diffuse Unilateral Subacute Neuroretinitis



- *Who is the typical DUSN pt?* An otherwise healthy adolescent or young adult
- *DUSN has two stages--what are they?*
  - 1) *(this stage occurs first)*
  - 2)

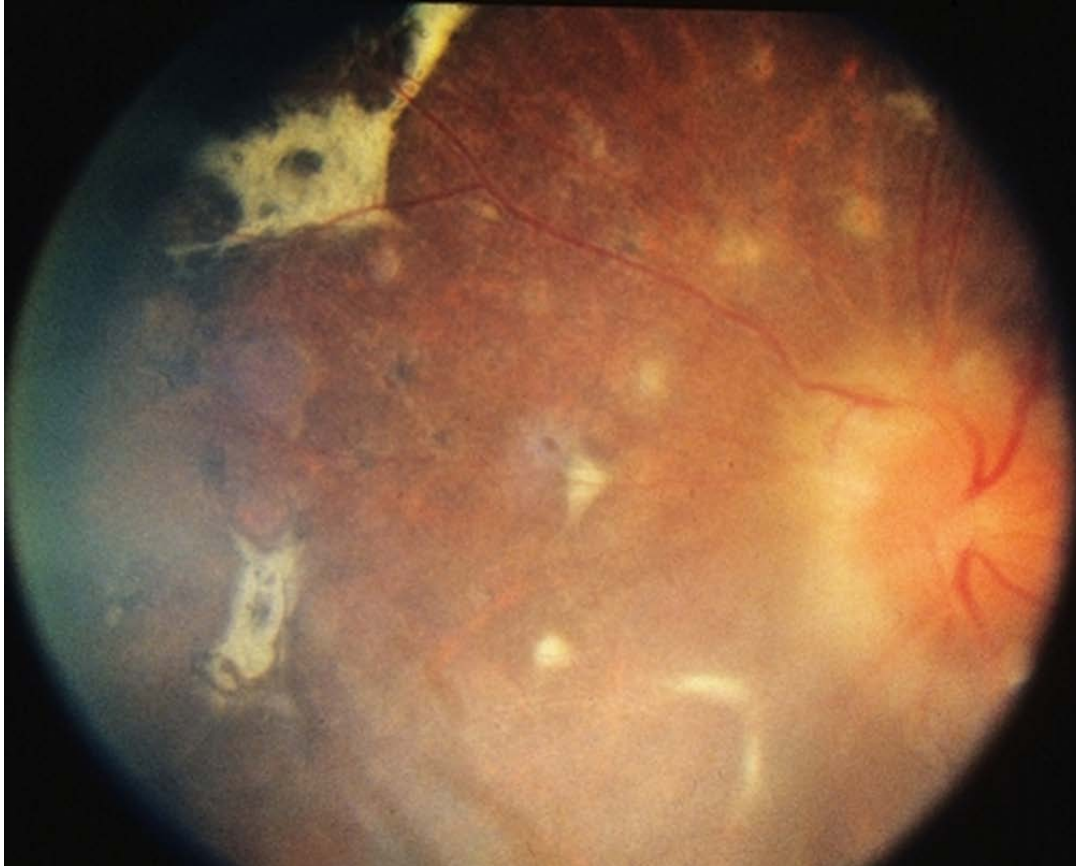
# A/Q

## Diffuse Unilateral Subacute Neuroretinitis



- *Who is the typical DUSN pt? An otherwise healthy adolescent or young adult*
- *DUSN has two stages--what are they?*
  - 1) In the **acute** stage, pts c/o decreased VA and pain. Exam reveals vitritis, disc edema, and multiple small gray/white retinal lesions. The signs/symptoms will wax and wane.
  - 2)

## Diffuse Unilateral Subacute Neuroretinitis




*DUSN: Acute stage*



# A/Q


## Diffuse Unilateral Subacute Neuroretinitis



- *Who is the typical DUSN pt? An otherwise healthy adolescent or young adult*
- *DUSN has two stages--what are they?*
  - 1) In the **acute** stage, pts c/o decreased VA and pain. Exam reveals vitritis, disc edema, and multiple small gray/white retinal lesions. The signs/symptoms will wax and wane.
  - 2) *(then this one)*

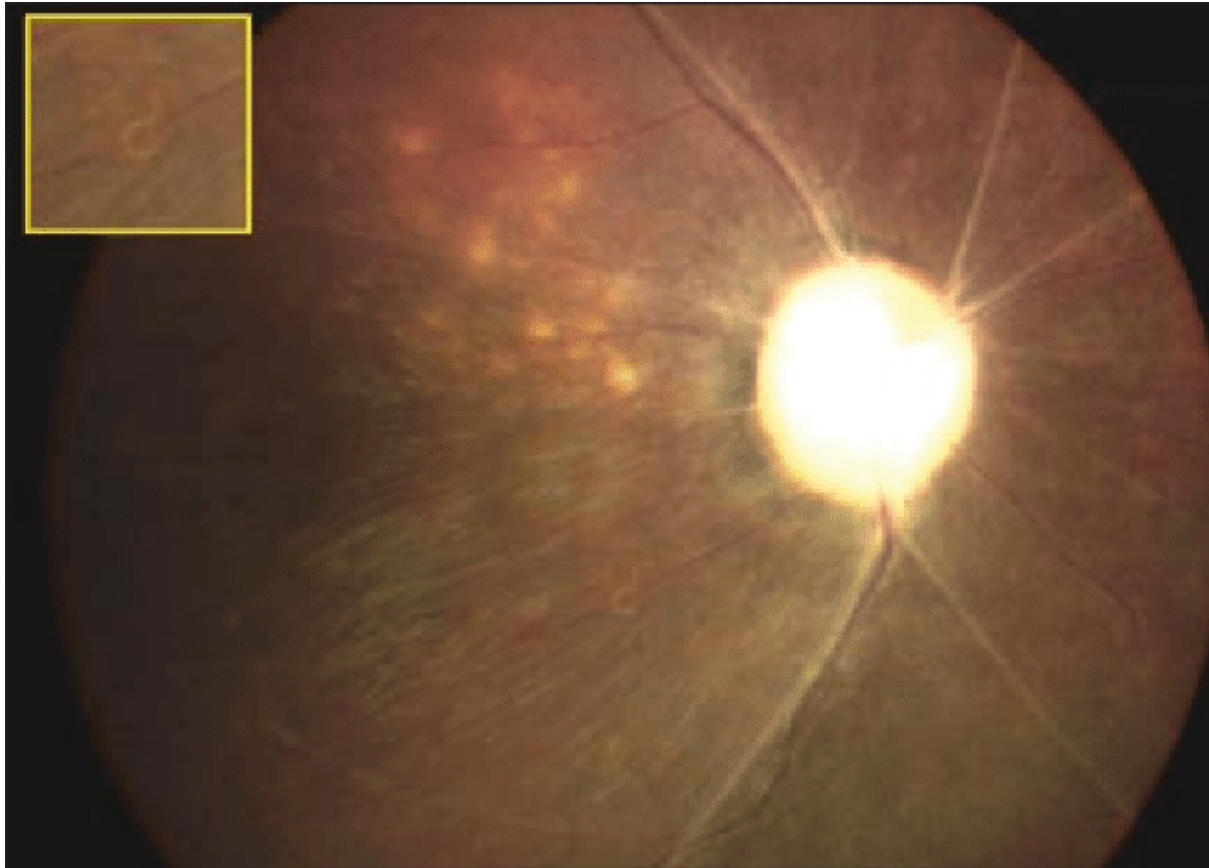

# A

## Diffuse Unilateral Subacute Neuroretinitis



- *Who is the typical DUSN pt? An otherwise healthy adolescent or young adult*
- *DUSN has two stages--what are they?*
  - 1) In the **acute** stage, pts c/o decreased VA and pain. Exam reveals vitritis, disc edema, and multiple small gray/white retinal lesions. The signs/symptoms will wax and wane.
  - 2) In **late**-stage disease, the RPE is depigmented, the disc is pallorous and atrophic, and the retinal vessels are attenuated. VA is poor.


## Diffuse Unilateral Subacute Neuroretinitis



*DUSN*: Late stage

# Q

## Diffuse Unilateral Subacute Neuroretinitis




- *Who is the typical DUSN pt? An otherwise healthy adolescent or young adult*
- *DUSN has two stages--what are they?*
  - 1) In the **acute** stage, pts c/o decreased VA and pain. Exam reveals vitritis, disc edema, and multiple small gray/white retinal lesions. The signs/symptoms will wax and wane.

*Hmm...A condition that strikes young, healthy adults...*

rous

# Q

## Diffuse Unilateral Subacute Neuroretinitis




- *Who is the typical DUSN pt? An otherwise healthy adolescent or young adult*
- *DUSN has two stages--what are they?*
  - 1) In the **acute** stage, pts c/o decreased VA and pain. Exam reveals vitritis, disc edema, and multiple small gray/white retinal lesions. The signs/symptoms will wax and wane.

*Hmm...A condition that strikes young, healthy adults...causes decreased vision...*

rous  
.

# Q

## Diffuse Unilateral Subacute Neuroretinitis




- *Who is the typical DUSN pt? An otherwise healthy adolescent or young adult*
- *DUSN has two stages--what are they?*
  - 1) In the **acute** stage, pts c/o decreased VA and pain. Exam reveals vitritis, disc edema, and multiple small gray/white retinal lesions. The signs/symptoms will wax and wane.

*Hmm...A condition that strikes young, healthy adults...causes decreased vision... vitritis...*

rous  
.

# Q

## Diffuse Unilateral Subacute Neuroretinitis




- *Who is the typical DUSN pt? An otherwise healthy adolescent or young adult*
- *DUSN has two stages--what are they?*
  - 1) In the **acute** stage, pts c/o decreased VA and pain. Exam reveals vitritis, disc edema, and multiple small gray/white retinal lesions.  
The signs/symptoms will wax and wane.

*Hmm...A condition that strikes young, healthy adults...causes decreased vision... vitritis...multiple small whitish lesions...*

rous  
.

# Q

## Diffuse Unilateral Subacute Neuroretinitis



- *Who is the typical DUSN pt? An otherwise healthy adolescent or young adult*
- *DUSN has two stages--what are they?*
  - 1) In the **acute** stage, pts c/o decreased VA and pain. Exam reveals vitritis, disc edema, and multiple small gray/white retinal lesions. The signs/symptoms will wax and wane.


*Hmm...A condition that strikes young, healthy adults...causes decreased vision... vitritis...multiple small whitish lesions...can wax and wane.*

rous  
.



# Q

## Diffuse Unilateral Subacute Neuroretinitis




- *Who is the typical DUSN pt? An otherwise healthy adolescent or young adult*
- *DUSN has two stages--what are they?*
  - 1) In the **acute** stage, pts c/o decreased VA and pain. Exam reveals vitritis, disc edema, and multiple small gray/white retinal lesions. The signs/symptoms will wax and wane.

*Hmm...A condition that strikes young, healthy adults...causes decreased vision... vitritis...multiple small whitish lesions...can wax and wane. Given this description, what general class of condition comes to mind?*

rouS  
.

# A

## Diffuse Unilateral Subacute Neuroretinitis




- *Who is the typical DUSN pt? An otherwise healthy adolescent or young adult*
- *DUSN has two stages--what are they?*
  - 1) In the **acute** stage, pts c/o decreased VA and pain. Exam reveals vitritis, disc edema, and multiple small gray/white retinal lesions. The signs/symptoms will wax and wane.

*Hmm...A condition that strikes young, healthy adults...causes decreased vision... vitritis...multiple small whitish lesions...can wax and wane. Given this description, what general class of condition comes to mind?*

**White Dot Syndromes.** When faced with a presumptive WDS pt, always consider whether it might be DUSN!

## Diffuse Unilateral Subacute Neuroretinitis



- *Who is the typical DUSN pt? An otherwise healthy adolescent or young adult*
- *DUSN has two stages--what are they?*
  - 1) In the **acute** stage, pts c/o decreased VA and pain. Exam reveals vitritis, disc edema, and multiple small gray/white retinal lesions. The signs/symptoms will wax and wane.


*Hmm...A condition that strikes young, healthy adults...causes decreased vision... vitritis...multiple small whitish lesions...can wax and wane. Given this description, what general class of condition comes to mind?*

**White Dot Syndromes.** When faced with a presumptive WDS pt, always consider whether it might be DUSN!

*White dot syndromes are covered in slide-set R16*

# Q

## Diffuse Unilateral Subacute Neuroretinitis



- *Who is the typical DUSN pt? An otherwise healthy adolescent or young adult*
- *DUSN has two stages--what are they?*
  - 1) In the **acute** stage, pts c/o decreased VA and pain. Exam reveals vitritis, disc edema, and multiple small gray/white retinal lesions. The signs/symptoms will wax and wane.

*Hmm...A condition that strikes young, healthy adults...causes decreased vision... vitritis...multiple small whitish lesions...can wax and wane. Given this description, what general class of condition comes to mind?*


**White Dot Syndromes.** When faced with a presumptive WDS pt, **always consider whether it might be DUSN!**

*Why is it so important to consider DUSN in WDS pts?*

OUS

# A

## Diffuse Unilateral Subacute Neuroretinitis



- *Who is the typical DUSN pt? An otherwise healthy adolescent or young adult*
- *DUSN has two stages--what are they?*
  - 1) In the **acute** stage, pts c/o decreased VA and pain. Exam reveals vitritis, disc edema, and multiple small gray/white retinal lesions. The signs/symptoms will wax and wane.

*Hmm...A condition that strikes young, healthy adults...causes decreased vision... vitritis...multiple small whitish lesions...can wax and wane. Given this description, what general class of condition comes to mind?*


**White Dot Syndromes.** When faced with a presumptive WDS pt, **always consider whether it might be DUSN!**

*Why is it so important to consider DUSN in WDS pts?  
Because if the diagnosis is made at this stage, DUSN can be cured*

OUS

# A

## Diffuse Unilateral Subacute Neuroretinitis




- *Who is the typical DUSN pt? An otherwise healthy adolescent or young adult*
- *DUSN has two stages--what are they?*
  - 1) In the **acute** stage, pts c/o decreased VA and pain. Exam reveals vitritis, disc edema, and multiple small gray/white retinal lesions. The signs/symptoms will wax and wane.

*Hmm...A condition that strikes young, healthy adults...causes decreased vision... vitritis...multiple small whitish lesions...can wax and wane. Given this description, what general class of condition comes to mind?*

**White Dot Syndromes.** When faced with a presumptive WDS pt, **always consider whether it might be DUSN!**

*Why is it so important to consider DUSN in WDS pts? Because if the diagnosis is made at this stage, DUSN can be cured. **But if you fail to diagnosis it, it will proceed inexorably to the untreatable late stage.***

OUS




# Q

## Diffuse Unilateral Subacute Neuroretinitis

- *Who is the typical DUSN pt? An otherwise healthy adolescent or young adult*
- *DUSN has two stages--what are they?*
  - 1) In the **acute** stage, pts c/o decreased VA and pain. Exam reveals vitritis, disc edema, and multiple small gray/white retinal lesions. The signs/symptoms will wax and wane.
  - 2) In **late**-stage disease, the RPE is depigmented, the disc is pallorous and atrophic, and the retinal vessels are attenuated. VA is poor.

*Hmm...A condition involving RPE changes...*




# Q

## Diffuse Unilateral Subacute Neuroretinitis

- *Who is the typical DUSN pt? An otherwise healthy adolescent or young adult*
- *DUSN has two stages--what are they?*
  - 1) In the **acute** stage, pts c/o decreased VA and pain. Exam reveals vitritis, disc edema, and multiple small gray/white retinal lesions. The signs/symptoms will wax and wane.
  - 2) In **late**-stage disease, the RPE is depigmented, the disc is pallorous and atrophic, and the retinal vessels are attenuated. VA is poor.

*Hmm...A condition involving RPE changes...optic disc pallor...*






# Q

## Diffuse Unilateral Subacute Neuroretinitis

- *Who is the typical DUSN pt? An otherwise healthy adolescent or young adult*
- *DUSN has two stages--what are they?*
  - 1) In the **acute** stage, pts c/o decreased VA and pain. Exam reveals vitritis, disc edema, and multiple small gray/white retinal lesions. The signs/symptoms will wax and wane.
  - 2) In **late**-stage disease, the RPE is depigmented, the disc is pallorous and atrophic, and the retinal vessels are attenuated. VA is poor.

*Hmm...A condition involving RPE changes...optic disc pallor...  
attenuated retinal vasculature...*




# Q

## Diffuse Unilateral Subacute Neuroretinitis

- *Who is the typical DUSN pt? An otherwise healthy adolescent or young adult*
- *DUSN has two stages--what are they?*
  - 1) In the **acute** stage, pts c/o decreased VA and pain. Exam reveals vitritis, disc edema, and multiple small gray/white retinal lesions. The signs/symptoms will wax and wane.
  - 2) In **late**-stage disease, the RPE is depigmented, the disc is pallorous and atrophic, and the retinal vessels are attenuated. VA is poor.

*Hmm...A condition involving RPE changes...optic disc pallor...attenuated retinal vasculature...poor vision.*




# Q

## Diffuse Unilateral Subacute Neuroretinitis

- *Who is the typical DUSN pt? An otherwise healthy adolescent or young adult*
- *DUSN has two stages--what are they?*
  - 1) In the **acute** stage, pts c/o decreased VA and pain. Exam reveals vitritis, disc edema, and multiple small gray/white retinal lesions. The signs/symptoms will wax and wane.
  - 2) In **late**-stage disease, the RPE is depigmented, the disc is pallorous and atrophic, and the retinal vessels are attenuated. VA is poor.

*Hmm...A condition involving RPE changes...optic disc pallor... attenuated retinal vasculature...poor vision. Given this description, what specific condition comes to mind?*



# A

## Diffuse Unilateral Subacute Neuroretinitis

- *Who is the typical DUSN pt? An otherwise healthy adolescent or young adult*
- *DUSN has two stages--what are they?*
  - 1) In the **acute** stage, pts c/o decreased VA and pain. Exam reveals vitritis, disc edema, and multiple small gray/white retinal lesions. The signs/symptoms will wax and wane.
  - 2) In **late**-stage disease, the RPE is depigmented, the disc is pallorous and atrophic, and the retinal vessels are attenuated. VA is poor.

*Hmm...A condition involving RPE changes...optic disc pallor... attenuated retinal vasculature...poor vision. Given this description, what specific condition comes to mind?*

**Retinitis pigmentosa.** When faced with a case of 'unilateral RP,' always consider DUSN.