



AMERICAN ACADEMY
OF OPHTHALMOLOGY®

Protecting Sight. Empowering Lives.®

Retinal and Ophthalmic Artery Occlusions Preferred Practice Pattern®

Secretary for Quality of Care
Timothy W. Olsen, MD

Academy Staff
Ali Al-Rajhi, PhD, MPH
Andre Ambrus, MLIS
Meghan Daly
Flora C. Lum, MD

Medical Editor: Susan Garratt

Approved by: Board of Trustees
September 7, 2019

© 2019 American Academy of Ophthalmology®
All rights reserved

AMERICAN ACADEMY OF OPHTHALMOLOGY and PREFERRED PRACTICE PATTERN are registered trademarks of the American Academy of Ophthalmology. All other trademarks are the property of their respective owners.

Preferred Practice Pattern® guidelines are developed by the Academy's H. Dunbar Hoskins Jr., MD Center for Quality Eye Care without any external financial support. Authors and reviewers of the guidelines are volunteers and do not receive any financial compensation for their contributions to the documents. The guidelines are externally reviewed by experts and stakeholders before publication.

Correspondence:
Ali A. Al-Rajhi, PhD, MPH, American Academy of Ophthalmology, P. O. Box 7424, San Francisco, CA 94120-7424. E-mail: aalrajhi@aao.org.

RETINA/VITREOUS PREFERRED PRACTICE PATTERN® DEVELOPMENT PROCESS AND PARTICIPANTS

The **Retina/Vitreous Preferred Practice Pattern® Panel** members wrote the Retinal and Ophthalmic Artery Occlusions Preferred Practice Pattern® (PPP) guidelines. The PPP Panel members discussed and reviewed successive drafts of the document, meeting in person twice and conducting other review by e-mail discussion, to develop a consensus over the final version of the document.

Retina/Vitreous Preferred Practice Pattern Panel 2018–2019

Amani Fawzi, MD, Macula Society Representative
Gurunadh A. Vemulakonda, MD, American Society of Retina Specialists Representative
Ron A. Adelman, MD, MPH, MBA, FACS
Steven T. Bailey, MD, Retina Society Representative
Jennifer I. Lim, MD
Gui-shang Ying, MD, PhD, Methodologist
Christina J. Flaxel, MD, Chair

We thank our partners, the Cochrane Eyes and Vision US Satellite (CEV@US), for identifying reliable systematic reviews that we cite and discuss in support of the PPP recommendations.

The Preferred Practice Patterns Committee members reviewed and discussed the document during a meeting in June 2019. The document was edited in response to the discussion and comments.

Preferred Practice Patterns Committee 2019

Robert S. Feder, MD, Chair
Roy S. Chuck, MD, PhD
Steven P. Dunn, MD
Christina J. Flaxel, MD
Steven J. Gedde, MD
Francis S. Mah, MD
Randall J. Olson, MD
David K. Wallace, MD, MPH
David C. Musch, PhD, MPH, Methodologist

The Retinal and Ophthalmic Artery Occlusions PPP was then sent for review to additional internal and external groups and individuals in July 2019. All those returning comments were required to provide disclosure of relevant relationships with industry to have their comments considered (indicated with an asterisk below). Members of the Retina/Vitreous Preferred Practice Pattern Panel reviewed and discussed these comments and determined revisions to the document.

FINANCIAL DISCLOSURES

In compliance with the Council of Medical Specialty Societies' Code for Interactions with Companies (available at www.cmss.org/codeforinteractions.aspx), relevant relationships with industry are listed. The Academy has Relationship with Industry Procedures to comply with the Code (available at <http://one.aao.org/CE/PracticeGuidelines/PPP.aspx>). A majority (88%) of the members of the Retina/Vitreous Preferred Practice Pattern Panel 2018–2019 had no financial relationship to disclose.

Retina/Vitreous Preferred Practice Pattern Panel 2018–2019

Christina J. Flaxel, MD: No financial relationships to disclose
 Ron A. Adelman, MD, MPH, MBA, FACS: No financial relationships to disclose
 Steven T. Bailey, MD: No financial relationships to disclose
 Amani Fawzi, MD: No financial relationships to disclose
 Jennifer I. Lim, MD: Alcon Laboratories, Genentech, Kodiak Sciences, EyePoint Pharmaceuticals—Consultant/Advisor; Genentech—Lecture Fees
 Gurunadh A. Vemulakonda, MD: No financial relationships to disclose
 Gui-shang Ying, MD, PhD: No financial relationships to disclose

Preferred Practice Patterns Committee 2019

Robert S. Feder, MD, Chair: No financial relationships to disclose
 Roy S. Chuck, MD, PhD: Novartis Pharmaceuticals, Shire—Consultant/Advisor
 Steven P. Dunn, MD: No financial relationships to disclose
 Christina J. Flaxel, MD: No financial relationships to disclose
 Steven J. Gedde, MD: No financial relationships to disclose
 Francis S. Mah, MD: Aerie Pharmaceuticals, Bausch + Lomb, EyePoint Pharmaceuticals, Novartis Pharmaceuticals, Ocular Therapeutix, Shire, Sun Pharmaceuticals—Consultant/Advisor; Bausch + Lomb, Novartis Pharmaceuticals, Shire, Sun Pharmaceuticals—Lecture Fees
 Randall J. Olson, MD: No financial relationships to disclose
 David K. Wallace, MD, MPH: No financial relationships to disclose
 David C. Musch, PhD, MPH, Methodologist: Chengdu Kanghong Biotechnology, IRIDEX, Notal Vision—Consultant/Advisor

Secretary for Quality of Care

Timothy W. Olsen, MD: No financial relationships to disclose

Academy Staff

Ali Al-Rajhi, PhD, MPH: No financial relationships to disclose
 Andre Ambrus, MLIS: No financial relationships to disclose
 Meghan Daly: No financial relationships to disclose
 Flora C. Lum, MD: No financial relationships to disclose

The disclosures of relevant relationships to industry of other reviewers of the document from January to October 2019 are available online at www.aao.org/ppp

TABLE OF CONTENTS

OBJECTIVES OF PREFERRED PRACTICE PATTERN GUIDELINES	P265
METHODS AND KEY TO RATINGS	P266
HIGHLIGHTED FINDINGS AND RECOMMENDATIONS FOR CARE	P267
INTRODUCTION	P268
Disease Definition	P268
Clinical Findings Characteristic of Retinal and Ophthalmic Artery Occlusion	P268
Patient Population	P271
Clinical Objectives	P271
BACKGROUND	P271
Incidence and Prevalence	P271
Risk Factors	P272
Natural History	P272
Rationale for Treatment	P272
CARE PROCESS	P273
Patient Outcome Criteria	P273
Diagnosis	P274
History	P275
Examination	P275
Diagnostic Tests	P276
Management	P277
Medical and Surgical Management	P278
Follow-up Evaluation	P278
Provider and Setting	P279
Counseling and Referral	P279
APPENDIX 1. QUALITY OF OPHTHALMIC CARE CORE CRITERIA	P280
APPENDIX 2. INTERNATIONAL STATISTICAL CLASSIFICATION OF DISEASES AND RELATED HEALTH PROBLEMS (ICD) CODES	P282
LITERATURE SEARCHES FOR THIS PPP	P283
RELATED ACADEMY MATERIALS	P283
REFERENCES	P284

Background:

An ophthalmic artery occlusion (OAO) is a partial or complete obstruction of the ophthalmic artery and may lead to severe ischemia of the affected globe and associated ocular tissues. There is central retinal artery occlusion (CRAO) that cause partial or complete obstruction of the central retinal artery; branch retinal artery occlusion (BRAO) that is a partial or complete obstruction of any of the branch tributaries of the central retinal artery; and arteritic retinal arterial occlusion (RAO) caused by giant cell arteritis. The recommendations of this Preferred Practice Pattern (PPP) are based on Cochrane-identified reliable systematic reviews.

An OAO, CRAO or BRAO can be associated with life-threatening conditions and their incidence increases with age. Risk factors to highlight include cigarette smoking, hypertension, high serum lipid levels, coagulopathy, body mass index, diabetes, and cardiac disease, including atrial fibrillation are all important modifiable risk factors associated with retinal emboli.

Rationale for treatment:

A careful systemic evaluation for any underlying disorder(s) should guide therapy. Specifically, causes of vasculitis that represent an ophthalmologic emergency. Acute, symptomatic OAO, CRAO, and BRAO represent urgent ophthalmic conditions and require prompt evaluation. Due to the high risk of ischemic stroke in cases if ocular arterial occlusions, a prompt referral to a stroke center for a medical evaluation is recommended.

Care Process:

Patient outcome criteria are to improve or stabilize visual function, reduce the risk of severe consequences (e.g., further vision loss, neovascular glaucoma) or cerebral and myocardial infarction, encourage smoking cessation, controlling chronic systematic diseases (e.g., diabetes, hypertension), bring awareness of the patient's retinal disease to their primary care physician, and maintain or improve quality of life. Thus, an initial examination of a patient starts with a careful medical history, which includes any known systemic disease.

Management recommendations are detailed in this PPP, which includes surgical management and follow-up evaluation. Since diabetes is a common contributor to RAO, the ophthalmologist may wish to become familiar with the Diabetic Retinopathy PPP.

OBJECTIVES OF PREFERRED PRACTICE PATTERN® GUIDELINES

As a service to its members and the public, the American Academy of Ophthalmology has developed a series of Preferred Practice Pattern® guidelines that **identify characteristics and components of quality eye care**. Appendix 1 describes the core criteria of quality eye care.

The Preferred Practice Pattern® guidelines are based on the best available scientific data as interpreted by panels of knowledgeable health professionals. In some instances, such as when results of carefully conducted clinical trials are available, the data are particularly persuasive and provide clear guidance. In other instances, the panels have to rely on their collective judgment and evaluation of available evidence.

These documents provide guidance for the pattern of practice, not for the care of a particular individual. While they should generally meet the needs of most patients, they cannot possibly best meet the needs of all patients. Adherence to these PPPs will not ensure a successful outcome in every situation. These practice patterns should not be deemed inclusive of all proper methods of care or exclusive of other methods of care reasonably directed at obtaining the best results. It may be necessary to approach different patients' needs in different ways. The physician must make the ultimate judgment about the propriety of the care of a particular patient in light of all of the circumstances presented by that patient. The American Academy of Ophthalmology is available to assist members in resolving ethical dilemmas that arise in the course of ophthalmic practice.

Preferred Practice Pattern® guidelines are not medical standards to be adhered to in all individual situations. The Academy specifically disclaims any and all liability for injury or other damages of any kind, from negligence or otherwise, for any and all claims that may arise out of the use of any recommendations or other information contained herein.

References to certain drugs, instruments, and other products are made for illustrative purposes only and are not intended to constitute an endorsement of such. Such material may include information on applications that are not considered community standard, that reflect indications not included in approved U.S. Food and Drug Administration (FDA) labeling, or that are approved for use only in restricted research settings. The FDA has stated that it is the responsibility of the physician to determine the FDA status of each drug or device he or she wishes to use, and to use them with appropriate patient consent in compliance with applicable law.

Innovation in medicine is essential to ensure the future health of the American public, and the Academy encourages the development of new diagnostic and therapeutic methods that will improve eye care. It is essential to recognize that true medical excellence is achieved only when the patients' needs are the foremost consideration.

All Preferred Practice Pattern® guidelines are reviewed by their parent panel annually or earlier if developments warrant and updated accordingly. To ensure that all PPPs are current, each is valid for 5 years from the approved by date unless superseded by a revision. Preferred Practice Pattern guidelines are funded by the Academy without commercial support. Authors and reviewers of PPPs are volunteers and do not receive any financial compensation for their contributions to the documents. The PPPs are externally reviewed by experts and stakeholders, including consumer representatives, before publication. The PPPs are developed in compliance with the Council of Medical Specialty Societies' Code for Interactions with Companies. The Academy has Relationship with Industry Procedures (available at www.aao.org/about-preferred-practice-patterns) to comply with the Code.

Appendix 2 contains the International Statistical Classification of Diseases and Related Health Problems (ICD) codes for the disease entities that this PPP covers. The intended users of the Retinal and Ophthalmic Artery Occlusions PPP are ophthalmologists.

METHODS AND KEY TO RATINGS

Preferred Practice Pattern® guidelines should be clinically relevant and specific enough to provide useful information to practitioners. Where evidence exists to support a recommendation for care, the recommendation should be given an explicit rating that shows the strength of evidence. To accomplish these aims, methods from the Scottish Intercollegiate Guideline Network¹ (SIGN) and the Grading of Recommendations Assessment, Development and Evaluation² (GRADE) group are used. GRADE is a systematic approach to grading the strength of the total body of evidence that is available to support recommendations on a specific clinical management issue. Organizations that have adopted GRADE include SIGN, the World Health Organization, the Agency for Healthcare Research and Policy, and the American College of Physicians.³

- ◆ All studies used to form a recommendation for care are graded for strength of evidence individually, and that grade is listed with the study citation.
- ◆ To rate individual studies, a scale based on SIGN¹ is used. The definitions and levels of evidence to rate individual studies are as follows:

I++	High-quality meta-analyses, systematic reviews of randomized controlled trials (RCTs), or RCTs with a very low risk of bias
I+	Well-conducted meta-analyses, systematic reviews of RCTs, or RCTs with a low risk of bias
I-	Meta-analyses, systematic reviews of RCTs, or RCTs with a high risk of bias
II++	High-quality systematic reviews of case-control or cohort studies High-quality case-control or cohort studies with a very low risk of confounding or bias and a high probability that the relationship is causal
II+	Well-conducted case-control or cohort studies with a low risk of confounding or bias and a moderate probability that the relationship is causal
II-	Case-control or cohort studies with a high risk of confounding or bias and a significant risk that the relationship is not causal
III	Nonanalytic studies (e.g., case reports, case series)

- ◆ Recommendations for care are formed based on the body of the evidence. The body of evidence quality ratings are defined by GRADE² as follows:

Good quality	Further research is very unlikely to change our confidence in the estimate of effect
Moderate quality	Further research is likely to have an important impact on our confidence in the estimate of effect and may change the estimate
Insufficient quality	Further research is very likely to have an important impact on our confidence in the estimate of effect and is likely to change the estimate Any estimate of effect is very uncertain

- ◆ Key recommendations for care are defined by GRADE² as follows:

Strong recommendation	Used when the desirable effects of an intervention clearly outweigh the undesirable effects or clearly do not
Discretionary recommendation	Used when the trade-offs are less certain—either because of low-quality evidence or because evidence suggests that desirable and undesirable effects are closely balanced

- ◆ The Highlighted Findings and Recommendations for Care section lists points determined by the PPP Panel to be of particular importance to vision and quality of life outcomes.
- ◆ All recommendations for care in this PPP were rated using the system described above. Ratings are embedded throughout the PPP main text in italics.
- ◆ Literature searches were undertaken in April 2018 and June 2019 in the PubMed database. Complete details of the literature search are available in www.aaopt.org/ppp.

HIGHLIGHTED FINDINGS AND RECOMMENDATIONS FOR CARE

An ophthalmic artery occlusion (OAO), central retinal artery occlusion (CRAO), or, less commonly, a branch retinal artery occlusion (BRAO) can be associated with life-threatening conditions (e.g., carotid occlusive or cardiac valve disease). In patients over 50 years of age, one must additionally suspect giant cell arteritis (GCA) and should consider urgent systemic corticosteroid therapy when GCA is diagnosed or very likely in an attempt to preserve or recover vision in the affected eye and preserve in the contralateral eye.

An OAO or retinal artery occlusion (RAO) occurring in a patient of any age should prompt a systemic evaluation for carotid occlusive and thromboembolic disease. Generally, this would be a workup for vasculitis or hypercoagulability in younger patients (under 50 years old) and an embolic workup in older patients (over 50 years old).

Acute, symptomatic OAO, CRAO, or BRAO from embolic etiologies should prompt an *immediate* referral to the nearest stroke referral center for prompt assessment for consideration of an acute intervention. The precise timing of evaluation for patients with an asymptomatic but newly diagnosed CRAO or BRAO is unclear, though these patients still warrant a timely referral.

In general, there are no proven treatments to reverse the vision loss caused by CRAO, BRAO, or OAO.

In vascular occlusive disorders of the eye, there is an increased risk for posterior and/or anterior segment neovascularization. Patients with greater ischemia require closer and more frequent follow-up. Panretinal photocoagulation (PRP) treatment is recommended for patients who develop iris or retinal neovascularization.

INTRODUCTION

The arterial circulation to the eye involves many branches. Any one of these branches may have impaired flow that results from an obstruction. An embolus, defined as “a solid, liquid or gaseous mass carried by the blood to a site distant from its origin,” can occlude the vessel or lead to thrombus formation (i.e., a blood clot). Inflammation of a retinal vessel wall, or vasculitis, may also lead to an occlusion or thrombus formation. In general, an obstruction of either an ophthalmic or retinal arteriole requires a careful evaluation for systemic diseases. Numerous studies have reported an association between symptomatic retinal artery occlusion (RAO) and stroke.⁴⁻¹²

DISEASE DEFINITION

An ophthalmic artery occlusion (OAO) is a partial or complete obstruction of the ophthalmic artery (branch of the internal carotid artery) and may lead to severe ischemia of the affected globe and associated ocular tissues. A central retinal artery occlusion (CRAO) is a partial or complete obstruction of the central retinal artery, after it branches off from the ophthalmic artery. A branch retinal artery occlusion (BRAO) is a partial or complete obstruction of any of the branch tributaries of the central retinal artery.¹³ Arteritic retinal arterial occlusion (RAO) is caused by giant cell arteritis while most nonarteritic RAO are commonly embolic in origin.

A CRAO is a rare condition that has an incidence of approximately 1 per 100,000 in a U.S. population¹⁴ or 7 to 10 per 100,000 in an entire Korean population over age 65.¹⁵ The incidence likely increases with age,^{14,15} and the mean age at presentation in the United States is the early 60s.¹⁴ CRAOs have also rarely been documented in children.¹⁶ A CRAO commonly leads to retinal ischemia and subsequent retinal cell death.

CLINICAL FINDINGS CHARACTERISTIC OF RETINAL AND OPHTHALMIC ARTERY OCCLUSION

Patients presenting with a CRAO typically describe a sudden, painless decrease in the visual acuity and field of vision in one eye that occurs over a period of seconds.¹⁴ In 1% to 2% of cases, there is a bilateral occurrence.¹⁷ The presenting visual acuity may vary widely, and the patient may or may not have readily visible fundus abnormalities. A deep retinal whitening (i.e., from paracentral acute middle maculopathy [PAMM] with an inner nuclear layer of hyper-reflectivity) may be noted initially before progression to a more complete CRAO.¹⁸ The classic appearance of retinal whitening and a cherry red spot may be absent or very subtle in the early stages, depending largely on the timing of the examination relative to the onset of obstruction. However, within several hours, the classic appearance of retinal whitening with the associated cherry red spot on the foveal center is typical. Retinal whitening is caused by opacification of the swollen, ischemic parafoveal nerve fiber layers.

The cherry red spot is seen because the foveal center, free of nerve fiber layers, transmits the normal coloration of the underlying, unaffected choroid. Hence, the normally perfused tissues appear red against the ischemic background of the nerve fiber layer.

Another key finding is the slow segmental blood flow, referred to as boxcar segmentation, that is observed within the retinal arterioles and veins. Boxcar segmentation of blood in the retinal veins and arteries is best visualized by means of slit-lamp biomicroscopy of the posterior. Approximately 15% to 25% of eyes will have a cilioretinal artery that perfuses a portion of the macula and, thus, spares a portion of the central vision.^{19,20} In a CRAO, there are typically no intraretinal hemorrhages, and the veins will have a normal caliber. This is in contrast to retinal vein occlusion, which is typified by diffuse intraretinal hemorrhages and venous tortuosity and dilation.

In cases of CRAO, the presenting visual acuity in a patient with an acute CRAO tends to be in the range of 20/200 to counting-fingers, yet can be as good as 20/20, depending on the presence of a cilioretinal artery and the degree of obstruction within the artery. In contrast, the presenting visual acuity for an OAO is usually hand motions or worse. This poor visual acuity is due to the location of the obstruction, which is proximal to the branch point of the ciliary arteries that provide flow to the choroid and portions of the optic nerve. Ophthalmic retinal artery occlusions and CRAOs will have a relative afferent pupillary defect that is commensurate with the degree of ischemia.

Over time, an occluded artery will eventually open and begin to reperfuse the retina. However, the visual acuity usually remains poor.²⁰ In vivo measurements of macular and nerve fiber layer thickness in RAO demonstrate that the inner retina thickens acutely, then subsequently thins from ischemia-related atrophy, and the retinal vessels usually remain attenuated in a process that appears to evolve over months.²¹ In some cases, there is a progression from PAMM to more complete inner retinal hyper-reflectivity.^{18,22} Iris neovascularization may develop in about 20% of cases of CRAO, and as soon as one week, but typically within 30-60 days, following a CRAO. The incidence or neovascularization, and the rapidity of its onset, is likely related to the level of overall ocular and retinal ischemia.²³

Cilioretinal artery occlusions may accompany a central retinal vein occlusion (CRVO). The cilioretinal artery occlusion occurs as a result of increased intravascular retinal venous pressure combined with the lower mean choroidal arterial pressure relative to the mean retinal arterial pressure. In cilioretinal arteries, the arterial flow originates from the short posterior ciliary arteries rather than from the central retinal artery. The lower intravascular arterial perfusion pressure in the cilioretinal artery is the result of multiple collateral flow channels that are present within the choroidal circulation. When the retinal venous circulation is occluded, flow through the cilioretinal artery is more easily impeded as a result of higher outflow resistance. Also, the ciliary circulation lacks the autoregulatory mechanism of the retinal circulation that compensates for changes in the intravascular pressure. Instead, the choroidal circulation is largely regulated by sympathetic innervation.²⁴

The combination of a CRAO or BRAO with a CRVO is rare; it usually is an indicator of an active systemic disease or it may occur in the setting of a retrobulbar hemorrhage.²⁵ Other etiologies include autoimmune disorders,²⁶ malignancies, blood dyscrasias, leukemia, and superior thoracic inlet lesions.²⁷ Patients with this combination of obstructions will generally have both dilated and tortuous veins, along with intraretinal hemorrhages in conjunction with broad areas of retinal ischemia, infarction, poor visual function, a poor prognosis, and a high risk (80%) of neovascular glaucoma.²⁵

Platelet-fibrin-cholesterol emboli (Hollenhorst plaques) are common emboli responsible for RAOs. Emboli can appear either within a vessel of similar caliber or at an arterial bifurcation. Commonly, these plaques originate from the carotid arteries, heart valves, or the aortic arch. Rare calcified emboli may originate from calcified cardiac valves. The presence of asymptomatic Hollenhorst plaques should prompt a nonurgent workup for systemic atheromatous disease.

Ophthalmic artery occlusions are usually located proximal to both the branch point of the general posterior ciliary arteries (choroidal supply) and central retinal artery (retinal supply). (See Figure 1.) In a patient with an OAO, the central retinal artery and ciliary arteries that supply blood flow to the choroid are obstructed, and vision is profoundly reduced. On funduscopic examination, a cherry red spot may not be detected because both the choroid and the retinal circulations are ischemic, with little vascular flow to the entire retina, including the foveal region (See Figure 2.). When the circulation of the optic disc is involved, there may be optic disc edema. A fluorescein angiogram will help demonstrate both retinal vascular occlusion as well as broad areas of choroidal nonperfusion. A dark ring of both choroidal and retinal nonperfusion may be seen surrounding the optic nerve in OAO as well as lobular or triangular areas of patchy choroidal nonperfusion (as is seen with giant cell arteritis [GCA]). The posterior pole or peripheral areas of triangular ischemia, also referred to as Amalric's triangle, is a reflection of the choroidal vascular flow distribution.

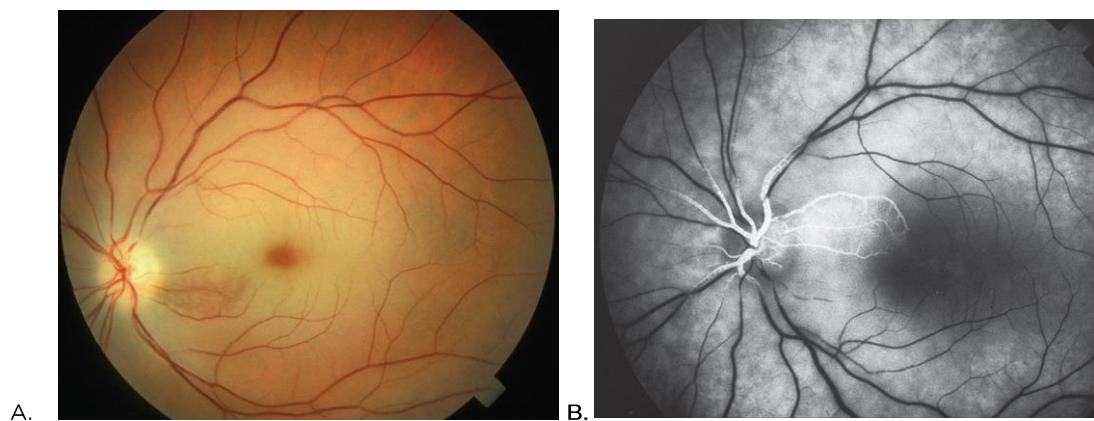


FIGURE 1. Central retinal artery occlusion (CRAO). A. Fundus photograph shows superficial macular opacification and a cherry-red spot in the foveola. B. Angiography image reveals preservation of a sector of superonasal macula related to cilioretinal vessels perfused in this image. The patient had hands motions visual acuity. (Courtesy of Hermann D. Schubert, MD. Adapted with permission from the American Academy of Ophthalmology Basic and Clinical Science Course Subcommittee. Basic and Clinical Science Course. Retina and Vitreous: Section 12, 2018-2019. San Francisco, CA: American Academy of Ophthalmology; 2018)

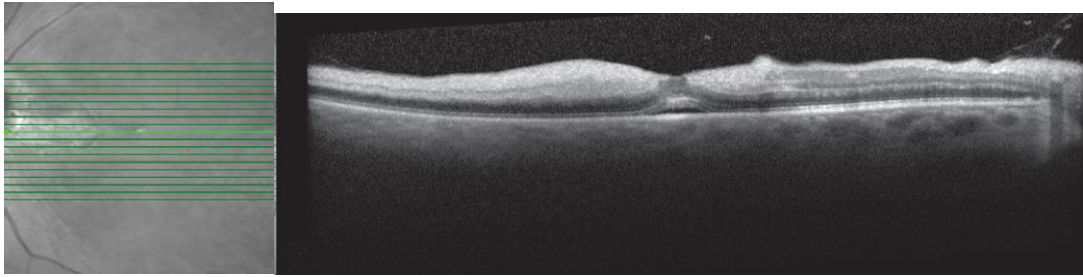


FIGURE 2. SD-OCT Scan of a case of CRAO similar to the one shown in Figure 1 with cilioretinal artery sparing shows hyperreflectivity in the area of clinical opacification of the inner two-thirds of the retina in the affected areas (X). All retinal layers are identifiable in the area of retina perfused by the cilioretinal artery, adjacent to the optic nerve head. The retina in the fovea is spared from opacification, resulting in the appearance of a cherry-red spot on the examination. Subfoveal fluid (asterisk) is variably present in these cases. (Courtesy of Colin A. McCannel, MD. Adapted with permission from the American Academy of Ophthalmology Basic and Clinical Science Course Subcommittee. Basic and Clinical Science Course. Retina and Vitreous: Section 12, 2018-2019. San Francisco, CA: American Academy of Ophthalmology; 2018).

PATIENT POPULATION

The incidence of RAOs increases with age.¹⁵ The incidence patterns for CRAO and stroke are similar; incidence increases with age (peaking near age 80) and occurs more frequently in men.²⁸

CLINICAL OBJECTIVES

- ◆ Identify patients at risk for developing RAO
- ◆ Reduce the risk of severe ocular consequences (e.g., further vision loss, neovascular glaucoma) or systemic conditions (e.g., cerebral and myocardial infarction)
- ◆ Optimize RAO risk factors, including smoking cessation, systemic blood pressure, and diabetes as well as other systemic risk factors (e.g., hyperlipidemia and cardiovascular disease)
- ◆ Monitor for signs of retinal or anterior segment angiogenesis that lead to further complications, such as vitreous hemorrhage or neovascular glaucoma
- ◆ Provide or refer for visual rehabilitation services when a patient has visual impairment from the disease

BACKGROUND

INCIDENCE AND PREVALENCE

According to U.S. epidemiologic data from Olmsted County, Minnesota, the incidence of developing a CRAO is approximately 1 per 100,000.²⁹ Similarly, the incidence reported from Korea was 7 to 10 cases per 100,000 among individuals aged 65 to 89 years, increasing with age.¹⁵

Branch retinal artery occlusions are also uncommon. In an Australian study of 3654 subjects over 49 years of age screened by means of a detailed eye examination, asymptomatic retinal emboli were present in about 1.4% of the population (95% confidence interval [CI] = 1.0–1.8), increasing with

age.³⁰ In the 10-year follow-up of this cohort from the Blue Mountains Eye Study, the incidence of retinal emboli increased to a 3% risk in the 1952 10-year survivors.³¹ Age was the key risk factor and there was not a significant gender predilection.

RISK FACTORS

Cigarette smoking, hypertension, body mass index, high serum lipid levels, diabetes, coagulopathy and cardiac disease, including atrial fibrillation are all important modifiable risk factors associated with retinal emboli.^{6,325,9,33-35}

NATURAL HISTORY

Central RAOs are commonly due to vascular embolic obstruction. One study reviewed a large number of ocular vascular occlusive cases and described varying degrees of recovery resulting from the inclusion of treatment for cases of giant cell arteritis.³⁶ The reported recovery rate is in contrast to the rate of less than 10% for nonarteritic CRAO patients who experienced any meaningful recovery of vision.³⁷

RATIONALE FOR TREATMENT

A careful systemic evaluation for any underlying disorder(s) should guide therapy. Specifically, causes of vasculitis, such as GCA, represent an ophthalmologic emergency. GCA typically affects Caucasians over 50 years of age with clinical findings of optic disc swelling, CRAO, and absence of emboli. Often, there is history of temporal tenderness, jaw claudication, weight loss, proximal myalgia, or fever. C-reactive protein (CRP) and/or erythrocyte sedimentation rate (ESR) are typically elevated. In cases of GCA, prompt initiation of systemic corticosteroid therapy is critical to prevent vision loss in the fellow eye or vascular occlusion elsewhere.^{38,39}

Acute, symptomatic OAO, CRAO, and BRAO represent urgent ophthalmic conditions and require prompt evaluation. Such occlusions may represent an important clinical indicator of an embolic, inflammatory, infectious, or other process that may require a systemic medical evaluation that is both urgent and targeted to the patient's presentation and medical history. In most cases of CRAO, a prompt referral to a stroke center for a medical evaluation is recommended because the risk of ischemic stroke is high during the first 1 to 4 weeks, ranging from 3 - 6% in two studies.^{28,35} The incidence of concurrent stroke has been found to be 20-24% in two retrospective studies.^{11,40} One of these studies identified via diffusion weighted magnetic resonance imaging, but not brain computed tomography, acute cortical lesions in subjects imaged within 7 days of ocular presentation.⁴¹ 112 consecutive patients with acute RAO (either with transient or fixed symptoms) were evaluated prospectively in a single center, and all underwent MRI brain acutely (within 24 hours) The majority (77/112) had CRAO or BRAO confirmed by ophthalmologic exam. Silent brain infarction, as evidenced by DWI abnormalities, was present in 19% of CRAO and 25% of BRAO subjects. This

rate is similar to what is seen in patients with amaurosis or cerebral hemispheric TIA in other studies. Thus, a recommendation for urgent workup is warranted.⁴²

The rationale for acute management of an RAO is very limited. Current evidence for effective interventional treatment for the ocular condition, other than corticosteroids for GCA, is controversial and limited to level II data. Thrombolytic or interventional treatments that attempted to preserve or recover vision in CRAO or BRAO have never been proven to be effective.⁴³⁻⁴⁵ The use of hyperbaric oxygen therapy (100% oxygen over 9 hours) has demonstrated efficacy over observation alone in several small randomized trials.⁴⁶

At present, only one-third of ophthalmologists transfer patients with incident CRAO to an emergency department for immediate evaluation.²⁸ Growing evidence recommends that acute RAO (symptoms within 24 hours) be treated as a medical emergency and be referred immediately to an emergency department or stroke center facility for neurological evaluation because of the increased risk of central nervous system stroke.^{28,35} Up to 24% of these patients have concurrent cerebrovascular accident on diffusion weighted MRI.^{11,40,42} Additionally, a new significant systemic cardiovascular condition (typically clinically significant carotid stenosis) is discovered in up to 70% of patients with symptomatic CRAO.⁶ A patient with symptomatic RAO should be referred for an urgent evaluation within 1 week's onset because the risk of stroke is highest within the first 7 days and remains elevated for 30 days.^{42,47} Silent brain infarction is a frequent finding in unselected patients with acute BRAO/CRAO or amaurosis fugax, and these silent infarctions bear a high risk for future stroke. These patients should undergo prompt referral to a stroke center.⁴⁷

Panretinal photocoagulation (PRP) with or without anti-vascular endothelial growth factor (anti-VEGF) therapy is recommended for patients who develop iris or retinal neovascularization.⁴⁸ Although PRP will not improve the visual acuity or field of vision, it will likely decrease VEGF production and subsequent progression to iris neovascularization and neovascular glaucoma. In acute cases, the provider may elect to initiate treatment with an intravitreal anti-VEGF agent (off-label indication) to supplement or to help facilitate PRP treatment.⁴⁹

CARE PROCESS

PATIENT OUTCOME CRITERIA

Patient outcome criteria include the following:

- ◆ Improvement or stabilization of visual function
- ◆ Improvement or stabilization of vision-related quality of life
- ◆ Reduction of the risk of severe consequences (e.g., further vision loss, neovascular glaucoma) or cerebral and myocardial infarction
- ◆ Identification of life-threatening conditions (e.g., GCA, carotid occlusive or cardiac valve disease)
- ◆ Encouragement to cease smoking

- ◆ Identification or optimization of control of chronic systemic diseases (e.g., diabetes, hypertension, lipid disorders)
- ◆ Establishment of effective communication with the patient's primary care physician about the status of the retinal disease and its relation to systemic disease

DIAGNOSIS

The initial examination of a patient includes all aspects of a comprehensive medical eye evaluation,⁵⁰ with particular attention to those aspects relevant to retinal vascular disease.

The investigation should begin with a careful medical history, including any known systemic disease, combined with a careful review of systems for embolic disease (e.g., transient ischemic symptoms, lateralizing weakness, paresthesias). Also, a careful history should help the clinician direct the evaluation. Documenting the patient's demographics, underlying systemic disease, as well as social (e.g., smoking) and family history are important. In particular, the ophthalmologist needs to recognize symptoms associated with GCA (e.g., vision loss, headaches, scalp tenderness, malaise, fatigue, temporal tenderness, jaw claudication, weakness, fever, diplopia, history of polymyalgia rheumatica), especially in patients over age 50. An immediate erythrocyte sedimentation rate, C-reactive protein, and complete blood count with platelets⁵¹ should be obtained from a patient with GCA symptoms.^{52,53}

Patients with GCA who are also diabetic should be monitored carefully in this situation since systemic corticosteroid treatment may destabilize glucose control. Once a diagnosis of an acute, symptomatic CRAO, BRAO, or OAO has been made, the ophthalmologist should refer to a stroke center [www.strokecenter.org/trials/centers] when one is available for prompt systemic evaluation of the patient (see Management section). The goals are twofold, first, to search for potential associated systemic disease(s) and, second, to determine specifically whether the patient is at risk for a subsequent stroke or myocardial infarction. An emergency department is the next option for an urgent evaluation, with clear instructions that the patient has experienced an eye "stroke." An expedited workup offers the best opportunity to evaluate, assess, and manage the risk for cerebral stroke or myocardial infarction. A central nervous system infarction is defined as brain, spinal cord, or retinal cell death attributable to ischemia, based on neuropathological neuroimaging and/or clinical evidence of permanent injury.⁵⁴ At present, there is no conclusive evidence to support referring asymptomatic patients who have a BRAO for an expedited stroke workup.

Experts appointed by the American Heart Association suggest that for patients presenting with symptomatic RAO a critical initial systemic evaluation be performed at the nearest acute stroke-ready hospital or stroke center.³⁴ In general, older individuals presenting with an RAO should also be evaluated for atheromatous and embolic vascular etiologies. Patients 50 years or older should undergo a workup for embolic sources.⁵⁵ In the absence of a clear etiology such as an embolus, the workup should include an evaluation for antiphospholipid antibodies and other hematologic diatheses, and autoimmune or other hypercoagulable states.⁵ For example, Susac syndrome should be considered in younger patients presenting with multiple or recurrent BRAOs.⁵⁶ This syndrome has a triad of hearing

loss (usually low frequency), central nervous system lesions (especially of the corpus callosum), and BRAOs. The clinician should also inquire about the signs or symptoms of vascular compromise associated with a carotid dissection (e.g., neck or face pain following recent trauma).

Poor choroidal circulation on fluorescein angiography or Indocyanine Green Angiography is suggestive of OAO. A major ophthalmic arterial obstruction may represent the initial manifestation of a systemic or embolic process that may subsequently involve the central nervous system or other organ systems.^{9,57} Stroke risk associated with newly diagnosed OAO, CRAO, or BRAO may be as high as 25%.^{4,11,35,47}

History

An initial history for retinal and ophthalmic artery occlusion should consider the following elements:

- ◆ Duration of vision loss
- ◆ Symptoms of GCA (e.g., vision loss, headaches, scalp tenderness, malaise, fatigue, temporal tenderness, jaw claudication, weakness, fever, myalgia, and diplopia)
- ◆ Medications
- ◆ Family history of cardiovascular disease, diabetes, systemic hypertension, or hyperlipidemia
- ◆ Medical history (e.g., systemic hypertension, diabetes, hyperlipidemia, cardiovascular disease, hemoglobinopathy, and polymyalgia rheumatica) or drug history (e.g., cocaine)
- ◆ Ocular history (e.g., trauma, other eye diseases, ocular injections, surgery)
- ◆ Social history (e.g., smoking)

Examination

The initial examination should include the following elements:

- ◆ Visual acuity
- ◆ Slit-lamp biomicroscopy
- ◆ Intraocular pressure
- ◆ Gonioscopy when neovascularization of the iris is present or suspected, or when the intraocular pressure is elevated. Neovascularization of the iris or the anterior chamber angle is best recognized prior to dilation, can rarely be seen in an acute arterial occlusion, and can occur up to 4 months later.
- ◆ Relative afferent pupil defect assessment
- ◆ Fundoscopy:
 - ◆ Slit-lamp biomicroscopy of the posterior pole

- ◆ Examination of the peripheral retina using indirect ophthalmoscopy through a dilated pupil. This is necessary to assess for the following features that are often associated with severe vision loss:
 - Retinal hemorrhages
 - Cotton wool spots
 - Retinal emboli
 - Retinal vascular “boxcarring”
 - Optic disc neovascularization and/or neovascularization elsewhere

Diagnostic Tests

A number of tests ancillary to the clinical examination may be considered, but they should not delay transfer to a stroke center in cases of acute, nonarteritic RAO. The most common tests include the following:

- ◆ Color and red-free fundus photography
- ◆ OCT
- ◆ Fluorescein angiography
- ◆ Indocyanine green angiography
- ◆ Ultrasonography in the setting of significant media opacity (to rule out other acute causes of vision loss such as retinal detachment)

Color Fundus Photography

Fundus photography is useful for documenting the severity of the retinal findings, vascular caliber, retinal hemorrhages, the presence and characteristics of intravascular emboli, and the presence of any new vessels in the retina or near the optic disc.

Optical Coherence Tomography

Optical coherence tomography provides high-resolution imaging of the retinal anatomy and thickness and of the vitreoretinal interface, and it detects other forms of macular disease in patients with RAO. In acute RAO, the first sign may be PAMM. Thickening and increased inner retinal reflectivity may be present, followed by inner retinal thinning in chronic RAO.⁵⁸

Fluorescein and Indocyanine Green Angiography

Fluorescein or indocyanine green (ICG) angiography may help demonstrate alterations in the arterial and choroidal flow patterns that may include delays in flow and ischemia, and also document the extent of retinal vasculature involvement. The ICG angiogram may be more useful for visualizing choroidal circulation, especially in a patient with GCA. The infrared absorption and emission characteristics of the ICG dye enable deeper imaging that may be

blocked on fluorescein angiography. The fluorescein angiogram helps to differentiate the origin and extent, especially of the RAO(s).

Although fluorescein angiography remains a valuable tool for physicians who diagnose and treat patients with retinal vascular disease, there are potential risks associated with the procedure. Severe medical complications may occur, including death, which has been reported in approximately 1 per 200,000 patients.⁵⁹ Fluorescein dye crosses the placenta into the fetal circulation,⁶⁰ yet detrimental effects of fluorescein dye on a fetus have not been documented.

Ultrasonography

Ultrasonography may be helpful to assess the anatomic status of the retina in the presence of a significant vitreous hemorrhage or other media opacity.

MANAGEMENT

Acute, symptomatic, posterior segment arterial occlusions represent an emergent ophthalmic condition⁶¹ and require prompt evaluation. They may be partial or complete, depending on whether there is evidence of blood flow.⁶² These vascular occlusions may represent an important clinical indicator of a more severe systemic disorder or of an embolic, inflammatory, infectious, or other process that may require a systemic medical evaluation that is both urgent and targeted to the patient as well as to his or her presentation and medical history. Immediate referral to a stroke center for a medical evaluation is advised. If a stroke center is not available, an emergency room is the next option.

In general, there are no proven therapies or treatments for symptomatic artery occlusions. There are case reports, small case series, and uncontrolled studies that suggest that several potential interventions may be helpful. However, there are no level I data to support any single specific therapy. Initial treatment of an acute CRAO may include digital massage, anterior chamber paracentesis, vasodilation, breathing into a paper bag, carbogen therapy, topical pressure-lowering therapies, or hyperbaric chambers. The rates of silent cerebral ischemia in RAO is the same as in hemispheric TIA, and the recommendation from multiple clinical trials is that TIA be worked up as stroke in the acute phase. Given the expected similarity of pathogenesis, RAO patients should be considered in the same way.⁴² None of these interventions has demonstrated significant benefit when compared to with the natural history of the disorder. In fact, recent metanalysis suggests that eyes receiving conservative therapy do worse than controls.⁶³ More aggressive treatments, such as thrombolysis or transluminal neodymium yttrium-aluminum-garnet (Nd:YAG) laser embolysis, have associated risks and cannot be currently recommended in the absence of strong evidence-based data.⁶⁴⁻⁶⁶

Both intra-arterial and intravenous thrombolytics have been investigated.^{67,68} However, there remains strong controversy about the best management strategy. There are meaningful limitations to establishing a reliable study design for such trials, especially given the complexity in disease variables and timing for intervention. Also, the low incidence of symptomatic arterial occlusions, especially

within optimal time constraints, limits enrollment of patients for interventional studies. The need for systemic testing and prompt intervention creates urgency and severely limits the study design.⁶⁴ At this point, there is insufficient evidence to support intra-arterial antifibrinolytic therapy for CRAO.⁴⁵

Physicians who manage a cilioretinal artery occlusion should first consider GCA in patients over 50 years of age. Alternatively, if there is an embolus involved with the cilioretinal circulation, a systemic evaluation similar to that for a CRAO should be initiated.

The patient with concomitant retinal artery and vein occlusions should be followed for the development of anterior segment neovascularization.⁴⁸

When ocular neovascularization is present, prompt PRP is indicated. The off-label use of intravitreal anti-VEGF agents may be helpful to optimize visualization when hyphemia or vitreous hemorrhage are present limiting visibility for PRP, and to minimize treatment-related complications such as macular edema that may follow complete PRP. Off-label anti-VEGF injections may help facilitate the laser application. When a vitreous hemorrhage is present that limits the view for laser application, temporizing anti-VEGF injections may be considered before pars plana vitrectomy.

As with a CRAO, multiple treatments for BRAO have been proposed; however, there are currently insufficient data to demonstrate any conclusive benefits from intervention beyond the natural history of the disease.⁶⁹ When presented with an asymptomatic BRAO, the most important approach for the clinician is to conduct a systemic evaluation that includes a careful medical history and an assessment for systemic disease, preferably in conjunction with the patient's internist.

For symptomatic carotid disease with more than a 70% carotid artery occlusion, an endarterectomy has demonstrated a better outcome than medical therapy.^{5,70-72} When the carotid occlusion is between 50% and 70%, the value of endarterectomy is less certain.^{5,73} The role of imaging for active carotid disease and subsequent therapy is currently evolving.

In general, antiplatelet and statin therapies will apply to the vast majority of affected patients. Carotid surgery will apply to less than 30% of patients.^{11,47,73}

Medical and Surgical Management

Panretinal photocoagulation is occasionally required in RAO and may be postponed until neovascularization is detected. However, in the presence of anterior segment neovascularization, and especially when neovascular glaucoma occurs, prompt laser PRP or anti-VEGF therapy with prompt or delayed PRP should be performed.

Follow-up Evaluation

The follow-up evaluation includes a history and examination.

History

A follow-up history should include changes in the following:

- ◆ Symptoms (e.g., change in vision, visual field loss, pain)
- ◆ Systemic condition (e.g., elevated blood pressure, systemic arterial hypertension, hypercholesterolemia, hyperglycemia/diabetes)

Examination

- ◆ Visual acuity⁷⁴
- ◆ Slit-lamp biomicroscopy with iris examination⁷⁵
- ◆ Intraocular pressure
- ◆ Undilated gonioscopy for iris neovascularization, especially when the intraocular pressure is elevated⁷⁵
- ◆ Biomicroscopic examination of the posterior pole after dilation of the pupils⁷⁶
- ◆ Peripheral retina and vitreous examination, when indicated⁷⁷
- ◆ OCT imaging, when appropriate
- ◆ Fluorescein angiography

PROVIDER AND SETTING

Although the ophthalmologist will perform most of the examination and all ocular surgery, trained individuals under the ophthalmologist's supervision and review may perform certain aspects of data collection, such as imaging. Because diabetes is a common contributor to RAO, the ophthalmologist caring for patients with this condition may wish to become familiar with the Diabetic Retinopathy PPP.⁷⁸

COUNSELING AND REFERRAL

A patient with an asymptomatic BRAO could be referred to a primary care physician for evaluation and management of relevant systemic condition(s). Acute, symptomatic patients with RAO or GCA should immediately be referred to a cardiologist, emergency room, or stroke center at presentation.⁷⁹ Examination results should be communicated promptly to the physician(s) managing the patient. An Eye MD Examination Report Form is available from the American Academy of Ophthalmology.⁸⁰ Because many of the recommendations are based on limited data, additional research on treatment of acute ischemic stroke³⁴ and RAO is needed.

Many patients with RAO or OAO will lose substantial vision despite various treatment options. Patients who fail to respond and those for whom further treatment is unavailable should be provided with proper professional support and considered for referrals for counseling, vision rehabilitation, or social services as appropriate.⁸¹ Patients with functionally limiting postoperative visual impairment should be considered for referral for vision rehabilitation and social services.^{81,82} More information on vision rehabilitation, including materials for patients, is available at www.aao.org/low-vision-and-vision-rehab.

APPENDIX 1. QUALITY OF OPHTHALMIC CARE CORE CRITERIA

*Providing quality care
is the physician's foremost ethical obligation, and is
the basis of public trust in physicians.*

AMA Board of Trustees, 1986

Quality ophthalmic care is provided in a manner and with the skill that is consistent with the best interests of the patient. The discussion that follows characterizes the core elements of such care.

The ophthalmologist is first and foremost a physician. As such, the ophthalmologist demonstrates compassion and concern for the individual, and utilizes the science and art of medicine to help alleviate patient fear and suffering. The ophthalmologist strives to develop and maintain clinical skills at the highest feasible level, consistent with the needs of patients, through training and continuing education. The ophthalmologist evaluates those skills and medical knowledge in relation to the needs of the patient and responds accordingly. The ophthalmologist also ensures that needy patients receive necessary care directly or through referral to appropriate persons and facilities that will provide such care, and he or she supports activities that promote health and prevent disease and disability.

The ophthalmologist recognizes that disease places patients in a disadvantaged, dependent state. The ophthalmologist respects the dignity and integrity of his or her patients, and does not exploit their vulnerability.

Quality ophthalmic care has the following optimal attributes, among others.

- ◆ The essence of quality care is a meaningful partnership relationship between patient and physician. The ophthalmologist strives to communicate effectively with his or her patients, listening carefully to their needs and concerns. In turn, the ophthalmologist educates his or her patients about the nature and prognosis of their condition and about proper and appropriate therapeutic modalities. This is to ensure their meaningful participation (appropriate to their unique physical, intellectual and emotional state) in decisions affecting their management and care, to improve their motivation and compliance with the agreed plan of treatment, and to help alleviate their fears and concerns.
- ◆ The ophthalmologist uses his or her best judgment in choosing and timing appropriate diagnostic and therapeutic modalities as well as the frequency of evaluation and follow-up, with due regard to the urgency and nature of the patient's condition and unique needs and desires.
- ◆ The ophthalmologist carries out only those procedures for which he or she is adequately trained, experienced and competent, or, when necessary, is assisted by someone who is, depending on the urgency of the problem and availability and accessibility of alternative providers.
- ◆ Patients are assured access to, and continuity of, needed and appropriate ophthalmic care, which can be described as follows.
 - ◆ The ophthalmologist treats patients with due regard to timeliness, appropriateness, and his or her own ability to provide such care.
 - ◆ The operating ophthalmologist makes adequate provision for appropriate pre- and postoperative patient care.
 - ◆ When the ophthalmologist is unavailable for his or her patient, he or she provides appropriate alternate ophthalmic care, with adequate mechanisms for informing patients of the existence of such care and procedures for obtaining it.
 - ◆ The ophthalmologist refers patients to other ophthalmologists and eye care providers based on the timeliness and appropriateness of such referral, the patient's needs, the competence and qualifications of the person to whom the referral is made, and access and availability.
 - ◆ The ophthalmologist seeks appropriate consultation with due regard to the nature of the ocular or other medical or surgical problem. Consultants are suggested for their skill, competence, and accessibility.

They receive as complete and accurate an accounting of the problem as necessary to provide efficient and effective advice or intervention, and in turn respond in an adequate and timely manner.

- ◆ The ophthalmologist maintains complete and accurate medical records.
- ◆ On appropriate request, the ophthalmologist provides a full and accurate rendering of the patient's records in his or her possession.
- ◆ The ophthalmologist reviews the results of consultations and laboratory tests in a timely and effective manner and takes appropriate actions.
- ◆ The ophthalmologist and those who assist in providing care identify themselves and their profession.
- ◆ For patients whose conditions fail to respond to treatment and for whom further treatment is unavailable, the ophthalmologist provides proper professional support, counseling, rehabilitative and social services, and referral as appropriate and accessible.
- ◆ Prior to therapeutic or invasive diagnostic procedures, the ophthalmologist becomes appropriately conversant with the patient's condition by collecting pertinent historical information and performing relevant preoperative examinations. Additionally, he or she enables the patient to reach a fully informed decision by providing an accurate and truthful explanation of the diagnosis; the nature, purpose, risks, benefits, and probability of success of the proposed treatment and of alternative treatment; and the risks and benefits of no treatment.
- ◆ The ophthalmologist adopts new technology (e.g., drugs, devices, surgical techniques) in judicious fashion, appropriate to the cost and potential benefit relative to existing alternatives and to its demonstrated safety and efficacy.
- ◆ The ophthalmologist enhances the quality of care he or she provides by periodically reviewing and assessing his or her personal performance in relation to established standards, and by revising or altering his or her practices and techniques appropriately.
- ◆ The ophthalmologist improves ophthalmic care by communicating to colleagues, through appropriate professional channels, knowledge gained through clinical research and practice. This includes alerting colleagues of instances of unusual or unexpected rates of complications and problems related to new drugs, devices or procedures.
- ◆ The ophthalmologist provides care in suitably staffed and equipped facilities adequate to deal with potential ocular and systemic complications requiring immediate attention.
- ◆ The ophthalmologist also provides ophthalmic care in a manner that is cost effective without unacceptably compromising accepted standards of quality.

Reviewed by: Council
Approved by: Board of Trustees
October 12, 1988

2nd Printing: January 1991

3rd Printing: August 2001

4th Printing: July 2005

APPENDIX 2. INTERNATIONAL STATISTICAL CLASSIFICATION OF DISEASES AND RELATED HEALTH PROBLEMS (ICD) CODES

Retinal arterial occlusion, which include entities with the following ICD-10 classifications:

	ICD-10 CM
Central retinal artery occlusion	H34.11
	H34.12
	H34.13
Arterial branch occlusion	H34.231
	H34.232
	H34.233
Partial retinal artery occlusion	H34.211
	H34.212
	H34.213
Transient retinal artery occlusion	H34.01
	H34.02
	H34.03

ICD = International Classification of Diseases; CM = Clinical Modification used in the United States

Additional information:

- For bilateral sites, the final character of the codes in the ICD-10 CM indicates laterality. If no bilateral code is provided and the condition is bilateral, separate codes for both the left and right side should be assigned. Unspecified codes should be used only when there is no other code option available.
- When the diagnosis code specifies laterality, regardless of which digit it is found in (i.e., 4th digit, 5th digit, or 6th digit):
 - Right is always 1
 - Left is always 2
 - Bilateral is always 3

LITERATURE SEARCHES FOR THIS PPP

Literature searches of the PubMed and Cochrane databases were conducted in April 2018; the search strategies are provided at www.aao.org/ppp. Specific limited update searches were conducted after June 2019.

(retinal artery occlusion/pathology[majr] OR retinal artery occlusion/physiology[majr] OR retinal artery occlusion/physiopathology[majr])

(retinal artery occlusion/surgery[mh] OR retinal artery occlusion/therapy[mh] OR retinal artery occlusion/drug therapy[mh])

(retinal artery occlusion/diagnosis[MeSH Major Topic])

("retinal artery occlusion"[MeSH Major Topic] OR "retinal artery occlusion"[tiab]) AND (risk[tiab] OR risk factors[mh]) OR Retinal Artery Occlusion/complications[mh]

retinal artery occlusion[majr] AND (Cost-Benefit Analysis[mh] OR Cost of Illness[mh] OR economics[MeSH Terms] OR cost[All Fields] OR cost[MeSH Terms])

RELATED ACADEMY MATERIALS

Basic and Clinical Science Course

Retina and Vitreous (Section 12, 2019–2020)

Focal Points

Retinal Arterial Occlusions (2010)

Patient Education

Face-Down Recovery After Retinal Surgery Brochure (2014)

Retina Informed Consent Video Collection (2013)

Preferred Practice Pattern® Guidelines – Free download available at www.aao.org/ppp.

Comprehensive Adult Medical Eye Evaluation (2015)

To order any of these products, except for the free materials, please contact the Academy's Customer Service at 866.561.8558 (U.S. only) or 415.561.8540 or www.aao.org/store.

REFERENCES

1. Scottish Intercollegiate Guidelines Network (SIGN). *SIGN 50: a guideline developer's handbook*. Edinburgh: SIGN; 2015. (SIGN publication no. 50). [November 2015]. Available from URL: <http://www.sign.ac.uk>.
2. Guyatt GH, Oxman AD, Vist GE, et al. GRADE: an emerging consensus on rating quality of evidence and strength of recommendations. *BMJ*. 2008;336(7650):924-926.
3. GRADE Working Group. Organizations that have endorsed or that are using GRADE. <http://www.gradeworkinggroup.org/>. Accessed September 2019.
4. Avery MB, Magal I, Kherani A, Mitha AP. Risk of Stroke in Patients With Ocular Arterial Occlusive Disorders: A Retrospective Canadian Study. *J Am Heart Assoc*. 2019;8(3):e010509.
5. Kernan WN, Ovbiagele B, Black HR, et al. American Heart Association Stroke Council, Council on Cardiovascular and Stroke Nursing, Council on Clinical Cardiology, and Council on Peripheral Vascular Disease. Guidelines for the prevention of stroke in patients with stroke and transient ischemic attack: a guideline for healthcare professionals from the American Heart Association/American Stroke Association. *Stroke*. 2014;45(7):2160-2236.
6. Callizo J, Feltgen N, Pantenburg S, et al. Cardiovascular Risk Factors in Central Retinal Artery Occlusion: Results of a Prospective and Standardized Medical Examination. *Ophthalmology*. 2015;122(9):1881-1888.
7. Mir TA, Arham AZ, Fang W, et al. Acute Vascular Ischemic Events in Patients With Central Retinal Artery Occlusion in the United States: A Nationwide Study 2003-2014. *Am J Ophthalmol*. 2019;200:179-186.
8. Zhou Y, Zhu W, Wang C. Relationship between retinal vascular occlusions and incident cerebrovascular diseases: A systematic review and meta-analysis. *Medicine (Baltimore)*. 2016;95(26):e4075.
9. Hayreh SS, Podhajsky PA, Zimmerman MB. Retinal artery occlusion: associated systemic and ophthalmic abnormalities. *Ophthalmology*. 2009;116(10):1928-1936.
10. Helenius J, Arsava EM, Goldstein JN, et al. Concurrent acute brain infarcts in patients with monocular visual loss. *Ann Neurol*. 2012;72(2):286-293.
11. Lee J, Kim SW, Lee SC, Kwon OW, Kim YD, Byeon SH. Co-occurrence of acute retinal artery occlusion and acute ischemic stroke: diffusion-weighted magnetic resonance imaging study. *Am J Ophthalmol*. 2014;157(6):1231-1238.
12. Chang YS, Chu CC, Weng SF, Chang C, Wang JJ, Jan RL. The risk of acute coronary syndrome after retinal artery occlusion: a population-based cohort study. *Br J Ophthalmol*. 2015;99(2):227-231.
13. Bakri SJ, Berrocal A, Capone Jr A, et al. Retinal Artery Occlusion. *Retina Health Series 2017*; <https://www.asrs.org/patients/retinal-diseases/32/retinal-artery-occlusion>. Accessed September 2019.
14. Brown GC. Retinal arterial obstructive disease. In: Ryan SJ, ed. *Retina*. St. Louis, MO: Mosby; 1994:1361-77.
15. Park SJ, Choi NK, Seo KH, Park KH, Woo SJ. Nationwide incidence of clinically diagnosed central retinal artery occlusion in Korea, 2008 to 2011. *Ophthalmology*. 2014;121(10):1933-1938.
16. Brown GC, Magargal LE, Shields JA, Goldberg RE, Walsh PN. Retinal arterial obstruction in children and young adults. *Ophthalmology*. 1981;88(1):18-25.
17. Brown GC, Magargal LE. Central retinal artery obstruction and visual acuity. *Ophthalmology*. 1982;89(1):14-19.
18. Bakhoun MF, Freund KB, Dolz-Marco R, et al. Paracentral Acute Middle Maculopathy and the Ischemic Cascade Associated With Retinal Vascular Occlusion. *Am J Ophthalmol*. 2018;195:143-153.
19. Brown GC, Shields JA. Cilioretinal arteries and retinal arterial occlusion. *Arch Ophthalmol*. 1979;97(1):84-92.
20. Hayreh SS, Zimmerman MB. Central retinal artery occlusion: visual outcome. *Am J Ophthalmol*. 2005;140(3):376-391.
21. Leung CK, Tham CC, Mohammed S, et al. In vivo measurements of macular and nerve fibre layer thickness in retinal arterial occlusion. *Eye (Lond)*. 2007;21(12):1464-1468.

22. Yu S, Pang CE, Gong Y, et al. The spectrum of superficial and deep capillary ischemia in retinal artery occlusion. *Am J Ophthalmol.* 2015;159(1):53-63.
23. Jung YH, Ahn SJ, Hong JH, et al. Incidence and Clinical Features of Neovascularization of the Iris following Acute Central Retinal Artery Occlusion. *Korean J Ophthalmol.* 2016;30(5):352-359.
24. Delaey C, Van De Voorde J. Regulatory mechanisms in the retinal and choroidal circulation. *Ophthalmic Res.* 2000;32(6):249-256.
25. Brown GC, Duker JS, Lehman R, Eagle RC, Jr. Combined central retinal artery-central vein obstruction. *Int Ophthalmol.* 1993;17(1):9-17.
26. Nishiguchi KM, Ito Y, Terasaki H. Bilateral central retinal artery occlusion and vein occlusion complicated by severe choroidopathy in systemic lupus erythematosus. *Lupus.* 2013;22(7):733-735.
27. Rachitskaya AV, Lee RK, Dubovy SR, Schiff ER. Combined central retinal vein and central retinal artery occlusions and neovascular glaucoma associated with interferon treatment. *Eur J Ophthalmol.* 2012;22(2):284-287.
28. Park SJ, Choi NK, Yang BR, et al. Risk and risk periods for stroke and acute myocardial infarction in patients with central retinal artery occlusion. *Ophthalmology.* 2015;122(11):2336-2343.
29. Leavitt JA, Larson TA, Hodge DO, Gullerud RE. The incidence of central retinal artery occlusion in Olmsted County, Minnesota. *Am J Ophthalmol.* 2011;152(5):820-823.
30. Mitchell P, Wang JJ, Li W, Leeder SR, Smith W. Prevalence of asymptomatic retinal emboli in an Australian urban community. *Stroke.* 1997;28(1):63-66.
31. Cugati S, Wang JJ, Rochtchina E, Mitchell P. Ten-year incidence of retinal emboli in an older population. *Stroke.* 2006;37(3):908-910.
32. Kewcharoen J, Tom ES, Wiboonchutikula C, et al. Prevalence of Atrial Fibrillation in Patients with Retinal Vessel Occlusion and Its Association: A Systematic Review and Meta-Analysis. *Curr Eye Res.* 2019:1-8.
33. Rudkin AK, Lee AW, Aldrich E, Miller NR, Chen CS. Clinical characteristics and outcome of current standard management of central retinal artery occlusion. *Clin Experiment Ophthalmol.* 2010;38(5):496-501.
34. Jauch EC, Saver JL, Adams HP, Jr., et al. American Heart Association Stroke Council, Council on Cardiovascular Nursing, Council on Peripheral Vascular Disease, Council on Clinical Cardiology. Guidelines for the early management of patients with acute ischemic stroke: a guideline for healthcare professionals from the American Heart Association/American Stroke Association. *Stroke.* 2013;44(3):870-947.
35. Callizo J, Feltgen N, Pantenburg S, et al. European Assessment Group for Lysis in the Eye. Cardiovascular risk factors in central retinal artery occlusion: results of a prospective and standardized medical examination. *Ophthalmology.* 2015;122(9):1881-1888.
36. Hayreh SS. Ocular vascular occlusive disorders: natural history of visual outcome. *Prog Retin Eye Res.* 2014;41:1-25.
37. Biousse V, Calvetti O, Bruce BB, Newman NJ. Thrombolysis for central retinal artery occlusion. *J Neuroophthalmol.* 2007;27(3):215-230.
38. Mazlumzadeh M, Hunder GG, Easley KA, et al. Treatment of giant cell arteritis using induction therapy with high-dose glucocorticoids: a double-blind, placebo-controlled, randomized prospective clinical trial. *Arthritis Rheum.* 2006;54(10):3310-3318.
39. Weyand CM, Goronzy JJ. Giant-cell arteritis and polymyalgia rheumatica. *Ann Intern Med.* 2003;139(6):505-515.
40. Lee AG, Levin, MH, Miller, NR, Stuart, A. CRAO: Harbinger of Ischemic Stroke. *EyeNet Magazine.* 2016. <https://www.aao.org/eyenet/article/crao-harbinger-of-ischemic-stroke?june-2016>. Accessed September 2019.
41. Zhang LY, Zhang J, Kim RK, et al. Risk of acute ischemic stroke in patients with monocular vision loss of vascular etiology. *J Neuroophthalmol.* 2018:[Epub ahead of print].
42. Golsari A, Bittersohl D, Cheng B, et al. Silent Brain Infarctions and Leukoaraiosis in Patients With Retinal Ischemia: A Prospective Single-Center Observational Study. *Stroke.* 2017;48(5):1392-1396.
43. Schumacher M, Schmidt D, Jurklies B, et al. Central retinal artery occlusion: local intra-arterial fibrinolysis versus conservative treatment, a multicenter randomized trial. *Ophthalmology.* 2010;117(7):1367-1375 e1361.
44. Wolf A, Schumacher M, Neubauer AS, et al. [Comparison of superselective intraarterial fibrinolysis with conservative therapy. Use in patients with acute non-arteritic central retinal artery occlusion]. *Ophthalmologie.* 2010;107(9):799-805.

45. Pielen A, Pantenburg S, Schmoor C, et al. Predictors of prognosis and treatment outcome in central retinal artery occlusion: local intra-arterial fibrinolysis vs. conservative treatment. *Neuroradiology*. 2015;57(10):1055-1062.
46. Wu X, Chen S, Li S, et al. Oxygen therapy in patients with retinal artery occlusion: A meta-analysis. *PLoS One*. 2018;13(8):e0202154.
47. Lauda F, Neugebauer H, Reiber L, Juttler E. Acute silent brain infarction in monocular visual loss of ischemic origin. *Cerebrovasc Dis*. 2015;40(3-4):151-156.
48. Duker JS, Brown GC. The efficacy of panretinal photocoagulation for neovascularization of the iris after central retinal artery obstruction. *Ophthalmology*. 1989;96(1):92-95.
49. Yang CS, Hung KC, Huang YM, Hsu WM. Intravitreal bevacizumab (Avastin) and panretinal photocoagulation in the treatment of high-risk proliferative diabetic retinopathy. *J Ocul Pharmacol Ther*. 2013;29(6):550-555.
50. Feder RS, Olsen TW, Prum BE, Jr., et al. Comprehensive Adult Medical Eye Evaluation Preferred Practice Pattern® Guidelines. *Ophthalmology*. 2016;123(1):P209-236. Available at www.aaojournal.org/content/preferred-practice-pattern or www.aao.org/ppp.
51. Foroozan R, Danesh-Meyer H, Savino PJ, Gamble G, Mekari-Sabbagh ON, Sergott RC. Thrombocytosis in patients with biopsy-proven giant cell arteritis. *Ophthalmology*. 2002;109(7):1267-1271.
52. Hayreh SS, Podhajsky PA, Raman R, Zimmerman B. Giant cell arteritis: validity and reliability of various diagnostic criteria. *Am J Ophthalmol*. 1997;123(3):285-296.
53. Scheurer RA, Harrison AR, Lee MS. Treatment of vision loss in giant cell arteritis. *Curr Treat Options Neurol*. 2012;14(1):84-92.
54. Sacco RL, Kasner SE, Broderick JP, et al. American Heart Association Stroke Council, Council on Cardiovascular Surgery and Anesthesia, Council on Cardiovascular Radiology and Intervention, Council on Cardiovascular and Stroke Nursing, Council on Epidemiology and Prevention, Council on Peripheral Vascular Disease, Council on Nutrition, Physical Activity and Metabolism. An updated definition of stroke for the 21st century: a statement for healthcare professionals from the American Heart Association/American Stroke Association. *Stroke*. 2013;44(7):2064-2089.
55. Greven CM, Slusher MM, Weaver RG. Retinal arterial occlusions in young adults. *Am J Ophthalmol*. 1995;120(6):776-783.
56. Dorr J, Krautwald S, Wildemann B, et al. Characteristics of Susac syndrome: a review of all reported cases. *Nat Rev Neurol*. 2013;9(6):307-316.
57. Recchia FM, Brown GC. Systemic disorders associated with retinal vascular occlusion. *Curr Opin Ophthalmol*. 2000;11(6):462-467.
58. Falkenberry SM, Ip MS, Blodi BA, Gunther JB. Optical coherence tomography findings in central retinal artery occlusion. *Ophthalmic Surg Lasers Imaging*. 2006;37(6):502-505.
59. Yannuzzi LA, Rohrer KT, Tindel LJ, et al. Fluorescein angiography complication survey. *Ophthalmology*. 1986;93(5):611-617.
60. Sunness JS. The pregnant woman's eye. *Surv Ophthalmol*. 1988;32(4):219-238.
61. Varma DD, Cugati S, Lee AW, Chen CS. A review of central retinal artery occlusion: clinical presentation and management. *Eye (Lond)*. 2013;27(6):688-697.
62. Ahn SJ, Woo SJ, Park KH, Jung C, Hong JH, Han MK. Retinal and choroidal changes and visual outcome in central retinal artery occlusion: an optical coherence tomography study. *Am J Ophthalmol*. 2015;159(4):667-676.
63. Dumitrascu OM, Shen JF, Kurli M, et al. Is Intravenous Thrombolysis Safe and Effective in Central Retinal Artery Occlusion? A Critically Appraised Topic. *Neurologist*. 2017;22(4):153-156.
64. Biousse V. Thrombolysis for acute central retinal artery occlusion: is it time? *Am J Ophthalmol*. 2008;146(5):631-634.
65. Mason JO, 3rd, Nixon PA, Albert MA, Jr. Trans-luminal Nd:YAG laser embolysis for branch retinal artery occlusion. *Retina*. 2007;27(5):573-577.
66. Opremcak E, Rehmar AJ, Ridenour CD, Borkowski LM, Kelley JK. Restoration of retinal blood flow via transluminal Nd:YAG embolysis/embolotomy (TYL/E) for central and branch retinal artery occlusion. *Retina*. 2008;28(2):226-235.
67. Feltgen N, Neubauer A, Jurklics B, et al. EAGLE-Study Group. Multicenter study of the European Assessment Group for Lysis in the Eye (EAGLE) for the treatment of central retinal artery occlusion: design issues and implications: EAGLE Study report no. 1. *Graefes Arch Clin Exp Ophthalmol*. 2006;244(8):950-956.

68. Hattenbach LO, Kuhli-Hattenbach C, Scharrer I, Baatz H. Intravenous thrombolysis with low-dose recombinant tissue plasminogen activator in central retinal artery occlusion. *Am J Ophthalmol*. 2008;146(5):700-706.
69. Fraser SG, Adams W. Interventions for acute non-arteritic central retinal artery occlusion. *Cochrane Database Syst Rev*. 2009(1):CD001989.
70. Radak DJ, Tanaskovic S, Ilijevski NS, et al. Eversion carotid endarterectomy versus best medical treatment in symptomatic patients with near total internal carotid occlusion: a prospective nonrandomized trial. *Ann Vasc Surg*. 2010;24(2):185-189.
71. Bohnstedt BN, Dhaemers R, Hsu D. Symptomatic carotid artery stenosis. *Semin Neurol*. 2013;33(5):456-461.
72. Shahidi S, Owen-Falkenberg A, Hjerpsted U, Rai A, Ellemann K. Urgent best medical therapy may obviate the need for urgent surgery in patients with symptomatic carotid stenosis. *Stroke*. 2013;44(8):2220-2225.
73. Rudkin AK, Lee AW, Chen CS. Vascular risk factors for central retinal artery occlusion. *Eye (Lond)*. 2010;24(4):678-681.
74. Early Treatment Diabetic Retinopathy Study Research Group. Early photocoagulation for diabetic retinopathy: ETDRS report number 9. *Ophthalmology*. 1991;98(5 Suppl):766-785.
75. Jacobson DR, Murphy RP, Rosenthal AR. The treatment of angle neovascularization with panretinal photocoagulation. *Ophthalmology*. 1979;86(7):1270-1277.
76. Early Treatment Diabetic Retinopathy Study Research Group. Photocoagulation for diabetic macular edema: Early Treatment Diabetic Retinopathy Study report number 1. *Arch Ophthalmol*. 1985;103(12):1796-1806.
77. Early Treatment Diabetic Retinopathy Study Research Group. Fundus photographic risk factors for progression of diabetic retinopathy: ETDRS report number 12. *Ophthalmology*. 1991;98(5 Suppl):823-833.
78. American Academy of Ophthalmology Retina/Vitreous Panel. Preferred Practice Pattern[®] Guidelines. Diabetic Retinopathy. San Francisco, CA: American Academy of Ophthalmology; 2016. Available at: www.aao.org/ppp.
79. Biousse V, Nahab F, Newman NJ. Management of Acute Retinal Ischemia: Follow the Guidelines! *Ophthalmology*. 2018;125(10):1597-1607.
80. Snead MP, Snead DR, James S, Richards AJ. Clinicopathological changes at the vitreoretinal junction: posterior vitreous detachment. *Eye (Lond)*. 2008;22(10):1257-1262.
81. Pertile G, Claes C. Silicone oil vs. gas for the treatment of full-thickness macular hole. *Bull Soc Belge Ophthalmol*. 1999;274:31-36.
82. Stelmack JA, Tang XC, Reda DJ, Rinne S, Mancil RM, Massof RW. LOVIT Study Group. Outcomes of the Veterans Affairs Low Vision Intervention Trial (LOVIT). *Arch Ophthalmol*. 2008;126(5):608-617.