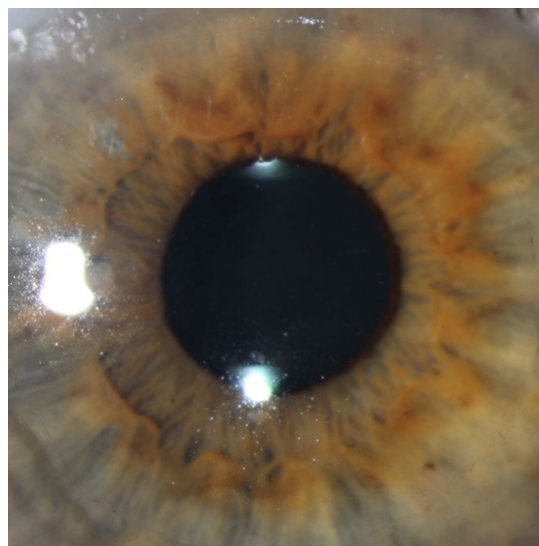


News in Review

COMMENTARY AND PERSPECTIVE

THIS MONTH, NEWS IN REVIEW HIGHLIGHTS SELECTED PAPERS from the original papers sessions at AAO 2018. Each was chosen by the session chair because it presents important news or illustrates a trend in the field. Only 4 subspecialties are included here; papers sessions will also be held in 5 other fields. For more information, see the Meeting Program, which you'll find in your meeting bag, or the Mobile Meeting Guide (aao.org/mobile).



CORNEA PAPER

Cornea Grafts: Ensuring Success

GRAFT FAILURE AFTER DESCEMET stripping automated endothelial keratoplasty (DSAEK) is more likely if the donor has diabetes or pseudophakic/aphakic corneal edema (PACE) and if there were complications during the surgery, researchers in the Corneal Preservation Time Study (CPTS) have found.¹

Building on previous evidence.

Earlier reports from the CPTS showed that graft preservation time of up to 11 days did not impact the 3-year success rate of DSAEK² and that preservation time of up to 13 days did not affect endothelial cell loss.³ In further analysis of data from this randomized, prospective clinical trial (1,330 eyes), the researchers looked for the influence on transplant success of secondary donor and recipient factors, said coauthor Mark A. Terry, MD, at the Devers Eye Institute in Portland, Oregon.

Risk of failure. The CPTS researchers found that early graft failure (within

8 weeks of surgery) was twice as likely if the donor tissue came from someone with diabetes and 4 times as likely if the recipient had a preoperative diagnosis of PACE. Even so, the 3-year graft success was over 90% when diabetic donor tissue was used and over 83% in recipients with PACE, Dr. Terry said.

Impact of operative factors. The analysis revealed that the surgeon's insertion technique did not matter but that surgical complications did, Dr. Terry said. "This study looked at many different ways of doing the surgery, and we found that it really doesn't matter what way you did the surgery, as long as you did the surgery well," he said. However, he added, "If the surgeon reported a complication during the surgery, those eyes had a highly statistically significant difference in success rates in terms of endothelial cell count and in terms of lasting 3 years."

Evidence-based road map. When these results are combined with the ear-

DIABETIC DONOR. This image was taken 10 years after surgery in a DSAEK donor who has diabetes.

lier CPTS results, cornea surgeons now have an evidence-based road map that can increase their chances of successful DSAEK, Dr. Terry said.

"These are the guidelines we're offering surgeons: We're telling them that their common preconceived notions of what constitutes the 'best' donor tissue is wrong—it turns out that age, storage time, and cell count of the donor tissue don't matter," he said.

Dr. Terry added, "Don't ask for young tissue; it doesn't make a difference. Don't ask for high endothelial cell counts; it doesn't make a difference. Don't ask for tissue that was harvested a day or 2 ago; it doesn't make a difference. Even the minimal standards set by the eye bank for quality donor tissue will yield excellent results in DSAEK surgery."

—Linda Roach

Factors Associated With Graft Success in the Cornea Preservation Time Study.

When: Monday, Oct. 29, during the second cornea original papers session (3:30-5:15 p.m.). **Where:** Room E450. **Access:** Free.

1 Terry MA et al., on behalf of the Cornea Preservation Time Study Group. *Ophthalmology*. Published online Aug. 8, 2018.

2 Rosenwasser GO et al. *JAMA Ophthalmol*. 2017; 135:1401-1409.

3 Lass JH et al. *JAMA Ophthalmol*. 2017;135: 1394-1400.

Relevant financial disclosures—Dr. Terry: Bausch + Lomb: P,L; Envisia: C; Moria: L.

GLAUCOMA PAPER

Sustained-Release Travoprost: Data at 12 Months

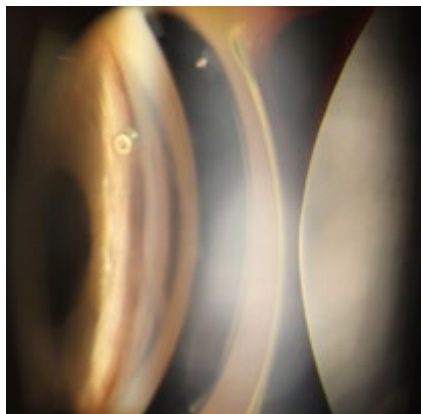
NO MORE BOTTLES, NO MORE DROPS.

For glaucoma patients and their doctors, that dream came a bit closer to reality with the announcement that iDose (Glaukos), a travoprost-eluting intraocular implant, was safe and effective in patients with open-angle glaucoma or ocular hypertension during a phase 2 clinical trial.

“The early results are promising,” said trial investigator John P. Berdahl, MD, with Vance Thompson Vision in Sioux Falls, South Dakota. Reduction in intraocular pressure (IOP) was sustained, he said, and the procedure was safe.

How it works. The iDose implant is filled with a proprietary formulation of travoprost that allows for consistent drug delivery and implanted in the angle during a microinvasive procedure. It continuously elutes therapeutic levels of travoprost for at least 1 year. Upon medication depletion, a new iDose is implanted and the old one is removed.

Study specifics. This prospective double-masked multicenter trial enrolled 154 patients who were on 0-3 glaucoma medications. Unmedicated mean diurnal IOP was 21-36 mm Hg in the study eye. Patients were randomized to 2 different eluting models of the delivery system—iDose-slow (n = 54) and iDose-fast (n = 51). Controls



IN PLACE. This gonioscopic image shows the implanted iDose.

(n = 49) received topical timolol ophthalmic solution 0.5% twice a day.

Findings. At 12 weeks, all study and control subjects achieved at least a 30% reduction in IOP. At 1 year, the subset of iDose eyes achieved a 33% reduction in IOP. Both the slow and fast models were equally efficacious. No adverse events, including hyperemia, were reported in either elution group.

Clinical implications. “Besides eliminating compliance issues, which are huge, we are glad to deliver the drug where we want it . . . inside the eye,” Dr. Berdahl said. “We know that topical drops are tough on the ocular surface, but we are willing to pay that price to lower IOP. Now we won’t have to.”

Having said that, he noted that with drops, patients are confident they are receiving the drug. But how would a patient know when the implant runs out of the medication? He suggested that an iDose replacement strategy might need to be implemented to ensure an uninterrupted drug supply.

Dr. Berdahl also noted that, for the study, the iDose was implanted in the operating room. But, he said, “I can envision the possibility of an in-office procedure” at some point in the future.

Continuing investigation. For the next phase, 1,000 patients are being recruited for the phase 3 trial, which is looking at similar endpoints: IOP

lowering and safety. And the phase 2 follow-up will continue through 3 years. In the meantime, Glaukos has begun seeking regulatory approvals for iDose travoprost in European markets and Japan. —Miriam Karmel

Relevant financial disclosures—Dr. Berdahl: Glaukos: C.

NEURO-OPHTHALMOLOGY PAPER

Botox Effective for Dry Eye and Photophobia

DOCTORS HAVE BEEN USING BOTULINUM TOXIN A (BoNT-A) to treat everything from facial wrinkles to strabismus. Now a study performed at the University of Miami supports adding photophobia and dry eye to the list, at least in patients with migraine.

“We found that dry eye symptoms, photophobia, and migraine pain severity were correlated and all improved following BoNT-A injection,” said Ryan Diel, MD, now a resident in internal medicine and ophthalmology at the University of Iowa in Iowa City. “Dry eye and migraine were initially thought of as 2 different diseases and treated independently. But these findings suggest that the symptoms are linked and represent different manifestations of the same underlying disease.”

A cohort study. For this study, 76 patients at the Miami Veterans Affairs Hospital with chronic migraine, for which BoNT-A is approved, were asked to assess the severity of migraine, photophobia, and dry eye symptoms prior to injection.

Then, 2 to 8 weeks postinjection, patients answered the same questions to assess treatment response. The researchers also evaluated whether preinjection tear volume, measured by the phenol red thread test (PRT), had any effect on symptoms.

Confirmatory findings. The study replicated findings of an earlier cross-sectional study at the same medical center.¹ Migraine, photophobia, and dry eye symptom scores were all sig-

Interim Results of a Prospective, Randomized Phase 2 Study Evaluating the Safety and Efficacy of Novel Sustained-Release Travoprost Intraocular Implants.

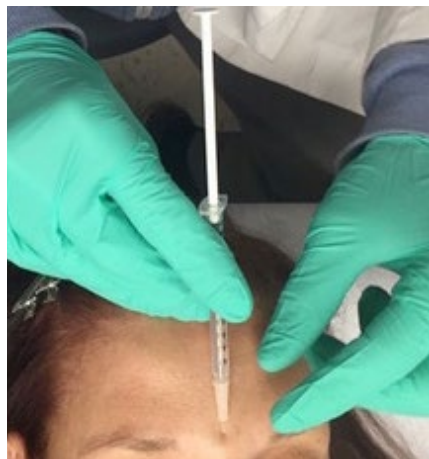When: Monday, Oct. 29, during the glaucoma original papers session (2:00-5:15 p.m.). **Where:** Room S404. **Access:** Free.

nificantly correlated, and symptoms improved following BoNT-A injections.

A surprise. However, PRT results did not correlate with symptom severity, meaning patients with photophobia and dry eye had relatively normal tear volume at baseline. “This suggests that the symptoms may not be related to abnormalities in the ocular surface,” Dr. Diel said. In other words, patients with migraine may experience significant photophobia and dry eye symptoms despite relatively normal ocular surface parameters.

Looking ahead. In this study, patients received approved BoNT-A injections for chronic migraine. “The question is whether BoNT-A can be used in patients with dry eye not associated with migraine,” Dr. Diel said. He plans to address that issue by using off-label BoNT-A injections in individuals who have dry eye and photophobia but are not affected by migraines.

“I hope that this and future studies will prompt physicians to consider new treatments for dry eye that is unresponsive to traditional therapies and in which neuropathic mechanisms are be-



INJECTION. A patient receiving a BoNT-A injection in the procerus muscle, 1 of the muscles injected in the study protocol.

OnabotulinumtoxinA Decreases Photophobia and Sensations of Dryness Independent of Tear Volume. *When:* Tuesday, Oct. 30, during the neuro-ophthalmology original papers session (8:30-10:00 a.m.). *Where:* Room S405. *Access:* Free.

lieved to underlie symptoms,” he said.
—Miriam Karmel

1 Diel RJ et al. *Ophthalmology*. 2018;125(1):139-140.
Relevant financial disclosures—Dr. Diel: None.

UVEITIS PAPER

Macular Edema in NIU: New Rx, New Delivery Method

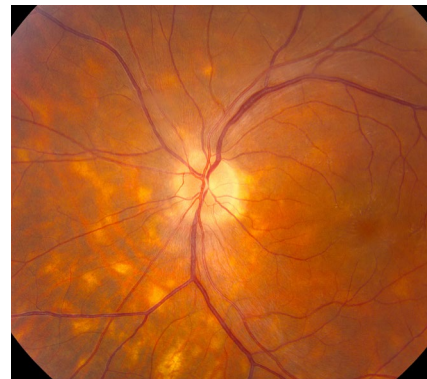
SUPRACHOROIDAL INJECTIONS OF A proprietary suspension of triamcinolone acetonide might present clinicians with a new treatment for the macular edema that can persist in patients with noninfectious uveitis (NIU) even after their inflammation is under control, according to the results of a phase 3 trial.

In the study, 46.9% of the patients who received a total of 2 suprachoroidal injections of the investigational new drug, CLS-TA (Clearside Biomedical) administered 12 weeks apart, gained at least 15 letters in best-corrected visual acuity at 24 weeks. That compared to 15.6% in the control subjects, who received sham injections, said Rahul N. Khurana, MD, with Northern California Retina Vitreous Associates in Mountain View, California.

Addressing an unmet need. This potential therapeutic approach would address a large unmet need in the treatment of patients with NIU, Dr. Khurana said.

“Uveitic macular edema is really challenging. It’s the leading cause of vision loss in patients with uveitis,” he said. “It occurs in about 40% of patients with uveitis, and it can be very difficult to manage even when you control the inflammation itself.”

Novel method of drug delivery. “Most of our medicines for diseases of the posterior segment have centered on delivering medications in the intravitreal space. This is one of the first clinical trials, if not the first, to look at the suprachoroidal space,” Dr. Khurana said. “So it’s really exciting to see a su-



EDEMA. This fundus image is of a patient with birdshot retinochoroidopathy (HLA-A29+) and cystoid macular edema.

prachoroidal treatment actually work.”

Measuring impact on vision. “This study was also unique in the sense that most uveitis studies evaluate a potential treatment’s effectiveness at treating inflammation by measuring vitreous haze. But in this study we actually looked at improvements in vision,” he said.

If CLS-TA ultimately wins marketing approval from the U.S. Food and Drug Administration, it has the potential to become a new paradigm for the treatment of visual impairment caused by uveitic macular edema, Dr. Khurana concluded.
—Linda Roach

Relevant financial disclosures—Dr. Khurana: Allergan: C; Clearside Biomedical: S; Genentech: C; Regeneron: C,S.

Phase 3 Efficacy Data of Suprachoroidally Injected CLS-TA for Macular Edema due to Noninfectious Uveitis.

When: Monday, Oct. 29, during the uveitis original papers session (8:30-10:00 a.m.). *Where:* Room S405. *Access:* Free.

POSTERS AT THE MEETING

For a look at cutting-edge research, visit the Scientific Poster Theater. *When:* For times, check the Mobile Meeting Guide at aao.org/mobile. *Where:* South Hall A. *Access:* Free.

See the financial disclosure key, page 10. For full disclosures, including category descriptions, view this News in Review at aao.org/eyenet.