

## CORNEA

# Rethinking Meibomian Gland Dysfunction: How to Spot It, Stage It and Treat It

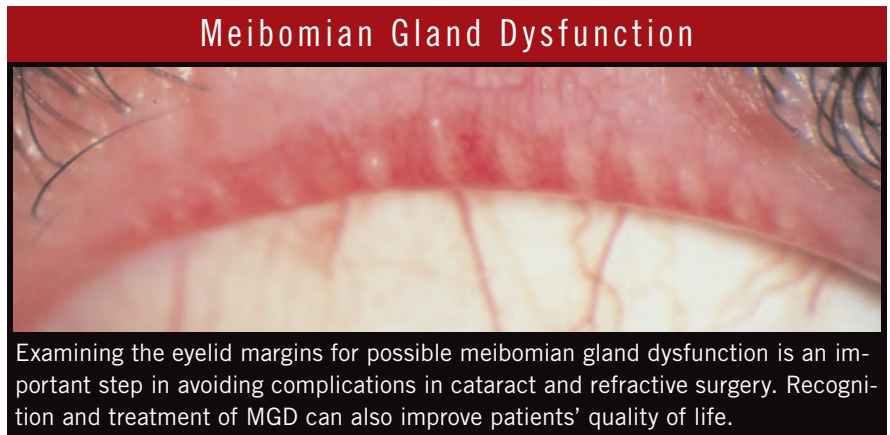
BY LINDA ROACH, CONTRIBUTING WRITER

INTERVIEWING PENNY A. ASBELL, MD, MARGUERITE B. McDONALD, MD, KELLY K. NICHOLS, MPH, PHD, OD, GUSTAVO E. TAMAYO, MD, AND JOSEPH TAUBER, MD

**M**eibomian gland dysfunction (MGD) is thought to be the leading cause of dry eye disease. Despite the importance of MGD to eye health, many questions have persisted about its classification and treatment. Now, answers abound in a comprehensive, 168-page, evidence-based report recently issued by an international panel of experts convened by the Tear Film & Ocular Surface Society (TFOS) and supported by unrestricted grants from 13 industry sponsors. Of particular interest to clinicians, the report includes a new algorithm for recognizing, classifying and treating MGD.

According to Marguerite B. McDonald, MD, a refractive surgeon at Ophthalmic Consultants of Long Island and clinical professor of ophthalmology at New York University, “There has been surprisingly little research on how to classify and manage MGD. You can sum up all the research that has been done very briefly.” After reviewing the report, she commented, “This group put an enormous amount of effort—hundreds and hundreds of hours—into culling the past research, weighing the evidence and developing a treatment algorithm based on what is known about MGD. They admit that the result might not be perfect, but it’s an important first step.”

At the behest of TFOS, the 50-plus researcher and clinician members of the International Workshop on Meibomian Gland Dysfunction first met in



late 2008 to launch the two-year project. Their report, published in March, reviews the limited research on MGD, incorporates emerging concepts about the condition and identifies future research needs.<sup>1</sup>

### Report's Significance for Clinical Care

MGD is “the most underrecognized, underappreciated and undertreated disease in ophthalmic care. It is so common as to be taken as ‘normal’ in many clinical practices,” according to Joseph Tauber, MD, an anterior segment subspecialist and refractive surgeon in Kansas City, Mo., who was a member of the workshop’s Management and Treatment Subcommittee. Yet taking MGD for granted can have a serious effect on the success of anterior segment surgery.

**Ocular surface is key to surgical outcomes.** The new staging and treatment algorithm has particular importance for cataract and refractive surgeons because unrecognized MGD

can compromise surgical results. “The final visual result of refractive surgery is largely dependent on the status of the tear film,” said Gustavo E. Tamayo, MD, director of the Bogotá Laser Refractive Institute in Bogotá, Colombia. “The correct diagnosis and treatment of any possible cause of dry eye, such as MGD, is mandatory for any type of surgical procedure.”

Penny A. Asbell, MD, professor of ophthalmology at Mount Sinai Medical Center in New York City, agreed: “To get good vision you need a good ocular surface. But the role of the meibomian glands in providing that good ocular surface has been underappreciated.” Dr. Asbell chaired the workshop’s Design and Conduct of Clinical Trials Subcommittee.

**Minimizing postsurgical complications.** Dr. Asbell noted that tear film irregularities change corneal reflectivity and can lead to inaccurate preoperative K readings and mistaken IOL power, causing dissatisfaction with the

refractive results, especially if the patient paid extra for presbyopia-correcting IOLs. In addition, untreated MGD can put cataract patients at higher risk for infection and inflammation. “We want to avoid lid inflammation that could be a source of contaminants during surgery as well as a risk factor for greater postoperative inflammation,” she said.

### Untangling the Terminology of MGD

Since the term *meibomian gland dysfunction* first appeared in the literature in 1980, it has been used interchangeably with a confusing array of other names for meibomian gland and eyelid conditions, the workshop’s Definition and Classification Subcommittee notes. These have included posterior blepharitis, meibomian gland disease, meibomitis, meibomianitis and meibomian keratoconjunctivitis.

Consequently, an important element in the MGD report is its attempt to standardize the definitions of MGD and related terms based on their pathophysiology:

- **Blepharitis**, the most general of the terms, describes inflammation of the eyelid as a whole. *Marginal blepharitis* is inflammation of the lid margin and comprises both anterior and posterior blepharitis.
- **Anterior blepharitis** refers to inflammation of the lid margin anterior to the gray line, concentrated around the lashes. It may be accompanied by squamous debris or collarettes around the lashes, and inflammation may spill onto the posterior lid margin.
- **Posterior blepharitis** is an inflammatory condition of the posterior lid margin. It has a variety of causes, including MGD, conjunctival inflammation (allergic or infectious) or other conditions, such as acne rosacea.
- **MGD** is “a chronic, diffuse abnormality of the meibomian glands, commonly characterized by terminal duct obstruction and/or qualitative/quantitative changes in the glandular secretion. This may result in alteration of the tear film, symptoms of eye irritation, clinically apparent inflammation, and ocular surface disease.”<sup>1</sup>

**Why meibum matters.** The workshop analysis divided MGD into two major types: 1) low delivery states, the most common form, characterized by a reduction in meibum, resulting from either hyposecretion or obstruction; and 2) high delivery states, characterized by hypersecretion. In this new classification system, the relationship between MGD and ocular surface diseases such as dry eye is based on changes in meibum secretion, which alter the makeup of the tear film and lead to subsequent surface irritation and inflammation.

### Highlights for Busy Clinicians

Acknowledging that busy comprehensive ophthalmologists might not have time to read the full report, the workshop produced a two-page overview of the highlights for clinical use.

#### Staging and treatment algorithm.

The most important part of the overview is a table proposing a staging and treatment algorithm for MGD. (See “Staging and Treatment of Meibomian Gland Dysfunction.”)

This algorithm fills a void that has hampered MGD treatment and research in the past, and it will set the stage for future improvements, according to the workshop’s leaders. “Once our algorithm is out there and is seen by clinicians, studies can be designed around it to test it. You have to start somewhere, and I felt that we would be doing a disservice if we didn’t try to define something that people could try to shoot holes in,” said the chairwoman of the workshop’s Steering Committee, Kelly K. Nichols, MPH, PhD, OD, associate professor of optometry at the Ohio State University and an expert in ocular surface diseases.

Dr. Tauber agreed: “Learning to use a standardized grading system in MGD will allow for an organized approach to therapy, rather than the random, grab-bag approach prescribed by many practitioners currently.”

### How to Detect Lid Problems

For ophthalmologists who want to do a better job of identifying MGD, Dr. Asbell had these tips:

**Do a slit-lamp exam.** At every pre-surgical exam, examine the lids thoroughly at the slit lamp by pulling down on the lower lid and up on the upper lid to expose the lid margin. Be sure to look closely at the orifices, where the meibomian secretions come out.

**Examine the meibum.** Use pressure to express some meibum and evaluate its appearance, which indicates the MGD stage (see table for meibum grading).

“I bet that nine out of 10 ophthalmologists don’t look closely at the lid when doing an eye exam before surgery,” Dr. Asbell said. “Both of these steps should be routine in every preoperative patient.”

**From detection to action.** Dr. Tauber advises clinicians to be alert for signs of MGD when a patient complains of nonspecific eye irritation or visual blur. Symptoms of MGD are very similar to those of aqueous-deficiency dry eye, but complaints of burning suggest lid margin disease, he noted.

“Optimizing the ocular surface health preoperatively is highly advisable, as it is far easier to prevent decompensation than to rehabilitate the surface later,” Dr. Tauber said. “Staging MGD is important, because in some cases, the addition of lid hygiene measures alone will be sufficient prior to surgery, while in other cases, surgery should be deferred for weeks or even months, until high-grade MGD is brought under control.”

**MGD and quality of life.** Dr. McDonald reminds her colleagues that blepharitis and MGD also deserve attention because they pose substantial quality-of-life issues for patients. “Even without any surgical considerations, untreated blepharitis or MGD causes very significant problems for them,” she said. “They can’t wear their contact lenses. Their eyes are so red and puffy that it puts their professional and personal lives in jeopardy—because they show up looking like they have a drinking or drug problem.”

*MORE ONLINE.* For background information on the International Workshop on Meibomian

Gland Dysfunction and links to the overview and report, go to [www.tearfilm.org](http://www.tearfilm.org). Or go directly to [www.iovs.org/content/52/4.toc](http://www.iovs.org/content/52/4.toc) for the complete report.

1 The International Workshop on Meibomian Gland Dysfunction. *Invest Ophthalmol Vis Sci* 2011;52(4):1917–2085.

*Dr. Asbell* has received speaking or consultant fees from Inspire, Aton, Pfizer, Bausch + Lomb, Johnson & Johnson, Vindico, Merck, Santen and Otsuka. *Dr. McDonald* is a consultant for Allergan, Alcon, AMO, Bausch + Lomb, Santen, Inspire, Ocularis Pharma, Focus Labs and NexisVision. *Dr. Nichols* has received speaking or consultant fees from

Alcon, Allergan, Inspire Pharmaceuticals, Pfizer and TearLab. *Dr. Tamayo* has received research funding from EyeGenics, is a member of the speakers' bureau for Presbia and has received speaking fees, research grants and travel funding from Abbott Medical Optics. *Dr. Tauber* is a consultant for Alcon, Allergan and Inspire.

## Staging and Treatment of Meibomian Gland Dysfunction

STAGE	CLINICAL DESCRIPTION	TREATMENT
1	<p>No <b>symptoms</b> of ocular discomfort, itching or photophobia</p> <p><b>Clinical signs</b> of MGD based on gland expression</p> <p>Minimally altered secretions: Grade <math>\geq 2</math> to <math>&lt; 4</math></p> <p>Expressibility: 1</p> <p>No ocular surface <b>staining</b></p>	<p><b>Inform</b> patient about MGD, the potential impact of diet and the effect of work/home environments on tear evaporation, and the possible drying effect of certain systemic medications</p> <p><b>Consider</b> eyelid hygiene including warming/expression as described below (<math>\pm</math>)</p>
2	<p>Minimal to mild <b>symptoms</b> of ocular discomfort, itching or photophobia</p> <p>Minimal to mild MGD <b>clinical signs</b></p> <p>Scattered lid margin features</p> <p>Mildly altered secretions: Grade <math>\geq 4</math> to <math>&lt; 8</math></p> <p>Expressibility: 1</p> <p>None to limited ocular surface <b>staining</b> (DEWS grade 0–7; Oxford grade 0–3)</p>	<p><b>Advise</b> patient on improving ambient humidity; optimizing workstations and increasing dietary omega-3 fatty acid intake (<math>\pm</math>)</p> <p><b>Institute</b> eyelid hygiene with eyelid warming (a minimum of four minutes, once or twice daily) followed by moderate to firm massage and expression of MG secretions (+)</p> <p><b>All the above, plus</b> (<math>\pm</math>)</p> <p>Artificial lubricants (for frequent use, nonpreserved preferred)</p> <p>Topical emollient lubricant or liposomal spray</p> <p>Topical azithromycin</p> <p>Consider oral tetracycline derivatives</p>
3	<p>Moderate <b>symptoms</b> of ocular discomfort, itching or photophobia with limitations of activities</p> <p>Moderate MGD <b>clinical signs</b></p> <p><math>\uparrow</math> lid margin features: plugging, vascularity</p> <p>Moderately altered secretions: Grade <math>\geq 8</math> to <math>&lt; 13</math></p> <p>Expressibility: 2</p> <p>Mild to moderate conjunctival and peripheral corneal <b>staining</b>, often inferior (DEWS grade 8–23; Oxford grade 4–10)</p>	<p><b>All the above, plus</b></p> <p>Oral tetracycline derivatives (+)</p> <p>Lubricant ointment at bedtime (<math>\pm</math>)</p> <p>Anti-inflammatory therapy for dry eye as indicated (<math>\pm</math>)</p>
4	<p>Marked <b>symptoms</b> of ocular discomfort, itching or photophobia with definite limitations of activities</p> <p>Severe MGD <b>clinical signs</b></p> <p><math>\uparrow</math> lid margin features: dropout, displacement</p> <p>Severely altered secretions: Grade <math>\geq 13</math></p> <p>Expressibility: 3</p> <p>Increased conjunctival and corneal <b>staining</b>, including central staining (DEWS grade 24–33; Oxford grade 11–15)</p> <p><math>\uparrow</math> Signs of inflammation: e.g., <math>\geq</math> moderate conjunctival hyperemia, phlyctenules</p>	<p><b>All the above, plus</b></p> <p>Anti-inflammatory therapy for dry eye (+)</p>
		<p><b>KEY</b></p> <p>(+) = supported by evidence; (<math>\pm</math>) = limited or emerging evidence. <b>Meibum quality</b> is assessed in each of 8 glands of the central third of the lower lid on a 0–3 scale for each gland: 0=clear meibum; 1=cloudy meibum; 2=cloudy with debris (granular); 3=thick, like toothpaste (range 0–24).</p> <p><b>Expressibility of meibum</b> is assessed from 5 glands: 0= all glands expressible; 1=3–4 glands expressible; 2=1–2 glands expressible; 3=no glands expressible. This can be assessed in the lower or upper lid.</p> <p><b>Numerical staining</b> scores refer to a summed score of staining of the exposed cornea and conjunctiva. The Oxford scale has a range of 0–15 and the DEWS scale has a range of 0–33.</p>
<p>Go to <a href="http://www.iovs.org/content/52/4.toc">www.iovs.org/content/52/4.toc</a> for the full report.</p>		