

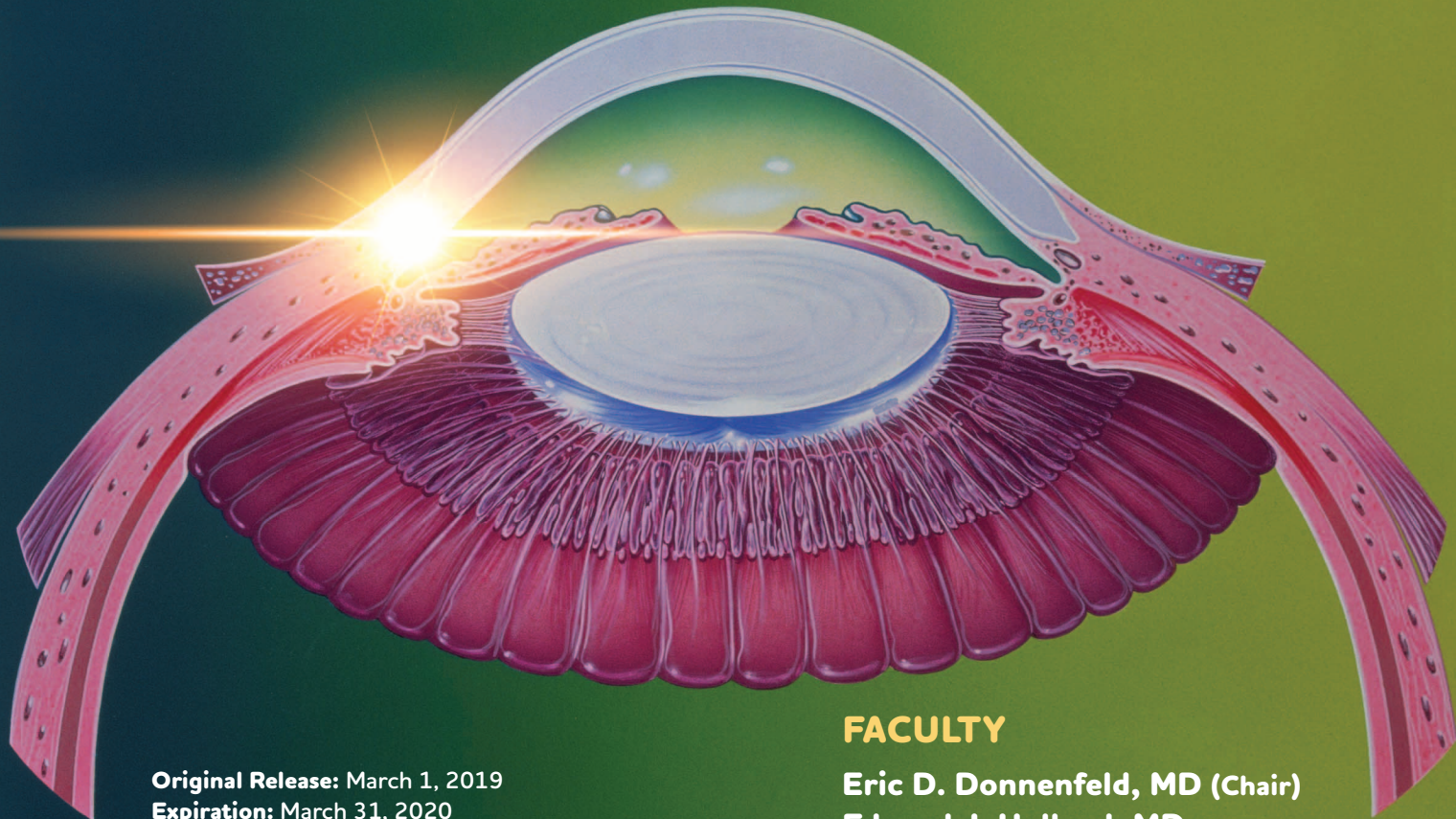
CME Monograph

VISIT [HTTPS://TINYURL.COM/INTRACAMERAL](https://tinyurl.com/intracamerall) FOR ONLINE TESTING AND INSTANT CME CERTIFICATE.

EARN CREDITS  
★ CME ★

## NEW APPROACHES FOR POSTOPERATIVE INFLAMMATION CONTROL

# THE ROLE OF INTRACAMERAL ANTI-INFLAMMATORY AGENTS



**Original Release:** March 1, 2019  
**Expiration:** March 31, 2020

### FACULTY

**Eric D. Donnenfeld, MD (Chair)**  
**Edward J. Holland, MD**  
**Elizabeth Yeu, MD**



This continuing medical education activity is jointly provided by **New York Eye and Ear Infirmary of Mount Sinai** and MedEdicus LLC.



This continuing medical education activity is supported through an unrestricted educational grant from EyePoint Pharmaceuticals.

Distributed with EyeNet

## FACULTY

### ERIC D. DONNENFELD, MD (CHAIR)

Clinical Professor of Ophthalmology  
New York University  
Langone Medical Center  
New York, New York  
Founding Partner  
Ophthalmic Consultants of  
Long Island and Connecticut  
Garden City, New York

### EDWARD J. HOLLAND, MD

Professor of Clinical Ophthalmology  
University of Cincinnati  
Director, Cornea Services  
Cincinnati Eye Institute  
Cincinnati, Ohio

### ELIZABETH YEU, MD

Assistant Professor of Ophthalmology  
Eastern Virginia Medical School  
Corneal, Cataract, and  
Refractive Surgeon  
Partner  
Virginia Eye Consultants  
Norfolk, Virginia

### CME REVIEWER FOR NEW YORK EYE AND EAR INFIRMARY OF MOUNT SINAI

### ROBERT LATKANY, MD

Founder, Dry Eye Clinic  
New York Eye and Ear Infirmary  
of Mount Sinai  
New York, New York

This CME activity is copyrighted to  
MedEdicus LLC ©2019.  
All rights reserved. 171

## LEARNING METHOD AND MEDIUM

This educational activity consists of a supplement and seven (7) study questions. The participant should, in order, read the learning objectives contained at the beginning of this supplement, read the supplement, answer all questions in the post test, and complete the Activity Evaluation/Credit Request form. To receive credit for this activity, please follow the instructions provided on the post test and Activity Evaluation/Credit Request form. This educational activity should take a maximum of 1.0 hour to complete.

## ACTIVITY DESCRIPTION

Patients undergoing ophthalmic surgery are prescribed topical medications to control postoperative inflammation and to prevent pain and other inflammation-related complications. Although the standard anti-inflammatory regimens that have been used are generally safe and effective when properly administered, they are not ideal, considering the likelihood of patient nonadherence and their potential to cause ocular surface damage. The desired results of this activity are to review the challenges accompanying topical anti-inflammatory therapy and present information on strategies for overcoming its limitations, with a focus on a new surgeon-administered intracameral corticosteroid that provides sustained drug release.

## TARGET AUDIENCE

This educational activity is intended for ophthalmologists.

## LEARNING OBJECTIVES

Upon completion of this activity, participants will be better able to:

- Identify optimal strategies for control of postoperative inflammation for patients undergoing ophthalmic surgery
- Discuss the efficacy of intracameral agents to control postoperative inflammation
- Explain the safety of intracameral agents to control postoperative inflammation
- Apply evidence-based approaches for optimal inflammation control in patients undergoing ophthalmic surgery

## ACCREDITATION STATEMENT

This activity has been planned and implemented in accordance with the accreditation requirements and policies of the Accreditation Council for Continuing Medical Education (ACCME) through the joint providership of **New York Eye and Ear Infirmary of Mount Sinai** and **MedEdicus LLC**. The **New York Eye and Ear Infirmary of Mount Sinai** is accredited by the ACCME to provide continuing medical education for physicians.

*In July 2013, the Accreditation Council for Continuing Medical Education (ACCME) awarded New York Eye and Ear Infirmary of Mount Sinai "Accreditation with Commendation," for six years as a provider of continuing medical education for physicians, the highest accreditation status awarded by the ACCME.*



## AMA CREDIT DESIGNATION STATEMENT

The **New York Eye and Ear Infirmary of Mount Sinai** designates this enduring material for a maximum of 1.0 **AMA PRA Category 1 Credit™**. Physicians should claim only the credit commensurate with the extent of their participation in the activity.

## GRANTOR STATEMENT

This continuing medical education activity is supported through an unrestricted educational grant from EyePoint Pharmaceuticals.

## DISCLOSURE POLICY STATEMENT

It is the policy of **New York Eye and Ear Infirmary of Mount Sinai** that the faculty and anyone in a position to control activity content disclose any real or apparent conflicts of interest relating to the topics of this educational activity, and also disclose discussions of unlabeled/unapproved uses of drugs or devices during their presentation(s). **New York Eye and Ear Infirmary**

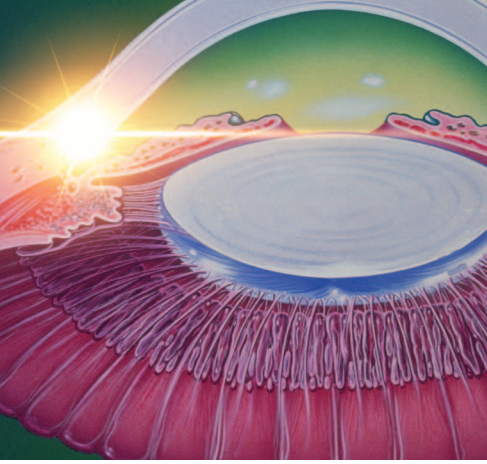
of **Mount Sinai** has established policies in place that will identify and resolve all conflicts of interest prior to this educational activity. Full disclosure of faculty/ planners and their commercial relationships, if any, follows.

## DISCLOSURES

**Eric D. Donnenfeld, MD**, had a financial agreement or affiliation during the past year with the following commercial interests in the form of *Consultant/Advisory Board*: AcuFocus, Inc; Alcon; Allergan; AqueSys, Inc; Avedro, Inc; Bausch & Lomb Incorporated; Beaver-Visitec International; ELENZA, Inc; EyePoint Pharmaceuticals; ForSight Labs, LLC; Glaukos Corporation; Icon Bioscience, Inc; Johnson & Johnson Vision Care, Inc; Kala Pharmaceuticals; Katena Products, Inc; LacriSciences LLP; LensGen; Mati Therapeutics, Inc; Merck & Co., Inc; Mimetogen Pharmaceuticals; NovaBay Pharmaceuticals, Inc; Novaliq GmbH Germany; OcuHub LLC; Odyssey Medical, Inc; Omega Ophthalmics; Omeros Corporation; Oyster Point Pharma, Inc; Pfizer Inc; PogoTec; PRN; Rapid Pathogen Screening, Inc; Shire; Strathspey Crown; Sun Pharmaceutical Industries, Inc; TearLab Corporation; TrueVision; Veracity Innovations LLC; and Zeiss; *Ownership Interest (Stock options, or other holdings, excluding diversified mutual funds)*: AcuFocus, Inc; AqueSys, Inc; Avedro, Inc; ELENZA, Inc; Glaukos Corporation; LacriSciences LLP; LensGen; Mati Therapeutics, Inc; Mimetogen Pharmaceuticals; NovaBay Pharmaceuticals, Inc; OcuHub LLC; PogoTec; Rapid Pathogen Screening, Inc; SARcode Bioscience, Inc; Strathspey Crown; TearLab Corporation; TrueVision; and Veracity Innovations LLC.

**Edward J. Holland, MD**, had a financial agreement or affiliation during the past year with the following commercial interests in the form of *Consultant/Advisory Board*: Aerie Pharmaceuticals, Inc; Azura Ophthalmics Ltd; CorneaGen; Glaukos Corporation; Kala Pharmaceuticals; Katena Products, Inc; Mati Therapeutics, Inc; Novartis Pharmaceuticals Corporation; Omeros Corporation; Precision Lens; Senju Pharmaceutical Co. Ltd; Shire; Sight Sciences; TearLab Corporation; and Vomaris Innovations, Inc; *Contracted Research*: Mati Therapeutics, Inc; Novartis Pharmaceuticals Corporation; Omeros Corporation; and Senju Pharmaceutical Co. Ltd; *Honoraria from promotional, advertising or non-CME services received directly from commercial interests or their Agents (eg, Speakers Bureaus)*: Novartis Pharmaceuticals Corporation; Omeros Corporation; Senju Pharmaceutical Co. Ltd; and Shire.

**Elizabeth Yeu, MD**, had a financial agreement or affiliation during the past year with the following commercial interests in the form of *Consultant/Advisory Board*: Alcon; Allergan; ArcScan, Inc; Aurea Medical; Avedro, Inc; Bausch & Lomb Incorporated; Beaver-Visitec International; Bio-Tissue; Bruder Healthcare; Cassini Technologies; CorneaGen; EyePoint Pharmaceuticals; Glaukos Corporation; Johnson & Johnson Vision Care, Inc; Kala Pharmaceuticals; LENSAR, LLC; Merck & Co., Inc; Mynosys Cellular Devices Inc; Novartis Pharmaceuticals Corporation; Ocular Science; Ocular Therapeutix, Inc; OCuSOFT Inc; Omeros Corporation; Oyster Point Pharma, Inc; ScienceBased Health; Shire; Sun Pharmaceutical Industries, Inc; TearLab Corporation; TearScience; Valeant; Veracity Innovations LLC; and Zeiss; *Contracted Research*: Alcon; Allergan; Bausch & Lomb Incorporated; Bio-Tissue; Cassini Technologies; Kala Pharmaceuticals; and Topcon Medical Systems, Inc; *Ownership Interest (Stock options, or other holdings, excluding diversified mutual funds)*: ArcScan, Inc; CorneaGen; Modernizing Medicine; Ocular Science; Oyster Point Pharma, Inc; and Strathspey Crown.



## NEW APPROACHES FOR POSTOPERATIVE INFLAMMATION CONTROL

# THE ROLE OF INTRACAMERAL ANTI-INFLAMMATORY AGENTS

### NEW YORK EYE AND EAR INFIRMARY OF MOUNT SINAI PEER REVIEW DISCLOSURE

Robert Latkany, MD, has no relevant commercial relationships to disclose.

### EDITORIAL SUPPORT DISCLOSURES

Cheryl Guttman Krader; Melissa Carter-Ozhan; Cynthia Tornallyay, RD, MBA, CHCP; Kimberly Corbin, CHCP; Barbara Aibel; and Michelle Ong have no relevant commercial relationships to disclose.

### DISCLOSURE ATTESTATION

The contributing physicians listed above have attested to the following:

- 1) that the relationships/affiliations noted will not bias or otherwise influence their involvement in this activity;
- 2) that practice recommendations given relevant to the companies with whom they have relationships/affiliations will be supported by the best available evidence or, absent evidence, will be consistent with generally accepted medical practice; and
- 3) that all reasonable clinical alternatives will be discussed when making practice recommendations.

### OFF-LABEL DISCUSSION

This CME activity includes discussion of unlabeled and/or investigative uses of drugs. Please refer to the official prescribing information for each drug discussed in this activity for FDA-approved dosing, indications, and warnings.

New York Eye and Ear Infirmary of Mount Sinai Privacy & Confidentiality Policies <http://www.nyee.edu/health-professionals/cme/enduring-activities>

### CME Provider Contact Information

For questions about this activity, call 212-870-8127.

### TO OBTAIN AMA PRA CATEGORY 1 CREDIT™

To obtain AMA PRA Category 1 Credit™ for this activity, read the material in its entirety and consult referenced sources as necessary. Please take this post test and evaluation online by going to <https://tinyurl.com/Intracameral>. Upon passing, you will receive your certificate immediately. You must score 70% or higher to receive credit for this activity, and may take the test up to 2 times. Upon registering and successfully completing the post test, your certificate will be made available online and you can print it or file it.

### DISCLAIMER

The views and opinions expressed in this educational activity are those of the faculty and do not necessarily represent the views of New York Eye and Ear Infirmary of Mount Sinai, MedEdicus LLC, EyePoint Pharmaceuticals, EyeNet, or the American Academy of Ophthalmology.

## LIMITATIONS OF CONVENTIONAL MANAGEMENT OF POSTOPERATIVE INFLAMMATION

All surgery induces tissue trauma, triggering inflammation that can lead to pain and complications if left untreated. Although advances in techniques and technologies have made modern cataract surgery much less traumatic than in the past, cystoid macular edema (CME) associated with inflammation remains the leading cause of visual impairment after uncomplicated cataract surgery.<sup>1</sup>

To prevent inflammation and its consequences, cataract surgeons typically use topical anti-inflammatory regimens combining a corticosteroid with a nonsteroidal anti-inflammatory drug (NSAID).<sup>2</sup> This approach, however, has several drawbacks. First, its efficacy depends on patient adherence, which is notoriously poor for topical ophthalmic medications.<sup>3,4</sup> In a study of 28 patients using a fixed-combination corticosteroid/antibiotic drop after cataract or glaucoma surgery, Hermann and colleagues found that only 50.2% of patients applied the correct number of drops, and 4 patients with cataract stopped using their medication early.<sup>4</sup>

There are many potential explanations for medication nonadherence. Patients might not use their eye drops as directed because they forget, the regimen is too complex and burdensome, or the medications cause discomfort when instilled. In addition, many patients are unable to accurately deliver drops into their eyes or have physical problems that limit their ability to dispense the medication from the bottle.<sup>5,6</sup> Some patients might even fail to acquire their medication because of cost.

Achieving a high concentration of anti-inflammatory drug at the target site immediately after surgery is important for preventing inflammation. With topical medications, however, bioavailability is limited because of washout from the ocular surface after administration and because of the need to penetrate through anatomic barriers.<sup>7</sup> Furthermore, with the use of corticosteroid suspensions, the dose dispensed during the first days of use can be suboptimal if the patient does not shake the container adequately to achieve a homogenous distribution of the settled drug particles.<sup>8</sup> In a study evaluating patient compliance with the direction to shake the corticosteroid suspension before use, nearly two-thirds of patients did not shake the bottle at all, and three-fourths of those who shook the bottle did not shake it enough times to dispense the labeled concentration of drug.<sup>8</sup>

In addition to the issues that can compromise treatment efficacy, there are safety issues accompanying the use of topical therapy. These include the potential for overuse, ocular surface toxicity, and intraocular pressure (IOP) elevations from exposure to high peak concentrations of corticosteroid and prolonged use.

## STRATEGIES THAT IMPROVE DRUG DELIVERY

New and emerging innovations in topical therapy and alternative methods of drug delivery offer strategies for circumventing the limitations of conventional topical anti-inflammatory treatment.

### Topical Treatment

Topical NSAIDs that can be used just once or twice daily can improve treatment adherence and safety by minimizing drop burden and simplifying the dosing regimen for patients. In addition, a new formulation of loteprednol etabonate—the first topical corticosteroid indicated for twice-daily use to treat postoperative inflammation and pain following ocular surgery—has been approved, and a second new loteprednol etabonate product for twice-daily use is under review by the US Food and Drug Administration (FDA).<sup>9,10</sup> All other topical corticosteroids are recommended to be administered 4 times a day.

The approved product contains loteprednol etabonate suspension, 1.0%, and offers improved drug bioavailability by using proprietary mucus-penetrating particle technology to carry the active ingredient through the tear film's mucous layer.<sup>9,11</sup> In 2 phase 3 clinical trials, loteprednol etabonate, 1.0%, with mucus-penetrating particle technology demonstrated statistically significant superiority to vehicle in the primary outcome measures analyzing the proportion of patients achieving complete resolution of anterior chamber cells (ACCs) and complete resolution of ocular pain at postoperative days 8 and 15 ( $P < .01$  for all comparisons).<sup>12</sup> The most common adverse events reported in the clinical trials were eye pain and posterior subcapsular cataract formation, likely the result of surgery. Intraocular pressure should be monitored if the drops are used for  $\geq 10$  days.

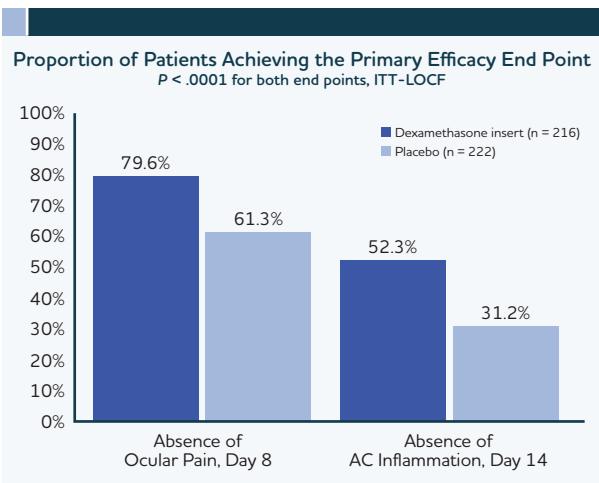
The other twice-daily loteprednol etabonate product is a submicron gel preparation containing loteprednol etabonate, 0.38%.<sup>10</sup> The submicron particle technology improves bioavailability by

helping to increase ocular penetration and residence time in anterior segment tissues. In a phase 3 study, patients were randomized 1:1:1 to 14 days of twice-daily ( $n = 171$ ) or 3-times-daily ( $n = 171$ ) treatment with the submicron loteprednol etabonate, 0.38%, gel or vehicle ( $n = 172$ ).<sup>13</sup> The rate of complete resolution of ACCs was significantly higher in both the twice-daily and 3-times-daily loteprednol etabonate groups than in the vehicle group (26.9% and 28.7% vs 9.3%, respectively;  $P < .0001$ ). The percentage of patients reporting grade 0 pain on day 8 was also significantly higher in both loteprednol etabonate groups than in the vehicle group (73.7% and 73.1% vs 47.7%, respectively;  $P < .0001$ ). Adverse events were comparable between the 2 loteprednol etabonate groups, with eye pain, photophobia, and foreign body sensation being the most common. Two patients using loteprednol etabonate twice daily had an IOP increase  $\geq 10$  mm Hg.

### External Sustained-Release Delivery Systems

Alternatives to conventional topical drops that provide sustained drug delivery are attractive because of their benefits for maintaining a constant therapeutic drug concentration at the target site and for eliminating treatment adherence as an issue. Within this category, 2 externally placed devices are being developed as a treatment for controlling postoperative ocular pain and inflammation after ocular surgery.

One product is a dexamethasone-eluting punctal plug, or insert, that is placed into the inferior distal horizontal canaliculus at the end of surgery; it provides tapered drug delivery to the ocular surface over a 30-day period, after which it dissolves and clears via the nasolacrimal system.<sup>14,15</sup> Results of a phase 3 study showed the dexamethasone intracanalicular insert ( $n = 216$ ) was superior to placebo (vehicle) ( $n = 222$ ) in the primary efficacy end points analyzing the percentage of patients achieving complete absence of ocular pain at day 8 (79.6% vs 61.3%;  $P < .0001$ ) and complete absence of ACCs at day 14 (52.3% vs 31.2%;  $P < .0001$ ) (Figure 1).<sup>15</sup> The most common ocular adverse events in patients receiving the dexamethasone insert in the study were eye inflammation, anterior chamber inflammation, and increase in IOP. These events were comparable to those of patients receiving the placebo.



**Figure 1. Intracanalicular dexamethasone insert reduced pain and inflammation following cataract surgery in the primary efficacy analysis of a phase 3 study<sup>15</sup>**

Abbreviations: AC, anterior chamber; ITT, intent to treat; LOCF, last observation carried forward.

A silicone punctal plug system containing the NSAID nepafenac is also in development and is being investigated in a phase 2 study.<sup>16</sup> The plug is inserted into the lower punctum 2 days prior to cataract surgery and remains for 2 weeks after the procedure. Results from a planned interim analysis performed after approximately 50% of patients were enrolled showed that on postoperative day 3, pain was absent in 71% of patients receiving the nepafenac plug and in 12% of control patients.<sup>17</sup> Data on inflammation scores also favored the active treatment group, and no unexpected side effects were reported. Unlike the intracanalicular insert, the nepafenac-containing plug does not dissolve, but it can be removed and replaced relatively easily.<sup>18</sup>

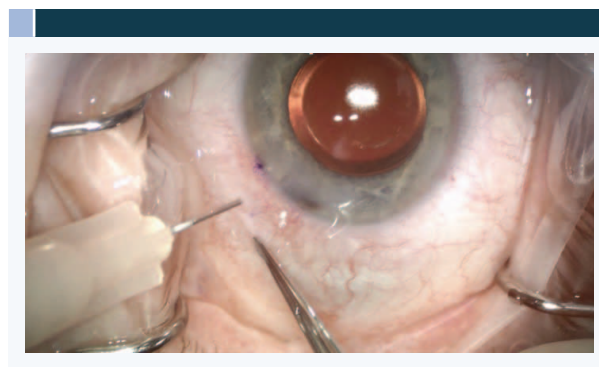
### Intraocular Drug Delivery

Compared with the punctal plug systems, intraocular drug delivery offers the advantage of immediate medication exposure at the target site, which, in theory, could optimize efficacy and reduce or even eliminate the need for postoperative topical treatment.

**Intravitreal Delivery.** Intraocular delivery of a corticosteroid is currently being performed by some cataract surgeons using a proprietary compounded corticosteroid/antibiotic combination (triamcinolone acetonide 3.0 mg/moxifloxacin 0.2 mg) that is injected into the anterior vitreous via a transzonular approach.<sup>19,20</sup> In an analysis of 1541 cases of cataract surgery, 1413 (92%) did not require supplemental medication postoperatively.<sup>20</sup>

This and another study reported a 2% rate of CME and a 5% to 9% rate of breakthrough pain/inflammation requiring rescue topical corticosteroid.<sup>19,20</sup> In addition, the compounded combination can cause blurred vision and floaters that can persist for at least 7 days.<sup>20</sup> Furthermore, cataract surgeons might not feel comfortable performing the transzonular injection—which can lead to zonular damage—or with the idea of entering the vitreous during an anterior segment procedure. The product is not FDA approved or eligible for any reimbursement.

**Intracameral Delivery.** Intracameral injection of a corticosteroid represents an alternative approach to intraocular corticosteroid delivery (**Figure 2**). A preservative-free formulation of triamcinolone acetonide for intraocular use is commercially available and might be used during cataract surgery to stain the vitreous in cases in which there is posterior capsule compromise.<sup>21,22</sup> Its use to control inflammation after cataract surgery is off-label, but there are published reports of its efficacy in reducing inflammation without the occurrence of any serious adverse events.<sup>23-25</sup>

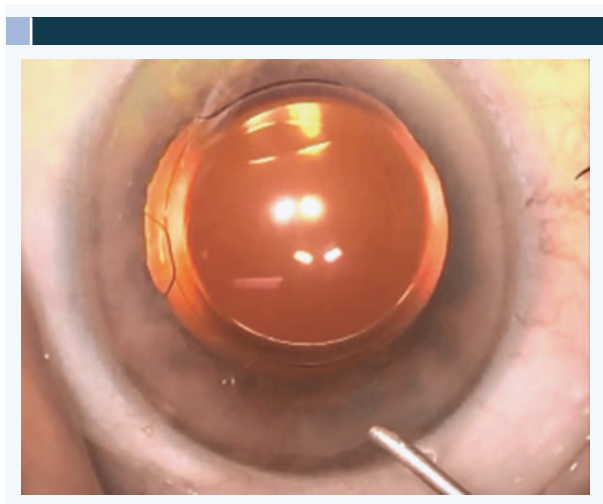


**Figure 2. Intracameral injection of triamcinolone acetonide.** Visit <https://tinyurl.com/Intracameral>.

Video courtesy of Eric D. Donnenfeld, MD

Dexamethasone intraocular suspension, 9%, (IBI-10090) was the first intracameral agent approved by the FDA for the treatment of postoperative inflammation.<sup>26</sup> The medication is administered as a 5- $\mu$ L dose into the posterior chamber inferiorly behind the iris at the end of the surgery (**Figure 3**). Using a novel, bioabsorbable drug delivery system, the product releases dexamethasone into the anterior chamber in a controlled manner with a tapering profile for up to 21 days.<sup>27</sup> The dexamethasone suspension is opaque, and as the droplet disperses in the eye, it can be associated with a mild reduction in vision for a few days.<sup>28</sup>

The results of 2 phase 3 trials established the efficacy and safety of the intracameral dexamethasone suspension.<sup>27,28</sup> The first, a double-masked clinical trial, randomized 394 patients undergoing cataract surgery into 3 groups (2:2:1): dexamethasone suspension 342 µg (n = 158); dexamethasone suspension 517 µg (dose in the commercially available product) (n = 156); and placebo (n = 80).<sup>27</sup> Patients were followed for 90 days after surgery.



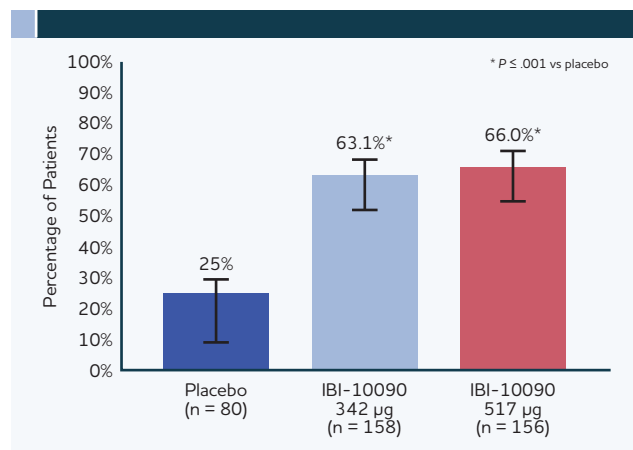
**Figure 3.** Intracameral injection of dexamethasone intraocular suspension, 9%. Visit <https://tinyurl.com/Intracameral>.

Video courtesy of Eric D. Donnenfeld, MD

The primary end point evaluated ACC clearing (ACC score = 0) at day 8, and found that the rate was significantly higher in both the low- and high-dose dexamethasone groups than in the placebo group (63.1% and 66.0% vs 25.0%, respectively;  $P \leq .001$  for both doses vs placebo) (Figure 4).<sup>27</sup> On postoperative day 8, rescue medication was used by 3 patients (1.9%) in each of the dexamethasone groups compared with 13 patients (16.3%) in the control group.

The intracameral dexamethasone product had an acceptable safety profile, with a lower overall incidence of treatment-emergent adverse events, compared with placebo.<sup>27</sup> During the entire follow-up period, an IOP increase  $\geq 10$  mm Hg occurred in 13% of patients receiving placebo, in 21% of patients receiving dexamethasone 342 µg, and in 29% of patients receiving dexamethasone 517 µg.

The second phase 3 study compared dexamethasone intraocular suspension 517 µg (n = 126) with topical prednisolone acetate, 1%, (n = 55) administered 4 times a day for 3 weeks in 194 patients undergoing cataract surgery.<sup>28</sup> This was an open-label study



**Figure 4.** Percentage of patients with anterior chamber cell grade 0 at day 8 in a double-masked phase 3 trial of intracameral sustained-release dexamethasone (IBI-10090).<sup>27</sup> The last-observation-carried-forward method was used to impute missing data. Treatment failure was assumed if a patient received rescue medication.

Reprinted from *Ophthalmology*, 125, Donnenfeld E, Holland E, Dexamethasone intracameral drug-delivery suspension for inflammation associated with cataract surgery: a randomized, placebo-controlled, phase III trial, 799-806. Copyright 2018, with permission from Elsevier.

designed with a primary objective to evaluate safety. Efficacy was analyzed as an exploratory end point. The results showed the 2 treatments were similarly effective for controlling postoperative inflammation. Rates of ACC clearing at day 8 were 51.6% in the patients receiving dexamethasone and 50.9% in the patients receiving topical prednisolone acetate. Rescue medication was used by 13 patients (10.3%) receiving dexamethasone and by none of the patients receiving topical prednisolone acetate.

The safety evaluation showed that both treatments were associated with transient increases in IOP.<sup>28</sup> The elevations occurred on the first postoperative day, and there were more cases of increased IOP in the dexamethasone intraocular suspension group than in the topical prednisolone acetate group (14/126 [11.1%] vs 2/55 [3.6%]). In all cases, the IOP on the first postoperative day was  $< 21$  mm Hg. Only 1 patient in the dexamethasone intraocular suspension group required treatment for elevated IOP, which resolved by postoperative day 8. Mean IOP in the intraocular dexamethasone group returned to the baseline level by day 3 postoperatively and remained stable throughout follow-up. The investigators suggested that demographic differences between the treatment groups might explain the higher rate of early increased IOP in the dexamethasone intraocular suspension group. Mean change from baseline in endothelial cell count was similar in the 2 groups.

## CASE DISCUSSION: CHOOSING ANTI-INFLAMMATORY THERAPY FOR A PATIENT NEEDING CATARACT SURGERY

From the Files of Elizabeth Yeu, MD

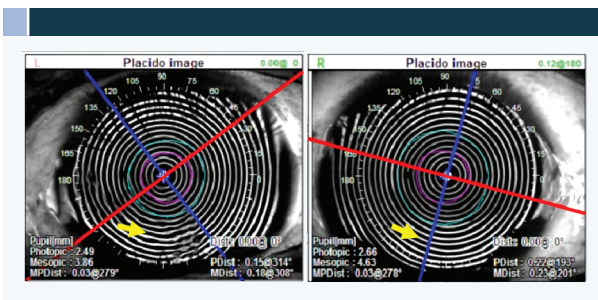
A 72-year-old Filipino man presented for cataract evaluation. He lives in the Philippines, and visits family in the United States once a year.

His current medical problems included type 2 diabetes mellitus, hypertension, hypercholesterolemia, benign prostatic hyperplasia, digital arthropathy, and mild hand tremor. He was taking sitagliptin, empaglifozin, glimepiride, metformin, losartan, simvastatin, and alfuzosin, and was using artificial tears for occasional dry eye symptoms.

The patient's manifest refraction (best-corrected visual acuity) was +1.50 +0.50 × 155 (20/40) OD and +2.75 +0.25 × 007 (20/40) OS. He stated that he was interested in spectacle independence after surgery.

Slit-lamp examination identified capping of the meibomian glands and midtemporal conjunctival chalasis. Staining showed trace punctate epithelial erosions OD and 1 to 2+ punctate epithelial erosions OS. The anterior chamber was deep and quiet. He had a 3+ nuclear sclerotic cataract OD and 2+ cortical cataract OS. The patient had brown, velvety irides, and both pupils dilated to only 5 mm. The dilated fundus examination result was normal, cup-to-disc ratio was 0.2 OU, and he had no retinopathy or macular pathology.

Meibography showed truncation of at least one-third of the meibomian glands. Consistent with the corneal staining, distortion of the inferior mires was noted on the Placido topography image of the left eye (**Figure 5**).



**Figure 5.** Original topography images of both eyes of the case patient at the preoperative visit

Image courtesy of Elizabeth Yeu, MD

## Discussion

**Dr Yeu:** Patients today have high expectations for outcomes after cataract surgery. In my experience, this is particularly true of patients who are in the Baby Boomer generation. Many of these individuals, who now comprise the 54- to 74-year-old age group, are still working, active, and have disposable income. Often, they are interested in minimizing the need to wear glasses after surgery, and—partly because they are paying out of pocket for an advanced technology intraocular lens (IOL)—they are expecting to have a complication-free postoperative course, with fast recovery of good uncorrected vision.

Preventing postoperative inflammation is critical for meeting expectations and achieving satisfaction in these patients, and is important in all cataract surgery patients for minimizing pain, preventing complications, and optimizing vision. When I am operating on older patients, I am particularly worried about treatment nonadherence that will increase their risk for postoperative inflammation.

The patient in this case falls into the first group, but there are also findings in his history and examination that raise concern about controlling postoperative inflammation, and that should be considered for surgical planning. First, he has diabetes, which is a risk factor for postoperative macular edema.<sup>29</sup> In addition, because he is using alfuzosin and his pupil dilates poorly, he is at risk for intraoperative complications that can lead to increased inflammation after surgery.<sup>2,30</sup> He also has a brown iris, which has been associated with more severe and more persistent postoperative inflammation.<sup>31,32</sup> Furthermore, he has physical issues that can compromise his ability to successfully use topical drops, and because he has marginally compensated dry eye disease (DED), it is important to minimize his use of topical drops because they can worsen the DED.

Optimizing the ocular surface by treating this patient's DED was the first issue that needed to be addressed. An unstable tear film affects the accuracy of keratometric readings and affects vision, and DED can worsen after cataract surgery.<sup>30</sup> When patients with DED are potential candidates for a diffractive IOL, I start them on an aggressive treatment regimen that includes a topical corticosteroid, and I have them return after 2 or 3 weeks. If I see they have responded well, I am more confident about using a diffractive IOL, but I also create a “contract” with these patients, asking them to commit to continue maintenance treatment for their DED.

## Case Continued

The patient was started on treatment for his DED, with nonpreserved artificial tears, loteprednol etabonate, 0.5%, 3 times a day, and an oral omega-3 supplement. When he returned after 3 weeks, his ocular surface was improved, and he was scheduled for surgery.

## Discussion

**Dr Yeu:** What have you been using as your perioperative medication regimen to prevent inflammation in routine cataract surgery?

**Dr Donnenfeld:** I start patients on a topical NSAID 3 days before surgery and continue the NSAID in uncomplicated cases for 1 month postoperatively. I prefer that patients use 1 of the NSAIDs that is approved for once-daily administration—either bromfenac, 0.07%, or nepafenac, 0.3%. Ketorolac, 0.5%, 4 times a day is particularly damaging to the ocular surface, and I avoid this medication whenever possible.<sup>33</sup>

Depending on the patient's insurance coverage, I will prescribe either a brand name or a generic topical corticosteroid. I like to use difluprednate, 0.05%, because of its potency,<sup>34</sup> and I prescribe it to be administered twice daily for 2 weeks and then once daily for another week.

**Dr Holland:** I use twice-daily topical difluprednate as my postoperative corticosteroid, but I am considering using the new twice-daily loteprednol etabonate, 1%. I am also interested in intracameral dexamethasone suspension when it is available. Regarding nonsteroidals, I start patients on 1 of the once-daily NSAIDs, and continue it for 1 month after surgery in routine cases and for 3 months in patients with diabetes or in those who have other risk factors for CME.

**Dr Yeu:** What would be your approach to control inflammation in a patient like this who has multiple risk factors for postoperative inflammation and issues that can limit his ability to use topical drops?

**Dr Donnenfeld:** The goal should be to eliminate inflammation—not just suppress it—and accomplishing this requires having a high level of anti-inflammatory medication in the eye immediately after surgery and maintaining coverage during a sufficiently long period postoperatively. Topical treatment with a corticosteroid suspension is not a good option because most patients do not shake their medication bottle adequately, and therefore can be getting a subtherapeutic dose in the initial days after surgery.<sup>8</sup> We also know that patients might stop using their

medication prematurely.<sup>4</sup> It is my clinical impression that medication noncompliance is an underlying cause in approximately 50% of the cases I see with a complication after uneventful cataract surgery.

A subconjunctival corticosteroid injection can be effective, although it is not very comfortable for patients. The European Society of Cataract and Refractive Surgeons conducted a prospective, randomized, controlled clinical trial to compare the efficacy of different approaches for reducing the risk of CME after uneventful cataract surgery and found a benefit for adding subconjunctival triamcinolone acetonide to topical treatment with bromfenac and dexamethasone in a high-risk group of patients with diabetes.<sup>35</sup>

I have had experience with the corticosteroid-containing compounded product that is administered through the zonules, but I stopped using it after some patients developed a vitreous hemorrhage.

My preference for a patient like this would be to use the surgeon-administered dexamethasone intraocular suspension because it assures immediate delivery of the corticosteroid to the target site and avoids the problem of nonadherence. I first came to appreciate the efficacy of intracameral corticosteroids for controlling intraocular inflammation in a case involving a patient with endothelial allograft rejection after penetrating keratoplasty.<sup>36</sup> The patient was resistant to intensive topical therapy and to a subconjunctival triamcinolone acetonide injection, but responded within 2 weeks to an intracameral triamcinolone acetonide injection.

Another advantage of using the dexamethasone intraocular suspension is that it has been granted pass-through status and reimbursement by the Centers for Medicare & Medicaid Services.<sup>37</sup> With pass-through status, the medication is provided at no cost to Medicare patients, the surgery center, and the surgeon. It should be mentioned that although the phase 3 studies of the dexamethasone intraocular suspension focused on patients undergoing cataract surgery,<sup>27,28</sup> this product can be used to prevent inflammation after other types of ocular surgery, including corneal transplantation or glaucoma procedures.

**Dr Holland:** I have never used the proprietary compounded intravitreal product containing triamcinolone because putting the corticosteroid in the vitreous never made sense to me. Administering triamcinolone as a sub-Tenon injection can be very effective for controlling inflammation.<sup>38</sup> As a downside, however, it can lead to subconjunctival hemorrhage in a



patient who otherwise would have a quiet, white eye after meticulous, uncomplicated cataract surgery.

I think there is a much stronger rationale for placing the corticosteroid in the anterior chamber, which is the site of the inflammation, rather than in the vitreous. I agree that there is a strong basis for minimizing the need for topical drops in the patient in this case, and I would use the dexamethasone intraocular suspension.

**Dr Yeu:** I also do not like to use the intravitreal corticosteroid and antibiotic injection because of the potential increase in positive pressure, the transient floater that persists for a couple of days, and for the potential increased risk of retinal detachment. A sub-Tenon or intracameral corticosteroid injection at the end of the case provides a high concentration of anti-inflammatory drug at the target site. When these approaches are done using medications off-label, we can expect some extended duration of activity, but they do not provide a sufficient length of coverage, so patients also need to use topical anti-inflammatory drops.

The dexamethasone intraocular suspension was not available when I operated on this patient. I treated him with an intracameral injection of a compounded combination of dexamethasone and moxifloxacin and prescribed a compounded drop containing an antibiotic, corticosteroid, and NSAID that would reduce the total drop burden and minimize the potential for nonadherence and ocular surface toxicity. Now that the dexamethasone intraocular suspension is available and FDA approved,<sup>26</sup> it is a viable option, considering it provides sustained drug delivery and has demonstrated safety.<sup>27,28</sup>

**Dr Holland:** The dexamethasone intraocular suspension had a favorable safety profile in the phase 3 clinical trials.<sup>27,28</sup> The transient increases in IOP that were observed postoperatively during the trials are probably attributable to retained viscoelastic because steroid-induced IOP elevation with topical or intraocular treatment generally does not develop until later.<sup>28,39</sup>

**Dr Donnenfeld:** There is a theoretical concern about IOP elevation with any intraocular corticosteroid injection, but the tapered-release profile provided by the delivery platform explains, in part, the low rate of IOP elevations in patients who received the dexamethasone intraocular suspension in the FDA trials.<sup>27,28</sup>

### Case Continued

Surgery was performed on the patient's left eye first, with implantation of a +3.25 D add multifocal IOL. The second eye surgery was done 10 days later, with

implantation of an extended-depth-of-focus IOL. The surgeries were performed with intracameral fixed-combination ketorolac/phenylephrine in the irrigating solution to maintain pupil dilation and control postoperative pain.

Intracameral compounded moxifloxacin/dexamethasone was injected at the end of the case. The patient was prescribed a compounded topical combination of gatifloxacin, 0.3%/prednisone acetate, 1%/ketorolac, 0.5%, 4 times daily for 2 weeks, followed by bromfenac, 0.07%, once daily for 3 weeks.

The patient was very happy with his outcome. At 2 weeks after the second eye surgery, his distance and near uncorrected visual acuity was 20/20- and J4 OD and 20/20 and J2 OS. He is continuing to take the oral omega-3 supplement, and his wife can administer his ophthalmic drops.

### Discussion

**Dr Yeu:** Investigators who conducted a preclinical study measuring ketorolac concentrations in the aqueous and vitreous after cataract surgery suggested that use of the commercially available fixed combination of intracameral phenylephrine/ketorolac might preclude the need for an NSAID postoperatively.<sup>40</sup> With this in mind and considering that in the phase 3 trials, approximately 50% to 65% of patients receiving the dexamethasone intraocular suspension had no evidence of inflammation at 8 days after surgery,<sup>27,28</sup> I am thinking about eliminating the topical NSAID from my postoperative regimen in routine cases when I use the 2 intracameral medications.

What are your thoughts about the need for using an NSAID for inflammation control when using the dexamethasone intraocular suspension?

**Dr Holland:** I am a big believer in using NSAIDs postoperatively until we have evidence from a prospective comparative clinical trial to show that they do not add a benefit for controlling postoperative pain and reducing the incidence of CME.

**Dr Donnenfeld:** There is a potential anti-inflammatory benefit associated with the use of intracameral ketorolac in the irrigating solution, but I agree that we need studies to show we can eliminate the NSAID after surgery.

To prevent endophthalmitis after cataract surgery, I am using intracameral moxifloxacin at the end of the procedure, although I still prescribe a topical antibiotic to be used for 8 days after surgery. By reducing postoperative drop burden, intracameral administration

of the antibiotic and the corticosteroid provides an enormous benefit for improving the quality of life of patients and overcoming the issue of medication adherence.

**Dr Holland:** I have used intracameral moxifloxacin for endophthalmitis prophylaxis in the past, but I am not currently using it. I think we need a product in the United States that is FDA approved for that indication, and I think this might come after completion of the American Society of Cataract and Refractive Surgery–sponsored TIME (Topical Versus Intracameral Moxifloxacin Endophthalmitis Prophylaxis) study. I foresee that we will eventually use intracameral moxifloxacin, the intracameral dexamethasone suspension, and an NSAID-eluting punctal plug that will give us a drop-free regimen for preventing pain, inflammation, and endophthalmitis after cataract surgery.

## TAKE-HOME MESSAGES

Inflammation control after ocular surgery is important for reducing pain and other complications, for optimizing visual recovery, and for achieving patient satisfaction.

Cataract surgeons typically use a topical treatment regimen combining a corticosteroid with an NSAID to prevent postoperative inflammation and its consequences, but topical treatments have several disadvantages.

- Poor patient adherence and difficulties with administration of eye drops can compromise efficacy
- Topical treatments can cause or worsen ocular surface disease that is already prevalent in the cataract surgery population
- Misuse of medications can increase the risk of adverse events

New and emerging topical formulations and drug delivery systems improve delivery of anti-inflammatory medications.

- Topical NSAIDs and corticosteroids in formulations that are designed to improve drug bioavailability allow for reduced dosing frequency, which can improve compliance
- Phase 3 trials of a punctal plug providing sustained release of dexamethasone have been completed, and a nepafenac-eluting punctal plug system is in earlier clinical development
- Transzonular intravitreal delivery of compounded triamcinolone/moxifloxacin and intracameral triamcinolone injection are being used by some surgeons, but have drawbacks
- Dexamethasone intraocular suspension is an FDA-approved option that has proven to be safe and effective for controlling inflammation after cataract surgery

## REFERENCES

1. Kim SJ, Schoenberger SD, Thorne JE, Ehlers JP, Yeh S, Bakri SJ. Topical nonsteroidal anti-inflammatory drugs and cataract surgery: a report by the American Academy of Ophthalmology. *Ophthalmology*. 2015;122(11):2159-2168.
2. American Academy of Ophthalmology. *Cataract in the Adult Eye Preferred Practice Pattern*<sup>®</sup>. San Francisco, CA: American Academy of Ophthalmology; 2016.
3. Dreer LE, Girkin C, Mansberger SL. Determinants of medication adherence to topical glaucoma therapy. *J Glaucoma*. 2012;21(4):234-240.
4. Hermann MM, Ustündag C, Diestelhorst M. Electronic compliance monitoring of topical treatment after ophthalmic surgery. *Int Ophthalmol*. 2010;30(4):385-390.
5. Dietlein TS, Jordan JF, Lüke C, Schild A, Dinslage S, Kriegelstein GK. Self-application of single-use eyedrop containers in an elderly population: comparisons with standard eyedrop bottle and with younger patients. *Acta Ophthalmol*. 2008;86(8):856-859.
6. Gao X, Yang Q, Huang W, et al. Evaluating eye drop instillation technique and its determinants in glaucoma patients. *J Ophthalmol*. 2018;2018:1376020.
7. Shah TJ, Conway MD, Peyman GA. Intracameral dexamethasone injection in the treatment of cataract surgery induced inflammation: design, development, and place in therapy. *Clin Ophthalmol*. 2018;12:2223-2235.
8. Apt L, Henrick A, Silverman LM. Patient compliance with use of topical ophthalmic corticosteroid suspensions. *Am J Ophthalmol*. 1979;87(2):210-214.
9. Kala Pharmaceuticals. Kala Pharmaceuticals announces FDA approval of Inveltys™ for the treatment of post-operative inflammation and pain following ocular surgery [press release]. <http://investors.kalarx.com/phoenix.zhtml?c=254596&p=irol-newsArticle&ID=2364665>. Published August 23, 2018. Accessed December 20, 2018.
10. PRNewswire. Bausch + Lomb announces publication of pivotal phase 3 data on loteprednol etabonate ophthalmic gel, 0.38% in *Journal of Cataract and Refractive Surgery* [press release]. <https://ir.bauschhealth.com/news-releases/2018/09-05-2018-183757454>. Published September 5, 2018. Accessed December 20, 2018.
11. Schopf L, Enlow E, Popov A, Bourassa J, Chen H. Ocular pharmacokinetics of a novel loteprednol etabonate 0.4% ophthalmic formulation. *Ophthalmol Ther*. 2014;3(1-2):63-72.
12. Inveltys [package insert]. Waltham, MA: Kala Pharmaceuticals, Inc; 2018.
13. Fong R, Silverstein BE, Peace JH, Williams JI, Vittitow JL. Submicron loteprednol etabonate ophthalmic gel 0.38% for the treatment of inflammation and pain after cataract surgery. *J Cataract Refract Surg*. 2018;44(10):1220-1229.

14. Walters T, Endl M, Elmer TR, Levenson J, Majmudar P, Masket S. Sustained-release dexamethasone for the treatment of ocular inflammation and pain after cataract surgery. *J Cataract Refract Surg*. 2015;41(10):2049-2059.
15. Tyson SL, Bafna S, Gira JP, et al; Dextenza Study Group. Multicenter randomized phase 3 study of a sustained-release intracanalicular dexamethasone insert for treatment of ocular inflammation and pain after cataract surgery [published online ahead of print October 24, 2018]. *J Cataract Refract Surg*. doi:10.1016/j.jcrs.2018.09.023.
16. Mali Therapeutics Inc. Safety/efficacy of nepafenac punctal plug delivery system compared to placebo to control ocular pain/inflammation after cataract. <https://clinicaltrials.gov/ct2/show/NCT03496467>. Updated September 25, 2018. Accessed December 20, 2018.
17. Business Wire. Mati Therapeutics interim phase II nepafenac clinical trial results signal significant post-op pain reduction in cataract surgery patients [press release]. <https://www.businesswire.com/news/home/20180904005058/en/Mati-Therapeutics-Interim-Phase-II-Nepafenac-Clinical>. Published September 4, 2018. Accessed December 20, 2018.
18. Holland EJ. Non-invasive punctal plug delivery system offers a host of positive performance characteristics. *Ophthalmology Times*. <http://www.opthalmologytimes.com/modern-medicine-cases/non-invasive-punctal-plug-delivery-system-offers-host-positive-performance-characteristics>. Published March 15, 2017. Accessed December 20, 2018.
19. Lewis JS. Macular edema following intravitreal triamcinolone as an alternative to post cataract anti-inflammatory drops. Poster presented at: 2014 Annual Meeting of the American Academy of Ophthalmology; October 28-21, 2014; Chicago, IL.
20. Tyson SL, Bailey R, Roman JS, Zhan T, Hark LA, Haller JA. Clinical outcomes after injection of a compounded pharmaceutical for prophylaxis after cataract surgery: a large-scale review. *Curr Opin Ophthalmol*. 2017;28(1):73-80.
21. Devgan U. Intraocular use of triamcinolone. *Ocular Surgery News*. <https://www.healio.com/opthalmology/ataract-surgery/news/print/ocular-surgery-news/%7B197d3bf8-09e1-436e-8a64-8338e38ddc7f%7D/intraocular-use-of-triamcinolone>. Published December 15, 2006. Accessed December 20, 2018.
22. Yamakiri K, Uchino E, Kimura K, Sakamoto T. Intracameral triamcinolone helps to visualize and remove the vitreous body in anterior chamber in cataract surgery. *Am J Ophthalmol*. 2004;138(4):650-652.
23. Dixit NV, Shah SK, Vasavada V, et al. Outcomes of cataract surgery and intraocular lens implantation with and without intracameral triamcinolone in pediatric eyes. *J Cataract Refract Surg*. 2010;36(9):1494-1498.
24. Karalezli A, Borazan M, Akova YA. Intracameral triamcinolone acetate to control postoperative inflammation following cataract surgery with phacoemulsification. *Acta Ophthalmol*. 2008;86(2):183-187.
25. Wang B, Dong N, Xu B, Liu J, Xiao L. Efficacy and safety of intracameral triamcinolone acetate to control postoperative inflammation after phacotrabeculectomy. *J Cataract Refract Surg*. 2013;39(11):1691-1697.
26. Business Wire. Icon Bioscience receives FDA approval for DEXYCU™, a potentially transformational drug therapy for treating inflammation associated with cataract surgery. <https://www.businesswire.com/news/home/20180212005404/en/Icon-Bioscience-Receives-FDA-Approval-DEXYCU-TM-Potentially>. Published February 12, 2018. Accessed December 21, 2018.
27. Donnenfeld E, Holland E. Dexamethasone intracameral drug-delivery suspension for inflammation associated with cataract surgery: a randomized, placebo-controlled, phase III trial. *Ophthalmology*. 2018;125(6):799-806.
28. Donnenfeld ED, Solomon KD, Matossian C. Safety of IBI-10090 for inflammation associated with cataract surgery: phase 3 multicenter study. *J Cataract Refract Surg*. 2018;44(10):1236-1246.
29. Chu CJ, Johnston RL, Buscombe C, Sallam AB, Mohamed Q, Yang YC; United Kingdom Pseudophakic Macular Edema Study Group. Risk factors and incidence of macular edema after cataract surgery: a database study of 81984 eyes. *Ophthalmology*. 2016;123(2):316-323.
30. Chang DF, Braga-Mele R, Mamalis N, et al; ASCRS Cataract Clinical Committee. ASCRS White Paper: clinical review of intraoperative floppy-iris syndrome. *J Cataract Refract Surg*. 2008;34(12):2153-2162.
31. Corbett MC, Hingorani M, Boulton JE, Shilling JS. Factors predisposing to postoperative intraocular inflammation. *Eur J Ophthalmol*. 1995;5(1):40-47.
32. Onodera T, Gimbel HV, DeBroff BM. Effects of cycloplegia and iris pigmentation on postoperative intraocular inflammation. *Ophthalmic Surg*. 1993;24(11):746-752.
33. Hovanesian J, Holland E. Tolerability and toxicity of topically applied nepafenac 0.3% compared with generic ketorolac 0.5 [published online ahead of print December 7, 2018]. *J Cataract Refract Surg*. doi:10.1016/j.jcrs.2018.08.039.
34. Donnenfeld ED. Difluprednate for the prevention of ocular inflammation postsurgery: an update. *Clin Ophthalmol*. 2011;5:811-816.
35. Wielders LHP, Schouten JSAG, Winkens B, et al; ESCRS PREMED Study Group. Randomized controlled European multicenter trial on the prevention of cystoid macular edema after cataract surgery in diabetics: ESCRS PREMED Study Report 2. *J Cataract Refract Surg*. 2018;44(7):836-847.
36. Maris PJ Jr, Correnti AJ, Donnenfeld ED. Intracameral triamcinolone acetate as treatment for endothelial allograft rejection after penetrating keratoplasty. *Cornea*. 2008;27(7):847-850.
37. Globe Newswire. EyePoint Pharmaceuticals secures pass-through payment status and assignment of C-code for DEXYCU™. <http://investors.psvida.com/news-releases/news-release-details/eyepoint-pharmaceuticals-secures-pass-through-payment-status-and>. Published September 5, 2018. Accessed December 21, 2018.
38. Khan H, Alam M, Khan A. Comparison of the safety and efficacy of single injection of subtenon triamcinolone and topical dexamethasone in reducing postoperative inflammation after phacoemulsification and intraocular lens implantation. *J Pak Med Assoc*. 2016;66(9):1127-1131.
39. Razeghinejad MR, Katz LJ. Steroid-induced iatrogenic glaucoma. *Ophthalmic Res*. 2012;47(2):66-80.
40. Waterbury LD. Alternative drug delivery for patients undergoing cataract surgery as demonstrated in a canine model. *J Ocul Pharmacol Ther*. 2018;34(1-2):154-160.



## CME POST TEST QUESTIONS

To obtain *AMA PRA Category 1 Credit™* for this activity, complete the CME Post Test and course evaluation **online** at <https://tinyurl.com/Intracameral> (Paper submissions cannot be processed.) Upon successful completion of the post test and evaluation, you will be able to generate an instant certificate of credit.

See detailed instructions at **To Obtain AMA PRA Category 1 Credit™** on page 3.

1. Recently approved and investigational products for optimizing control of postoperative inflammation include all the following, EXCEPT:
  - a. Intracameral dexamethasone intraocular suspension
  - b. Dexamethasone-eluting punctal plug
  - c. Nepafenac-eluting punctal plug
  - d. Sub-Tenon triamcinolone acetonide
2. In a phase 3 placebo-controlled trial, intracameral injection of sustained-release dexamethasone demonstrated a statistically significant benefit for:
  - a. Clearing ACCs
  - b. Controlling postoperative pain
  - c. Preventing postoperative CME
  - d. Reducing macular thickening
3. In a phase 3 study, compared with topical prednisolone acetate, the intracameral injection of dexamethasone intraocular suspension was associated with:
  - a. A lower incidence of IOP spikes
  - b. More endothelial cell loss
  - c. A similar rate of ACC clearing at day 8
  - d. A lower rate of rescue medication use
4. The dexamethasone intraocular suspension delivers the active ingredient for up to \_\_\_\_ days.
  - a. 7
  - b. 14
  - c. 21
  - d. 42
5. An 88-year-old widow who lives independently presents for cataract surgery. Her current problems include osteoarthritis affecting her hands and fingers, hyperlipidemia, and well-controlled type 2 diabetes mellitus. Which treatment would you choose to control postoperative inflammation?
  - a. Intracameral dexamethasone intraocular suspension
  - b. Intravitreal dexamethasone implant
  - c. Once-daily topical nepafenac plus twice-daily loteprednol etabonate, 0.5%, suspension
  - d. Transzonular intravitreal triamcinolone/moxifloxacin
6. A proprietary compounded fixed combination of triamcinolone 3.0 mg/moxifloxacin 0.2 mg is delivered:
  - a. As an erodible pellet into the anterior chamber
  - b. By addition into the surgical irrigating solution
  - c. Into the vitreous through the zonules
  - d. Using a nondegradable conjunctival ring
7. In a study by Hermann and colleagues of patients using a corticosteroid/antibiotic drop after cataract or glaucoma surgery, approximately what percentage of subjects applied the correct number of drops?
  - a. 25%
  - b. 33%
  - c. 50%
  - d. 70%