

PREFERRED PRACTICE PATTERN®



**Diabetic
Retinopathy**

Secretary for Quality of Care
Anne L. Coleman, MD, PhD

Academy Staff
Nicholas P. Emptage, MAE
Doris Mizuri
Shannon Kealey, MLS
Flora C. Lum, MD

Medical Editor: Susan Garratt
Design: Socorro Soberano

Approved by: Board of Trustees
September 20, 2014

Copyright © 2014 American Academy of Ophthalmology®
All rights reserved
Updated January 2016

AMERICAN ACADEMY OF OPHTHALMOLOGY and PREFERRED PRACTICE PATTERN are registered trademarks of the American Academy of Ophthalmology. All other trademarks are the property of their respective owners.

This document should be cited as follows:

American Academy of Ophthalmology Retina/Vitreous Panel. Preferred Practice Pattern® Guidelines. Diabetic Retinopathy. San Francisco, CA: American Academy of Ophthalmology; 2016. Available at: www.aaopt.org/ppp.

Preferred Practice Pattern® guidelines are developed by the Academy's H. Dunbar Hoskins Jr., M.D. Center for Quality Eye Care without any external financial support. Authors and reviewers of the guidelines are volunteers and do not receive any financial compensation for their contributions to the documents. The guidelines are externally reviewed by experts and stakeholders before publication.



RETINA/VITREOUS PREFERRED PRACTICE PATTERN[®] DEVELOPMENT PROCESS AND PARTICIPANTS

The **Retina/Vitreous Preferred Practice Pattern[®] Panel** members wrote the Diabetic Retinopathy Preferred Practice Pattern[®] (“PPP”) guidelines. The PPP Panel members discussed and reviewed successive drafts of the document, meeting in person twice and conducting other review by e-mail discussion, to develop a consensus over the final version of the document.

Retina/Vitreous Preferred Practice Pattern Panel 2013–2014

Timothy W. Olsen, MD, Chair

Ron A. Adelman, MD, MPH, MBA, FACS, Retina Society Representative

Christina J. Flaxel, MD

James C. Folk, MD, American Society of Retina Specialists Representative

Jose S. Pulido, MD, MS, Macula Society Representative

Carl D. Regillo, MD, FACS

Leslie Hyman, PhD, Methodologist

The **Preferred Practice Patterns Committee** members reviewed and discussed the document during a meeting in March 2014. The document was edited in response to the discussion and comments.

Preferred Practice Patterns Committee 2014

Stephen D. McLeod, MD, Chair

Robert S. Feder, MD

Timothy W. Olsen, MD

Bruce E. Prum, Jr., MD

C. Gail Summers, MD

Ruth D. Williams, MD

David C. Musch, PhD, MPH, Methodologist

The Diabetic Retinopathy PPP was then sent for review to additional internal and external groups and individuals in June 2014. All those returning comments were required to provide disclosure of relevant relationships with industry to have their comments considered. Members of the Retina/Vitreous Preferred Practice Pattern Panel reviewed and discussed these comments and determined revisions to the document.

Academy Reviewers

Board of Trustees and Committee of Secretaries
Council

General Counsel

Ophthalmic Technology Assessment Committee
Retina/Vitreous Panel

Basic and Clinical Science Course Subcommittee

Practicing Ophthalmologists Advisory Committee for
Education

Invited Reviewers

American Society of Retina Specialists

Canadian Ophthalmological Society

Central American Retina and Vitreous Society

European Society of Retina Specialists

The Macula Society

National Eye Institute

National Medical Association

Pan-American Retina and Vitreous Society

The Retina Society

Thai Retina Society

Naresh Mandava, MD

Wayne A. Solley, MD



FINANCIAL DISCLOSURES

In compliance with the Council of Medical Specialty Societies' Code for Interactions with Companies (available at www.cmss.org/codeforinteractions.aspx), relevant relationships with industry are listed. The Academy has Relationship with Industry Procedures to comply with the Code (available at www.aao.org/about-preferred-practice-patterns). A majority (86%) of the members of the Retina/Vitreous Preferred Practice Pattern Panel 2013–2014 had no financial relationship to disclose.

Retina/Vitreous Preferred Practice Pattern Panel 2013–2014

Ron A. Adelman, MD, MPH, MBA, FACS: No financial relationships to disclose

Christina J. Flaxel, MD: No financial relationships to disclose

James C. Folk, MD: No financial relationships to disclose

Leslie Hyman, PhD: No financial relationships to disclose

Timothy W. Olsen, MD: No financial relationships to disclose

Jose S. Pulido, MD, MS: No financial relationships to disclose

Carl D. Regillo, MD, FACS: Alcon Laboratories, Inc., Allergan, Inc., Genentech, Inc., Regeneron Pharmaceuticals, Inc., ThromboGenics, Inc. – Consultant/Advisor

Preferred Practice Patterns Committee 2014

Robert S. Feder, MD: No financial relationships to disclose

Stephen D. McLeod, MD: No financial relationships to disclose

David C. Musch, PhD, MPH: Neurotech USA, Inc. – Consultant/Advisor

Timothy W. Olsen, MD: No financial relationships to disclose

Bruce E. Prum, Jr., MD: No financial relationships to disclose

C. Gail Summers, MD: No financial relationships to disclose

Ruth D. Williams, MD: No financial relationships to disclose

Secretary for Quality of Care

Anne L. Coleman, MD, PhD: No financial relationships to disclose

Academy Staff

Nicholas P. Emptage, MAE: No financial relationships to disclose

Susan Garratt: No financial relationships to disclose

Shannon Kealey, MLS: No financial relationships to disclose

Flora C. Lum, MD: No financial relationships to disclose

Doris Mizuiri: No financial relationships to disclose

The disclosures of relevant relationships to industry of other reviewers of the document from January to August 2014 are available online at www.aao.org/ppp.



TABLE OF CONTENTS

OBJECTIVES OF PREFERRED PRACTICE PATTERN GUIDELINES	2
METHODS AND KEY TO RATINGS	3
HIGHLIGHTED FINDINGS AND RECOMMENDATIONS FOR CARE	4
INTRODUCTION	5
Disease Definition	5
Patient Population	5
Clinical Objectives	5
BACKGROUND	5
Introduction	5
Prevalence of Diabetes	6
Prevalence of Diabetic Retinopathy	6
Risk Factors	6
Natural History	7
CARE PROCESS	9
Patient Outcome Criteria	10
Diagnosis	10
History	10
Physical Examination	10
Ancillary Tests	11
Management	13
Prevention and Early Detection of Diabetic Retinopathy	13
Secondary Prevention	13
Medical and Surgical Management	14
Other Treatments	19
Follow-up Evaluation	20
Provider and Setting	20
Physician Quality Reporting System	20
Counseling and Referral	20
Socioeconomic Considerations	21
APPENDIX 1. QUALITY OF OPHTHALMIC CARE CORE CRITERIA	22
APPENDIX 2. INTERNATIONAL STATISTICAL CLASSIFICATION OF DISEASES AND RELATED HEALTH PROBLEMS (ICD) CODES	24
APPENDIX 3. PREFERRED PRACTICE PATTERN RECOMMENDATION GRADING	26
APPENDIX 4. MAJOR STUDY RESULTS	36
APPENDIX 5. GLYCEMIC CONTROL	40
APPENDIX 6. CLASSIFICATION OF DIABETIC RETINOPATHY IN THE EARLY TREATMENT OF DIABETIC RETINOPATHY STUDY	42
GLOSSARY	43
RELATED ACADEMY MATERIALS	48
REFERENCES	49



OBJECTIVES OF PREFERRED PRACTICE PATTERN® GUIDELINES

As a service to its members and the public, the American Academy of Ophthalmology has developed a series of Preferred Practice Pattern® guidelines that **identify characteristics and components of quality eye care**. Appendix 1 describes the core criteria of quality eye care.

The Preferred Practice Pattern® guidelines are based on the best available scientific data as interpreted by panels of knowledgeable health professionals. In some instances, such as when results of carefully conducted clinical trials are available, the data are particularly persuasive and provide clear guidance. In other instances, the panels have to rely on their collective judgment and evaluation of available evidence.

These documents provide guidance for the pattern of practice, not for the care of a particular individual. While they should generally meet the needs of most patients, they cannot possibly best meet the needs of all patients. Adherence to these PPPs will not ensure a successful outcome in every situation. These practice patterns should not be deemed inclusive of all proper methods of care or exclusive of other methods of care reasonably directed at obtaining the best results. It may be necessary to approach different patients' needs in different ways. The physician must make the ultimate judgment about the propriety of the care of a particular patient in light of all of the circumstances presented by that patient. The American Academy of Ophthalmology is available to assist members in resolving ethical dilemmas that arise in the course of ophthalmic practice.

Preferred Practice Pattern® guidelines are not medical standards to be adhered to in all individual situations. The Academy specifically disclaims any and all liability for injury or other damages of any kind, from negligence or otherwise, for any and all claims that may arise out of the use of any recommendations or other information contained herein.

References to certain drugs, instruments, and other products are made for illustrative purposes only and are not intended to constitute an endorsement of such. Such material may include information on applications that are not considered community standard, that reflect indications not included in approved U.S. Food and Drug Administration (FDA) labeling, or that are approved for use only in restricted research settings. The FDA has stated that it is the responsibility of the physician to determine the FDA status of each drug or device he or she wishes to use, and to use them with appropriate patient consent in compliance with applicable law.

Innovation in medicine is essential to ensure the future health of the American public, and the Academy encourages the development of new diagnostic and therapeutic methods that will improve eye care. It is essential to recognize that true medical excellence is achieved only when the patients' needs are the foremost consideration.

All Preferred Practice Pattern® guidelines are reviewed by their parent panel annually or earlier if developments warrant and updated accordingly. To ensure that all PPPs are current, each is valid for 5 years from the "approved by" date unless superseded by a revision. Preferred Practice Pattern guidelines are funded by the Academy without commercial support. Authors and reviewers of PPPs are volunteers and do not receive any financial compensation for their contributions to the documents. The PPPs are externally reviewed by experts and stakeholders, including consumer representatives, before publication. The PPPs are developed in compliance with the Council of Medical Specialty Societies' Code for Interactions with Companies. The Academy has Relationship with Industry Procedures (available at www.aaopt.org/about-preferred-practice-patterns) to comply with the Code.

Appendix 2 contains the International Statistical Classification of Diseases and Related Health Problems (ICD) codes for the disease entities that this PPP covers. The intended users of the Diabetic Retinopathy PPP are ophthalmologists.



METHODS AND KEY TO RATINGS

Preferred Practice Pattern® guidelines should be clinically relevant and specific enough to provide useful information to practitioners. Where evidence exists to support a recommendation for care, the recommendation should be given an explicit rating that shows the strength of evidence. To accomplish these aims, methods from the Scottish Intercollegiate Guideline Network¹ (SIGN) and the Grading of Recommendations Assessment, Development and Evaluation² (GRADE) group are used. GRADE is a systematic approach to grading the strength of the total body of evidence that is available to support recommendations on a specific clinical management issue. Organizations that have adopted GRADE include SIGN, the World Health Organization, the Agency for Healthcare Research and Policy, and the American College of Physicians.³

- ◆ All studies used to form a recommendation for care are graded for strength of evidence individually, and that grade is listed with the study citation.
- ◆ To rate individual studies, a scale based on SIGN¹ is used. The definitions and levels of evidence to rate individual studies are as follows:

I++	High-quality meta-analyses, systematic reviews of randomized controlled trials (RCTs), or RCTs with a very low risk of bias
I+	Well-conducted meta-analyses, systematic reviews of RCTs, or RCTs with a low risk of bias
I-	Meta-analyses, systematic reviews of RCTs, or RCTs with a high risk of bias
II++	High-quality systematic reviews of case-control or cohort studies High-quality case-control or cohort studies with a very low risk of confounding or bias and a high probability that the relationship is causal
II+	Well-conducted case-control or cohort studies with a low risk of confounding or bias and a moderate probability that the relationship is causal
II-	Case-control or cohort studies with a high risk of confounding or bias and a significant risk that the relationship is not causal
III	Nonanalytic studies (e.g., case reports, case series)

- ◆ Recommendations for care are formed based on the body of the evidence. The body of evidence quality ratings are defined by GRADE² as follows:

Good quality	Further research is very unlikely to change our confidence in the estimate of effect
Moderate quality	Further research is likely to have an important impact on our confidence in the estimate of effect and may change the estimate
Insufficient quality	Further research is very likely to have an important impact on our confidence in the estimate of effect and is likely to change the estimate Any estimate of effect is very uncertain

- ◆ Key recommendations for care are defined by GRADE² as follows:

Strong recommendation	Used when the desirable effects of an intervention clearly outweigh the undesirable effects or clearly do not
Discretionary recommendation	Used when the trade-offs are less certain—either because of low-quality evidence or because evidence suggests that desirable and undesirable effects are closely balanced

- ◆ The Highlighted Findings and Recommendations for Care section lists points determined by the PPP Panel to be of particular importance to vision and quality of life outcomes.
- ◆ All recommendations for care in this PPP were rated using the system described above. To locate ratings for specific recommendations, see Appendix 3 for additional information.
- ◆ A literature search to update the PPP was undertaken in June 2013 in PubMed and the Cochrane Library. Complete details of the literature search are available at www.ao.org/ppp.



HIGHLIGHTED FINDINGS AND RECOMMENDATIONS FOR CARE

The prevalence of diabetes, both worldwide and in the United States, is increasing; as such, the prevalence of diabetic retinopathy and vision-threatening diabetic retinopathy (VTDR) is also expected to increase dramatically.

Currently, only about 60% of people with diabetes have yearly screenings for diabetic retinopathy.

People with Type 1 diabetes should have annual screenings for diabetic retinopathy beginning 5 years after the onset of their disease, whereas those with Type 2 diabetes should have a prompt examination at the time of diagnosis and at least yearly examinations thereafter.

Maintaining near-normal glucose levels and near-normal blood pressure lowers the risk of retinopathy developing and/or progressing, so patients should be informed of the importance of maintaining good glycosylated hemoglobin levels, serum lipids, and blood pressure.

Patients with diabetes may use aspirin for other medical indications without an adverse effect on their risk of diabetic retinopathy.

Women who develop gestational diabetes do not require an eye examination during pregnancy and do not appear to be at increased risk of developing diabetic retinopathy during pregnancy. However, patients with diabetes who become pregnant should be examined early in the course of the pregnancy.

Referral to an ophthalmologist is required when there is any nonproliferative diabetic retinopathy, proliferative retinopathy, or macular edema.

Ophthalmologists should communicate both ophthalmologic findings and level of retinopathy to the primary care physician. They should emphasize to the patient the need to adhere to the primary care physician's guidance to optimize metabolic control.

Intravitreal injections of anti-vascular endothelial growth factor (VEGF) agents have been shown to be an effective treatment for center-involving diabetic macular edema and also as an alternative therapy for proliferative diabetic retinopathy.

At this time, laser photocoagulation remains the preferred treatment for non-center-involving diabetic macular edema.



INTRODUCTION

DISEASE DEFINITION

Diabetic retinopathy is a leading cause of visual impairment in working-age adults. Although defects in neurosensory function have been demonstrated in patients with diabetes mellitus prior to the onset of vascular lesions, the most common early clinically visible manifestations of diabetic retinopathy include microaneurysm formation and intraretinal hemorrhages. Microvascular damage leads to retinal capillary nonperfusion, cotton wool spots, increased numbers of hemorrhages, venous abnormalities, and intraretinal microvascular abnormalities (IRMA). During this stage, increased vasopermeability can result in retinal thickening (edema) and/or exudates that may lead to a loss in central visual acuity. The proliferative stage results from closure of arterioles and venules with secondary proliferation of new vessels on the disc, retina, iris, and in the filtration angle. These new vessels then lead to traction retinal detachments and neovascular glaucoma, respectively. Vision can be lost in this stage as a result of capillary nonperfusion or edema in the macula, vitreous hemorrhage, and distortion or traction retinal detachment.

A description of the fundus findings in various stages of diabetic retinopathy is included in the Natural History section, and important terms are defined in the Glossary.

PATIENT POPULATION

The patient population includes all patients with diabetes mellitus.

CLINICAL OBJECTIVES

- ◆ Identify patients at risk of developing diabetic retinopathy.
- ◆ Encourage a collaborative approach between the patient, the primary care physician, and subspecialists in the management of the patient's systemic disorder, with specific attention to control of blood sugar (hemoglobin A_{1c} [HbA_{1c}]), blood pressure, serum lipids, body weight, and management of renal disease, coronary artery disease,⁴ and neuropathy.
- ◆ Encourage and provide lifelong monitoring of retinopathy progression.
- ◆ Treat patients with visual loss or those at risk for visual loss from diabetic retinopathy.
- ◆ Minimize the side effects of treatment that might adversely affect the patient's vision and/or vision-related quality of life.
- ◆ Provide or refer for visual rehabilitation services when a patient has visual impairment from the disease.



BACKGROUND

INTRODUCTION

Two forms of diabetes mellitus are recognized. Type 1, previously called juvenile-onset or insulin-dependent diabetes, is characterized by cellular-mediated autoimmune destruction of the beta-cells in the pancreas and usually leads to severe insulin deficiency. Type 2 diabetes was previously referred to as adult-onset or noninsulin-dependent diabetes. Type 2 is characterized by a range of disease from insulin resistance with relative insulin deficiency to predominately an insulin secretory defect combined with insulin resistance. Type 2 patients usually have a relative rather than an absolute insulin deficiency, may take insulin, yet typically do not need insulin for survival. Many patients with Type 2 diabetes are obese, and obesity itself causes relative insulin resistance. Between 90% and 95% of all patients with diabetes have Type 2 diabetes.⁵ Because of the disproportionately large number of patients with Type 2 diabetes, this group comprises a larger proportion of the disease burden in patients with visual impairment from diabetic retinopathy, even though Type 1 diabetes is associated with more frequent and more severe ocular complications.^{6,7}

Diabetic Retinopathy PPP: Risk Factors

Prevalence of Diabetes

An estimated 25.6 million Americans aged 20 years or older have either been diagnosed or remain undiagnosed with diabetes mellitus (11% of people in this age group),⁸ and about one-third are not aware that they have the disease.⁹ An additional 79 million persons have impaired fasting blood glucose levels (based on both fasting blood glucose levels and HbA_{1c} levels).⁹ In the United States, an estimated three out of five people with diabetes have one or more of the complications associated with the disease.¹⁰ Americans of African descent or Hispanic ethnicity have a disproportionately high prevalence of diabetes compared with Americans of European descent (12.6%, 11.8%, 7.0%, respectively), whereas Asian Americans have only a slightly higher prevalence (8.4%).⁹ Native Americans and Alaskan Natives have an approximate diabetes prevalence of 9%, with a 46% increase between 1990 and 1998 among this group under age 35.^{11,12} Other research suggests a high prevalence of diabetes in Asia.^{13,14} In addition, there is evidence suggesting that diabetes develops at earlier ages and carries a higher incidence of complications among ethnic minorities.¹⁵⁻¹⁷

According to estimates based from the United States Census Bureau data, approximately one-third of Americans are at risk of developing diabetes mellitus during their lifetime.¹⁸ With increasing industrialization and globalization, there is a concomitant increasing prevalence of diabetes that is leading to a worldwide epidemic.¹⁹ An alarming increase in the frequency of Type 2 diabetes in the pediatric age group has been noted in several countries,^{7,20-24} including in the United States, and has been associated with the increased frequency of childhood obesity.²⁵ Diabetes is one of the most common diseases in school-aged children. Clearly, these trends predict an increase in the number of individuals with diabetes as well as the associated increased costs for health care and the burdens of disability associated with diabetes and its complications.

Prevalence of Diabetic Retinopathy

Diabetic retinopathy is a leading cause of new cases of legal blindness among working-age Americans and represents a leading cause of blindness in this age group worldwide.²⁶ The prevalence rate for retinopathy for all adults with diabetes aged 40 and older in the United States is 28.5% (4.2 million people); worldwide, the prevalence rate has been estimated at 34.6% (93 million people). An estimate of the prevalence rate for vision-threatening diabetic retinopathy (VTDR) in the United States is 4.4% (0.7 million people). Worldwide, this prevalence rate has been estimated at 10.2% (28 million people).^{27,28} Assuming a similar prevalence of diabetes mellitus, the projected prevalence of individuals with any diabetic retinopathy in the United States by the year 2020 is 6 million persons, and 1.34 million persons will have VTDR.

RISK FACTORS

Duration of diabetes is a major risk factor associated with the development of diabetic retinopathy. After 5 years, approximately 25% of Type 1 patients will have retinopathy. After 10 years, almost 60% have retinopathy, and after 15 years, 80% have retinopathy.^{29,30} In the Wisconsin Epidemiologic Study of Diabetic Retinopathy (WESDR) for patients ages 30 and younger, proliferative diabetic retinopathy (PDR), the most vision-threatening form of the disease, was present in approximately 50% of Type 1 patients who had the disease for 20 years.³¹ In the Los Angeles Latino Eye Study (LALES) and in Proyecto VER (Vision, Evaluation and Research), 18% of participants with diabetes of more than 15 years' duration had PDR, with no difference in the percentage with PDR between those with Type 1 versus Type 2 diabetes.^{30,32}

Of Type 2 patients over the age of 30 who have a known duration of diabetes of less than 5 years, 40% of those patients taking insulin and 24% of those not taking insulin have retinopathy. These rates increase to 84% and 53%, respectively, when the duration of diabetes has been documented for up to 19 years. Proliferative diabetic retinopathy develops in 2% of Type 2 patients who have diabetes for less than 5 years and in 25% of patients who have diabetes for 25 years or more.³³ Comparisons of information from WESDR and more recent population-based studies such as Proyecto VER and LALES may account for differences in blood glucose and hypertension management that have occurred over time.

Glycemic control is the key modifiable risk factor associated with the development of diabetic retinopathy. Support for this association is based on both clinical trials and epidemiologic studies.³⁴⁻⁴¹ There is general agreement that duration of diabetes and severity of hyperglycemia are the major risk factors for developing retinopathy. Once retinopathy is present, duration of diabetes appears to be a less important factor than glycemic control in forecasting progression from earlier to later stages of retinopathy.^{42,43} It is recommended that a HbA_{1c} of 7% or lower is the target for glycemic control in most patients, whereas in selected patients, there may be some benefit to setting a lower target of 6.5%.⁴⁴ Intensive management of hypertension may slow retinopathy progression, yet the data remain inconclusive.^{45,46} Large studies have suggested that management of serum lipids may reduce retinopathy progression and the need for treatment.⁴⁷⁻⁵⁰ There is less agreement among studies concerning the importance of other factors such as age, type of diabetes, clotting factors, renal disease, physical inactivity, inflammatory biomarkers, and use of angiotensin-converting enzyme inhibitors.^{42,48,51-54} Many of these factors are associated with substantial cardiovascular morbidity and mortality and other complications associated with diabetes. Thus, ophthalmologists should encourage patients with diabetes to be as compliant as possible with therapy of all medical aspects of their disease.⁵⁵

NATURAL HISTORY

Diabetic retinopathy progresses in an orderly fashion from mild to more severe stages when there is not appropriate intervention. It is important to recognize the stages when treatment may be most beneficial. Several decades of clinical research have provided excellent data on the natural course of the disease and on treatment strategies that are 90% effective in preventing the occurrence of severe vision loss.⁵⁶ The outcomes of key clinical trials form a solid foundation in support of treating diabetic retinopathy. The results of these studies are summarized in Appendices 4 and 5. Major studies include the following (see Glossary):

- ◆ Diabetes Control and Complications Trial (DCCT)^{36,57,58}
- ◆ Follow-up study to the DCCT titled Epidemiology of Diabetes Interventions and Complications (EDIC)^{35,37,49,59,60}
- ◆ Diabetic Retinopathy Study (DRS)^{61,62}
- ◆ Early Treatment Diabetic Retinopathy Study (ETDRS)⁶³⁻⁶⁵
- ◆ Diabetic Retinopathy Vitrectomy Study (DRVS)⁶⁶
- ◆ Wisconsin Epidemiologic Study of Diabetic Retinopathy (WESDR)⁶⁷
- ◆ Fenofibrate Intervention and Event Lowering in Diabetes (FIELD) study⁶⁸
- ◆ Action to Control Cardiovascular Risk in Diabetes (ACCORD) trial⁶⁹
- ◆ Diabetic Retinopathy Clinical Research Network (DRCR.net) Protocol I study⁷⁰
- ◆ United Kingdom Prospective Diabetes Study (UKPDS)^{38,45,71}

The nonproliferative stages of diabetic retinopathy are characterized by retinal vascular related abnormalities, such as microaneurysms, intraretinal hemorrhages, venous dilation, and cotton-wool spots. Increased retinal vascular permeability that occurs at these or later stages of retinopathy may result in retinal thickening (edema) and lipid deposits (hard exudates). Clinically significant macular edema (CSME) is a term commonly used to describe retinal thickening and/or adjacent hard exudates that either involve the center of the macula or threaten to involve it. Patients with CSME should be considered for prompt treatment, particularly when the center of the macula is already involved or if retinal thickening and/or hard exudates are very close to the center (see Care Process). Clinically significant macular edema can be divided into center-involving and non-center-involving macular edema. (See Glossary.)

As diabetic retinopathy progresses, there is a gradual closure of retinal vessels that results in impaired perfusion and retinal ischemia. Signs of increasing ischemia include venous abnormalities (e.g., dilation, beading, loops), IRMA, and more severe and extensive vascular leakage characterized by increasing retinal hemorrhages and exudation. When these signs progress beyond certain defined thresholds, severe nonproliferative diabetic retinopathy (NPDR) is diagnosed. Such patients should be considered candidates for treatment with panretinal (scatter) photocoagulation (see Care Process).

**Diabetic Retinopathy PPP:
Disease Severity Scale**

The more advanced stage, PDR, is characterized by the onset of neovascularization at the inner surface of the retina induced by more global retinal ischemia. New vessels on or near the optic disc (NVD) and new vessels elsewhere in the retina (NVE) are prone to bleed, resulting in vitreous hemorrhage. These new vessels may undergo fibrosis and contraction; this and other fibrous proliferation may result in epiretinal membrane formation, vitreoretinal traction bands, retinal tears, and traction or rhegmatogenous retinal detachments. When new vessels are accompanied by vitreous hemorrhage, or when new vessels at the optic disc occupy greater than or equal to about one-quarter to one-third disc area, even in the absence of vitreous hemorrhage, PDR is considered high-risk. (See Glossary.) Neovascular glaucoma can result from new vessels growing on the iris (NVI) and anterior chamber angle structures. Patients with neovascular glaucoma or high-risk PDR should receive prompt panretinal photocoagulation, and their treating ophthalmologist should also consider initiating anti-vascular endothelial growth factor (VEGF) therapy (see Care Process and Glossary).

Table 1 classifies diabetic retinopathy by severity based on clinical findings. In an attempt to improve communication worldwide between ophthalmologists and primary care physicians caring for patients with diabetes, an international clinical disease severity scale has been developed for diabetic retinopathy and macular edema⁷² (See Tables 1 and 2.) This scale is based on the ETDRS classification of diabetic retinopathy and on the data collected from clinical trials and epidemiologic studies of diabetic retinopathy. (See Appendix 6.)

TABLE 1 DIABETIC RETINOPATHY DISEASE SEVERITY SCALE AND INTERNATIONAL CLINICAL DIABETIC RETINOPATHY DISEASE SEVERITY SCALE

Disease Severity Level	Findings Observable upon Dilated Ophthalmoscopy
No apparent retinopathy	No abnormalities
Mild NPDR (see Glossary)	Microaneurysms only
Moderate NPDR (see Glossary)	More than just microaneurysms but less than severe NPDR
Severe NPDR	
U.S. Definition	Any of the following (4-2-1 rule) and no signs of proliferative retinopathy: <ul style="list-style-type: none"> • Severe intraretinal hemorrhages and microaneurysms in each of four quadrants • Definite venous beading in two or more quadrants • Moderate IRMA in one or more quadrants
International Definition	Any of the following and no signs of proliferative retinopathy: <ul style="list-style-type: none"> • More than 20 intraretinal hemorrhages in each of four quadrants • Definite venous beading in two or more quadrants • Prominent IRMA in one or more quadrants
PDR	One or both of the following: <ul style="list-style-type: none"> • Neovascularization • Vitreous/preretinal hemorrhage

IRMA = intraretinal microvascular abnormalities; NPDR = nonproliferative diabetic retinopathy; PDR = proliferative diabetic retinopathy

NOTE:

- Any patient with two or more of the characteristics of severe NPDR is considered to have very severe NPDR.
- PDR may be classified as high-risk and non-high-risk. See Table 6 for more information.

Adapted with permission from Wilkinson CP, Ferris FL III, Klein RE, et al. Proposed international clinical diabetic retinopathy and diabetic macular edema disease severity scales. *Ophthalmology* 2003;110:1679.

TABLE 2 INTERNATIONAL CLINICAL DIABETIC MACULAR EDEMA DISEASE SEVERITY SCALE

Proposed Disease Severity Level	Findings Observable upon Dilated Ophthalmoscopy
Diabetic macular edema apparently absent	No apparent retinal thickening or hard exudates in posterior pole
Diabetic macular edema apparently present	Some apparent retinal thickening or hard exudates in posterior pole
If diabetic macular edema is present, it can be categorized as follows:	
Proposed Disease Severity Level	Findings Observable upon Dilated Ophthalmoscopy*
Diabetic macular edema present	<ul style="list-style-type: none"> • Mild diabetic macular edema: some retinal thickening or hard exudates in posterior pole but distant from the center of the macula • Moderate diabetic macular edema: retinal thickening or hard exudates approaching the center of the macula but not involving the center • Severe diabetic macular edema: retinal thickening or hard exudates involving the center of the macula

Reproduced with permission from Wilkinson CP, Ferris FL III, Klein RE, et al. Proposed international clinical diabetic retinopathy and diabetic macular edema disease severity scales. *Ophthalmology* 2003;110:1680.

* Hard exudates are a sign of current or previous macular edema. Diabetic macular edema is defined as retinal thickening; this requires a three-dimensional assessment that is best performed by dilated examination using slit-lamp biomicroscopy and/or stereoscopic fundus photography. Optical coherence tomography may supplement the fundus evaluation for determining the presence of diabetic macular edema.



CARE PROCESS

The care process for diabetic retinopathy includes a medical history, a regular ophthalmologic examination or screening of high-quality retinal photographs of patients who have not had previous treatment for diabetic retinopathy or other eye disease, and regular follow-up. The purpose of an effective screening program is to determine who needs to be referred to an ophthalmologist for close follow-up and possible treatment, and who may simply be screened annually. Early detection of retinopathy depends on educating patients who have diabetes, as well as their family, friends, and health care providers, about the importance of regular eye examination even though the patient may be asymptomatic. In lay terms, patients must be informed that they may have good vision and no ocular symptoms but that they may still have significant disease that needs treatment. They should be educated that early treatment works best and that is why they need to return for an annual eye examination, even when their vision is good. Individuals with Type 2 diabetes mellitus without diabetic retinopathy should be encouraged to have an annual dilated eye examination to detect the onset of diabetic retinopathy.^{29,33,73-90} Individuals with Type 1 diabetes mellitus without diabetic retinopathy should have annual dilated eye examinations beginning 5 years after the onset of diabetes.^{29,91} The recommended timing of the first ophthalmic examination and subsequent follow-up examinations for patients with diabetes is listed in Table 3 and described in the Management section.

TABLE 3 RECOMMENDED EYE EXAMINATIONS FOR PATIENTS WITH DIABETES MELLITUS AND NO DIABETIC RETINOPATHY

Diabetes Type	Recommended Initial Evaluation	Recommended Follow-up*
Type 1	5 years after diagnosis ²⁹	Yearly ²⁹
Type 2	At time of diagnosis ^{33,92}	Yearly ^{33,92}
Pregnancy† (Type 1 or Type 2)	Soon after conception and early in the first trimester ⁹³⁻⁹⁵	<ul style="list-style-type: none"> • No retinopathy to mild or moderate NPDR: every 3–12 months⁹³⁻⁹⁵ • Severe NPDR or worse: every 1–3 months⁹³⁻⁹⁵

NPDR = nonproliferative diabetic retinopathy

* Abnormal findings may dictate frequent follow-up examinations.

† Women who develop gestational diabetes do not require an eye examination during pregnancy and do not appear to be at increased risk for diabetic retinopathy during pregnancy.

Diabetic Retinopathy PPP: Patient Outcome Criteria

Maintaining near-normal glucose levels and near-normal blood pressure lowers the risk of retinopathy developing and/or progressing,^{35,36,38,45,96} so patients should be informed of the importance of maintaining good glycosylated hemoglobin levels, serum lipids, and blood pressure. Aspirin may be used by diabetic patients for other medical indications without concern that the aspirin therapy will worsen diabetic retinopathy.^{97,98}

PATIENT OUTCOME CRITERIA

Patient outcome criteria include the following:

- ◆ Improvement or stabilization of visual function
- ◆ Improvement or stabilization of vision-related quality of life
- ◆ Optimal control of glucose, blood pressure, and other risk factors through close communication with the patient's primary care physician regarding the status of the diabetic retinopathy and the need for optimal metabolic control

DIAGNOSIS

The initial examination for a patient with diabetes mellitus includes all features of the comprehensive adult medical eye evaluation,⁹⁹ with particular attention to those aspects relevant to diabetic retinopathy.

History

An initial history should consider the following elements:

- ◆ Duration of diabetes^{29,42,100}
- ◆ Past glycemic control (HbA_{1c})^{42,58,100}
- ◆ Medications
- ◆ Medical history (e.g., obesity, renal disease,^{29,33} systemic hypertension,^{29,33} serum lipid levels,¹⁰¹ pregnancy,^{93,94} neuropathy)
- ◆ Ocular history (e.g., trauma, other eye diseases, ocular injections, surgery, including retinal laser treatment and refractive surgery)

Physical Examination

The initial examination should include the following elements:

- ◆ Visual acuity¹⁰²
- ◆ Slit-lamp biomicroscopy
- ◆ Intraocular pressure (IOP)
- ◆ Gonioscopy before dilation, when indicated. Iris neovascularization is best recognized prior to dilation. When neovascularization of the iris is present or suspected, or if the IOP is elevated, undilated gonioscopy can be used to detect neovascularization in the anterior chamber angle.
- ◆ Pupillary assessment for optic nerve dysfunction
- ◆ Thorough funduscopy including stereoscopic examination of the posterior pole⁶⁵
- ◆ Examination of the peripheral retina and vitreous

A dilated pupil is preferred to ensure optimal examination of the retina, because only 50% of eyes are correctly classified for the presence and severity of retinopathy through undilated pupils.¹⁰³ Slit-lamp biomicroscopy is the recommended method to evaluate retinopathy in the posterior pole and midperipheral retina.⁶⁵ Examination of the peripheral retina is best performed using indirect ophthalmoscopy or slit-lamp biomicroscopy.

Because treatment is effective in reducing the risk of visual loss, a detailed examination is indicated to assess for the following features that often lead to visual impairment:

- ◆ Macular edema
- ◆ Signs of severe NPDR (extensive retinal hemorrhages/microaneurysms, venous beading, and IRMA)
- ◆ Optic nerve head neovascularization and/or neovascularization elsewhere
- ◆ Vitreous or preretinal hemorrhage

Examination Schedule

Type 1 Diabetes

Many studies of patients with Type 1 diabetes have reported a direct relationship between the prevalence and severity of retinopathy and the duration of diabetes.^{33,104,105} The development of vision-threatening retinopathy is rare in children prior to puberty.^{104,106} Among patients with Type 1 diabetes, substantial retinopathy may become apparent as early as 6 to 7 years after onset of the disease.²⁹ Ophthalmic examinations are recommended beginning 5 years after the diagnosis of Type 1 diabetes and annually thereafter, which will detect the vast majority of Type 1 patients who require therapy.^{29,91} Patient education about the visual impact of early glucose control is important and should begin with the onset of disease.

Type 2 Diabetes

The time of onset of Type 2 diabetes is often difficult to determine and may precede the diagnosis by a number of years.¹⁰⁷ Up to 3% of patients whose diabetes is first diagnosed at age 30 or later will have CSME or high-risk features at the time of the initial diagnosis of diabetes.²⁹ About 30% of patients will have some manifestation of diabetic retinopathy at diagnosis. Therefore, the patient should be referred for ophthalmologic evaluation at the time of diagnosis.^{33,92}

Diabetes Associated with Pregnancy

Diabetic retinopathy can worsen during pregnancy due to the physiologic changes of pregnancy itself or changes in overall metabolic control.⁹³⁻⁹⁵ Patients with diabetes who plan to become pregnant should have an ophthalmologic examination prior to pregnancy and counseled about the risk of development and/or progression of diabetic retinopathy. The obstetrician or primary care physician should carefully guide the management of the pregnant patient with diabetes' blood glucose, blood pressure, as well as other issues related to pregnancy.⁹³⁻⁹⁵ During the first trimester, an eye examination should be performed with repeat and follow-up visits scheduled depending on the severity of retinopathy. (See Table 3.) Women who develop gestational diabetes¹⁰⁸ do not require an eye examination during pregnancy and do not appear to be at increased risk for diabetic retinopathy during pregnancy.

After the examination, the ophthalmologist should discuss the results and their implications with the patient. Both eyes should be classified according to the categories of diabetic retinopathy and macular edema discussed in the Natural History and Treatment sections. Each category has an inherent risk for progression and is dependent upon adherence to overall diabetes control. Thus, the diagnostic category, combined with the level of diabetes control, determines the timing for both the intervention and follow-up examination.

Ancillary Tests

If used appropriately, a number of tests ancillary to the clinical examination may enhance patient care. The most common tests include the following:

- ◆ Color and red-free fundus photography
- ◆ Optical coherence tomography (OCT)
- ◆ Fluorescein angiography (FA)
- ◆ Ultrasonography

Color Fundus Photography

Fundus photography is a reproducible technique for detecting diabetic retinopathy and has been used in large clinical research studies. Fundus photography is also useful for documenting the severity of the diabetes, the presence of NVE and NVD, the response to treatment, and the need for additional treatment at future visits.

Optical Coherence Tomography

Optical coherence tomography provides high-resolution imaging of the vitreoretinal interface, neurosensory retina, and subretinal space. Optical coherence tomography can be used to quantify retinal thickness, monitor macular edema, identify vitreomacular traction, and detect other forms of macular disease in patients with diabetic macular edema.¹⁰⁹⁻¹¹⁴ (See Table 4.) Large clinical trials testing anti-VEGF treatment have utilized OCT rather than stereoscopic photographs or clinical examination to evaluate and follow macular edema status because it allows an objective, accurate assessment of the amount and location of retinal thickening.^{70,115-117} In clinical practice, decisions are often based on OCT findings. For example, the decision to repeat anti-VEGF injections, change therapeutic agents (e.g., intraocular corticosteroids), initiate laser treatment, or even consider vitrectomy surgery is often based in part on OCT findings. Nevertheless, retinal thickness, even when measured by OCT, is not always consistently correlated with visual acuity.^{118,119}

TABLE 4 USE OF OPTICAL COHERENCE TOMOGRAPHY FOR DIABETIC RETINOPATHY

Situation	Usually	Occasionally	Never
To evaluate unexplained visual acuity loss	•		
To identify areas of vitreomacular traction	•		
To evaluate patients with difficult and/or questionable examinations for DME	•		
To investigate other causes of macular swelling		•	
To screen a patient with no or minimal diabetic retinopathy			•

DME = diabetic macular edema

Fluorescein Angiography

Routine FA is not indicated as a part of the regular examination of patients with diabetes. Macular edema and PDR are best diagnosed by means of clinical examination and/or FA. As the use of anti-VEGF agents and intraocular corticosteroids has increased for the treatment of macular edema, the use of focal laser surgery has decreased. Therefore, the need for angiography that localizes leaking microaneurysms or areas of capillary dropout has also declined.

Nevertheless, FA is useful to differentiate diabetic macular swelling from other macular disease or for a patient with unexplained vision loss. (See Table 5.) Angiography can identify macular capillary nonperfusion¹²⁰ in the foveal or even in the entire macular region as an explanation for vision loss that is unresponsive to therapy. Fluorescein angiography may also detect areas of untreated retinal capillary nonperfusion that could explain persistent retinal or disc neovascularization after previous scatter laser surgery. Thus, FA remains a valuable tool, and facilities for conducting FA should be available to physicians who diagnose and treat patients with diabetic retinopathy.

TABLE 5 USE OF FLUORESCHEIN ANGIOGRAPHY FOR DIABETIC RETINOPATHY

Situation	Usually	Occasionally	Never
To guide laser treatment of CSME	•		
To evaluate unexplained visual loss	•		
To identify suspected but clinically obscure retinal neovascularization	•		
To identify areas of vitreomacular traction		•	
To rule out other causes of macular swelling		•	
To identify large areas of capillary nonperfusion		•	
To evaluate patients with difficult and/or questionable examinations for DME		•	
To screen a patient with no or minimal diabetic retinopathy			•

CSME = clinically significant macular edema; DME = diabetic macular edema

An ophthalmologist who orders FA must be aware of the potential risks associated with the procedure, because severe medical complications may occur, including death in about 1/200,000 patients.¹²¹ Each angiography facility should have in place an emergency care plan and a clear protocol to minimize the risks and to manage complications. Fluorescein dye crosses the placenta into the fetal circulation,¹²² but detrimental effects of fluorescein dye on a fetus have not been documented.

Ultrasonography

Ultrasonography is an extremely valuable diagnostic tool that enables assessment of the status of the retina in the presence of a vitreous hemorrhage or other media opacity. Furthermore, B-scan ultrasonography may be helpful to define the extent and severity of vitreoretinal traction, especially on the macula of diabetic eyes. Currently, ultrasonography is used secondary to OCT testing when there is clear media.

MANAGEMENT

A healthy diet and lifestyle that includes exercise and weight control may decrease the risk of developing diabetes in some patients;^{123,124} however, diabetes complications simply cannot be prevented in all cases. Nevertheless, the visual complications of diabetes mellitus can at least be moderated by a healthy lifestyle. When visual complications occur, treatment is believed to yield a substantial cost savings when compared with the direct costs for individuals disabled by vision loss (see Socioeconomic Considerations section). According to the National Committee for Quality Assurance's Health Plan Employers Data Information Set System, national monitoring of quality data has shown a slow but definite trend toward improving rates of screening examinations and blood glucose control.¹²⁵ Still, screening rates remain lower than ideal in spite of evidence supporting the effectiveness of treatment. Physicians who care for patients with diabetes, and patients themselves, need to be educated about indications for ophthalmologic referral. (See Table 6.)

Prevention and Early Detection of Diabetic Retinopathy

Analyses from two clinical trials show that treatment for diabetic retinopathy may be 90% effective in preventing severe vision loss (visual acuity <5/200) using current therapeutic treatment strategies.⁵⁶ Although effective treatment is available, fewer patients with diabetes are referred by their primary care physicians for ophthalmic care than would be expected according to guidelines by the American Diabetes Association and the American Academy of Ophthalmology.¹²⁶ In two community-based studies, 43% to 65% of participants had not received a dilated eye examination at the time of enrollment.^{125,127}

The purpose of an effective screening program for diabetic retinopathy is to determine who needs to be referred to an ophthalmologist for close follow-up and possible treatment and who may simply be screened annually. Some studies have shown that screening programs using digital retinal images taken with or without dilation may enable early detection of diabetic retinopathy along with an appropriate referral.⁷³⁻⁸¹ Digital cameras with stereoscopic capabilities are useful for identifying subtle neovascularization and macular edema.^{82,83} Optical coherence tomography appears to be an effective and sensitive imaging tool for detecting diabetic macular edema as long as there are no other causes for cystoid macular edema.^{113,128}

Studies have found a positive association between participating in a photographic screening program and subsequent adherence to receiving recommended comprehensive dilated eye examinations by a clinician.^{84,85} Of course, such screening programs are more relevant when access to ophthalmic care is limited.⁸⁶⁻⁸⁹ Screening programs should follow established guidelines.⁹⁰ Given the known gap in accessibility of direct ophthalmologic screening, fundus photographic screening programs may help increase the chances that at-risk individuals will be promptly referred for more detailed evaluation and management.

Secondary Prevention

The DCCT showed that the development and progression of diabetic retinopathy in patients with Type 1 diabetes can be delayed when the HbA_{1c} is optimized.³⁶ (See Appendix 5.) Establishing a close partnership with the ophthalmologist and the primary care physician is an

Diabetic Retinopathy PPP: Medical and Surgical Management

important step to ensure optimal patient care. Furthermore, it is important to help educate patients with diabetes as well as their primary care physician about the ophthalmologic implications of controlling blood glucose (as monitored by HbA_{1c}) to as near normal as is safely possible. Results from multiple studies have demonstrated the value of controlling blood glucose, serum lipid levels, and blood pressure in patients with Type 2 diabetes. (See Appendix 5 for further information.)

Aspirin therapy has been evaluated for use in the management of diabetic retinopathy. The ETDRS found that aspirin therapy at a dose of 650 mg per day does not slow the progression of diabetic retinopathy.⁹⁷ Also, aspirin therapy did not cause more severe, more frequent, or longer-lasting vitreous hemorrhages in patients with PDR.⁹⁸ As such, aspirin appears to be neither helpful nor harmful in the management of diabetic retinopathy. Therefore, no recommended changes in medically administered aspirin therapy are indicated in the setting of diabetic retinal disease.

Medical and Surgical Management

Management recommendations for patients with diabetes are summarized in Table 6 and are described according to severity of the retinopathy. Given the recent evidence on the efficacy of anti-VEGF therapies in patients with center-involved CSME, the population may be further distinguished as having center-involving or non-center-involving diabetic macular edema. The table provides guidance for a preferred practice pattern for the general population of patients with diabetes; however, specific needs may vary on a case-by-case basis. Table 7 lists side effects and complications of treatment.

TABLE 6 MANAGEMENT RECOMMENDATIONS FOR PATIENTS WITH DIABETES

Severity of Retinopathy	Presence of Macular Edema	Follow-up (Months)	Panretinal Photocoagulation (Scatter) Laser	Focal and/or Grid Laser*	Intravitreal Anti-VEGF Therapy
Normal or minimal NPDR	No	12	No	No	No
Mild NPDR	No	12	No	No	No
	ME	4–6	No	No	No
	CSME†	1*	No	Sometimes	Sometimes
Moderate NPDR	No	12‡	No	No	No
	ME	3–6	No	No	No
	CSME†	1*	No	Sometimes	Sometimes
Severe NPDR	No	4	Sometimes	No	No
	ME	2–4	Sometimes	No	No
	CSME†	1*	Sometimes	Sometimes	Sometimes
Non-high-risk PDR	No	4	Sometimes	No	No
	ME	2–4	Sometimes	No	No
	CSME†	1*	Sometimes	Sometimes	Sometimes
High-risk PDR	No	4	Recommended	No	Alternative ^{129,130}
	ME	4	Recommended	Sometimes	Usually
	CSME†	1*	Recommended	Sometimes	Usually

Anti-VEGF = anti-vascular endothelial growth factor; CSME = clinically significant macular edema; ME = non-clinically significant macular edema; NPDR = nonproliferative diabetic retinopathy; PDR = proliferative diabetic retinopathy

* Adjunctive treatments that may be considered include intravitreal corticosteroids or anti-VEGF agents (off-label use, except aflibercept and ranibizumab). Data from the Diabetic Retinopathy Clinical Research Network in 2011 demonstrated that, at two years of follow-up, intravitreal ranibizumab with prompt or deferred laser resulted in greater visual acuity gain and intravitreal triamcinolone acetonide plus laser also resulted in greater visual gain in pseudophakic eyes compared with laser alone.¹³¹ Individuals receiving the intravitreal injections of anti-VEGF agents may be re-examined as early as one month following injection.

† Exceptions include hypertension or fluid retention associated with heart failure, renal failure, pregnancy, or any other causes that may aggravate macular edema. Deferral of photocoagulation for a brief period of medical treatment may be considered in these cases.¹³² Also, deferral of CSME treatment is an option when the center of the macula is not involved, visual acuity is excellent, close follow-up is possible, and the patient understands the risks.

‡ Or at shorter intervals if signs approaching those of severe NPDR appear.

TABLE 7 SIDE EFFECTS AND COMPLICATIONS OF TREATMENT FOR DIABETIC RETINOPATHY

Treatment	Side Effect/Complication
Focal laser photocoagulation for diabetic macular edema	<ul style="list-style-type: none"> • Possible transient initial decrease in central vision • Paracentral scotomas if laser burns have been placed close to the fovea, especially large or confluent burns¹³³ • Permanent central scotoma from inadvertent foveal burns • Expansion of laser scar area (over many years)
Panretinal photocoagulation (scatter) for severe NPDR or PDR	<ul style="list-style-type: none"> • Transient central vision loss from macular edema¹⁰² • Peripheral visual field constriction with delayed dark adaptation • Vitreous hemorrhage if neovascularization is present • Reduced or compromised accommodation¹³⁴ • Pupillary dilation (mydriasis)
Vitrectomy	<ul style="list-style-type: none"> • Recurrent vitreous hemorrhage^{135,136} • Retinal tear or detachment¹³⁷ • Vision loss^{137,138} • Infectious endophthalmitis¹³⁹ • Cataract¹⁴⁰
Intravitreal injections	<ul style="list-style-type: none"> • Cataract^{141,142} • Elevated intraocular pressure (i.e., corticosteroids)^{141,142} • Infectious endophthalmitis • Noninfectious inflammatory reactions • Possible systemic effect from intravitreal medication • Increased retinal traction

NPDR = nonproliferative diabetic retinopathy; PDR = proliferative diabetic retinopathy

Normal or Minimal NPDR

The patient with a normal retinal examination or minimal NPDR (i.e., with rare microaneurysms) should be re-examined annually,²⁹ because within 1 year 5% to 10% of patients without retinopathy will develop diabetic retinopathy. Existing retinopathy will worsen by a similar percentage.^{51,52,57} Laser surgery, color fundus photography, and FA are not necessarily indicated.

Mild to Moderate NPDR without Macular Edema

Patients with retinal microaneurysms and occasional blot hemorrhages or hard exudates should be re-examined within 6 to 12 months, because disease progression is common.⁵¹ The natural history of Type 1 diabetic patients suggests that approximately 16% of patients with mild retinopathy (hard exudates and microaneurysms only) will progress to proliferative stages within 4 years.⁵¹

Laser surgery and FA are not indicated for this group of patients. Color fundus photography and OCT imaging of the macula may occasionally be helpful to establish a baseline for future comparison and for patient education. (See Ancillary Tests section.)

For patients with mild NPDR, the 4-year incidence of either CSME or macular edema that is not clinically significant is approximately 12%. For moderate NPDR, the risk increases to 23% for patients with either Type 1 or 2 diabetes.¹⁰² Patients with macular edema that is not clinically significant should be re-examined within 3 to 4 months, because they are at significant risk of developing CSME.⁶⁵

Mild to Moderate NPDR with CSME

Clinically significant macular edema is defined by the ETDRS to include any of the following features:

- ◆ Thickening of the retina at or within 500 μm of the center of the macula
- ◆ Hard exudates at or within 500 μm of the center of the macula, when associated with adjacent retinal thickening. (This criteria does not apply to residual hard exudates that remain after successful treatment of prior retinal thickening.)
- ◆ A zone or zones of retinal thickening one disc area or larger, where any portion of the thickening is within one disc diameter of the center of the macula

It is now appropriate to subdivide diabetic macular edema according to involvement at the center of the macula, because the risk of visual loss and the need for treatment is greater when the center is involved. The diagnosis of diabetic macular edema can be difficult. Macular edema is best evaluated by dilated examination using slit-lamp biomicroscopy, OCT, and/or stereoscopic fundus photography. An ophthalmologist who treats patients for this condition should be familiar with relevant studies and techniques as described in the ETDRS and subsequent studies, such as the DRCR.net Protocol trial⁷⁰ and other studies involving anti-VEGF treatment.^{65,120} Fluorescein angiography prior to laser surgery for CSME is often helpful for identifying treatable lesions. Fluorescein angiography is less relevant when there are circinate lipid exudates and the leaking lesions are clearly detected within the lipid ring. Fluorescein angiography is also useful for detecting capillary dropout and pathologic enlargement of the foveal avascular zone, a feature that may be useful when planning treatment.⁶⁵ Color fundus photography is often helpful to document the status of the retina even if laser surgery is not performed. (See Ancillary Tests section.) Optical coherence tomography is also a helpful screening tool that is able to detect subtle edema and also to follow the course of edema after treatment.

The traditional treatment for CSME has been laser surgery. However, current data from multiple well-designed studies demonstrate that intravitreal anti-VEGF agents provide a more effective treatment for center-involved CSME than monotherapy with laser surgery.^{65,70,116,120,131,143-149} The visual acuity gain and reduction in macular thickness following the administration of the combination of intravitreal ranibizumab, with prompt or deferred laser surgery, had better outcomes than laser alone after 2 years of follow-up.¹³¹ Recent clinical trials have divided clinically significant diabetic macular edema into center-involving (ci-CSME) and non-center-involving (nci-CSME). Enrollment in these recent clinical trials included only subjects with ci-CSME. When ci-CSME is present, the anti-VEGF therapies provide a better visual acuity and anatomic (less macular edema) outcome than focal/grid laser surgery alone. (See Glossary.) Deferred laser surgery may ultimately decrease the need for repeat anti-VEGF injections. For nci-CSME, the role of laser surgery is guided by the ETDRS. The ETDRS demonstrated a definite benefit in favor of laser photocoagulation surgery in both ci-CSME and nci-CSME. Therefore, both anti-VEGF and laser remain effective treatment options for CSME as outlined above.

Anti-VEGF Therapy

Multiple studies have demonstrated the benefit of anti-VEGF therapy in cases of center-involving diabetic macular edema. (See Appendix 4.) At the present time, anti-VEGF therapy is the initial treatment choice for center-involving macular edema, with possible subsequent or deferred focal laser treatment. The Ranibizumab for Edema of the macula in Diabetes (READ-2) study involved 126 patients randomized to either anti-VEGF therapy (in this case ranibizumab alone), laser alone, or focal/grid laser combined with anti-VEGF therapy. (See Glossary.) The group that received anti-VEGF therapy alone or with laser treatment did better than the group treated with laser alone.¹⁵⁰ The Diabetic Retinopathy Clinical Research Network (DRCR.net) Protocol I also showed that anti-VEGF with either prompt or deferred laser photocoagulation was better than either laser alone or laser combined with triamcinolone acetonide.⁷⁰ (See Glossary.) These referenced studies used ranibizumab, while the Bevacizumab or Laser Treatment (BOLT) study also showed

favorable outcomes for bevacizumab use over macular laser treatment in eyes with ci-CSME.¹⁵¹ (See Glossary.) The DME and VEGF Trap-Eye: Investigation of Clinical Impact (DA VINCI) study demonstrated better outcomes using aflibercept over laser treatment for ci-CSME.¹⁵² (See Glossary.) Most recently, the DRCR.net protocol T demonstrated that anti-VEGF therapy using bevacizumab, ranibizumab, or aflibercept is an effective treatment for center-involving CSME. However, at worse levels of initial visual acuity (20/50 or worse), aflibercept was more effective at improving visual acuity than the other anti-VEGF agents tested.¹⁵³ Treating physicians should note that the use of betadine antiseptic drops and a lid speculum is recommended during intravitreal injections. The use of routine antibiotic eye drops is not recommended before or following intravitreal injection procedures.¹⁵⁴ Individuals receiving the intravitreal injections of anti-VEGF agents may be examined at 1 month following therapy. (See Table 6.) Uncommon, yet severe, adverse side effects are associated with intravitreal injections. These include infectious endophthalmitis, cataract formation, retinal detachment, and elevated IOP, particularly for the corticosteroids such as triamcinolone. (See Table 7.)

Laser Photocoagulation

Effective laser treatment and retreatment protocols have been detailed in the DRS and the ETDRS.^{61,155,156} With the advent of anti-VEGF therapy for macular edema, many retina specialists prefer to use a modified ETDRS treatment approach. This includes a less intense laser treatment, greater spacing, directly targeting microaneurysms, and avoiding foveal vasculature within at least 500 μm of the center of the macula.¹⁵⁷ Preoperatively, the ophthalmologist should discuss with the patient the side effects and risks of treatment.^{65,120} A follow-up examination for individuals with CSME should be scheduled within 3 to 4 months of laser surgery.⁶⁵ Rarely, focal laser photocoagulation may induce subretinal fibrosis with choroidal neovascularization, a complication that may be associated with permanent central vision loss.¹⁵⁸⁻¹⁶⁰ Other than choroidal neovascularization, the most important factor associated with the development of subretinal fibrosis includes both the more severe levels of subretinal hard exudates and elevated serum lipids prior to laser photocoagulation.¹⁶¹ Approximately 8% of cases of subretinal fibrosis can be directly related to focal laser photocoagulation.

Effects Related to Other Treatments

There have been case reports of idiosyncratic macular edema that is temporally associated with use of the glitazone class of oral antihyperglycemic agents.^{162,163} When substantial vitreomacular traction is present, pars plana vitrectomy may improve visual acuity in selected patients who have diffuse CSME that is unresponsive to previous macular laser photocoagulation and/or anti-VEGF therapy.¹⁶⁴⁻¹⁶⁶ However, the value of vitrectomy in CSME is difficult to study in a randomized clinical trial, as there are many variables. (See DRCR.net protocol D.¹⁶⁷)

Treatment Deferral

When treatment for macular edema is deferred, the patient should be observed closely (at least every 3 to 4 months) for signs of progression.

Severe NPDR and Non-High-Risk PDR

Severe NPDR and non-high-risk PDR are discussed together because the ETDRS data showed that they have a similar clinical course and subsequent recommendations for treatment are similar. In eyes with severe NPDR, the risk of progression to proliferative disease is high. Half of patients with severe NPDR will develop PDR within 1 year, and 15% will have high-risk PDR.¹⁰² For patients with very severe NPDR, the risk of developing PDR within 1 year is 75%. Furthermore, 45% will become high-risk PDR in this same time frame. Therefore, these patients should be re-examined within 2 to 4 months.^{102,168} Refer to Table 1 for the definition of severe NPDR and very severe NPDR.

The ETDRS compared early panretinal photocoagulation with deferral of photocoagulation with careful follow-up (at 4-month intervals) and prompt panretinal photocoagulation if progression to high-risk PDR occurred. (See Appendix 4.) Although the study did not provide definitive guidelines, the ETDRS suggested that panretinal photocoagulation should not be recommended for eyes with mild or moderate NPDR, provided that follow-up could be maintained. When retinopathy is more severe, panretinal photocoagulation should be considered and should not be delayed when the eye reaches the high-risk proliferative stage.¹⁰² (See Appendix 4.) Careful follow-up at 3 to 4 months is important: if

Diabetic Retinopathy PPP: Medical and Surgical Management

the patient will not or cannot be followed closely or if there are associated medical conditions such as impending cataract surgery or pregnancy, early laser panretinal photocoagulation may be warranted.^{102,168} Laser photocoagulation may be indicated, particularly when access to health care is difficult. If laser surgery is elected, full panretinal photocoagulation is a proven treatment approach. Partial or limited panretinal photocoagulation treatment is not recommended.⁶¹

Additional analyses of visual outcome in ETDRS patients with severe NPDR to non-high-risk PDR suggest that the recommendation to consider panretinal photocoagulation before the development of high-risk PDR is particularly appropriate for patients with Type 2 diabetes. The risk of severe vision loss or vitrectomy was reduced by 50% (2.5% vs. 5%, $P=0.0001$) in patients with Type 2 diabetes who were treated early when compared with deferral panretinal photocoagulation until high-risk PDR developed.¹⁶⁸ For patients with Type 1 diabetes, the timing of the panretinal photocoagulation depends on the patient's compliance with follow-up and the status and response to treatment of the fellow eye. For both patients with Type 1 and Type 2 diabetes, impending or recent cataract surgery or pregnancy may increase the risk of progression and may influence the decision to perform panretinal photocoagulation.

The goal of laser surgery is to reduce the risk of vision loss. Preoperatively, the ophthalmologist should assess for the presence of macular edema, discuss side effects of treatment and risks of visual loss with the patient, and obtain informed consent.^{155,156}

When panretinal photocoagulation for severe NPDR or non-high-risk PDR is to be performed on eyes with macular edema, many experts think that it is preferable to perform focal photocoagulation and/or anti-VEGF therapy prior to panretinal photocoagulation. (See Glossary.) There is evidence based on clinical trials that panretinal photocoagulation, as used in the DRS and ETDRS, may exacerbate macular edema and may increase the rate of moderate visual loss (i.e., doubling of the visual angle) compared with untreated control eyes.¹⁰² (See Glossary.) However, panretinal photocoagulation surgery should not be delayed when PDR is at the high-risk stage (i.e., if NVD is extensive or vitreous/preretinal hemorrhage has occurred recently). In such cases, anti-VEGF therapy and panretinal photocoagulation may be performed concomitantly. Currently, the role of anti-VEGF therapy in the management of severe NPDR and non-high-risk PDR is under investigation.

Fluorescein angiography may be helpful to determine the presence or absence of areas of nonperfusion and/or clinically undetected areas of retinal neovascularization and to establish the cause for a loss in visual acuity.

High-Risk PDR

The presence of any three of the following four features characterizes DRS high-risk PDR:

- ◆ Neovascularization (at any location)
- ◆ Neovascularization at the optic disc
- ◆ Severe neovascularization:
 - ◆ New vessels within one disc diameter of the optic nerve head that are larger than one-quarter to one-third disc area in size
 - ◆ New vessels elsewhere that are at least one-half disc area in size
- ◆ Vitreous or preretinal hemorrhage

The risk of severe visual loss among patients with high-risk PDR is reduced substantially by treatment using panretinal photocoagulation as described in the DRS and ETDRS. (See Glossary.) Most patients with high-risk PDR should receive panretinal photocoagulation surgery expeditiously.^{61,169} Panretinal photocoagulation usually induces regression of retinal neovascularization. This technique has been fully described^{61,155} and the results are summarized in Appendix 4.

Very recently, the DRICR.net study protocol S has demonstrated that alternative use of anti-VEGF agents (ranibizumab was used in this protocol), may be an alternative to panretinal laser photocoagulation.¹²⁹ However, many feel that panretinal photocoagulation remains the first choice for management of PDR. The anti-VEGF alternative could be considered for patients who can follow-up regularly. Further studies are required to determine the long-term implications of using anti-VEGF agents alone.¹³⁰

Additional panretinal photocoagulation, anti-VEGF therapy, or vitrectomy surgery may be necessary to address increasing neovascularization of the iris and should be considered for the following situations:

- ◆ Failure of the neovascularization to regress
- ◆ Increasing neovascularization of the retina or iris
- ◆ New vitreous hemorrhage
- ◆ New areas of neovascularization

For patients who have CSME in addition to high-risk PDR, combined anti-VEGF therapy and panretinal photocoagulation at the first treatment session and in the early stages of such higher risk eyes could also be considered. Fluorescein angiography does not usually need to be performed in order to apply the panretinal photocoagulation effectively. However, a fluorescein angiogram may be used to guide focal photocoagulation. In some cases, vitreous hemorrhage may recur in patients who have had extensive panretinal photocoagulation. These hemorrhages may be due to traction on pre-existing or involuted neovascularization. They may clear spontaneously and do not necessarily require additional panretinal laser surgery.

Some patients with previously untreated PDR who have vitreous opacities and active neovascular or fibrovascular proliferation should be considered as candidates for pars plana vitrectomy.^{66,170-172} The value of early vitrectomy tends to increase with the increasing severity of neovascularization. (See Appendix 4.) The role of anti-VEGFs in these later stages of proliferative retinopathy is under investigation.

High-Risk PDR Not Amenable to Photocoagulation

In some patients with severe vitreous or preretinal hemorrhage, it may not be possible to deliver laser photocoagulation adequately. Furthermore, advanced active PDR may persist despite extensive panretinal photocoagulation. In such cases, vitrectomy surgery may be indicated. Vitreous surgery is frequently indicated in patients with macula-threatening traction retinal detachment (particularly of recent onset), combined traction-rhegmatogenous retinal detachment, and vitreous hemorrhage precluding panretinal photocoagulation. Patients with vitreous hemorrhage and rubeosis iridis also should be considered for prompt vitrectomy and intraoperative panretinal photocoagulation surgery. The role of anti-VEGFs in treatment of these cases is under investigation.

Other Treatments

Several studies have evaluated the use of intravitreal administration of short- and long-acting corticosteroids for the treatment of diabetic macular edema and the use of anti-VEGF agents in the treatment of PDR. An earlier DRCR.net study evaluated the role of intravitreal triamcinolone acetonide compared with focal laser photocoagulation. Treatment with intravitreal triamcinolone acetonide resulted in an early decrease in retinal thickness at 4 months, yet by 24 months those patients randomized to focal/grid laser photocoagulation had better mean visual acuity and fewer adverse effects of cataract development and elevation of IOP.¹⁷³ At 3 years, these results were largely unchanged.¹⁷⁴ However, this study did not evaluate the role of intravitreal corticosteroids plus standard focal/grid laser photocoagulation compared with laser photocoagulation alone. A subsequent study showed increased visual gain in pseudophakic eyes that were given the combination of the intravitreal triamcinolone acetonide and laser; however, even in this group the eyes treated with anti-VEGF agents tended to do better overall.^{131,144} Future studies will help define the role of corticosteroids in the treatment strategies for persons with diabetic macular edema.

Micropulse laser treatment as well as FA-guided therapy have also been advocated. Studies suggest that micropulse laser induces less damage to the macula, and several studies using this method have shown encouraging results. This method has not been compared with standard or modified ETDRS laser surgery in randomized clinical trials.¹⁷⁵

Follow-Up Evaluation

The follow-up evaluation includes a history and examination.

History

A follow-up history should include changes in the following:

- ◆ Symptoms
- ◆ Systemic status (pregnancy, blood pressure, serum cholesterol, renal status)
- ◆ Glycemic status (HbA_{1c})^{42,58,100}

Examination

A follow-up examination should include the following elements:

- ◆ Visual acuity¹⁰²
- ◆ Slit-lamp biomicroscopy with iris examination¹⁷⁶
- ◆ Intraocular pressure
- ◆ Gonioscopy (preferably before dilation when iris neovascularization is suspected or if IOP is elevated)¹⁷⁶
- ◆ Stereoscopic examination of the posterior pole after dilation of the pupils⁶⁵
- ◆ OCT imaging, when appropriate
- ◆ Peripheral retina and vitreous examination, when indicated⁶⁴

Recommended intervals for follow-up are given in Table 6.

PROVIDER AND SETTING

Although the ophthalmologist will perform most of the examination and all surgery, certain aspects of data collection may be performed by trained individuals under the ophthalmologist's supervision and review. Because of the complexities of the diagnosis and treatment for diabetic retinopathy, the ophthalmologist caring for patients with this condition should be familiar with the specific recommendations of relevant clinical trials.^{37,70,101,102,117,150-152,156,177-184}

PHYSICIAN QUALITY REPORTING SYSTEM

The Physician Quality Reporting System (PQRS) program, initially launched by the Centers for Medicare and Medicaid Services in July 2007, encourages quality improvement through the use of clinical performance measures on a variety of clinical conditions. Measures in the 2014 program for diabetic eye care include an annual dilated eye examination for patients with diabetes, documentation of the level of severity of retinopathy and the presence or absence of macular edema, and communication of examination results to the physician managing ongoing diabetes care for patients with diabetic retinopathy.¹⁸⁵

COUNSELING AND REFERRAL

The ophthalmologist should refer patients with diabetes to a primary care physician for appropriate management of their systemic condition and should communicate examination results to the physician managing the patient's ongoing diabetes care. An Eye MD Examination Report Form is available from the American Academy of Ophthalmology.¹⁸⁶

Some patients with diabetic retinopathy will lose substantial vision despite being treated according to the recommendations in this document.¹⁶⁸ Patients whose conditions fail to respond to surgery and those for whom further treatment is unavailable should be provided with proper professional support and offered referral for counseling, vision rehabilitation, or social services as appropriate.¹⁸⁷ Vision rehabilitation restores functional ability,¹⁸⁸ and patients with functionally limiting postoperative visual impairment should be referred for vision rehabilitation and social services.¹⁸⁷ More information on vision rehabilitation, including materials for patients, is available at www.aaopt.org/smart-sight-low-vision.

SOCIOECONOMIC CONSIDERATIONS

One analysis of medical and economic effects of diabetic retinopathy control predicted that over their lifetime, 72% of patients with Type 1 diabetes would eventually develop PDR requiring panretinal photocoagulation and that 42% will develop macular edema.¹⁸⁹ If treatments are delivered as recommended in the clinical trials, the model predicted a cost of \$966 per person-year of vision saved for patients with PDR and \$1120 per person-year of central visual acuity saved for patients with macular edema. These costs are less than the cost of a year of Social Security disability payments for patients disabled by vision loss. Therefore, treatment yields a substantial savings compared with the direct cost to society of untreated PDR in a Type 1 diabetic patient.¹⁹⁰ The indirect costs in lost productivity and human suffering are even greater.

Another analysis estimated that screening and treatment of eye disease in patients with diabetes costs, on average, \$3190 per quality adjusted life year (QALY) saved.¹⁹¹ For patients with Type 1 diabetes, it costs \$1996 per QALY saved; for patients with Type 2 diabetes who use insulin, it costs \$2933 per QALY saved; and for patients with Type 2 diabetes who do not use insulin, it costs \$3530 per QALY saved. Insofar as patients with Type 2 diabetes not using insulin represent the largest subset of the patient population, most of the economic benefits of screening and treatment are realized among these patients.

A recent (2013) cost-effectiveness analysis of various interventions for diabetic macular edema evaluated the cost effectiveness of anti-VEGF therapies for CSME. Compared with laser alone, the incremental cost-effectiveness of laser plus bevacizumab is \$11,138/QALY and thus seems to confer the greatest value among the various treatment options for CSME.¹⁹² By comparison, the cost-utility of laser photocoagulation for diabetic macular edema is \$3101/QALY,¹⁹³ whereas laser photocoagulation for extrafoveal choroidal neovascularization is \$23,640/QALY.¹⁹⁴ Finally, a cost-utility analysis of detection and treatment of diabetic retinopathy in patients with Type 1 and Type 2 diabetes demonstrates that provision of recommended ophthalmic care would reduce the prevalence of blindness by 52% and that the direct costs of care would be less than the losses in productivity and the costs of facilities provided for disability.¹⁹⁵



APPENDIX 1. QUALITY OF OPHTHALMIC CARE CORE CRITERIA

*Providing quality care
is the physician's foremost ethical obligation, and is
the basis of public trust in physicians.
AMA Board of Trustees, 1986*

Quality ophthalmic care is provided in a manner and with the skill that is consistent with the best interests of the patient. The discussion that follows characterizes the core elements of such care.

The ophthalmologist is first and foremost a physician. As such, the ophthalmologist demonstrates compassion and concern for the individual, and utilizes the science and art of medicine to help alleviate patient fear and suffering. The ophthalmologist strives to develop and maintain clinical skills at the highest feasible level, consistent with the needs of patients, through training and continuing education. The ophthalmologist evaluates those skills and medical knowledge in relation to the needs of the patient and responds accordingly. The ophthalmologist also ensures that needy patients receive necessary care directly or through referral to appropriate persons and facilities that will provide such care, and he or she supports activities that promote health and prevent disease and disability.

The ophthalmologist recognizes that disease places patients in a disadvantaged, dependent state. The ophthalmologist respects the dignity and integrity of his or her patients, and does not exploit their vulnerability.

Quality ophthalmic care has the following optimal attributes, among others.

- ◆ The essence of quality care is a meaningful partnership relationship between patient and physician. The ophthalmologist strives to communicate effectively with his or her patients, listening carefully to their needs and concerns. In turn, the ophthalmologist educates his or her patients about the nature and prognosis of their condition and about proper and appropriate therapeutic modalities. This is to ensure their meaningful participation (appropriate to their unique physical, intellectual, and emotional state) in decisions affecting their management and care, to improve their motivation and compliance with the agreed plan of treatment, and to help alleviate their fears and concerns.
- ◆ The ophthalmologist uses his or her best judgment in choosing and timing appropriate diagnostic and therapeutic modalities as well as the frequency of evaluation and follow-up, with due regard to the urgency and nature of the patient's condition and unique needs and desires.
- ◆ The ophthalmologist carries out only those procedures for which he or she is adequately trained, experienced, and competent, or, when necessary, is assisted by someone who is, depending on the urgency of the problem and availability and accessibility of alternative providers.
- ◆ Patients are assured access to, and continuity of, needed and appropriate ophthalmic care, which can be described as follows.
 - ◆ The ophthalmologist treats patients with due regard to timeliness, appropriateness, and his or her own ability to provide such care.
 - ◆ The operating ophthalmologist makes adequate provision for appropriate pre- and postoperative patient care.
 - ◆ When the ophthalmologist is unavailable for his or her patient, he or she provides appropriate alternate ophthalmic care, with adequate mechanisms for informing patients of the existence of such care and procedures for obtaining it.
 - ◆ The ophthalmologist refers patients to other ophthalmologists and eye care providers based on the timeliness and appropriateness of such referral, the patient's needs, the competence and qualifications of the person to whom the referral is made, and access and availability.

Appendix 1. Quality of Ophthalmic Care Core Criteria

- ◆ The ophthalmologist seeks appropriate consultation with due regard to the nature of the ocular or other medical or surgical problem. Consultants are suggested for their skill, competence, and accessibility. They receive as complete and accurate an accounting of the problem as necessary to provide efficient and effective advice or intervention, and in turn they respond in an adequate and timely manner. The ophthalmologist maintains complete and accurate medical records.
- ◆ On appropriate request, the ophthalmologist provides a full and accurate rendering of the patient's records in his or her possession.
- ◆ The ophthalmologist reviews the results of consultations and laboratory tests in a timely and effective manner and takes appropriate actions.
- ◆ The ophthalmologist and those who assist in providing care identify themselves and their profession.
- ◆ For patients whose conditions fail to respond to treatment and for whom further treatment is unavailable, the ophthalmologist provides proper professional support, counseling, rehabilitative and social services, and referral as appropriate and accessible.
- ◆ Prior to therapeutic or invasive diagnostic procedures, the ophthalmologist becomes appropriately conversant with the patient's condition by collecting pertinent historical information and performing relevant preoperative examinations. Additionally, he or she enables the patient to reach a fully informed decision by providing an accurate and truthful explanation of the diagnosis; the nature, purpose, risks, benefits, and probability of success of the proposed treatment and of alternative treatment; and the risks and benefits of no treatment.
- ◆ The ophthalmologist adopts new technology (e.g., drugs, devices, surgical techniques) in judicious fashion, appropriate to the cost and potential benefit relative to existing alternatives and to its demonstrated safety and efficacy.
- ◆ The ophthalmologist enhances the quality of care he or she provides by periodically reviewing and assessing his or her personal performance in relation to established standards, and by revising or altering his or her practices and techniques appropriately.
- ◆ The ophthalmologist improves ophthalmic care by communicating to colleagues, through appropriate professional channels, knowledge gained through clinical research and practice. This includes alerting colleagues of instances of unusual or unexpected rates of complications and problems related to new drugs, devices, or procedures.
- ◆ The ophthalmologist provides care in suitably staffed and equipped facilities adequate to deal with potential ocular and systemic complications requiring immediate attention.
- ◆ The ophthalmologist also provides ophthalmic care in a manner that is cost effective without unacceptably compromising accepted standards of quality.

Reviewed by: Council
Approved by: Board of Trustees
October 12, 1988

2nd Printing: January 1991

3rd Printing: August 2001

4th Printing: July 2005



APPENDIX 2. INTERNATIONAL STATISTICAL CLASSIFICATION OF DISEASES AND RELATED HEALTH PROBLEMS (ICD) CODES

Diabetic retinopathy, which includes entities with the following ICD-9 and ICD-10 classifications (see Glossary):

	ICD-9 CM	ICD-10 CM
Diabetic retinopathy:		
background	362.01	<ul style="list-style-type: none"> • E10.311 Type 1 with macular edema • E10.319 Type 1 without macular edema • E11.311 Type 2 with macular edema • E11.319 Type 2 without macular edema • E13.311 other specified types of diabetes mellitus with unspecified diabetic retinopathy with macular edema • E13.319 other specified types of diabetes mellitus with unspecified diabetic retinopathy without macular edema
proliferative	362.02	<ul style="list-style-type: none"> • E10.351 Type 1 with macular edema • E10.359 Type 1 without macular edema • E11.351 Type 2 with macular edema • E11.359 Type 2 without macular edema • E13.351 other specified diabetes mellitus with proliferative diabetic retinopathy with macular edema • E13.359 other specified diabetes mellitus with proliferative diabetic retinopathy without macular edema
nonproliferative, NOS	362.03	<ul style="list-style-type: none"> • E10.321 Type 1 with macular edema • E10.329 Type 1 without macular edema • E11.321 Type 2 with macular edema • E11.329 Type 2 without macular edema • E13.321 other specified types of diabetes mellitus with mild nonproliferative diabetic retinopathy with macular edema • E13.329 other specified types of diabetes mellitus with mild nonproliferative diabetic retinopathy without macular edema
nonproliferative, mild	362.04	
nonproliferative, moderate	362.05	<ul style="list-style-type: none"> • E10.331 Type 1 with macular edema • E10.339 Type 1 without macular edema • E11.331 Type 2 with macular edema • E11.339 Type 2 without macular edema • E13.331 other specified types of diabetes mellitus with moderate nonproliferative diabetic retinopathy with macular edema • E13.339 other specified types of diabetes mellitus with moderate nonproliferative diabetic retinopathy without macular edema

**Diabetic Retinopathy PPP:
Appendix 2. ICD Codes**

	ICD-9 CM	ICD-10 CM
Diabetic retinopathy (continued):		
nonproliferative, severe	362.06	<ul style="list-style-type: none"> • E10.341 Type 1 with macular edema • E10.349 Type 1 without macular edema • E11.341 Type 2 with macular edema • E11.349 Type 2 without macular edema • E13.341 other specified types of diabetes mellitus with severe nonproliferative diabetic retinopathy with macular edema • E13.349 other specified types of diabetes mellitus with severe nonproliferative diabetic retinopathy without macular edema
Diabetic macular edema	362.07	<ul style="list-style-type: none"> • E10.321 Type 1 mild nonproliferative diabetic retinopathy • E10.331 Type 1 moderate nonproliferative diabetic retinopathy • E10.341 Type 1 severe nonproliferative diabetic retinopathy • E10.351 Type 1 proliferative diabetic retinopathy • E11.321 Type 2 mild nonproliferative diabetic retinopathy • E11.331 Type 2 moderate nonproliferative diabetic retinopathy • E11.341 Type 2 severe nonproliferative diabetic retinopathy • E11.351 Type 2 proliferative diabetic retinopathy • E13.321 other specified diabetes mellitus with mild nonproliferative diabetic retinopathy • E13.331 other specified diabetes mellitus with moderate nonproliferative diabetic retinopathy

ICD = International Classification of Diseases; CM = Clinical Modification used in the United States; NOS = not otherwise specified

Additional information for ICD-10 codes:

- Certain ICD-10 CM categories have applicable 6th characters. In the diabetic retinopathy series, indicate "with or without" macular edema. Laterality indicators are not required in this series.
 - 1 = with macular edema
 - 9 = without macular edema
- For bilateral sites, the final character of the codes in the ICD-10 CM indicates laterality. If no bilateral code is provided and the condition is bilateral, separate codes for both the left and right side should be assigned. *Unspecified codes should only be used when there is no other code option available.*



APPENDIX 3. PREFERRED PRACTICE PATTERN RECOMMENDATION GRADING

The grades herein report the SIGN grade associated with the included studies supporting each recommendation (I++; I+; I-; II++; II+; II-; III), the GRADE evaluation of the body of evidence (Good, Moderate, Insufficient), and the GRADE assessment of the strength of the recommendation (Strong, Discretionary). Details of these grading systems are reported in the Methods and Key to Ratings section.

Highlighted Findings and Recommendations for Care

Page 4: People with Type 1 diabetes should have annual screenings for diabetic retinopathy beginning 5 years after the onset of their disease, while those with Type 2 diabetes should have yearly screening for diabetic retinopathy beginning immediately following their diagnosis: II+; Good; Strong

Page 4: Patients with diabetes may use aspirin for other medical indications without an adverse effect on their risk of diabetic retinopathy: I++; Good; Discretionary

Page 4: Women who develop gestational diabetes do not require an eye examination during pregnancy, and do not appear to be at increased risk of developing diabetic retinopathy during pregnancy. However, diabetics who become pregnant should be examined early in the course of the pregnancy: II+; Good; Strong

Page 4: Referral to an ophthalmologist is required when there is any non-proliferative diabetic retinopathy, proliferative retinopathy or macular edema: III; Good; Strong

Page 4: Ophthalmologists should communicate the ophthalmologic findings and level of retinopathy with the primary care physician as well as the need for optimizing metabolic control: III; Good; Strong

Page 4: Intravitreal injections of anti-vascular endothelial growth factor (VEGF) agents have been shown to be an effective treatment for center-involving diabetic macular edema: I++; Good; Strong

Page 4: At this time, laser photocoagulation remains the preferred treatment for non-center-involving diabetic macular edema: I++; Good; Strong

Introduction

Page 7: It is recommended that an HbA1c of 7.0% or lower is the target for glycemic control in most patients while in selected patients, there may be some benefit to setting a target of 6.5%: I++; Good; Strong

Page 8: Intensive management of hypertension may slow retinopathy progress, but the data are inconclusive: II++; Moderate; Discretionary

Page 8: Management of serum lipids may reduce retinopathy progression and the need for treatment: II+; Moderate; Discretionary

Page 8: It is reasonable to encourage patients with diabetes to be as compliant as possible with therapy of all medical aspects of their disease: II++; Good; Strong

Care Process

Page 9: The care process for diabetic retinopathy includes a medical history, a regular ophthalmologic examination or screening of high quality retinal photographs of patients who have not had previous treatment for diabetic retinopathy or other eye disease and regular follow-up: III; Good; Strong

Page 9: Patients must be informed that they may have good vision and no ocular symptoms, yet may still have significant disease that needs treatment. They should be educated that early treatment works best and is why they need to return for an annual eye examination, even when their vision is good: III; Good; Strong

Page 9: Individuals with Type 2 diabetes mellitus without diabetic retinopathy should be encouraged to have an annual dilated eye exam or screenings using fundus photography to detect the onset of diabetic retinopathy: II++; Good; Strong

Page 9: Those with Type 1 diabetes mellitus without diabetic retinopathy should have annual dilated eye examinations or screenings beginning 5 years after the onset of diabetes: II++; Good; Strong

Page 9: Table 3, Recommended initial evaluation for Type 1 diabetes: 5 years after diagnosis: II++; Good; Strong

Page 9: Table 3: Recommended follow-up evaluation for Type 1 diabetes: Yearly: III; Good; Strong

Page 9: Table 3: Recommended initial evaluation for Type 2 diabetes: At time of diagnosis: II+; Good; Strong

Page 9: Table 3: Recommended follow-up evaluation for Type 2 diabetes: Yearly: III; Good; Strong

Page 9: Table 3: Recommended initial evaluation for pregnant women with diabetes (Type 1 or Type 2): Soon after conception and early in first trimester: III; Good; Strong

Page 9: Table 3: Recommended follow-up evaluation for pregnant women with diabetes (Type 1 or Type 2), no retinopathy to mild or moderate NPDR: Every 3–12 months: III; Good; Strong

Page 9: Table 3: Recommended follow-up evaluation for pregnant women with diabetes (Type 1 or Type 2), severe NPDR or worse: Every 1–3 months: III; Good; Strong

Page 10: Patients should be informed of the importance of maintaining good glycosylated hemoglobin levels, serum lipids, and blood pressure: III; Good; Strong

Page 10: Aspirin may be used by diabetic patients for other medical indications without concern that the aspirin therapy will worsen diabetic retinopathy: III; Moderate; Discretionary

Page 10: The initial examination for a patient with diabetes mellitus includes all features of the comprehensive adult medical eye evaluation, with particular attention to those aspects relevant to diabetic retinopathy: II++; Good; Strong

Page 10: An initial history should consider duration of diabetes: II++; Good; Strong

Page 10: An initial history should consider past glycemic control: II++; Good; Strong

Page 10: An initial history should consider medications: III; Good; Strong

Page 10: An initial history should consider medical history: II++; Good; Strong

Page 10: An initial history should consider ocular history: III; Good; Strong

Page 10: The initial physical examination should include visual acuity: III; Good; Strong

Page 10: The initial physical examination should include slit-lamp biomicroscopy: III; Good; Strong

Page 10: The initial physical examination should include intraocular pressure: III; Good; Strong

Page 10: The initial physical examination should include gonioscopy before dilation, when indicated: III; Good; Strong

Page 10: The initial physical examination should include thorough funduscopy, including stereoscopic examination of the posterior pole: III; Good; Strong

Page 10: The initial physical examination should include examination of the peripheral retina and vitreous: III; Good; Strong

**Diabetic Retinopathy PPP:
Appendix 3. PPP Recommendation Grading**

Page 10: Slit-lamp biomicroscopy is the recommended method to evaluate retinopathy in the posterior pole and midperipheral retina: III; Good; Strong

Page 10: Examination of the peripheral retina is best performed with indirect ophthalmoscopy or with slit-lamp biomicroscopy: III; Good; Strong

Page 10: A detailed examination is indicated to assess for macular edema: III; Good; Strong

Page 10: A detailed examination is indicated to assess for signs of severe NPDR: III; Good; Strong

Page 10: A detailed examination is indicated to assess for optic nerve head neovascularization and/or neovascularization elsewhere: III; Good; Strong

Page 10: A detailed examination is indicated to assess for vitreous or preretinal hemorrhage: III; Good; Strong

Page 11: Ophthalmic examinations are recommended beginning 5 years after the diagnosis of Type I diabetes and annually thereafter: II++; Good; Strong

Page 11: The patient with Type 2 diabetes should be referred for ophthalmologic evaluation at the time of diagnosis: II+; Good; Strong

Page 11: Patients with diabetes who plan to become pregnant should have an ophthalmologic examination prior to pregnancy and should be counseled about the risk of development and/or progression of diabetic retinopathy: III; Good; Strong

Page 11: The obstetrician or primary care physician should carefully guide the management of the pregnant diabetic's blood glucose as well as other issues related to pregnancy: III; Good; Strong

Page 11: During the first trimester, an eye examination should be performed with repeat and follow-up visits scheduled depending on the severity of retinopathy: III; Good; Strong

Page 11: Women who develop gestational diabetes¹⁰⁸ do not require an eye examination during pregnancy and do not appear to be at increased risk for diabetic retinopathy during pregnancy: II+; Good; Strong

Page 11: After the first-trimester eye examination, the ophthalmologist should discuss the results and their implications with the patient: III; Good; Strong

Page 11: Both eyes should be classified according to the categories of diabetic retinopathy and macular edema discussed in the Natural History and Treatment sections: III; Good; Strong

Page 11: If used appropriately, color and red-free fundus photography ancillary to the clinical examination may enhance patient care: III; Insufficient; Discretionary

Page 11: If used appropriately, optical coherence tomography ancillary to the clinical examination may enhance patient care: III; Insufficient; Discretionary

Page 11: If used appropriately, fluorescein angiography ancillary to the clinical examination may enhance patient care: III; Insufficient; Discretionary

Page 11: If used appropriately, ultrasonography ancillary to the clinical examination may enhance patient care: III; Insufficient; Discretionary

Page 12: Table 4: OCT is usually used to evaluate unexplained visual acuity loss: III; Insufficient; Discretionary

Page 12: Table 4: OCT is usually used to identify areas of vitreomacular traction: III; Insufficient; Discretionary

Page 12: Table 4: OCT is usually used to evaluate patients with difficult and/or questionable examinations for DME: III; Insufficient; Discretionary

Page 12: Table 4: OCT is occasionally used to investigate other causes of macular swelling: III; Insufficient; Discretionary

Page 12: Table 4: OCT is never used to screen a patient with no or minimal diabetic retinopathy: III; Good; Strong

Page 12: Routine fluorescein angiography is not indicated as a part of the regular examination of patients with diabetes: III; Good; Strong

Page 12: Facilities for fluorescein angiography should be available to physicians who diagnose and treat patients with diabetic retinopathy: II++; Good; Discretionary

Page 12: Table 5: Fluorescein angiography is usually used to guide laser treatment of CSME: III; Insufficient; Discretionary

Page 12: Table 5: Fluorescein angiography is usually used to evaluate unexplained visual loss: III; Insufficient; Discretionary

Page 12: Table 5: Fluorescein angiography is usually used to identify suspected but clinically obscure retinal neovascularization: III; Insufficient; Discretionary

Page 12: Table 5: Fluorescein angiography is occasionally used to identify areas of vitreomacular traction: III; Insufficient; Discretionary

Page 12: Table 5: Fluorescein angiography is occasionally used to rule out other causes of macular swelling: III; Insufficient; Discretionary

Page 12: Table 5: Fluorescein angiography is occasionally used to identify large areas of capillary nonperfusion: III; Insufficient; Discretionary

Page 12: Table 5: Fluorescein angiography is occasionally used to evaluate patients with difficult and/or questionable examinations for DME: III; Insufficient; Discretionary

Page 12: Table 5: Fluorescein angiography is never used to screen a patient with no or minimal diabetic retinopathy: III; Good; Strong

Page 13: Each angiography facility should have in place an emergency care plan and a clear protocol to minimize the risks and to manage complications: III; Good; Strong

Page 13: Ultrasonography is an extremely valuable diagnostic tool that enables assessment of the status of the retina in the presence of a vitreous hemorrhage or other media opacity: III; Good; Strong

Page 13: Physicians who care for patients with diabetes, and patients themselves, need to be educated about indications for ophthalmologic referral: III; Good; Strong

Page 13: Screening programs should follow established guidelines: III; Good; Strong

Page 13: Close partnership with the primary care physician is important to make sure that the care of the patient is optimized: III; Good; Strong

Page 14: It is important to educate patients with diabetes, in conjunction with their primary care physician, on the importance of optimizing control of blood glucose to as near normal as is safely possible: III; Good; Strong

Page 14: Aspirin appears to be neither helpful nor harmful in the management of diabetic retinopathy: I++; Good; Discretionary

Page 14: Table 6: Follow-up for patients with normal or minimal NPDR and no DME: 12 months: III; Good; Strong

**Diabetic Retinopathy PPP:
Appendix 3. PPP Recommendation Grading**

Page 14: Table 6: Follow-up for patients with mild NPDR and no DME: 12 months: III; Good; Strong

Page 14: Table 6: Follow-up for patients with mild NPDR and ME: 4–6 months: III; Good; Strong

Page 14: Table 6: Follow-up for patients with mild NPDR and CSME: 1 month: III; Good; Strong

Page 14: Table 6: Panretinal photocoagulation laser treatment not recommended for patients with normal or minimal NPDR: III; Good; Strong

Page 14: Table 6: Panretinal photocoagulation laser treatment not recommended for patients with mild NPDR and no DME: III; Good; Strong

Page 14: Table 6: Panretinal photocoagulation laser treatment not recommended for patients with mild NPDR and ME: III; Good; Strong

Page 14: Table 6: Panretinal photocoagulation laser treatment not recommended for patients with mild NPDR and CSME: III; Good; Strong

Page 14: Table 6: Focal and/or grid laser treatment not recommended for patients with normal or minimal NPDR: III; Good; Strong

Page 14: Table 6: Focal and/or grid laser treatment not recommended for patients with mild NPDR and no DME: III; Good; Strong

Page 14: Table 6: Focal and/or grid laser treatment not recommended for patients with mild NPDR and ME: III; Good; Strong

Page 14: Table 6: Focal and/or grid laser treatment sometimes recommended for patients with mild NPDR and CSME: I++; Good; Strong

Page 14: Table 6: Intravitreal anti-VEGF treatment sometimes recommended for patients with mild NPDR and CSME: I++; Good; Strong

Page 14: Table 6: Follow-up for patients with moderate NPDR and no DME: 6–12 months: III; Good; Strong

Page 14: Table 6: Follow-up for patients with moderate NPDR and ME: 3–6 months: III; Good; Strong

Page 14: Table 6: Follow-up for patients with moderate NPDR and CSME: 1 month: III; Good; Strong

Page 14: Table 6: Panretinal photocoagulation laser treatment not recommended for patients with moderate NPDR and no DME: III; Good; Strong

Page 14: Table 6: Panretinal photocoagulation laser treatment not recommended for patients with moderate NPDR and ME: III; Good; Strong

Page 14: Table 6: Panretinal photocoagulation laser treatment not recommended for patients with moderate NPDR and CSME: III; Good; Strong

Page 14: Table 6: Focal and/or grid laser treatment not recommended for patients with moderate NPDR and no DME: III; Good; Strong

Page 14: Table 6: Focal and/or laser treatment not recommended for patients with moderate NPDR and ME: III; Good; Strong

Page 14: Table 6: Focal and/or grid laser treatment sometimes recommended for patients with moderate NPDR and CSME: I++; Good; Strong

Page 14: Table 6: Intravitreal anti-VEGF treatment sometimes recommended for patients with moderate NPDR and CSME: I++; Good; Strong

Page 14: Table 6: Follow-up for patients with severe NPDR and no DME: 4 months: III; Good; Strong

Page 14: Table 6: Follow-up for patients with severe NPDR and ME: 2–4 months: III; Good; Strong

Page 14: Table 6: Follow-up for patients with severe NPDR and CSME: 1 month: III; Good; Strong

Page 14: Table 6: Panretinal photocoagulation laser treatment sometimes recommended for patients with severe NPDR and no DME: I++; Good; Strong

Page 14: Table 6: Panretinal photocoagulation laser treatment sometimes recommended for patients with severe NPDR and ME: I++; Good; Strong

Page 14: Table 6: Panretinal photocoagulation laser treatment sometimes recommended for patients with severe NPDR and CSME: I++; Good; Strong

Page 14: Table 6: Focal and/or grid laser treatment not recommended for patients with severe NPDR and no DME: III; Good; Strong

Page 14: Table 6: Focal and/or grid laser treatment not recommended for patients with severe NPDR and ME: III; Good; Strong

Page 14: Table 6: Focal and/or grid laser treatment sometimes recommended for patients with severe NPDR and CSME: III; Good; Strong

Page 14: Table 6: Intravitreal anti-VEGF treatment not recommended for patients with severe NPDR and no DME: III; Good; Strong

Page 14: Table 6: Intravitreal anti-VEGF treatment not recommended for patients with severe NPDR and ME: III; Good; Strong

Page 14: Table 6: Intravitreal anti-VEGF treatment sometimes recommended for patients with severe NPDR and CSME: III; Insufficient; Discretionary

Page 14: Table 6: Follow-up for patients with non-high-risk PDR and no DME: 4 months: III; Good; Strong

Page 14: Table 6: Follow-up for patients with non-high-risk PDR and ME: 4 months: III; Good; Strong

Page 14: Table 6: Follow-up for patients with non-high-risk PDR and CSME: 1 month: III; Good; Strong

Page 14: Table 6: Panretinal photocoagulation laser treatment sometimes recommended for patients with non-high-risk PDR and no DME: I++; Good; Strong

Page 14: Table 6: Panretinal photocoagulation laser treatment sometimes recommended for patients with non-high-risk PDR and ME: I++; Good; Strong

Page 14: Table 6: Panretinal photocoagulation laser treatment sometimes recommended for patients with non-high-risk PDR and CSME: I++; Good; Strong

Page 14: Table 6: Focal and/or grid laser treatment not recommended for patients with non-high-risk PDR and no DME: III; Good; Strong

Page 14: Table 6: Focal and/or grid laser treatment not recommended for patients with non-high-risk PDR and ME: III; Good; Strong

Page 14: Table 6: Focal and/or grid laser treatment sometimes recommended for patients with non-high-risk PDR and CSME: III; Good; Strong

Page 14: Table 6: Intravitreal anti-VEGF treatment not recommended for patients with non-high-risk PDR and no DME: III; Good; Strong

**Diabetic Retinopathy PPP:
Appendix 3. PPP Recommendation Grading**

Page 14: Table 6: Intravitreal anti-VEGF treatment not recommended for patients with non-high-risk PDR and ME: III; Good; Strong

Page 14: Table 6: Intravitreal anti-VEGF treatment sometimes recommended for patients with non-high-risk PDR and CSME: III; Insufficient; Discretionary

Page 14: Table 6: Follow-up for patients with high-risk PDR and no DME: 4 months: III; Good; Strong

Page 14: Table 6: Follow-up for patients with high-risk PDR and ME: 4 months: III; Good; Strong

Page 14: Table 6: Follow-up for patients with high-risk PDR and CSME: 1 month: III; Good; Strong

Page 14: Table 6: Panretinal photocoagulation laser treatment recommended for patients with high-risk PDR and no DME: I++; Good; Strong

Page 14: Table 6: Panretinal photocoagulation laser treatment recommended for patients with high-risk PDR and ME: I++; Good; Strong

Page 14: Table 6: Panretinal photocoagulation laser treatment usually recommended for patients with high-risk PDR and CSME: I++; Good; Strong

Page 14: Table 6: Focal and/or grid laser treatment not recommended for patients with high-risk PDR and no DME: III; Good; Strong

Page 14: Table 6: Focal and/or grid laser treatment sometimes recommended for patients with high-risk PDR and ME: III; Good; Strong

Page 14: Table 6: Focal and/or grid laser treatment sometimes recommended for patients with high-risk PDR and CSME: III; Good; Strong

Page 14: Table 6: Intravitreal anti-VEGF treatment considered for patients with high-risk PDR and no DME: III; Good; Strong

Page 14: Table 6: Intravitreal anti-VEGF treatment usually recommended for patients with high-risk PDR and ME: III; Good; Strong

Page 14: Table 6: Intravitreal anti-VEGF treatment usually recommended for patients with high-risk PDR and CSME: III; Good; Strong

Page 15: The patient with a normal retinal exam or minimal NPDR should be re-examined annually: III; Good; Strong

Page 15: Laser surgery, color fundus photography, and fluorescein angiography are not indicated for patients with normal retinal examinations or minimal NPDR: III; Good; Strong

Page 15: Patients with retinal microaneurysms and occasional blot hemorrhages or hard exudates should be re-examined within 6 to 12 months: III; Good; Strong

Page 15: Laser surgery and fluorescein angiography are not indicated for mild to moderate NPDR without macular edema: III; Good; Strong

Page 15: Color fundus photography and OCT imaging of the macular may occasionally be helpful to establish a baseline for future comparison: III; Insufficient; Discretionary

Page 15: Patients with mild or moderate NPDR and non-clinically significant macular edema should be re-examined within 3 to 4 months: III; Good; Strong

Page 16: Macular edema is best evaluated by dilated examination using slit-lamp biomicroscopy, optical coherence tomography, and/or stereoscopic fundus photography: III; Good; Strong

Page 16: An ophthalmologist who treats patients for macular edema should be familiar with relevant studies and techniques as described in the ETDRS: III; Good; Strong

Page 16: Fluorescein angiography prior to laser surgery for CSME is often helpful for identifying treatable lesions: III; Good; Discretionary

Page 16: Fluorescein angiography is useful for identifying capillary dropout and pathologic enlargement of the foveal avascular zone, a feature that may be useful when planning treatment: III; Good; Discretionary

Page 16: Color fundus photography is often helpful to document the status of the retina even if laser surgery is not performed: III; Good; Discretionary

Page 16: Optical coherence tomography is a helpful screening tool to detect subtle edema and to follow the course of edema after treatment: III; Good; Discretionary

Page 16: The treatment of CMSE has traditionally been laser surgery; however, current data demonstrates that intravitreal anti-VEGF agents are effective treatments for center-involving CSME: I++; Good; Strong

Page 16: The ETDRS demonstrated a benefit of laser photocoagulation in both ci-CSME and nci-CSME: I++; Good; Strong

Page 16: Anti-VEGF therapy is the treatment of choice for macular edema with or without focal laser treatment: I++; Good; Strong

Page 17: Treating physicians should note that the use of betadine antiseptic drops is recommended during intravitreal injections: III; Good; Strong

Page 17: The use of routine antibiotic eye drops is not recommended before or following intravitreal injection procedures: III; Insufficient; Discretionary

Page 17: Many retina specialists prefer a less intense laser treatment, greater spacing, directly targeting microaneurysms, and avoiding foveal vasculature within at least 500 μm of the center of the macula: I++; Good; Discretionary

Page 17: Preoperatively, the ophthalmologist should discuss with the patient the side effects and risks of treatment: III; Good; Strong

Page 17: A follow-up examination for individuals with CSME should be scheduled within 3 to 4 months of laser surgery: III; Good; Strong

Page 17: Individuals receiving the intravitreal injections of anti-VEGF agents may be examined at 1 month following therapy: III; Good; Strong

Page 17: When treatment for macular edema is deferred, the patient should be observed closely (at least every 3 to 4 months) for signs of progression: III; Good; Strong

Page 17: Patients with very severe NPDR should be re-examined within 2 to 4 months: III; Good; Strong

Page 17: Panretinal photocoagulation should not be recommended for eyes with mild or moderate NPDR, provided that follow-up [can] be maintained: I++; Good; Strong

Page 17: When retinopathy is more severe, panretinal photocoagulation should be considered and should not be delayed when the eye reaches the high-risk proliferative stage: I++; Good; Strong

Page 18: Careful follow-up at 3 to 4 months is important: if the patient will not or cannot be followed closely or if there are associated medical conditions such as impending cataract surgery or pregnancy, then early laser photocoagulation may be warranted: III; Good; Strong

Page 18: Laser photocoagulation may be indicated particularly when access to health care is difficult: III; Insufficient; Discretionary

**Diabetic Retinopathy PPP:
Appendix 3. PPP Recommendation Grading**

Page 18: If laser surgery is elected, full panretinal photocoagulation is a proven surgical technique: I++; Good; Strong

Page 18: Partial panretinal photocoagulation treatment is not recommended: III; Good; Strong

Page 18: The recommendation to consider panretinal photocoagulation before the development of high-risk PDR is particularly appropriate for patients with Type 2 diabetes and severe to non-high-risk NPDR: II++; Moderate; Strong

Page 18: For patients with Type 1 diabetes, the timing of the panretinal photocoagulation depends on the compliance with follow-up and the status and response to treatment of the fellow eye: III; Insufficient; Discretionary

Page 18: Preoperatively [to laser surgery], the ophthalmologist should assess macular edema, discuss side effects of treatment and risks of visual loss with the patient, and obtain informed consent: III; Good; Strong

Page 18: When panretinal photocoagulation for severe NPDR or non-high-risk PDR is to be performed on eyes with macular edema, many experts think that it is preferable to perform focal photocoagulation and/or anti-VEGF therapy prior to panretinal photocoagulation: III; Good; Strong

Page 18: Panretinal photocoagulation surgery should not be delayed when PDR is at the high-risk stage: III; Good; Strong

Page 18: When PDR is at the high-risk stage, anti-VEGF therapy and panretinal photocoagulation may be performed concomitantly: III; Good; Strong

Page 18: Fluorescein angiography may be helpful to determine the presence or absence of areas of nonperfusion and/or clinically undetected areas of retinal neovascularization and to establish the cause for a loss in visual acuity: III; Moderate; Discretionary

Page 18: The risk of severe visual loss among patients with high-risk PDR is reduced substantially by treatment using panretinal photocoagulation as described in the DRS and ETDRS: I++; Good; Strong

Page 18: Most patients with high-risk PDR should receive panretinal photocoagulation surgery expeditiously: II++; Good; Strong

Page 19: Additional panretinal photocoagulation or vitrectomy may be required for increasing neovascularization of the iris and may be considered for the following indications: failure of the neovascularization to regress; increasing neovascularization of the retina or iris; new vitreous hemorrhage; new areas of neovascularization: III; Insufficient; Discretionary

Page 19: For patients who have CSME in addition to high-risk PDR, combined anti-VEGF therapy and panretinal photocoagulation at the first treatment session should be considered: III; Insufficient; Discretionary

Page 19: Fluorescein angiography does not usually need to be performed in order to apply the panretinal photocoagulation effectively. If CSME is present, however, a fluorescein angiogram may be used to guide focal photocoagulation: III; Insufficient; Discretionary

Page 19: Vitreous hemorrhages following extensive panretinal photocoagulation may clear spontaneously and do not necessarily require additional laser surgery: III; Insufficient; Discretionary

Page 19: Some patients with previously untreated PDR who have vitreous opacities and active neovascular or fibrovascular proliferation should be considered candidates for pars plana vitrectomy: I++; Good; Strong

Page 19: In some patients with severe vitreous or preretinal hemorrhage, in which advanced, active PDR persists despite extensive panretinal photocoagulation, vitrectomy surgery may be indicated: III; Insufficient; Discretionary

Page 19: Vitreous surgery is frequently indicated in patients with traction macular detachment (particularly of recent onset), combined traction–rhegmatogenous retinal detachment, and vitreous hemorrhage precluding panretinal photocoagulation: III; Insufficient; Discretionary

Page 19: Patients with vitreous hemorrhage and rubeosis iridis also should be considered for prompt vitrectomy and intraoperative panretinal photocoagulation surgery: III; Insufficient; Discretionary

Page 20: A follow-up history should include changes in symptoms: III; Good; Strong

Page 20: A follow-up history should include changes in systemic status: III; Good; Strong

Page 20: A follow-up history should include changes in glycemic status: III; Good; Strong

Page 20: A follow-up examination should include visual acuity: III; Good; Strong

Page 20: A follow-up examination should include slit-lamp biomicroscopy with iris examination: III; Good; Strong

Page 20: A follow-up examination should include intraocular pressure: III; Good; Strong

Page 20: A follow-up examination should include gonioscopy (preferably before dilation when iris neovascularization is suspected or if IOP is elevated): III; Good; Strong

Page 20: A follow-up examination should include stereoscopic examination of the posterior pole after dilation of the pupils: III; Good; Strong

Page 20: A follow-up examination should include OCT imaging, when appropriate: III; Good; Strong

Page 20: A follow-up examination should include peripheral retina and vitreous examination, when indicated: III; Good; Strong

Page 20: Although the ophthalmologist will perform most of the examination and all surgery, certain aspects of data collection may be performed by trained individuals under the ophthalmologist’s supervision and review: III; Good; Strong

Page 20: Because of the complexities of the diagnosis and treatment for diabetic retinopathy, the ophthalmologist caring for patients with this condition should be familiar with the specific recommendations of relevant clinical trials: III; Good; Strong

Page 20: The ophthalmologist should refer patients with diabetes to a primary care physician for appropriate management of their systemic condition, and should communicate examination results to the physician managing the patient’s ongoing diabetes care: III; Good; Strong

Page 20: Those whose conditions fail to respond to surgery and those for whom further treatment is unavailable should be provided with proper professional support and offered referral for counseling, vision rehabilitation, or social services as appropriate: III; Good; Strong

Page 20: Patients with functionally limiting postoperative visual impairment should be referred for vision rehabilitation and social services: III; Good; Strong

APPENDIX 5

Page 40: Frequent ophthalmologic monitoring is important when patients are being brought under better control: III; Good; Strong

Page 40: Diabetes mellitus education and regular reinforcement should be provided by diabetes nurses and dietitian educators and may help minimize the risk of hypoglycemia: III; Good; Strong



APPENDIX 4. MAJOR STUDY RESULTS

DIABETIC RETINOPATHY STUDY (1972–1979)

The Diabetic Retinopathy Study (DRS) was designed to investigate the value of laser photocoagulation surgery for patients with severe NPDR and PDR.⁶¹ The results are shown in Table A4-1.

TABLE A4-1 VISUAL OUTCOME FOR LASER PHOTOCOAGULATION FROM THE DIABETIC RETINOPATHY STUDY

Baseline Severity of Retinopathy	Duration of Follow-up (Years)	Control Patients (% with Severe Visual Loss)	Treated Patients (% with Severe Visual Loss)
Severe nonproliferative	2	3	3
	4	13	4
Mild proliferative	2	7	3
	4	21	7
High-risk proliferative	2	26	11
	4	44	20

NOTE: Severe visual loss was defined as worse than 5/200 visual acuity at two or more consecutive completed visits (scheduled at 4-month intervals).

WISCONSIN EPIDEMIOLOGIC STUDY OF DIABETIC RETINOPATHY (1979)

The Wisconsin Epidemiologic Study of Diabetic Retinopathy (WESDR) began in 1979. It was initially funded by the National Eye Institute, which is part of the National Institutes of Health. The purpose of the WESDR is to describe the frequency and incidence of complications associated with diabetes (eye complications such as diabetic retinopathy and visual loss, kidney complications such as diabetic nephropathy, and amputations), and to identify risk factors (such as poor glycemic control, smoking, and high blood pressure) that may contribute to the development of these complications.⁶⁷

EARLY TREATMENT DIABETIC RETINOPATHY STUDY (1985–1990)

The Early Treatment Diabetic Retinopathy Study (ETDRS) investigated the value of photocoagulation surgery for patients with NPDR or PDR without high-risk characteristics.^{65,102} The results for eyes with macular edema are shown in Table A4-2. Visual loss was defined as at least doubling of the visual angle (e.g., 20/20 to 20/40, or 20/50 to 20/100).

TABLE A4-2 VISUAL OUTCOME FOR LASER PHOTOCOAGULATION TREATMENT FROM THE EARLY TREATMENT DIABETIC RETINOPATHY STUDY

Extent of Macular Edema	Duration of Follow-up (Years)	Control Patients (% with Visual Loss)	Treated Patients (% with Visual Loss)
CSME (center of macula not involved)	1	8	1
	2	16	6
	3	22	13
CSME (center of macula involved)	1	13	8
	2	24	9
	3	33	14

CSME = clinically significant macular edema

NOTE: Visual loss was defined as at least doubling of the visual angle.

Results of Early Scatter Laser Treatment in ETDRS

In eyes with NPDR or non-high-risk PDR, early panretinal photocoagulation was compared with deferral of photocoagulation, and although there was a beneficial treatment effect, the outlook for maintaining vision was good in both groups. The 5-year rates of severe visual loss or vitrectomy ranged from 2% to 6% in eyes assigned to early photocoagulation and from 4% to 10% in eyes assigned to deferral. Early panretinal photocoagulation was associated with side effects (small decreases in visual acuity and visual field) in some eyes, and the ETDRS concluded that deferral of photocoagulation was preferable at least until retinopathy was approaching the high-risk stage. Eyes approaching that stage had a 50% risk of reaching it within 12 to 18 months. Eyes in this category had very severe NPDR or non-high-risk PDR characterized by NVD less than one-quarter to one-third disc area and/or NVE, without vitreous or preretinal hemorrhage.

Recent additional analyses of visual outcome in ETDRS patients with severe NPDR to non-high-risk PDR suggest that the recommendation to consider panretinal photocoagulation before the development of high-risk PDR is particularly appropriate for patients with Type 2 diabetes.¹⁶⁸ The risk of severe vision loss or vitrectomy was reduced by 50% in patients who were treated early compared with those who deferred treatment until high-risk PDR developed.

For patients with Type 1 diabetes, the timing of the panretinal photocoagulation will depend on the compliance with follow-up, status and response to treatment of the fellow eye, impending cataract surgery, and/or pregnancy status.

DIABETIC RETINOPATHY VITRECTOMY STUDY (1983–1987)

The Diabetic Retinopathy Vitrectomy Study (DRVS) investigated the role of vitrectomy in managing eyes with very severe PDR.^{66,170-172} The benefit of early vitrectomy for severe vitreous hemorrhage (defined as hemorrhage obscuring the macula or major retinal vessels for three disc diameters from the macular center) was seen in Type 1 patients, but no such advantage was found in Type 2 patients, who did not benefit from earlier surgery. Early vitrectomy was beneficial among patients with visual acuity of 5/200 or worse and severe vitreous hemorrhage with reduced vision for at least 1 month and without previous treatment or complications such as retinal detachment or neovascularization of the iris. Overall, at 2 years after surgery, 25% of the early vitrectomy group and 15% of the deferral group had visual acuity of 20/40 or better. The advantage was most pronounced in patients with Type 1 diabetes (36% vs. 12% for early vitrectomy versus deferral of vitrectomy, respectively) and was not statistically significant for patients with Type 2 diabetes.

The DRVS showed that early vitrectomy was beneficial for patients with visual acuity of 20/400 or better plus one of the following: (1) severe neovascularization and fibrous proliferation; (2) fibrous proliferation and moderate vitreous hemorrhage; or (3) moderate neovascularization, severe fibrous proliferation, and moderate vitreous hemorrhage. Among such patients, 44% with early vitrectomy and 28% in the observation group had visual acuity of 20/40 or better at 4 years of follow-up.

The results of the DRVS should be interpreted in light of subsequent advances in vitreoretinal surgery, such as the introduction of small-gauge vitrectomy technology, endoscopic and indirect ophthalmoscopic laser photocoagulation, and advanced instrumentation. The use of long-acting intraocular gases such as sulfur hexafluoride and perfluoropropane, the use of viscodissection, and the use of heavier-than-water liquids such as perfluoro-octane are advances in vitreoretinal surgery that developed after the DRVS. Thus, the results may actually be better than those reported in the DRVS.^{136,196} Early vitrectomy should be considered for selected patients with Type 2 diabetes, particularly those in whom severe vitreous hemorrhage prohibits laser therapy photocoagulation of active neovascularization.

FENOFIBRATE INTERVENTION AND EVENT LOWERING IN DIABETES (FIELD) STUDY (2005)

The FIELD study was a randomized controlled trial that evaluated long-term fenofibrate therapy for the reduction of cardiovascular events in 9795 patients with Type 2 diabetes mellitus. Fenofibrate did not significantly reduce the risk of the primary outcome of coronary events. It did reduce total cardiovascular events, mainly due to fewer nonfatal myocardial infarctions and revascularizations. The higher rate of starting statin therapy in patients allocated to receive placebo might have masked a moderately larger treatment benefit.

DIABETIC RETINOPATHY CLINICAL RESEARCH NETWORK (DRCR.NET) (2002–PRESENT)

The Diabetic Retinopathy Clinical Research Network (DRCR.net) is a collaborative network dedicated to facilitating multicenter clinical research of diabetic retinopathy, diabetic macular edema, and associated conditions. The DRCR.net supports the identification, design, and implementation of multicenter clinical research initiatives focused on diabetes-induced retinal disorders. Principal emphasis is placed on clinical trials, but epidemiologic outcomes and other research may be supported as well.

The DRCR.net was formed in 2002 and currently includes over 109 participating sites (offices) with over 320 physicians throughout the United States. The DRCR.net is funded by the National Eye Institute (NEI), which is a part of the National Institutes of Health, the branch of government that funds medical research.

The DRCR.net has completed multiple clinical trials evaluating the role of anti-VEGF, laser treatment, and corticosteroids in diabetic macular edema. One of the most important is Protocol I: Intravitreal Ranibizumab for Diabetic Macular Edema with Prompt vs. Deferred Laser Treatment. Three-year results were reported in 2012. The study utilized ranibizumab monthly until improvement no longer occurred (with resumption if the condition worsened) and random assignment to focal/grid laser treatment promptly or deferred (≥ 24 weeks). The 3-year results suggest that focal/grid laser treatment at the initiation of intravitreal ranibizumab is no better, and possibly worse for vision outcomes, than deferring laser treatment for ≥ 24 weeks in eyes with DME involving the fovea and with vision impairment.⁷⁰

A previous publication from Protocol I results confirmed the 1 year results that intravitreal ranibizumab with prompt or deferred laser was more effective through 2 years compared with prompt laser alone for the treatment of DME involving the central macula. Laser was not associated with endophthalmitis, the rare but potentially devastating complication of injecting ranibizumab. In pseudophakic eyes, results with intravitreal triamcinolone plus prompt laser appeared similar to results in the ranibizumab arms and were more effective than laser alone, but the triamcinolone plus prompt laser arm had an increased risk of IOP elevation.¹³¹

STUDY OF RANIBIZUMAB INJECTION IN SUBJECTS WITH CSDME WITH CENTER INVOLVEMENT SECONDARY TO DIABETES MELLITUS (RISE AND RIDE)

The RISE and RIDE trials were parallel phase III multicenter double-masked sham injection–controlled randomized studies conducted at private and university-based retina specialty clinics in the United States and South America. (See Glossary.)

The phase III results for both studies were published in 2012. The studies utilized monthly intravitreal ranibizumab (0.5 or 0.3 mg) or sham injections, with macular laser available if needed. The study concluded that ranibizumab rapidly and sustainably improved vision, reduced the risk of further vision loss, and improved macular edema in patients with DME, with low rates of ocular and nonocular side effects.¹⁴⁷

RANIBIZUMAB FOR EDEMA OF THE MACULA IN DIABETES (READ-2)

READ-2 was a phase II multicenter randomized controlled trial that compared 0.5 mg injections of ranibizumab versus focal laser treatment over 2 years in patients with Type 1 or Type 2 diabetes mellitus and DME. Patients randomized to one arm of the trial received ranibizumab at baseline, and at 1, 3 and 5 months after baseline; a second arm received laser treatment at baseline and at 3 months (if needed); the third arm received both ranibizumab and laser treatment at baseline and 3 months. From month 5, all subjects received ranibizumab every 2 months and/or maintenance laser treatment every 3 months.

At 24 months, differences between the groups were not statistically significant, and all groups experienced improved visual acuity. Patients receiving combined ranibizumab and laser treatment required fewer injections than patients receiving ranibizumab alone.¹⁵⁰

BEVACIZUMAB OR LASER THERAPY (BOLT) STUDY

BOLT was a phase II 2-year randomized controlled trial that compared intravitreal 1.25 mg bevacizumab injections and focal laser treatment in patients with persistent DME and visual impairment. Bevacizumab patients received an injection every 6 weeks, whereas laser patients were treated every 4 weeks.

At 2 years, visual acuity results were substantially better in the bevacizumab group compared with the laser group, with significant differences in the proportions of patients gaining 10 letters and 15 letters. No patients lost 10 or more letters in the bevacizumab group, compared with 14% of patients treated with laser.¹⁵¹

DME AND VEGF TRAP-EYE: INVESTIGATION OF CLINICAL IMPACT (DA VINCI) STUDY

DA VINCI was an active-controlled phase II randomized controlled trial that compared various doses of aflibercept and focal laser treatment in patients with CSME. At 1 year, patients receiving aflibercept had greater gains in visual acuity (averaging 9.7–12.0 letters gained) compared with patients receiving laser treatment (averaging -1.3 letters lost). Aflibercept patients were also more likely to gain 10 or more letters and 15 or more letters than patients in the laser treatment arm.¹⁵²



APPENDIX 5. GLYCEMIC CONTROL

The Diabetes Control and Complications Trial (DCCT) was a multicenter, randomized controlled trial designed to study the connection between glycemic control and retinal, renal, and neurologic complications of Type 1 diabetes mellitus. Published results from this trial demonstrated that improved blood sugar control can delay the onset and slow the progression of diabetic retinopathy, nephropathy, and neuropathy in Type 1 patients.⁵⁷ The DCCT showed a strong exponential relationship between the risk of diabetic retinopathy and the mean hemoglobin A_{1c} (HbA_{1c}) level. For each 10% decrease in the HbA_{1c} (e.g., from 9% to 8.1%), there was a 39% decrease in the risk of progression of retinopathy over the range of HbA_{1c} values. There was no glycemic threshold when the risk of retinopathy was eliminated above the nondiabetic range of HbA_{1c} (4% to 6.05%).

After 6.5 years of follow-up, the DCCT ended, and all patients were encouraged to pursue strict control of blood sugar. Most of these patients are being followed in the Epidemiology of Diabetes Interventions and Complications (EDIC) study, which includes 95% of the DCCT subjects. A total of 1294 to 1335 patients have been examined annually in the EDIC study. Further progression of diabetic retinopathy during the first 4 years of the EDIC study was 66% to 77% less in the former intensive treatment group than in the former conventional treatment group.³⁵ The benefit persisted even at 7 years. This benefit included an effect on severe diabetic retinopathy, including severe NPDR, PDR, CSME, and the need for focal/grid or panretinal laser photocoagulation.³⁷ The decrease in HbA_{1c} from 9% to approximately 8% did not drastically reduce the progression of diabetic retinopathy in the former conventional treatment group, nor did the increase in HbA_{1c} from approximately 7% to approximately 8% drastically accelerate diabetic retinopathy in the former intensive treatment group.³⁵ Thus, it takes time for improvements in control to negate the long-lasting effects of prior prolonged hyperglycemia, and once the biological effects of prolonged improved control are manifest, the benefits are long-lasting. Furthermore, the total glycemic exposure of the patient (i.e., degree and duration) determines the degree of retinopathy observed at any one time.

A positive relationship between the 4-year incidence and progression of retinopathy and glycosylated hemoglobin remains after controlling for other risk factors, such as duration of diabetes and severity of retinopathy at a baseline examination.^{51,52,100} Extrapolation of pathologic and clinical experience strongly suggests that poor levels of control contribute to microangiopathy, including retinopathy.¹⁹⁷ The development of PDR parallels an increased risk of nephropathy, myocardial infarction, and/or cerebral vascular accidents.

Although good glycemic control is advised, there is some evidence that rapid improvement of long-standing poor control may increase the risk of retinopathy progression over the first year for some patients. About 10% of Type 1 patients who had initial retinopathy at the beginning of the DCCT had increased retinopathy progression.¹⁹⁸ Specifically, there may be a transient increase in the number of cotton-wool spots seen on retinal examination. Frequent ophthalmologic monitoring is important when diabetic patients are being brought under better metabolic control.¹⁹⁸

In the DCCT there was a threefold increase in severe hypoglycemic events and excess weight gain among patients using intensive treatment regimens. Increased risk of hypoglycemia is a consequence of strict blood glucose control. Irregular food intake, failure to check blood glucose before planned or unplanned vigorous exercise or before operating a motor vehicle, and excess alcohol are risk factors for hypoglycemia. Diabetes mellitus education and regular reinforcement should be provided by diabetes nurses and dietitian educators and may help minimize the risk of hypoglycemia.

The United Kingdom Prospective Diabetes Study (UKPDS),^{38,96} a randomized controlled clinical trial of blood glucose control, enrolled 3867 patients with newly diagnosed Type 2 diabetes. Intensive blood glucose control by either the sulfonylureas or insulin decreased the risk of microvascular complications but not the risk of macrovascular disease. There were no adverse effects of the individual drugs on the cardiovascular outcome. In this study, there was a 29% reduction in the need for retinal photocoagulation in the group that had intensive glucose therapy compared with those that had conventional treatment (relative risk, 0.71; 95% confidence interval, 0.53–0.96; $P=0.003$).

The ACCORD (Action to Control Cardiovascular Risk in Diabetes) study (www.accordtrial.org) was a large clinical trial of adults with established Type 2 diabetes who are at especially high risk of cardiovascular disease (CVD). Type 2 diabetes increases the risk of a number of complications, especially CVD, which is the leading cause of early death in people with diabetes.

The ACCORD study consisted primarily of three clinical trials that tested treatment approaches to determine the best ways to decrease the high rate of major CVD events—heart attack, stroke, or death from CVD—among people with Type 2 diabetes who are at especially high risk of having such a CVD event. These three treatment approaches were intensive lowering of blood sugar levels compared with a more standard blood sugar treatment; intensive lowering of blood pressure compared with standard blood pressure treatment; and treatment of multiple blood lipids with two drugs—a fibrate plus a statin—compared with one drug, a statin alone.¹⁹⁹

The study began enrolling participants in 2001 and took place in 77 clinical sites across the United States and Canada. A total of 10,251 adults with established Type 2 diabetes participated in ACCORD. At enrollment, study participants were between age 40 and 79 (average age 62), had diabetes for an average of 10 years, and were at especially high risk for CVD events because they already had pre-existing CVD, evidence of subclinical CVD, or at least two CVD risk factors in addition to Type 2 diabetes. The other CVD risk factors could be high low-density lipoprotein (LDL) cholesterol, high blood pressure, smoking, or obesity.

The primary outcome measure for all three trials was the first occurrence after randomization of a major CVD event, specifically nonfatal heart attack, nonfatal stroke, or CVD death. Secondary outcomes include total mortality (death), microvascular outcomes (e.g., eye, kidney, and nerve complications), health-related quality of life, and cost-effectiveness.

All three ACCORD clinical trials have ended. The National Heart, Lung, and Blood Institute (NHLBI) stopped the intensive blood sugar lowering strategy in 2008 due to safety concerns. Participants in the intensive blood sugar treatment strategy group were transitioned to the standard treatment strategy. The blood pressure and lipid treatment trials continued until the planned end of the study in 2009. In its regular review of the available study data, the ACCORD Data and Safety Monitoring Board (DSMB) noticed an unexpected increase in total deaths from any cause among participants who had been randomly (by chance) assigned to the intensive lowering of blood sugar levels group compared with those assigned to the standard blood sugar treatment group. The data analyses showed that over an average of 3.5 years of treatment (ranging from about 2 years to about 7 years), 257 participants in the intensive group died compared with 203 in the standard group—a difference of 54 deaths, or an excess of about 3 deaths per 1,000 participants treated for a year. This translates to a statistically significant 22% higher rate of death in the intensive group than in the standard group.

There was a trend toward lower (10% lower) rate of primary outcome events, primarily nonfatal heart attacks, in the intensive group compared with the standard treatment group. However, the DSMB recommended discontinuing intensive blood sugar treatment because the harm of the intensive strategy outweighed the potential benefit. The NHLBI accepted the DSMB's recommendation and decided to transition all participants to the standard blood sugar strategy.

The results of the blood sugar trial were published in 2008.²⁰⁰ There was no significant difference in the primary study outcome between the intensive and standard blood pressure treatment groups. The primary outcome was the time to first occurrence after randomization of a heart attack, a stroke, or a cardiovascular death. Thus, the primary hypothesis of the ACCORD BP trial was not supported. There was, however, a significant reduction in the rate of strokes, although the numbers were relatively small. This reduction in stroke was consistent with previous blood pressure lowering trials. Overall, however, the findings from the ACCORD blood pressure trial suggest that, on average, the standard treatment for lowering blood pressure was just as good as the intensive lowering treatment for cardiovascular outcomes.

The results of the lipid²⁰¹ and the blood pressure²⁰² trials were published in 2010. Overall, the fibrate and the placebo groups did not differ in the rates of the combined outcome of heart attacks, strokes, or cardiovascular death. The results, however, suggest that men may benefit from this treatment, but there was a trend toward more cardiovascular problems in women receiving the combination therapy compared with those who received statins only. Also, the group of patients who at the start of the trial had the lowest level of HDL cholesterol combined with the highest level of triglycerides (which represented only 17% of the ACCORD participants) may have benefitted from this combined drug treatment.



APPENDIX 6. CLASSIFICATION OF DIABETIC RETINOPATHY IN THE EARLY TREATMENT OF DIABETIC RETINOPATHY STUDY

The Early Treatment of Diabetic Retinopathy Study (ETDRS) classification of diabetic retinopathy and definitions of macular edema are in Tables A6-1 and A6-2.

TABLE A6-1 CLASSIFICATION OF DIABETIC RETINOPATHY IN THE EARLY TREATMENT OF DIABETIC RETINOPATHY STUDY

Disease Severity Level	Findings Observable upon Dilated Ophthalmoscopy
Mild nonproliferative retinopathy	At least one microaneurysm, and definition not met for moderate nonproliferative retinopathy, severe nonproliferative retinopathy, early proliferative retinopathy, or high-risk proliferative retinopathy (see below)
Moderate nonproliferative retinopathy	Hemorrhages and/or microaneurysms \geq standard photograph 2A*; and/or soft exudates, venous beading, or intraretinal microvascular abnormalities definitely present; and definition not met for severe nonproliferative retinopathy, early proliferative retinopathy, or high-risk proliferative retinopathy (see below)
Severe nonproliferative retinopathy	Cotton-wool spots, venous beading, and intraretinal microvascular abnormalities all definitely present in at least two of fields four through seven; or two of the preceding three lesions present in at least two of fields four through seven and hemorrhages and microaneurysms present in these four fields, \geq standard photo 2A in at least one of them; or intraretinal microvascular abnormalities present in each of fields four through seven and \geq standard photograph 8A in at least two of them; and definition not met for early proliferative retinopathy or high-risk proliferative retinopathy (see below)
Early proliferative retinopathy (i.e., proliferative retinopathy without Diabetic Retinopathy Study high-risk characteristics) (see Glossary)	New vessels; and definition not met for high-risk proliferative retinopathy (see below)
High-risk proliferative retinopathy (i.e., proliferative retinopathy with Diabetic Retinopathy Study high-risk characteristics) (see Glossary)	New vessels on or within one disc diameter of the optic disc (NVD) \geq standard photograph 10A* (about one-quarter to one-third disc area), with or without vitreous or preretinal hemorrhage; or vitreous and/or preretinal hemorrhage accompanied by new vessels, either NVD $<$ standard photograph 10A or new vessels elsewhere (NVE) \geq one-quarter disc area

Adapted with permission from the Early Treatment Diabetic Retinopathy Study Research Group. Early Treatment Diabetic Retinopathy Study design and baseline patient characteristics: ETDRS report number 7. Ophthalmology 1991;98:742.

* Early Treatment Diabetic Retinopathy Study Research Group. Grading diabetic retinopathy from stereoscopic color fundus photographs--an extension of the modified Airlie House classification: ETDRS report number 10. Ophthalmology 1991;98:786-806.

TABLE A6-2 DIABETIC MACULAR EDEMA DISEASE DEFINITIONS IN THE EARLY TREATMENT OF DIABETIC RETINOPATHY STUDY

Disease Severity Level	Findings Observable upon Dilated Ophthalmoscopy
Diabetic macular edema apparently absent	No apparent retinal thickening or hard exudates in posterior pole
Diabetic macular edema apparently present	Thickening of retina within one disc diameter of the center of the macula; and/or hard exudates \geq standard photograph 3* in a standard 30° photographic field centered on the macula (field 2), with some hard exudates within one disc diameter of the center of the macula
Clinically significant macular edema	Retinal thickening at or within 500 μ m of the center of the macula; and/or hard exudates at or within 500 μ m of the center of the macula, if associated with thickening of the adjacent retina; and/or a zone or zones of retinal thickening one disc area in size at least part of which was within one disc diameter of the center

Adapted with permission from the Early Treatment Diabetic Retinopathy Study Research Group. Early Treatment Diabetic Retinopathy Study design and baseline patient characteristics: ETDRS report number 7. Ophthalmology 1991;98:742.

* Early Treatment Diabetic Retinopathy Study Research Group. Grading diabetic retinopathy from stereoscopic color fundus photographs--an extension of the modified Airlie House classification: ETDRS report number 10. Ophthalmology 1991;98:786-806.



GLOSSARY

Action to Control Cardiovascular Risk in Diabetes (ACCORD) trial: A large multicenter clinical trial that evaluated intensive control of blood sugar, intensive control of blood pressure, and statin therapy (with or without fibrate treatment) for the prevention of cardiovascular disease events among high-risk patients with Type 2 diabetes.

ACCORD: See Action to Control Cardiovascular Risk in Diabetes trial.

Anti-VEGF: See Anti-vascular endothelial growth factor.

Anti-vascular endothelial growth factor (VEGF): Substances that inhibit the action of vascular endothelial growth factor protein.

Bevacizumab or Laser Treatment (BOLT) study: A randomized trial that evaluated intravitreal bevacizumab or conventional laser treatment for center-involving diabetic macular edema.

BOLT: See Bevacizumab or Laser Treatment study.

Clinically significant macular edema (CSME): Retinal thickening at or within 500 μm of the center of the macula; and/or hard exudates at or within 500 μm of the center of the macula, if associated with thickening of the adjacent retina; and/or a zone or zones of retinal thickening one disc area in size, any part of which is within one disc diameter of the center of the macula.

CSME: See Clinically significant macular edema.

ci-CSME: Center-involving CSME.

DA VINCI: See DME and VEGF Trap-Eye: Investigation of Clinical Impact study.

DCCT: See Diabetes Control and Complications Trial.

Diabetes Control and Complications Trial (DCCT): A multicenter randomized controlled trial designed to study the connection between glycemic control and retinal, renal, and neurologic complications of Type 1 diabetes mellitus. (See Appendix 5.)

Diabetes mellitus: According to the American Diabetes Association Expert Committee on the Diagnosis and Classification of Diabetes Mellitus, the criteria for the diagnosis of diabetes mellitus are as follows.

- ◆ Fasting plasma glucose equal to or exceeding 126 mg/dL (7.0 mmol/L). Fasting is defined as no caloric intake for at least 8 hours.
- or
- ◆ Symptoms of hyperglycemia and a casual plasma glucose concentration equal to or exceeding 200 mg/dL (11.1 mmol/L). “Casual” is defined as any time of day without regard to time since last meal. The classic symptoms of hyperglycemia include polyuria, polydipsia, and unexplained weight loss.
- or
- ◆ A plasma glucose measurement at 2 hours postload equal to or exceeding 200 mg/dL (11.1 mmol/L) during an oral glucose tolerance test. The test should be performed as described by the World Health Organization, using a glucose load containing the equivalent of 75 g anhydrous glucose dissolved in water. However, the expert committee has recommended against oral glucose tolerance testing for routine clinical use. (Source: Report of the Expert Committee on the Diagnosis and Classification of Diabetes Mellitus. *Diabetes Care* 2008;31 (suppl):55-60.)

Diabetic Retinopathy Clinical Research Network (DRCR.net): A multicenter trial that is evaluating different treatment modalities for diabetic retinopathy.

Diabetic Retinopathy Study (DRS): A study designed to investigate the value of xenon arc and argon photocoagulation surgery for patients with severe NPDR and PDR. (See Appendix 4.)

**Diabetic Retinopathy PPP:
Glossary**

Diabetic Retinopathy Vitrectomy Study (DRVS): A study that investigated the role of vitrectomy in managing eyes with very severe PDR. (See Appendix 4.)

DME and VEGF Trap-Eye: Investigation of Clinical Impact (DA VINCI) study: A randomized trial of the use of aflibercept for diabetic macular edema.

DRCR.net: See Diabetic Retinopathy Clinical Research Network.

DRS: See Diabetic Retinopathy Study.

DRVS: See Diabetic Retinopathy Vitrectomy Study.

Early Treatment Diabetic Retinopathy Study (ETDRS): A study that investigated the value of photocoagulation surgery for patients with NPDR or PDR who did not have high-risk characteristics. (See Appendix 4.)

Early proliferative diabetic retinopathy (i.e., proliferative retinopathy without DRS high-risk characteristics): New vessels that do not meet the criteria of high-risk proliferative retinopathy.

EDIC: See Epidemiology of Diabetes Interventions and Complications study.

Epidemiology of Diabetes Interventions and Complications (EDIC) study: An observational study following 95% of the DCCT subjects. (See Appendix 5.)

ETDRS: See Early Treatment Diabetic Retinopathy Study.

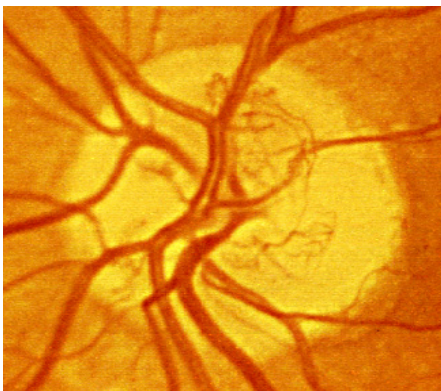
Fenofibrate Intervention and Event Lowering in Diabetes (FIELD) study: A large randomized controlled trial that evaluated long-term fenofibrate therapy for prevention of cardiovascular events in patients with Type 2 diabetes mellitus.

FIELD study: See Fenofibrate Intervention and Event Lowering in Diabetes study.

Focal photocoagulation: A laser technique directed to abnormal blood vessels with specific areas of focal leakage (i.e., microaneurysms) to reduce chronic fluid leakage in patients with macular edema.

Grid photocoagulation: A laser technique in which a grid pattern of scatter burns is applied in areas of diffuse macular edema and nonperfusion. Typically, fluorescein angiograms of these areas show a diffuse pattern rather than focal leakage.

High-risk proliferative diabetic retinopathy (PDR): New vessels on or within one disc diameter of the optic disc equaling or exceeding standard photograph 10A (about one-quarter to one-third disc area), with or without vitreous or preretinal hemorrhage; or vitreous and/or preretinal hemorrhage accompanied by new vessels either on the optic disc less than standard photograph 10A or new vessels elsewhere equaling or exceeding one-quarter disc area.



Standard photograph 10A defines the lower border of moderate NVD. NVD covers approximately one-third the area of the standard disc. This extent of NVD alone would constitute PDR with high-risk characteristics.

Reprinted with permission from the Early Treatment Diabetic Retinopathy Study Research Group. Grading diabetic retinopathy from stereoscopic color fundus photographs—an extension of the modified Airlie House classification: ETDRS report number 10. *Ophthalmology* 1991;98:786-806.

ICD-9: International Statistical Classification of Diseases and Related Health Problems, Ninth Edition.

ICD-10: International Statistical Classification of Diseases and Related Health Problems, Tenth Edition.

Intraretinal microvascular abnormalities (IRMA): Tortuous intraretinal vascular segments, varying in caliber from barely visible to 31 μ m in diameter (one-quarter the width of a major vein at the disc margin); they occasionally can be larger. IRMA may be difficult to distinguish from neovascularization.

IRMA: See Intraretinal microvascular abnormalities.

Macular edema: Thickening of the retina within one or two disc diameters of the center of the macula. (See Clinically significant macular edema.) Any other thickening of the macula not within this area is non-CSME.

Mild nonproliferative diabetic retinopathy (NPDR): At least one microaneurysm and less than moderate nonproliferative diabetic retinopathy.

Moderate nonproliferative diabetic retinopathy (NPDR): Hemorrhages and/or microaneurysms greater than standard photograph 2A, and/or soft exudates, venous beading, or intraretinal microvascular abnormalities present but less than severe nonproliferative retinopathy.

Moderate visual loss: The loss of 15 or more letters on the ETDRS visual acuity chart, or doubling of the visual angle (e.g., 20/20 to 20/40, or 20/50 to 20/100).

nci-CSME: Non-center-involving CSME.

New vessels at the optic disc (NVD): New vessels at the optic disc; neovascularization on or within one disc diameter of the optic disc.

New vessels elsewhere in the retina (NVE): New vessels elsewhere in the retina; neovascularization elsewhere in the retina and greater than one disc diameter from the optic disc margin.

New vessels on the iris (NVI): New vessels on the iris; neovascularization of the iris.

Nonproliferative diabetic retinopathy (NPDR): The phases of diabetic retinopathy with no evidence of retinal neovascularization.

NPDR: See Nonproliferative diabetic retinopathy.

NVD: See New vessels at the optic disc.

NVE: See New vessels elsewhere in the retina.

NVI: See New vessels on the iris.

OCT: See Optical coherence tomography.

Optical coherence tomography (OCT): A diagnostic test using low energy lasers that takes a cross-section image of the retina. Used mostly to determine if there are membranes on the surface of the macula or fluid within or beneath it.

Panretinal photocoagulation: A type of laser surgery used for patients with proliferative diabetic retinopathy. The surgery is delivered in a scatter pattern throughout the peripheral fundus and is intended to lead to a regression of neovascularization.

PDR: See Proliferative diabetic retinopathy.

Proliferative diabetic retinopathy (PDR): Advanced disease characterized by NVD and/or NVE.

**Diabetic Retinopathy PPP:
Glossary**

Quality adjusted life year (QALY): A measure of health outcome that assigns to each year of a patient's life a weight (ranging from 0 to 1) corresponding to the health-related quality of life during that year, such that a value of 1 indicates a year of optimal health and a value of 0 indicates a year in a health state judged equivalent to death.

QALY: See Quality adjusted life year.

Ranibizumab for Edema of the mAcula in Diabetes (READ-2) study: A prospective multicenter randomized controlled trial that compared 0.5 mg ranibizumab and laser photocoagulation for the treatment of diabetic macular edema.

READ-2: See Ranibizumab for Edema of the mAcula in Diabetes study.

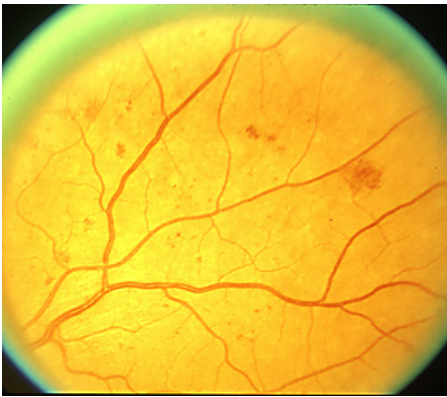Retinal hard exudate: Protein and lipid accumulation within the retina.

RIDE: A study of ranibizumab injection in subjects with clinically significant macular edema with center-involvement secondary to diabetes mellitus.

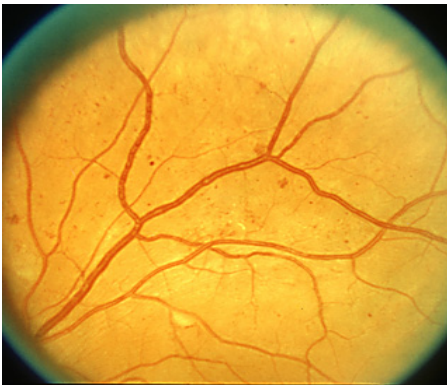RISE: A study of ranibizumab injection in subjects with clinically significant macular edema with center-involvement secondary to diabetes mellitus.

Scatter photocoagulation: See Panretinal photocoagulation.

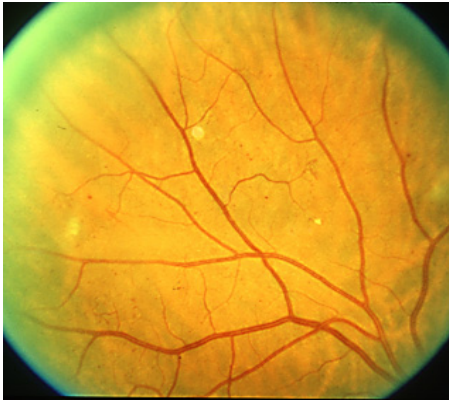Severe nonproliferative diabetic retinopathy (NPDR): Using the 4-2-1 rule, the presence of at least one of the following features: (1) severe intraretinal hemorrhages and microaneurysms, equaling or exceeding standard photograph 2A, present in four quadrants; (2) venous beading in two or more quadrants (standard photograph 6A); or (3) moderate intraretinal microvascular abnormalities equaling or exceeding standard photograph 8A in one or more quadrants.



Standard photograph 2A, the standard for hemorrhages/microaneurysms. Eyes with severe NPDR have this degree of severity of hemorrhages and microaneurysms in all four midperipheral quadrants.



Standard photograph 6A, less severe of two standards for venous beading. Two main branches of the superior temporal vein show beading that is definite but not severe.



Standard photograph 8A, the standard for moderate IRMA. Patients with severe NPDR have moderate IRMA of at least this severity in at least one quadrant.

Reprinted with permission from the Early Treatment Diabetic Retinopathy Study Research Group. Grading diabetic retinopathy from stereoscopic color fundus photographs--an extension of the modified Airlie House classification: ETDRS report number 10. *Ophthalmology* 1991;98:786-806.

Severe visual loss: Occurrence of visual acuity worse than 5/200 at any two consecutive visits scheduled at 4-month intervals.

UKPDS: See United Kingdom Prospective Diabetes Study.

United Kingdom Prospective Diabetes Study (UKPDS): A randomized controlled clinical trial of blood glucose control in patients with newly diagnosed Type 2 diabetes. (See Appendix 5.)

VTDR: Vision-threatening diabetic retinopathy.

WESDR: See Wisconsin Epidemiologic Study of Diabetic Retinopathy

Wisconsin Epidemiologic Study of Diabetic Retinopathy: A large epidemiologic study of complications associated with diabetes and of risk factors associated with those complications.



RELATED ACADEMY MATERIALS

Basic and Clinical Science Course

Retina and Vitreous (Section 12, 2014–2015)

Clinical Statements –

Free download available at <http://one.aao.org/guidelines-browse?filter=clinicalstatement>.

International Clinical Classification System for Diabetic Retinopathy and Diabetic Macular Edema (2012)

Screening for Diabetic Retinopathy (2014)

Verifying the Source of Compounded Bevacizumab for Intravitreal Injections (2012)

Focal Points

Retinal Optical Coherence Tomography (2014)

Update on the Management of Diabetic Retinopathy (2011)

Ophthalmic Technology Assessment –

Published in *Ophthalmology*, which is distributed free to Academy members; links to full text available at www.aao.org/ota.

Anti-VEGF Pharmacotherapy for Diabetic Macular Edema (2012)

Laser Scanning Imaging for Macular Disease (2007; reviewed for currency 2012)

Single Field Fundus Photography for Diabetic Retinopathy Screening (2004; reviewed for currency 2010)

Patient Education

Diabetic Retinopathy Brochure (2014)

Diabetic Retinopathy Brochure (Spanish: Retinopatía Diabética) (2014)

EyeSmart® What is Diabetic Retinopathy? Available at:

www.geteyesmart.org/eyesmart/diseases/diabetic-retinopathy/index.cfm

EyeSmart® What is Diabetic Retinopathy? (Spanish: ojosSanos™ ¿Qué Es la Retinopatía Diabética?)

Disponible en www.geteyesmart.org/eyesmart/diseases-es/retinopatia-diabetica/index.cfm

Retina Informed Consent Video Collection (2013)

Preferred Practice Pattern® Guidelines – Free download available at www.aao.org/ppp.

Comprehensive Adult Medical Eye Evaluation (2010)

To order any of these products, except for the free materials, please contact the Academy's Customer Service at 866.561.8558 (U.S. only) or 415.561.8540 or www.aao.org/store.



REFERENCES

1. Scottish Intercollegiate Guidelines Network. Annex B: key to evidence statements and grades of recommendations. In: SIGN 50: A Guideline Developer's Handbook. Available at: www.sign.ac.uk/guidelines/fulltext/50/annexb.html. Accessed June 11, 2014
2. Guyatt GH, Oxman AD, Vist GE, et al. GRADE: an emerging consensus on rating quality of evidence and strength of recommendations. *BMJ* 2008;336:924-6.
3. GRADE Working Group. Organizations that have endorsed or that are using GRADE. Available at: www.gradeworkinggroup.org/society/index.htm. Accessed June 11, 2014.
4. Kawasaki R, Tanaka S, Abe S, et al. Japan Diabetes Complications Study Group. Risk of cardiovascular diseases is increased even with mild diabetic retinopathy: the Japan Diabetes Complications Study. *Ophthalmology* 2013;120:574-82.
5. American Diabetes Association. Diagnosis and classification of diabetes mellitus. *Diabetes Care* 2010;33 Suppl 1:S62-9.
6. Klein R, Klein BE, Moss SE. Visual impairment in diabetes. *Ophthalmology* 1984;91:1-9.
7. Eppens MC, Craig ME, Cusumano J, et al. Prevalence of diabetes complications in adolescents with type 2 compared with type 1 diabetes. *Diabetes Care* 2006;29:1300-6.
8. Centers for Disease Control and Prevention. National diabetes fact sheet: national estimates and general information on diabetes and prediabetes in the United States, 2011. Atlanta, GA: U.S. Department of Health and Human Services, Centers for Disease Control and Prevention; 2011. Available at: www.cdc.gov/diabetes/pubs/pdf/ndfs_2011.pdf. Accessed June 11, 2014.
9. Cowie CC, Rust KF, Byrd-Holt DD, et al. Prevalence of diabetes and impaired fasting glucose in adults in the U.S. population: National Health And Nutrition Examination Survey 1999-2002. *Diabetes Care* 2006;29:1263-8.
10. American Association of Clinical Endocrinologists. State of diabetes complications in America: a comprehensive report issued by the American Association of Clinical Endocrinologists. 2007;2, 4. Available at: http://multivu.prnewswire.com/mnr/AACE/2007/docs/Diabetes_Complications_Report.pdf. Accessed June 11, 2014.
11. Acton KJ, Burrows NR, Moore K, et al. Trends in diabetes prevalence among American Indian and Alaska native children, adolescents, and young adults. *Am J Public Health* 2002;92:1485-90.
12. Prevalence of diagnosed diabetes among American Indians/Alaskan Natives--United States, 1996. *MMWR Morb Mortal Wkly Rep* 1998;47:901-4.
13. Liu L, Wu X, Geng J, et al. Prevalence of diabetic retinopathy in mainland China: a meta-analysis. *PLoS One* 2012;7:e45264.
14. Namperumalsamy P, Kim R, Vignesh TP, et al. Prevalence and risk factors for diabetic retinopathy: a population-based assessment from Theni District, south India. *Br J Ophthalmol* 2009;93:429-34.
15. Harris MI, Flegal KM, Cowie CC, et al. Prevalence of diabetes, impaired fasting glucose, and impaired glucose tolerance in U.S. adults. The Third National Health and Nutrition Examination Survey, 1988-1994. *Diabetes Care* 1998;21:518-24.
16. Harris MI, Klein R, Cowie CC, et al. Is the risk of diabetic retinopathy greater in non-Hispanic blacks and Mexican Americans than in non-Hispanic whites with type 2 diabetes? A U.S. population study. *Diabetes Care* 1998;21:1230-5.
17. Geiss LS, Cowie CC. Type 2 diabetes and persons at high risk of diabetes. In: Narayan KM, Williams D, Gregg EW, Cowie CC, eds. *Diabetes Public Health: From Data to Policy*. New York: Oxford University Press, Inc.; 2011:15-32.
18. Narayan KM, Boyle JP, Thompson TJ, et al. Lifetime risk for diabetes mellitus in the United States. *JAMA* 2003;290:1884-90.
19. Danaei G, Finucane MM, Lu Y, et al. National, regional, and global trends in fasting plasma glucose and diabetes prevalence since 1980: systematic analysis of health examination surveys and epidemiological studies with 370 country-years and 2.7 million participants. *Lancet* 2011;378:31-40.
20. Pinhas-Hamiel O, Zeitler P. The global spread of type 2 diabetes mellitus in children and adolescents. *J Pediatr* 2005;146:693-700.

**Diabetic Retinopathy PPP:
References**

21. Urakami T, Kubota S, Nitadori Y, et al. Annual incidence and clinical characteristics of type 2 diabetes in children as detected by urine glucose screening in the Tokyo metropolitan area. *Diabetes Care* 2005;28:1876-81.
22. Wei JN, Sung FC, Lin CC, et al. National surveillance for type 2 diabetes mellitus in Taiwanese children. *JAMA* 2003;290:1345-50.
23. Fagot-Campagna A, Pettitt DJ, Engelgau MM, et al. Type 2 diabetes among North American children and adolescents: an epidemiologic review and a public health perspective. *J Pediatr* 2000;136:664-72.
24. McMahon SK, Haynes A, Ratnam N, et al. Increase in type 2 diabetes in children and adolescents in Western Australia. *Med J Aust* 2004;180:459-61.
25. Kaufman FR. Type 2 diabetes mellitus in children and youth: a new epidemic. *J Pediatr Endocrinol Metab* 2002;15 Suppl 2:737-44.
26. Klein BE. Overview of epidemiologic studies of diabetic retinopathy. *Ophthalmic Epidemiol* 2007;14:179-83.
27. Kempen JH, O'Colmain BJ, Leske MC, et al. The prevalence of diabetic retinopathy among adults in the United States. *Arch Ophthalmol* 2004;122:552-63.
28. Zhang X, Saaddine JB, Chou CF, et al. Prevalence of diabetic retinopathy in the United States, 2005-2008. *JAMA* 2010;304:649-56.
29. Klein R, Klein BE, Moss SE, et al. The Wisconsin Epidemiologic Study of Diabetic Retinopathy. II. Prevalence and risk of diabetic retinopathy when age at diagnosis is less than 30 years. *Arch Ophthalmol* 1984;102:520-6.
30. Varma R, Torres M, Pena F, et al. Prevalence of diabetic retinopathy in adult Latinos: the Los Angeles Latino eye study. *Ophthalmology* 2004;111:1298-306.
31. Hirai FE, Knudtson MD, Klein BE, Klein R. Clinically significant macular edema and survival in type 1 and type 2 diabetes. *Am J Ophthalmol* 2008;145:700-6.
32. West SK, Klein R, Rodriguez J, et al. Diabetes and diabetic retinopathy in a Mexican-American population: Proyecto VER. *Diabetes Care* 2001;24:1204-9.
33. Klein R, Klein BE, Moss SE, et al. The Wisconsin Epidemiologic Study of Diabetic Retinopathy. III. Prevalence and risk of diabetic retinopathy when age at diagnosis is 30 or more years. *Arch Ophthalmol* 1984;102:527-32.
34. Diabetes Control and Complications Trial Research Group. Progression of retinopathy with intensive versus conventional treatment in the Diabetes Control and Complications Trial. *Ophthalmology* 1995;102:647-61.
35. Diabetes Control and Complications Trial/Epidemiology of Diabetes Interventions and Complications Research Group. Retinopathy and nephropathy in patients with type 1 diabetes four years after a trial of intensive therapy. *N Engl J Med* 2000;342:381-9.
36. Diabetes Control and Complications Trial Research Group. The relationship of glycemic exposure (HbA1c) to the risk of development and progression of retinopathy in the Diabetes Control and Complications Trial. *Diabetes* 1995;44:968-83.
37. Writing Team for the Diabetes Control and Complications Trial/Epidemiology of Diabetes Interventions and Complications Research Group. Effect of intensive therapy on the microvascular complications of type 1 diabetes mellitus. *JAMA* 2002;287:2563-9.
38. UK Prospective Diabetes Study (UKPDS) Group. Intensive blood-glucose control with sulphonylureas or insulin compared with conventional treatment and risk of complications in patients with type 2 diabetes (UKPDS 33). *Lancet* 1998;352:837-53.
39. Kohner EM, Stratton IM, Aldington SJ, et al. Relationship between the severity of retinopathy and progression to photocoagulation in patients with Type 2 diabetes mellitus in the UKPDS (UKPDS 52). *Diabet Med* 2001;18:178-84.
40. Wong TY, Liew G, Tapp RJ, et al. Relation between fasting glucose and retinopathy for diagnosis of diabetes: three population-based cross-sectional studies. *Lancet* 2008;371:736-43.
41. White NH, Sun W, Cleary PA, et al. Prolonged effect of intensive therapy on the risk of retinopathy complications in patients with type 1 diabetes mellitus: 10 years after the Diabetes Control and Complications Trial. *Arch Ophthalmol* 2008;126:1707-15.

42. Davis MD, Fisher MR, Gangnon RE, et al. Risk factors for high-risk proliferative diabetic retinopathy and severe visual loss: Early Treatment Diabetic Retinopathy Study report number 18. *Invest Ophthalmol Vis Sci* 1998;39:233-52.
43. Kilpatrick ES, Rigby AS, Atkin SL, Frier BM. Does severe hypoglycaemia influence microvascular complications in Type 1 diabetes? An analysis of the Diabetes Control and Complications Trial database. *Diabet Med* 2012;29:1195-8.
44. American Diabetes Association. Standards of medical care in diabetes--2013. *Diabetes Care* 2013;36 Suppl 1:S11-66.
45. UK Prospective Diabetes Study Group. Tight blood pressure control and risk of macrovascular and microvascular complications in type 2 diabetes: UKPDS 38. *BMJ* 1998;317:703-13.
46. Snow V, Weiss KB, Mottur-Pilson C. The evidence base for tight blood pressure control in the management of type 2 diabetes mellitus. *Ann Intern Med* 2003;138:587-92.
47. van Leiden HA, Dekker JM, Moll AC, et al. Blood pressure, lipids, and obesity are associated with retinopathy: The Hoorn Study. *Diabetes Care* 2002;25:1320-5.
48. Klein R, Sharrett AR, Klein BE, et al. The association of atherosclerosis, vascular risk factors, and retinopathy in adults with diabetes: the atherosclerosis risk in communities study. *Ophthalmology* 2002;109:1225-34.
49. Lyons TJ, Jenkins AJ, Zheng D, et al. Diabetic retinopathy and serum lipoprotein subclasses in the DCCT/EDIC cohort. *Invest Ophthalmol Vis Sci* 2004;45:910-8.
50. Lopes-Virella MF, Baker NL, Hunt KJ, et al. High concentrations of AGE-LDL and oxidized LDL in circulating immune complexes are associated with progression of retinopathy in type 1 diabetes. *Diabetes Care* 2012;35:1333-40.
51. Klein R, Klein BE, Moss SE, et al. The Wisconsin Epidemiologic Study of Diabetic Retinopathy. IX. Four-year incidence and progression of diabetic retinopathy when age at diagnosis is less than 30 years. *Arch Ophthalmol* 1989;107:237-43.
52. Klein R, Klein BE, Moss SE, et al. The Wisconsin Epidemiologic Study of Diabetic Retinopathy. X. Four-year incidence and progression of diabetic retinopathy when age at diagnosis is 30 years or more. *Arch Ophthalmol* 1989;107:244-9.
53. Kriska AM, LaPorte RE, Patrick SL, et al. The association of physical activity and diabetic complications in individuals with insulin-dependent diabetes mellitus: the Epidemiology of Diabetes Complications Study--VII. *J Clin Epidemiol* 1991;44:1207-14.
54. Muni RH, Kohly RP, Lee EQ, et al. Prospective study of inflammatory biomarkers and risk of diabetic retinopathy in the diabetes control and complications trial. *JAMA Ophthalmol* 2013;131:514-21.
55. American Diabetes Association. Standards of medical care in diabetes--2008. *Diabetes Care* 2008;31 Suppl 1:S12-54.
56. Ferris FL III. How effective are treatments for diabetic retinopathy? *JAMA* 1993;269:1290-1.
57. Diabetes Control and Complications Trial Research Group. The effect of intensive treatment of diabetes on the development and progression of long-term complications in insulin-dependent diabetes mellitus. *N Engl J Med* 1993;329:977-86.
58. Diabetes Control and Complications Trial Research Group. The effect of intensive diabetes treatment on the progression of diabetic retinopathy in insulin-dependent diabetes mellitus: the Diabetes Control and Complications Trial. *Arch Ophthalmol* 1995;113:36-51.
59. Epidemiology of Diabetes Interventions and Complications (EDIC) Research Group. Epidemiology of Diabetes Interventions and Complications (EDIC): design, implementation, and preliminary results of a long-term follow-up of the Diabetes Control and Complications Trial cohort. *Diabetes Care* 1999;22:99-111.
60. Diabetes Control and Complications Trial/Epidemiology of Diabetes Interventions and Complications (DCCT/EDIC) Research Group. Modern-day clinical course of type 1 diabetes mellitus after 30 years' duration: the diabetes control and complications trial/epidemiology of diabetes interventions and complications and Pittsburgh Epidemiology of Diabetes complications experience (1983-2005). *Arch Intern Med* 2009;169:1307-16.
61. Diabetic Retinopathy Study Research Group. Indications for photocoagulation treatment of diabetic retinopathy: Diabetic Retinopathy Study report number 14. *Int Ophthalmol Clin* 1987;27:239-53.

**Diabetic Retinopathy PPP:
References**

62. Diabetic Retinopathy Study Research Group. Photocoagulation treatment of proliferative diabetic retinopathy: the second report of Diabetic Retinopathy Study findings. *Ophthalmology* 1978;85:82-106.
63. Early Treatment Diabetic Retinopathy Study Research Group. Grading diabetic retinopathy from stereoscopic color fundus photographs--an extension of the modified Airlie House classification: ETDRS report number 10. *Ophthalmology* 1991;98:786-806.
64. Early Treatment Diabetic Retinopathy Study Research Group. Fundus photographic risk factors for progression of diabetic retinopathy: ETDRS report number 12. *Ophthalmology* 1991;98:823-33.
65. Early Treatment Diabetic Retinopathy Study Research Group. Photocoagulation for diabetic macular edema: Early Treatment Diabetic Retinopathy Study report number 1. *Arch Ophthalmol* 1985;103:1796-806.
66. Diabetic Retinopathy Vitrectomy Study Research Group. Early vitrectomy for severe vitreous hemorrhage in diabetic retinopathy: four-year results of a randomized trial--Diabetic Retinopathy Vitrectomy Study report 5. *Arch Ophthalmol* 1990;108:958-64.
67. Klein R, Klein BE, Moss SE, Cruickshanks KJ. The Wisconsin Epidemiologic Study of diabetic retinopathy. XIV. Ten-year incidence and progression of diabetic retinopathy. *Arch Ophthalmol* 1994;112:1217-28.
68. Scott R, Best J, Forder P, et al, FIELD Study Investigators. Fenofibrate Intervention and Event Lowering in Diabetes (FIELD) study: baseline characteristics and short-term effects of fenofibrate [ISRCTN64783481]. *Cardiovasc Diabetol* 2005;4:13.
69. Goff DC Jr, Gerstein HC, Ginsberg HN, et al, ACCORD Study Group. Prevention of cardiovascular disease in persons with type 2 diabetes mellitus: current knowledge and rationale for the Action to Control Cardiovascular Risk in Diabetes (ACCORD) trial. *Am J Cardiol* 2007;99:4i-20i.
70. Elman MJ, Qin H, Aiello LP, et al, Diabetic Retinopathy Clinical Research Network. Intravitreal ranibizumab for diabetic macular edema with prompt versus deferred laser treatment: three-year randomized trial results. *Ophthalmology* 2012;119:2312-8.
71. UK Prospective Diabetes Study (UKPDS) Group. Effect of intensive blood-glucose control with metformin on complications in overweight patients with type 2 diabetes (UKPDS 34). *Lancet* 1998;352:854-65.
72. Wilkinson CP, Ferris FL III, Klein RE, et al. Proposed international clinical diabetic retinopathy and diabetic macular edema disease severity scales. *Ophthalmology* 2003;110:1677-82.
73. Williams GA, Scott IU, Haller JA, et al. Single-field fundus photography for diabetic retinopathy screening: a report by the American Academy of Ophthalmology. *Ophthalmology* 2004;111:1055-62.
74. Lin DY, Blumenkranz MS, Brothers RJ, Grosvenor DM. The sensitivity and specificity of single-field nonmydriatic monochromatic digital fundus photography with remote image interpretation for diabetic retinopathy screening: a comparison with ophthalmoscopy and standardized mydriatic color photography. *Am J Ophthalmol* 2002;134:204-13.
75. Larsen N, Godt J, Grunkin M, et al. Automated detection of diabetic retinopathy in a fundus photographic screening population. *Invest Ophthalmol Vis Sci* 2003;44:767-71.
76. Leese GP, Ellis JD, Morris AD, Ellingford A. Does direct ophthalmoscopy improve retinal screening for diabetic eye disease by retinal photography? *Diabet Med* 2002;19:867-9.
77. Ahmed J, Ward TP, Bursell SE, et al. The sensitivity and specificity of nonmydriatic digital stereoscopic retinal imaging in detecting diabetic retinopathy. *Diabetes Care* 2006;29:2205-9.
78. Velez R, Haffner S, Stern MP, Vanheuve WJ. Ophthalmologist vs retinal photographs in screening for diabetic retinopathy. *Clinical Research* 1987;35:A363.
79. Pugh JA, Jacobson JM, Van Heuven WA, et al. Screening for diabetic retinopathy. The wide-angle retinal camera. *Diabetes Care* 1993;16:889-95.
80. Lawrence MG. The accuracy of digital-video retinal imaging to screen for diabetic retinopathy: an analysis of two digital-video retinal imaging systems using standard stereoscopic seven-field photography and dilated clinical examination as reference standards. *Trans Am Ophthalmol Soc* 2004;102:321-40.
81. Abramoff MD, Folk JC, Han DP, et al. Automated analysis of retinal images for detection of referable diabetic retinopathy. *JAMA Ophthalmol* 2013;131:351-7.

82. Rudnisky CJ, Hinz BJ, Tennant MT, et al. High-resolution stereoscopic digital fundus photography versus contact lens biomicroscopy for the detection of clinically significant macular edema. *Ophthalmology* 2002;109:267-74.
83. Cavallerano JD, Aiello LP, Cavallerano AA, et al. Nonmydriatic digital imaging alternative for annual retinal examination in persons with previously documented no or mild diabetic retinopathy. *Am J Ophthalmol* 2005;140:667-73.
84. Fonda SJ, Bursell SE, Lewis DG, et al. The relationship of a diabetes telehealth eye care program to standard eye care and change in diabetes health outcomes. *Telemed J E Health* 2007;13:635-44.
85. Conlin PR, Fisch BM, Cavallerano AA, et al. Nonmydriatic teleretinal imaging improves adherence to annual eye examinations in patients with diabetes. *J Rehabil Res Dev* 2006;43:733-40.
86. Diamond JP, McKinnon M, Barry C, et al. Non-mydriatic fundus photography: a viable alternative to fundoscopy for identification of diabetic retinopathy in an Aboriginal population in rural Western Australia? *Aust N Z J Ophthalmol* 1998;26:109-15.
87. Klein R, Klein BE. Screening for diabetic retinopathy, revisited. *Am J Ophthalmol* 2002;134:261-3.
88. Maberley D, Walker H, Koushik A, Cruess A. Screening for diabetic retinopathy in James Bay, Ontario: a cost-effectiveness analysis. *CMAJ* 2003;168:160-4.
89. Farley TF, Mandava N, Prall FR, Carsky C. Accuracy of primary care clinicians in screening for diabetic retinopathy using single-image retinal photography. *Ann Fam Med* 2008;6:428-34.
90. Li HK, Horton M, Bursell SE, et al. Telehealth practice recommendations for diabetic retinopathy, second edition. *Telemed J E Health* 2011;17:814-37.
91. Lueder GT, Silverstein J, American Academy of Pediatrics Section on Ophthalmology and Section on Endocrinology. Screening for retinopathy in the pediatric patient with type 1 diabetes mellitus. *Pediatrics* 2005;116:270-3. Reaffirmed 2014.
92. Diabetes Prevention Program Research Group. The prevalence of retinopathy in impaired glucose tolerance and recent-onset diabetes in the Diabetes Prevention Program. *Diabet Med* 2007;24:137-44.
93. Klein BE, Moss SE, Klein R. Effect of pregnancy on progression of diabetic retinopathy. *Diabetes Care* 1990;13:34-40.
94. Chew EY, Mills JL, Metzger BE, et al. Metabolic control and progression of retinopathy. The Diabetes in Early Pregnancy Study. National Institute of Child Health and Human Development Diabetes in Early Pregnancy Study. *Diabetes Care* 1995;18:631-7.
95. Diabetes Control and Complications Trial Research Group. Effect of pregnancy on microvascular complications in the diabetes control and complications trial. *Diabetes Care* 2000;23:1084-91.
96. UK Prospective Diabetes Study (UKPDS). VIII. Study design, progress and performance. *Diabetologia* 1991;34:877-90.
97. Early Treatment Diabetic Retinopathy Study Research Group. Effects of aspirin treatment on diabetic retinopathy: ETDRS report number 8. *Ophthalmology* 1991;98:757-65.
98. Chew EY, Klein ML, Murphy RP, et al. Effects of aspirin on vitreous/preretinal hemorrhage in patients with diabetes mellitus: Early Treatment Diabetic Retinopathy Study report number 20. *Arch Ophthalmol* 1995;113:52-5.
99. American Academy of Ophthalmology Preferred Practice Patterns Committee. Preferred Practice Pattern[®] Guidelines. Comprehensive Adult Medical Eye Evaluation. San Francisco, CA: American Academy of Ophthalmology; 2010. Available at: www.aao.org/ppp.
100. Klein R, Klein BE, Moss SE, et al. Glycosylated hemoglobin predicts the incidence and progression of diabetic retinopathy. *JAMA* 1988;260:2864-71.
101. Chew EY, Klein ML, Ferris FL III, et al. Association of elevated serum lipid levels with retinal hard exudate in diabetic retinopathy: Early Treatment Diabetic Retinopathy Study (ETDRS) report 22. *Arch Ophthalmol* 1996;114:1079-84.
102. Early Treatment Diabetic Retinopathy Study Research Group. Early photocoagulation for diabetic retinopathy: ETDRS report number 9. *Ophthalmology* 1991;98:766-85.
103. Klein R, Klein BE, Neider MW, et al. Diabetic retinopathy as detected using ophthalmoscopy, a nonmydriatic camera and a standard fundus camera. *Ophthalmology* 1985;92:485-91.
104. Klein R, Klein BE, Moss SE, et al. Retinopathy in young-onset diabetic patients. *Diabetes Care* 1985;8:311-5.

Diabetic Retinopathy PPP: References

105. Frank RN, Hoffman WH, Podgor MJ, et al. Retinopathy in juvenile-onset diabetes of short duration. *Ophthalmology* 1980;87:1-9.
106. Krolewski AS, Warram JH, Rand LI, et al. Risk of proliferative diabetic retinopathy in juvenile-onset type I diabetes: a 40-yr follow-up study. *Diabetes Care* 1986;9:443-52.
107. Klein R, Klein BE, Moss SE. Epidemiology of proliferative diabetic retinopathy. *Diabetes Care* 1992;15:1875-91.
108. Gunderson EP, Lewis CE, Tsai AL, et al. A 20-year prospective study of childbearing and incidence of diabetes in young women, controlling for glycemia before conception: the Coronary Artery Risk Development in Young Adults (CARDIA) Study. *Diabetes* 2007;56:2990-6.
109. Kaiser PK, Riemann CD, Sears JE, Lewis H. Macular traction detachment and diabetic macular edema associated with posterior hyaloidal traction. *Am J Ophthalmol* 2001;131:44-9.
110. Martidis A, Duker JS, Greenberg PB, et al. Intravitreal triamcinolone for refractory diabetic macular edema. *Ophthalmology* 2002;109:920-7.
111. Strom C, Sander B, Larsen N, et al. Diabetic macular edema assessed with optical coherence tomography and stereo fundus photography. *Invest Ophthalmol Vis Sci* 2002;43:241-5.
112. McDonald HR, Williams GA, Scott IU, et al. Laser scanning imaging for macular disease: a report by the American Academy of Ophthalmology. *Ophthalmology* 2007;114:1221-8.
113. Virgili G, Menchini F, Dimastrogiovanni AF, et al. Optical coherence tomography versus stereoscopic fundus photography or biomicroscopy for diagnosing diabetic macular edema: a systematic review. *Invest Ophthalmol Vis Sci* 2007;48:4963-73.
114. Bressler NM, Edwards AR, Antoszyk AN, et al. Retinal thickness on Stratus optical coherence tomography in people with diabetes and minimal or no diabetic retinopathy. *Am J Ophthalmol* 2008;145:894-901.
115. Davis MD, Bressler SB, Aiello LP, et al. Comparison of time-domain OCT and fundus photographic assessments of retinal thickening in eyes with diabetic macular edema. *Invest Ophthalmol Vis Sci* 2008;49:1745-52.
116. Do DV, Nguyen QD, Khwaja AA, et al. READ-2 Study Group. Ranibizumab for edema of the macula in diabetes study: 3-year outcomes and the need for prolonged frequent treatment. *JAMA Ophthalmol* 2013;131:139-45.
117. Brown DM, Nguyen QD, Marcus DM, et al, RIDE and RISE Research Group. Long-term outcomes of ranibizumab therapy for diabetic macular edema: the 36-month results from two phase III trials: RISE and RIDE. *Ophthalmology* 2013;120:2013-22.
118. Browning DJ, Glassman AR, Aiello LP, et al. Relationship between optical coherence tomography-measured central retinal thickness and visual acuity in diabetic macular edema. *Ophthalmology* 2007;114:525-36.
119. Browning DJ, Apte RS, Bressler SB, et al. Association of the extent of diabetic macular edema as assessed by optical coherence tomography with visual acuity and retinal outcome variables. *Retina* 2009;29:300-5.
120. Early Treatment Diabetic Retinopathy Study Research Group. Focal photocoagulation treatment of diabetic macular edema. Relationship of treatment effect to fluorescein angiographic and other retinal characteristics at baseline: ETDRS report number 19. *Arch Ophthalmol* 1995;113:1144-55.
121. Yannuzzi LA, Rohrer KT, Tindel LJ, et al. Fluorescein angiography complication survey. *Ophthalmology* 1986;93:611-7.
122. Sunness JS. The pregnant woman's eye. *Surv Ophthalmol* 1988;32:219-38.
123. Tuomilehto J, Lindstrom J, Eriksson JG, et al. Prevention of type 2 diabetes mellitus by changes in lifestyle among subjects with impaired glucose tolerance. *N Engl J Med* 2001;344:1343-50.
124. Knowler WC, Barrett-Connor E, Fowler SE, et al. Reduction in the incidence of type 2 diabetes with lifestyle intervention or metformin. *N Engl J Med* 2002;346:393-403.
125. National Committee for Quality Assurance. Improving quality and patient experience: the state of health care quality 2013. 2013:53. Available at: www.ncqa.org/Portals/0/Newsroom/SOHC/2013/SOHC-web_version_report.pdf. Accessed June 11, 2014.
126. Kraft SK, Marrero DG, Lazaridis EN, et al. Primary care physicians' practice patterns and diabetic retinopathy: current levels of care. *Arch Fam Med* 1997;6:29-37.

127. Paz SH, Varma R, Klein R, et al, Los Angeles Latino Eye Study Group. Noncompliance with vision care guidelines in Latinos with type 2 diabetes mellitus: the Los Angeles Latino Eye Study. *Ophthalmology* 2006;113:1372-7.
128. Glassman AR, Beck RW, Browning DJ, et al. Comparison of optical coherence tomography in diabetic macular edema, with and without reading center manual grading from a clinical trials perspective. *Invest Ophthalmol Vis Sci* 2009;50:560-6.
129. Writing Committee for the Diabetic Retinopathy Clinical Research Network. Panretinal photocoagulation vs intravitreal ranibizumab for proliferative diabetic retinopathy: a randomized clinical trial. *JAMA* 2015;314:2137-46.
130. Olsen TW. Anti-VEGF pharmacotherapy as an alternative to panretinal laser photocoagulation for proliferative diabetic retinopathy. *JAMA* 2015;314:2135-6.
131. Elman MJ, Bressler NM, Qin H, et al. Diabetic Retinopathy Clinical Research Network. Expanded 2-year follow-up of ranibizumab plus prompt or deferred laser or triamcinolone plus prompt laser for diabetic macular edema. *Ophthalmology* 2011;118:609-14.
132. Early Treatment Diabetic Retinopathy Study Research Group. Photocoagulation for diabetic macular edema: Early Treatment Diabetic Retinopathy Study report number 4. *Int Ophthalmol Clin* 1987;27:265-72.
133. Schatz H, Madeira D, McDonald HR, Johnson RN. Progressive enlargement of laser scars following grid laser photocoagulation for diffuse diabetic macular edema. *Arch Ophthalmol* 1991;109:1549-51.
134. Braun CI, Benson WE, Remaley NA, et al. Accommodative amplitudes in the Early Treatment Diabetic Retinopathy Study. *Retina* 1995;15:275-81.
135. Novak MA, Rice TA, Michels RG, Auer C. Vitreous hemorrhage after vitrectomy for diabetic retinopathy. *Ophthalmology* 1984;91:1485-9.
136. Gupta B, Sivaprasad S, Wong R, et al. Visual and anatomical outcomes following vitrectomy for complications of diabetic retinopathy: the DRIVE UK study. *Eye (Lond)* 2012;26:510-6.
137. Schachat AP, Oyakawa RT, Michels RG, Rice TA. Complications of vitreous surgery for diabetic retinopathy. II. Postoperative complications. *Ophthalmology* 1983;90:522-30.
138. Aaberg TM, Van Horn DL. Late complications of pars plana vitreous surgery. *Ophthalmology* 1978;85:126-40.
139. Chu KM, Chen TT, Lee PY. Clinical results of pars plana vitrectomy in posterior-segment disorders. *Ann Ophthalmol* 1985;17:686-93.
140. Chew EY, Benson WE, Remaley NA, et al. Results after lens extraction in patients with diabetic retinopathy: Early Treatment Diabetic Retinopathy Study report number 25. *Arch Ophthalmol* 1999;117:1600-6.
141. Gillies MC, Sutter FK, Simpson JM, et al. Intravitreal triamcinolone for refractory diabetic macular edema: two-year results of a double-masked, placebo-controlled, randomized clinical trial. *Ophthalmology* 2006;113:1533-8.
142. Chieh JJ, Roth DB, Liu M, et al. Intravitreal triamcinolone acetate for diabetic macular edema. *Retina* 2005;25:828-34.
143. Diabetic Retinopathy Clinical Research Network, Googe J, Brucker AJ, Bressler NM, et al. Randomized trial evaluating short-term effects of intravitreal ranibizumab or triamcinolone acetate on macular edema after focal/grid laser for diabetic macular edema in eyes also receiving panretinal photocoagulation. *Retina* 2011;31:1009-27.
144. Diabetic Retinopathy Clinical Research Network, Elman MJ, Aiello LP, Beck RW, et al. Randomized trial evaluating ranibizumab plus prompt or deferred laser or triamcinolone plus prompt laser for diabetic macular edema. *Ophthalmology* 2010;117:1064-77.
145. Ho AC, Scott IU, Kim SJ, et al. Anti-vascular endothelial growth factor pharmacotherapy for diabetic macular edema: a report by the American Academy of Ophthalmology. *Ophthalmology* 2012;119:2179-88.
146. Mitchell P, Bandello F, Schmidt-Erfurth U, et al. RESTORE Study Group. The RESTORE study: ranibizumab monotherapy or combined with laser versus laser monotherapy for diabetic macular edema. *Ophthalmology* 2011;118:615-25.
147. Nguyen QD, Brown DM, Marcus DM, et al. Ranibizumab for diabetic macular edema: results from 2 phase III randomized trials: RISE and RIDE. *Ophthalmology* 2012;119:789-801.

**Diabetic Retinopathy PPP:
References**

148. Thomas BJ, Shienbaum G, Boyer DS, Flynn HW, Jr. Evolving strategies in the management of diabetic macular edema: clinical trials and current management. *Can J Ophthalmol* 2013;48:22-30.
149. U.S. Food and Drug Administration, Center for Drug Evaluation and Research. Lucentis (ranibizumab injection). BLA 25156. Available at: www.accessdata.fda.gov/drugsatfda_docs/label/2012/125156s0069s0076lbl.pdf. Accessed June 11, 2014.
150. Nguyen QD, Shah SM, Khwaja AA, et al, READ-2 Study Group. Two-year outcomes of the ranibizumab for edema of the macula in diabetes (READ-2) study. *Ophthalmology* 2010;117:2146-51.
151. Rajendram R, Fraser-Bell S, Kaines A, et al. A 2-year prospective randomized controlled trial of intravitreal bevacizumab or laser therapy (BOLT) in the management of diabetic macular edema: 24-month data: report 3. *Arch Ophthalmol* 2012;130:972-9.
152. Do DV, Nguyen QD, Boyer D, et al, DA VINCI Study Group. One-year outcomes of the DA VINCI Study of VEGF Trap-Eye in eyes with diabetic macular edema. *Ophthalmology* 2012;119:1658-65.
153. Diabetic Retinopathy Clinical Research Network. Aflibercept, bevacizumab, or ranibizumab for diabetic macular edema. *N Engl J Med* 2015;372:1193-203.
154. Parke DW II, Coleman AL, Rich WL III, Lum F. Choosing Wisely: five ideas that physicians and patients can discuss. *Ophthalmology* 2013;120:443-4.
155. Early Treatment Diabetic Retinopathy Study Research Group. Techniques for scatter and local photocoagulation treatment of diabetic retinopathy: Early Treatment Diabetic Retinopathy Study report number 3. *Int Ophthalmol Clin* 1987;27:254-64.
156. Early Treatment Diabetic Retinopathy Study Research Group. Treatment techniques and clinical guidelines for photocoagulation of diabetic macular edema. Early Treatment Diabetic Retinopathy Study report number 2. *Ophthalmology* 1987;94:761-74.
157. Fong DS, Strauber SF, Aiello LP, et al. Comparison of the modified Early Treatment Diabetic Retinopathy Study and mild macular grid laser photocoagulation strategies for diabetic macular edema. *Arch Ophthalmol* 2007;125:469-80.
158. Guyer DR, D'Amico DJ, Smith CW. Subretinal fibrosis after laser photocoagulation for diabetic macular edema. *Am J Ophthalmol* 1992;113:652-6.
159. Han DP, Mieler WF, Burton TC. Submacular fibrosis after photocoagulation for diabetic macular edema. *Am J Ophthalmol* 1992;113:513-21.
160. Fong DS, Segal PP, Myers F, et al, Early Treatment Diabetic Retinopathy Study Research Group. Subretinal fibrosis in diabetic macular edema: ETDRS report no. 23. *Arch Ophthalmol* 1997;115:873-7.
161. Lewis H, Schachat AP, Haimann MH, et al. Choroidal neovascularization after laser photocoagulation for diabetic macular edema. *Ophthalmology* 1990;97:503-10; discussion 510-1.
162. Colucciello M. Vision loss due to macular edema induced by rosiglitazone treatment of diabetes mellitus. *Arch Ophthalmol* 2005;123:1273-5.
163. Ryan EH, Jr., Han DP, Ramsay RC, et al. Diabetic macular edema associated with glitazone use. *Retina* 2006;26:562-70.
164. Massin P, Duguid G, Erginay A, et al. Optical coherence tomography for evaluating diabetic macular edema before and after vitrectomy. *Am J Ophthalmol* 2003;135:169-77.
165. Otani T, Kishi S. A controlled study of vitrectomy for diabetic macular edema. *Am J Ophthalmol* 2002;134:214-9.
166. Yamamoto T, Hitani K, Tsukahara I, et al. Early postoperative retinal thickness changes and complications after vitrectomy for diabetic macular edema. *Am J Ophthalmol* 2003;135:14-9.
167. Diabetic Retinopathy Clinical Research Network Writing Committee, Haller JA, Qin H, Apte RS, et al. Vitrectomy outcomes in eyes with diabetic macular edema and vitreomacular traction. *Ophthalmology* 2010;117:1087-93.
168. Ferris F. Early photocoagulation in patients with either type I or type II diabetes. *Trans Am Ophthalmol Soc* 1996;94:505-37.
169. Diabetic Retinopathy Study Research Group. Four risk factors for severe visual loss in diabetic retinopathy: the third report from the Diabetic Retinopathy Study. *Arch Ophthalmol* 1979;97:654-5.
170. Diabetic Retinopathy Vitrectomy Study Research Group. Early vitrectomy for severe vitreous hemorrhage in diabetic retinopathy: two-year results of a randomized trial--Diabetic Retinopathy Vitrectomy Study report 2. *Arch Ophthalmol* 1985;103:1644-52.

171. Diabetic Retinopathy Vitrectomy Study Research Group. Early vitrectomy for severe proliferative diabetic retinopathy in eyes with useful vision: results of a randomized trial--Diabetic Retinopathy Vitrectomy Study report 3. *Ophthalmology* 1988;95:1307-20.
172. Diabetic Retinopathy Vitrectomy Study Research Group. Early vitrectomy for severe proliferative diabetic retinopathy in eyes with useful vision: clinical application of results of a randomized trial--Diabetic Retinopathy Vitrectomy Study report 4. *Ophthalmology* 1988;95:1321-34.
173. Diabetic Retinopathy Clinical Research Network. A randomized trial comparing intravitreal triamcinolone acetonide and focal/grid photocoagulation for diabetic macular edema. *Ophthalmology* 2008;115:1447-59.
174. Diabetic Retinopathy Clinical Research Network. Three-year follow-up of a randomized trial comparing focal/grid photocoagulation and intravitreal triamcinolone for diabetic macular edema. *Arch Ophthalmol* 2009;127:245-51.
175. Luttrull JK, Dorin G. Subthreshold diode micropulse laser photocoagulation (SDM) as invisible retinal phototherapy for diabetic macular edema: a review. *Curr Diabetes Rev* 2012;8:274-84.
176. Jacobson DR, Murphy RP, Rosenthal AR. The treatment of angle neovascularization with panretinal photocoagulation. *Ophthalmology* 1979;86:1270-7.
177. Fong DS, Ferris FL III, Davis MD, Chew EY, Early Treatment Diabetic Retinopathy Study Research Group. Causes of severe visual loss in the early treatment diabetic retinopathy study: ETDRS report no. 24. *Am J Ophthalmol* 1999;127:137-41.
178. Sivaprasad S, Crosby-Nwaobi R, Heng LZ, et al. Injection frequency and response to bevacizumab monotherapy for diabetic macular oedema (BOLT report 5). *Br J Ophthalmol* 2013;97:1177-80.
179. Diabetic Retinopathy Study Research Group. Photocoagulation treatment of proliferative diabetic retinopathy: clinical application of Diabetic Retinopathy Study (DRS) findings, DRS report number 8. *Ophthalmology* 1981;88:583-600.
180. Turner RC. The U.K. Prospective Diabetes Study. A review. *Diabetes Care* 1998;21 Suppl 3:C35-8.
181. Nathan DM, Bayless M, Cleary P, et al, DCCT/EDIC Research Group. Diabetes control and complications trial/epidemiology of diabetes interventions and complications study at 30 years: advances and contributions. *Diabetes* 2013;62:3976-86.
182. Ismail-Beigi F, Craven T, Banerji MA, et al, ACCORD Trial Group. Effect of intensive treatment of hyperglycaemia on microvascular outcomes in type 2 diabetes: an analysis of the ACCORD randomised trial. *Lancet* 2010;376:419-30. Erratum in: *Lancet* 2010;376:1466.
183. Bressler SB, Qin H, Melia M, et al, Diabetic Retinopathy Clinical Research Network. Exploratory analysis of the effect of intravitreal ranibizumab or triamcinolone on worsening of diabetic retinopathy in a randomized clinical trial. *JAMA Ophthalmol* 2013;131:1033-40.
184. Diabetic Retinopathy Clinical Research Network Authors/Writing Committee. Macular edema after cataract surgery in eyes without preoperative central-involved diabetic macular edema. *JAMA Ophthalmol* 2013;131:870-9.
185. Centers for Medicare and Medicaid Services. Physician Quality Reporting System. Available at: www.cms.gov/PQRS or www.aao.org/advocacy/reimbursement/pqri/reporting_options.cfm#5 (login required). Accessed June 11, 2014.
186. American Academy of Ophthalmology. Clinical Statement. Eye MD Examination Report Form. San Francisco, CA: American Academy of Ophthalmology; 2005; Reviewed 2012. Available at: <http://one.aao.org/guidelines-browse?filter=clinicalstatement>. Accessed June 11, 2014.
187. American Academy of Ophthalmology Vision Rehabilitation Committee. Preferred Practice Pattern[®] Guidelines. Vision Rehabilitation. San Francisco, CA: American Academy of Ophthalmology; 2013. Available at: www.aao.org/ppp.
188. Stelmack JA, Tang XC, Reda DJ, et al, LOVIT Study Group. Outcomes of the Veterans Affairs Low Vision Intervention Trial (LOVIT). *Arch Ophthalmol* 2008;126:608-17.
189. Javitt JC, Canner JK, Sommer A. Cost effectiveness of current approaches to the control of retinopathy in type I diabetics. *Ophthalmology* 1989;96:255-64.
190. Javitt JC, Aiello LP, Bassi LJ, et al. Detecting and treating retinopathy in patients with type I diabetes mellitus. Savings associated with improved implementation of current guidelines. *American Academy of Ophthalmology. Ophthalmology* 1991;98:1565-73; discussion 1574.

**Diabetic Retinopathy PPP:
References**

191. Javitt JC, Aiello LP. Cost-effectiveness of detecting and treating diabetic retinopathy. *Ann Intern Med* 1996;124:164-9.
192. Stein JD, Newman-Casey PA, Kim DD, et al. Cost-effectiveness of various interventions for newly diagnosed diabetic macular edema. *Ophthalmology* 2013;120:1835-42.
193. Sharma S, Brown GC, Brown MM, et al. The cost-effectiveness of grid laser photocoagulation for the treatment of diabetic macular edema: results of a patient-based cost-utility analysis. *Curr Opin Ophthalmol* 2000;11:175-9.
194. Busbee BG, Brown MM, Brown GC, Sharma S. CME review: a cost-utility analysis of laser photocoagulation for extrafoveal choroidal neovascularization. *Retina* 2003;23:279-87.
195. Crijns H, Casparie AF, Hendrikse F. Continuous computer simulation analysis of the cost-effectiveness of screening and treating diabetic retinopathy. *Int J Technol Assess Health Care* 1999;15:198-206.
196. Ho T, Smiddy WE, Flynn HW Jr. Vitrectomy in the management of diabetic eye disease. *Surv Ophthalmol* 1992;37:190-202.
197. Klein R. Hyperglycemia and microvascular and macrovascular disease in diabetes. *Diabetes Care* 1995;18:258-68.
198. Diabetes Control and Complications Trial Research Group. Early worsening of diabetic retinopathy in the Diabetes Control and Complications Trial. *Arch Ophthalmol* 1998;116:874-86.
199. ACCORD Study Group. Action to Control Cardiovascular Risk in Diabetes (ACCORD) trial: design and methods. *Am J Cardiol* 2007;99:21i-33i.
200. Action to Control Cardiovascular Risk in Diabetes Study Group. Effects of intensive glucose lowering in type 2 diabetes. *N Engl J Med* 2008;358:2545-59.
201. ACCORD Study Group. Effects of combination lipid therapy in type 2 diabetes mellitus. *N Engl J Med* 2010;362:1563-74. Erratum in: *N Engl J Med* 2010;362:1748.
202. ACCORD Study Group. Effects of intensive blood-pressure control in type 2 diabetes mellitus. *N Engl J Med* 2010;362:1575-85.



P.O. Box 7424
San Francisco,
California 94120-7424
415.561.8500

Diabetic
Retinopathy
Updated 2016