



SURGICAL MANAGEMENT OF STRABISMUS

EUGENE M. HELVESTON, M.D.

Emeritus Professor of Ophthalmology
Indiana University School of Medicine
Department of Ophthalmology
Section of Pediatric Ophthalmology and Strabismus
Indianapolis, Indiana

FIFTH EDITION

With 852 illustrations

With love and gratitude

to my wife

Barbara

Preface to the fifth edition

The 33 years since the publication of the *Atlas of Strabismus Surgery* has seen a steady growth in the number of ophthalmologists specializing in the diagnosis and treatment of strabismus. Membership in the American Association for Pediatric Ophthalmology and Strabismus has grown to more than 500 members and the International Strabismological Association boasts 300 members in 25 countries. Several journals deal exclusively or largely with the subject of strabismus and several high quality texts have been published dealing with strabismus diagnosis and management. Moreover, an explosion in the field of information technology has brought people together and facilitated the distribution of information in a way not dreamed of when the first edition of this book was written.

This fifth edition is renamed *Surgical Management of Strabismus* reflecting the fact that the major emphasis has shifted from a description of surgical procedures to a discussion of why and how these procedures are used to treat the patient with strabismus. There have been relatively few substantive changes in surgical technique. It is how these techniques are applied including the 'what' and 'when' which make up the bulk of this book.

A new concept that has influenced surgical management during the last decade is that of the pulleys associated with the horizontal rectus muscles. Study of these structures made possible in part by new imaging techniques, but more importantly by meticulous study of anatomic specimens, has helped make the management of 'A' and 'V' more logical and effective.

Included in this book are 135 strabismus cases managed by me either in the clinic or by means of consultation carried out by me and other mentors on patients sent by dozens of partners from countries

around the world. These patients' consultations were made possible by ORBIS Telemedicine, Cyber-Sight that is supported by the server at Flight Safety in New York and provided through the generosity of Mr. Albert Ueltschi. By viewing these images and reading the discussion that accompanies each, it is my hope that the reader will by critical analysis along with comparison of the patients seen in his or her clinic hone skills for a more effective personal approach to the whole patient leading to better outcome.

This book represents the 'full circle' in that it is based on experience during a professional lifetime in the care of patients with strabismus. It is my hope that what I have learned and then shared here will be of use to those who follow.

As with any effort like this there are many deserving people to thank. First among these is Mrs. Lynda Smallwood who more than any person is responsible for this book being completed. She not only typed the manuscript, but also assembled and formatted the entire book making it ready for the printer by simply submitting it in electronic format ready for duplication. Truly a monumental task! Others who worked hard and effectively are Leslie Abrams, Michelle Harmon, Gwen Kopecky, Sharon Teal who so ably carried on the art work begun by Craig Gosling, and Ann Hammer who read the first three chapters. I am grateful to the many Cyber-Sight partners who submitted hundreds of cases, and to my fellow Cyber-Sight strabismus mentors, especially Dan Neely who faithfully and expertly responded when called on. I thank all of my teachers, especially Gunter von Noorden my mentor beginning in 1966 and my friend for life. Most of all, I thank my wife Barbara for her unselfish and unfailing support, and my two daughters both of whom had the good sense to marry outstanding strabismologists.

Eugene M. Helveston

From the

Preface to the first edition

There have been several excellent texts on strabismus including strabismus surgery in the past few years, but developments have moved rapidly. Recent advances in technique have greatly expanded the options available to the strabismus surgeon. More accurate diagnostic tests leading to a better understanding of the pathophysiology of strabismus and amblyopia have convinced some surgeons of the need for surgery in infants as young as 5 months of age. Improved anesthesia and an increasing boldness on the part of the strabismus surgeon have led to outpatient extraocular muscle surgery in some instances without patch and without ointment or drops. The limbal and cul-de-sac (or fornix) extraocular muscle exposure techniques have largely superceded the transconjunctival incision in the interpalpebral space among younger surgeons. The retinal surgeon has opened new dimensions in the degree to which sub-Tenon's space may be explored.

There have been several excellent texts on strabismus including strabismus surgery in the past few years, but developments have moved rapidly. Recent advances in technique have greatly expanded the options available to the strabismus surgeon. More accurate diagnostic tests leading to a better understanding of the pathophysiology of strabismus and amblyopia have convinced some surgeons of the need for surgery in infants as young as 5 months of age. Improved anesthesia and an increasing boldness on the part of the strabismus surgeon have led to outpatient extraocular muscle surgery in some instances without patch and without ointment or drops.

New sutures, adhesives, muscle sleeves, and implantation materials have proved useful innovations. Globe fixation sutures, conjunctival recession and relaxation procedures, forced duction and active forced generation tests, as well as topical anesthesia for extraocular muscle surgery, have greatly enlarged

the vista of strabismus surgery.

For these reasons it seems appropriate at this time to compile an up-to-date atlas of strabismus surgery. This atlas employs schematic drawings designed to illustrate at each step only that anatomy significant to the step shown for easier orientation of the reader. Procedures that I have found useful have been given emphasis; those that are controversial or that I have not found to be particularly helpful have been omitted. Some "favorite technique" may be omitted simply because I prefer an alternative choice; those that I think should be avoided will be clearly labeled so.

No attempt will be made to give a set of surgical recipes that will result in a predetermined amount of straightening. Instead, general concepts leading to a philosophy for strabismus surgery will be presented. My intent is that this atlas will be of help to the practicing strabismus surgeon and the resident in ophthalmology by bringing together in one volume many techniques from a variety of sources for quick and easy reference.

Several people who assisted significantly in their own way to make this atlas possible deserve my sincere thanks. Dr. Gunter K. von Noorden, teacher, critic, and friend, introduced me to strabismus and to the pursuit of academic ophthalmology. Craig Gosling worked with industry and imagination on the illustrations, the heart of any atlas. My residents and many of my colleagues, in particular Drs. Marshall M. Parks and Phillip Knapp, provided both stimulus and direction.

Eugene M. Helveston

Contents

Section 1

1 History of strabismus surgery, 1

2 Surgical anatomy, 15

- Overview, 15
- Palpebral fissure size, 15
- Extraocular muscle size, 16
- Pulleys, 18
- Palpebral fissure shape, 21
- Epicanthal folds, 22
- Conjunctiva, 23
- Tenon's capsule, 24
- Surgical anatomy of the rectus muscles, 28
- Characteristics of the extraocular muscles, 31
- Motor physiology, 31
- Underaction and "overaction", 34
- Surgical anatomy of the inferior oblique, 35
- Lockwood's ligament, 37
- Superior oblique, 38
- Whitnall's ligament, 41
- Trochlea, 42
- Anterior segment blood supply, 48
- Vortex veins, 51
- Orbit and extraocular muscle imaging, 52
- Growth of eye from birth through childhood, 54
- Sclera, 56

3 Parasurgical procedures and preparation, 59

- Overview, 59
- Physical examination, 60
- Consent for strabismus surgery, 60
- Instruments used in strabismus surgery, 63
- Sutures and needles for strabismus surgery, 64

- Anesthesia for strabismus surgery, 67
- Preparation of the patient in the operating room, 70
- Layout of the operating room and anesthetic apparatus, 72
- Patient monitoring, 73
- Magnification in strabismus surgery, 74
- Wearing a mask, 74
- Outpatient surgery: the day of surgery, 75
- Postoperative care of the patient, 76

Section 2

4 Work-up of the strabismus patient, 79

- Design of the surgical procedure, 79
- Step 1: Patient evaluation, 81
- Diagnostic considerations for strabismus with restrictions, 90
- Differential intraocular pressure test, 98
- Step 2: Results to be expected from surgery, 108
- Summary of steps 1 & 2 in the design of strabismus surgery, 117
- Step 3: Guidelines for application of surgical options, 117
- Step 4: Surgical technique, 117
- Step 5: Follow-up of the surgical patient, 120

5 Diagnostic categories and classifications of strabismus, 123

- Congenital esotropia, 125
- Intermittent exotropia, 142
- Brown syndrome, 147
- Duane syndrome, 149
- Superior oblique palsy, 151

Section 3

6 Mechanics of surgery, 163

- Techniques of exposure, 163
- Limbal incision, 171
- Incisions for exposing the obliques, 174
- Obtaining improved exposure, 175
- Cuffed superior limbal incision, 176

7 Recession of a rectus muscle, 177

- Overview, 177
- Excessive recession, 177
- Recessions measured from?, 178
- Medial rectus recession, 179
- Lateral rectus recession, 181
- Superior rectus recession, 182
- Inferior rectus recession, 184
- Rectus muscle recession technique, 186
- Variations in suture and needle placement, 188
- Vertical displacement of the horizontal rectus, 190
- Resection effect of suture placement posterior to the muscle hook, 192
- Hang-back recession, 193
- Partial disinsertion, 194
- Recession of a rectus muscle with sparing of the anterior arteries, 194
- Slanted recession, 196
- 'Y' split of the lateral rectus, 197

8 Resection of a rectus muscle, 199

- Overview, 199
- Horizontal rectus resection (medial and lateral rectus muscles), 199
- Management of the intermuscular membrane in horizontal rectus resection, 200
- Resection clamp technique for rectus muscle resection, 201
- Double-arm suture technique for rectus muscle resection, 205
- Resection of the superior rectus, 206
- Inferior rectus resection technique, 207
- Tandem suture technique for rectus muscle resection, 208
- Plication (tuck) of a rectus muscle, 210
- Displacement of horizontal rectus muscles with resection for 'A' and 'V' patterns, 211
- Vertical effect from horizontal rectus resection and recession, 212

9 Surgery of the obliques, 215

- Oblique muscle surgery, 215
- Weakening the inferior oblique, 216
- Strengthening the inferior oblique, 225
- Strengthening the superior oblique, 235

10 Marginal myotomy: technique and indications, 241

- Historical review, 241
- Quantifying the marginal myotomy, 242
- Technique for a 'double 80%' marginal myotomy, 244
- Indications for a marginal myotomy, 245
- Other considerations, 248

11 Faden operation (posterior fixation suture), 247

- Posterior fixation suture (retroequatorial myopexy, faden operation), 247
- Placement of a posterior fixation suture after detaching the muscle, 251
- Placement of a posterior fixation suture without detaching the muscle, 251
- "Reinforced" posterior fixation suture, 252
- Combined posterior fixation and recession, 252
- Adjustable "faden", 252

12 Adjustable sutures: techniques for restriction, 255

- Overview, 255
- Technique for the adjustable suture, 255
- Tandem adjustable suture, 259
- Adjustable suture considerations, 260
- Conjunctival recession, 261
- Traction sutures, 263

13 Muscle transposition procedures, 265

- Overview, 265
- A review of muscle transposition procedures, 265
- Rectus muscle transfer, 268
- Scleral augmented muscle-tendon transfer, 270
- Knapp procedure, 272
- Superior oblique tendon transfer, 273
- Transposition for head tilt without oblique muscle dysfunction, 274

14 Botox (Botulinum A-toxin), 275

- Overview, 275
- The drug, 275
- Indications for Botox, 276
- Use of Botox in treatment of strabismus, 276
- Retrobulbar Botox for treatment of nystagmus, 277
- Botox for treatment of benign essential blepharospasm, 277
- Technique of injection, 277
- Botox for the treatment of blepharospasm, 281
- Injection techniques for blepharospasm and facial spasm, 281

- Inclusion of the inferior oblique in the lateral rectus insertion, 471
- Muscle-tendon rupture, 472
- Hyphema, 472
- Posterior chamber hemorrhage, 473
- Motility disturbance after nonmotility procedures, 473
- Postoperative Brown syndrome, 473
- Symblepharon, 474
- Orbital hemorrhage, 475
- Orbital cellulitis, 476
- Endophthalmitis, 476
- Postoperative communication, 477
- Operation on the wrong muscle, 477
- A homily, 477
- Operation on the wrong patient, 477
- Undesirable overcorrections and undercorrections, 478

Section 4

15 Telemedicine: distance medicine, 285

- Real time vs. store and forward, 285
- Moving or still, 285
- Image size, 285
- Computer, 286
- Start of Cyber-Sight, 286
- Telemedicine consultation cases, 292

Reading list, 479

Index, 495

16 Strabismus case management, 359

17 Complications in strabismus surgery, 455

- Complications of strabismus surgery?, 455
- Criteria for success after strabismus surgery, 455
- Informed consent, 457
- Diplopia, 457
- Reoperation, 458
- Loss of vision, 458
- Postoperative nausea and vomiting, 458
- Acute, allergic suture reaction, 459
- Chronic suture granuloma, 460
- Reaction to synthetic absorbable suture, 460
- Subconjunctival cysts, 460
- Prolapse of Tenon's capsule, 462
- Suture abscess, 463
- Delle, 463
- Lid fissure anomalies, 464
- Ptosis of the upper lid, 465
- Scleral perforation, 465
- Slipped or lost muscle, 466
- Anterior segment ischemia, 469
- Persistent overaction of the inferior oblique muscle, 470
- Inferior oblique adherence syndrome, 470

Section 1

Chapter 1: History of strabismus surgery

Chapter 2: Surgical anatomy

Chapter 3: Parasurgical procedures and preparation

History of strabismus surgery

Strabismus, recognized from the earliest times because the eyes are readily observable, has changed little in form throughout the years. However, its causes are now well understood, and its treatment undergoes regular revision and refinement. The condition, at first, was considered to be a visitation of an evil spirit and incurable. The earliest physicians suggested treatment with the only available methods—potions, purification, and diet. In the seventh century, masks designed to redirect the visual axes were described. Curiously, variations of this type of treatment are still advocated by some today in the form of sector occlusion, despite 13 centuries of failure!

The practice of strabismus surgery began inauspiciously in 1739 with the efforts of *John Taylor* (Figure 1). He is reported to have had “...a considerable amount of sense...,” according to Stewart Duke-Elder, who said Taylor undoubtedly recognized that strabismus was a muscle abnormality that could be treated by dividing the extraocular muscles.* However, Taylor’s surgery was not successful. On the contrary, Taylor is said to have been a showman who may have only snipped the conjunctiva, patched one eye, and left town before the results could be assessed. By patching the unoperated eye and having the operated eye take up fixation, Taylor’s procedure would have given the appearance of being successful since the operated eye would appear to have been ‘straightened.’ John Taylor’s position in history appears to be one of ridicule rather than honor.

After Taylor, several surgeons contributed to the body of knowledge that led to successful, scientifically founded strabismus surgery. In 1752, *Eschenbach* made the comment “each oculist dreams from time to time that it may be possible to dissect completely or partially the offending rectus muscle”.

In 1816 *Dulspech*, an orthopedic surgeon, performed tenotomy of the Achilles tendon as treatment for club foot with a technique not too different from strabismus surgery. *Gibson* experimented with extraocular



Figure 1
Abundant showmanship and fast carriage rather than surgical skills were outstanding attributes of the first strabismus ‘surgeon’ John Taylor (1703-1772), an itinerant healer who is depicted in this eighteenth century drawing.

*Duke-Elder S and Wybar K: *System of ophthalmology*, Vol 6, Ocular motility and strabismus, St Louis, 1973, The CV Mosby Co.
†von Noorden GK (ed): *History of Strabismology*, Belgium 2002, J. P. Wayenborgh

muscle transection for treatment of esotropia in 1818 but did not report this until 1841. *White*, in 1827, made similar attempts without success. *Stromeyer* performed extraocular muscle tenectomy on a cadaver in 1838, and a year later, *Dieffenbach* performed successful myotomy of the medial rectus on a 7-year-old boy with esotropia. His priority was contested by *Cunier*, but the honor has been granted to *Dieffenbach*. The year 1839 is generally considered to be the beginning of modern strabismus surgery.

In the nearly century and a half since its beginning with *Dieffenbach*, strabismus surgery has undergone many refinements, but the basic principles have changed little. The orthopedic principles that were adhered to at the beginning of strabismus surgery remain as the primary guiding factors today. To these have been added new knowledge of the central nervous system influences and psycho-physical factors related to strabismus. Understanding of neural mechanisms combined with knowledge and appreciation of both the dynamic muscle forces and the physiologic and pathologic restrictive aspects of ocular motility make strabismus surgery a science. Improved diagnostic techniques, such as passive duction testing, interpretation of differential intraocular pressure, differential saccadic velocity measurement, electrooculogram testing of nystagmus, and generated muscle force testing, have enabled more accurate diagnosis leading to more accurate surgery.

Improved imaging techniques, especially those using magnetic resonance imaging (MRI), have made possible the noninvasive morphologic study of extraocular muscles. Technical improvements in anesthesia, sutures and needles, implanted materials, antibiotics, corticosteroids, and, most recently, injectable toxins have broadened the scope of strabismus surgery. Recent studies of the origins of the most common strabismus, essential infantile or congenital esotropia, have promoted earlier surgery. Strabismus surgery, frequently done as an office procedure in its early years, is now once again done on an outpatient basis.

Strabismus surgery began with weakening procedures of the medial rectus. These procedures were first performed by transecting the muscle and often produced disastrous results (Figure 2). Shifting surgery from the belly of the muscle to the tendon reduced the number of overcorrections (Figure 3). Tendon weakening or lengthening, which avoided cutting across the full width of the tendon, was subsequently carried out using a variety of ingenious techniques. The earliest of these were performed without placing a needle and suture through the tendon. Instead, one or more incisions were made in the muscle or tendon, usually at right angles to the long axis of the muscle and crossing the midline. Later, tendon lengthening procedures used sutures. (Figure 4 & 5).

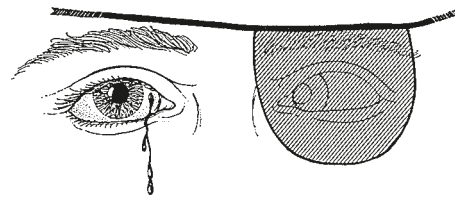
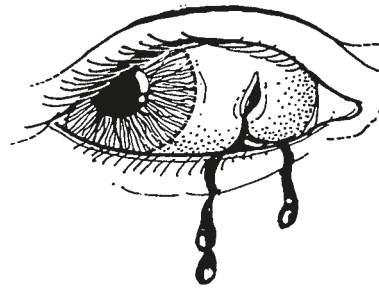


Figure 2

Taylor may have only snipped the conjunctiva, patched the eye, and then left town. He is said to have operated twice on *Bach*, the musician of Leipzig, who later became blind. The antics of Taylor may have been responsible for a 100-year delay in the establishment of strabismus surgery as part of the surgeon's armamentarium.

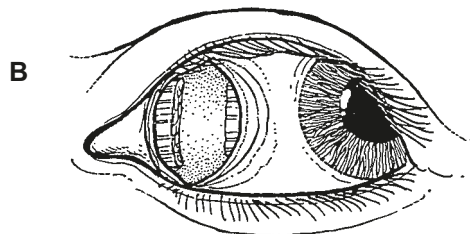
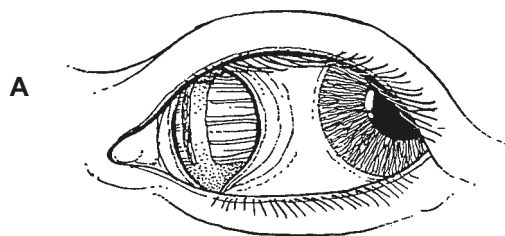


Figure 3

- A** Myectomy of the medial rectus for esotropia, as performed by *Dieffenbach* in 1839, often produced a large exotropia and unsightly medial displacement of the caruncle. The so-called cure may have been only a slight improvement over the malady.
- B** Simple tenotomy carried out nearer the insertion reduced the number and severity of overcorrections and lessened caruncle displacement.

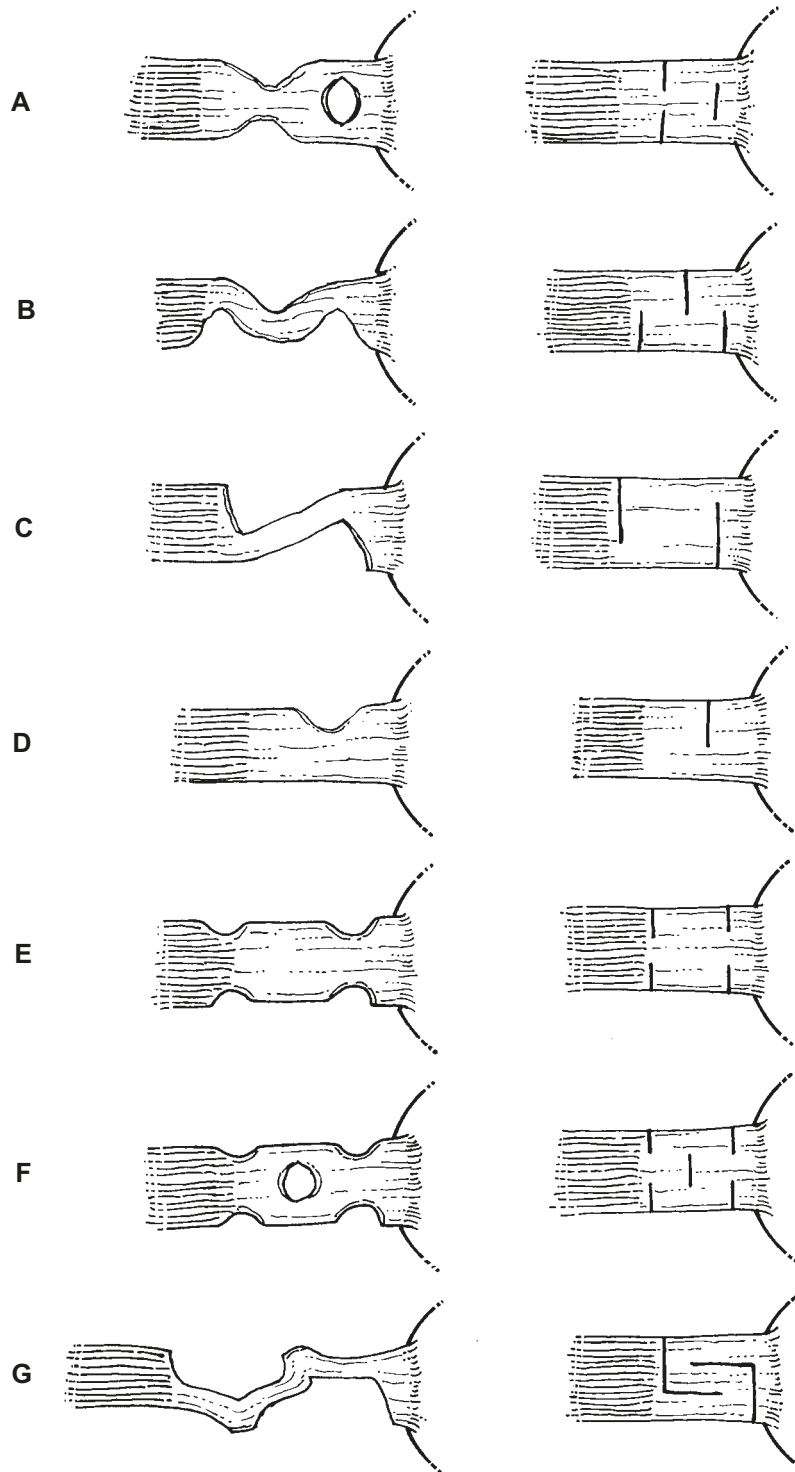


Figure 4

A wide variety of tendon lengthening procedures provided a safeguard against overcorrection and could also be carried out without sutures. The simple Z tenotomy (Blaskovics, 1912) is still used today for weakening an already maximally recessed muscle (Chapter 4).

- | | |
|------------------------|-------------------|
| A O'Connor | E Abadie |
| B Bishop-Harmon | F Verhoeff |
| C Blaskovics | G Terrien |
| D von Graefe | |

Some modern surgeons are reporting satisfactory clinical results from tenotomy which does not cut across all fibers, but more or less nicks the muscle. Biglan reports success treating small vertical deviations by doing incomplete tenotomy of the superior rectus.

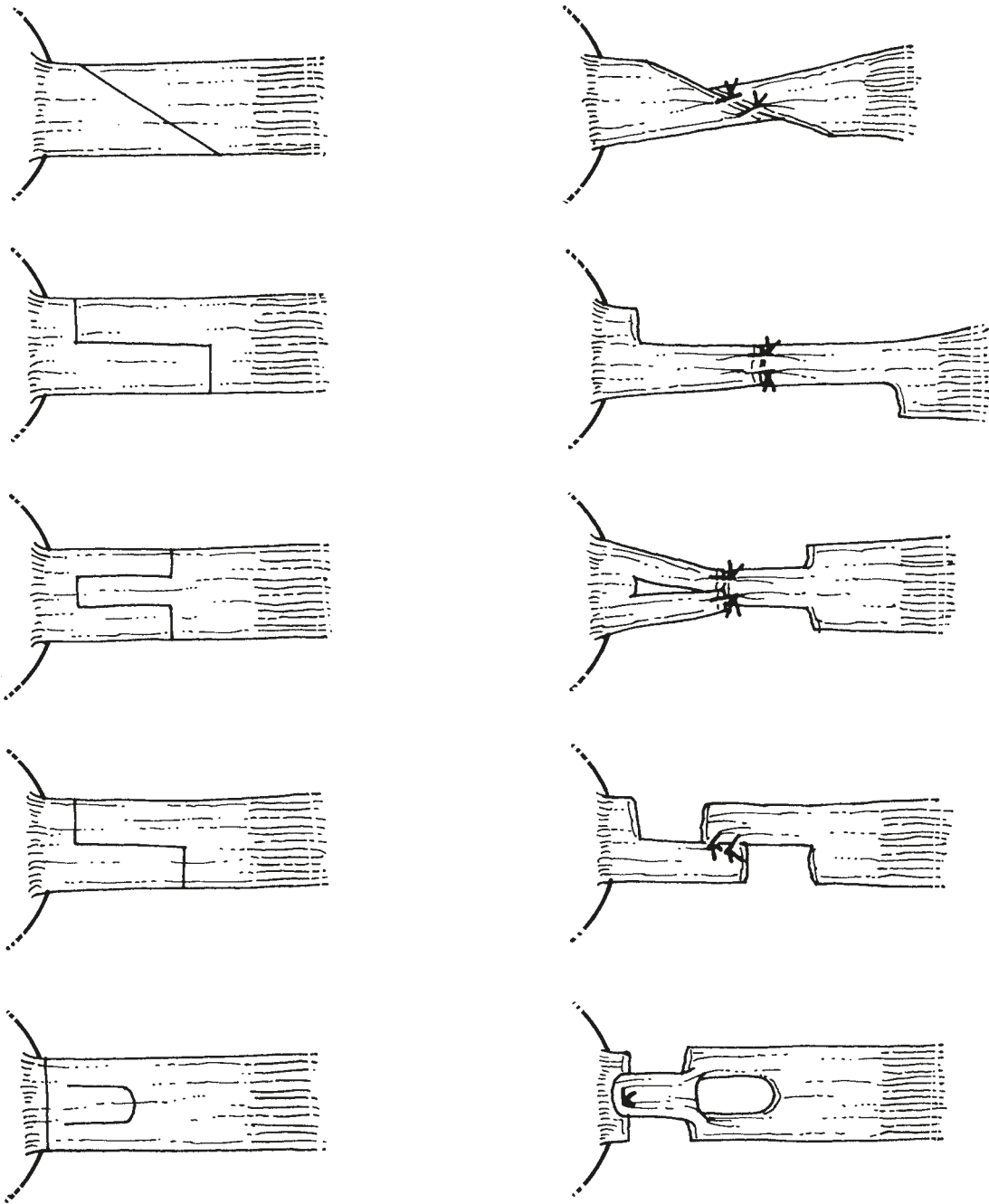


Figure 5
The use of sutures added to the complexity and safety, if not the effectiveness, of tenotomy. Again, the principle was that a lengthened tendon-muscle would result in reduced muscle pull and therefore produce a change in alignment, shifting the globe 'away' from the weakened muscle.

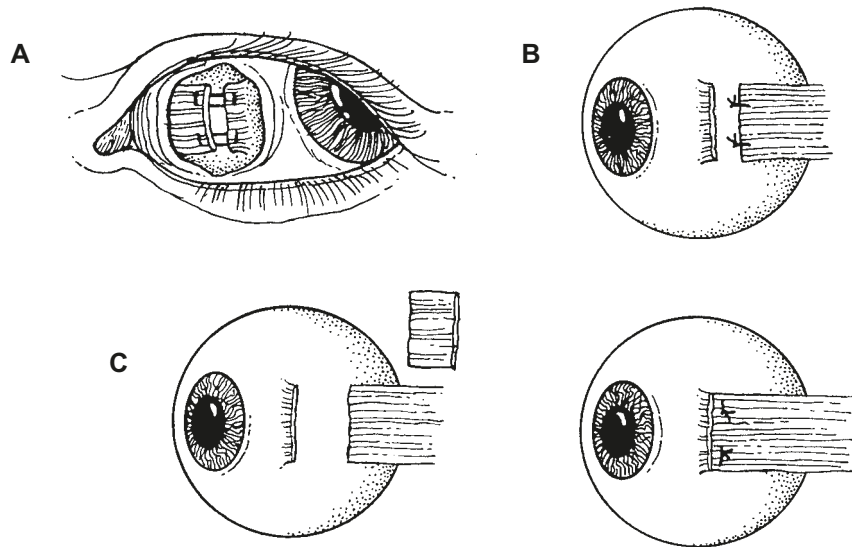


Figure 6

A Sutures were also used to reapproximate myotomized muscles to avoid producing more than the intended result. The sutures were not placed in the sclera. They were placed only in the cut ends of the muscle and tendon. The initial use of sutures apparently was for overcorrected and not primary cases.

B *Prince* (1887) was credited with describing recession with the tendon actually sutured to the sclera. This procedure was the forerunner of more accurate and reproducible surgery.

C *Worth* (1904) described resection using sutures. This muscle shortening was accomplished with or without recession of the antagonist muscle.

Late in the nineteenth century, measured recession with reattachment of the muscle to the sclera was carried out. Tendon and muscle tucking or plication; muscle advancement procedures; and, later, resection and advancement procedures were also performed (Figure 6).

Surgery of the oblique muscles began when inferior oblique weakening was carried out to treat myopia and asthenopia, not surprisingly without success. The superior oblique muscle was considered by some *noli me tangere*, loosely translated today as ‘off limits,’ in the early twentieth century. However, all types of oblique surgery had been described by the middle part of the twentieth century. Fink, in 1951, said “up to a few years ago, all corrective surgical measures for *the* obliques were not considered feasible because of anatomical difficulty.”*

Along with oblique muscle surgery and vertical rectus muscle recession and resection, extraocular muscle transfer procedures were used for strabismus caused by muscle paralysis. Although, at first, the improved alignment after eye muscle transfer procedures was thought to be due to postoperative neurologic reorientation, it became apparent from electromyographic studies that the effect of an extraocular muscle transfer procedure was mediated through mechanical factors.

Technical advances in strabismus surgery have occurred along with, and in some ways because of,

advances in anesthesia. A glass of wine and a good lunch followed by a head lock and a quick surgeon were early ‘anesthesia.’ This was replaced by pontocaine, cocaine, and ether for general anesthesia, and later, a wide variety of modern agents were used. Supporting modern anesthetic agents are the extensive and detailed monitoring devices that provide instantaneous, real-time recordings of temperature, respiration, electrocardiographic data, and oxygen saturation.

Highlights of the history of strabismus surgery from its earliest beginnings in 1739 to the present are depicted in the following drawings. They describe a wide variety of manipulations that surgeons employed to straighten the eyes by altering the state of the extraocular muscle (Figures 7-24). The statement has been made, “Those who do not learn from history are destined to repeat it.” Thus, some surgical procedures have a tendency to be rediscovered every generation or so by surgeons who may have overlooked an earlier description. Nonetheless, strabismus surgery has followed a steady progression, with improvement through innovations in the surgical technique, combined with better instruments, more reliable sutures, safer anesthesia, and a better appreciation on the part of the surgeon of neural, sensory, and mechanical factors.

*Fink WH: *Surgery of the oblique muscles of the eye*, St Louis, 1951, The CV Mosby Co.

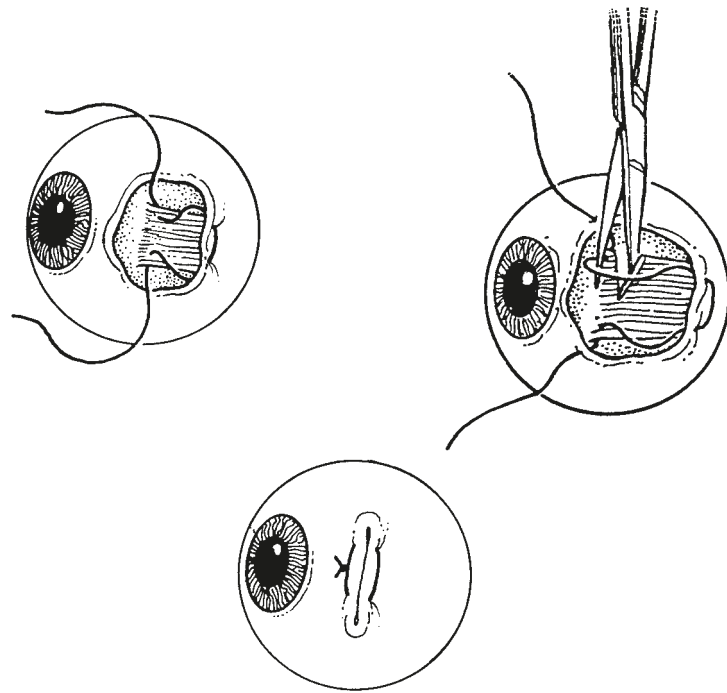


Figure 7

Most early recession procedures involved sutures entering and exiting the conjunctiva for added security and to facilitate removal of silk sutures. Tenon's capsule and the muscle capsule were incorporated in recessions and resections. The muscle is cut between bites of the preplaced suture to avoid 'loss' of the disconnected proximal muscle end. Externally placed buttons or bolsters added additional support to the recessed muscle, facilitated suture adjustment, and made suture removal easier.

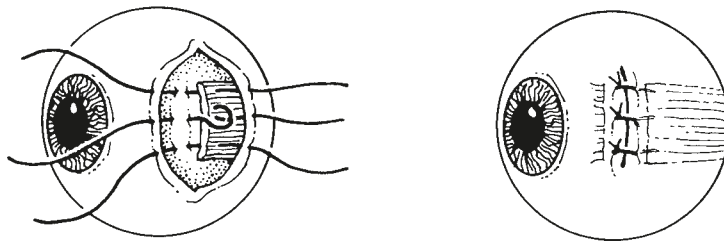


Figure 8

Jameson's technique for recession included several sutures anchoring the muscle to the sclera. The external sutures could be removed and loosened or tightened postoperatively if a significant overcorrection or undercorrection was produced.

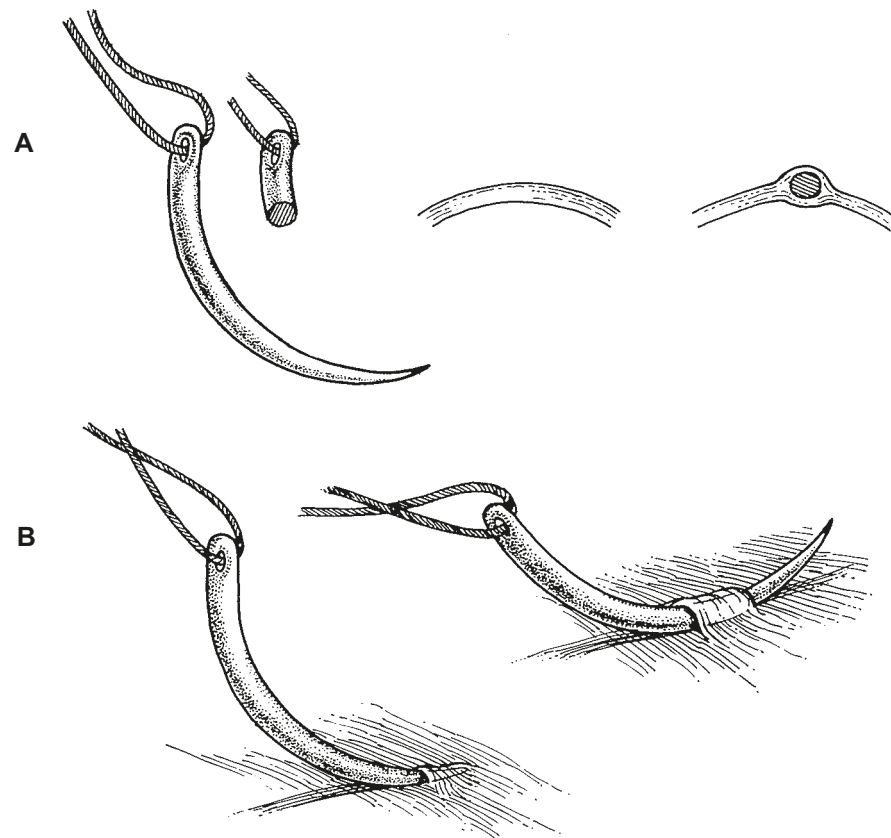


Figure 9

A Early needles were round; had eyes for threading the suture; and in most cases, had a wire diameter greater than the thickness of the sclera. These factors made the ophthalmic needle a 'formidable weapon.'

B Jameson admonished surgeons to keep the needle in view while passing it through the sclera, to avoid entering the globe and creating what he described as panophthalmia.

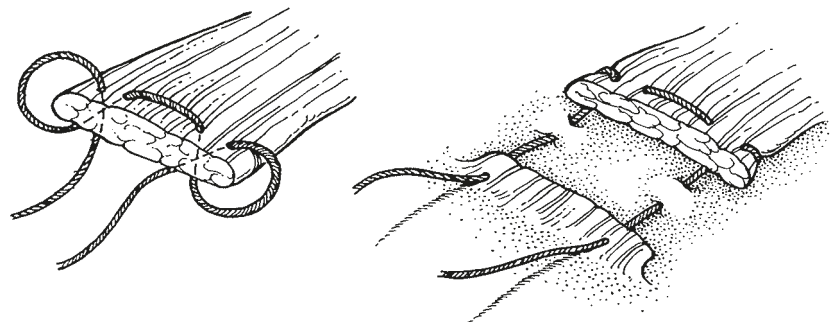


Figure 10

Peter's whip stitch for securing the cut end of the muscle during recession of a rectus muscle is a sound technique that is still used today.

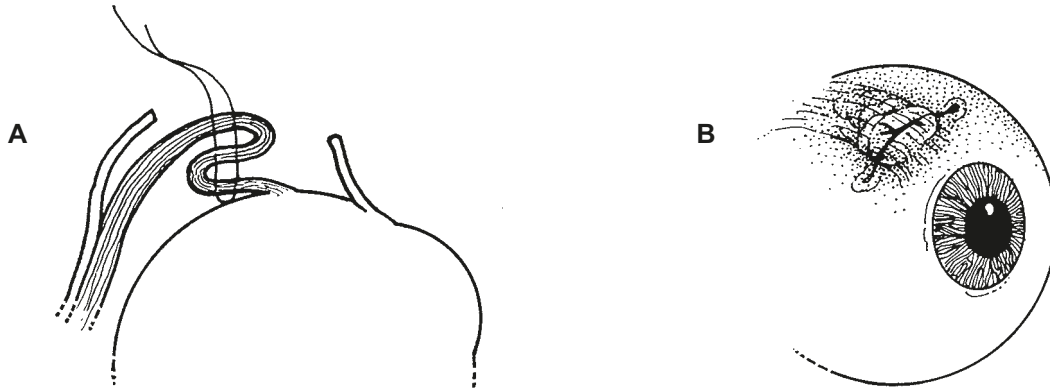


Figure 11

A A simple tuck for muscle-tendon shortening ('strengthening') avoided the need for placing a needle through the sclera and produced a shortened muscle without removing a piece.

B When performed near the limbus, tucking tended to produce unsightly bulk that could be cosmetically disfiguring.

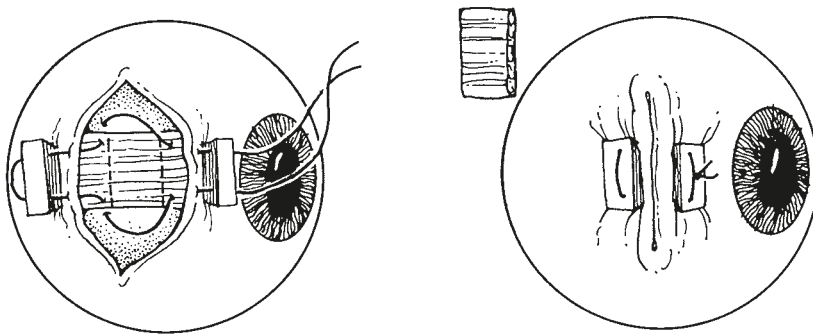


Figure 12

Pragnen used gold buttons as bolsters to eliminate 'cheese wiring' of the externalized suture when carrying out resection of a rectus muscle. This technique allowed postoperative adjustment of the length of the muscle.

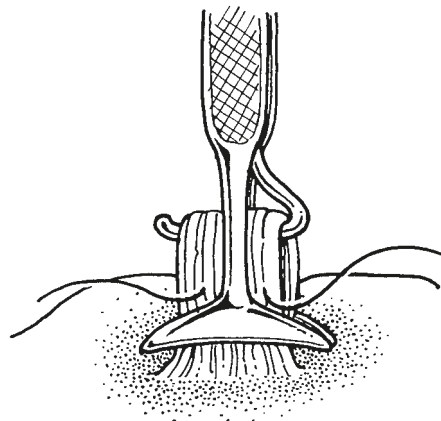


Figure 13

Peter's modification of the Bishop tucking instrument was one of several elegant instruments that were designed to facilitate the tucking procedure. Tucking of the extraocular muscles was an early favorite muscle shortening 'strengthening' procedure.

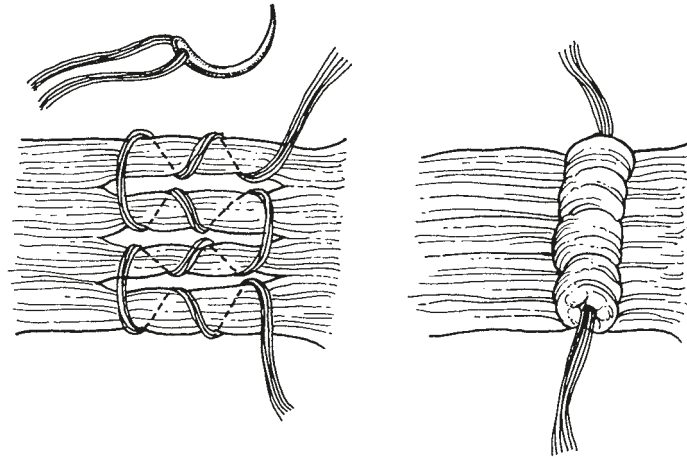


Figure 14

An ingenious technique, the O'Connor cinch, produced minimal shortening of a rectus muscle. A large, dull needle was used to weave a multiple-strand suture through slips of the tendon or muscle. The greater the number of threads, producing a bulkier suture and a greater diameter of thread, the more shortening of the muscle is produced.

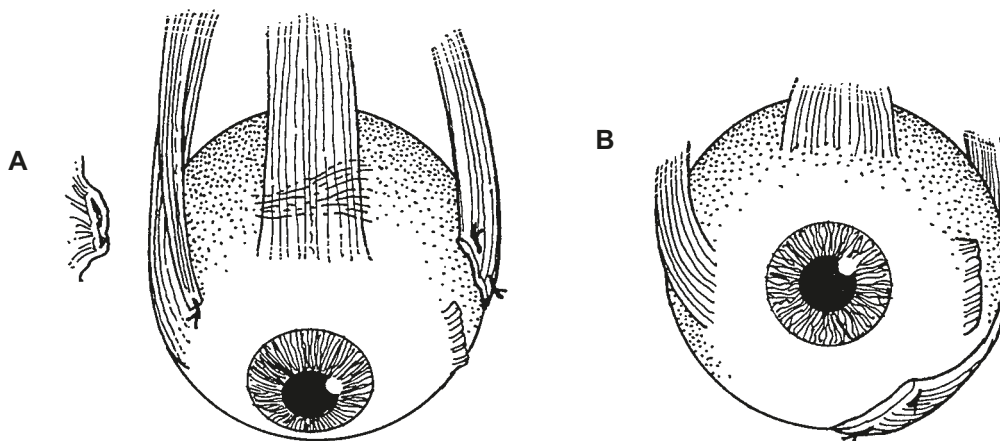


Figure 15

A Peter suggested fracturing the trochlea and then shifting and attaching the superior oblique muscle to a point near the medial rectus insertion. This procedure was combined with lateral rectus tenotomy or recession for treatment of third cranial nerve palsy.

B The lateral rectus was shifted for treatment of congenital absence of the inferior rectus.

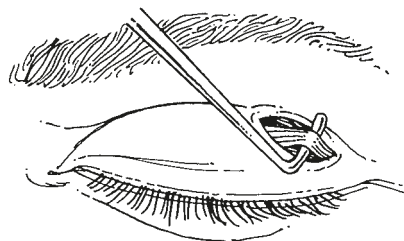


Figure 16

A transcutaneous approach to the superior oblique tendon afforded exposure for tenectomy or tucking. Skin incisions were commonly used for exposure of both superior and inferior oblique muscles in the early twentieth century.

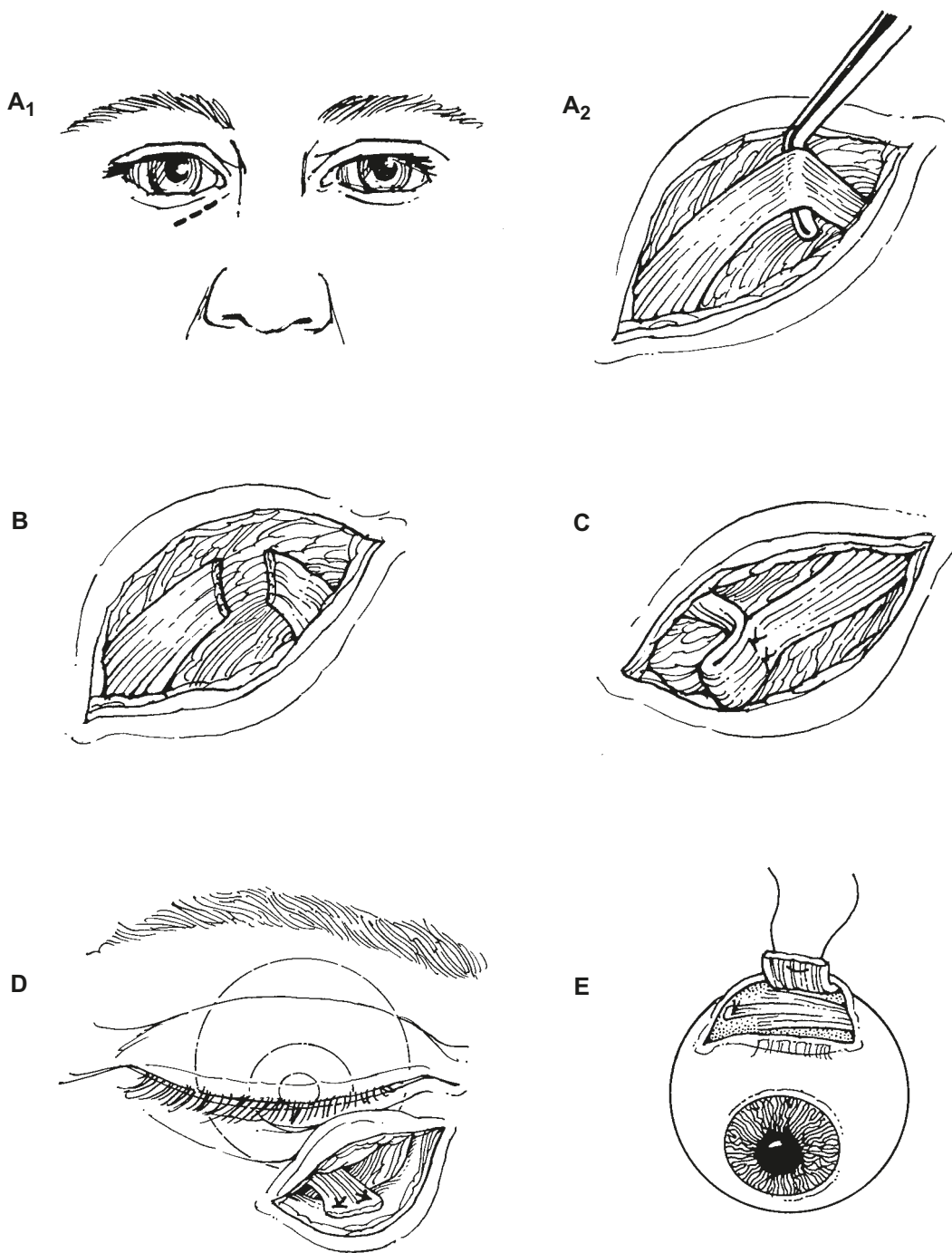


Figure 17

- A₁** Wheeler exposed the inferior oblique muscle nasal to the inferior rectus through a skin incision.
- A₂** The inferior oblique muscle was then engaged with a muscle hook.
- B** From that exposure the muscle could be weakened by myotomy.
- C** The muscle also could be shortened by a tuck.
- D** A curious inferior oblique 'strengthening' procedure performed by Wheeler was disinsertion of the muscle followed by reinsertion of the cut end into the inferior orbital rim periosteum.

- E** Wheeler strengthened the superior oblique muscle by advancing the central portion of the tendon. He recognized that this procedure produced decreased elevation in adduction. In addition, he recognized that shifting the tendon anteriorly produced intorsion and that posterior fibers influenced depression of the globe, a concept later credited to Harada and Ito (*Jpn J Ophthalmol* 8:88, 1964).

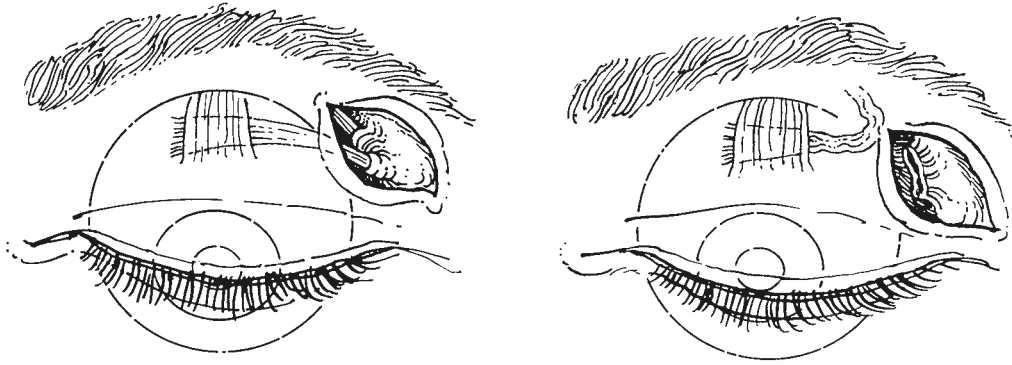


Figure 18

Hughes and Bogart exposed the trochlea subperiosteally, freed it, and pushed it backward several millimeters to weaken the superior oblique. This formidable procedure was accomplished with a transcutaneous approach. No reports of series of patients having this procedure performed on them were described. It is unlikely that his procedure was done widely; it indicates the imagination and ingenuity of the early strabismus surgeon. This procedure, when performed inadvertently after use of the Lynch incision for exposure of the ethmoid sinus, can produce superior oblique underaction, creating the clinical picture of superior oblique palsy which, in turn, results in diplopia for the unlucky patient.

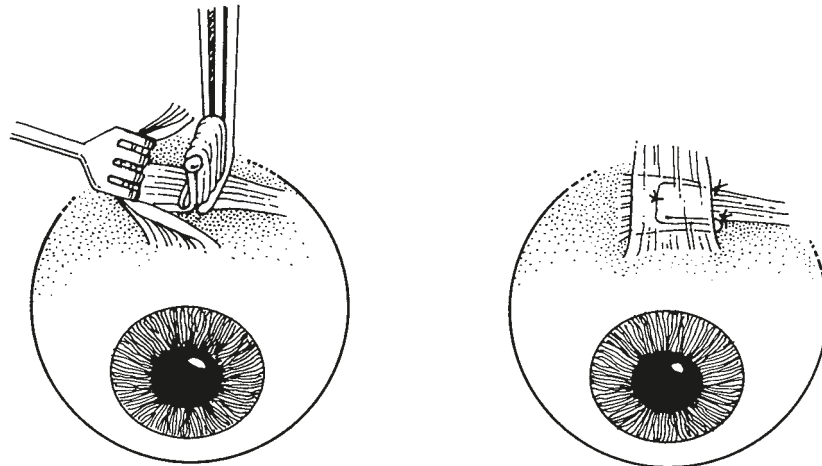


Figure 19

White plicated the superior oblique tendon medial to the superior rectus using a tucking instrument. He advised placing the tuck nearer the superior rectus and away from the 'pulley' of the trochlea to avoid having the superior oblique tendon become hung up in the trochlea.

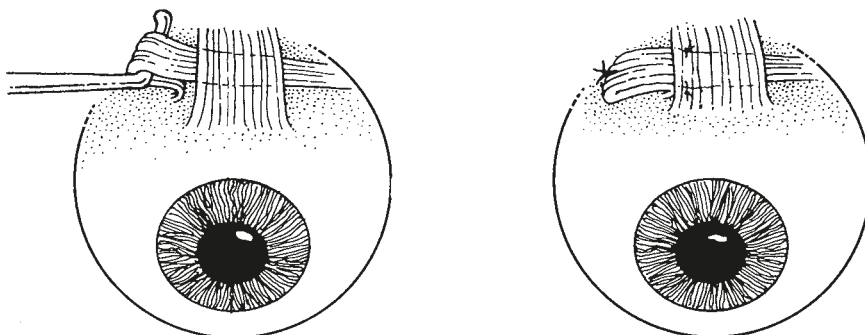


Figure 20

McLean engaged the superior oblique tendon temporally and brought the redundant loop of tendon temporally. This technique for tucking the superior oblique tendon was said to reduce the incidence of postoperative limitation of elevation in adduction by avoiding the trochlea and by reducing the likelihood of adherence of the redundant loop of tendon to the superior rectus. However, any superior oblique tuck will cause a Brown postoperatively unless the tuck is done in a loose tendon and will result postoperatively in an equal and normal superior oblique traction test (see chapter 9).

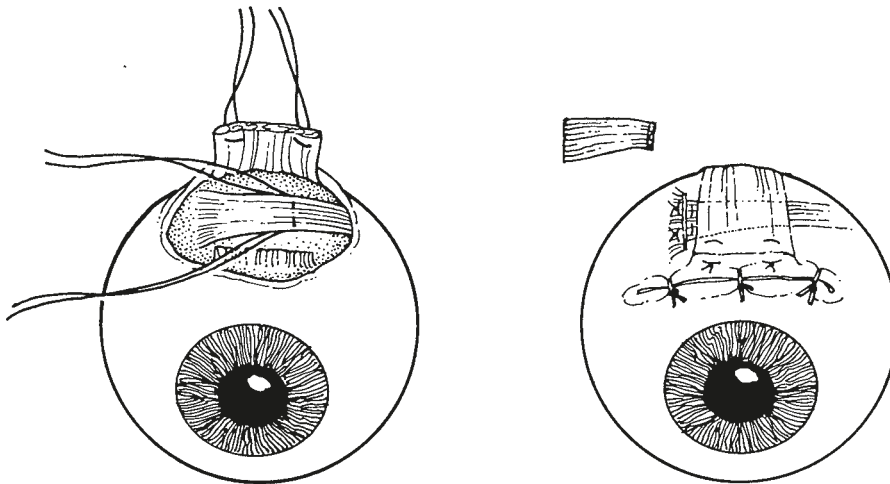


Figure 21

Based on a procedure originally suggested by McGuire, *Fink* described resection of the superior oblique tendon after detaching the superior rectus muscle. Removal of the superior rectus provided improved exposure of the superior oblique tendon.

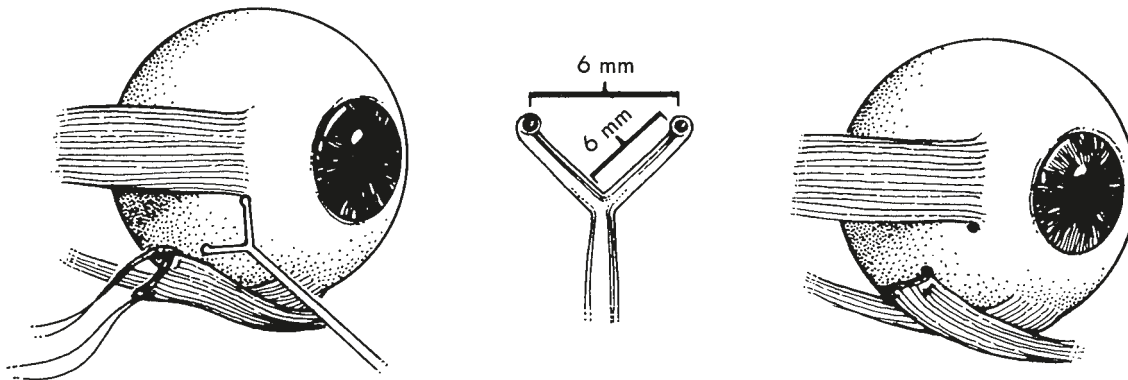


Figure 22

Fink recessed the inferior oblique muscle using a recession localizer that had a 7 cm handle with 6 mm arms projecting at 90 degrees from each other and a 1 mm tip with a concavity to hold gentian violet for marking. The purpose of the instrument was to allow for an accurate 8.0 mm recession of the inferior oblique muscle. By estimation the recession could be reduced to 6.0 mm or increased to 10.0 mm.

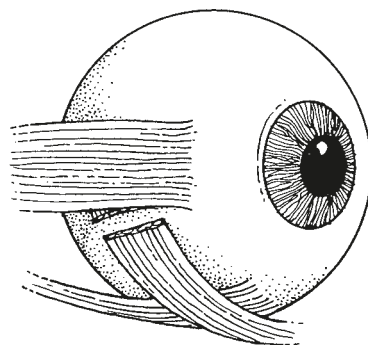


Figure 23

Following the lead of *Duane*, *White* and *Brown* weakened the inferior oblique by disinsertion without reattachment, considering the procedure safe and effective.

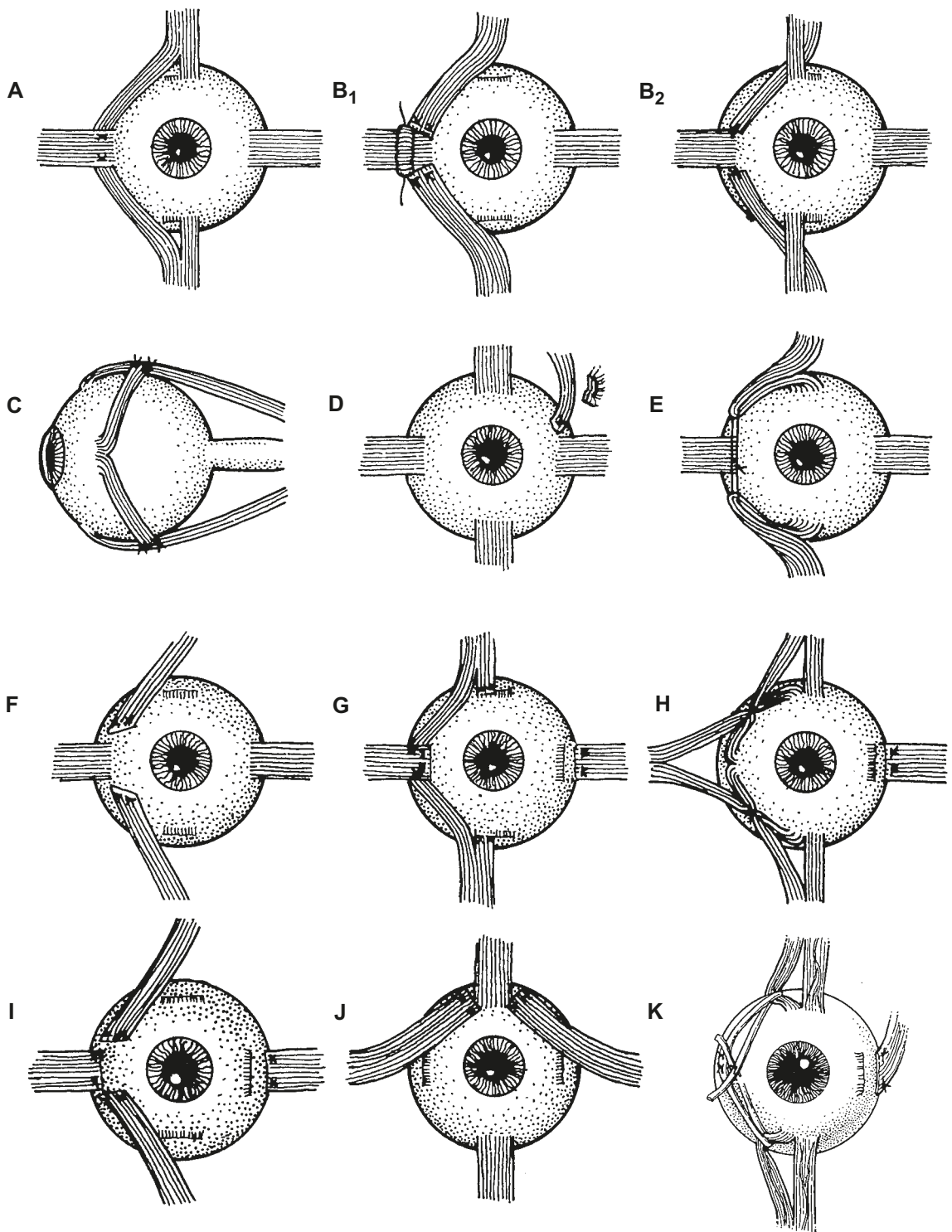


Figure 24

Several techniques have been described for extraocular muscle transfer. The underlying principle for each procedure, except superior oblique tendon transfer, is to shift the pull of antagonist muscles to a point on the globe coinciding with the insertion of the rectus muscle lying between. The procedures shown have been described by the following:

A Hummelsheim

B₁ O'Connor

B₂ Modified O'Connor

C Wiener

D Peter

E Hildreth

F Schillinger

G Beren-Girard

H Jensen

I Uribe

J Knapp

K Helveston*

*done in the case of an absent medial rectus

A limited number of manipulations can be performed on an extraocular muscle. The muscle can be shortened and then made to stretch, at first under tension, to the original preoperative distance between origin and insertion while presumably being more 'effective;' the muscle can be retroplaced with the same length of muscle going between two points closer together than the original origin and insertion; or a 'longer' muscle connecting the original origin and insertion can be created with myotomy or tenotomy. The insertion can be shifted to a new place on the globe, retaining the same innervation but having an altered mechanical effect.

Recent innovations in strabismus surgery include change in the arc of contact produced by the Faden operation (retroequatorial myopexy or posterior fixation suture); denervation of the inferior oblique muscle; detachment of the rectus muscles with sparing of the anterior ciliary vessels; and toxin injection at the motor end-plate to weaken a muscle's function by interference with nerve transmission at the myoneural junction. Thermal disruption of selected eye muscle fibers has been described but has not yet been proven successful.

Early strabismus surgeons had an accurate grasp of muscle function but little appreciation for orbital fascial anatomy. Numerous references to the encountering of fat during strabismus surgery suggest that even the best surgeons found orbital fat on a routine basis. Except for referring to cutting across the conjunctiva, Tenon's capsule, and the muscle capsule, scarcely a comment on these fascial tissues is found

in early literature dealing with strabismus surgery. Modern strabismus surgery differs significantly from early strabismus surgery in its attention to detail in dealing with the orbital fascia and fat. Recent description of the anatomy of the trochlea, the inferior oblique, and especially of the muscle pulleys has provided new insight for strabismus surgeons.

These tissues are thought by some surgeons to be as important as the muscle itself. This book will emphasize the importance of technique in the belief that the surgeon who exercises impeccable care when dealing with all tissues encountered in strabismus surgery will attain better results.

Some operations that have been suggested by older surgeons or a few contemporary surgeons are not mentioned even as an option in either the historical or current sections. These omissions indicate a bias, which I hope will not result in overlooking useful procedures. Only procedures of sufficient historical interest or contemporary procedures that have some rational basis will be described. When appropriate, alternative techniques will be described.

The use of *adhesives* and *plastic sleeves* and *sheets* or *caps* mentioned in previous editions now are mentioned here only as a part of the history of strabismus surgery. Like many of the procedures shown in this chapter, these techniques sounded good, were tried, but now are relegated mostly to memory.

For a more complete review of the history of strabismology, the reader is advised to consult *The History of Strabismology* edited by Gunter von Noorden (J. P. Wayenborgh, Belgium, 2002).

Surgical anatomy

Overview

The successful strabismus surgeon has a clear understanding of the anatomy of the extraocular muscles which move the eyes, and also of the fascia, fat, nerves, and the blood supply of the eye and orbit. Although the extraocular muscles, especially that part anterior to the equator, are the focus of strabismus surgery, structures such as the conjunctiva, anterior Tenon's capsule, posterior Tenon's capsule (intermuscular membrane and muscle sheaths), and the newly-described pulleys influence both movement and alignment of the eyes. The sum of these structures, including those observed during the course of surgery and others never seen, work in concert actively and passively to support, guide, restrict, or modify movement of the eyes both physiologically in health and pathologically in the case of strabismus.

The surgeon must be concerned with the mechanics of access to the operative site, first between the lids and then through the conjunctiva and Tenon's capsule. A proper start is required if the surgeon expects a successful conclusion. The location, as well as the blood supply, innervation, and action of each of the extraocular muscles, must be known, including the contribution of each muscle's intrinsic blood supply to the nutrition of the anterior segment. Scleral thickness, which varies according to location, must be taken into account especially when placing a needle into the sclera.

The action of each extraocular muscle is influenced by the location of its insertion on the globe and by the location of its pulley (or equivalent structure), in particular, those pulleys associated with the medial and lateral rectus muscles. A thorough understanding of these anatomic relationships forms the basis for a logical mechanical approach to surgery on the extraocular muscles, including recession, resection, transposition, transection, plication, union, and chemodenervation. In addition, orbital structures surrounding the globe and extraocular muscles profoundly affect the design, execution, and results of

extraocular muscle surgery. The orbital fat must be recognized, respected, and left undisturbed. Lockwood's ligament and associated lower lid retractors providing support to structures that influence the lower lid position and to the inferior oblique and inferior rectus muscles must be dealt with properly to avoid lower lid ptosis. Whitnall's ligament associated with the levator palpebri, while not ordinarily encountered in the course of strabismus surgery, plays an important part in surgery of the upper lid. The vortex veins, although often observed in contrast to orbital fat which is *not*, should not be disturbed.

Much of the new information about the anatomy and physiology of the structures of the orbit comes from laboratory studies using ultrasonography, computerized tomography (CT), magnetic resonance imaging (MRI), and histochemical techniques. Use of some of these in clinical practice can also aid in strabismus diagnosis and in the design and execution of successful extraocular muscle surgery.

The following material describing surgical anatomy and functional physiology is intended to provide practical information for the strabismus surgeon.

Palpebral fissure size

The dimensions of the palpebral opening increase nearly 50% in width and 20% in height between infancy and adulthood. Configuration varies with a person's physical and racial characteristics (Figure 1). The size and shape of the palpebral opening should be considered at the outset of extraocular muscle surgery. To start with, a lid speculum appropriate to the size of the palpebral opening should be used (Figure 2). In addition, the surgeon should expect to encounter more difficulty with exposure and suture placement in medial rectus recession and also in patients with a small palpebral fissure or deeply-set eyes. However, measured recession can be

accomplished even with the smallest lid fissure opening in an infant beginning at 4 months. Limited working area is not an adequate reason for doing a marginal myotomy as an initial weakening procedure of a medial rectus muscle in congenital esotropia simply because a marginal myotomy is thought to be easier to accomplish than a measured recession. Extraocular muscle surgery in an adult with deeply-set eyes and a smaller than average palpebral opening can be more difficult than such surgery in a 3- or 4-year-old child with a normal or larger than normal palpebral opening (Figure 3, 4).

Ptosis, pseudo ptosis, lid retraction, exophthalmos, and enophthalmos all represent lid and palpebral fissure variations that will be encountered and must be both understood and dealt with in the gamut of strabismus management. These issues will be dealt with in more detail during the discussion of clinical examples.

Extraocular muscle size

Unlike the palpebral opening which differs significantly according to age, the extraocular muscle size, or at least width at insertion, is closer to constant throughout life. A child with a tiny palpebral opening is likely to have a medial rectus whose insertion width is very close to the adult average measurement of 10 mm. This means that the *timing* of strabismus surgery is not determined by either the size of the palpebral opening or of the extraocular muscles. Globe size, on the other hand, is significant in the design of strabismus surgery. Comparing globe size and extraocular muscle location, Swan and co-workers pointed out that in newborns, the posterior part of the globe is relatively smaller than the anterior part, meaning that a recession of 3 mm could place the medial rectus *at the equator*. This is important information but not for strabismus surgery, which is not indicated anyway in the newborn because of immaturity of the binocular system. The globe in the 4-month-old, an age some consider the earliest appropriate for strabismus surgery, is 19.5 mm in axial length. This is sufficient size to allow an appropriate recession of the medial rectus in congenital esotropia. For example, a recession of 9.5 mm measured from the *limbus* places the new insertion of the medial rectus at the equator in a 4-month-old with an axial length of 19.5 mm (Figure 5). The insertion of the medial rectus in an infant can be closer than 5.5 mm from the limbus. This means that a medial rectus recession, if measured 9.5 mm from the limbus, will be at *least* equal to a 4 mm recession, if measured from a medial rectus insertion that was 5.5 mm from the limbus. It could also be as large as 6 mm considering measurement from the insertion, if the medial rectus inserts 3.5 mm from the limbus as it does in some infants. With continued growth of the globe

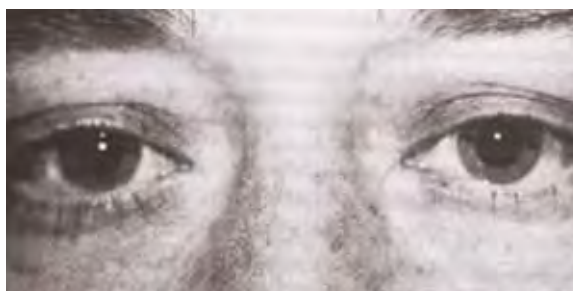

Figure 1
The average adult palpebral opening is 28 mm long and 10 mm high.



Figure 2
Lieberman speculums, pediatric (top) and adult (bottom), are ideal for strabismus surgery.

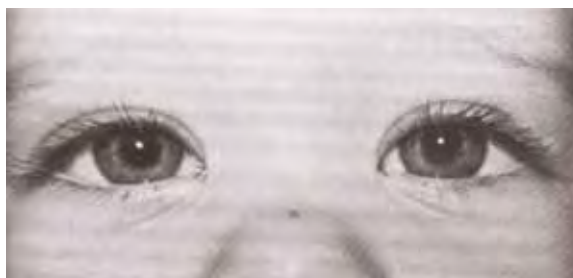


Figure 3
An average 18-month-old child has a palpebral opening 20 mm long and 8.5 mm high.

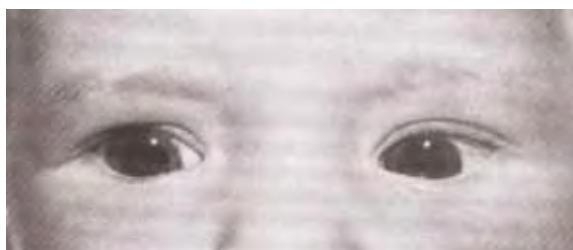


Figure 4
A newborn has a palpebral opening measuring 18 mm long and 8 mm high.

taking place primarily in the posterior part, the relative position of the medial rectus insertion will move anteriorly, and therefore safely, with maturity.

The point of measuring from the limbus is that this provides a safe technique for performing a larger recession of the medial rectus, especially in those cases with medial rectus insertions closer to the limbus (Figure 6). Measurement from the limbus begs the question, "Is the significant factor in correction of esotropia the size of medial rectus recession or the new position of the muscle on the globe?" The answer may be that both play a role. We do know that

undercorrection of congenital esotropia occurred in nearly 50% of cases when the maximum for medial rectus recession was on the order of 5.5 mm from the insertion as was the 'rule' in the 1960's. This undercorrection rate reduced immediately to approximately 10% in a series when medial rectus recession was measured from the limbus. This technique of recession measured from the limbus, allowing larger but safe recessions, is now joined by larger recession measured from the insertion. These larger recessions, some 7 mm or more, have been implicated in a higher overcorrection rate.

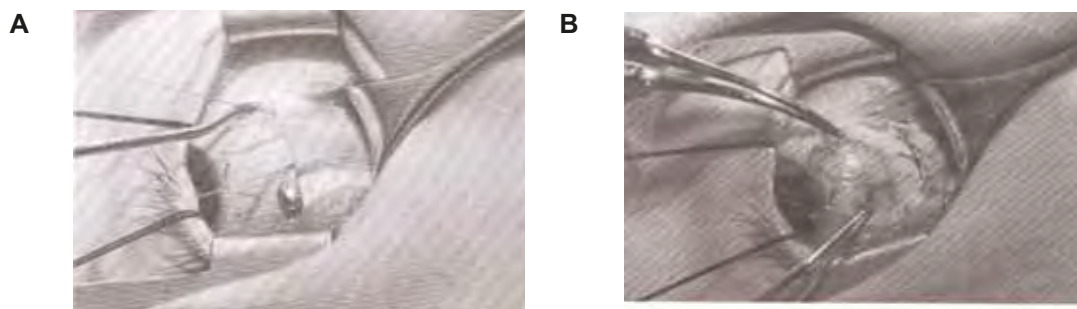


Figure 5

A The medial rectus of a 4-month-old measures approximately 10 mm at the insertion.

B The muscle has been recessed 9.5 mm from the limbus using a limbal incision.

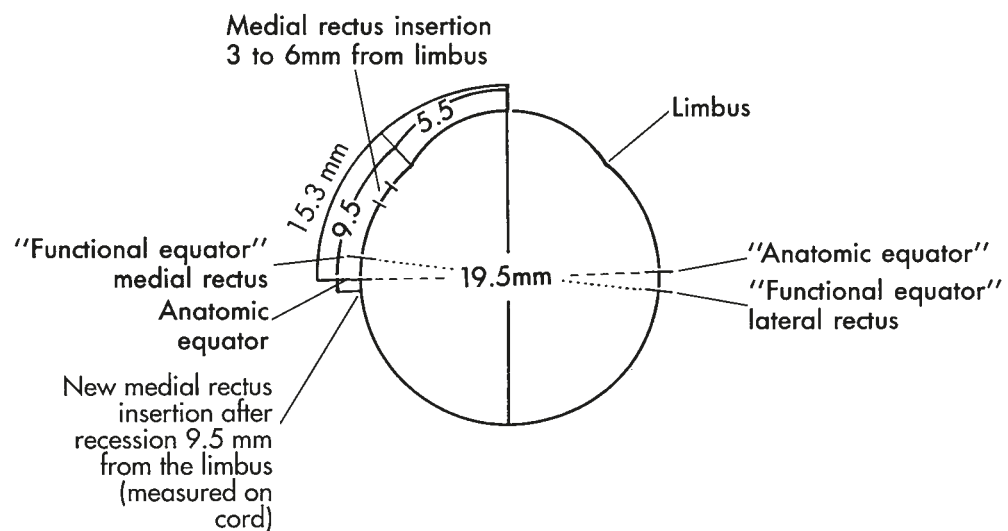


Figure 6

In a 4-month-old with an axial length of 19.5 mm, a recession 9.5 mm from the limbus places the new insertion of the medial rectus approximately at the equator.

Pulleys

Around 1990, Joseph Demer and associates began study of the anatomy and actions of the extraocular muscles using high resolution magnetic resonance imaging on clinical patients and normal subjects aided in some cases by the use of paramagnetic MRI contrast agents (Figure 7, 8). This work, along with detailed histologic and histochemical study of human and monkey orbital tissue in the laboratory, led to the following summation by the authors in 2002. "The resulting reexamination of EOM (extraocular muscle) anatomy and physiology has been so revealing as to suggest a fundamental paradigm shift having broad basic and clinical implications."

Demer and associates' conclusions are summarized as follows:

1. Orbital structures called 'pulleys' are associated with each of the rectus muscles and the inferior oblique.
2. The 'pulleys' receive the contractile force of the extraocular muscles and inflect the paths of the muscles in a "qualitatively similar manner to the inflection of the superior oblique (SO) tendon path by the trochlea" (Figure 9).
3. The paths of the extraocular muscles posterior to the pulleys (between the pulleys and the annulus of Zinn) remain constant regardless of the position of the globe. There is no 'side slip' of the rectus muscles, (except in the case of an abnormality of the pulley).
4. The functional origin of the extraocular muscles is at their pulleys (Figure 10).
5. The orbital one-half of the extraocular muscle fibers insert into the pulley and the bulbar one-half of extraocular muscle fibers pass forward to attach to the globe at the muscle's insertion (Figure 11).
6. Only that portion of the extraocular muscle anterior to the pulleys moves in the direction of the globe's movement (Figure 12).
7. Upward displacement of the lateral rectus pulleys and downward displacement of the medial rectus pulleys are associated with 'A' pattern. (Figure 13) Downward displacement of the lateral rectus pulleys and upward displacement of the medial rectus pulleys are associated with 'V' pattern (Figure 14).
8. Pulleys made up of collagen, elastin, and richly innervated smooth muscle are situated in the orbit in the area previously called check ligaments. They are not readily distinguishable clinically and require special techniques to be seen in the laboratory.
9. Several other pulley abnormalities could be associated with strabismus entities including:

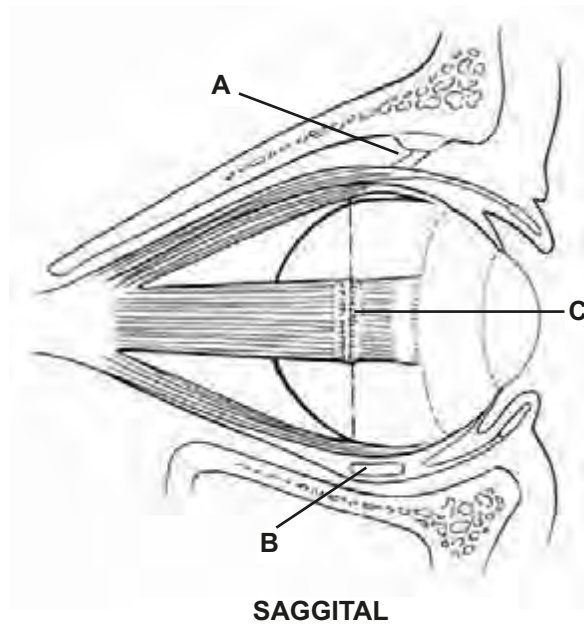


Figure 7

The 'pulley zone' is roughly at the junction of the middle and posterior third of the globe, similar to Listing's plane (see page 32).

- A Trochlea of the superior oblique - inflection of the superior oblique.
- B Lockwood ligament - the 'pulley' of inferior rectus -- the functional origin of the inferior oblique (the functional insertion of the inferior oblique after distal myectomy).
- C The pulley of the horizontal recti.

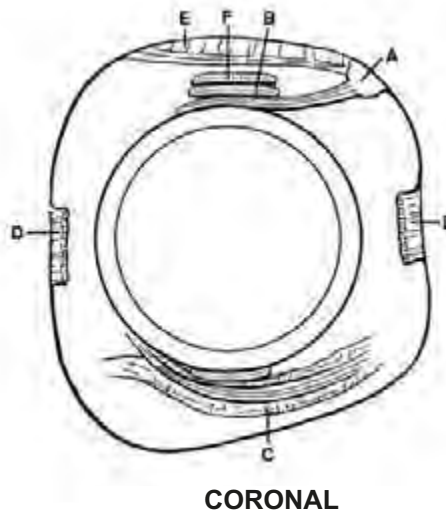


Figure 8

- A Trochlea
- B Confluence of superior oblique tendon and superior rectus sheath
- C Lockwood's ligament
- D Pulley of the horizontal recti
- E Whitnall's ligament
- F Levator palpebri

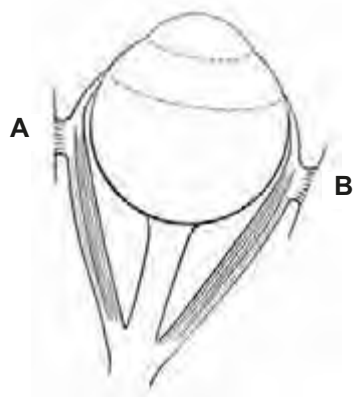


Figure 9
The pulleys which 'inflect the paths of the muscle.'
A Medial rectus pulley
B Lateral rectus pulley

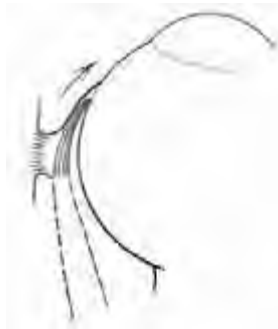


Figure 10
The functional origin of the rectus muscles is at the pulleys.

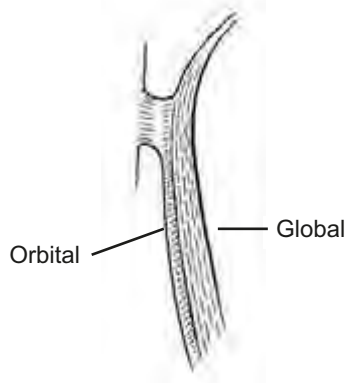


Figure 11
The orbital fibers insert into the pulleys of the horizontal recti and the global fibers insert into sclera.

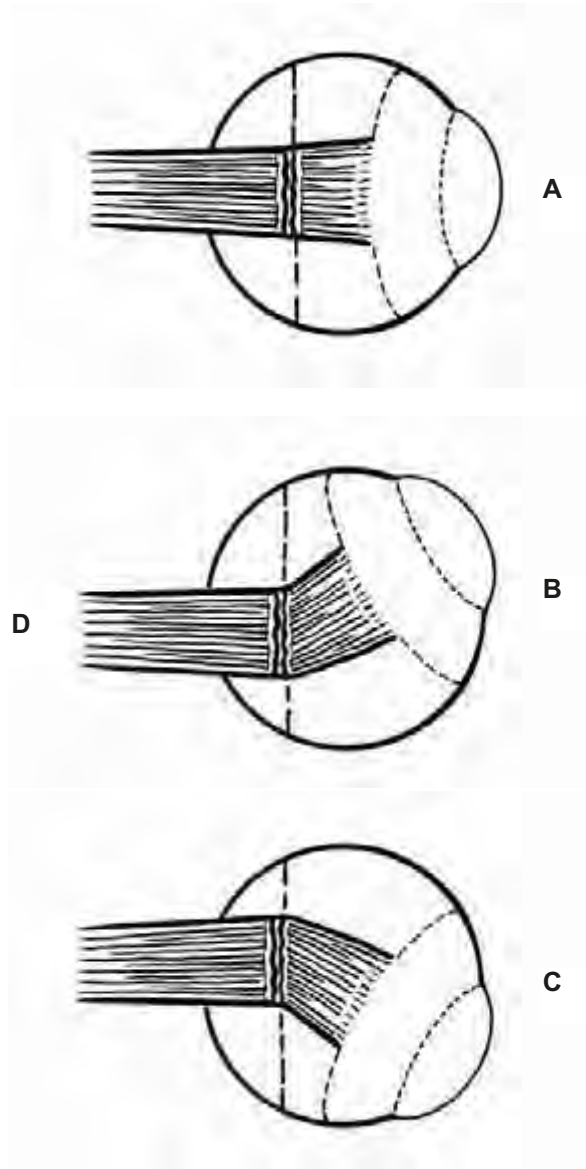


Figure 12
The muscle - tendon anterior to the pulley
A Passes straight in primary position
B Courses upward in upgaze
C Courses downward in downgaze
D The direction of the muscle posterior to the pulley does not change during up and downgaze

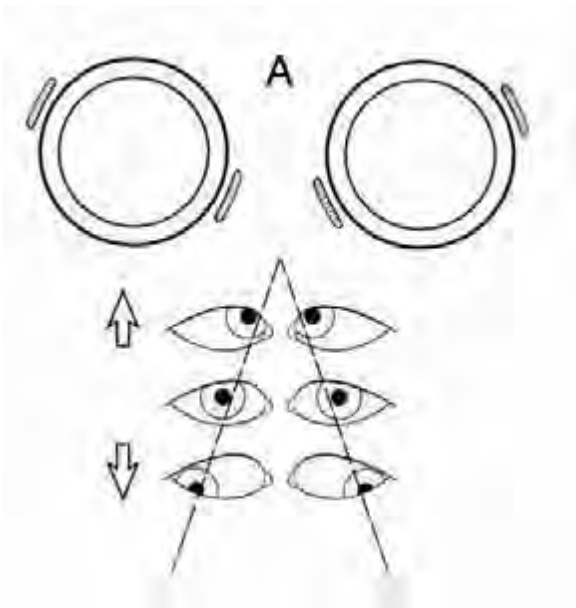


Figure 13
Some combination of:
Upward displacement of the lateral recti
Downward displacement leads to 'A' pattern

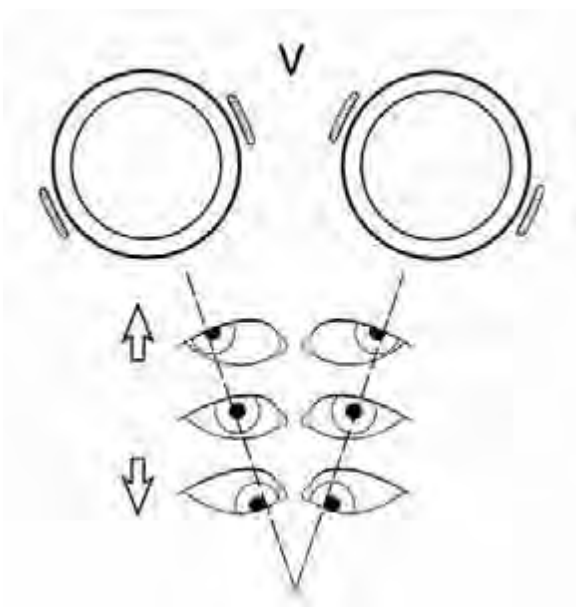


Figure 14
Some combination of:
Downward displacement of the lateral recti
Upward displacement of the medial recti leads to 'V' pattern

'Y' pattern exotropia (pulley instability of the superior rectus, inferior rectus and lateral rectus); incomitant strabismus (abnormal sideslip of rectus extraocular muscle paths in certain gaze positions); and Brown syndrome (downward shift of the lateral rectus pulley in adduction or supraduction).

The strabismus surgeon should be aware of the existence of pulleys and of their significance when undertaking the management of strabismus. Although the surgeon will neither observe nor manipulate these structures except in special cases, they are nonetheless an important factor in establishing a proper diagnosis and in designing the best surgical procedure in many cases. An appreciation of the function of the pulleys contributes to understanding the behavior of the eye movements in the strabismus patient as well as in the normal. Diagnosis, plan for treatment, and assessment of the outcomes of treatment of strabismus are enhanced by knowledge of the extraocular muscle pulleys.

The reasons that the strabismus surgeon is not likely to see the pulleys are several. First, surgery of the extraocular muscles is carried out beneath anterior Tenon's capsule and in the plane of posterior Tenon's capsule. It is done anterior to the origin of anterior Tenon's capsule which itself is just anterior to the location of the pulleys. Second, dissection carried posterior to the origin of anterior Tenon's capsule (where it can be seen fusing with the muscle sheath or posterior Tenon's capsule) will expose extraocular fat, which both complicates surgery and obscures the surrounding anatomy, including the pulleys. Third, although the pulleys are located in the orbital fat just behind the insertion of anterior Tenon's capsule, they are virtually impossible to identify for what they are. This should be obvious since these structures escaped detection for nearly 200 years, in spite of extensive study of the contents of the human orbit carried out by many competent investigators.

Prior to the studies of Demer and associates, the closest anyone could come to identifying these structures was a description of the 'check ligaments' of the horizontal recti, Whitnall's ligament superiorly, the trochlea, and Lockwood's ligament. By asking the right questions and using advanced techniques for imaging and histochemical analysis, along with meticulous dissection and histologic study, Demer and associates accomplished the difficult task of describing newly-recognized anatomy. But, as with so many other discoveries in science, this new revelation came after the earlier work of others which gave hints of what would be. In this case, the observation of Urrets-Zavalía, which called attention to the relationship of palpebral fissure configuration and vertical incomitance, is certainly a precursor to the revelation of pulley displacement. The long known association of 'V' pattern with the pronounced antimon-

goloid fissures of Crouzon and the individuals with true mongoloid fissures who demonstrate an 'A' pattern also provided clues. Limon in Mexico was particularly instrumental in correlating orbital anatomy with a variety of strabismus patterns which were no doubt influenced by the as yet undiscovered pulleys.

Palpebral fissure shape

The palpebral fissure may be level, mongoloid, or antimongoloid, depending on the relative positions of the medial and lateral canthi. If the outer canthus is higher than the inner canthus, a mongoloid palpebral slant exists (Figure 15). If the outer canthus is lower than the inner canthus, an antimongoloid palpebral slant exists (Figure 16). A straight edge held in front of the palpebral fissure connecting the canthi may be used to compare the relative canthal height. The 'normal' relative canthal height depends on race. In whites, the palpebral fissure is usually slightly mongoloid; that is, the lateral canthus is slightly higher than the medial canthus. Careful measurements of the Oriental palpebral fissure indicate less mongoloid slant than would be expected from casual observation. The mongoloid slant illusion in many cases is created by the absence of a skin fold in the upper lid and from a superior epicanthal fold.

The palpebral fissure configuration imparts a characteristic appearance to an individual including, at times, a pseudostrabismus. This assumes clinical significance because it is a common cause for referral for suspected esotropia especially in infants. Vertically incomitant strabismus (A and V patterns) in esotropia seems to follow a pattern related to the slant of the fissures. This pattern was first pointed out by Urrets-Zavalía who noted that in esotropia a mongoloid fissure tends to be associated with an A pattern and an antimongoloid fissure with a V pattern. He found no similar correlation in exodeviations. When examining a strabismus patient who has either a mongoloid or an antimongoloid lid fissure, vertical incomitance should be looked for.

Patients with myelomeningocele demonstrate a consistent abnormality in the configuration of the palpebral fissure (Figure 17). What appears to be a mongoloid slant in reality may be a straightening of the lower lid margin, which gives the illusion of a mongoloid slant. These patients frequently demonstrate an A pattern usually associated with overaction of the superior oblique muscle, and sometimes with dissociated vertical deviation. The diagnosis of myelomeningocele can be suspected in most cases simply by looking at the lid configuration.

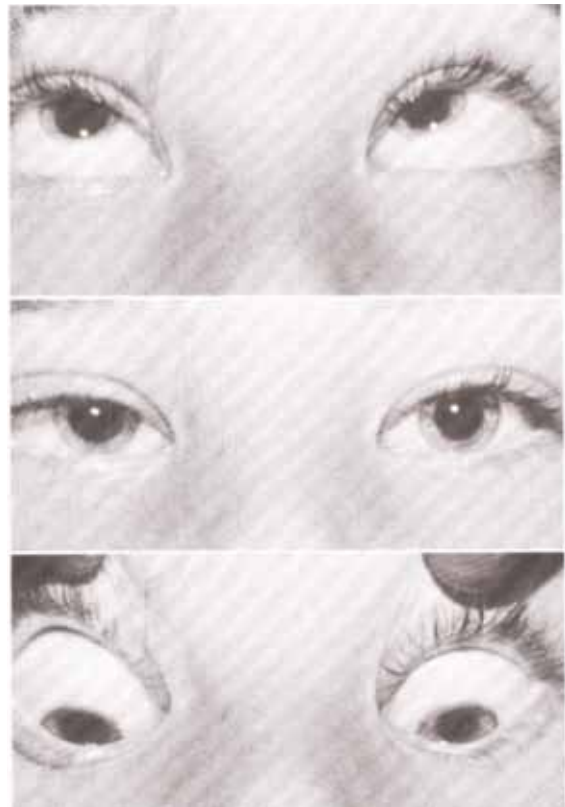


Figure 15

'A' esotropia in a patient with mongoloid palpebral fissures.



Figure 16

'V' esotropia in a patient with antimongoloid palpebral fissures.



Figure 17
A patient with myelomeningocele and a straight lower lid margin simulating a mongoloid slant. This is a common but unexplained finding in such patients.

Epicanthal folds

Epicanthal folds are present to some degree in most infants and children during the first few years of life (Figure 18 A, B). These skin folds can create an illusion of esotropia. Parents think one eye turns in because no 'white' can be seen medially, especially in the adducted eye in lateral versions. Two techniques can be used to relieve parental concern regarding pseudoesotropia from epicanthus. First, the examiner demonstrates the centered pupillary reflexes with a muscle light. Second, the examiner carefully pulls the skin forward over the bridge of the nose to demonstrate the 'straightening' effect of exposing the medial conjunctiva or 'white of the eye' (Figure 19). It is still a good rule for the ophthalmologist presented with an obvious case of pseudostrabismus to carry out a complete eye examination, including cycloplegic refraction and retinal examination. A medial skin fold sweeping upward from below is called epicanthus inversus (Figure 20).

Telecanthus, which is an increased interorbital distance, may be confused with epicanthus (Figure 21). Normally, the intercanthal distance is about one-half the pupillary distance. Intercanthal separation in excess of this suggests true telecanthus, but this diagnosis must be confirmed by radiologic evaluation demonstrating a bony abnormality. Other midline facial abnormalities, especially clefting of a facial structure in the presence of telecanthus, should raise the suspicion of defects at the base of the skull including encephalocele. These patients also may have optic nerve anomalies ranging from hypoplasia to morning glory disk or even may be missing a medial rectus muscle.

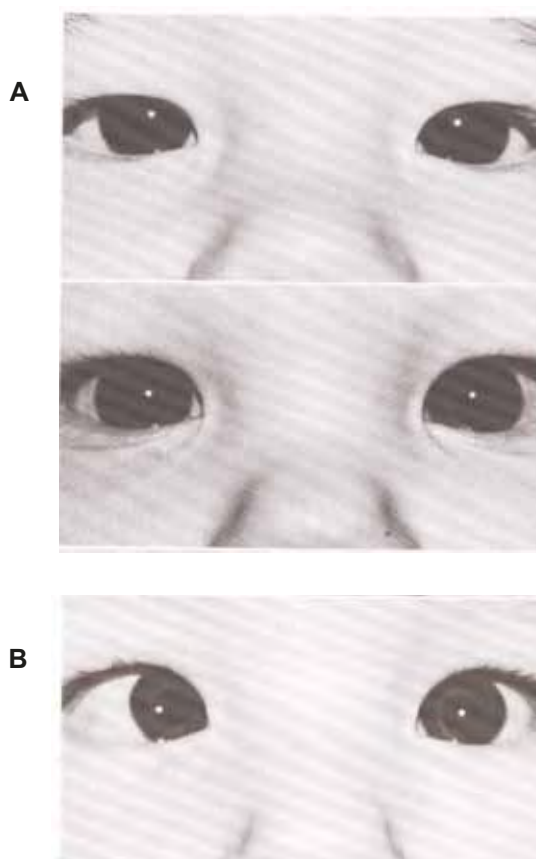


Figure 18
A Epicanthal folds obscure the nasal conjunctiva in both patients, giving the appearance of esotropia. However, the light reflex is centered in the pupil in each case. This reflex indicates the presence of parallel pupillary axes and, therefore, straight eyes or absence of manifest strabismus. Cover testing must be performed eventually to confirm the presence of parallel visual axes because a large angle kappa* could hide a small manifest esodeviation.
B Epicanthal folds are present, but the displaced pupillary reflex in the right eye confirms the presence of a right esotropia.

*Angle kappa is the angle formed by the pupillary axis and the visual axis. A positive angle kappa is present when the visual axis is nasal to the pupillary axis. This simulates exotropia and is common. A negative angle kappa is present when the visual axis is temporal to the pupillary axis. This simulates esotropia and is much less common than positive angle kappa.

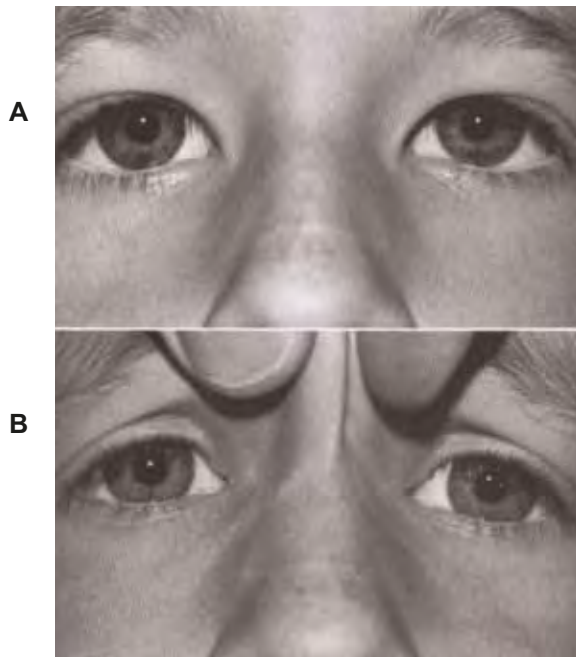


Figure 19

- A** Centered pupillary light reflex
B The 'straightening' effect of exposing more 'white' nasally. (This is shown in an older patient because it is difficult to photograph the younger child where the test is more effective.)



Figure 20

A skin fold originating below and sweeping upward is called epicanthus inversus. This deformity is frequently associated with blepharophimosis and ptosis. These three deformities, which may be combined with telecanthus, cause significant disfigurement and present a formidable therapeutic challenge.

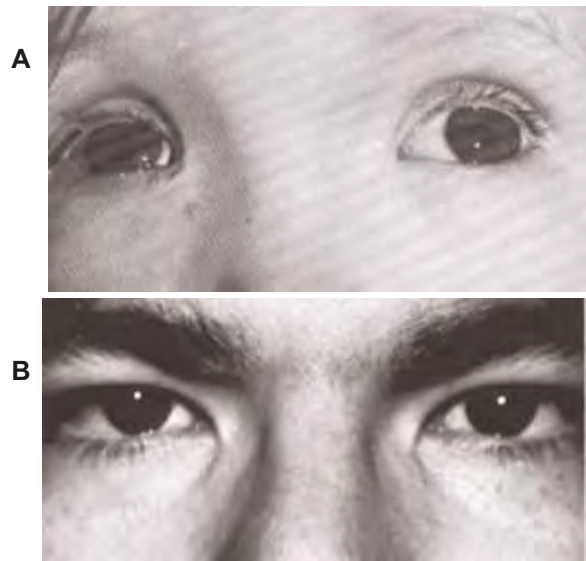


Figure 21

- A** This patient demonstrates telecanthus with an interorbital dimension clearly more than one-half the interpupillary distance and also an exotropia.
B This patient with telecanthus also has prominent epicanthal folds.

Conjunctiva

The bulbar conjunctiva, fused to the underlying anterior Tenon's capsule, loosely covers the anterior part of the globe from the fornices above and below and from the canthi medially and laterally. The bulbar conjunctiva and anterior Tenon's capsule have multiple, fine imbedded arterioles and veins. These are branches of the anterior ciliary circulation and of the marginal arcades of the vessels of the lids. Their number and configuration vary from person to person. This circulation furnishes a small but probably significant blood supply to the anterior segment. The fused conjunctiva and anterior Tenon's capsule attach firmly to the sclera at the limbus (Figure 22). The combined conjunctiva and underlying anterior Tenon's capsule is thick and has substance in infancy and childhood but becomes much thinner and more friable in adulthood and old age.

The plica semilunaris is a fold in the conjunctiva located far medially in the palpebral fissure and is mostly *below* the midline. The caruncle, located just medial to the plica, is about 3 mm in diameter, covered with squamous epithelium, and often contains small hairs (Figure 23). The relationship of the plica and caruncle to each other and to the palpebral fissure is an important cosmetic factor in strabismus surgery. When repairing the conjunctiva, care should be taken not to alter the position of these structures. It is par-

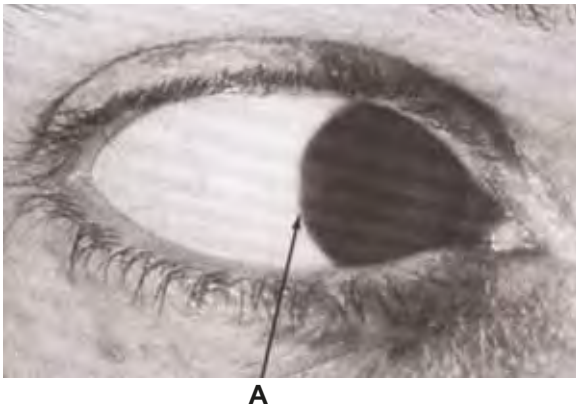


Figure 22
The topographic landmarks of the conjunctiva important to the strabismus surgeon are the following:
A The fusion of the conjunctiva and anterior Tenon's capsule with the sclera at the limbus

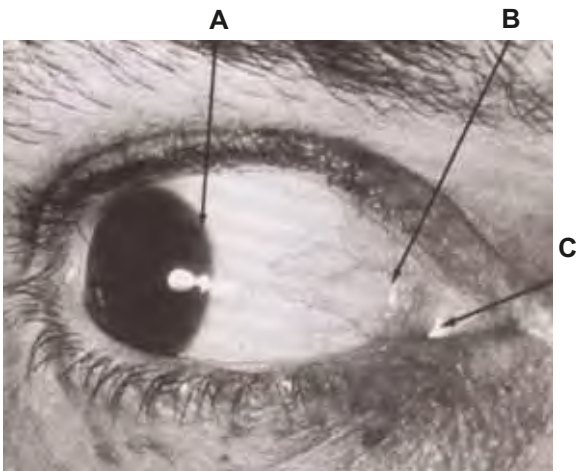


Figure 23
A The limbus
B The plica semilunaris
C The caruncle

ticularly important that the plica not be displaced laterally, making it more obvious as a reddened, unsightly mass seen in the palpebral opening.

A fat pad is present in the inferior fornix extending to within 12 to 14 mm of the limbus (Figure 24). This fat pad is beneath conjunctiva and its posterior condensations behind the orbital septum, and is outside both layers of Tenon's capsule in the extraconal space. A transconjunctival incision made medially and laterally in the inferior cul-de-sac should be posterior to the attachment of posterior Tenon's capsule or at least 8 mm from the limbus in order to expose bare sclera. However, it should also be anterior to the inferior fat pad, no more than approximately 12 mm from the limbus. There is no comparable fat pad superiorly.

During extraocular muscle surgery, all incisions should be limited to the bulbar conjunctiva; they should not extend into the fornix or palpebral conjunctiva. An incision carried too deeply into the fornix causes unnecessary bleeding and serves no purpose. Transconjunctival incision in the palpebral opening over the insertion of the medial or lateral rectus should be avoided, if possible, because it can lead to unsightly scarring, which in extreme cases can even restrict motility.

When prior surgery has left the conjunctiva reddened and unsightly or scarred so that it limits motility, the conjunctiva can be recessed with or without removal of conjunctival tissue. In these cases, the sclera is left uncovered. Sclera is rapidly re-covered with epithelium when it is left exposed, remaining comfortable in the process. It is *not* necessary to use a mucous membrane graft to cover exposed sclera. As long as one of the opposing surfaces behind the lids is covered with epithelium, a symblepharon will not develop.

Tenon's capsule

Tenon's capsule is a structure with definite body and substance in childhood which gradually atrophies in old age but not to the same degree as conjunctiva. Tenon's capsule has an anterior and posterior part. Anterior Tenon's capsule is the vestigial capsulopalpebral head of the rectus muscles. This covers the anterior half to two-thirds of the rectus muscles in their sheaths as well as the intermuscular membrane. Anterior Tenon's capsule is fused with the undersurface of conjunctiva and attaches to sclera at the limbus. The fused conjunctiva-anterior Tenon's capsule is movable over underlying posterior Tenon's capsule and episclera, the latter being the anterior extension of posterior Tenon's capsule. Episclera starts at the level of the insertion of the rectus muscles in a line around the globe, which is called the spiral of Tillaux. Episclera joins conjunctiva and anterior Tenon's capsule, fusing at the limbus.

Posterior Tenon's capsule is made up of the fibrous sheath of the rectus muscles together with the intermuscular membrane. According to Lester Jones, the tissues that make up posterior Tenon's capsule form at a later evolutionary stage than those forming anterior Tenon's capsule. Fibrous attachments between the inner surface of anterior Tenon's capsule and the outer muscle sheath (part of posterior Tenon's capsule) fuse at a point 15 to 20 mm behind the insertion of the medial and lateral rectus muscles to form a barrier to extraconal fat. A condensation of fibrous tissue and smooth muscle between the outer surface of anterior Tenon's capsule and the orbital wall medially and laterally is the location of the aforementioned pulleys of the horizontal rectus muscles. If the horizontal rectus muscle is separated completely from

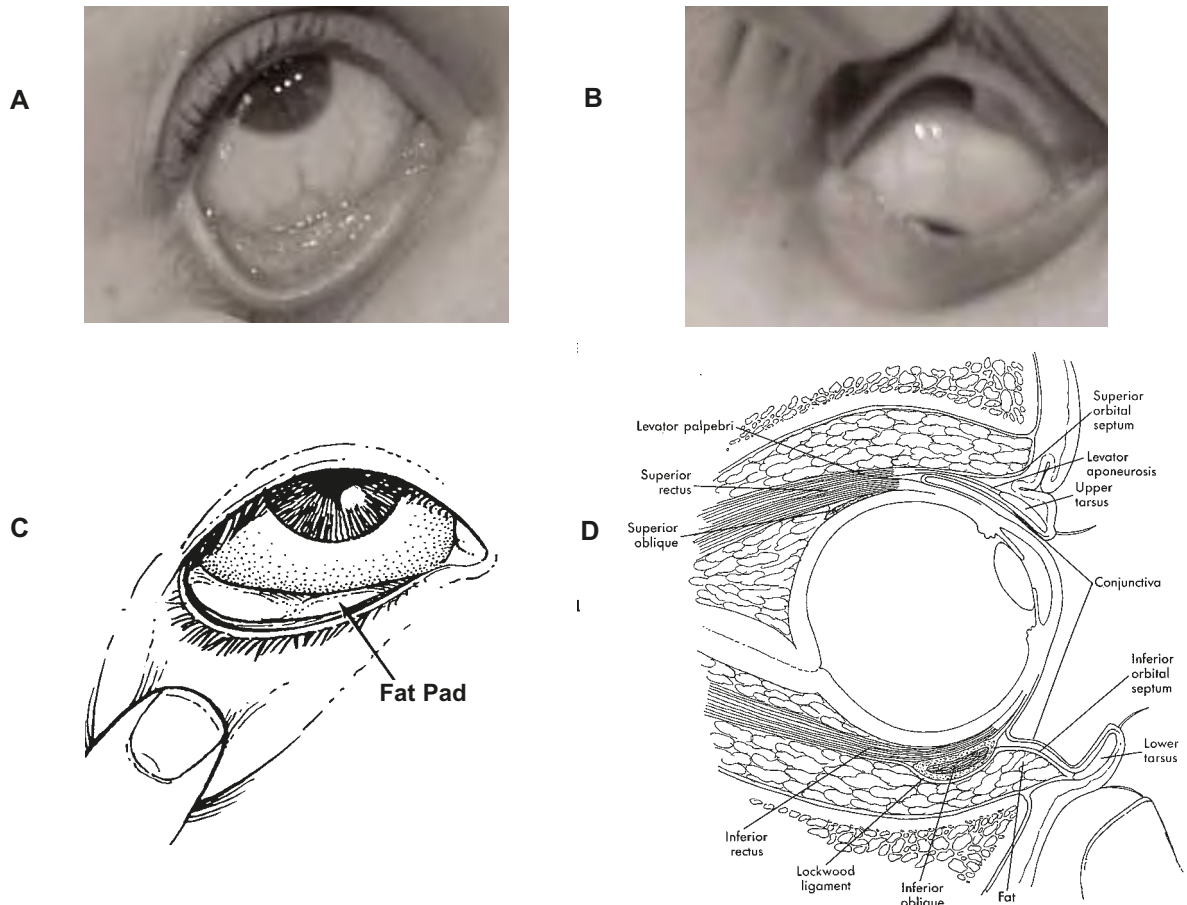


Figure 24

- A** The shallow lower fornix with a visible fat pad beneath conjunctiva
B The deep upper fornix with no visible fat under conjunctiva
C The inferior fat pad shown frontally

- D** Sagittal section of the orbit shows the relationships of the vertical rectus muscles, fat compartments, oblique muscles, orbital septa, and lids. It should be noted that on the superior aspect of the globe, the extraconal fat lies above the levator palpebrae and behind the orbital septum. Surgery on the superior oblique muscle is not associated with extraconal fat because of the barrier of the levator palpebrae muscle. Pulling the lower lid down allows the inferior fat pad to prolapse.

anterior Tenon's capsule, exposing extraconal fat, there will be no or reduced pulley effect on the eye muscle. This will result in up and down 'slip' of the muscle relative to the globe. It is not practical or even logical in the usual strabismus surgery to free pulleys outside anterior Tenon's capsule, but this could be done for special need. Eye muscle surgery is routinely performed entirely *inside* anterior Tenon's capsule with *no* fat exposure (Figure 25 A-C).

Posterior Tenon's capsule, composed of the muscle's capsule and the intermuscular membrane, unites the rectus muscles in a ring around the globe. The extent to which the intermuscular membrane is cut during surgery influences how far the rectus muscles, particularly the medial and to some extent the lateral, will retract during surgery. Dissection of posterior Tenon's capsule far posteriorly leads to exposure of *intraconal* fat, so called because it resides inside the muscle cone. Excessive dissection of anterior Tenon's capsule exposes *extraconal* fat and risks

disruption of the pulleys of the medial and lateral rectus muscles.

While extraocular muscle surgery is performed beneath anterior Tenon's capsule, it is done *within* the plane of posterior Tenon's capsule. The intermuscular membrane part of posterior Tenon's capsule must be fenestrated in order to place a muscle hook behind the insertion of a rectus muscle (Figure 26 A-D). How much more dissection is done in the intermuscular membrane beyond the minimum required to gain access to the muscle is the decision of the surgeon. It is probably wise to do as little cutting of posterior Tenon's capsule as is compatible with the conduct of the surgical procedure intended. Retinal detachment surgery, in contrast to extraocular muscle surgery, is carried out *beneath* posterior Tenon's capsule. This enables a view of the scleral surface far posteriorly to a point near the posterior ciliary vessels and the optic nerve.

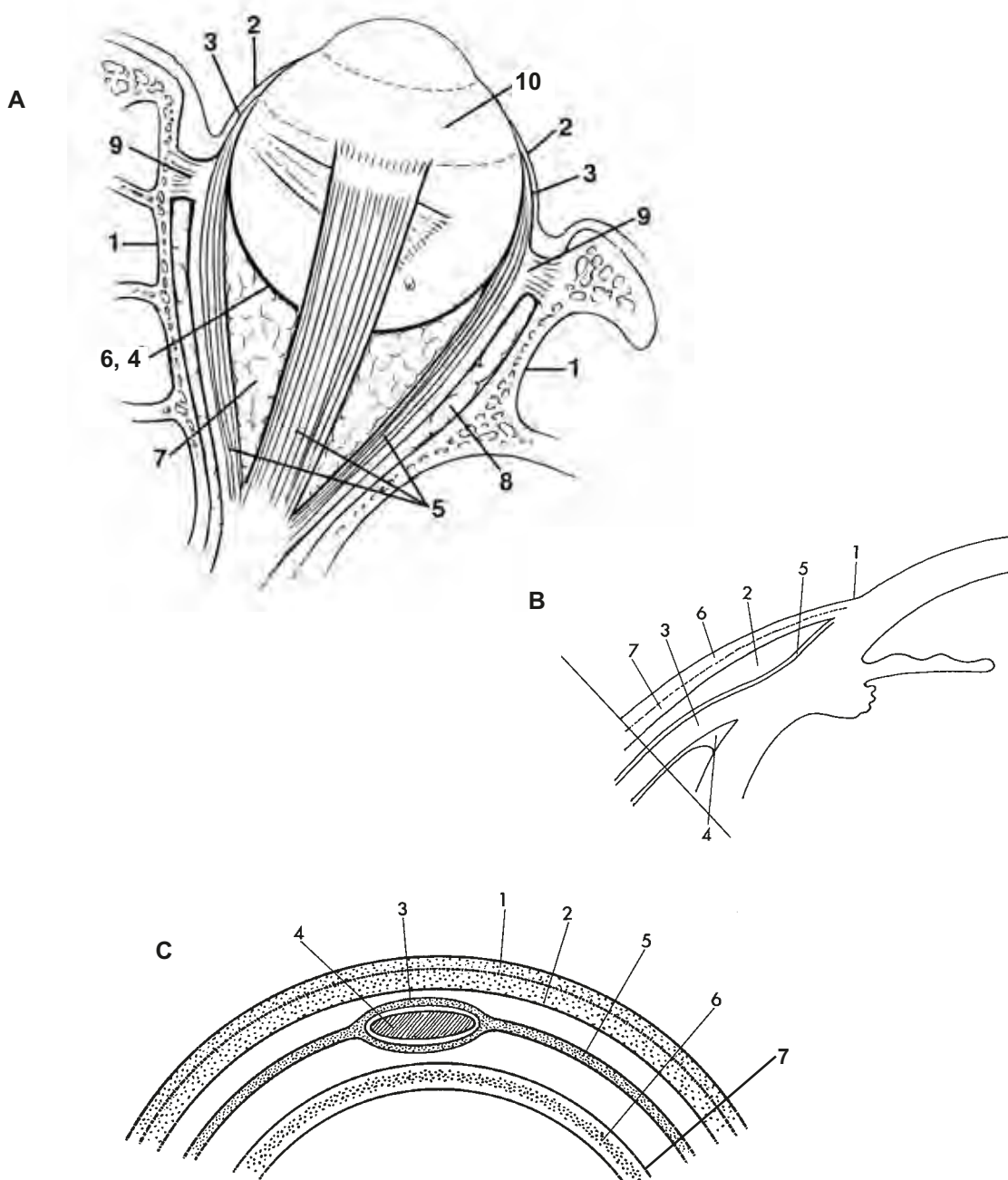


Figure 25 The Conjunctiva/Tenon's Capsule Relationships

A Axial view of the orbit

- 1 Wall of the orbit
- 2 Conjunctiva
- 3 Anterior Tenon's capsule
- 4 Posterior Tenon's capsule
- 5 The muscle
- 6 Intermuscular membrane (posterior Tenon's capsule)
- 7 Intraconal orbital fat
- 8 Extraconal orbital fat
- 9 Horizontal pulley
- 10 Episclera

B

- 1 The limbal fusion of the conjunctiva and anterior Tenon's capsule
- 2 Potential space between anterior Tenon's capsule and episclera
- 3 The muscle in its sheath (posterior Tenon's capsule) inserting into the sclera
- 4 Postinsertional muscle footplates
- 5 Episclera
- 6 Conjunctiva
- 7 Anterior Tenon's capsule

C Coronal section of B at X

- 1 Conjunctiva
- 2 Anterior Tenon's capsule
- 3 Muscle sheath
- 4 Extraocular muscle
- 5 Intermuscular membrane
- 6 Sclera substance
- 7 Sclera surface

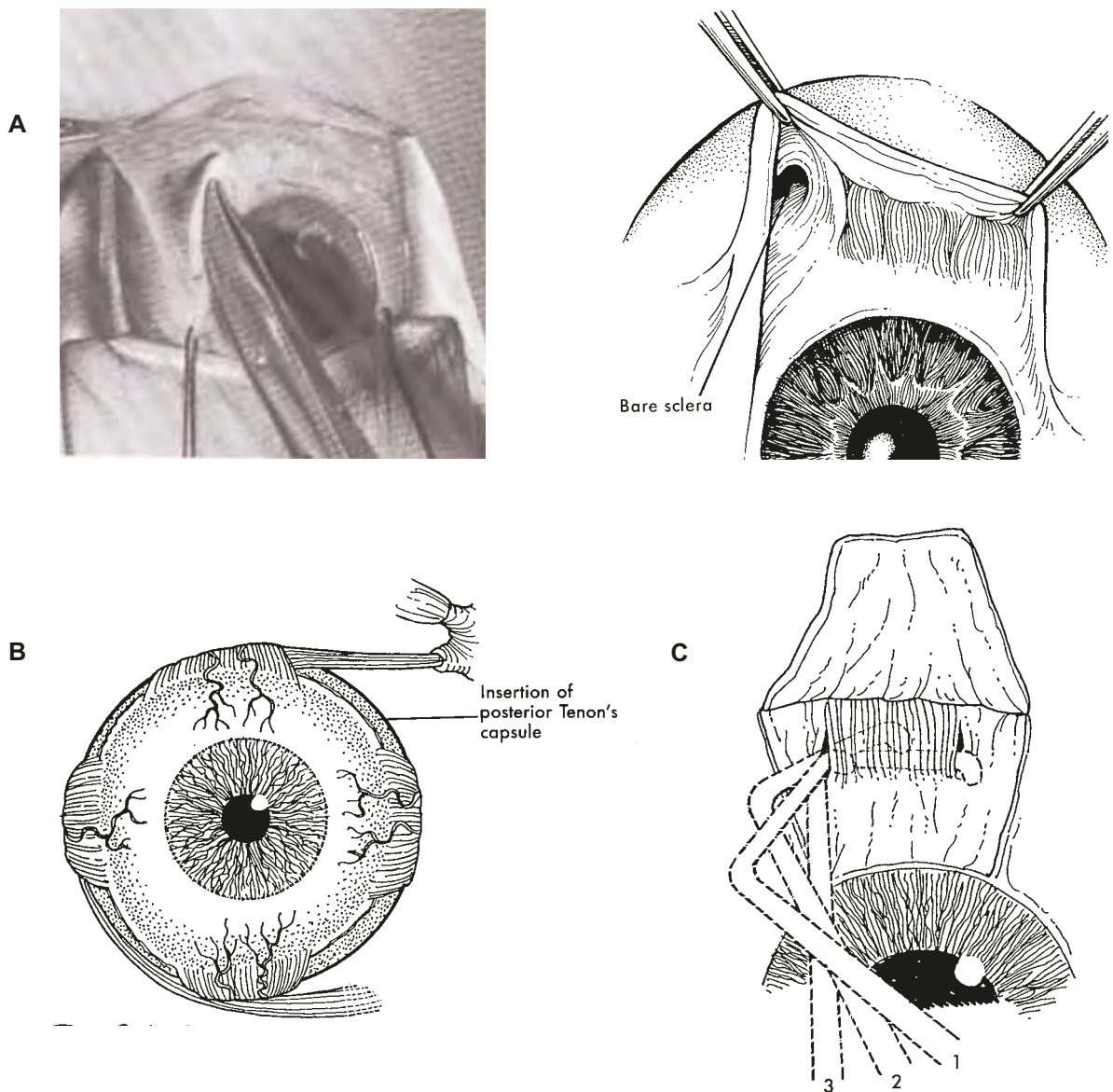


Figure 26

A When the layer of fused conjunctiva-anterior Tenon's capsule is retracted, the muscle insertion in its sheath is exposed. Fibrous attachments are seen between the undersurface of anterior Tenon's capsule and the outer surface of the muscle. The fusion of the intermuscular membrane (posterior Tenon's capsule), as well as of the muscle to the sclera, is apparent. This fusion of the intermuscular membrane to the sclera must be incised before the bare sclera and subposterior Tenon's capsule space can be encountered. Only after entering subposterior Tenon's capsule space can the insertion of the rectus muscle be engaged cleanly on a muscle hook. This is the 'free space' used by the retina surgeon. The tip of the scissors in the photo points to this 'free space.'

B Posterior Tenon's capsule attaches to sclera at the muscle's insertion and in the intermuscular space forming the spiral of Tillaux.

C The muscle hook is placed in a 'hole' created in intermuscular membrane adjacent to the muscle insertion and glides along bare sclera behind the rectus muscle insertion and is exposed at the opposite muscle border with a snip incision.

continued.

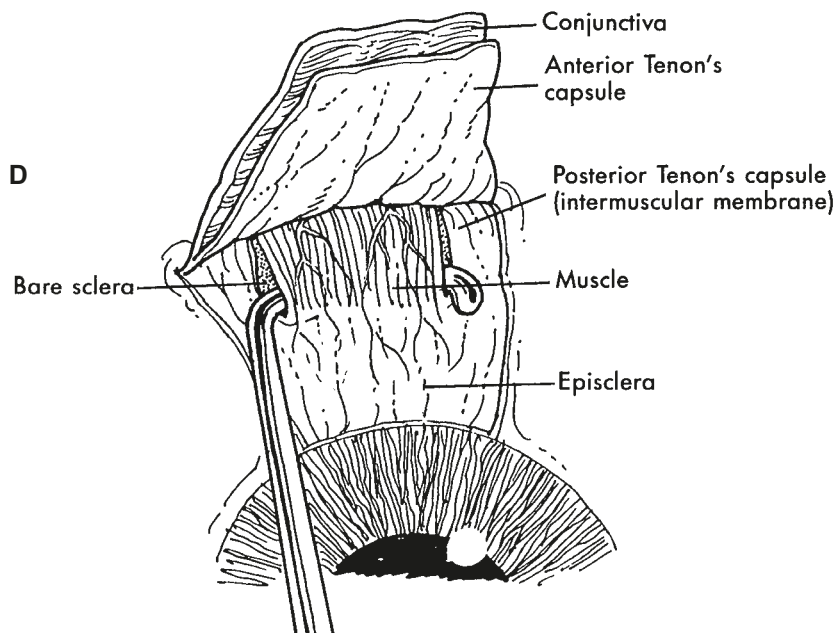


Figure 26, cont'd

D The muscle hook is placed in a 'hole' created in intermuscular membrane adjacent to the muscle insertion and glides along bare sclera behind the rectus muscle insertion and is exposed at the opposite muscle border with a snip incision. With a limbal incision, the multiple layers and surfaces associated with the rectus muscles can be readily seen. Conjunctiva and anterior Tenon's capsule shown here separated are actually fused and separated only with difficulty.

Surgical anatomy of the rectus muscles

Each rectus muscle inserts at a different distance from the limbus. The insertions of these muscles are the prime surgical landmarks in extraocular muscle surgery. The medial rectus is said to insert in the normal eye 5.5 mm from the limbus. This figure presumably was arrived at from study of otherwise normal eyes. Since no specific mention is made of whether the measurements were taken from specimens with strabismus, it is assumed they were not. The average distance between the limbus and the medial rectus insertion of 112 medial rectus muscles in 66 esotropic patients was 4.4 mm with a range of 3.0 to 6.0 mm. Eight patients had unequal medial rectus insertion to limbus measurements. There was no correlation found between the angle of esodeviation and the distance of the medial rectus insertion from the limbus. The variability of this insertion along with its lack of correlation with the angle of esotropia begs the question, "Is the insertion the best landmark for measurement of a medial rectus recession?" Since the answer is obviously no, it is preferable to use the limbus, a more consistent anatomical point, as the reference for recession of the medial rectus muscle. When measuring from the limbus, the amount of

muscle retroplacement from the muscle's actual insertion can be noted by those surgeons accustomed to the 'traditional' medial rectus recession 'numbers' used as guidelines for recession. For example, if a 5.5 mm recession of the medial rectus is done in a patient whose medial rectus inserts 4.5 mm from the limbus (not noticed by the surgeon) and a 5.5 mm recession is done, the new insertion site is located 9.0 mm from the limbus in a normal sized eye. This could result in an undercorrection, and in all likelihood, this occurred not infrequently when 5.5 mm was considered the maximum medial rectus recession. On the other hand, if in this same patient the medial rectus were recessed 10.0 mm from the limbus, the resultant recession measured from the insertion would actually be 6.5 mm, a number perhaps considered too large for the deviation but one which would be required because of the medial rectus insertion site being closer to the limbus.

Use of the limbus as the point of reference for medial rectus recession allows the surgeon to perform *larger* recessions *safely* by not exceeding the landmark of the equator. The equatorial landmark has been shown to be reliable because in patients with

refractive errors between + or - 4.00 diopters, the axial length of the eye is predictable for the age of the patient. This has been confirmed by simple to perform axial length measurement with the A-scan device. At the same time, the corneal dimension is also reliable. If it appears to be other than the normal dimension, this is obvious and measurement for confirmation is simple. Whether or not discovery of the pulleys will alter this thinking is not clear now. It is known, however, that successful realignment of congenital esotropia occurs more frequently when measurement is carried out from the limbus compared to the prior upper limit of recession of 5.5 mm. With larger medial rectus recession measured from the insertion now being done, first surgery alignment in congenital esotropia is improved, but the incidence of overcorrection is not known.

The inferior rectus inserts 6.5 mm from the limbus; the lateral rectus inserts 6.9 mm from the limbus (range: 4.5 to 8.0 mm);* and the superior rectus inserts 7.7 mm from the limbus. Beginning with the medial rectus and moving inferiorly and temporally, each rectus muscle inserts farther from the limbus. The line connecting these insertions is called the spiral of Tillaux (Figure 27). The circumference of the ring formed by closing the spiral is approximately 80 mm. The width of the insertion of each of the rectus muscles is approximately 10 mm. The distance between the adjacent insertion borders is approximately 10 mm (Figure 28).

.....
 The issue can be summed up as follows: *the insertion of the medial rectus muscle in esotropia tends to be closer to the limbus than the 5.5 mm stated for the normal. Therefore, recession measured from the limbus, a more reliable landmark, allows larger recessions to be done safely thus reducing the likelihood of undercorrection.*

The insertion of the rectus muscles can be seen relatively easily through the intact conjunctiva. This means that the muscles' location can be confirmed when the eye is rotated and the conjunctiva is brought tightly over the insertion of any of the rectus muscles. Close observation reveals the line of insertion of the muscle, with the muscle appearing as a slightly darker and faintly raised structure beneath conjunctiva (Figure 29). By confirming the rectus muscle's insertion in this manner, the surgeon can locate each of the rectus muscles accurately in roughly the 3, 6, 9, and 12 o'clock positions of the globe. This maneuver leads to proper traction suture or traction forceps placement and allows strategic placement of the incision through conjunctiva leading to accurate localiza-

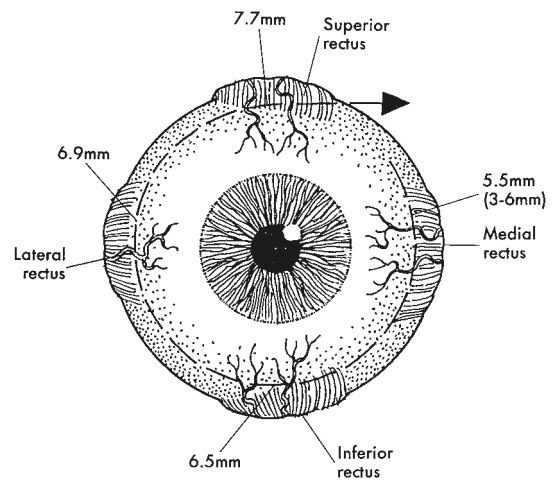


Figure 27
 The spiral of Tillaux and the relationship of the rectus muscle insertions.

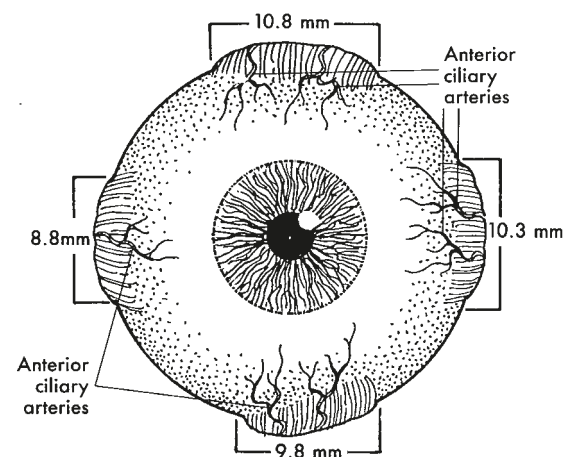


Figure 28
 Width of the rectus muscle insertions

tion of the muscle to be operated upon. This maneuver to establish the location of the rectus muscles should be done routinely at the outset of each eye muscle surgical procedure.

The rectus muscles are all approximately 40 mm long and each receives innervation from the under-surface (intraconal space) at the junction of the middle and posterior thirds of the muscle or 26 mm from the insertion. The six pairs of extraocular muscles are characterized in Table 1.

* Although the lateral rectus insertion site is variable, it is not common to measure from the limbus for recession of this muscle.

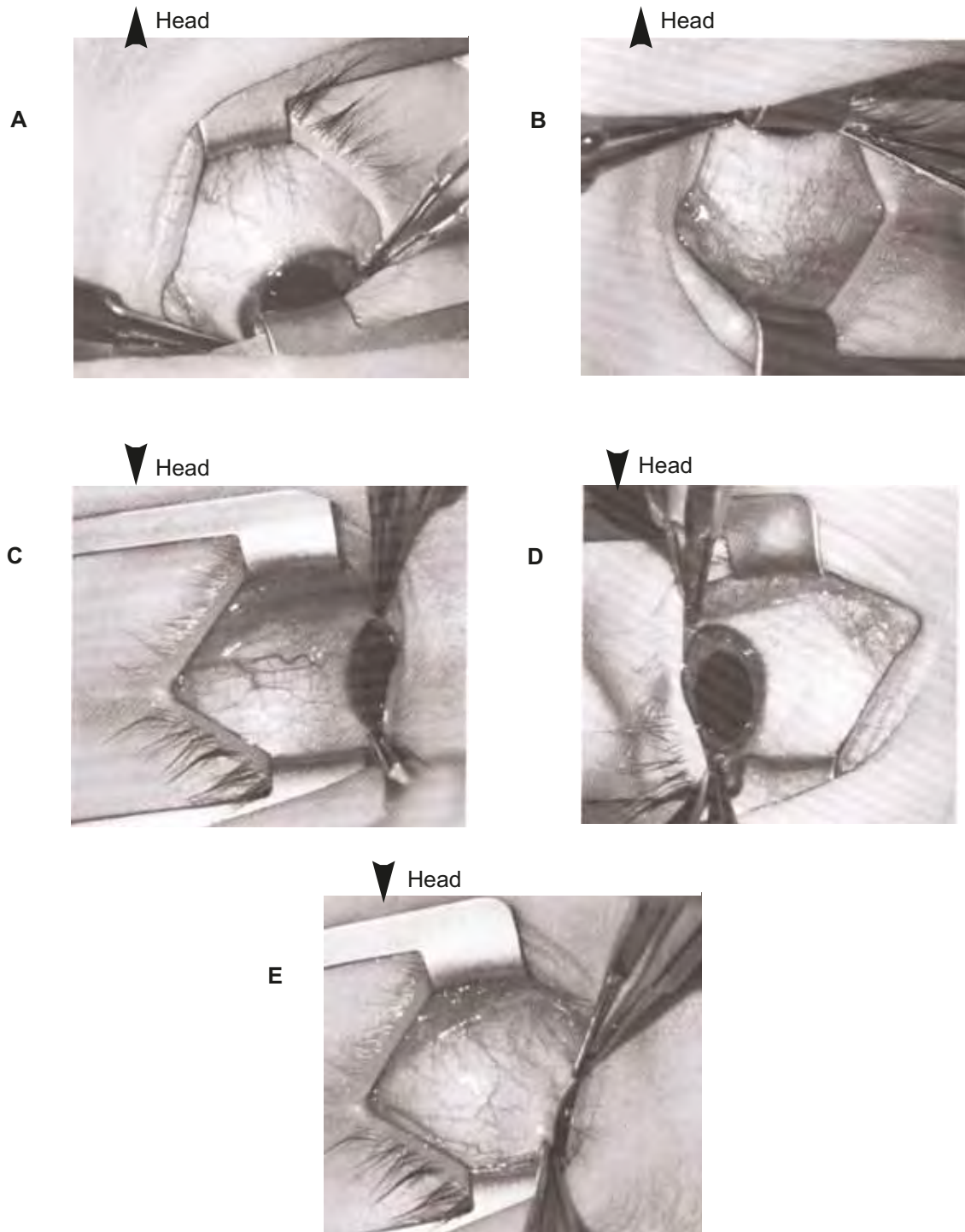


Figure 29

- A** The superior rectus muscle seen through the intact conjunctiva and anterior Tenon's capsule.
- B** The insertion of the inferior rectus muscle seen through the intact conjunctiva. Note fat pad.
- C** The insertion of the lateral rectus muscle seen through the intact conjunctiva.

- D** The insertion of the medial rectus muscle seen through the intact conjunctiva.
- E** The insertion of the lateral and inferior rectus muscles seen through the intact conjunctiva with the inferior temporal orbital fat pad seen just inside the lower lid margin. The site of the incision for inferior oblique exposure is shown. This view is shown from above.

Muscle	Length(mm)	Nerve	Point of Innervation	Tendon* (mm)	Muscle action
Medial rectus (MR)	40	III Inferior division	26 mm from insertion	L: 3.7 W: 10.3	Adduction
Inferior rectus (IR)	40	III Inferior division	26 mm from insertion	L: 5.5 W: 9.8	Depression Excycloduction Adduction
Lateral rectus (LR)	40	VI	26 mm from insertion	L: 8.8 W: 9.2	Abduction
Superior rectus (SR)	40	III Superior division	26 mm from insertion	L: 5.8 W: 10.8	Elevation Incycloduction Adduction
Inferior oblique (IO)	36	III Inferior division	12 mm posterior to insertion of inferior rectus at its lateral border	L: < 1 W: 9.4	Elevation Excycloduction Abduction
Superior oblique (SO)	60	IV	26 mm from trochlea	L: 30 W: 10.7	Depression Incycloduction Abduction

* L - length; W - width at insertion

Table 1 Extraocular Muscles

Characteristics of the extraocular muscles

The extraocular muscles are similar to skeletal muscles though there are differences undoubtedly related to the very specialized function of the extraocular muscles. Both skeletal and extraocular muscles have several types of twitch fibers, but the extraocular muscles are unique, having tonically contracting fibers not found in skeletal muscle. The twitch fibers of extraocular muscles are called Fibrillenstruktur, and the unique slow tonic fibers are called Felderstruktur. There are two muscle fiber layers in the medial and lateral recti. The shorter orbital layer inserts in the muscle pulley, and the longer global fibers insert into sclera at the muscle's *insertion*. The muscle fibers are long, traversing the entire length of the muscle, or in some cases, nearly so. The blood supply of the extraocular muscles is rich, coming from the muscular branches of the ophthalmic artery. The extraocular muscles have the lowest innervation ratio of any of the muscles of the body; that is, they have the *most* nerve fibers per muscle fiber. This is appropriate to meet the stringent requirements of accuracy of fixation and smoothness of following required to support a visual apparatus capable of both rapid, accurate movement and sustained fixation. There is evidence, not always corroborated but accumulating nonetheless, showing that the extraocular muscles participate in proprioception. Muscle spindles and other muscle sensors communicate by means of an *inflow* mechanism which is functional but apparently less powerful than the *outflow* mechanism generated from stimuli arising in the retina.

Motor physiology

Fick's axes - Listing's lane

The theoretical center of rotation of the eye is at the intersection of the three principal axes of Fick (Figure 30). The X-axis crosses the eye horizontally; the Y-axis passes through the center of the pupil (through the 'y' sutures of the lens); and the Z-axis crosses the eye vertically. Vertical movements take place around the X-axis, torsion takes place around the Y-axis, and medial and lateral rotation takes place around the Z-axis. This is a simplistic but useful way to characterize movements of the eye. However, the eye actually moves in Listing's plane, responding to the summation of the actions of all of the extraocular muscles. All of the movements of the globe can be described as taking place in Listing's plane. The new

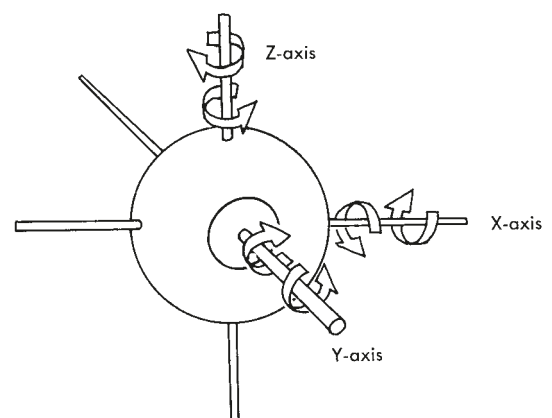


Figure 30

description of the pulleys provides a useful concept for appreciating Listing's plane which appears to coincide with the functional insertion of the rectus muscles at the pulleys (Figure 31).

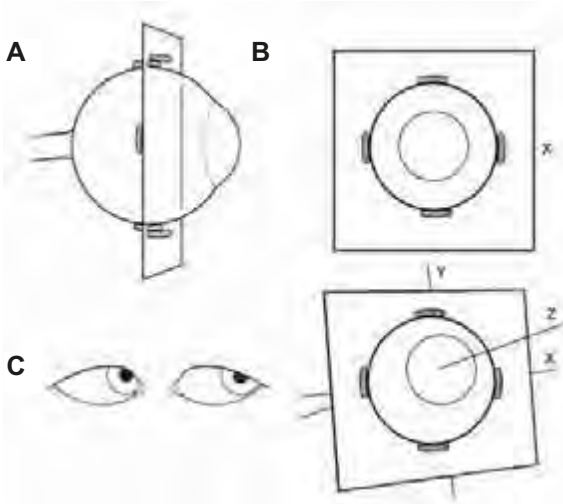


Figure 31

- A** Sagittal representation demonstrates how Listing's plane coincides logically with the pulleys as the functional origin of the rectus muscles.
B Frontal view of Listing's plane
C Looking up to the left, the eyes move in Listing's plane.

Pulleys

The extraocular muscles initiate ocular movement and then sustain a new position of the globe through a complex transfer of energy. The insertion of each extraocular muscle on the globe acts on what we tend to think of as a point-to-point basis. The actual muscle-globe relationship, however, is mediated through a complex arrangement of fascial attachments, including anterior and posterior Tenon's capsule, conjunctiva, and numerous attachments between these structures. Initiation of the globe's movement can only be carried out by the action of the muscles. This movement can be slowed or stopped by the passive fascial structures, including fat that surround the globe and extraocular muscles. Movement of the globe stopped by passive fascial structures is useful physiologically, or harmful in pathologic states. Normal ocular movements are stopped by mechanical factors in the extremes of abduction, adduction, elevation, and depression. These mechanical factors are the check 'ligaments' associated with the pulleys or pulley-like structures that are formed by fascial condensations between anterior Tenon's capsule and the periorbita. In simple terms, the muscles act like a rope passing through a pulley on their way to attaching to the globe. The pull of the muscle on the globe occurs at the point where the muscle attaches to the

globe, the insertion. The pulling effect on the globe comes from the location of the pulley regardless of where the pull is initiated before it reaches the pulley. This new 'post pulley' concept replaces the earlier held notion that the functional insertion of the extraocular muscle was at the point of tangency with the globe, which is anterior to the equator medially and just behind the equator laterally. The new pulley concept seems to be more compatible with the results of strabismus management particularly dealing with 'A' and 'V' patterns in comparison with those previously held (Figure 32).

Muscle forces

The extraocular muscles have a resting tension of 12 to 15 g. This tension increases to 40 to 50 g in the agonist during a saccade. Tension in the antagonist also increases somewhat during a saccade because of the length tension effect and despite decreased innervation. Maximum isometric contraction of an extraocular muscle is approximately 125 g. The tension of the extraocular muscles when the eyes are shifted away from the primary position and then stabilized is greater than the tension in the primary position. When the eye is stabilized in any position; that is, not moving, tension is equal in opposing muscles. When the eyes are in a position away from the primary, static tension must be increased compared to the primary or neutral position. This is to overcome the passive forces of the orbital fascia which must be deflected to maintain position of the eye away from the primary position. When the eye muscles are in the resting state under general anesthesia, the eyes are more or less centered in the palpebral fissure or they may be slightly exotropic. If the eyes are passively moved from this position, they will spring back. This action is the basis for the spring back balance test of Jampolsky. This is a technique for evaluating the balance of purely passive forces in ocular alignment and, therefore, a guide to surgery in cases with mechanical restrictions.

During pursuit movements, both eyes move at the same, usually moderate, speed, and in the same direction: right, left, up, down. While carrying out vergence movements, eye movement is slower and in opposite directions. During convergence (e.g. the right eye moves to the left and the left eye to the right), both eyes are looking toward the nose, so to speak. The opposite takes place during divergence, although pure divergence amplitude is limited and occurs in the normal only when stimulated. When the eyes suddenly change fixation from one object to another, a rapid movement or saccade takes place. The two eyes normally move at the same speed and in the same direction at speeds up to 250 to 400 degrees/sec. This saccadic speed is reduced in a paretic muscle more or less proportional to the degree

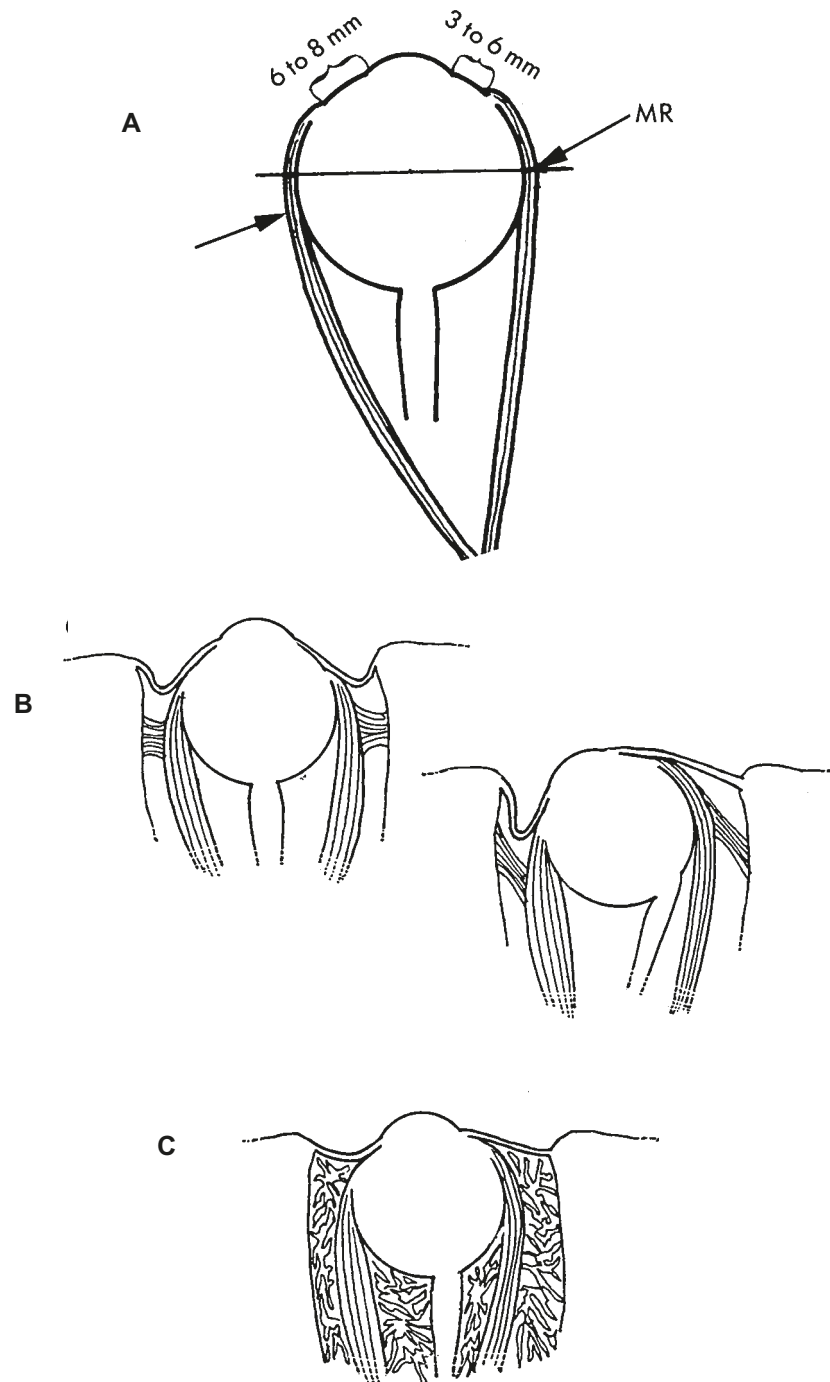


Figure 32

A The medial rectus inserts between 3 and 6 mm from the limbus.
B Pulley tissues also act as check 'ligaments' at extremes of gaze.

C In the pathologic state, restriction in any of the inner fascial structures around the globe may limit passive ductions. In the presence of a normal agonist, these abnormalities usually result in increased intraocular pressure and changes in the palpebral fissure.

of muscle weakness. Reduction of speed of a saccade is a fairly accurate estimate of the extent of weakness of a muscle. The slower a saccade, compared to the normal fellow eye, the weaker the muscle in question. The human extraocular muscle is richly innervated. The ratio of nerve fibers to muscle fibers in the extraocular muscle is 1:5 compared to 1:120 in skeletal muscle in the leg.

Apex of the orbit

The eyes move in the manner of a servomechanism, that is, a given event predictably produces an appropriate response. For example, shift of the object of regard to the temporal retina of the right eye and nasal retina of the left eye produces just enough levoversion to place the object of regard on the foveas. Bitemporal retinal disparity will cause convergence, for example.

The extraocular muscles have their anatomic origin around the ligament of Zinn at the apex of the orbit (Figure 33). This site is also the point of entry of the major nerves and blood vessels supplying the orbit and globe. Knowledge of these structures and their relationships is vital to understanding many pathologic conditions in and around the orbit.

Underaction and ‘overaction’

When eye movements, versions or ductions are evaluated clinically, reference is made to overaction or underaction of a muscle. Underaction of the extraocular muscles can be readily explained due to reduced rotation of the globe. This is from decreased innervation, loss of muscle substance, or because of an altered position of the muscle on the globe. Underaction can also result from tightness or tethering of the passive fascial structures and have no relation to how effectively the muscle can pull. When a normal muscle contracts in the presence of a restriction, a rise in intraocular pressure will result. For example, in cases of thyroid myopathy involving the inferior recti, patients have been treated for glaucoma because of the elevated intraocular pressure which occurred during attempts to look up. Underaction associated with paresis or paralysis of the agonist can be shown by observing a saccade. In this case, the saccadic velocity will be reduced and no increase in intraocular pressure will be noted when movement is attempted in the restricted field. Underaction of the superior oblique can result from a congenitally elongated tendon with a normal saccade. This will be discussed in detail later.

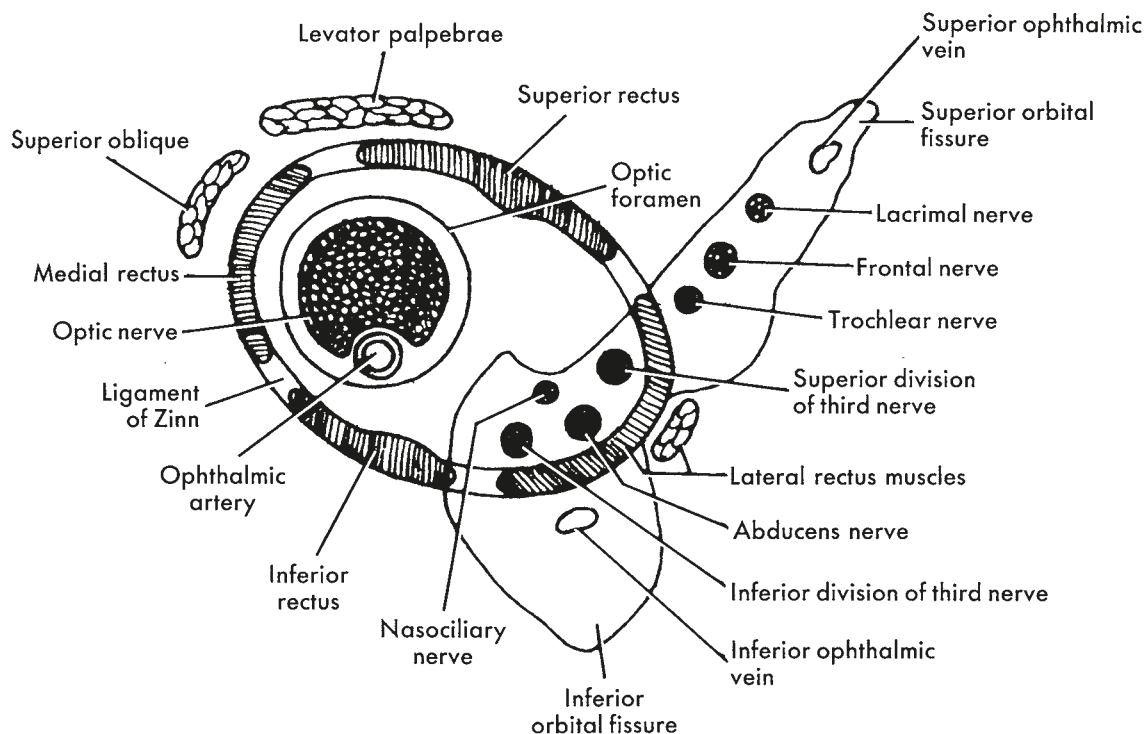


Figure 33

The configuration of structures passing through the optic foramen, superior and inferior orbital fissure, and annular ligament of Zinn of the left eye.

'Overaction' of an extraocular muscle is more accurately described in most cases not as over exuberance of the muscle but as 'underaction' of the passive checking tissue. Observation of clinical strabismus suggests that only cases of excess innervation such as occurs in the yoke muscle of a paretic muscle can legitimately be called overaction. In spite of the obvious misnomer, the term 'overaction' is firmly implanted in the literature and the language of the strabismologist.

Surgical anatomy of the inferior oblique

The inferior oblique muscle is 36 mm long. It originates a few millimeters behind the medial end of the inferior orbital rim just lateral to the lacrimal fossa and proceeds posteriorly and temporally at an angle of 51 degrees with the frontal plane passing beneath the inferior rectus (between the inferior rectus and the floor of the orbit) (Figure 34). It inserts beneath the inferior border of the lateral rectus muscle, approximately 12 mm from the insertion of the lateral rectus. The posterior extent of the inferior oblique insertion overlies a point 2 mm below and 2 mm lateral to the macula. The middle of the distal half of the muscle covers the inferior temporal vortex vein. The blood vessels in the inferior oblique do not contribute to the blood supply of the anterior segment of the globe. This muscle receives its innervation on its upper surface at the point where it passes beneath the lateral border of the inferior rectus, approximately 12 mm posterior to the lateral corner of the insertion of the inferior rectus. The inferior oblique muscle is unique in its anatomic relationships. This muscle behaves as though it has two potential insertions and two potential points of origin. Because the inferior oblique is innervated near its middle, it may be weakened either proximal or distal to its point of innervation.

The inferior oblique muscle was subjected to surgery as early as 1841, but for myopia! By 1885, inferior oblique weakening for treatment of superior oblique palsy was done. The muscle was exposed through a skin incision and the muscle was cut medial to Lockwood's ligament. This technique persisted into the middle of the twentieth century. After that, more attention was directed to weakening the muscle distal to Lockwood's ligament nearer the insertion. Currently the most effective techniques for inferior oblique weakening include myotomy, myectomy, and recession, placing the new insertion at various positions in the inferior temporal quadrant according to the surgeon's preference. Surgical techniques for inferior oblique weakening also vary in the extent to which the inferior oblique is freed from its union with Lockwood's ligament and in the management of the neuro-vascular bundle.

In order to avoid surgery on the inferior oblique in some cases of overaction, Bielschowsky was said to have lowered the medial rectus. This portended treatment of 'A' and 'V' pattern with vertical shift of the rectus muscles and possibly the description of the pulleys of the rectus muscles whose anomalous location leads to vertical incomitance.

Recently, inferior oblique anterior transposition has been used for the treatment of inferior oblique 'overaction' especially when it is associated with dissociated vertical deviation (DVD). The mechanism of action for this treatment of DVD has been explained by Stager who demonstrated that the robust neurovascular bundle of the inferior oblique is effective in anchoring the transposed inferior oblique insertion. This is the same neurovascular bundle that was cut by Parks during the denervation and extirpation procedure for maximum *weakening* of the inferior oblique.

Myectomy or large recession of the inferior oblique distal to the muscle's attachment at

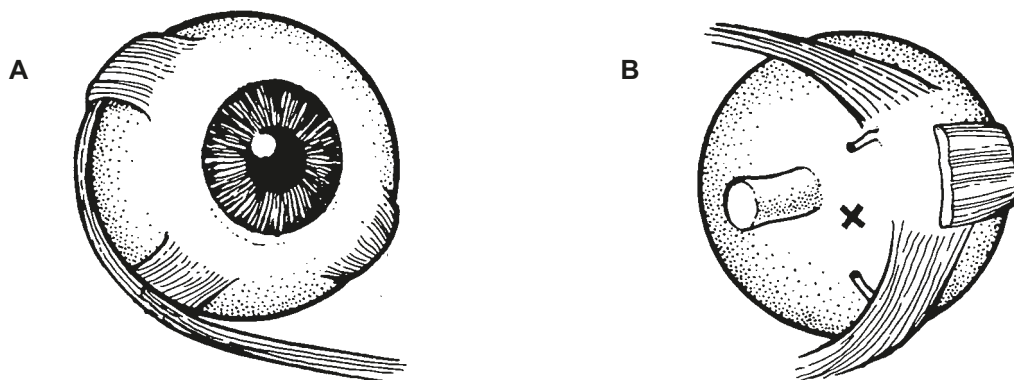


Figure 34
The inferior oblique (A) from in front and (B) from behind.

Lockwood's ligament makes this attachment equivalent to the new functional insertion (Figure 35). Although not done now, earlier procedures for weakening the inferior oblique, which were carried out nasal to the ligament of Lockwood, meant that the inferior oblique union with Lockwood's ligament became the functional origin. A procedure described by Stager and Weakley transected the inferior rectus on both sides of Lockwood's ligament relying on a small segment of the middle of the muscle stabilized by Lockwood's and the neurovascular bundle. In cases of 'extirpation and denervation' of the inferior oblique, a large myectomy of the distal inferior oblique is combined with transection of the neurovascular bundle.

The inferior oblique is unique among the extraocular muscles in that, in many cases, weakening of this muscle, even by extensive surgery, seems to have relatively little effect on movement of the globe or alignment of the eyes. Even after large recession or myectomy, apparent overaction of the inferior oblique can persist. This is probably due to horizontal rectus action from upward pulley displacement of the medial rectus. Also, in the relatively uncommon inferior oblique palsy, strabismus is much less than would occur after palsy of any of the other muscles. Effective weakening of this muscle could be made more difficult because of the unique anatomy. Likewise neurologically, the muscle's innervation by the inferior branch of cranial nerve III makes isolated paralysis rare. In contrast, the inferior oblique seems to 'overact' commonly. But is 'overaction' the right term? Some think it is not, suggesting that the preferred term would simply describe appearance not etiology. The term "elevation in adduction," which replaces the Latin "strabismus sursoadductorius," seems to be a valid description of what has been called 'overaction' of the inferior

oblique. The descriptive term 'elevation in adduction' describes a condition where the inferior oblique is responsible for elevation, not necessarily from its overacting but rather from the lack of checking from a weak (or absent) superior oblique. In defense of the term 'overaction' of the inferior oblique, this term also describes the extorsion and abduction caused by the inferior oblique in cases of anomalous orbital anatomy and/or upshift of the medial rectus pulleys and in cases of deficient adduction.

Lockwood's ligament

Lockwood's ligament may be compared to a hammock supporting the globe (Figure 36). It forms a dense condensation of tissue that engulfs the inferior rectus and inferior oblique muscles beneath the globe. The attachment of Lockwood's ligament to the inferior oblique affects globe movement from the inferior oblique muscle when it contracts, even when the inferior oblique is transected on both sides of Lockwood's!

Attachments between Lockwood's ligament and neighboring muscle and fascial structures are connected to the lower lid. This makes lower lid ptosis a potential complication of inferior rectus recession (Figure 37). To avoid this, the inferior rectus should be freed extensively during surgery. Guyton, et. al., have recommended that Lockwood's ligament be advanced when recession of the inferior rectus muscle is carried out. When resection of the inferior rectus is performed, persistent attachment of this muscle to Lockwood's ligament can cause just the opposite, a bothersome and cosmetically unacceptable elevation of the lower lid resulting in narrowing of the palpebral fissure. Freeing the inferior rectus muscle from Lockwood's ligament also helps avoid this complication.

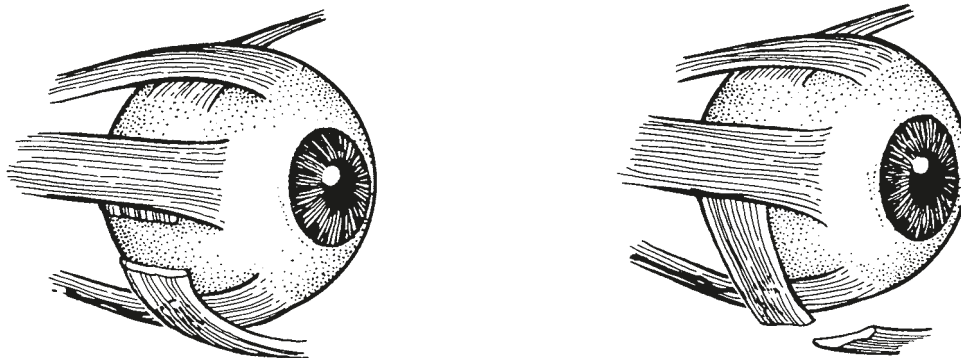


Figure 35

The inferior oblique behaves as if it had two potential origins and two potential insertions because of its union with Lockwood's ligament as it passes beneath the inferior rectus. In addition, at the mid-section of the inferior oblique is a stout neurovascular bundle, described in detail by Stager and associates, which acts both as a restraining anchor and a source of innervation.

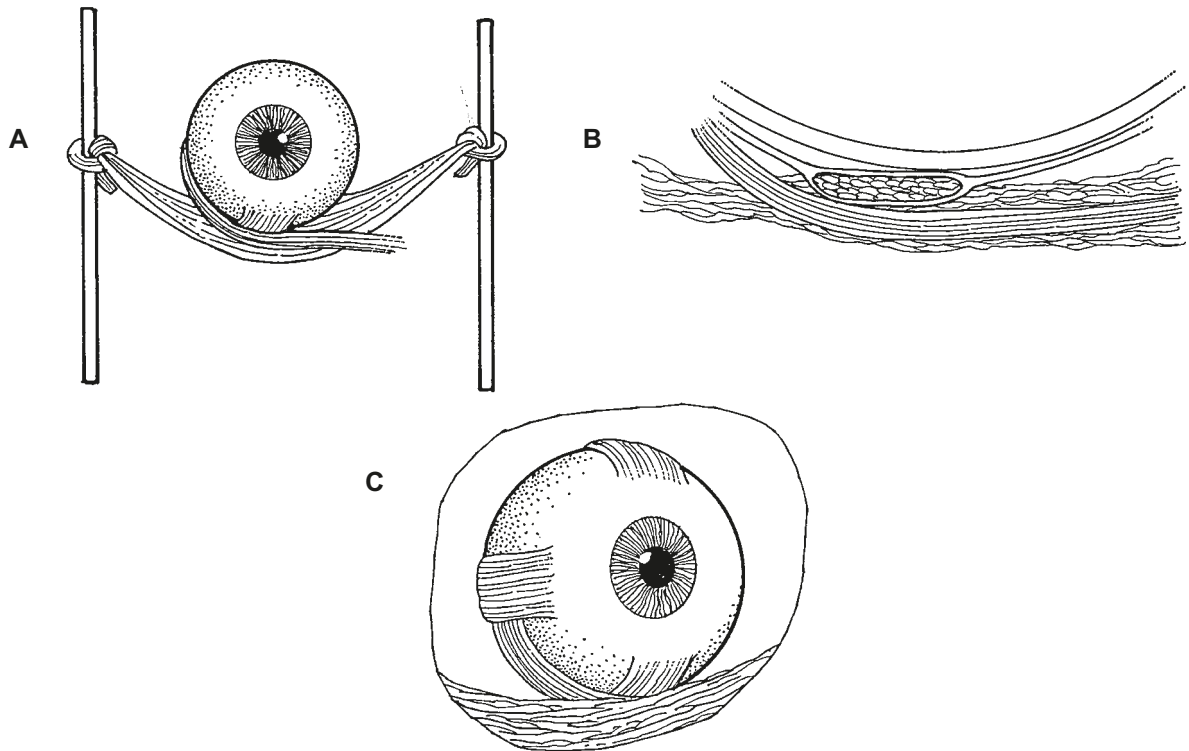


Figure 36

- A** The ligament of Lockwood could be compared to a hammock supporting the globe.
- B** The inferior oblique passes beneath the inferior rectus, through Lockwood's ligament and orbital fat approximately 12 - 14 mm from the limbus.
- C** The inferior fat pad is prominent and should not be disturbed during surgery of the inferior rectus.

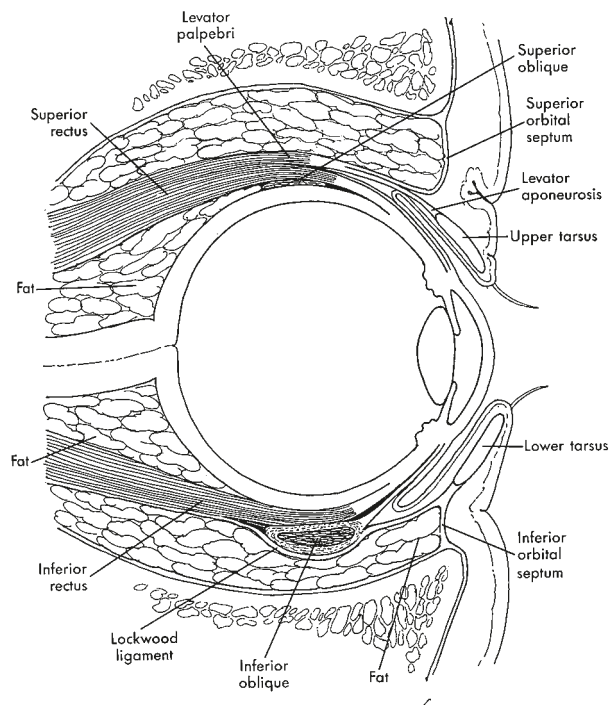


Figure 37

A sagittal section of the complex anatomy of the orbit shows the intimate relationship of the inferior rectus, inferior oblique, and Lockwood's ligament. This complex, in turn, is connected to the lower lid tarsus and inferior orbital septum. The inferior extraconal fat protrudes farther forward compared to the extraconal fat of the superior globe. Recession of the inferior rectus causes recession of the lower lid and widening of the fissure. Advancement or resection of the inferior rectus causes narrowing of the palpebral fissure. Placement of the conjunctival incision too far from the limbus inferiorly can result in disturbance of the extraconal fat compartment.

Superior oblique

The superior oblique muscle has a muscular portion and a tendinous portion, both of which are approximately 30 mm long. The muscle portion originates superiorly and nasal to the ligament of Zinn at the apex of the orbit and becomes tendinous 10 mm before reaching the trochlea. The trochlea, a cartilaginous saddle-shaped structure, is located at the junction of the medial and superior orbital rim just posterior to the orbital rim. The trochlea acts as a pulley redirecting the course of the superior oblique tendon. approximately 54 degrees from the frontal plane. The tendon passes beneath the superior rectus, inserting under the lateral border of the superior rectus usually 5-7 mm posterior to the temporal superior rectus insertion or approximately 13 mm from the limbus (Figure 38). That portion of the superior oblique tendon passing beneath the superior rectus muscle is attached to the undersurface of this muscle through the common sheath of the superior rectus muscle. Therefore, to obtain an effective large recession of the superior rectus muscle, it is logical to free it from the superior oblique tendon. A hang loose superior rectus recession which is not secured at the intended reinsertion site may not accomplish the intended retroplacement of the superior rectus muscle unless the superior oblique - superior rectus attachment is freed.

The diameter of the superior oblique tendon between the trochlea and the medial border of the superior rectus is about 3 mm. The tendon is white, surrounded by dense fascia, and lacking a discreet tendon sheath. Because of this fascia, the superior oblique tendon nasal to the superior rectus can be somewhat difficult to identify when approached outside of anterior Tenon's capsule. However, when approached from the undersurface of anterior Tenon's capsule, the superior oblique tendon is an easily distinguishable structure (Figure 39). The nerve to the superior oblique enters the muscular portion 26 mm posterior to the trochlea. Blood vessels in the superior oblique do not contribute to the blood supply of the anterior segment of the globe.

The insertion of the superior oblique is broad, measuring on average 10.7 mm. The fibers at this point are very thin and fuse with sclera in a manner that makes the superior oblique insertion difficult to distinguish from sclera. Only after carefully looking in the area where the superior oblique should insert can these fibers be seen coursing temporally and slightly posterior. At times the surgeon must employ a fine hook to carefully 'tease' the insertion into view. The insertion of the superior oblique has been shown to be the most variable of any of the extraocular muscles. While the tendon usually inserts at the lateral border of the superior rectus muscle about 5 to 7 mm behind the superior rectus insertion, the superior oblique tendon can be found more anterior. In other

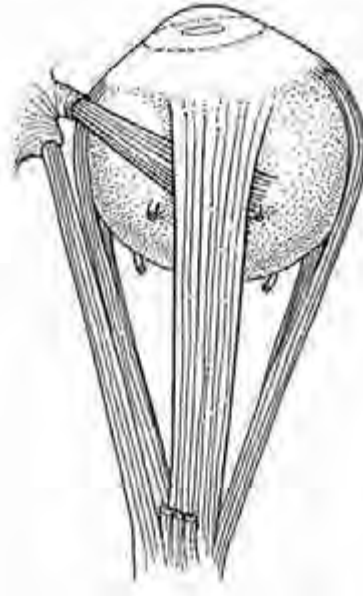


Figure 38

The superior oblique tendon is redirected to 54 from the frontal plane and passes posteriorly and temporally beneath the superior rectus.

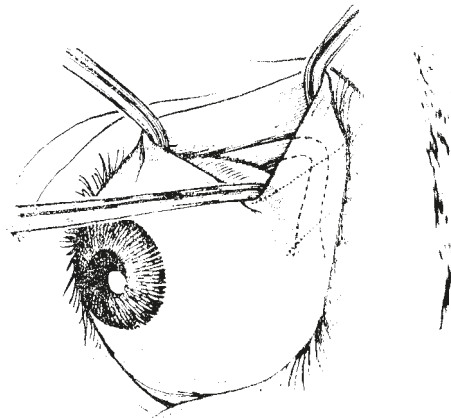


Figure 39

From Parks MM, Helveston EM. Direct visualization of the superior oblique tendon. Archives of Ophthalmology, 1970, 84:491-494. Used with permission.

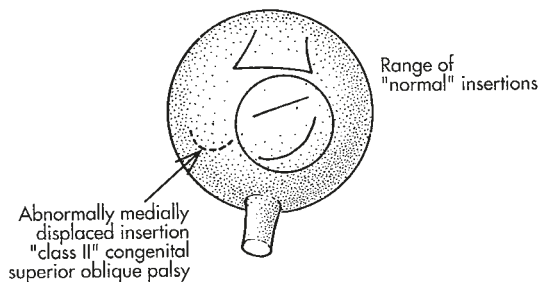


Figure 40

The 'normal' insertion of the superior oblique varies. The insertion displaced medial to the superior rectus results in underaction.

cases, the superior oblique can be found inserting at the medial border of the superior rectus. This results in superior oblique 'underaction' with exocyclotropia because this nasal displacement reduces the torsional effect of the superior oblique. A wide range of other anomalies is seen with the superior oblique tendon from laxity causing congenital superior oblique 'palsy' to absence of the reflected tendon. This spectrum of anomalies suggests a new way of classifying congenital superior oblique palsy (see page 157).

The superior oblique tendon joins with the undersurface of the superior rectus muscle by a common muscle-tendon capsular attachment. This attachment can be seen clearly when the superior rectus muscle has been detached from the globe and lifted upward (Figure 41). The firmness of this attachment varies, but these two structures do not appear to be entirely free of any connection to each other in the normal state. As stated above, if recession of the superior rectus is attempted without securing the superior rectus at the intended site of reattachment to

the sclera, as in 'hang-loose' recession, an unpredictable result may occur simply on the basis of the anatomy. The union of the superior oblique tendon and superior rectus could pull the superior rectus forward toward the limbus as the eye rotates from depression to the primary position (Figure 42). Therefore, the hang-loose recession of the superior rectus muscle used in cases of dissociated vertical deviation lacks a sound anatomic basis.

In order to recess the superior rectus more than 5 or 6 mm with a 'hang-loose,' the superior rectus should be freed from the superior oblique. For a recession as great as 10 mm as some claim with the 'hang-loose,' the superior rectus insertion must be *behind* the path of the superior oblique. Prieto Diaz demonstrated with x-ray a 15 mm recession of the superior rectus from the limbus in down gaze after 'hang-loose' of the superior rectus. Would this recession be as large with the eye in primary position?

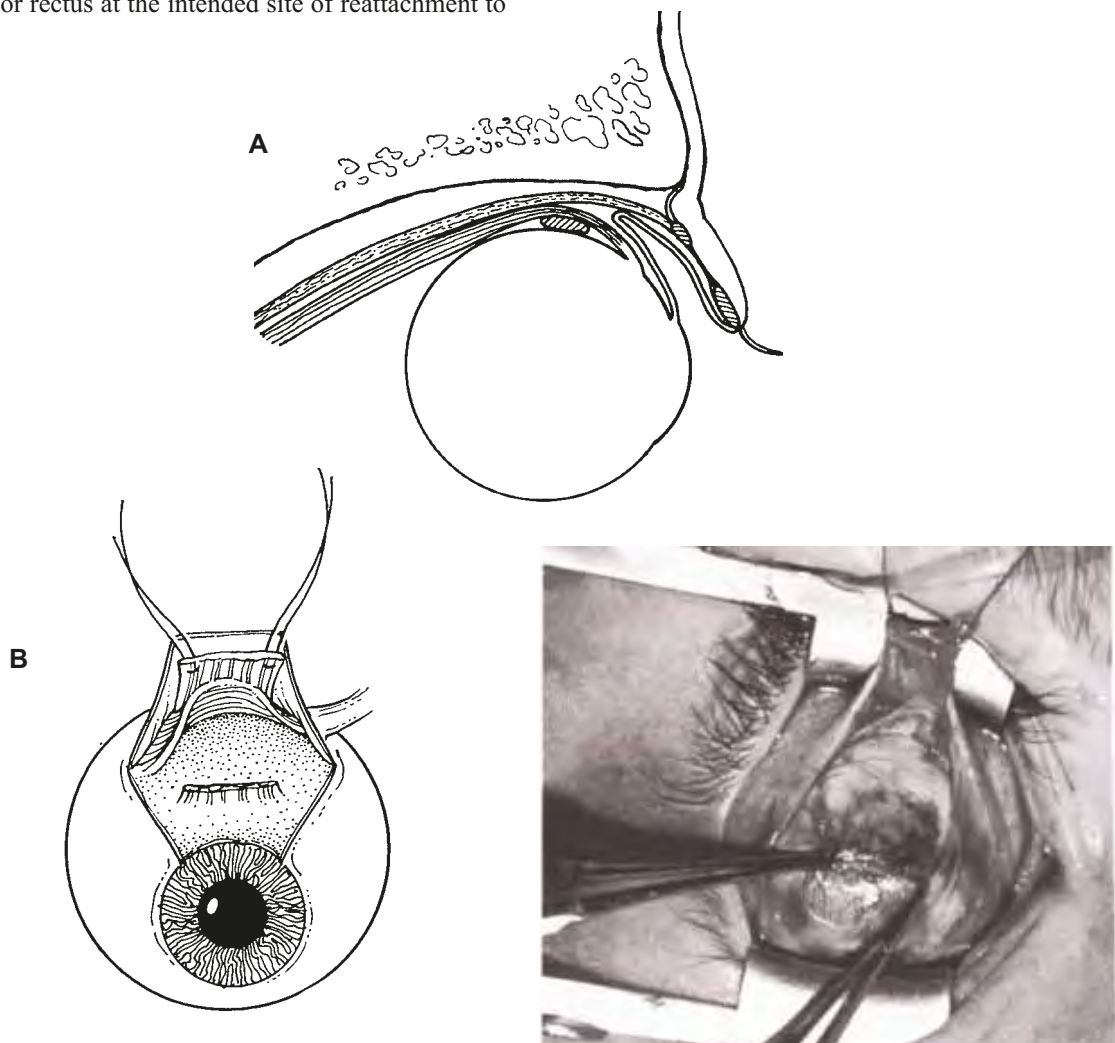


Figure 41

A The superior oblique passes beneath the superior rectus

B The superior oblique remains attached to the superior rectus when the rectus is detached and pulled up.

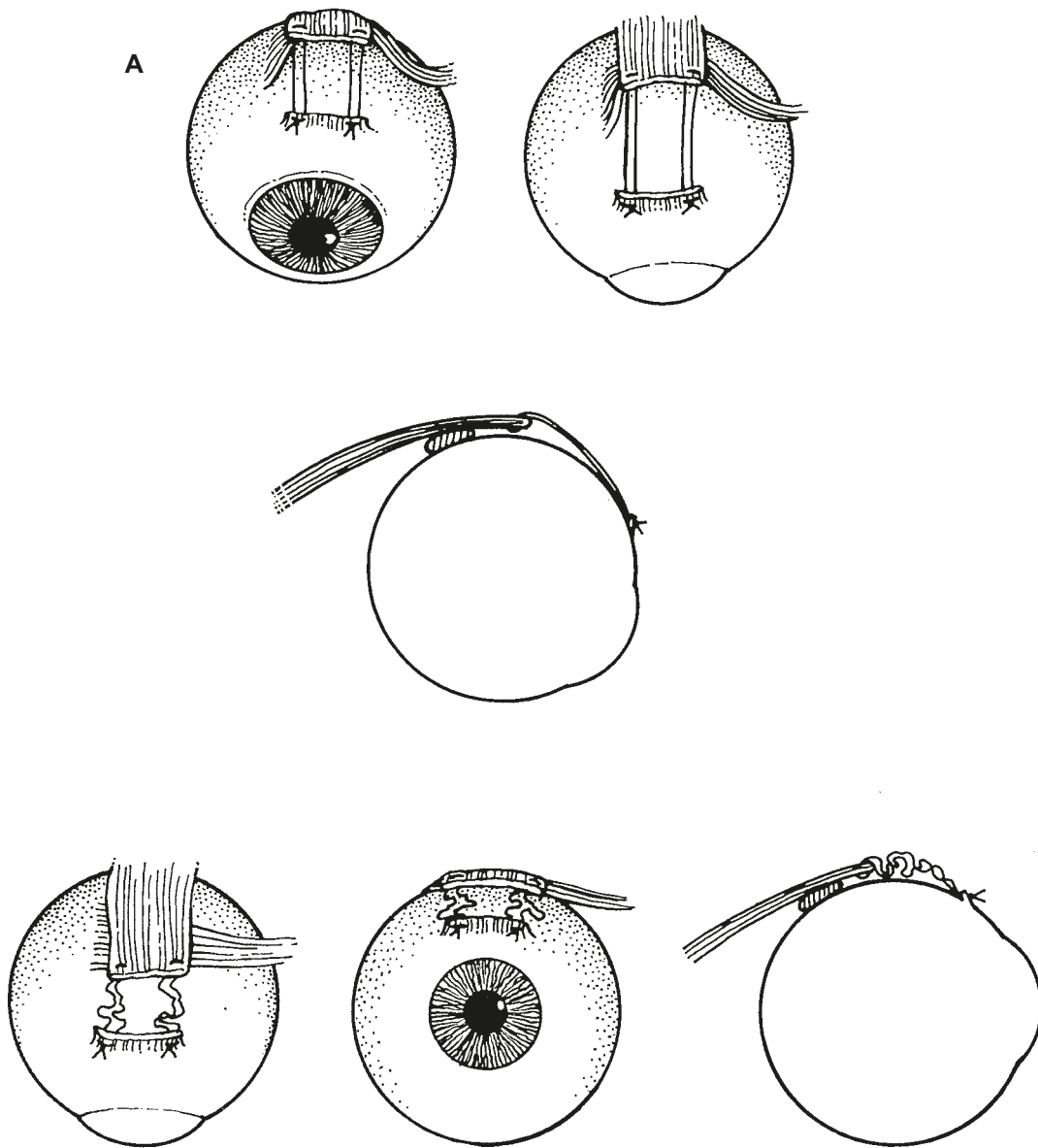


Figure 42

A When the eye is rotated downward, the superior rectus is the intended distance in a very large 'hang loose' recession even if the superior oblique tendon - superior rectus union is intact.

B When the eye returns to the primary position, the superior rectus could be pulled forward, reducing the amount of recession.

Whitnall's ligament

Whitnall's (superior transverse) ligament and the superior oblique tendon in the trochlea have common fascial attachments at the orbital rim (Figure 43). If the superior transverse ligament is weakened inadvertently while hooking the superior oblique tendon, thereby weakening the medial horn of the levator muscle, ptosis of the nasal portion of the upper lid

usually results. Therefore, it is safer to hook the superior oblique tendon under direct vision. This can be done between the nasal border of the superior rectus and the trochlea or an even safer place is at the insertion. Whitnall's ligament acts as a clothesline, suspending the levator aponeurosis and the medial portion of the superior oblique tendon.

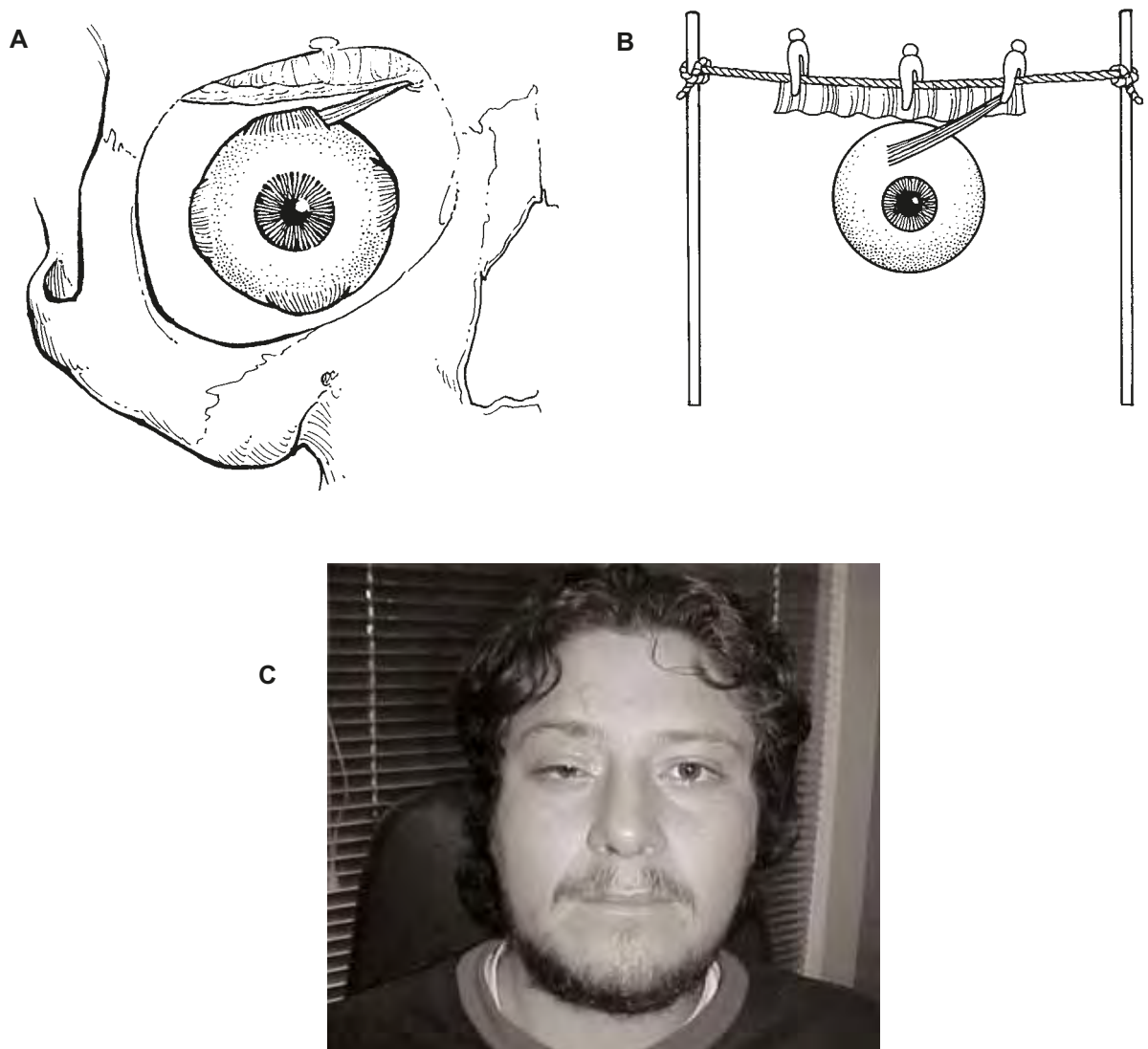


Figure 43

- A** The relationship of Whitnall's ligament and the superior oblique tendon. 'Blind hooking' the superior oblique tendon can damage Whitnall's, producing ptosis.
- B** Whitnall's ligament acts like a clothesline with orbital structures suspended.

- C** Nasal ptosis right eye from disruption of Whitnall's ligament after hooking of the superior oblique tendon in a 'blind sweep' nasal to the superior rectus.

Trochlea

The trochlea remained the largest undescribed portion of human anatomy until 1982. I began the definitive study of the human trochlea with the original exenteration specimen shown below that contained the superior oblique tendon, trochlea, and the distal superior oblique muscle, all in their physiologic relationships* (Figure 44). The intact nature of the specimen allowed separation of the structures comprising the superior oblique complex as shown. This specimen was carefully dissected and extensively recorded including videotaped images showing the way in which the superior oblique tendon passed through or more accurately slid in a telescoping manner inside the trochlea. These studies confirmed that

the trochlea is the functional origin of the superior oblique muscle (actually the superior oblique tendon).

The tendon of the superior oblique can telescope inward toward the apex of the orbit approximately 16 mm during maximum downgaze in adduction and telescope 16 mm outward in maximum upgaze in adduction. Tendon movement cannot exceed these limits because the peripheral superior oblique tendon fibers are attached to the trochlea. The multiple fiber layers making up the superior oblique tendon slide with a cumulative effect with only the central fibers carrying out the maximum excursion (Figure 45).

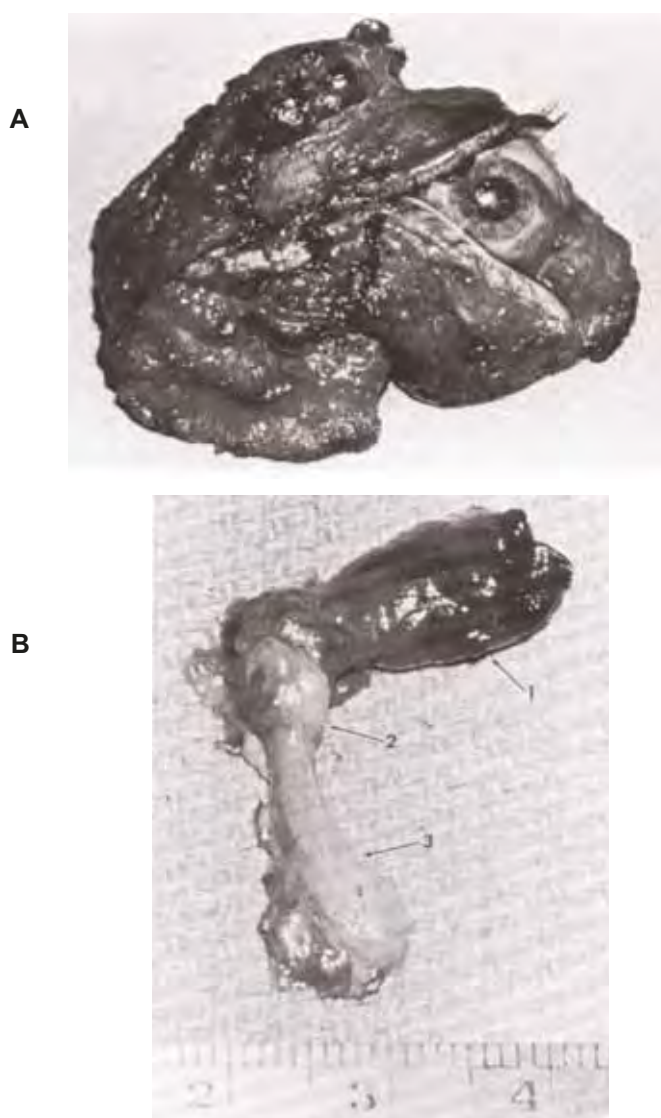


Figure 44

A Exenterated orbit specimen containing the superior oblique complex

B The trochlear complex including: 1) distal muscle, 2) trochlea, and 3) proximal tendon. These were dissected from exenteration specimen.

* Helveston EM, Merriam WW, Ellis FD, et. al. The trochlea: a study of the anatomy and physiology, *Ophthalmology*, 89(2):124, 1982.

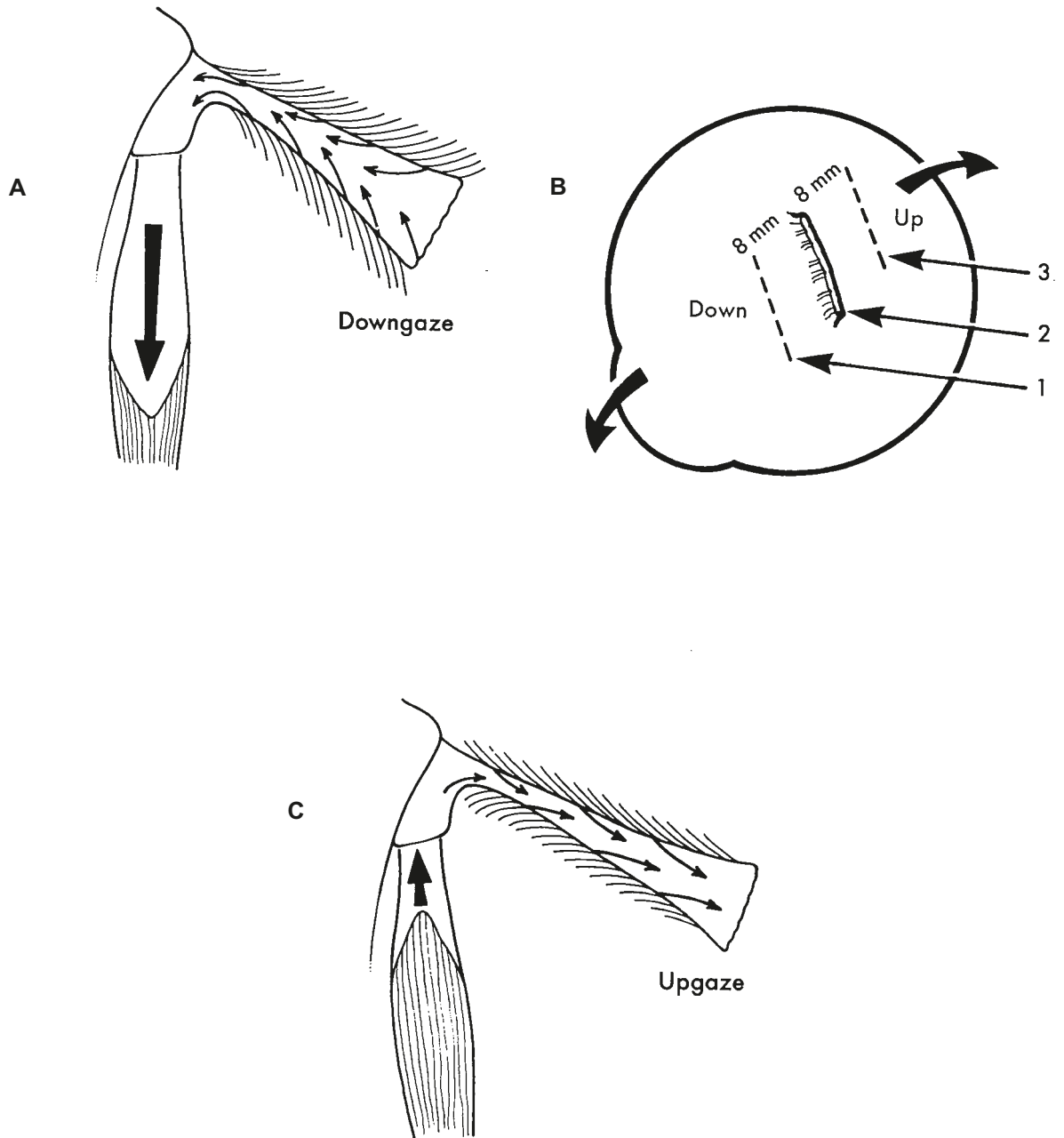


Figure 45

- A** In downgaze the direction of movement of superior oblique tendon fibers
- B** Location and distance of movement of the superior oblique insertion in: 1) downgaze, 2) primary position, and 3) upgaze

- C** In upgaze the direction of movement of superior oblique tendon fibers

Reasons why the trochlea remained undescribed and undisturbed during the course of strabismus surgery for so long include its location just inside the superior orbital rim and its close relationship to the superior orbital vessels and nerves (Figure 46). The superior oblique tendon transfer procedure, as first described, did include subperiosteal dislocation of the trochlea through a skin incision, but there is no evidence that the trochlea itself was seen when this procedure was done. Most 'anatomic' drawings represent the trochlea in a stylized fashion, portraying it as a sling through which the tendon passes freely or else it is shown as a 'lump' with the tendon entering on one side and exiting on the other.

Study of the trochlea first made possible by the exenteration specimen shown in Figure 44 and later

by study of autopsy specimens demonstrated that the bulk of the trochlea is made up of a cartilage saddle 5.5 mm long, 4 mm thick, and 4 mm wide with a groove facing the orbital wall and with a curve convex toward the bone (Figure 47). Scanning electron microscopy demonstrates the following trochlear components (Figure 48):

- 1) Cartilage saddle
- 2) A bursa-like space on the bearing surface between the tendon and the groove in the cartilaginous saddle
- 3) A fibrillar-vascular structure surrounding the superior oblique tendon
- 4) The superior oblique tendon
- 5) Fibrous bands attaching the trochlea to the bone of the orbit

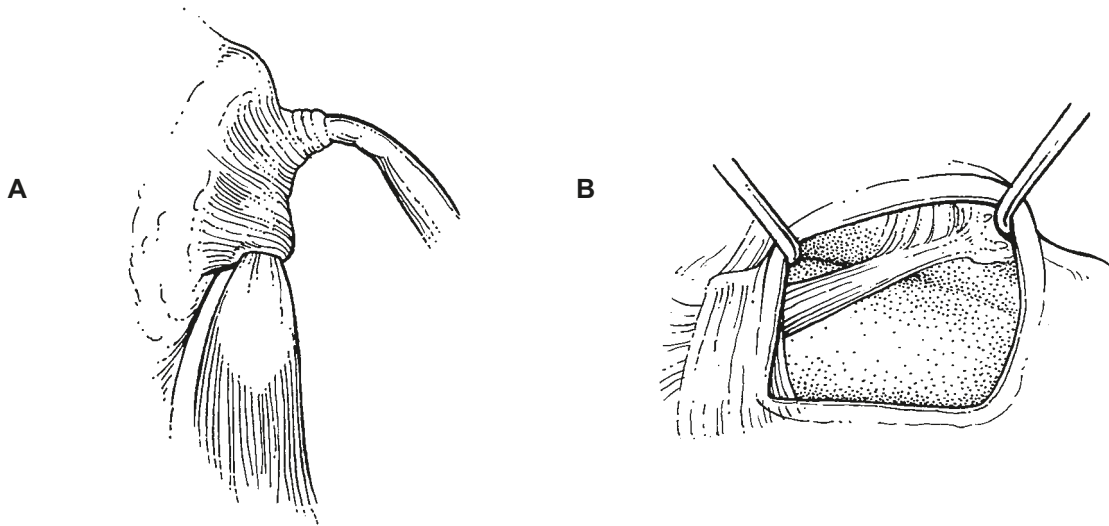


Figure 46
A The trochlea attached to the medial orbital wall with the tendon entering and exiting.

B With fascial tissues removed the superior oblique tendon seen exiting the trochlea through a cuff attached to the trochlea.

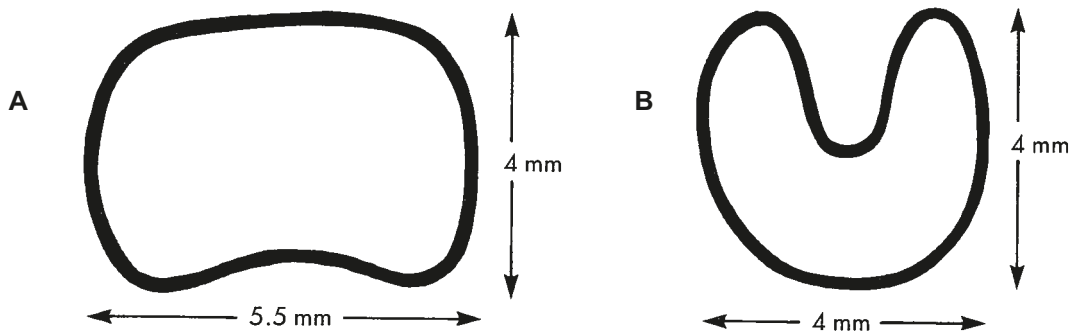


Figure 47 Dimensions of the trochlea
A Saggital

B Coronal



Figure 48

1) cartilage saddle, 2) bursa, 3) fibrillar - vascular space, 4) tendon, 5) attachment to orbital rim

The superior oblique tendon in the trochlea is made up of approximately 270 bundles of fibers. In the several specimens studied, individual fibers in the bundles range in size from 0.01 to 0.1 mm. The fibers appear discreet and flattened or triangular (Figure 49).

A description of the conclusions of the work describing the form and function of the trochlea is depicted in a composite drawn schematically by

Craig Gosling of the medical illustration department at the Indiana University School of Medicine demonstrates the proposed dynamic relationship of the components of the trochlea. Significantly, the superior oblique tendon fibers appear to slide by each other with a definite limit for each fiber, meaning that the more central fibers move farther than the more peripheral fibers and that the tendon moves with a cumulative effect (Figure 50).

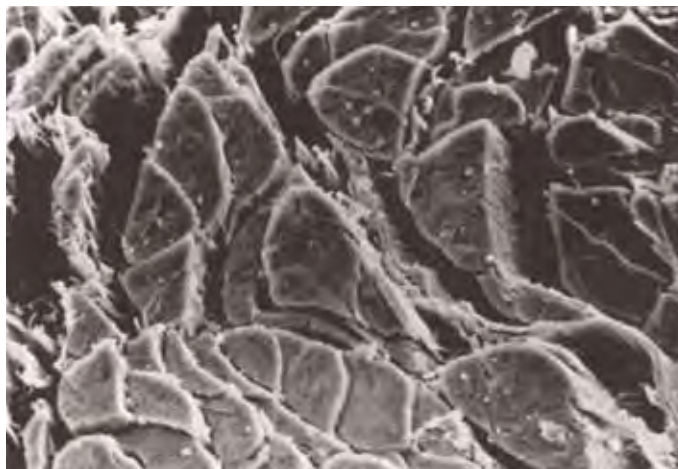


Figure 49

Scanning electron microscopy view of superior oblique tendon x320

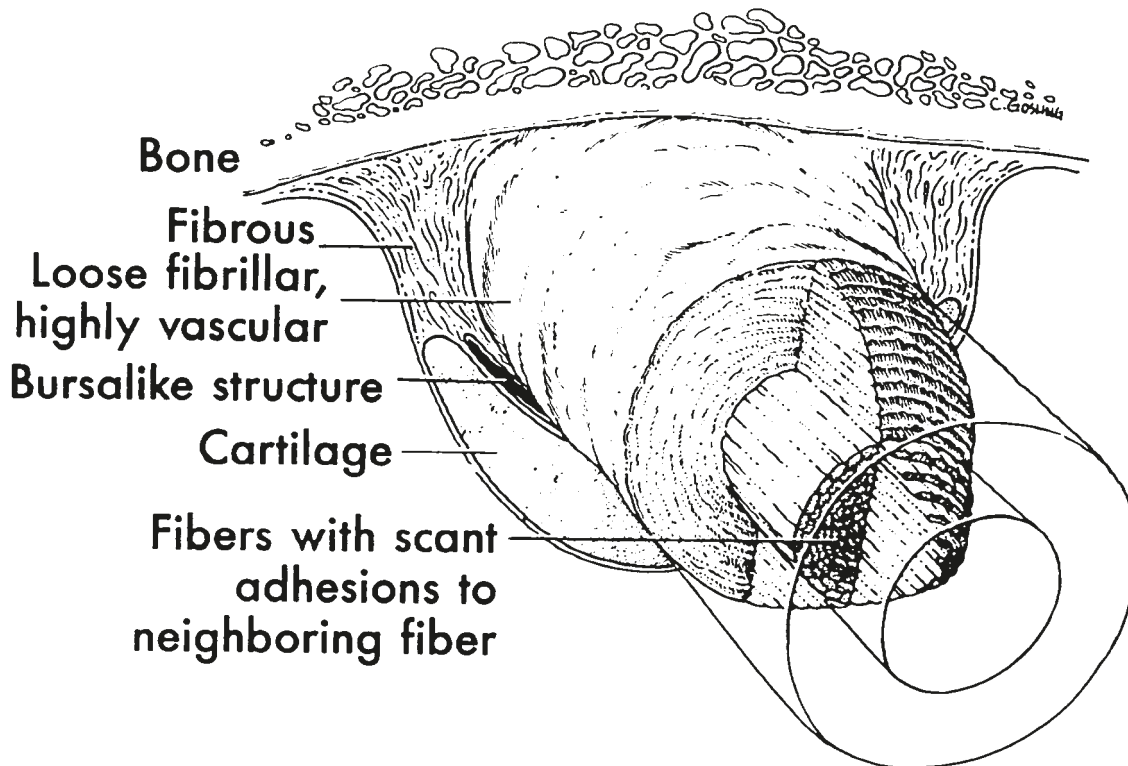


Figure 50 Composite

In the combined experience of strabismus surgeons, the superior oblique muscle has been found to be anomalous more frequently than any other extraocular muscle. The insertion varies widely in its location. More importantly, absence of the superior oblique tendon in cases of superior oblique ‘palsy’ has been observed and reported. In most of these cases, a diagnosis of unilateral or bilateral superior oblique palsy was made and surgery was undertaken with the intention of doing a tuck of the superior oblique tendon. If a careful search at the insertion reveals no superior oblique tendon in these cases, the incision should be enlarged, the superior rectus detached, and the sclera inspected from the superior border of the *horizontal* recti to several millimeters posterior to the equator, including the entire anterior-superior globe. If no superior oblique tendon is found, an inferior oblique myectomy is carried out. Also performed is a recession of the yoke of the absent superior oblique, the contra lateral inferior rectus, and/or recession of the ipsilateral superior rectus (Figure 51).

When these patients were studied retrospectively, they had, in addition to their apparent superior oblique palsy, a higher incidence of amblyopia and/or horizontal strabismus compared to patients with superior oblique palsy in whom a superior oblique tendon was found. Only 1 of 28 patients with congenital superior oblique palsy who had a superior oblique tendon at surgery had amblyopia and/or horizontal strabismus. Also, all patients who eventually had absence of one or both superior oblique muscles had pronounced underaction of the superior oblique muscle on the involved side preoperatively. Absence of the trochlea and superior oblique muscle has been demonstrated on CT (Figure 52). Patients with a diagnosis of congenital superior oblique palsy, with or without a superior oblique tendon, have in common a superior oblique traction test suggesting a lax or absent tendon and are likely to have facial asymmetry, with the larger face on the side of the paretic or absent superior oblique.

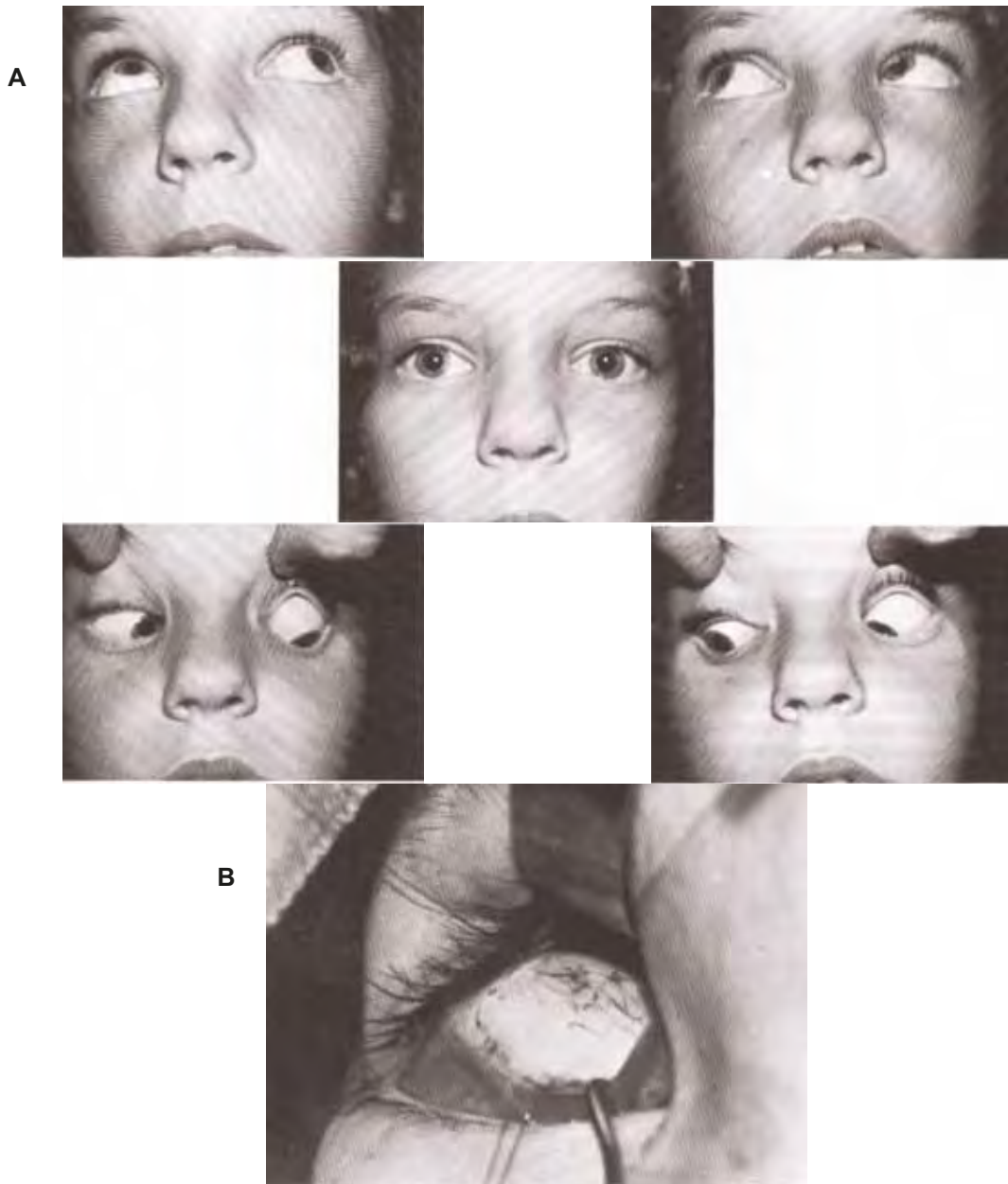


Figure 51

A Gaze positions showing 'overaction' of the right inferior oblique and underaction of the right superior oblique.

B At surgery, absence of the right superior oblique tendon was confirmed.

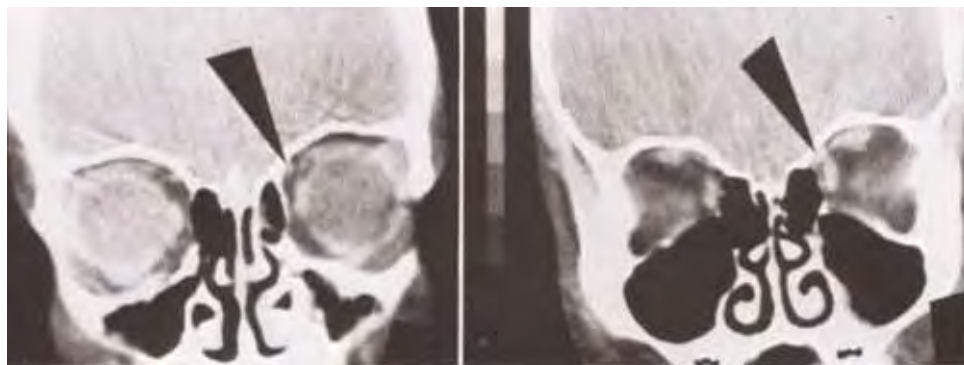


Figure 52

A CT scan showing trochlea on the left and no trochlea on the right.

B Same patient demonstrating the superior oblique muscle on the right and no muscle on the left.

Anterior segment blood supply

The principal blood supply to the anterior segment of the eye is from the anterior ciliary arteries, which travel in the four rectus muscles with anastomoses to the conjunctival and anterior Tenon's vessels (Figure 53). These arteries are the major blood supply to the anterior segment. The rest of the blood to the anterior segment is supplied by the two long posterior ciliary arteries that come forward intrasclerally at the 3- and 9-o'clock positions. Both sets of arteries originate from the ophthalmic artery. Each of the rectus muscles has two anterior ciliary arteries, with the exception of the lateral rectus which has one. These arteries lie within the muscle until near the tendon when they exit the muscle and travel in the muscle capsule. There they are visible until reaching the muscle's insertion where they enter sclera to form the episcleral circle. From the episcleral circle, blood flows to the intramuscular circle and from there flows into multiple branches of the major arterial circle supplying blood to the ciliary muscle, ciliary process, and iris. This circle is discontinuous. The anterior ciliary arteries furnish 70 to 80% of the blood supply to the anterior segment. The long posterior ciliary artery bypasses the episcleral circle and joins the intramuscular circle. The recurrent ciliary artery serving the choroid is supplied by the intramuscular circle. The long posterior ciliary arteries provide less than 30% of the blood supply to the anterior segment. Of the two long posterior ciliary arteries, the medial provides the most blood (Figure 54).

As a rule, at least one anterior ciliary artery should remain undisturbed by strabismus surgery to avoid anterior segment ischemia. However, anterior segment ischemic changes have been seen after as few as two muscles have been detached. Conversely, all four muscles have been detached at one procedure or in two, staged procedures separated by months or years without producing anterior segment ischemia, in some cases. Orge, et. al. have shown that detachment of rectus muscles can reduce blood flow in the ophthalmic artery 30%, presumably because of 'downstream' effects. Such a change in susceptible individuals could lead to acute anterior segment ischemia.

There is no evidence that severed anterior ciliary arteries ever recanalize to nourish the anterior segment, but time could be a factor in establishing collateral circulation. The conjunctival circulation and its contribution to the anterior segment have been discussed as factors that influence the type of conjunctival incision to be made. The cul-de-sac incision, which disrupts conjunctival circulation less than the limbal incision, has been suggested as being safer. In contrast, Awaya has detached all four rectus muscles at a single procedure to lower intraocular pressure as an alternative to cyclocryotherapy in advanced glau-

coma. Patients achieved lowered intraocular pressure without experiencing the typical clinical signs of anterior segment ischemia.

The medial anterior segment circulation is the most protected because it is supplied by two anterior ciliary arteries and a long posterior ciliary artery (Figure 55). The superior and inferior quadrants are the least protected because they have no long posterior ciliary artery. In clinical practice, it is not known with certainty what factors ultimately influence the postsurgical dynamics of anterior segment circulation in a given case. Some useful guidelines follow:

1. *When a muscle is detached and reattached, anterior ciliary vessels do not recannulate.*
2. *Because there are no long posterior ciliary arteries superiorly or inferiorly, detachment of the superior or inferior rectus muscles disrupts iris vessel filling more than detachment of the horizontal recti.*
3. *Older, vascularly-compromised patients may be more likely than young, healthy patients to develop anterior segment changes after eye muscle surgery.*
4. *Iris angiography is a valid way to assess anterior segment circulation at a given time, but it is not a valid or practical predictor to determine what might happen if eye muscles are detached.*
5. *Anterior segment ischemia is rare, fortunately.*
6. *If anterior segment ischemia occurs, it should be treated with atropine and frequent instillation of topical steroids.*

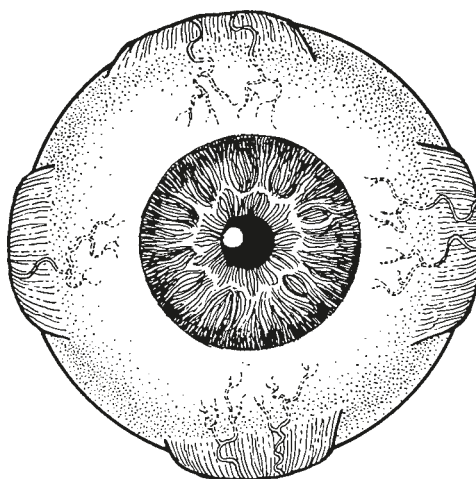


Figure 53

There are seven anterior ciliary arteries, two each in the superior, inferior, and medial rectus muscles. The lateral rectus has one. The anatomy of these vessels is subject to marked variation.

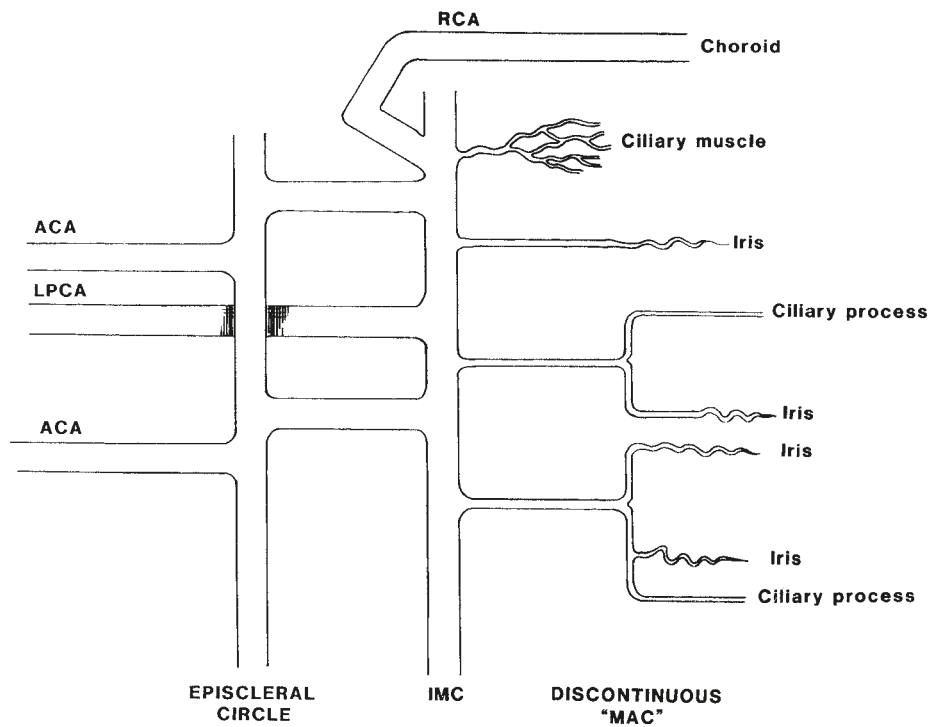


Figure 54

Schematic of the blood supply of the anterior segment from Saunders, et. al.

ACA = anterior ciliary artery

LPCA = long posterior ciliary artery

IMC = intramuscular circle

RCA = recurrent choroidal artery

From Saunders RA, et al. Anterior segment ischemia after strabismus surgery. Survey of Ophthalmology, 1994, 38(5):456-466. Used with permission.

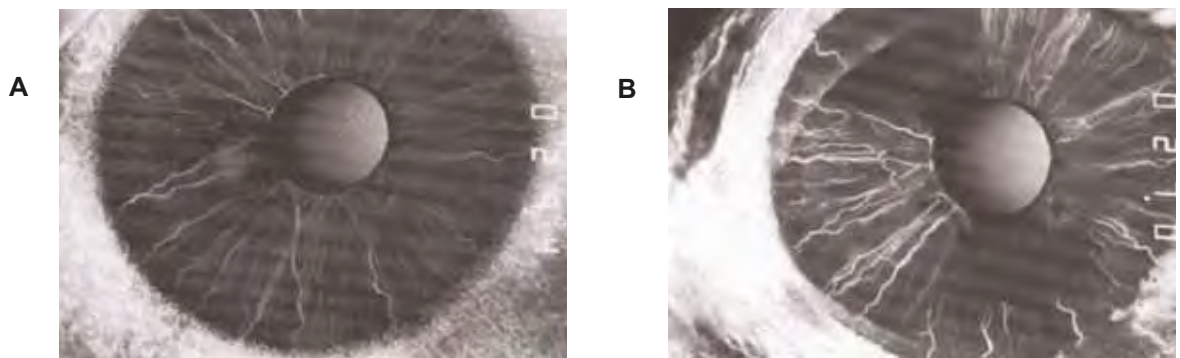


Figure 55

A Normal iris filling after preoperative intravenous injection of fluorescein in a 30-year-old man.

B First postoperative day after detachment and transfer of the superior and inferior rectus muscles. Note superior and inferior sector filling delay.

continued.

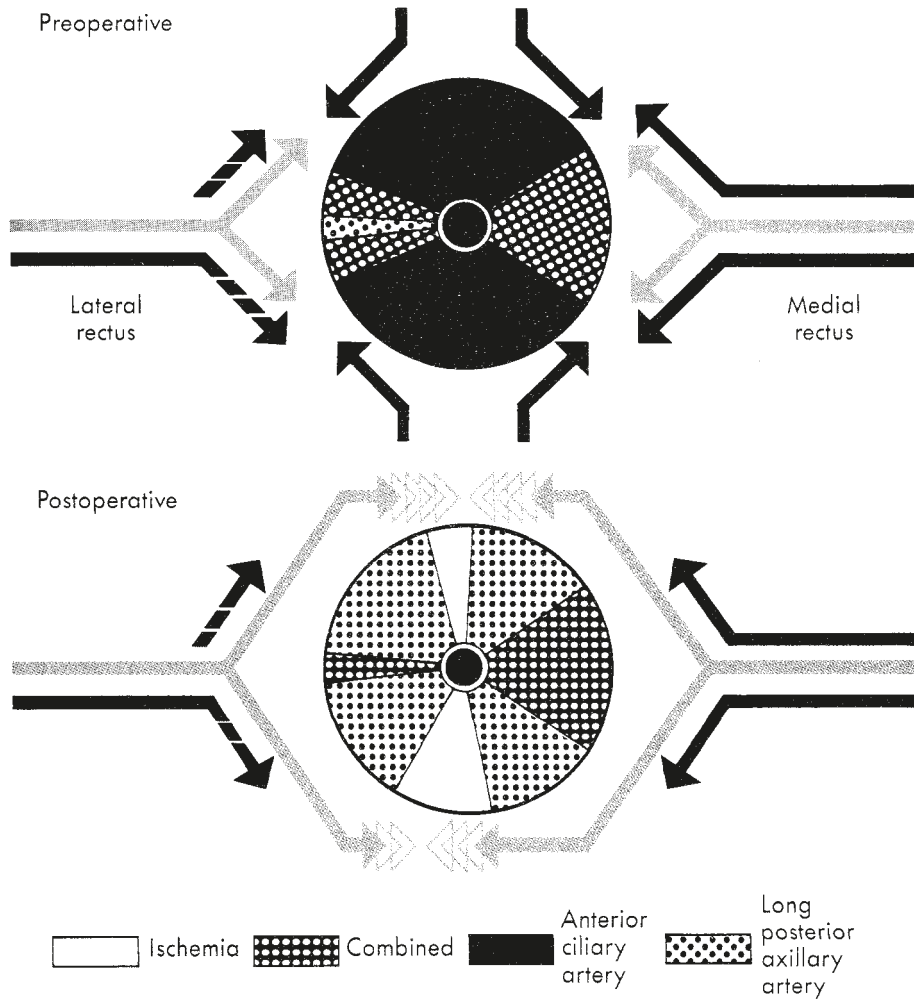


Figure 55, cont'd
 From Olver J, Lee JP: Eye 3:318-326, 1989.

A variety of eye muscle transfer procedures, including the Jensen tendon-muscle splitting transfer, are designed to spare one anterior ciliary vessel in each of the split muscles. However, von Noorden has pointed out that the surgeon should look for anomalous anterior ciliary vessels that may crowd to the half of the muscle that is pulled over for the transfer and should then avoid ligating both vessels since this would leave no anterior ciliary vessel in the undisturbed portion of the muscle.

Both McKeown, et. al., and Roth, in separate papers published in 1989, described a technique for detaching a rectus muscle while sparing the anterior ciliary arteries (Figure 56). The technique requires meticulous dissection aided by magnification with the operation microscope. Because of the low incidence of clinically significant anterior segment ischemia and the difficulty of this procedure, its use is likely to be highly selective.

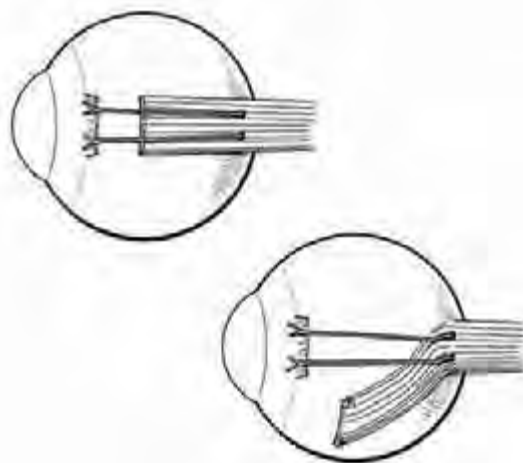


Figure 56
 The anterior ciliary arteries are dissected from the superficial capsular muscle tissue allowing repositioning of the muscle while leaving blood flow undisturbed.

Vortex veins

There are normally four vortex veins in each eye. They are located roughly equidistant in the quadrants of the globe; that is, 90 degrees apart (Figure 57). These veins drain blood from the iris, ciliary body, and choroid. Their appearance is variable and rarely will they number greater than four. These veins have a tortuous 5-7 mm intrascleral course and a similar extrascleral course before passing through posterior Tenon's into the intraconal space. The superior vortex veins empty into the superior orbital vein, and the remaining vortex veins empty into the inferior orbital vein.

In the course of strabismus surgery, each of the vortex veins seems to have its own 'personality' (Figure 58). The superior temporal vortex vein is seen at the posterior insertion of the superior oblique tendon. This is a reliable finding. The superior nasal vortex vein and/or the inferior nasal vortex vein may be seen while recessing the medial rectus, but rarely. The inferior nasal and inferior temporal vortex veins

are observed in almost every case of inferior rectus surgery. This occurs because the inferior vortex veins are situated about 1 mm closer to the midline near the equator. Dissection of the inferior rectus is usually carried posteriorly to a point often posterior to the inferior vortex veins to limit the lid effects of Lockwood's ligament. The inferior temporal vortex vein is encountered in nearly every case when engaging the inferior oblique in the inferior temporal quadrant. It is rare to encounter a vortex vein during surgery on the superior or lateral rectus.

If the surgeon exercises reasonable care, the vortex veins will remain intact. They look vulnerable but are actually fairly resistant to careful manipulation. Rupture of a vortex vein is rare, if surgery is done carefully. If a vortex vein is ruptured, it is treated with compression, and if necessary, cautery. A great deal of discoloration and swelling will occur, but there is no lasting complications to the surgery.

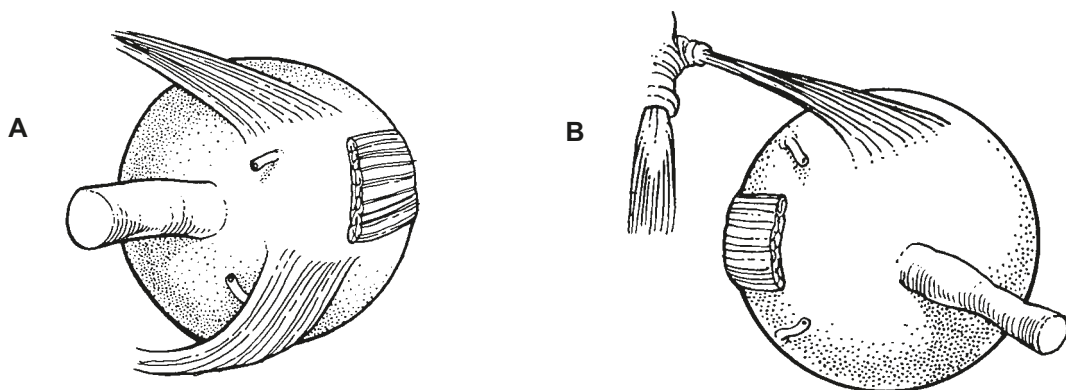


Figure 57 The four vortex veins are viewed from the posterior aspect of the globe.

A Lateral

B Medial

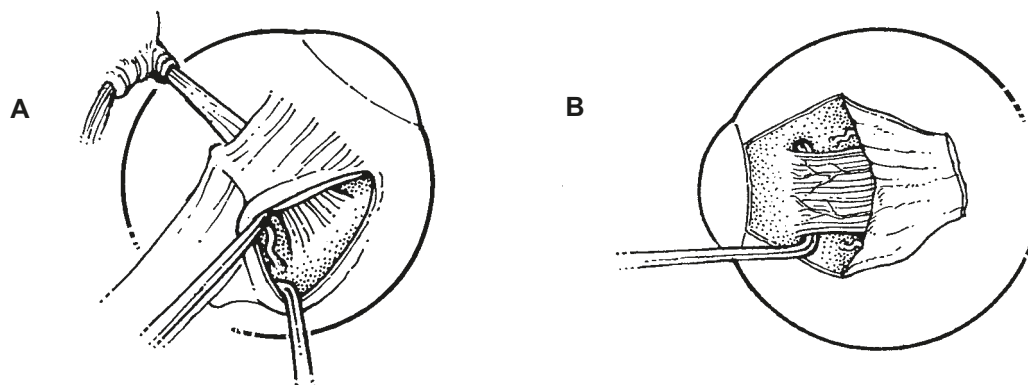


Figure 58

A The superior temporal vortex vein is seen at the posterior insertion of the superior oblique. Vortex veins are not seen routinely during surgery on the superior rectus.

B A vortex vein may be seen but rarely at either (or both) borders of the medial rectus.

continued.

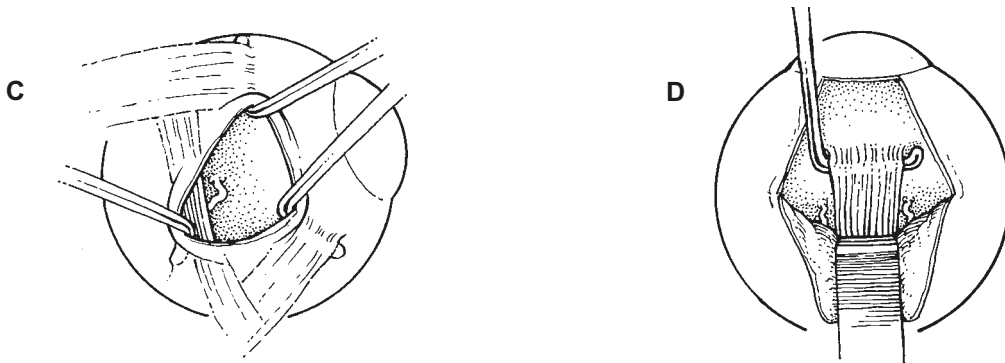


Figure 58, cont'd

C A vortex vein is seen routinely under the mid-belly of the distal inferior oblique.

D Vortex veins are seen at one or both borders of the inferior rectus.

Orbit and extraocular muscle imaging

Two widely used techniques for imaging the orbit and the extraocular muscles are computed tomography (CT) and magnetic resonance imaging (MRI) (Figure 59). CT utilizes high resolution x-rays recorded in fine cuts. CT is superior to MRI for detecting calcium within a lesion or bony changes such as with an orbital fracture and in identifying early invasion or modeling from an adjacent lesion. Iodine-containing contrast material can aid the diagnostic capability of CT but possible side effects could be serious.

MRI provides high soft tissue contrast along with high spatial resolution achievable in multiple planes giving excellent anatomic detail of soft tissues. The MRI utilizes a strong magnetic field to align a portion of the nuclear spin that is ordinarily random. Using the aligned proton as a target, the field is exposed to pulsed energy that momentarily allows the proton to resume its usual position only to become realigned at the end of the pulse. The energy given off during realignment enables the signal which in turn produces the image. The pulse sequences are called T1 and T2. Fluid is dark on T1 weighted images, and fat is bright. Fat is darker and less distinct on T2 weighted images (Figure 60). Various techniques are available to suppress the fat with T1 images thus providing a better image of some orbital contents.

For viewing the extraocular muscles, T1 weighted images of dark muscles are satisfactory. The views may be coronal, axial, or saggital (Figure 61). Thyroid myopathy with enlarged muscle bellies is seen well in a coronal view but can also be appreciated in the axial and saggital views. Enlarged muscles can also be seen in pseudo tumor which involves all of the muscle and tendon in contrast to thyroid myopathy that spares the tendon. Myositis is also readily observed as muscle enlargement. These subtle diagnostic differences can be detected on a complete MRI study.

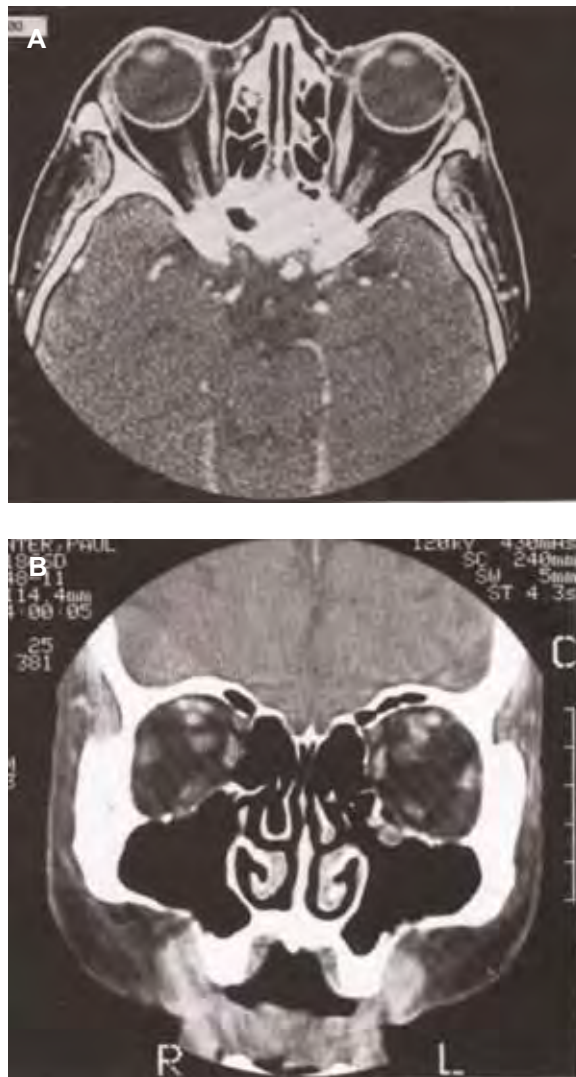


Figure 59

A Axial CT

B Axial MRI - T1 weighted image

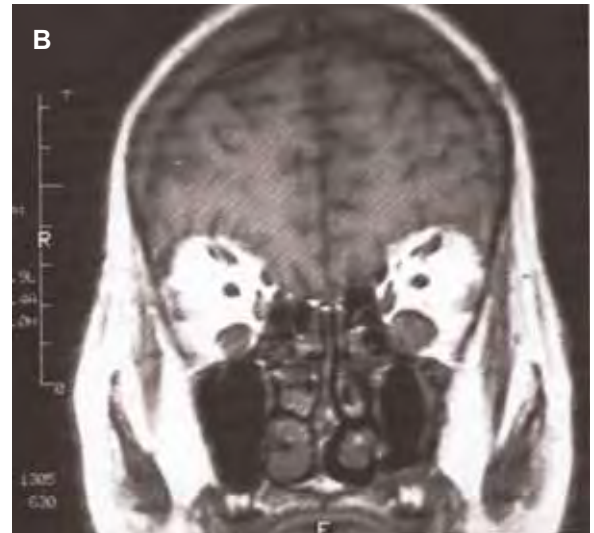
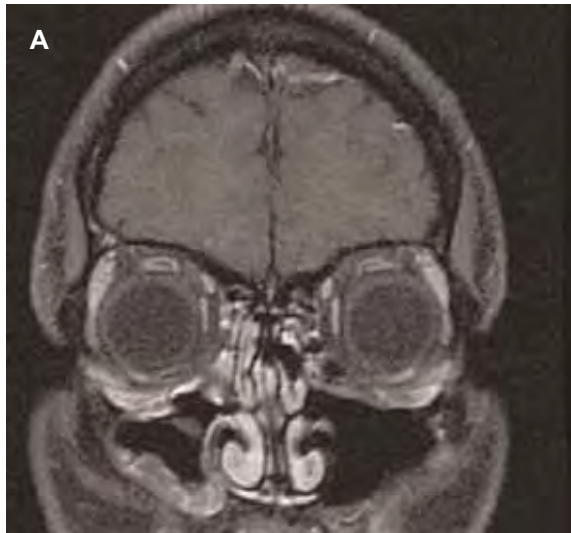


Figure 60

A Normal T1 weighted coronal MRI

B Abnormal T1 weighted coronal MRI showing enlarged inferior recti (dark area).

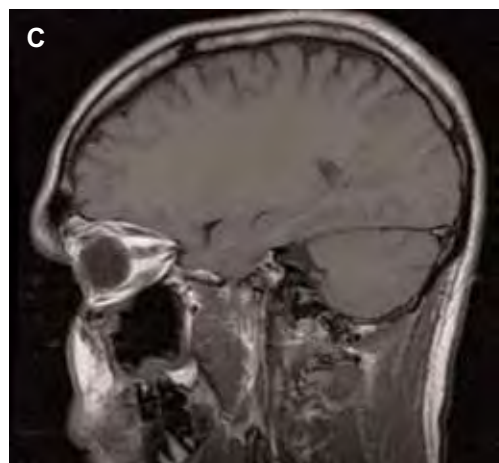
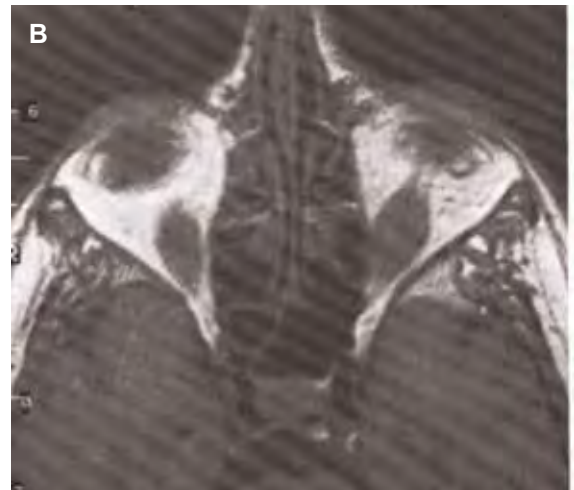
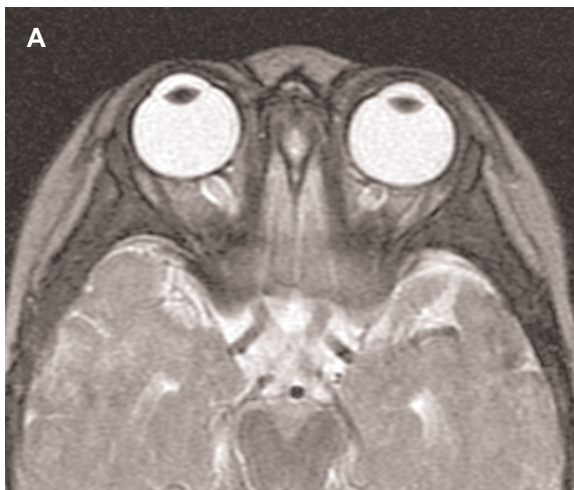


Figure 61

A Normal T2 weighted axial MRI

B T1 weighted axial MRI with diminished signal from fat. Note the enlarged muscle bellies.

C Normal T1 weighted sagittal MRI

While coronal and saggital views are effective for finding muscle belly enlargement, the axial view is best for identifying a slipped or 'lost' muscle. Because of the anatomic characteristics of the rectus muscles, the medial rectus is the only muscle likely to undergo sufficient slippage to present a clinical challenge in finding the muscle.

Recent description of the muscle pulleys, particularly those related to the horizontal recti, has prompted Demer and associates to stress the value of imaging for the diagnosis and treatment planning of a variety of strabismus entities. These include: incomitant strabismus, 'A' and 'V' patterns, Brown syndrome, 'heavy eye' in high myopia, and others.

The strabismus surgeon now employs imaging on a selective basis. Some deterrents to routine use of imaging include: high cost, inability to use in young children, lack of need in many cases, and, of course, habit. It is likely, in the future, that techniques will improve and costs will come down making imaging a more frequently-utilized tool for strabismus management. Ultrasound in the A or B scan mode can be employed as an alternative method for orbital and extraocular muscle imaging. This technique is office based and less expensive but is more difficult to interpret.

Growth of eye from birth through childhood

The eye undergoes significant growth between the neonatal period and adulthood (Figure 62). Study of this growth in vivo is made possible by the use of accurate, quick, and reliable A-scan biometry. The A-scan biometer, used principally for intraocular lens calculations in adults, has been applied to children to obtain measurements of the anteroposterior diameter. Gilles first used these measurements which he combined with corneal diameter measurements and measurements of the medial rectus insertion site to arrive at a more scientific formula for recession of the medial recti. Kushner found an inverse relationship between axial length and response (prism diopter change per millimeter of surgery) in esotropic patients. This finding is expected since the maximum 'torque' can be obtained with a smaller 'gear' or, in

the case of strabismus surgery, with a smaller eye. In clinical practice, the most important advantages of using these measurements seem to be consistency and the ability to do the largest recession without crippling the medial rectus by placing the new insertion too far posteriorly.

Studies of the globe in neonates and infants indicate that the posterior aspect of the globe is relatively hypodeveloped compared to the anterior aspect. This means that recession of the medial rectus in a newborn could put the new insertion site behind the equator, even in cases where as little as 3 mm of recession were done. Therefore, it has been advocated that surgery should not be done on very young infants. Surgery on infants as young as two or three months has been reported, but is not something that could be considered routine or advisable based on anatomic studies. In addition, there is good evidence that four months may be the earliest age that congenital esotropia can be diagnosed with confidence. Surgery on infants with infantile esotropia between the fourth and sixth month is now common and is safe. The axial length of the typical eye at this age is 19.5 mm. Such eyes are entirely suitable for surgery consisting of bimedial rectus recession to a point approximately 9.5 mm from the limbus. A safe lower age limit for surgery in cases of congenital infantile esotropia with no other contraindications is four months. Surgery for congenital esotropia by six months of age is now common and is shown in Figure 63.

Nanophthalmos describes an otherwise normally functioning eye but with a shorter anteroposterior diameter. These eyes have increased scleral thickness but decreased rigidity and are subject to retinal detachment. These eyes also have hyperopia and an increased incidence of glaucoma.

High myopia results in a significant increase in the anteroposterior diameter. Anteroposterior diameters as long as 27 mm in a six-year-old child with -11.00 D of myopia have been measured and some adults have axial length measurements greater than 30 mm. This can lead to intermuscular membrane rupture, pulley displacement, and muscle slip causing eso - hypotropia or 'heavy eye.'

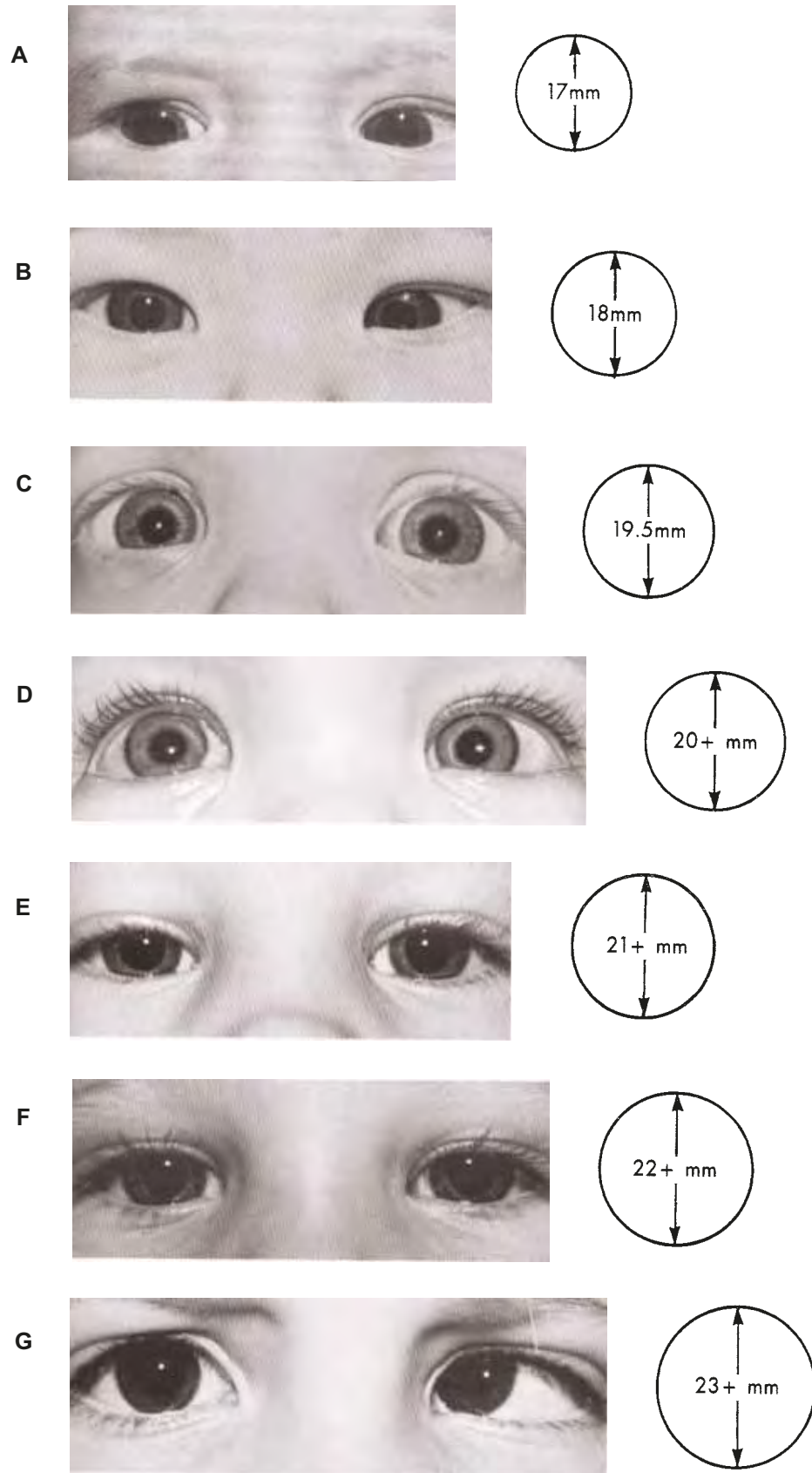


Figure 62

A One-week-old child, anterior-posterior diameter 17+ mm
B Three-month-old child, anterior-posterior diameter 18+ mm
C Four-month-old child, anterior-posterior diameter 19.5+ mm

D One-year-old child, anterior-posterior diameter 20+ mm
E Two-year-old child, anterior-posterior diameter 21+ mm.
F Three-year-old child, anterior-posterior diameter 22+ mm
G Five-year-old child, anterior-posterior diameter 23+ mm

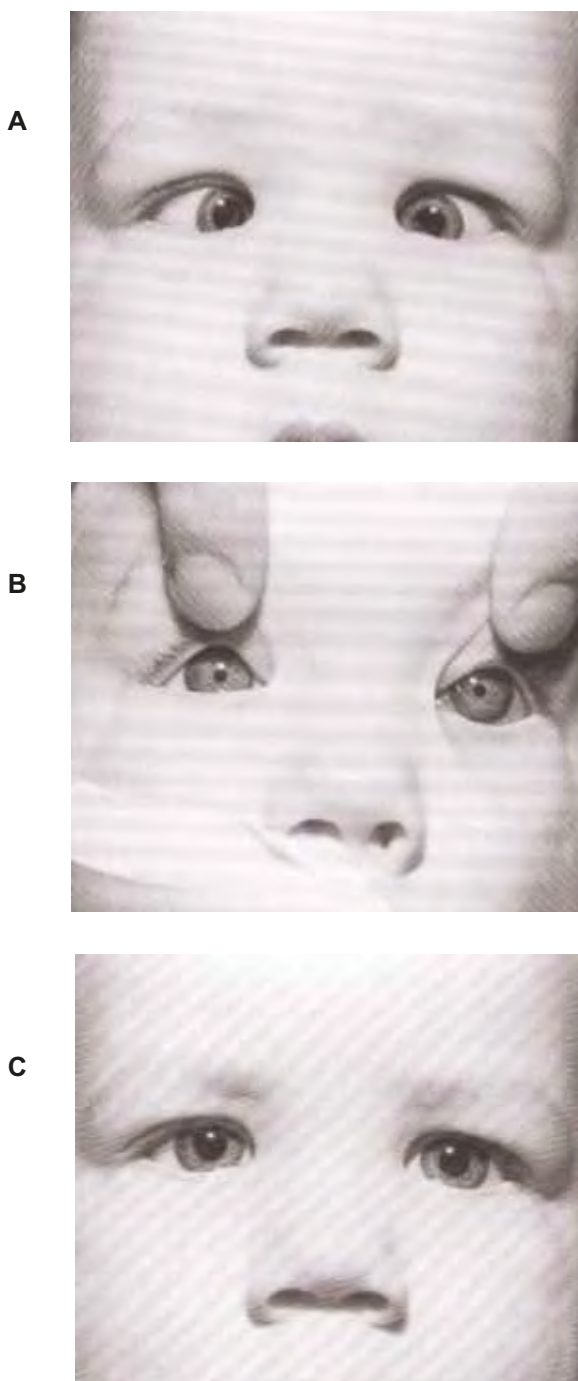


Figure 63

- A** Six-month-old with 50 diopters congenital esotropia preoperatively.
B Same patient immediately after surgery in the operating room. Both medial recti were recessed to a point 10 mm from the limbus. The axial length was 19.5 mm in each eye.
C Same patient at age 1 year.

Sclera

The thickness of the sclera varies according to location (Figure 64).

1. At the limbus, the sclera is 0.8 mm thick.
2. Anterior to the rectus muscle insertions, it is 0.6 mm thick.
3. Posterior to the rectus muscle insertions, it is 0.3 mm thick.
4. At the equator, it is 0.5 to 0.8 mm thick.
5. At the posterior pole, it is greater than 1 mm thick. The area of greatest surgical activity for the extraocular muscle surgeon coincides with the thinnest area of the sclera.

Care must be exercised when placing a needle into the sclera (Figure 65). A reverse cutting needle should be used only while exercising extreme caution because such a needle may be as thick as or thicker than the sclera into which it is inserted. This could lead to scleral perforation, an event that undoubtedly occurs more often than is suspected or reported. Fortunately, most cases of inadvertent scleral perforation heal without incident. If such a cutting needle is used, it should be very fine (preferably less than 0.3 mm), if possible, and it should be inserted carefully with the top of the needle seen through the superficial sclera at all times. For added safety, the cutting edge can be directed sideways so that it cuts along the scleral lamellae rather than into the eye, as shown. A curved cutting needle is less likely to perforate the sclera than a reverse cutting needle, but the curved cutting needle is prone to 'cut itself out' of the sclera unless an excessively deep bite is taken.

A much safer needle to use is the spatula design. With such a needle, only the tip and sides are cutting edges. The sclera is displaced upward and downward away from the body of the needle and is cut laterally and ahead of the needle. This action makes the complication of scleral perforation less likely to occur with spatula needles than with cutting needles. The spatula needle's widest dimension should remain *parallel* to the scleral surface. Needles with a wire diameter of .203 mm are both sufficiently strong and delicate enough to be inserted safely.

A keystone spatula, with cutting tip *up*, is safe but can 'cut out' of sclera. A keystone spatula, cutting tip *down*, produces a longer track but can also 'cut in' to the eye. A hexagonal spatula or 'neutral' tip needle must be guided to stay at mid-scleral level.

The sclera is white and opaque when fully hydrated. If this tissue becomes dried out, it becomes dark amber-colored and translucent. Re-hydration rapidly restores the opaque whiteness of the scleral tissue.

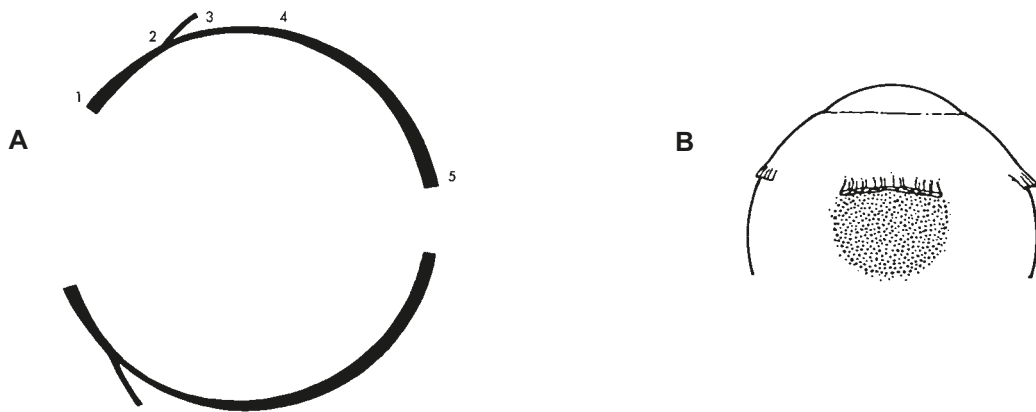


Figure 64

A The sclera varies in thickness according to location

B The sclera is thinnest, 0.3 mm, posterior to the rectus muscle insertion

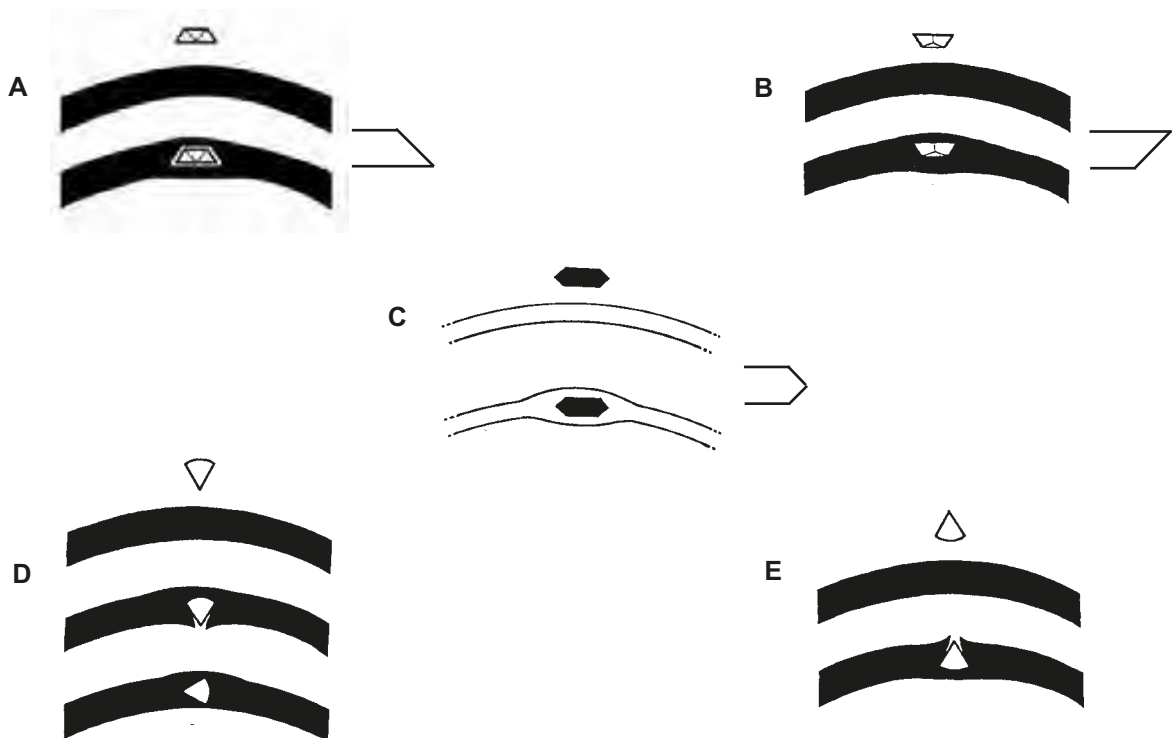


Figure 65

A Keystone spatula, cutting tip down

B Keystone spatula, cutting tip up

C Hexagonal spatula, neutral cutting tip

D Reverse cutting - tends to cut in - can be placed sideways

E Curved cutting - tends to be cut out

3

Parasurgical procedures and preparation

Overview

The instruments required for extraocular muscle surgery are simple and relatively few. As with any type of surgery, however, the surgeon must have available all instruments required for a particular procedure, and these instruments must be in good working order.

Anesthesia suitable for extraocular muscle surgery varies according to the patient's individual requirements and the surgeon's personal preference. Children always require general anesthesia with endotracheal intubation or with ketamine dissociation which can be used with or without endotracheal intubation. Insufflation anesthesia, which leaves the patient's airway unguarded except by the patient's own response, has been replaced in most cases by safer techniques which guard the airway. The general anesthetic agent or agents used for children or adults are usually determined by the anesthesiologist. Cooperative adults may be operated on successfully with local anesthesia, and a few surgeons have used topical anesthesia for extraocular muscle surgery in carefully selected patients.

The lids and face around both eyes must be washed and properly draped and the operative field freed of clutter to prepare the patient for surgery. Antibiotic drops or ointment, often with steroid, are used postoperatively by nearly all strabismus surgeons. Infection after strabismus surgery is not common, and rarely serious, and reaction to surgery tends to be mild. However, the use of postoperative antibiotics often with added corticosteroid is still considered worthwhile by many surgeons. A patch may be used according to the surgeon's preference, but is usually not necessary.

Surgery is done on an outpatient basis, with both children and adults arriving at the hospital on the morning of surgery and leaving several hours after

surgery. In cases where the health of a patient could be compromised by outpatient surgery, the patient can be admitted the day before surgery. Occasionally, a patient requires admission on the night of surgery on an unscheduled basis because of excessive vomiting, breathing difficulties, or some other complication which may be unrelated to the surgery itself.

The advent of mandated outpatient strabismus surgery requires that the surgeon and staff, including the operating room and recovery nurses and anesthesia staff, participate in thorough preoperative education. This includes the family and to some degree the patient, including both the understanding child and the adult. The family and/or patient should be made to understand that all liquids and solids by mouth must be withheld for a period of up to 8 hours before the scheduled time of surgery. The family and/or patient should be assisted in obtaining necessary preoperative laboratory tests before the day of surgery. In the past, this has consisted of determination of hemoglobin or hematocrit, but this is now considered unnecessary in a healthy child. Further blood testing is rarely required. A urinalysis is not required. Most adult patients over 55 years of age require an electrocardiogram (ECG), which is usually performed in the holding area just before surgery. In selected cases of adult patients and less often in children with a history of lung or breathing difficulties, a chest x-ray study is required. Patients taking anticoagulants should be advised to consult their primary physicians regarding a safe time to stop and then restart this medicine. Likewise, diabetics or patients with other significant health issues must be identified and given proper advice, usually by their primary care physician.

A patient who lives fairly close to the facility where the surgery is performed may leave from home and return home on the day of surgery. In cases

where the patient lives farther away, i.e., more than two hours by car, it may be more convenient for the patient and family to stay the night before surgery in a hotel, motel, with family living locally, or in a hospital-based housing facility nearby. Likewise, for comfort and safety, these patients should stay near the hospital on the night of surgery. These patients may be examined on the day after surgery. Other patients needing same day adjustment of an adjustable suture can be retained in a short stay hospital unit. A next-day examination is an absolute requirement if an adjustable suture must be adjusted on the morning after surgery but it is optional in most other cases.

From a practical standpoint, it is necessary to stress to patients the importance of arriving at the hospital at the appointed time in order to avoid a shut-down of the operating room for lack of a patient. At the same time, it is necessary to explain that because of occasional unavoidable delays, the surgery may not start at the scheduled time. It is essential to provide the family additional support during the outpatient surgery process because both the patients and their families tend to be less comfortable as outpatients compared to in-patients.

Physical examination

The physical examination is simple and is usually completed just before surgery. However, to expedite the flow of outpatient surgery, it may be completed in the clinic or office up to 30 days* before scheduled surgery. Likewise, laboratory tests are valid for 30 days*. No matter when the physical examination takes place, the patient's temperature is recorded just before surgery. In addition, at this time, the anesthesiologist performs auscultation of the lungs and the heart and reviews the patient's current and past medications and the pertinent anesthesia history.

The preoperative history obtained by the surgeon or team includes inquiry about upper respiratory or breathing difficulties, cardiac difficulties, fever, ear infection, bleeding tendencies, and prior anesthesia difficulties (especially family history of malignant hyperthermia). Any medicine used, including aspirin, should be recorded and made known to the surgeon. Drug allergies should be noted. The history continues with a review of systems. Physical examination includes evaluation of the heart and lungs and an overall observation of the patient.

The eye findings that were recorded in the clinic chart at the time surgery was scheduled should be reviewed, and the patient's current motility should be compared to these findings. If there is a major discrepancy between these findings, it may be prudent to cancel surgery, although this action is rarely taken.

The main purpose of the immediate preoperative examination, in my opinion, is to confirm that the surgeon has accurate information so that the proper surgery will be performed. If the physical status militates against a safe surgical experience, surgery should be canceled and rescheduled. In cases where there is a question about a child being ill before the day scheduled for surgery, parents are advised to call a day or two ahead of surgery and to consult their local doctor about the advisability of proceeding. The combined surgeon-anesthesiologist history and physical examination done immediately preoperatively ensures that the patient is sufficiently healthy to undergo surgery. A sample preoperative physical examination is shown in Figure 1.

Consent for strabismus surgery

Before strabismus surgery is begun, appropriate informed consent must be obtained from the patient or from a parent or legal guardian. A standard operative consent form is available in most surgical facilities. A sample of this form is shown in Figure 2. In addition to the standard consent form with the usual disclaimers used for any type of surgery, it is necessary to advise patients undergoing strabismus surgery of the following complications unique to strabismus surgery:

Diplopia. Patients should be told they might see double at some time after surgery. This can occur as soon as the patient opens his/her eyes after surgery. Diplopia can even be considered a favorable sign in patients with fusion potential. In case of an incomitant deviation, a patient may be able to 'find' double vision looking in one direction, but also may be able to eliminate it looking in another. Patients are told not to be alarmed if diplopia occurs. They should be told that it either goes away or if not, it can be managed successfully in nearly every case.

Loss of vision. Loss of vision after strabismus surgery can occur, but it is rare! For example, this can occur if a needle is placed too deeply, passing through the retina and producing a vitreous hemorrhage which can clear with time, or it can cause retinal detachment. Although scleral-retinal perforation may occur in as many as 1% of strabismus cases, significant complications from this cause are rare. Infection producing endophthalmitis can also cause loss of vision. Fortunately, this too is extremely rare. Anterior segment ischemia causing cataract can cause variable reduction in vision.

* Time limits may vary at different facilities.

M6178675 Rev. 4/84	Indiana University Hospitals 1100 W. Michigan St. Indianapolis, Indiana 46202							
EXAMINATION Name _____ I.U. # _____ Home Ph. _____ Bus. Ph. _____ Birth Date _____ History of present illness: _____ _____ _____	<input type="checkbox"/> Inpatient <input type="checkbox"/> Outpatient							
HISTORY AND PHYSICAL Past Medical History: Major Illnesses and Operations _____ _____ Present Medications _____ Allergies and Sensitivities _____ Other _____ Systemic Review Negative _____ Comment _____ Cardiovascular _____ Respiratory _____ Gastrointestinal _____ Genitourinary _____ Nervous _____ Other _____ Physical Examination T _____ Pulse _____ B.P. _____ Normal _____ Abnormal _____ Comment _____ HEENT _____ Heart _____ Lungs _____ Other _____ Date of Surgery _____ Diagnosis and Surgical Procedure _____ Signature _____ M.D.								
PREOPERATIVE ORDERS 1. Nothing by mouth after _____ or _____ 2. CBC, Electrolyte, Urinalysis, _____ 3. EKG, _____ 4. Chest X-ray, _____ 5. Preop Medications: _____ _____ 6. Other: _____ _____ Date _____ Signature _____ M.D.								
CIRCLE OR COMPLETE ORDERED WORK								
MEDICAL RECORD COPY AMBULATORY SURGERY — HISTORY AND PHYSICAL PREOPERATIVE ORDERS		M-2						
B-CLIN. NOTES	E-LAB	G-X-RAY	K-DIAGNOSTIC	M-SURGERY	Q-THERAPY	T-ORDERS	W-NURSING	Y-MISC.

Figure 1

INDIANA UNIVERSITY HOSPITALS 1100 W. Michigan Street Indianapolis, Indiana 46202							
Re	#6	CONSENT FOR PROCEDURE				M6316000	
<p>I (we) hereby request and consent to the performance of the following operation or procedure on the patient by _____ M.D., and members of the medical staff and personnel of the Indiana University Hospitals, the administration of anesthetics deemed advisable by the physician performing the operation or procedure, the administration of blood or blood components or derivatives, and extensions of the operation or procedure if considered advisable by the physician performing the operation or procedure, and disposal of any tissue, organ or body part, including scientific investigation excepting as noted below:</p> <p style="text-align: right;"><input type="checkbox"/> Inpatient <input type="checkbox"/> Outpatient</p> <p>— Operation or procedure: _____</p> <p>— Exceptions, if any: _____ (If none, write "none")</p> <p>I acknowledge that I have had an opportunity to discuss with _____ M.D. the operation or procedure, its purpose and nature, reasonable alternatives, possible consequences of remaining untreated, and risks and possible complications. I understand that the practice of medicine is not an exact science, that it may involve the making of medical judgments based upon the facts known to the physician at the time, that it is not reasonable to expect the physician to be able to anticipate nor explain all risks and complications, that an undesirable result does not necessarily indicate an error in judgment, that no guarantee as to results have been made to nor relied upon by me, and I wish to rely on the physician to exercise judgment during the course of the procedure or operation which he feels at the time, based upon the facts then known, are in my best interest.</p> <p>PHYSICIAN'S NOTE: Please list the most common and serious risks and complications of the intended procedure(s) you discussed with the patient.</p> <p style="text-align: right;">Signed _____ M.D.</p> <p>WITNESS TO SIGNATURE:</p> <p>_____ Patient's Name: _____</p> <p>Date: _____ Patient's Signature (See Reverse Side)</p> <p>Time: _____ AM PM</p> <p style="text-align: right;">Relationship or authority if not signed by the Patient</p>							
MEDICAL RECORD COPY		CONSENT FOR PROCEDURE				M-1	
B-CLIN. NOTES	E-LAB	G-X-RAY	K-DIAGNOSTIC	M-SURGERY	Q-THERAPY	T-ORDERS	W-NURSING
							Y-MISC.

Figure 2

Need for reoperation. The need for a reoperation after strabismus surgery is not really a complication by itself. In most cases, before doing strabismus surgery, the surgeon can give the patient an approximate percentage figure for the need for reoperation. For example, the surgeon can tell the patient/family that in spite of making a 100% effort to straighten the eyes, there is a ($\pm 10\%$, 20%, 30%, etc.) likelihood of the need for reoperation. In the case of congenital esotropia, this percentage is between 5% and 20%. In cases where prior surgery has been performed, when the strabismus is complicated, or after injury, need for reoperation may be as high as 50%. A reoperation may be necessary, even in a case where everything goes exactly as planned, because a totally predictable response is not possible in every case. On the other hand, in cases of a slipped or lost muscle, excessive hemorrhage, fat exposure, etc., reoperation may be necessary where things did not go as planned.

A separate consent obtained by the anesthesiologist can include information about the chance of breathing difficulties, vomiting, sore throat, or even of heart attack or death!

Instruments used in strabismus surgery

The complete instrument assortment for strabismus surgery is shown as assembled on the instrument stand (Figure 3). Not every instrument is used in each case, but ideally, all should be available each time strabismus surgery is done. In case the complete set is not available, the minimum instruments for strabismus surgery are the following: lid speculum, fine

scissors, fine forceps, muscle hooks of various sizes, retractors, needle holders, a caliper, and something to provide cautery. An open flame and a probe projecting from a metal ball are used in many developing countries to achieve cautery. Although a variety of specialized instruments have been introduced over the years, these basic instruments have remained essentially unchanged in number and design for a hundred years or more.

In response to finer sutures and needles, better understanding of anatomy, and more widespread use of magnification, several modifications to the basic instruments for strabismus surgery have been made. These instruments are now available from Katena Products, Inc. (Figure 4). These include the Lieberman speculum in an adult and pediatric size; and the Helveston 'Barbie' retractor in three sizes, standard, 'big', and 'great big,' used in place of the bulkier Desmarres retractors. Also newly modified are three muscle hooks including the small, right angle 'teaser' hook to be used in place of the heavier curved Stevens hook; three sizes of the standard muscle hook with a finer 'hook' end to be used in place of the bulkier Jameson hook; and two sizes of a sharp, pointed 'finder' hook to be used *very carefully* as a combination muscle hook and dissector. A curved caliper is a modification of an earlier instrument developed by William Scott. This newer caliper is both finer at the tip which also has a marking point and has a longer handle making it easier to use. A modification of the Moody locking Castroviejo includes a curved, heavier handle and a more durable sliding lock mechanism.

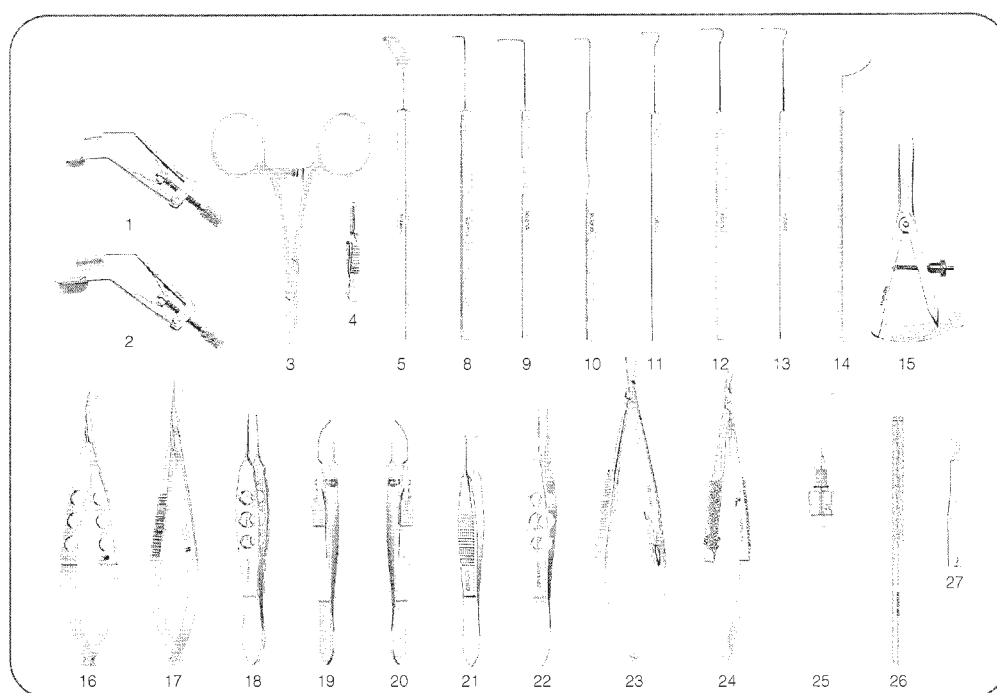


Figure 3

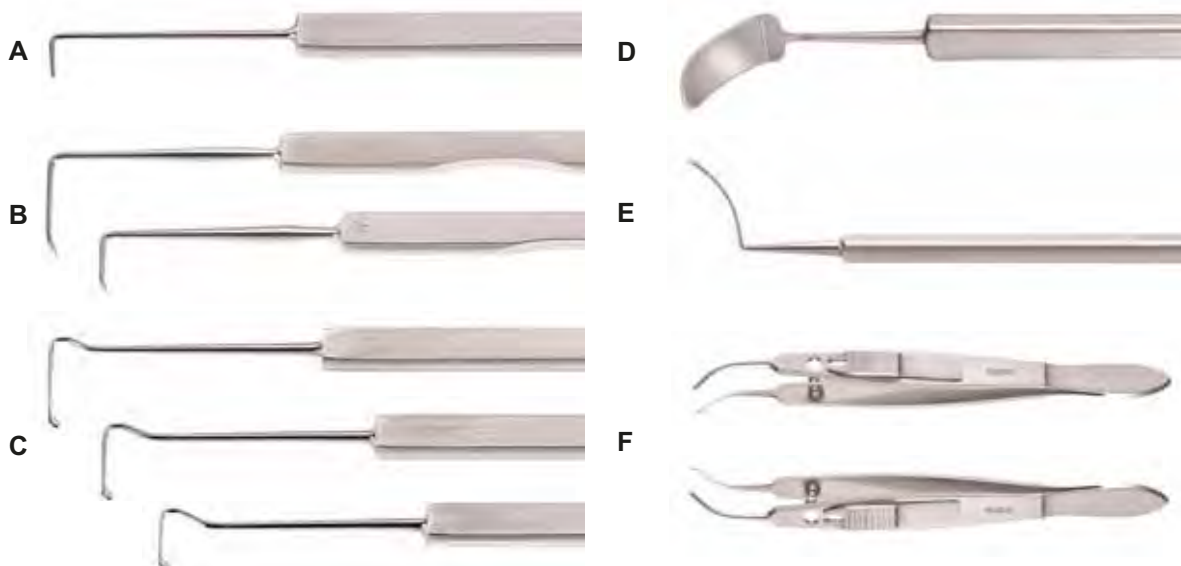


Figure 4 Helveston instruments

- A** Teaser hook
B Finder hook
C Fine muscle hooks

- D** Barbie retractor (3 sizes)
E Scleral ruler (modified from William Scott)
F Moody-Castroviejo curved locking forceps (with slider)

Other specialized instruments for strabismus surgery that have not been shown in the complete surgery set are used according to the individual surgeon's preference. These include various muscle resection clamps; the superior oblique tendon tucker in several sizes; muscle hooks with a thin metallic shield to guard against 'too deep' needle placement; the heavy 'Green' muscle hook especially used by some surgeons who perform the cul-de-sac incision; a hook with a 'double foot' to aid suture placement; and more.

The size and style of forceps depends on the surgeon's preference. In general, two sizes include the heavier size with 0.5 mm teeth and the more delicate forceps with 0.12 mm teeth, especially useful for grasping the conjunctiva. The design of the teeth, especially those found on the 0.5 mm forceps, vary in their effect on tissue grasping and tissue tearing. The Pearse forceps features a half circle cut out on each arm of the forceps that have square tips. This design is easier on tissue. There is also a wide array of needle holders either locking or non-locking with jaws of varying size and shape suitable for the needles used according to the surgeon's preference.

Sutures and needles for strabismus surgery

Overview, historical perspective

Nonabsorbable suture - early use

Strabismus surgery, introduced by Dieffenbach in 1839, was done without suture. At the outset, techniques were limited to partial or complete myotomy

or tenotomy whose only effect was to weaken the muscle. Simply cutting the muscle like this frequently produced overcorrection that was difficult or impossible to reverse. As a result, the initial wave of enthusiasm for strabismus surgery waned.

By the second half of the nineteenth century, heavy silk sutures about the size of current 4-0 or 5-0 calibre were employed to control weakening and also for muscle shortening or 'strengthening.' These silk sutures were often waxed at the time of surgery to help ease the passage through tissue. The re-usable needles for introducing this suture were large, made of round wire, and had an eye to thread the suture. Because of the bulk of these needles compared to the thickness (thinness) of the sclera, sutures secured the muscle to overlying Tenon's capsule and conjunctiva with the knots tied externally. Muscles were not anchored to the sclera as done today. These silk sutures eventually had to be removed to avoid infection or excess reaction.

Animal product absorbable suture

Absorbable, catgut suture that is actually produced from sheep intestine was introduced for strabismus surgery around the turn of the twentieth century. This suture was used widely until the early 1970's. Catgut suture offered a definite advantage over silk by being absorbable. Disadvantages of catgut suture are that it lacks strength and uniformity. These sutures also produce significant inflammatory reaction. In an attempt to remedy some of these problems, collagen suture was introduced in the 1960's. Though still an animal product absorbable suture and no stronger than catgut, collagen promised some

improvement over catgut. Collagen suture is formed by an extrusion of homogenized, pooled beef fascia and is 100% collagen, making it smooth, conformable, and easy to handle. Collagen suture also is easy to tie, producing a secure knot. Theoretically, the pooled fascia making up collagen suture should result in reduced antigenicity and therefore reduced inflammatory reaction making it superior to catgut. On the contrary, reaction with collagen is similar to that seen with catgut. Mild to moderate inflammatory reaction occurs in about one case in five and severe suture granuloma occurs in about one percent. An additional drawback is that when using either catgut or collagen, anyone but the most expert surgeon can expect to break at least one suture per strabismus surgical procedure!

Synthetic absorbable suture

Beginning in the 1970's, synthetic absorbable suture became available for strabismus surgery. This material is a polymer of sugar and is called polyglycolic acid or polyglactin 910, the latter also known as Vicryl. This uniform, braided suture is coated with a material similar to that used for making the suture itself. This coating is added to smooth the suture making for easier passage through tissue. For either recession or resection of a muscle, 6-0 suture is sufficiently strong and is the choice of most surgeons. For closure of the conjunctiva, 8-0 suture may be used. Some surgeons prefer to use an 8-0 collagen for this purpose because this suture dissolves readily and strength is not an issue for this suture application.

In addition to being both strong and uniform, synthetic absorbable suture is less likely to cause tissue reaction as seen with animal product sutures. The incidence of tissue reaction of any kind with synthetic absorbable suture is on the order of one percent or less. These sutures retain holding properties for 14 to 21 days, a time more than sufficient to ensure secure healing of the extraocular muscle to sclera, something which actually takes place in a few days. The synthetic absorbable suture absorbs completely in about three months.

In a recent survey of experienced strabismus surgeons, the introduction of synthetic absorbable suture was near the top in importance of all of the innovations for strabismus management in the past half century. Several of those surgeons considered the introduction of this suture to be *the* most important strabismus treatment advance in this period. It is likely that the re-introduction of adjustable sutures, another of the 'strabismus related top ten' events of the past half century, was made possible largely because of synthetic absorbable suture. This suture is strong enough to allow the manipulation required at adjustment while also being absorbable and minimally reactive.

A small drawback of braided synthetic absorbable suture is a tendency for the suture to engage tissue and drag this tissue along with the suture (Figure 5). This can lead to premature knotting and inaccurate tissue apposition. When using this synthetic suture, it is important for the surgeon to be aware of this and to avoid tissue 'drag' while advancing the suture. With all of the advantages offered by this new suture, this small annoyance is just that, small and manageable. Another thing to remember with this synthetic absorbable suture is that it does not

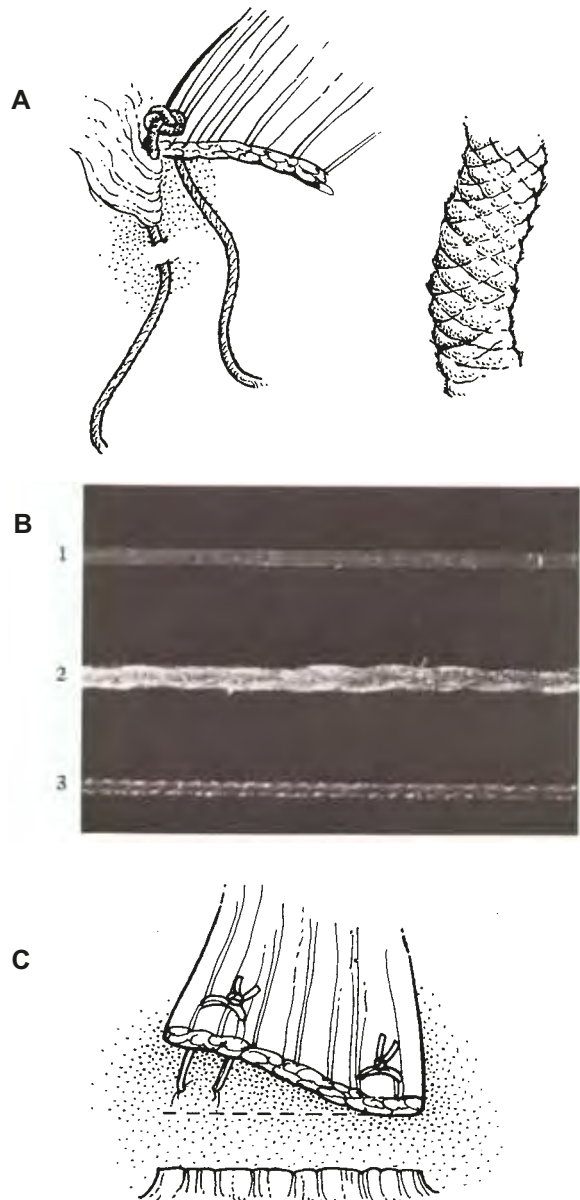


Figure 5

- A The 'rough' braided surface of braided Vicryl can lead to tissue 'grab' as it passes through Tenon's capsule
 B Comparison of 1) collagen, 2) uncoated, undyed Vicryl, 3) coated, dyed Vicryl
 C Poor muscle scleral union due to premature knotting

dissolve unless buried. Exposed knots become stiff and can be irritating. It is sometimes necessary to cut off the knots of exposed 8-0 sutures used to close conjunctiva.

Nonabsorbable suture

Nonabsorbable suture such as 5-0 or 6-0 nylon or Dacron which causes minimal reaction and is superior to silk may be used for tucking procedures carried out on the superior oblique tendon or rectus muscles. This type of suture is also useful for rectus muscle union as done with the Jensen procedure or more recently that described by Foster and Buckley for the enhancement of rectus muscle transfer. The posterior fixation suture (retro-equatorial myopexy) or ‘faden operation’ is also a place where non-absorbable sutures are useful.

Black silk sutures size 4-0 or 5-0 are useful for traction during surgery. They are placed temporarily near the limbus to pull the eye in a given direction to facilitate exposure. Another use of black silk traction sutures is to pull and then anchor the eye in an exaggerated direction for a few days after surgery. This maneuver is designed to oppose early postoperative healing that could tend to negate some or all of the weakening effects of surgery. These silk sutures are usually inexpensive and have large needles which must be inserted into episclera with care, but which easily pass through the lids when necessary.

Needles

The ‘anatomy’ of an ophthalmic needle is shown in Figure 6. The relationship of needle size and configuration and anatomy of the sclera is discussed in Chapter 2. The choice of a needle for strabismus surgery is based in part on surgeon's preference, availability of needle and suture combinations, and the unique requirements of a given procedure. For recession and resection, a spatula needle with a wire diameter of .203 mm is suitable. The surgeon should be aware that the configuration of the tip of the needle will influence the path of the needle while passing through sclera. If the tip bevels downward, the needle will tend to go deeper into and even through sclera. A neutral tip will go where the needle is directed and a tip beveled upward will have a tendency to cut out and therefore must be continually directed slightly downward to stay in sclera. Any of these needle types is acceptable, but for safety, it is necessary for the surgeon to be aware of the needle configuration. If there is any question, the surgeon should examine the needle tip with magnification before the surgery is begun.

Needle placement in sclera

How deeply should the needle (suture) be placed in sclera and how long should the suture track be placed in sclera to ensure secure attachment of the

muscle to sclera? To answer these questions, Coats and Paysse placed 6-0 Vicryl sutures into human bank sclera with the suture track at various depths and lengths and then measured the force necessary to pull the suture free from sclera. The results showed that suture placed in a track 1.5 mm or longer at a depth of at least 0.2 mm required in excess of 200 gm force to cause the suture track to fail. This is a greater force than can be expected in the physiologic state, indicating that this manner of suture placement in sclera is both safe and effective (Figure 7).

Some surgeons prefer the ‘crossed swords’ needle placement as described by Parks (Figure 8). With this technique, the needles are passed through sclera for approximately 5.0 mm or longer. These

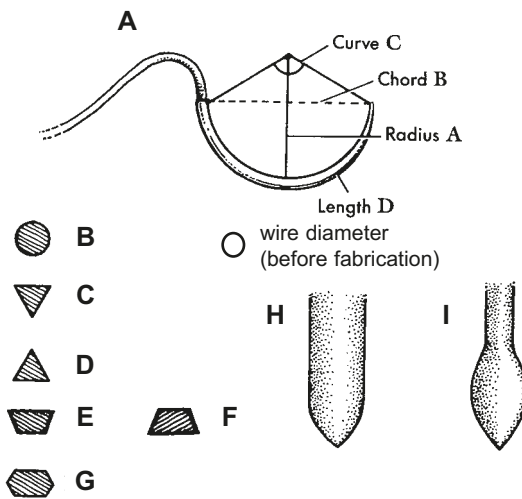


Figure 6
 A Various dimensions
 B Round
 C Cutting
 D Reverse cutting
 E Keystone - up cutting tip
 F Keystone - down cutting tip
 G Hexagon - neutral tip
 H Parallel
 I Cobra head

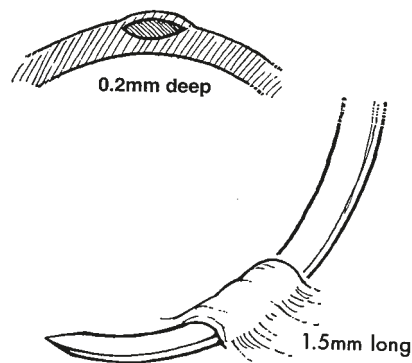


Figure 7

two long shallow bites do not provide any more security for muscle attachment to the globe once the sutures are tied, but this technique does allow the muscle to remain securely at the point of intended recession against the sclera even before the suture is tied because of friction in the suture tunnel. When using the 'crossed swords' technique, the first needle is left in place until the second needle is inserted into sclera. Each needle is then advanced in turn until both needles just clear sclera. After this, the suture on each needle is advanced in turn. This maneuver is carried out to avoid having the sharp side of the spatula needle cut the other end of the suture being advanced. A needle with a 'down' directed tip makes this maneuver easier to perform, but extra care is required to prevent the needle from going 'too deep.'

Perforation of sclera by a needle placed too deeply probably occurs more frequently than is suspected. Morris, et. al. in a prospective study found one perforation in 67 patients, 100 eyes. This is likely to be a reliable statistic (1%) even for experienced surgeons. A 'too deep' suture rarely causes a problem. Moreover, it is not usual practice for a surgeon to dilate the pupil and look at the retina over the site of muscle reattachment, meaning that most of these occurrences probably go undiscovered and unreported. This may be for the best since overzealous attempts at treating these mostly innocuous retinal perforations has resulted in serious complications including loss of the eye (Figure 9).

Anesthesia for strabismus surgery

The choice of anesthesia (general, dissociative, local, or topical) for strabismus surgery is influenced by age of the patient, the wishes of the patient, the requirements of the patient's strabismus condition, and finally by the experience or preference of the surgeon. The popularity of adjustable sutures, often adjusted during surgery, has made the use of topical and local anesthesia more common in recent years. A few surgeons use general anesthesia in cases with adjustable suture, reinstating a brief general anesthetic for adjustment. If general anesthesia is the choice, the anesthesiologist decides on the specific agent or agents to be used, as well as the amount and type of premedication. For patients using echothiophate iodide (phospholine iodide), the use of succinylcholine is definitely contraindicated. A patient who has been treated with echothiophate iodide can retain low blood levels of pseudocholinesterase for weeks or even months after discontinuing the medicine. In the presence of low blood pseudocholinesterase levels, succinylcholine causes prolonged apnea that may require the patient to be assisted by a respirator for several hours after surgery to ensure proper breathing. If there is any question

about the safety of using succinylcholine, it should not be used. As a substitute, pancuronium, or other nondepolarizing muscle relaxant, may be used.

In cases scheduled for general anesthesia where a family history of malignant hyperthermia is uncovered, pre-treatment with dantrolene is required. Study of phenylketopyruvate serum levels can be useful in predicting susceptibility to malignant hyper-

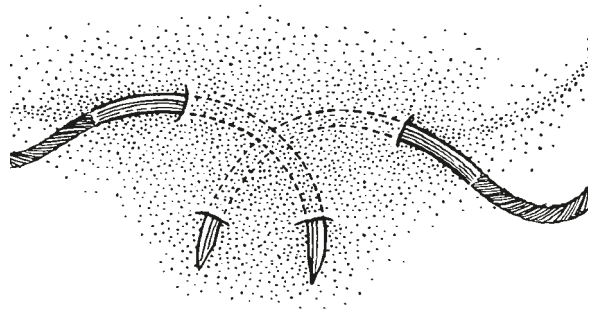


Figure 8

The 'crossed swords' technique of Parks.

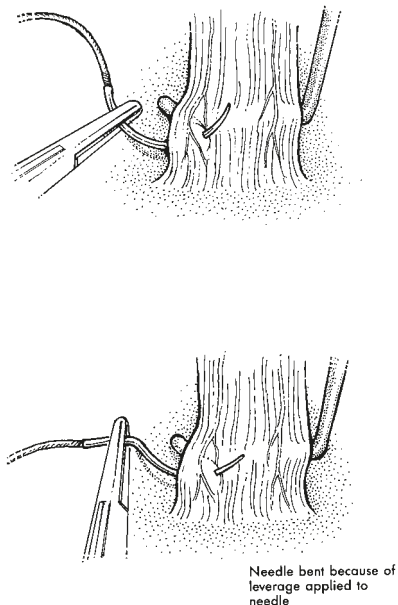


Figure 9

Fine ophthalmic needles should be advanced along their curve and not 'forced' through tissue or used excessively to lift tissue. Failure to observe this can result in a bent needle.

thermia in a patient with a questionable family history. When a patient with malignant hyperthermia or a suspicion of this condition is to be given general anesthesia, in addition to pre-treating the patient with dantrolene, the anesthesia machine is flushed with oxygen for 24 hours to rid the machine of all traces of halothane. The preferred general anesthetic regimen for patients with malignant hyperthermia is fentanyl, nitrous oxide, and a muscle relaxant.

General anesthesia

Most immature patients (younger than mid-teens) require general anesthesia for extraocular muscle surgery. This anesthetic is administered through an endotracheal tube or with a laryngeal cuff with the anesthetic agent(s) and oxygen delivered directly to the lungs. The agent most commonly used for general anesthesia is halothane (Fluothane). Other agents such as fluroxene (Fluoromar); cyclopropane; methoxyflurane (Penthrane); and a combination of nitrous oxide, barbiturate, and narcotic may be used but have no advantage over halothane. Thiopental sodium (Pentothal) given intravenously or nitrous oxide given by mask is the most common agent used for induction before intubation. Versed 0.5 mg/kg may be used as a pre-anesthetic calming drug in excitable younger children between ages 1 and 7 years. It is given in a grape-flavored liquid in the outpatient holding area. Open-drop ether, which had been used for induction of anesthesia for infants, is now of historic interest. Ether has a wide margin of safety, but postoperative vomiting is frequent.

Preoperative medication for infants should be limited to a moderate dose of atropine given intramuscularly. The dose for preoperative atropine is 0.01 mg/kg, with a minimum of 0.1 mg and a maximum of 0.4 mg. Older children and adults having general anesthesia may require narcotics and, in some cases, barbiturates in addition to atropine. The doses should be selected on an individual basis.

Preoperative narcotic is associated with a higher incidence of postoperative nausea and vomiting. With the advent of outpatient surgery, pre-medication is omitted except in cases where Versed is used. Preoperative medication with droperidol 0.075 mg/kg has been said to reduce postoperative vomiting from 60% to 16% when given intravenously before muscle manipulation. This medication does not prolong the patient's recovery to full alertness or the time in the recovery room. Outpatient strabismus surgery can be performed safely with only versed for pre-medication and without other prophylaxis for postoperative vomiting. Even with this 'minimalist' routine, postoperative vomiting occurs rarely.

A new agent for general anesthesia is Propofol (Diprivan), a drug which is administered intravenously. Propofol has the advantage of reducing the incidence of nausea and vomiting after eye muscle sur-

gery. There is also less anesthesia 'hangover' and less postoperative analgesic agent may be needed. The induction dose is 2 to 3 mg/kg. Anesthesia is maintained with an IV drip titrated at approximately 200 mg/kg/min. Low doses of nitrous oxide or halothane may be used to supplement anesthesia.

When an adjustable suture is used and adjustment is contemplated for the afternoon of surgery, preoperative and postoperative narcotics should be withheld, used in a limited fashion, or reversed after the operative procedure using naloxone (Narcan).

With outpatient surgery now routine and narcotics and barbiturates withheld from children preoperatively, a dramatic reduction in postoperative vomiting is noted. The advantage of being able to use a slightly reduced amount of general anesthetic agent after pre-medication with narcotics is outweighed by the fact that after a short procedure, a heavily pre-medicated patient may exhibit prolonged drowsiness, not from the general anesthetic agent, but from the preoperative medications.

General anesthesia allows the surgeon more freedom in manipulation of the muscles and accurate interpretation of passive ductions. Therefore, many surgeons prefer general anesthesia for all strabismus surgery. As with general anesthesia used for any type of surgery, patients undergoing strabismus surgery should be monitored constantly by the anesthesiologist in order to diagnose immediately emergencies such as arrhythmia, hypoxia, bradycardia associated with the oculocardiac reflex, or cardiac arrest.

When bradycardia from the oculocardiac reflex occurs, all tension on the muscle should stop immediately, and the muscle should not be placed under tension again until the heart rate returns to normal. It is not necessary to remove the muscle hook from behind the muscle's insertion, but the surgeon must relax all pressure on the muscle insertion. If repeated muscle stimulation causes further bradycardia, the patient should be given intravenous atropine by the anesthesiologist, the dose is usually the maximum 0.4 mg intravenously. The use of atropine in adults to block the oculocardiac reflex increases the likelihood of cardiac arrhythmia such as bigeminy. Bradycardia persisting after atropine has been injected intravenously may be treated with a retrobulbar injection of 1 to 3 ml of 1% or 2% lidocaine (Xylocaine). Bradycardia from the oculocardiac reflex rarely disrupts the normal conduct of surgery. If it does occur, it requires just a few seconds pause. With real-time, accurate monitoring, including audible pulse recording, the surgeon should be able to recognize the earliest signs of bradycardia and reduce the pull on the muscle. This usually leads to restoration of the patient's normal heart rate in just a few seconds. Cardiac arrest is treated with ventilation and closed chest heart massage both begun immediately. If cardiac contraction does not begin after several minutes,

3 to 5 ml of intravenous epinephrine 1:10,000 may be given. I have no personal experience with this or other more radical measures.

Dissociative anesthesia

Ketamine, a dissociative anesthetic, has been used for a variety of ophthalmic procedures, including strabismus surgery. With ketamine, the patient has no cognizance of pain because the drug causes a dissociation between the painful stimulus and any awareness of the stimulus. Involuntary movements of all parts of the body, including the eyes, do persist with ketamine, and tonus of the extraocular muscles remains. Therefore, the eye must be stabilized with traction sutures and the surgeon must be constantly on the alert for unexpected ocular movements. The persistent muscle tonus also makes interpretation of passive ductions less reliable. Patients under ketamine anesthesia also secrete saliva freely, which requires suction during the procedure. The dose of ketamine is titrated to effect and is often given with other analgesics or sedatives.

In older children and adults, the combination of prolonged drowsiness, disturbing dreams, and hallucinations is a significant drawback to using ketamine. The disadvantages of ketamine may outweigh its advantages for strabismus surgery. However, ketamine's unique properties make it an ideal agent when anesthesia is required for injection of Botox in infants and children young enough to avoid the side effects. Persistent firing of the motor end-plates, which can be detected by electromyography, allows accurate local-

ization of the needle before injection. Ketamine anesthesia is used widely, usually with other appropriate agents, in developing countries for strabismus surgery because of its wide margin of safety. Anesthesiologists skilled in the use of ketamine can administer this drug effectively and apparently with few of the drawbacks listed here.

Local anesthesia

Perilimbal anesthesia

Either 1% or 2% lidocaine (Xylocaine), with or without epinephrine 1:100,000 added, provides satisfactory local anesthesia for strabismus surgery in cooperative teenagers and adults (Figure 10). For perilimbal anesthesia, between 1 and 3 ml of the agent is injected into the subconjunctival space for 360 degrees around the limbus. This is followed by 1 minute of gentle massage with the fingers through a 4" x 4" gauze pad over the closed eye. Surgery may then begin. A variety of other techniques for anesthetizing the anterior part of the eye to allow safe and effective eye muscle surgery including peribulbar anesthesia can be employed. In all cases where local or topical anesthesia is used, oxygen is provided continuously via nasal catheter under the drapes. With oxygen used this way, care should be exercised to keep open flame or 'red hot' thermal cautery away from the flowing oxygen to avoid fire. In addition, an intravenous line is kept open with a normal saline drip and constant ECG monitoring is maintained. An anesthesiologist may be in attendance and may use intravenous analgesics as needed.

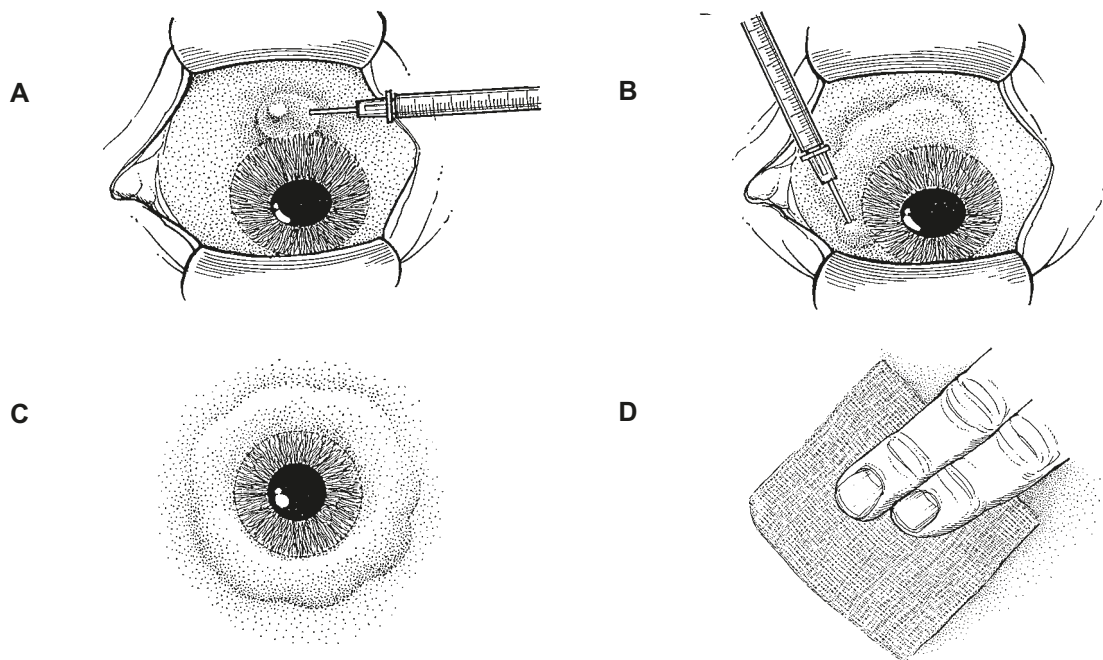


Figure 10

A A small subconjunctival bleb is raised
 B Injecting into the previous bleb, the limbus is ringed

C Up to 3 ml of anesthesia has been injected
 D Gentle massage is carried out

Retrolbulbar anesthesia

For retrolbulbar anesthesia, 2 or 3 ml of 1% or 2% lidocaine (Xylocaine), with or without epinephrine 1:100,000 added, is injected into the retrolbulbar space (into the muscle cone). A 38 mm, 25-gauge needle on a 5 ml syringe is used. The needle tip enters through the skin just inside the orbital rim at the junction of the inferior and lateral orbital rim. The needle is directed slightly medially and superiorly for nearly the full length of the needle. The agent is then injected slowly. Some surgeons inject slowly while the needle is entering to push tissue away from the tip. One may also retract the plunger to ensure there is no backflow of blood before injecting. This avoids inadvertently delivering the agent intravenously. In the rare event of a retrolbulbar hemorrhage, surgery is postponed.

After approximately 5 minutes, surgery may begin. A successful retrolbulbar injection gives satisfactory anesthesia to the anterior globe and extraocular muscles. However, the patient may experience pain deep in the orbit, presumably in the area of the ligament of Zinn, when muscles are tugged on, particularly during a resection procedure. Patients also may experience pain when the insertion of a muscle is manipulated. Adjustment of a suture can be done several hours after retrolbulbar anesthesia. Proper timing for adjustment can be determined by observing full rotations of the eye.

The awake patient

The surgeon must exercise greater care when performing surgery under any type of local anesthesia with the patient awake. Care must be taken to ensure gentle manipulation and to exert very little traction on the extraocular muscles because of the deep orbital pain this maneuver produces at the origin of the muscles. Topical tetracaine or xylocaine 5% anesthetic drops may be placed on the cornea and on the operative site both before initial injection of lidocaine and repeatedly during the procedure. Anesthetic agent may be injected before the patient's face is prepared with the surgical scrub and before the surgeon scrubs. This interval allows sufficient time for the anesthetic agent to take effect. If needed, additional lidocaine is injected around the operative site during the procedure. The conjunctival anesthesia usually wears off sooner than that around the muscle insertion. During the procedure, the patients may also receive the synthetic narcotic agents, fentanyl citrate 2 mg/kg, and diazepam 0.25 mg/kg. The smallest possible amounts of these agents are given to ensure patient alertness, especially when the patient is asked to cooperate during adjustment of alignment on the table.

Topical anesthesia

Surgery may be performed on the extraocular muscles of a cooperative adult using only tetracaine or cocaine hydrochloride 4% solution instilled in the cul-de-sacs and on the cornea before surgery and repeatedly on the operative site during surgery. Several drops of lidocaine (Xylocaine) 5% may also be used topically. Because this technique demands an extremely cooperative patient combined with a surgeon who uses delicate technique, it has limited application. With use of topical or local anesthesia, it is possible to employ cover testing and/or diplopia testing during surgery with the patient either lying on the table or sitting up. Results for surgery may be enhanced by this 'on the table' testing which allows adjustments in the amount of surgery at a time when the surgeon is free to titrate the amount of surgery. It is not necessary to block the lids for successful surgery.

The use of local and topical anesthesia demands cooperation by the patient and intense concentration by the surgeon. Local anesthesia can be used for both first surgeries and repeat surgeries. In some cases, the opportunity to adjust surgery on the table and the fact that the patient avoids the postoperative discomfort frequently associated with general endotracheal anesthesia makes the extra effort using local and topical anesthesia worthwhile.

Preparation of the patient in the operating room

The patient should be positioned with the head at the end of the operating table. The surrounding area should be free of unnecessary equipment. If general anesthesia is used, connectors should be fashioned so that tubes will not interfere with the surgical field. Although the endotracheal tube is well anchored, the surgeon should always warn the anesthesiologist before moving the patient's head. After anesthesia has been obtained, the area around both eyes should be washed thoroughly. The skin in the area outlined in Figure 11 is washed using Betadine soap or equivalent and water for 1 to 3 minutes followed by a thorough rinse with sterile water. Several drops of Betadine solution are then placed in the cul-de-sacs. This solution is then rinsed from the eyes with sterile normal saline. An iodine preparation may then be painted over the area that has been scrubbed and the skin is blotted dry. It is not necessary to trim the eyelashes. Cloth drapes or self-adhering drapes are placed over the nose, forehead, and sides of the head. After this draping is completed, forced ductions are carried out in all directions in both eyes. A self-adhering monocular plastic drape or equivalent is then placed over the lids with the adhesive applied to the lids and periocular area (Figure 11).

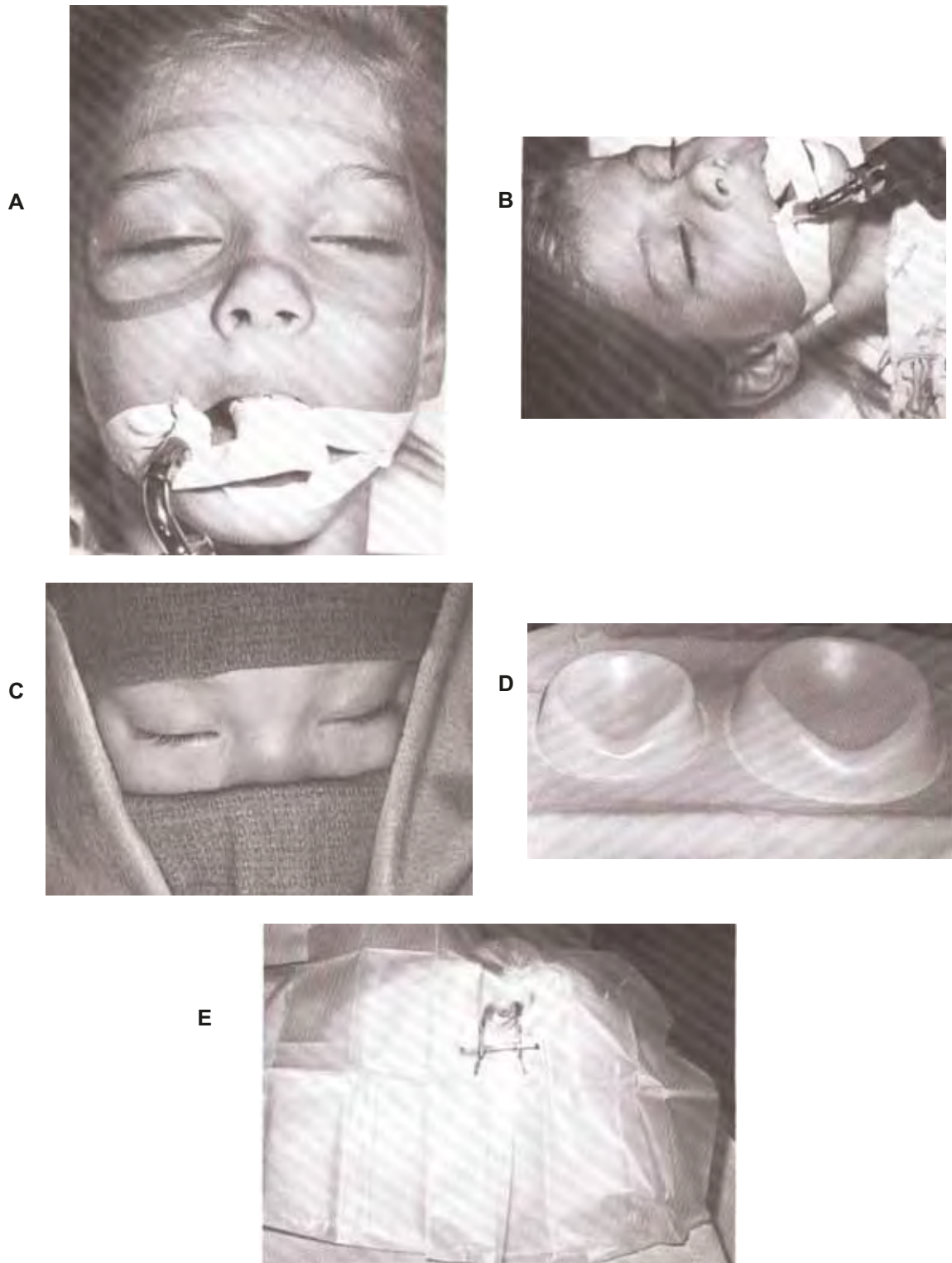


Figure 11

A Area of skin washed
B Endotracheal tube firmly anchored
C Cloth drapes

D Concave head support
E Fully draped operative site using disposable drapes (cloth may also be used).

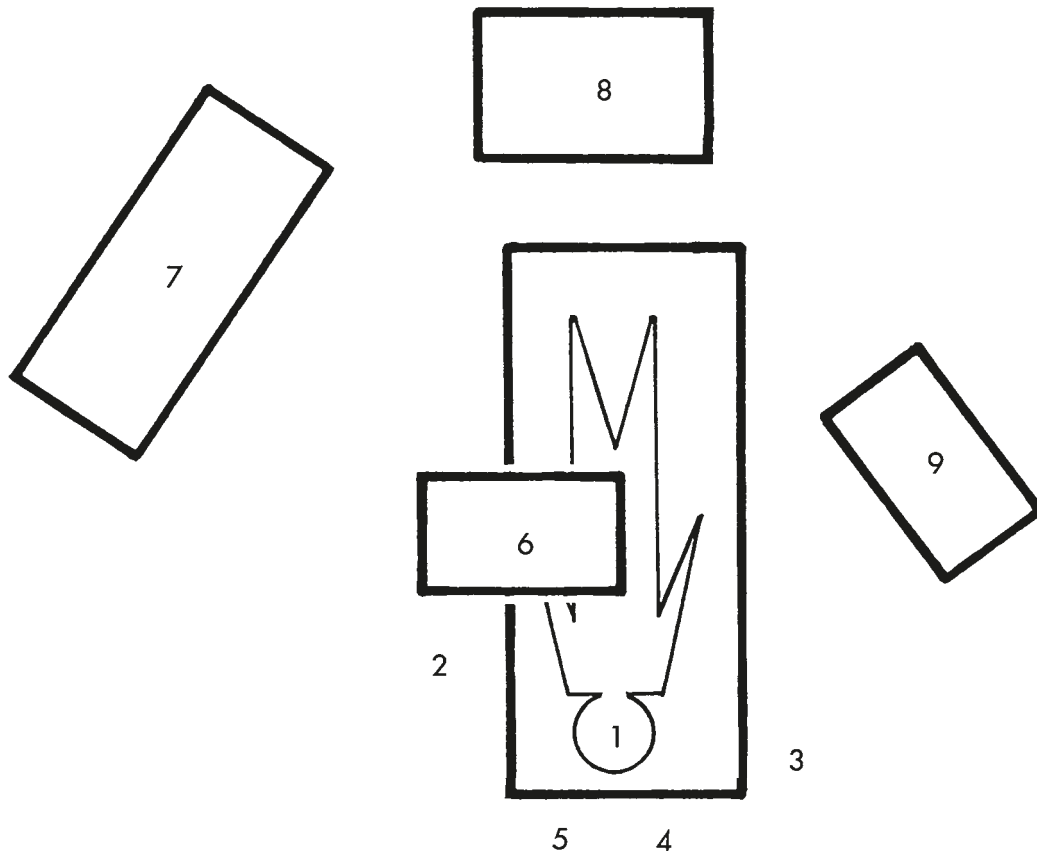


Figure 12

1) Patient (the most important part); 2) scrub nurse; 3) anesthesiologist; 4) surgeon; 5) assistant; 6) 'Mayo' instrument stand; 7) back table for drapes, solutions, etc.; 8) viewable monitors; 9) anesthesia machine

Layout of the operating room and anesthetic apparatus

The layout of the operating room may include the features illustrated in Figure 12. This is a scheme which is common and convenient.

Patient monitoring

In the ideal setting, after endotracheal anesthesia has been established, the patient monitor and safety devices are connected (Figure 13). The array is as follows: (1) endotracheal tube, (2) mass spectrograph lead, (3) esophageal stethoscope, (4) nasal temperature probe, (5) ECG leads, (6) heating blanket, (7) Doppler arterial flow sensor, (8) sphygmomanometer cuff, and (9) indwelling intravenous catheter. The monitoring display unit situated at the foot of the operating table in clear view of both the surgeon and the anesthesiologist is ideal but not a requirement. This setup when available provides clearly presented,

real-time information available to surgeon, anesthesiologist, and nurses. Information that is available includes ECG configuration, pulse, temperature, and oxygen and carbon dioxide saturation levels. For more detailed study, the ECG paper strip may be run. The pulse rate is displayed on a digital readout. The temperature is constantly displayed on the digital screen. One of the most effective monitoring capabilities of modern anesthetic machines is the constant monitoring of expired carbon dioxide seen on the anesthesia console (Figure 14).

Many surgeons are more comfortable seated when operating (Figure 15). A variety of stools are available. It is important that the surgeon choose one that he or she can adjust to prevent unnecessary interruption of surgery required while an assistant adjusts the surgeon's stool.

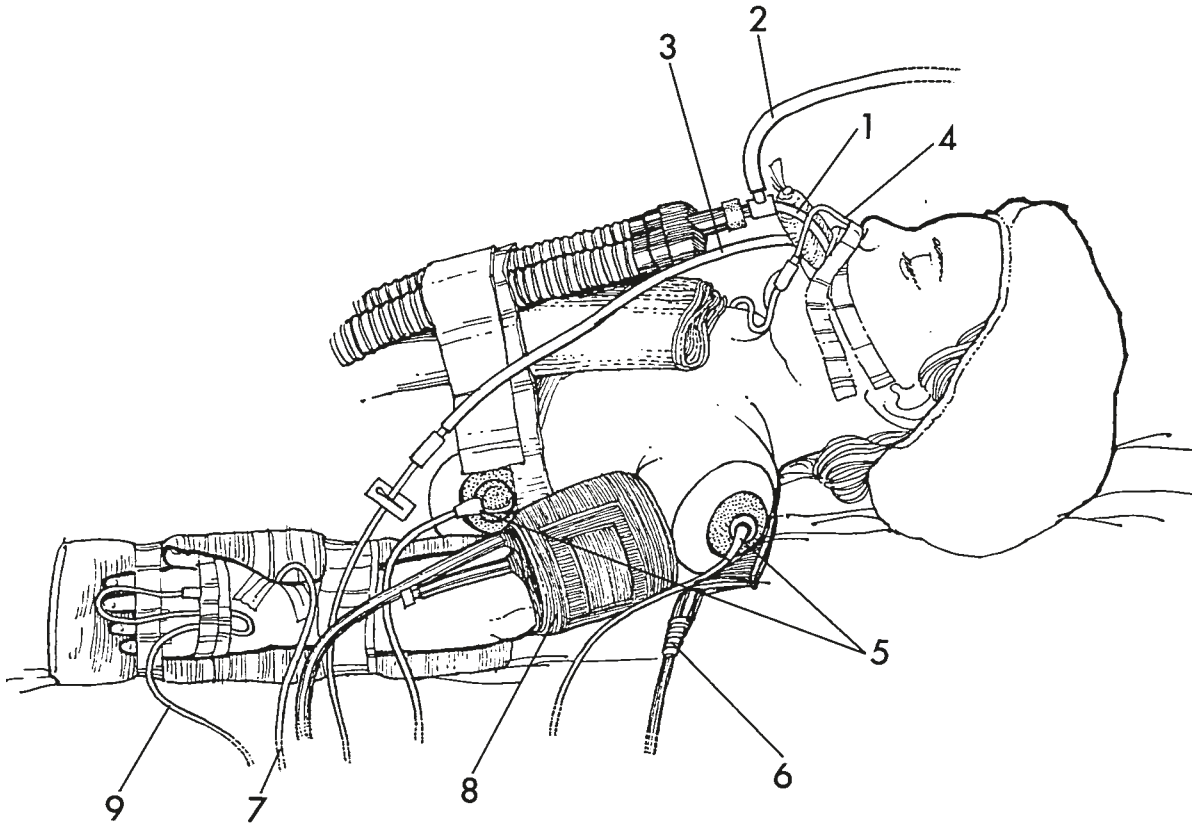


Figure 13

- 1 endotracheal tube
- 2 mass spectrograph lead
- 3 esophageal stethoscope
- 4 nasal temperature probe
- 5 ECG leads
- 6 heating blanket
- 7 Doppler arterial flow sensor
- 8 sphygmomanometer cuff
- 9 indwelling intravenous catheter.

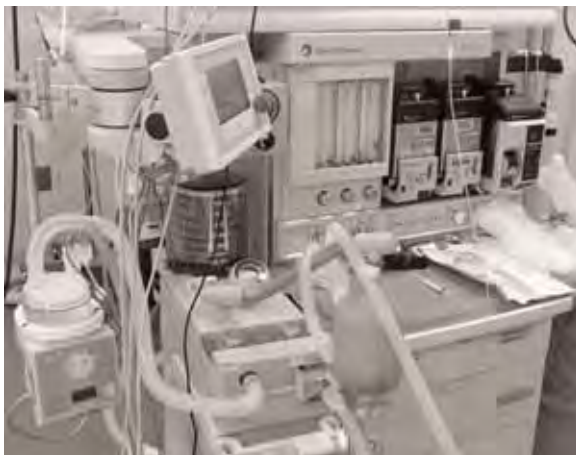

Figure 14
Console of a modern anesthesia machine

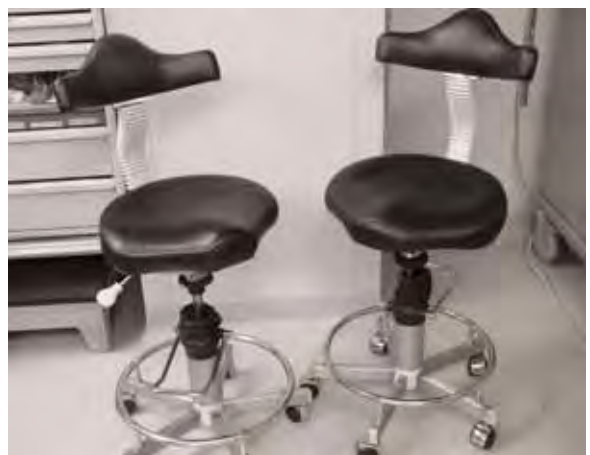

Figure 15
Surgeon's adjustable stool

Magnification in strabismus surgery

The use of smaller diameter suture material and finer, sharper needles has made it preferable, if not necessary, to use magnification for strabismus surgery. Telescopes mounted on glasses frames or on a headband are extremely useful. The magnification may vary from 2.5X to 4.5X. The limiting factors in magnification include (1) surgeon's comfort, (2) restricted field size, (3) limited depth of focus, and (4) need for increased illumination.

For comfort, a properly fitted pair of spectacle frames with a wide elastic band behind the head connecting the temple pieces of the glasses frame works well (Figure 16). The surgeon soon becomes accustomed to the various restrictive factors associated with use of a magnifying device while enjoying the improved view. If the surgeon has presbyopia, he or she may choose to place a suitable add low in the spectacle lens to obtain a wider useful field of vision when looking at near, but away from the operative field and 'around' the loupes (Figure 17).

How much magnification is best?

Field size decreases with increase in magnification. The trade-off should be arrived at by the surgeon through a trial and error method. Working distance is unique to the particular magnifying instrument used. This should be selected according to the surgeon's preference, but the working distance should not be too close. Depth of focus also should be determined by trial and error. Illumination may be improved by using an overhead operating room light that is properly adjusted. Some surgeons prefer additional light supplied by a head-mounted fiberoptic light (Figure 18).

A few surgeons use a floor-mounted or ceiling-mounted microscope for strabismus surgery. This technique provides excellent magnification and illumination; however, with this technique, the surgeon is even more severely restricted. Those surgeons who use a microscope for strabismus surgery are strong advocates for this technique. I suspect that once a surgeon has used the operation microscope and is reconciled to the trade off, it is difficult to go back to lower magnification. The optics and illumination of the operation microscope can be used to obtain videotapes of strabismus procedures. During these cases, the surgeon may elect to use a loupe for magnification while operating 'around the microscope.' Some surgeons who use the technique of anterior ciliary vessel salvage while recessing or resecting an extraocular muscle have recommended use of a microscope.

Wearing a mask

A mask of paper or cloth should be worn by *all* personnel in the operating room. It is disturbing to see a mask worn *below* the nose. This is a breach of technique seen all too often in some operating rooms of the world. This lapse of technique should not be tolerated. It defeats the purpose of the surgical mask.



Figure 16 Operation telescopic loupes



Figure 17
Zeiss telescopic loupes mounted on a sturdy spectacle frame with an elastic head strap

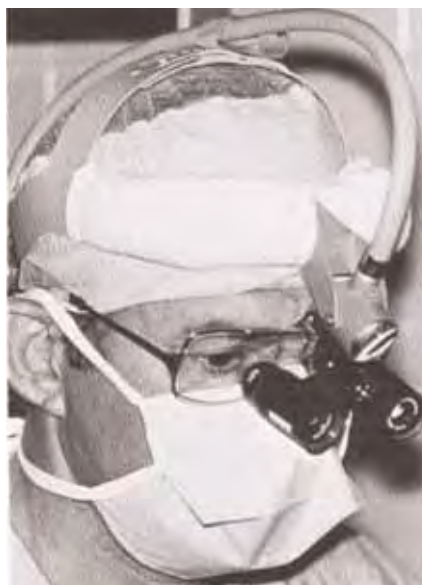

Figure 18
A fiber optic head-mounted spot light provides superior illumination especially when working in a deep, narrow cavity.

Outpatient surgery: the day of surgery

A scheme for outpatient surgery begins with the patient arriving and checking in at the outpatient surgery unit. For 8:00 AM surgery, arrival time is between 6:30 and 6:45 AM. The patient may go to the laboratory, if a hemoglobin-hematocrit is to be obtained. If done in advance of the day of surgery, laboratory results usually remain valid for 30 days in an otherwise healthy patient. Depending on the age and health of the patient, the anesthesiologist may choose to waive the hemoglobin determination. The patient returns to a holding area where the surgeon verifies the ocular motility findings, reviews the surgical plan, obtains operative consent, obtains a pertinent medical history, and performs a brief physical

examination. The anesthesiologist also obtains a history, performs a physical examination, and obtains consent for the anesthesia. Pre-medication with Versed may be given in selected children at this time. The patient is taken to the operating room where the surgery is carried out. After surgery the patient is taken to the recovery room and remains there until fully reactive. This takes 20 to 40 minutes or longer. The intravenous line is usually discontinued before the patient leaves the recovery room. The patient returns to the outpatient area holding room. The patient leaves the outpatient area (for an 8:00 AM case, approximately 2:00 PM) (Figure 19).

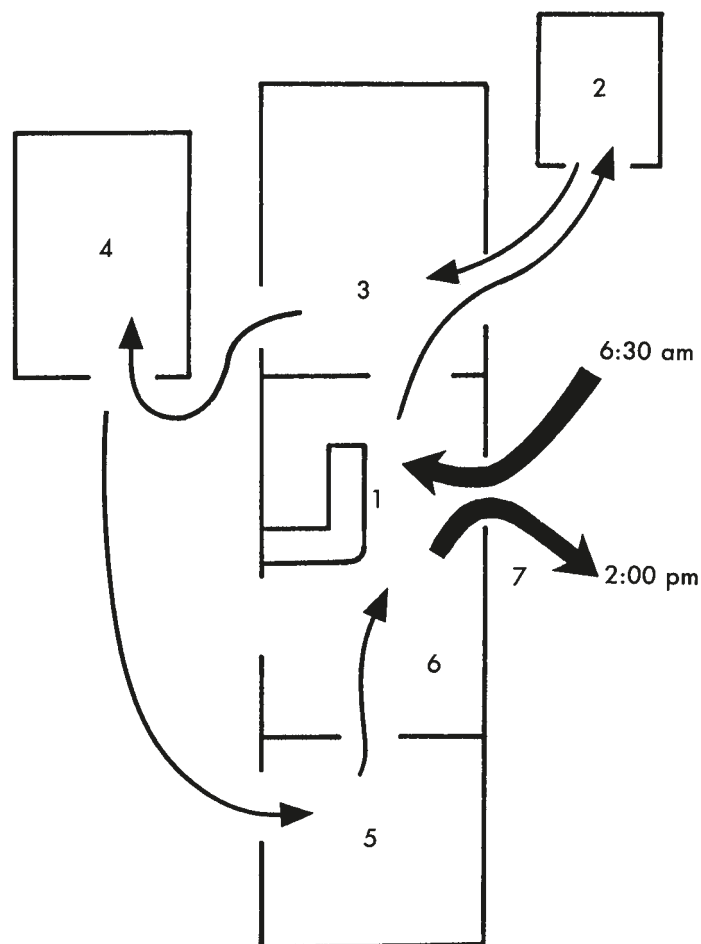


Figure 19

- 1 Check in
- 2 Laboratory, if needed
- 3 Physical examination/consent holding area
- 4 Operating room
- 5 Recovery room (patient could be discharged from recovery room)

- 6 Postoperative holding area (could be same room as pre-operative holding)
- 7 Discharge

Postoperative care of the patient

A patch may be used postoperatively over one eye, but never over both eyes. Any questionable benefit resulting from reduced ocular motility when bilateral patches are used is far outweighed by the emotional trauma this practice causes. If both eyes have been operated on with a single muscle treated in each eye, no patch is used. If a recession-resection has been performed on one eye, a patch may be placed on the operated eye for 24 hours and then removed. If three or more muscles are involved and both eyes have been operated on, the eye with greater reaction may be patched for 24 hours only. A patch for at least one eye is definitely indicated when the cornea has been abraded during the course of surgery. In addition to using the patch in cases of corneal drying/abrasion, homatropine 5% or other longer acting cycloplegic drops are placed in the cul-de-sac and sulfacetamide sodium and prednisolone combination or equivalent drops are used. Ointment is avoided.

As with patching, the use of drops or ointments postoperatively varies from surgeon to surgeon. Some prefer none, whereas others use antibiotic drops or ointment, and still others use antibiotics and steroids in combination. An ointment with sodium sulfacetamide and prednisolone combined, once or twice a day for 5 to 10 days is a safe choice. Although rare, infection after eye muscle surgery does occur and the morbidity from use of antibiotics and steroids is extremely low. Patients also tend to be more comfortable with drops.

Patients, parents, or other family members are contacted immediately after surgery and a 'report' is given on the patient's response to surgery. This is done preferably in person or by phone. Within the first 1 or 2 hours after surgery, the patient's ocular motility is checked in the holding area. Patients are discharged routinely 2 to 4 hours after surgery. The time between the end of surgery and discharge from the outpatient postoperative holding area varies from

patient to patient, according to the type of anesthesia, and depends entirely on the effects of anesthesia. When local or topical anesthesia is used in adults, they frequently leave the area in an hour or less. When a general anesthesia is given, children are required to stay for a minimum of 1 to 3 hours before the anesthesiologist discharges them. Before patients who have had general anesthesia are discharged, it is prudent to determine that they can retain clear liquids in small amounts.

Patients are seen 1 week and again 8 weeks postoperatively. At the 8-week visit, the results of surgery are usually apparent. In cases where early postoperative treatment such as prisms, patching, or other techniques are necessary, the postoperative routine is individualized according to the patient's needs. Specific postoperative management for individual cases is discussed in later chapters.

Less than 1 in 50 patients scheduled for outpatient surgery has an unplanned overnight admission, usually for one of two causes: persistent vomiting or breathing difficulties. The incidence of postoperative vomiting has decreased dramatically in both severity and frequency with the advent of outpatient surgery. The most obvious variable is the fact that outpatients are not receiving preoperative narcotics. Careful preoperative evaluation by both the surgeon and the anesthesiologist identifies most infants and children who have the potential for postoperative breathing difficulties because of upper respiratory infection. When a potential problem is identified during the preoperative work up, surgery is cancelled or the anesthesiologist takes special precautions. However, the best precaution is to tell parents if they have any question about their child's health to call the outpatient facility the day before scheduled outpatient surgery. A proper decision made at this time could save an unnecessary trip to the hospital.

Section 2

Chapter 4: Work up of the strabismus patient

Chapter 5: Diagnostic categories and classification of strabismus

4

Work up of the strabismus patient

Design of the surgical procedure

Certain principles have proven useful to me in the surgical management of strabismus over the past forty plus years. They will be presented here in the form of guidelines. These guidelines are at times specific and at other times general, but in all cases the intent is to present enlightened opinions based on what I have *learned*, rather than dogma stubbornly held to because it was what I was *taught*. These guidelines, when properly applied to a specific case, are intended to lead to the design of a surgical procedure that will be customized to the individual and his or her strabismus problem. This plan for surgery must be arrived at dynamically with three basic components contributing to the ultimate surgical design. These components should be determined accurately, understood thoroughly, and combined logically. When these logical but simple steps are carried out, the answers to the questions of design - *which muscle* and *how much surgery* - should be clear or at least 'clearer' to the surgeon. After a plan has been established two additional steps in the surgical management of strabismus, surgical technique and follow-up, will be covered.

Step 1

The ophthalmologist first obtains and records a pertinent history and compiles is an accurate, complete set of measurements that include an accurate cycloplegic refraction. This latter, often underrated, component of the strabismus evaluation is especially important if any hyperopia is present in a patient with an esodeviation. If any question remains regarding the accuracy of the cycloplegic refraction, it should be repeated until accuracy is assured. Objective, automated refraction is a useful examination tech-

nique. It provides rapid measurement of the refractive error after cycloplegia with values similar to retinoscopy carried out by an experienced examiner. However, the surgeon in training should learn the technique of accurate, *on axis* retinoscopy. This is the only technique for refraction suitable for the infant, toddler, and preschool child.

Step 2

Second, the surgeon should be aware of surgical options available for a given condition. The surgeon should have the ability to carry out these procedures with skill and confidence. The importance of technique in performing strabismus surgery cannot be overemphasized. The surgeon also must know approximately how much change in ocular alignment will be produced with each procedure in *his or her own hands*.

Step 3

The third step in the design of the surgical procedure joins steps 1 and 2 and is the 'art of strabismus surgery.' This aspect of the surgical design deals with how various types of patients and various categories of deviations respond to given amounts of surgery. The *anticipated* response in a given patient, therefore, modifies the results to be expected from a particular procedure. In addition, the most desirable end result that could be obtained from surgery such as slight overcorrection or undercorrection can be determined, but only after careful evaluation has led to a thorough understanding of the patient. For example, a patient with a large deviation will obtain more correction per millimeter of surgery than a patient who has a smaller deviation; esotropic patients with amblyopia may

be overcorrected with the same amount of surgery that would produce an undercorrection in a nonamblyopic patient; patients with fusion potential should be slightly overcorrected; patients without fusion potential should be undercorrected, and so on. Adults without fusion potential always look better with a small-angle exotropia compared to a small-angle esotropia.* This extra bit of insight as to how a particular type of patient will respond to a given amount of surgery helps the surgeon combine each patient's needs with the type and amount of surgery required. In this way the likelihood of a good result is maximized.

It should be understood that all appropriate nonsurgical treatment that would eliminate the need for surgery or enhance the results obtained from surgery including treatment for amblyopia should be carried out. These include such measures as the correction of hyperopia in esotropic patients suspected of having an accommodative element to their esotropia and, when suitable, the use of prisms, anticholinesterase drops, and appropriate orthoptic exercises. Botox treatment must be considered in selected patients, but in my experience this treatment is indicated in only 3% of cases. A detailed discussion of nonsurgical treatment of strabismus will not be provided in this book.

The following specific nonsurgical procedures are worth mentioning briefly:

1. Anticholinesterase drugs are used for treatment of refractive-accommodative esotropia. Echothiophate iodide (Phospholine) 0.125% or 0.06% used as often as one drop once each day in each eye or as little as once per week in each eye can reduce or, in some cases, eliminate esotropia. I use this treatment primarily as a diagnostic tool. With moderate-to small-angle residual deviations in a patient with fusion potential, anticholinesterase treatment can be used therapeutically but never for an indefinite period. The prolonged use of echothiophate iodide can produce iris cysts. The concurrent use of phenylephrine hydrochloride (Neo-Synephrine) 2.5% drops once each day reduces the likelihood that these cysts will develop. When we use anticholinesterase treatment it is usually for a specific, predetermined period of weeks or months. A common use for anticholinesterase treatment is in lieu of glasses when a child removes them for swimming or while engaged in similar activities. Another effective anticholinesterase is disopropyl fluorophosphate (Fluoropyl) which is supplied in ointment form.
2. We frequently use Fresnel prisms in our clinic for patients who have fusion potential and are bothered by diplopia from small-angle strabismus which may be changing. These prisms reduce visual acuity proportional to their strength at a rate of approximately 1 line per 10 prism diopters. In addition, they can yellow with age, particularly when worn by a patient who smokes. In spite of these drawbacks, Fresnel prisms continue to be used effectively to relieve diplopia, particularly in the patients with residual strabismus and especially in the early postoperative period. They can also be placed obliquely to treat small angle horizontal and vertical strabismus that coexist. Permanent prisms are used in small-angle residual comitant strabismus with diplopia in patients when prism therapy is preferred to (repeat) surgery. When cared for properly Fresnel prisms can be worn effectively for long periods of time.
3. In some cases of accommodative spasm, chronic atropinization is used to eliminate accommodative convergence and is combined with bifocals to treat the near blur. This temporary treatment is designed to break the cycle of accommodative spasm.
4. Occluding contact lenses or high plus contact lenses can be used in one eye in cases of intractable diplopia.
5. A simple patch may be the only way to relieve a patient's symptoms from diplopia. Acquired third nerve palsy is the most common and troublesome cause of intractable diplopia for adults in our practice.
6. Pyridostigmine (Mestinon) for the treatment of diplopia from ocular myasthenia gravis is commonly mentioned. However, we have not found that ocular myasthenia responds well to anticholinesterase treatment. Prednisone by mouth in doses from 10 to 50 mg or more every other day in pulsed therapy during episodes of diplopia may be the only way to maintain comfortable single binocular vision in a patient with diplopia from the effects of ocular myasthenia.
7. Therapeutic orthoptics include measures such as diplopia awareness, fusional range enhancement, near point of convergence training, and supervision of amblyopia treatment. The last two are the most commonly used of the orthoptic treatment modalities.
8. Therapeutic occlusion for amblyopia is the most commonly used nonsurgical adjunctive strabismus therapy. Atropine drops are also

* Look at large paintings of faces on an advertising billboard. The eyes, in order to look aligned, are painted with a large positive angle kappa making them slightly exotropic. You will also see this in post-Renaissance portraits. Earlier artwork depicts subjects who appear esotropic or with a reduced pupillary distance.

used in one eye to treat amblyopia by creating a blur.

9. The prism adaptation test is a nonsurgical technique that helps to predict the response to surgery in a patient with residual esotropia. To do this test, fully correcting Fresnel prisms are placed on the glasses of a strabismus patient with residual refractive esotropia who is also wearing full hyperopic correction. Two responses are possible. In one the angle remains fully corrected with prisms after prolonged wear and the patient either does or does not demonstrate fusion with the Worth four-light. These patients have surgery for the angle measured which is equal to the amount of prism used. In the other response, the angle of deviation increases so that it measures essentially the same or close to it while wearing the prisms compared to before the prisms were placed after an adaptation period of hours to weeks. This response is termed 'eating up the prism' or *anomalous motor response*. In this case, additional prisms are placed until there is no more response or when up to 60Δ are placed. Surgery in this case is performed for the maximum angle found; that is, prism plus measured angle. In cases where the prisms correct the deviation fully in the distance but an esodeviation remains at near, surgery is done for the near deviation. This technique was subjected to a national collaborative study which demonstrated a small but statistically significant improvement in results using information from the prism adaptation test.

Step 4

The fourth factor in the treatment of strabismus is the surgical technique itself. The care and skill with which surgery should be performed will be referred to throughout the pages of this book.

Step 5

The fifth component of the surgery experience is follow-up. The patient's response to surgery should be monitored carefully in the postoperative period. Patching therapy for amblyopia may need to be initiated or resumed, anticholinesterase drops may be required, or prisms may be needed. In addition, complications of surgery are always a possibility and, if present, should be diagnosed and treated promptly. If there is a complication associated with the surgery or if the result is less than expected - disappointing, you, the surgeon should acknowledge this. Tell the patient that you recognize this and be positive, but have empathy. Let the patient know that you will see the problem through to either remedy the problem or

obtain help if necessary. This reassurance alone will allay the patient's concerns in most cases. It has been our practice to include 6 months to 1 year of follow-up in the surgical fee. This makes follow up easier on the patient and the surgeon! Based on each patient's situation, we attempt to schedule follow-up without causing financial or other hardship and we individualize follow-up according to special patient needs.

A successfully treated congenital esotropia patient who also develops postoperative amblyopia requires careful follow up to monitor the amblyopia and supervise patching. If the eyes are successfully straightened, the marker for amblyopia - strabismus - is gone, making it difficult for the family to detect persistence or recurrence of amblyopia. It is the surgeon's responsibility to carry out the visual examination and supervise the appropriate amblyopia treatment in these cases. The incidence of amblyopia in *untreated* congenital esotropia is 6% according to Calcutt and Murray compared to between 30% and 50% in large series of operated congenital esotropia patients. These data underscore the strabismus surgeon's responsibility for close postoperative follow-up of visual acuity.

Step 1: Patient evaluation

The initial workup may be recorded on a preprinted sheet similar to the one illustrated in Figure 1. The following questions should be answered and the indicated tests performed and recorded during the process of patient evaluation before strabismus surgery.

History:

Why was the patient brought in (why did he or she come in) for an examination?

What have the parents (what has the patient) noted about the eyes? ET, XT, hyper, constant, intermittent, closes one eye, tilts head, elevates or depresses the chin, eyes 'jiggle,' etc.?

Age of onset - when did the problem begin?

Current age

Birth weight (premature?)

Growth and development

o Present weight

o Sat up when?*

o Walked when?*

* of interest primarily in infants and young children

Any allergies, what medications are currently being used

Significant illness and surgical history

Indiana University Hospitals
1100 West Michigan Street
Indianapolis, Indiana 46202

Rev. 8-89	OCULAR MOTILITY EXAMINATION		M6470000		
AGE ONSET		HX:	AGE NOW		
(1) B.W. -			Med. Hx -		
Term -			Fam. Hx -		
Meds. -					<input type="checkbox"/> In Patient <input type="checkbox"/> Out Patient
Allergy -					
GLASSES (/ /)	OCCLUSION	ORTHOPTICS	SURGERY		
OD					
OS					
ADD					
(2) VISION	LETTER CHT.	NEAR	"E"	ALLEN	FIX-FOLLOW
OD	/	OD	/	/	OD
OS	/	OS	/	/	OS
(3) EXTERNAL	Normal	(4) IOP	FIXATION	(5) MOTILITY	SCREEN COMITANCE
Lids	Abnormal	OD _____		DUCTIONS	
Adnexa		OS _____			
Lacrimal		Tono ___ Appl ___	HEAD POSTURE		
(6) SENSORY	Range	Stereo	Worth 4-Dot	Nystagmus:	
Amblyoscope				Absent <input type="checkbox"/>	
OBJ. =	Div: /	Fly + -	Color Plates	Pendular <input type="checkbox"/>	
SUB. =	Conv: /	Animals / 3	OD	Jerk <input type="checkbox"/>	
		Dots / 9	OS		
(7) PATTERN	(8) PRISM COVER TEST	(9) PUPILS:			
A	DIST. s GL. =	(10) RNS			
V	DIST. c GL. =	Cycloplegia _____			
None	NEAR s GL. =	OD sph _____ cy _____ x _____			
	NEAR c GL. =	OS sph _____ cy _____ x _____			
	c ADD =	(11) Media			
	NPA =	Normal			
	NPC =	Abnormal			
(13) DIAGNOSIS		(12) Fundus Disc Macula Vessels Periphery			
		Normal Abnormal			
(14) TREATMENT					
(15) RETURN APPT. _____	DATE _____	SIGNATURE _____ MO			
MEDICAL RECORD COPY	OCULAR MOTILITY EXAMINATION				B-70
B-CLIN. NOTES	E-LAB	G-X-RAY	K-DIAGNOSTIC	M-SURGERY	O-THERAPY
					T-ORDERS
					W-NURSING
					Y-MISC.

Figure 1

A preprinted examination data collection sheet is a useful adjunct to the examination, particularly for the patient's first visit. This form has been effective in our clinic, but in most instances a practitioner will design a form to meet his or her unique needs. The importance of showing this form is that it includes most of the tests required for a complete examination. Results of other tests such as passive duction evaluation, tensilon test, exophthalmometry, etc. may be noted on this form in the appropriate area with explanatory labels.

Subjective complaints:

Diplopia (binocular - monocular)
Oscillopsia
Asthenopia
Getting worse or better
Cosmetic issues
Image tilt

Occlusion:

Which eye
How long
How well

Orthoptics:

Type of exercises
How long
How well

Family history:

Strabismus - parents, siblings, others
Glaucoma
Diabetes
Other eye problems
Trouble with anesthesia (malignant hyperthermia)

General health:

Trauma history
Diabetes
Fatigability
Developmental delays

Special characteristics:

Head tilt (nodding)
Preferred eye
Variability of deviation
Face turn
Dancing eyes (nystagmus)
Facial asymmetry

Prior treatment:

Glasses
o When prescribed
o Prescription
 Bifocals
 Prisms

Ocular surgery:

When
What was done
By whom

Visual acuity testing

Visual acuity is recorded as the smallest object a patient can see at a given distance. 20/20 vision (or 6/6 vision) means that at 20 feet (approximately 6 meters) a patient can see an object that subtends 5 minutes of arc with components of 1 minute. In the

decimal system this is recorded as 1.0. The letter E with its 5 combined spaces and bars is an ideal target. If the smallest object an individual can see at 20 feet subtends 5 minutes of arc at 200 feet the object is 10 times larger. This is calculated as 20/200, 6/60, or 0.1. Visual acuity recorded as the viewing distance over the distance the smallest object seen subtends 5 minutes and is recorded: 20/60, 6/18, 0.3, etc.

With an infant or a child too young to cooperate for visual acuity testing, reaction to the examiner's face, a light, a non-illuminated (silent) interesting or compelling object, social situations, and, if poor vision is suspected, to an optokinetic tape or drum should be observed. Notation is made describing the best acuity observed; for example, 'appears to be (not to be) visually alert to: (a note is made describing the size of the smallest object seen). Strong preference for one eye associated with objection to occlusion of this eye usually indicates amblyopia or an organic visual defect in the other eye. However, even normal infants tend to object vigorously to occlusion of either eye. Cross fixation, or using the eyes alternately, rules out amblyopia. Dim illumination is best for evaluation of vision in the neonate or very young infant. Simply turning off the overhead lights may turn a recalcitrant newborn with closed lids into an interested patient able to fixate on the examiner's face.

The preferential looking technique using Teller acuity cards has been used to quantify resolution acuity in the newborn and infant. This method can be employed to determine an objective value for visual acuity in a very young child. However, to determine relative acuity in order to establish the presence of preference of one eye for fixation and therefore amblyopia, simple clinical observation of fixation preference is sufficient to detect a difference in visual acuity of one octave in most young patients.

An E chart or a STYCAR (HOTV) chart visual acuity test can usually be accomplished at the earliest with girls at age 3 and with boys at age 3 1/2, although exceptions do occur. Linear testing with E's or letters is valid. Testing with isolated E's gives erroneously good vision results in the presence of functional amblyopia because of the absence of the crowding phenomenon. Crowding can be achieved resulting in accurate vision testing even with isolated optotypes by using crowding bars. These are lines equal to the width of the optotype segments placed at each side and above and below the single optotype used for visual acuity testing. We use isolated E's mainly for instruction. Vision in older children is determined with the letter chart. In children where testing with the E chart cannot be accomplished, Lea symbols or other recognizable pictures can be used. The Lea symbols are particularly useful to demonstrate a difference in visual acuity between the two eyes in a child too young to cooperate for other visu-

al acuity testing. In an office or clinic setting, computer generated visual acuity testing provides all of the visual acuity testing options while at the same time providing standardized illumination, random display, and more. This instrumentation is useful but expensive.

Relative visual acuity is more useful clinically than absolute acuity in an infant suspected of having amblyopia. Recognition acuity with Snellen optotypes (E's, the alphabet, or symbols) is a more stringent and, therefore, more accurate test than resolution acuity done with stripes. For this reason, we test vision with Snellen optotypes determining recognition acuity whenever we can obtain cooperation from a child.

If decreased vision is found in each eye when checked monocularly, vision should be checked binocularly. The examiner in this case should be looking for latent gross or micronystagmus. Fogging with a plus lens may be used to block vision in one eye but avoid nystagmus when determining monocular visual acuity in a patient with latent nystagmus. Near vision should be checked with E's, isolated letters or numbers, or sentence reading, depending on age.

Visual acuity testing with neutral density filters can differentiate functional from organic amblyopia. Vision in an eye with functional amblyopia remains at or near the same level when neutral filters of increasing density are introduced. Vision in a normal eye or in an eye with an organic cause for poor vision decreases proportionally with the increased density of the filter.

Near point of accommodation is determined in cooperative patients by moving a card with small print closer to the patient until the blur point is reached. The near point of accommodation is recorded in diopters or centimeters.

Pupillary response to light is evaluated by moving a light from in front of one eye to in front of the other in reduced ambient light. A Marcus Gunn afferent pupillary defect indicating decreased optic nerve function can be demonstrated with this test by noting a dilated pupil with the light shining in the involved eye (direct response) and constriction of the pupil when the light shines in the fellow eye (consensual response). With the 'swinging' flashlight afferent pupillary defect test, as the light moves rapidly back and forth, both eyes dilate when the light is shining in the abnormal eye and both eyes constrict when the light is shining in normal eye.

Preliminary evaluation of binocular function

Fixation

If neither eye is preferred for fixation and if the eyes appear grossly straight, fusion may be present or at least apparent. This can be confirmed with a stereo

acuity test or with the Worth four-lights. In this case, the word *fusion* is recorded. In the presence of strabismus, if one eye is preferred for fixation and the other eye deviates, the notation is *fixation OD* or *fixation OS*. If either eye is used for fixation with free alternation between the eyes or cross fixation is noted (the left eye fixes in right gaze and the right eye fixes in left gaze) free alternation may be present and is recorded as such. A patient may prefer one eye but hold fixation briefly with the non-preferred eye after the cover has been removed from the preferred eye. Such a patient usually does not hold fixation in the non-preferred eye through a blink. This type of acuity response is recorded as *prefers OD, will hold but not take up fixation OS, will not hold fixation through a blink*, etc.

Gross, wandering fixation may be present in the non-preferred eye and should be recorded as such. Nystagmus, if present, is noted and characterized as latent or manifest according to when the nystagmus is present, and horizontal, rotary, vertical, pendular, jerk, and the like according to the pattern of nystagmus. Frequency, amplitude, positions of greater intensity, and null point are also described. Nystagmoid movements differ from nystagmus in that the former are non-rhythmic and usually result from a sensory rather than a motor defect.

A peculiar type of ocular motility and head posture anomaly occurs with *ocular motor apraxia*. With this condition the eyes do not move in response to voluntary attempts at binocular vision through versions. Instead, the head moves past the point of fixation on the object of regard bringing the eyes along, so to speak. Then when the eyes have established fixation on the intended object, the head rotates back while the eyes maintain fixation on the object. This enigmatic supranuclear congenital condition tends to improve with age and requires no specific treatment.

Asymmetric, often unilateral, horizontal nystagmus with head nodding and torticollis in an otherwise normal child approximately 1 or 2 years old may be *spasmus nutans*. This is a benign condition that also requires no treatment. Spasmus nutans always improves. Unless this condition can be clearly differentiated from potentially serious causes of acquired nystagmus such as chiasmal glioma or posterior fossa tumor, computed tomography (CT) or magnetic resonance imaging (MRI) of the head should be performed. There are widely differing points of view regarding imaging in cases of apparent spasmus nutans. Some pediatric ophthalmologists and neuro-ophthalmologists advocate imaging in every case while others, including myself, will do imaging only in cases where an additional physical sign is present such as fussiness, weight loss, or some other added sign.

Vertical nystagmus with retraction is a sign of a lesion around the chiasm. Patients with retraction

nystagmus should be studied with appropriate imaging. Any vertical nystagmus, particularly when acquired, should be evaluated with a neurologic workup including CT or MRI. Downbeating nystagmus may be associated with Arnold-Chiari malformation and upbeating nystagmus with rostral brain stem lesions. Rapid, flutter movements are associated with neuroblastoma. Acquired nystagmus in childhood is always a matter of concern. It is the responsibility of the examining physician to make a decision about further workup and/or referral and at the very least to maintain careful follow up, such as three month intervals.

Ductions

Ductions or monocular movements are evaluated in extreme abduction, adduction, sursumduction, and deorsumduction. In cases where abduction is 'avoided' such as occurs in congenital esotropia with cross fixation where the right eye looks left and the left eye looks right, ductions are tested with the Doll's head test (Figure 2). This is also called the oculocephalic reflex test. This test is done by rotating the head rapidly to one side while particularly observing the eye opposite the direction of head rotation. Ductions are graded 1+ to 4+ overaction (this is a relative value) and -1 to -4 underaction. Forced ductions, muscle-force generation, and saccadic speeds are determined in patients with significant limitation of ductions.

Head posture

Any face turn, chin elevation or depression, or head tilt is noted and recorded. This observation is an especially helpful clue in patients with vertical muscle palsies and strabismus with limitation of ductions where fusion is present. An anomalous head posture is also a prominent feature of nystagmus with null point. A bizarre head posture may be assumed to aid in fusion or even in some cases to increase the amount of diplopia to aid suppression. A simple diagram showing the head posture and direction of gaze can be useful. At this point any facial asymmetry, a common finding in congenital superior oblique palsy, clefting, skin tags, hypertelorism, unusual palpebral fissure characteristics, etc. should be noted.

Screen comitance

Versions, or binocular eye movements, are evaluated in the extreme diagnostic positions comparing movements in the extremes of gaze carried out by yoked muscles. Arrows and hash marks on the record indicate overaction or underaction of the muscles. Arrows outside the figure indicate overaction and hash marks on the lines denote underaction. The lines drawn as paired H figures represent the field of action rather than the location of the yoked extraocular muscles.

Sensory evaluation

In selected cases, certain sensory tests should be performed after the history has been taken but before the eyes have been dissociated with covering and before visual acuity has been determined. Some patients are able to fuse in casual seeing situations that are not stressful, but lose their weak hold on fusion after the slightest dissociation. Patients with any type of intermittent deviation and bifoveal or peripheral fusion should have their stereo acuity determined initially and then should be tested with the Worth four-dot test before resuming the more usual flow of the examination. In addition, stereo acuity testing is a good screening device for patients in whom the surgeon suspects the examination will be normal. Any patient who accurately sees nine out of nine Titmus vectographic targets and, therefore, can appreciate 40 seconds of arc disparity, is unlikely to have a significant problem with their binocular mechanism or visual acuity.

Haploscope examination

This testing requires an instrument which stimulates the eyes separately but provides images with varying degrees of similarity and is designed to test the ability of the eyes to work together in response to a variety of stimuli. This testing is ordinarily done by an orthoptist.




Figure 2
Doll's head, oculocephalic response to elicit lateroversion (abduction), in an infant.

First-degree fusion

The *objective angle* is determined after dissociation with the haploscope. It represents the patient's manifest or latent strabismus (total fusion free deviation). Since the two targets are presented alternately, this is essentially the same angle found with alternate prism and cover testing. The *subjective angle* is the angle at which the patient superimposes images of objects by manipulating the arms of the amblyoscope. These angles are determined clinically using dissimilar, incomplete, grade I, simultaneous macular perception slides in the arms of the major amblyoscope or other haploscopic devices; for example, a lion in a cage, etc. Comparison of these two angles indicates the status of retinal correspondence, at least at the level of dissociation created by the amblyoscope. When the objective and subjective angles are the same, retinal correspondence is normal. When the subjective angle is zero and the objective angle is either plus (base out esodeviation) or minus (base in exodeviation), harmonious anomalous retinal correspondence is present. When the subjective angle is less than the objective angle but other than zero, non-harmonious anomalous retinal correspondence is present. If no subjective angle can be determined with grade I slides, first-degree fusion is absent. First-degree fusion and normal retinal correspondence are favorable but by no means certain indications that a functional result with fusion may be obtained from surgery.

Second-degree fusion

Range of fusion. If a subjective angle is found with appropriate slides, grade II fusion targets are inserted into the arms of the major amblyoscope and the patient's fusional amplitudes are determined. Grade II fusion slides are similar in their overall outline and differ only in detail. These differences serve as checkpoints ensuring that both eyes are seeing a target. With grade II targets in the amblyoscope, the arms are first shifted from the subjective angle outward (exo) and then inward (eso). Fusional amplitudes are an expression of the patient's ability to keep the images as one and, therefore, fused by either diverging or converging the eyes as the arms of the amblyoscope are shifted outward and inward. Fusional divergence is usually tested before fusional convergence. A 'make' and 'break' point for each is recorded; for example, -6 to -4 and +40 to +28. This means that the patient experienced diplopia when the arms got to 6D exodeviation but was able to refuse the images as the arms were returned to 4D exodeviation; fusion was held to 40D of convergence before diplopia appeared and the doubled images were

refused at convergence of 28D. The presence of second-degree fusion indicates that a functional result with fusion and fusional amplitudes should be obtainable with proper surgery. Such patients even when slightly overcorrected by surgery are those best able to obtain excellent long-term results. Fusional amplitudes can be measured in free space using the principles of the haploscope but shifting images seen by the two eyes with a prism bar containing horizontal prisms of gradually increasing strength from 1 to 40D.

Stereo acuity. This has been called third-degree fusion, but it should be recognized that these *degrees of fusion* are not a continuum but actually test different things: first degree - retinal correspondence; second degree - motor fusion; third degree - sensory fusion. The Titmus vectograph is used to test stereo acuity. Findings with this test are recorded as fly (3000 seconds arc disparity); A, B, C animals; and the fraction of the nine dots that the patient can appreciate. The ninth dot on the Titmus vectograph describes 40 seconds of arc disparity.*

Stereopsis is not recordable in manifest strabismus of sufficient size to warrant surgery. However, it may be quite good in intermittent deviations such as intermittent exotropia even with large angles or in small angle manifest strabismus with peripheral fusion.

Stereo acuity is tested using the polarized vectograph method that measures the ability to fuse laterally displaced objects within Panum's fusional space producing the illusion of depth. But a drawback of this test is that careful study of these images can offer monocular clues. Random dot vectographs have embedded disparity not seen monocularly. This so-called global stereopsis is said to provide more accurate findings of stereo acuity. Both of these tests require viewing with polarized glasses. Stereo acuity can also be measured without the use of spectacles using the Lang test or the Frisbie test. Stereo acuity can also be measured in free space using the Howard-Dolman apparatus which requires the examinee to align distant objects. This test is used primarily in clinical research settings.

Worth four-dot testing. Worth four-dot testing is performed at variable near distances and at 20 feet. Results of this testing are recorded as fusion, diplopia, alternation, or suppression of one eye. In many instances, patients with small-angle esotropia, central suppression, and peripheral fusion will fuse a four-light pattern that produces a large retinal image but will suppress one set of lights when the retinal image is made smaller either by reducing the size of the tar-

*Titmus vectograph findings in seconds of arc disparity are: fly = 3000, cat = 400, rabbit = 200, monkey = 100, 1/9 = 800, 2/9 = 400, 3/9 = 200, 4/9 = 140, 5/9 = 100, 6/9 = 80, 7/9 = 60, 8/9 = 50, 9/9 = 40.

get or increasing the viewing distance. A gross estimation of the size of the central functional scotoma present during binocular vision in patients with strabismus can be made by determining how far the four lights must be removed from the patient and, therefore, how small the retinal image becomes before suppression occurs. The size of the retinal image created by the four lights as the lights recede from the patient can be calculated, but the precise value is not clinically important. The Worth four-dot test may also be considered a gross color vision test and a test of retinal correspondence. If four lights in proper alignment are seen in the presence of a manifest strabismus, harmonious anomalous retinal correspondence may be inferred. This is a gross test and not one that is likely to alter decisions regarding treatment, although four light fusion is considered a favorable finding with the prism adaptation test.

Bagolini striated glasses. Bagolini glasses are essentially 'see-through, micro Maddox rods' that turn a point of light into a line while not disturbing vision. These glasses are ordinarily placed in a trial frame with their axes at 135° OD and 45° OS (or equivalent). They are used to determine retinal correspondence in casual seeing. Nearly all strabismic patients when viewing a point of light will see diagonal lines intersecting at the light or where the light is stimulating the retina in cases with a small central scotoma. This finding is compatible with harmonious anomalous retinal correspondence in the strabismic patient. Some patients will see one diagonal line corresponding to the preferred eye while suppressing the non-preferred eye. Other patients will see a complete line corresponding to the preferred eye and an incomplete line, with a missing segment adjacent to the light, with the non-preferred eye. These test results ordinarily do not influence surgical planning. These have been used by investigators for a variety of diagnostic and therapeutic manipulations and for the study of retinal correspondence and abnormal binocular movement.

After-image test. The afterimage test is used to determine retinal correspondence in extreme dissociation. Anomalous retinal correspondence occurring on the afterimage test indicates a deep sensory anomaly. Retinal correspondence tends to be normal or harmonious anomalous when tested with the Bagolini glasses, normal or anomalous with the haploscope, and normal with the after-image test, indicating that retinal correspondence response varies with the testing conditions and the test. All that can be inferred from this testing is how completely the eyes have adapted to the strabismus angle. To do an afterimage test, a bar of bright light with a non-illuminated central fixation point is presented horizontally to the eye used for fixation and then vertically to the other eye. If the afterimage intersects at the fixation point, normal retinal correspondence is present with this test. If

the lines do not intersect at the fixation point, deep anomalous correspondence is present.

Sensory fixation. Fixation behavior is determined with an ophthalmoscope that contains a fixation target that the patient is asked to look at with each eye while the fellow eye is occluded. The examiner can compare the retinal point used to fixate this target with the anatomic location of the fovea. This point of fixation is recorded directly on the chart with a small x. Fixation with any retinal point other than the fovea means that acuity in that eye will be reduced. The farther the point of fixation is from the fovea, the greater the reduction in acuity. Amblyopia with peripheral eccentric fixation suggests the possibility of a significant overcorrection of an esodeviation even when moderate surgery is done.

Implications of sensory testing. Sensory testing is useful both preoperatively and postoperatively. The closer to normal the preoperative sensory findings, the more the surgeon should try to create surgical alignment or a slight surgical overcorrection that would lead to fusion. Postoperative sensory testing is a check on surgical results and a guide to further non-surgical treatment that should be pursued appropriately in the case of an undercorrection or an overcorrection in a potentially fusing patient.

Measurement of alignment - prism cover testing and other methods

Alternate prism and cover testing is a method to measure the maximum deviation. This testing is performed at distance (20 feet) and near (13 inches), with and without glasses (if they are worn) while the patient views an *accommodative* target in the primary position. The use of an accommodative target and the wearing of glasses are essential because together they control the patient's accommodative convergence. Prism and cover testing is also done in approximately 30° of upgaze and downgaze while the patient wears full correction and views an accommodative target in the distance. If this test is performed at near while measuring for A and V pattern, the patient should wear +3.00 D lenses over the distance correction to eliminate the effects of accommodative convergence, especially in downgaze.

Upgaze and downgaze can be achieved by tilting the patient's head forward and backward. This maneuver uncovers an A or V pattern which is best tested while the patient fixes on a distant target. A 10Δ difference between upgaze and downgaze is significant for diagnosing an A pattern and a 15Δ difference is significant for a V pattern.

Other useful variations of prism and cover testing that can be performed before or after the alternate prism and cover test include the following:

1. The **cover-uncover test** differentiates a tropia from a phoria. Both are measured at the

- same time but not differentiated with the alternate prism and cover test. Movement of the covered eye immediately after the cover is removed and while the uncovered eye maintains fixation indicates a phoria. A tropia is noted by first establishing the fixing eye and then covering it while observing the fellow eye for movement. If the fellow eye does not move, the patient is *orthotropic*. If the eye moves to take up fixation, a tropia is present and the direction should be noted. If the eyes move inward toward the nose, an *exoshift* is recorded; if the eyes move outward toward the ear, an *esoshift* is recorded. When the eyes appear straight and/or good stereo acuity has been measured, even while assuming a face turn, head tilt, etc., the surgeon should proceed to the motor evaluation. The patient could have an incomitant mechanical strabismus dealt with by the patient with a face turn, head tilt, or both. This would have been uncovered for example in a case of Brown or Duane while testing ductions. A phoria is the most important feature found with the cover-uncover test. With aligned eyes in casual seeing, a phoria can be measured with alternate prism and cover testing. This testing also measures the total deviation, phoria, and tropia when these coexist.
2. **Lateral gaze prism and cover testing** can reveal the presence of lateral incomitance which is especially important in exodeviations and in previously operated patients.
 3. **Prism and cover testing with either eye fixing** helps to determine the primary and secondary deviation. This test is a variation of the simultaneous prism and cover test.
 4. **Simultaneous prism and cover testing (SPC)** determines the actual tropia in casual seeing in patients where a tropia and phoria coexist (monofixational esophoria, monofixation syndrome, microstrabismus, or small-angle tropia with peripheral fusion). The fixing eye is first identified. Then it is covered while a prism of appropriate size and orientation is simultaneously placed in front of the deviating eye. The amount of prism is increased or decreased until no movement occurs in the deviating eye. The prism needed to preempt re-fixation with the deviating eye is a measure of the alignment during casual seeing.
 5. The **Hirschberg test** compares the location of the light reflex which is normally in the center of the pupil of each eye to the anatomic central pupillary axes. It is performed when patient cooperation is poor. For each millimeter of displacement of the corneal light reflex in the non-fixing eye, approximately 7 degrees or 15Δ of deviation is present.
 6. The **Krimsky test** determines the amount of prism that must be placed before the fixing eye to center the corneal light reflex in the pupil of the non-fixing eye as this eye passively moves according to Hering's law (see page 105). This test is particularly useful when the patient has such poor vision in one eye that fixation is not taken up well with that eye during prism and cover testing.
 7. **Prism and cover testing with either eye fixing in the nine diagnostic positions of gaze** is performed in cases of muscle palsy, particularly vertical muscle palsy. This is the premier measurement of alignment.
 8. **Alternate prism and cover testing with the head tilted** approximately 45° to the right and to the left is called the Bielschowsky test. This test which is said to be positive when a vertical deviation increases with head tilt is useful for identifying isolated cyclovertical muscle palsy.
 9. **Dissociated vertical deviation (DVD)** is noted when either eye drifts upward the same or differing amounts when occluded and down when the cover is removed with cover-uncover testing. It is recorded as $+1 (\pm 5\Delta)$ to $+4 (\pm 25\Delta)$. Some surgeons prefer to measure rather than estimate DVD. This measurement may be performed in a manner similar to that with the simultaneous prism and cover test. However, DVD may be present with a coexisting true vertical deviation that is in the same or opposite direction as the DVD. DVD is also often of different amplitude in various fields of gaze and may demonstrate movement in only one eye! DVD may even present as pseudo-overaction of the inferior obliques. This is confirmed by noting a hyperdeviation of the occluded, abducted eye during lateral gaze. With true inferior oblique overaction, and no DVD the occluded abducted eye is more likely to be hypodeviated. Also, a V pattern should be present with true inferior oblique overaction. An eye with DVD that moves upward when covered can drift well below the midline when the cover is removed. This phenomenon has been called a 'falling eye.' Some eyes with very poor vision will drift below the midline with an accompanying vertical bobbing of the eye. This is called the Heiman-Bielschowsky phenomenon. An exodeviation of one eye only is called dissociated horizontal deviation (DHD). This is in a way an extension of DVD. The two have been char-

acterized as the dissociated strabismus complex (DSC) by M. E. Wilson.

10. A **translucent occluder*** held before one eye forces fixation with the other eye but allows observation of the occluded eye. This is an excellent way to observe the deviation in DVD. This testing is used effectively in telemedicine (see chapter 15).
11. **Red lens and Maddox rod tests** are useful subjective tests and for charting in cases of small-angle vertical and/or horizontal strabismus with symptomatic diplopia.
12. The **double Maddox rod test** is useful in the diagnosis and measurement of cyclodeviations.
13. The **4Δ base-out prism test** may be used to uncover a scotoma in the macula of one eye in patients with microtropia.
14. A **Hess, Lancaster, or Lees screen** may be used to plot directly the deviation in a cooperative strabismic patient.
15. **Diplopia fields** are mapped with a Goldmann perimeter or arc perimeter while the patient views the moving fixation target with both eyes open and with the head centrally positioned and stabilized. The documentation provided is valuable for following recovery from an acute paresis and especially for medicolegal and compensation purposes.

Refraction

Refraction has a vital role in the diagnosis and treatment of strabismus. It is imperative that those involved in the care of the strabismus patient understand the principles of refraction, have the skills to perform accurate measurement of the refractive error, and use spectacle correction or the equivalent as required in the treatment of strabismus. *If you intend to treat patients with strabismus but are not competent with refraction technique, you should stop here. Learn how to refract and then resume your study. A person ignorant of refraction methods is not fully qualified to treat strabismus!*

Work up of the patient with strabismus always starts with the refraction. In heavily pigmented patients a cycloplegic refraction is performed using atropine solution 1.0% (1 drop) or atropine ointment 1% (¼-inch strip) in each eye for 3 days before the day of examination. When drops are used, the atropine may also be applied on the day of the examination. Careful instructions are given to the parents to avoid overdosage. These instructions include using no more medicine than prescribed and holding a finger over the punctum for 30 seconds after drops are instilled in one eye in the morning and the other in the

afternoon. Use of atropine is usually restricted to preschool-aged children, for initial refraction, and when esotropia is present.

When refracting a lightly pigmented patient in the usual office setting, a cycloplegic refraction can be performed satisfactorily approximately 20 to 40 minutes after one or two drops of cyclopentolate (Cyclogyl) 1% have been instilled in the cul-de-sac in children over 1 year. One drop of phenylephrine (Neo-Synephrine) 2.5% may be used in addition to the cyclopentolate in patients with dark irides. In children under 1 year of age, cyclopentolate 0.5% drops are used.

In esodeviating patients the full hyperopia must be elicited. Hyperopia as low as +3.00 D should receive a trial treatment with glasses in patients with esotropia usually beginning after 1 year of age. However, I have seen several patients less than 1 year of age with esotropia relieved by wearing a +3.00 D correction. Echothiophate iodide (Phospholine) drops (0.06% to 0.125%, one drop in each eye each morning for 3 weeks) in lieu of glasses may help to determine what effect the hyperopia (accommodative effort) has on the esodeviation, but because anticholinesterase drops only reduce the effective accommodative convergence/accommodation ratio (AC/A) and do not eliminate the need for accommodation, they are not a true substitute for glasses.

A difference in the refractive error between the eyes is called anisometropia. Difference of as little as +1.00 or +2.00 diopters can be amblyopiogenic and usually indicates the need for the full refractive difference to be prescribed. If glasses are prescribed with the hyperopia reduced, it should be reduced equally. For example, OD +2.00 +1.00 x 90, OS +6.00 +2.00 x 90, could be 'cut' to OD +1.00 +1.00 x 90, OS +5.00 +2.00 x 90. These glasses would be effective and better tolerated.

Adult patients do not ordinarily require cycloplegia, but in selected cases of convergence excess this may be needed. It is best to avoid use of cycloplegics in pre-presbyopic adults. Use of cycloplegics in such patients can precipitate presbyopia resulting in a very unhappy patient.

Fundus examination

Examination of the retina is carried out using a standard or small portable indirect ophthalmoscope. It is a relatively simple matter to see the retina posterior to the equator in a squirming infant using the indirect ophthalmoscope. This examination to rule out pathologic conditions in the posterior pole is an essential part of the evaluation of every strabismus patient. Remember, esotropia is the second most common presenting sign, after white pupil of retinoblas-

* This technique was made popular by Annette Spielmann of Nancy, France.

toma! The direct ophthalmoscope is used to study detail of the optic nerves and maculae and to determine fixation behavior in the older child with amblyopia. A total retina examination such as that needed to rule out retinoblastoma in an infant requires an examination under general anesthesia. For purposes of strabismus, examination of the posterior retina as it affects central vision is sufficient.

Biomicroscopic examination

Examination of the anterior segment should be performed on all patients, particularly when echthiophage iodide is used, because of the possibility of iris cysts and to confirm continued clarity of the lens. A portable slit lamp is a valuable instrument for examining children under 3 years of age. At the very least, the anterior segment should be studied using the direct ophthalmoscope. When nystagmus and decreased vision are noted, iris transillumination defects indicative of albinism, either oculocutaneous or ocular, should be looked for.

External examination

The appearance of the lids should be noted. Is there ptosis or epicanthus (superioris or inferioris)? Are the palpebral fissures mongoloid, anti-mongoloid, or normal? Is there proptosis, hypertelorism, microphthalmos? Is lid lag present? Are there conjunctival scars? All of this information should be recorded.

Diagnosis of the strabismus condition

When sufficient historical data and motility and refractive measurements have been recorded, a diagnosis is made. This diagnosis can be made in most cases after the initial examination. Repeated measurements at one or more subsequent visits should be taken in some cases before a final quantitative diagnosis is established and a specific surgical treatment plan determined. For example; congenital esotropia, longstanding superior oblique palsy, sensory esotropia or exotropia and similar types of strabismus can usually be scheduled for surgery at the initial visit and then re-evaluated on the day of surgery. In contrast, intermittent exotropia in the toddler, acute cranial nerve palsies, and residual refractive esotropia may require a longer period of observation along with repeated measurements.

Other special examinations may be employed for complex diagnosis including the following:

1. Tensilon test
2. Differential intraocular pressure test
3. Saccadic velocity observed and with electro-oculogram recording
4. Nystagmography
5. Iris angiography
6. Imaging of the orbit with CT or MRI

7. Forced ductions
8. Generated muscle force

The diagnosis should include as much information as possible about the strabismus problem including notation of some or all of the following:

1. Etiology
2. Direction of deviation (eso, exo, hyper, cyclo)
3. Comitance
4. Fixation behavior
5. Vision (amblyopia)
6. Refraction, accommodative factors
7. AC/A
8. Manifest or latent
9. Constant or intermittent
10. A or V pattern
11. Mechanical factors (forced ductions)
12. Cranial nerve status (saccadic velocity - secondary deviation)
13. Muscle force
14. Lid fissure configuration
15. DVD - DHD
16. Head posture
17. Aberrant regeneration
18. Oblique muscle function
19. Facial asymmetry
20. Ptosis (upper or lower lid)

Diagnostic considerations for strabismus with restrictions

Clinical evaluation of strabismus with restricted motility

Underaction

Apparent excesses or real deficiencies of ocular movements can occur with longstanding strabismus. Even more dramatic and obvious apparent excesses and real deficiencies occur with acute palsies and with congenital restrictive strabismus such as with Brown, Duane, Möbius, or fibrosis syndromes. Other causes of strabismus with restriction include metabolic (thyroid ophthalmopathy), iatrogenic (postoperative eye muscle surgery, cataract, or retinal detachment surgery), traumatic (blowout fracture), fibrosis syndrome, progressive ophthalmoplegia, orbital tumor, inflammation, and more. Accurate analysis of the sometimes subtle abnormalities in the extent and character of ocular movement caused by acute or longstanding strabismus, or from any of the other causes listed, is an essential step in the planning and ultimate execution of the correct surgical procedure. For example, in an esotropic patient with deficient abduction in the chronically esodeviated eye and otherwise full unrestricted ductions, the correct surgery would be dictated by the results of testing both active and passive movement in the deviated eye. In such a

patient, any mechanical restriction to abduction must be released before the eye could be straightened and before there could be any hope of normal or near normal abduction. Whether release of the medial restriction alone would be sufficient or whether ipsilateral lateral rectus resection or even a muscle transfer should be performed would depend on the results of testing for generated muscle force. If, for example, generated force were brisk and the angle of deviation small, freeing of the restriction with or without medial rectus recession could be sufficient. If the angle were large and the generated force only moderate, lateral rectus resection in addition to the medial rectus recession might be necessary. Finally, if generated force toward abduction were minimal or nil, it would be necessary to do some type of extraocular muscle transfer procedure. Whether the medial rectus were recessed or weakened with Botox would depend on the degree of restriction and to some extent on the angle of deviation as well as on the surgeon's own preference.

Except in certain cases of total sixth or third nerve palsy and a few other examples, such as inferior rectus denervation as occurs in certain cases of blowout fracture, some eye movement force remains in the so-called underacting muscle. This remaining force, though diminished, points out that emphasis should be placed on freeing of mechanical restrictions. In some cases this is relatively easy, such as in cases of longstanding strabismus with a normally contracting antagonist. On the other hand, freeing of the restriction in a congenital Brown syndrome to restore normal or near normal ocular motility can be difficult to accomplish. In addition, freeing of restricted movements can result in a distressing overcorrection.

Overaction

Overaction of extraocular muscles is more difficult to analyze and categorize than is underaction of extraocular muscles. For this reason, we use the term 'apparent overaction.' There is no evidence that the so-called overacting muscle has more force or has a greater saccadic velocity. Even though the eye appears to move farther in the usual field of action. This is seen as excess adduction or abduction in longstanding esotropia or exotropia. This overaction may be seen because the checking of muscle action is relaxed or relatively ineffective. In the case of overacting oblique muscles, the apparent increase in action may be a horizontal movement which allows the globe to move farther laterally in the orbit. Careful observation of the apparent overacting superior and inferior oblique frequently reveals that overaction is actually abduction. This produces the well-known 'V' with overaction of the inferior obliques and 'A' with overaction of the superior obliques. Overaction of the superior oblique can be seen in the

normal eye in cases of superior oblique palsy with restriction of the ipsilateral superior rectus. This is due to a Hering's law response with the normal superior oblique receiving the same innervation as its yoke, the inferior rectus, in the involved eye.

Congenital or acquired incomitant strabismus with limitations in motility caused by muscle palsies or mechanical restrictions, or a combination of the two, is usually easy to recognize. However, an accurate and correct diagnosis in such cases is absolutely essential before a plan for surgery can be determined. Nowhere in strabismus treatment is proper diagnosis more essential to proper execution of surgical skills than in these cases of incomitant strabismus. The differential diagnosis of strabismus with restricted motility requires analysis of saccadic movements, forced (passive) ductions, and muscle force generation in addition to the usually performed prism and cover tests.

Evaluation of noncomitant strabismus

The example shown in Figure 3 is a model for any type of strabismus with restricted motility in one or both eyes and in one or more fields of gaze. The analysis becomes more complicated as more muscles and fields of gaze are involved, but the principles are the same. The patient has a right esotropia in the primary position. This is the primary deviation and measures 50Δ . In levoversion the eyes are grossly parallel, with normal adduction of the right eye and normal abduction of the left eye. No muscle weakness or mechanical restriction is apparent in this direction of gaze. In dextroversion the right esotropia increases markedly. Abduction of the right eye is deficient, whereas adduction of the left eye is normal or could be increased. The decreased abduction in the right eye could be the result of a paretic right lateral rectus, a mechanical restriction associated with the right medial rectus or with various muscular or fascial structures in the right eye, or a combination of the two. When the patient fixes with the right, 'paretic' eye the left esotropia is increased to 70Δ . This is called the secondary deviation.

Saccadic velocity analysis

Observed saccadic velocity is a useful clinical tool for differentiating a weak muscle from a normal muscle, which underacts only because it is held in check by mechanical restrictions. A normal extraocular muscle will produce a brisk movement of the eye with a peak velocity of 400° per second to as high as 600° per second. A paretic muscle will usually produce velocities at about one-tenth this speed. This movement may be produced not by the paretic muscle but by elastic orbital forces influenced by relaxation of the antagonist of the paretic muscle. Decreased saccadic velocity can be readily observed in the clinical setting. The electro-oculograph pro-

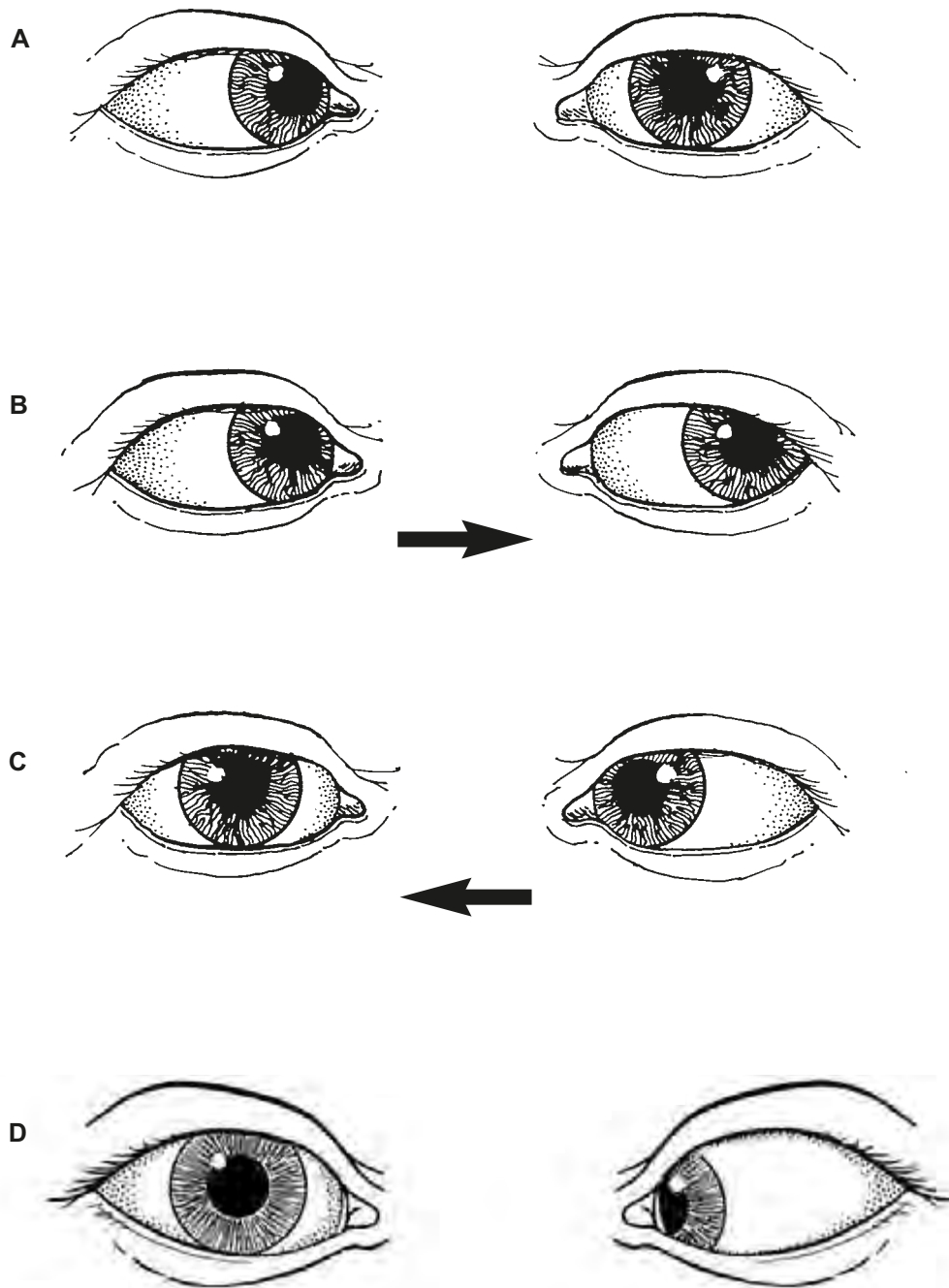


Figure 3

- A Fixing with the sound eye (primary deviation) - a right esotropia is observed.
- B Levoversion is essentially normal.

- C Dextroversion shows limitation of abduction in the right eye.
- D Fixing with the paretic eye and/or mechanically restricted right eye produces a larger secondary deviation.

vides recordings useful for determining subtle deficiencies and for purposes of documentation in the laboratory. But for clinical evaluation, observation alone is usually sufficient.

Saccadic velocity analysis begins with the patient fixing on an object in the field opposite that of the suspected paretic muscle (Figure 4). The patient shown has a right esotropia. To begin the test for saccadic velocity, the patient is asked to look far to the left in the field opposite that of the muscle whose

function is in question. The patient is then asked to abruptly switch fixation to an object in the field of action of the suspected paretic muscle. In this case the patient is asked to switch fixation from extreme levoersion to extreme dextroversion. To accomplish this maneuver, it is best to instruct the patient to 'look at' an object that the examiner holds in the patient's far left field and then to 'look at' an object held in the examiner's hand in the patient's far right field. During the patient's switch of fixation, the examiner observes

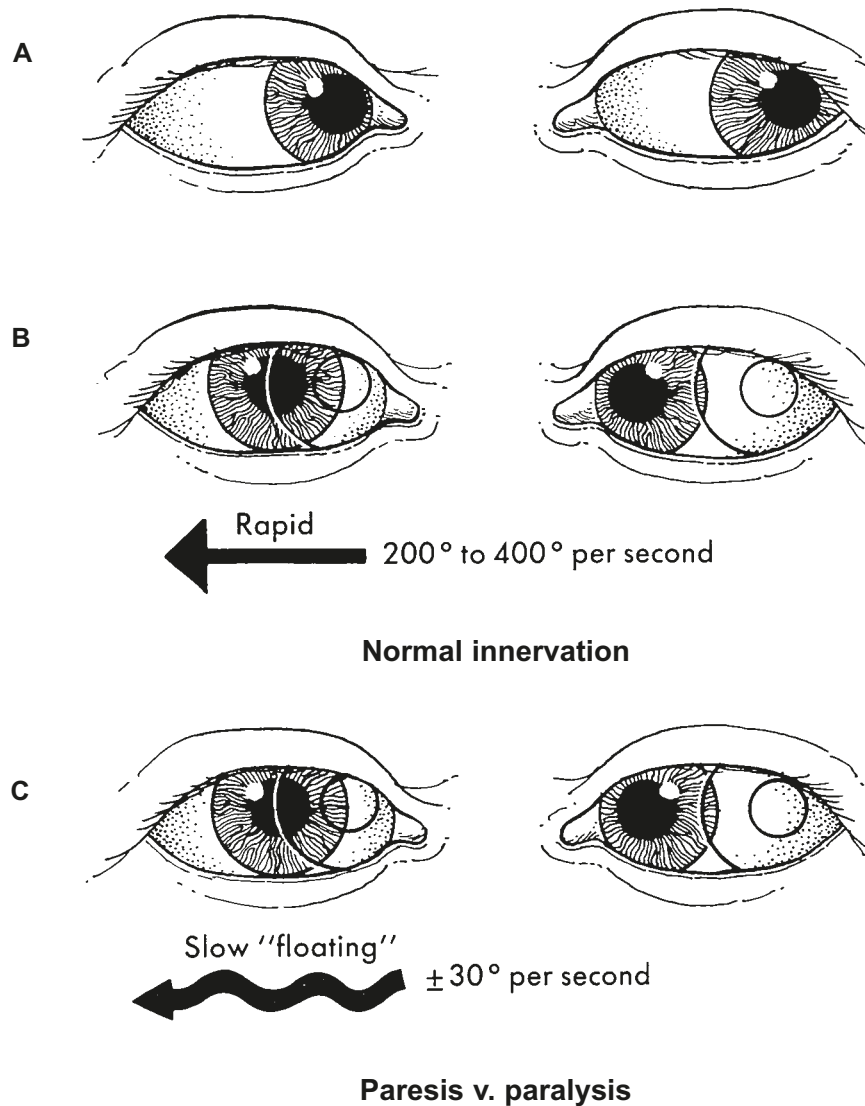


Figure 4

A Eyes are in a gaze opposite the field of action of the underacting muscle
B Fixation shifts from extreme left to extreme right gaze resulting in a saccade. In this case the eyes move with equal velocity but excursion of the right eye is limited suggesting normal innervation to the right lateral rectus. Restricted right eye movement is likely due to mechanical factors.

C A slow or 'floating' saccade indicates decreased innervation of the right lateral rectus. No information is available about possible mechanical restriction.

the speed of the movement in the eye with limited motility (the right eye). If this eye moves at a normal saccadic speed (200 to 400 degrees/sec), as does the normal eye which serves as a control, the apparently underacting muscle (the right lateral rectus) is probably contracting in a normal or nearly normal way. The limited motility is probably caused by mechanical restriction associated with this muscle's antagonist or other fascial structures around the globe. On the other hand, if the eye moves to its final position in attempted dextroversion with a slow, floating movement (± 30 degrees/sec), which is slower than the fellow eye, this evidence suggests that the right lateral rectus is paretic. In this case, little can be determined regarding the presence or absence of an associated mechanical restriction. A possible co-existing mechanical restriction is determined only after passive duction testing has been performed. Saccadic velocity analysis also can be performed with the aid of an electro-oculograph that provides a printed read-out. The electro-oculograph measures peak velocity on one track. A second track measures the magnitude of the ocular movement and displays a slope of the ocular movement speed (Figure 5).

Forced (passive ductions)

Forced or passive ductions should be carried out at some time on all patients undergoing strabismus surgery. This test can be done at the time of surgery, after adequate anesthesia has been obtained. The test is performed in both eyes in all directions. In most cases, forced or passive ductions are performed in the operating room just before the actual surgery is begun. The test is accurate immediately if a non-depolarizing muscle relaxant has been used during general anesthesia, but can only be performed after 15 or 20 minutes if succinylcholine or equivalent has been used because of muscle contraction.

In cooperative patients with restricted motility about whom the surgeon wants as much information as possible before going to the operating room, forced ductions can be carried out in the office using topical anesthesia. Several drops of proparacaine hydrochloride or tetracaine are sufficient to anesthetize the conjunctiva. In place of these anesthetic agents, 5% lidocaine (Xylocaine) drops may be used. As another alternative for anesthesia, a cotton-tipped applicator saturated with cocaine hydrochloride 4% is held against the conjunctiva at the point where the forced

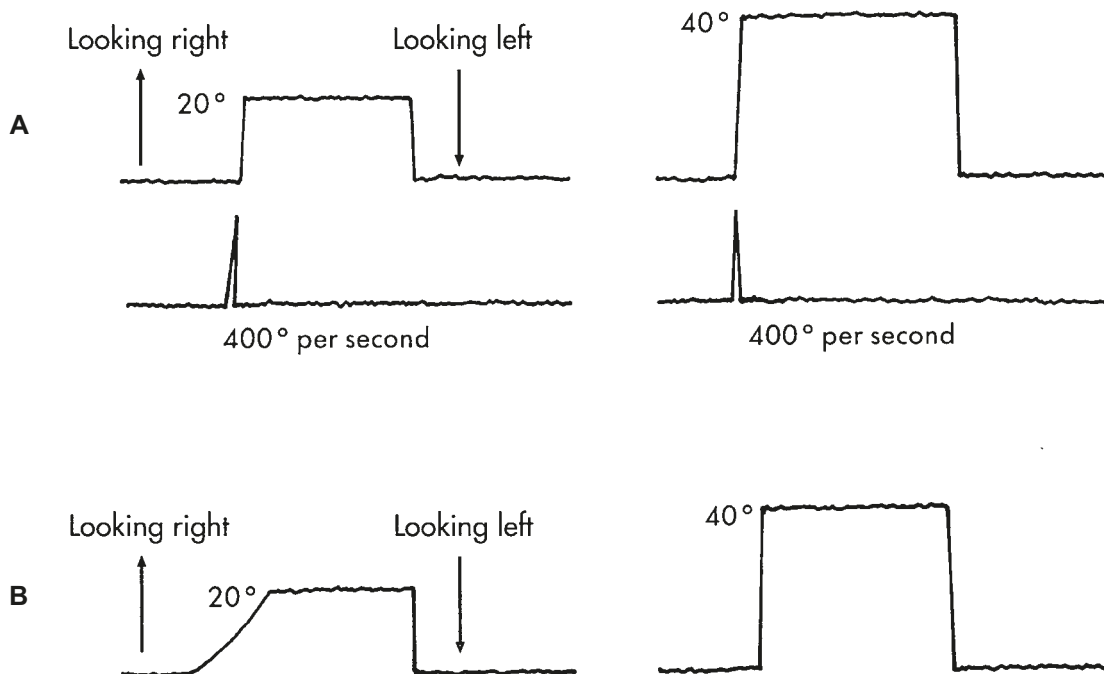


Figure 5

A Limited movement in the right eye with normal saccadic velocity indicates that restriction is causing the strabismus.

B A slow saccadic velocity indicates weakness of the right lateral rectus muscle. No information is revealed about possible co-existing restrictions. This must be analyzed with forced duction testing. Peak velocity is not shown.

duction forceps are to be applied. Fine-toothed forceps are used to grasp the conjunctiva and episclera, and the patient is asked to look toward the field of action of the restricted motility. The examiner then gently assists the eye into the full extent of the attempted duccion.

Three important techniques to practice when doing the forced duccions on a patient in the clinic are 1) gently lift the eye as it is rotated on the physiologic axis center of rotation while avoiding pushing the globe back in the orbit, 2) grasp the conjunctiva-episclera with a secure bite with the forceps, and 3) instruct/reassure the patient to continue looking in the field to be tested and avoid a refixation that could cause the cornea to be scraped by the forceps creating a corneal abrasion or tearing the conjunctiva.

It has been suggested that passive duccions can be tested using just a cotton-tipped applicator to move the globe after instillation of a topical anesthetic. This technique avoids the complications just described.

In the example shown, the patient has a right esotropia and limited abduction of the right eye (Figure 6). After anesthetizing the eyes the patient is asked to look as far to the right as possible. The conjunctiva and episclera of the right eye are grasped with a fine-toothed forceps at the nasal limbus (3 o'clock position). The examiner then attempts to abduct the right eye gently but forcibly while following the normal arc of rotation of the eye around its physiologic vertical axis. If the eye cannot be abducted fully, a mechanical restriction is present and the limitation of abduction results from mechanical causes with or without associated paresis of the lateral rectus (as inferred from saccadic velocity analysis). If the eye can be abducted fully and the examiner feels no resistance to forced abduction, no mechanical restriction is present and a right lateral rectus paresis is indicated. This finding is always associated with a 'floating saccade.'

Passive duccion testing of the oblique muscles

Superior oblique traction test

Guyton suggested an ingenious scheme for evaluating the status of the superior oblique tendon. This test depends on feeling a 'knife edge' response when gently pushing the globe backward in the orbit while rolling the globe back and forth over the stretched superior oblique tendon. This test is interpreted according to the surgeon's experience. It is performed in the operating room with the patient under general anesthesia to achieve the proper level of muscle relaxation. Plager has expanded on the 'testing for tightness (or laxity)' of the obliques, adding testing of the inferior oblique muscle.

Traction testing of the superior oblique tendon can reveal laxity of the tendon which is the hallmark of 'anatomic' congenital superior oblique palsy with its frequent anatomic anomalies of the tendon. When laxity of the superior oblique tendon is found, it is much more likely that the superior oblique tendon will be explored, found to be loose or abnormally inserted, and subsequently tucked, resected, or redirected. On the other hand, if the tendon is thought to be normal based on the superior oblique traction test, the diagnosis is more likely acquired superior oblique palsy or neurogenic congenital superior oblique palsy and tuck or resection of the superior oblique is not performed, avoiding a postoperative Brown syndrome. This superior oblique traction test adds to the accuracy of both diagnosis and treatment of superior oblique palsy. Saunders and later Plager described an intraoperative traction test to determine the proper amount to tuck the superior oblique tendon. Guided by this test the tuck can be loosened if the tendon is found too tight or tightened if the tendon remains lax.

To perform the superior oblique traction test on the right eye, shown from above in Figure 7, the eye is grasped at the limbus with fine-toothed forceps at the 4 to 10 o'clock positions (shown) or the 2 and 8 o'clock positions (not shown) on the left eye. The view is from above the patient's head. The eye is pushed back in the orbit in full adduction. The eye is then brought temporally while continuing to push it back in the orbit. A normal taut superior oblique will cause the globe to 'pop up.' This reaction can be felt and seen. As the globe slips over the superior oblique tendon toward abduction, the eye recedes a bit further in the orbit. If no tendon is felt or a very slack tendon is felt and the eye does not 'pop up' but instead slides back into the orbit when the globe is brought temporally, the superior oblique is loose or absent. Regardless of the tightness or looseness of the tendon, the eye is easily pushed back in the orbit in full abduction. In the case of a very loose tendon the cornea remains out of view during the temporal excursion of the globe.

Inferior oblique traction test

The inferior oblique traction test is best used to confirm that apparent inferior oblique overaction is due to a taut inferior oblique muscle and is done when inferior oblique overaction persists after the muscle has ostensibly been weakened. When performing this test, it is not uncommon to find a tight inferior oblique response in a muscle that has been previously weakened. When this is encountered and the inferior oblique is explored most likely either the cut ends of the muscle have reunited or some other type of fibrous attachment is effective in causing persistent inferior oblique overaction. In either situation, severing the attachments that cause inferior oblique function lateral to the inferior rectus is usually effective

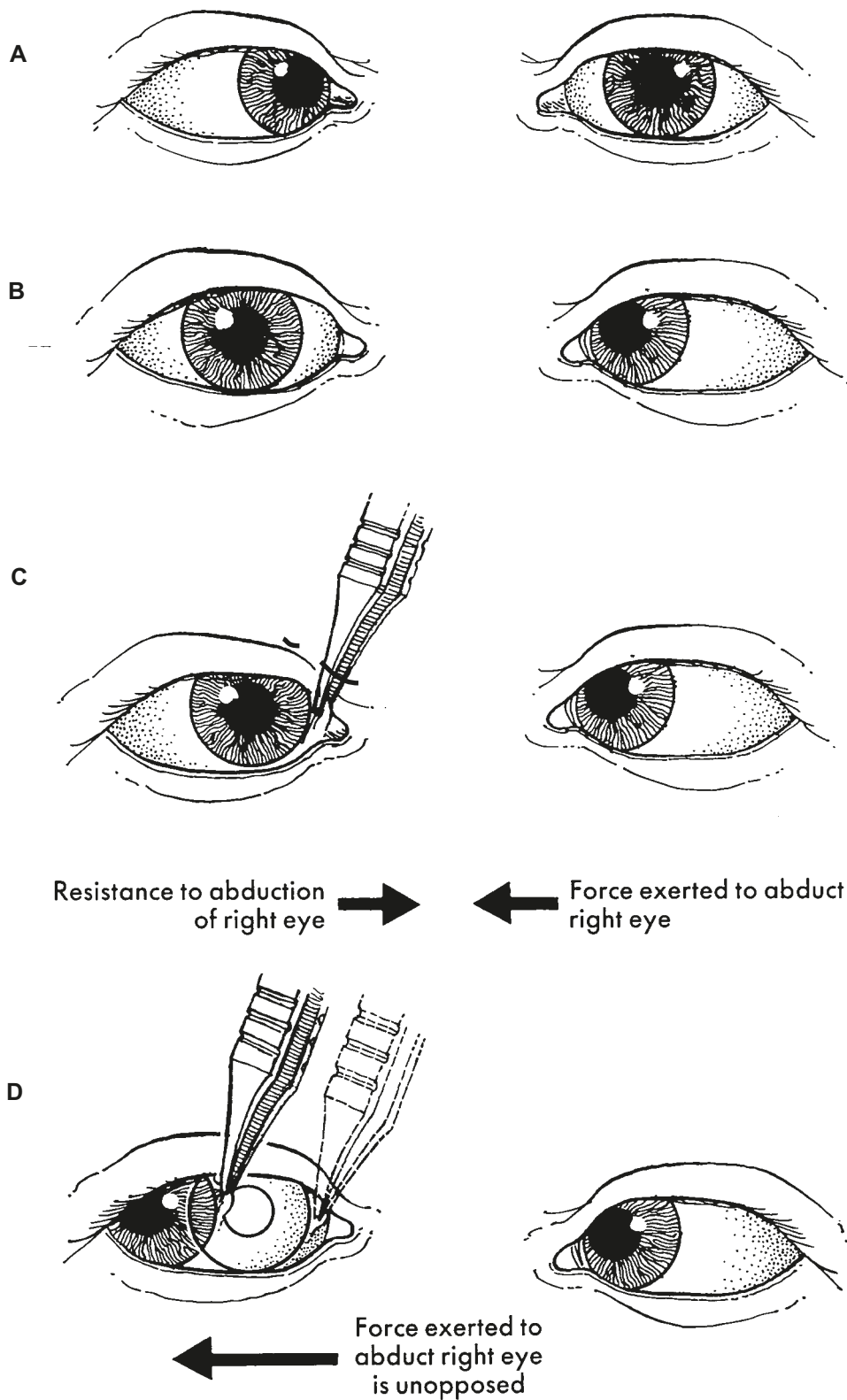


Figure 6

- A Fixing with the sound left eye (primary deviation)
- B In dextroversion, limited abduction of the right eye is seen.
- C After topical anesthetic has been applied, the examiner attempts to complete abduction of the right eye. If this is not possible - the eye is stiff and immovable - mechanical restriction is present.
- D If the eye goes freely into abduction, passive or forced ductions are free confirming that no mechanical restriction is present.

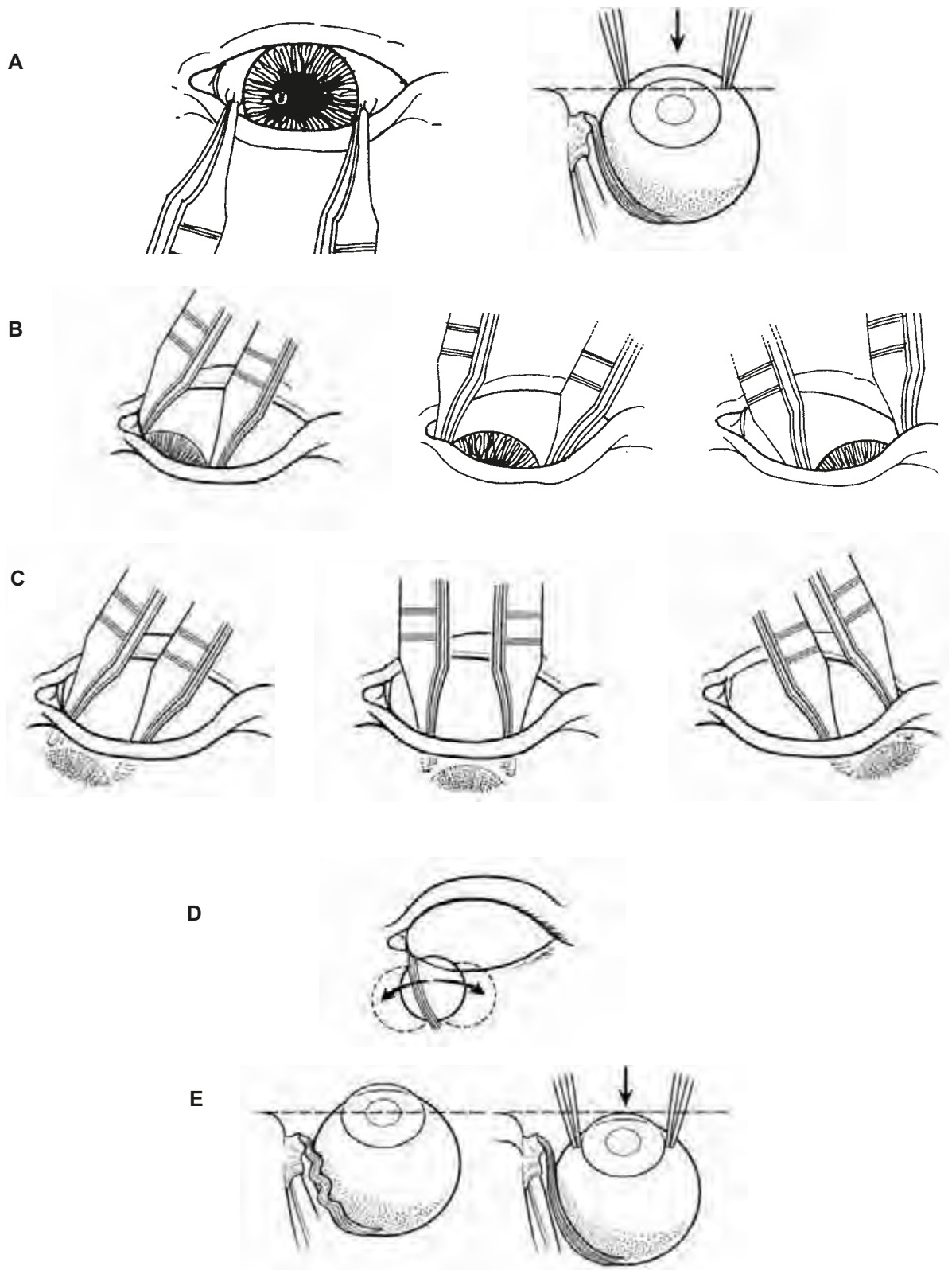


Figure 7 The superior oblique traction test (viewed from above the patient's head)

- A** The eye is grasped at the 2 o'clock and 10 o'clock position (right eye from above) in preparation for the superior oblique traction test.
- B** The eye is pushed back into the orbit and is guided from nasal to temporal. As it goes over the normal superior oblique tendon, the eye 'pops' up.
- C** With a lax or loose tendon the cornea disappears and remains hidden behind the upper lid as the eye is rotated.
- D** The relative path of the globe as it passes over a normal tendon.
- E** A lax superior oblique tendon allows the globe to be pushed backward into the orbit.

provided that the case is not otherwise complicated. In cases of inferior oblique adherence or inferior oblique inclusion, however, the outcome of reoperation is not so optimistic. Restrictions often persist in spite of careful attempts to free all adhesions in the infero-temporal quadrant.

To perform the inferior oblique traction test, the eye is grasped at the limbus with fine-toothed forceps at the 2 and 8 o'clock positions on the right eye (or the 4 and 10 o'clock positions on the left eye), shown from above in Figure 8. The eye is pushed back in the orbit in full adduction. The eye is then brought temporally while continuing to push back in the orbit. A normal or taut inferior oblique will cause the globe to 'pop up'. This reaction can be felt and seen. If no taut muscle is felt and the eye does not 'pop up' when the globe is brought temporally, the inferior oblique is not tight and probably has been effectively weakened. Regardless of the tightness or looseness of the muscle, the eye is easily pushed back in the orbit in full abduction.

Generated muscle force

Another step in analysis of strabismus with restricted motility is to perform the active muscle-force generation test. This test determines, in the presence of restricted eye movements, the amount of force generated by a given extraocular muscle within the range of movement noted on testing of versions and ductions. Active muscle force generation is a tactile test that complements saccadic velocity analysis which is a visual test.

The information obtained from saccadic analysis, forced ductions, the muscle-force generation and in a few cases the differential intraocular pressure test helps indicate if recession-resection and freeing of restrictions are indicated or if muscle transfer with or without freeing of restrictions is required. When normal contraction plus mechanical restriction is present, the restriction first must be eliminated by freeing conjunctival-globe-muscle-fascial adhesions. Detaching and recessing or otherwise weakening a muscle may be required. Either recession alone or a recession-resection procedure should be performed as indicated. When reduced or weak muscle contraction is discovered, as evidenced by reduced generated muscle force, a muscle transfer is usually indicated. This is done with or without weakening the antagonist based on the forced duction test, the age of the patient, and the number of undisturbed anterior ciliary arteries.

To start the test, the patient is instructed to look in the direction opposite from the field of action of the muscle to be tested. In the example cited (a right esotropia with limited abduction of the right eye), the patient is asked to look far to the left (Figure 9). Several drops of proparacaine hydrochloride (0.5%) are sufficient to anesthetize the cornea and conjunctiva. A cotton-tipped applicator saturated with cocaine

hydrochloride 4% held against the conjunctiva at the point where it is to be grasped with the forceps may also be used to anesthetize the conjunctiva. The anesthetized conjunctiva and episclera of the right eye are grasped with fine-toothed forceps at the nasal limbus (3 o'clock) and the patient is asked to move the eye slowly far to the right while the examiner attempts to stabilize the right eye in extreme adduction. The amount of tug felt by the examiner through the forceps indicates the contracting power of the right lateral rectus. If no appreciable tug is felt, little or no contraction of the right lateral rectus occurred. This type of response is associated with a floating saccade.

If the examiner feels a brisk tug on the forceps stabilizing the eye, the right lateral rectus has significant contracting power. This type of response is associated with a brisk, normal-velocity, saccadic movement. The limited movement in this case is caused by a mechanical 'leash' or tethering effect usually caused by scar tissue, adhesions, or a spastic, contracted antagonist. The surgeon can test generated force in the normal eye of a patient after topical anesthesia to establish a feel for this test.

More accurate determination of active muscle force generation can be obtained by using a strain-gauge. Black silk sutures (4-0 or 5-0) are affixed to the episclera and attached to the strain gauge deflector. A perilimbal suction cup or a special forceps can be used to connect the episclera to a suture or other device that in turn attaches to the strain gauge. Isometric contractions should be 60 to 90 gm or more in a normal muscle and are reduced to approximately 10 gm in complete paralysis. Even with paralysis some force is measured because of passive tissue forces. These more accurate tests are reserved for the laboratory.

Differential intraocular pressure test

The differential intraocular pressure (IOP) test is a useful indirect technique for diagnosing generated muscle force and confirming mechanical restriction in the face of a normal agonist. This test is based on the fact that in the normal patient the eye rotates around the center of the globe. During normal movement the antagonist relaxes as the agonist contracts and no excessive pressure is placed externally on the globe, and IOP remains normal. At extremes of ductions in the normal eye, an increase in IOP occurs because ocular movement is stopped by mechanical checking by the antagonist rather than by lack of agonist contraction power. In cases where ocular movement is limited by mechanical restriction, the IOP increases when the eye attempts to move into the restricted field. On the other hand, when a restricted movement is not accompanied by an increase in IOP, paresis may be indicated. The differential IOP test

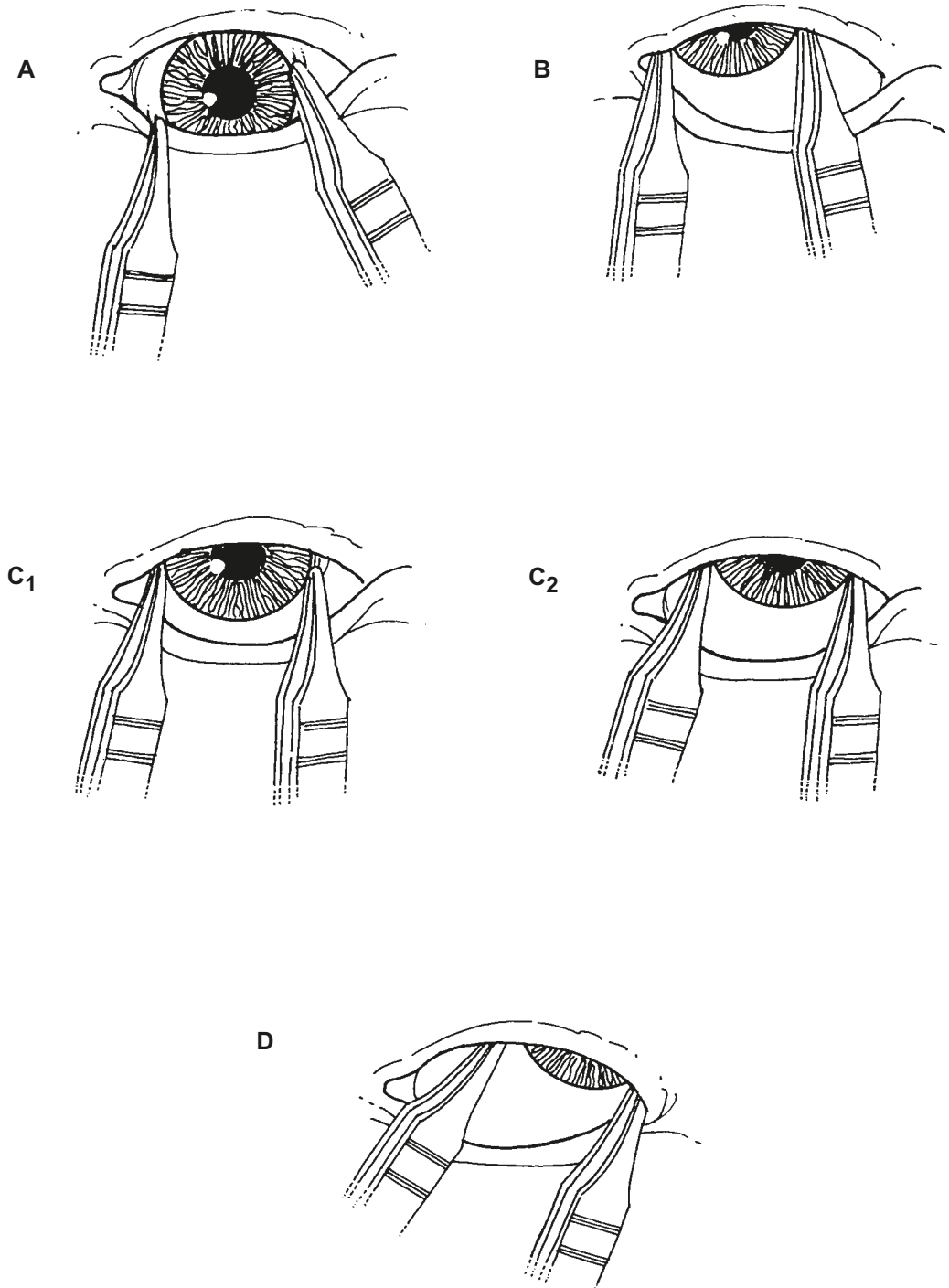


Figure 8 The inferior oblique traction test viewed from above the patient's head

- A** The right eye is grasped at the limbus.
- B** The eye is rotated nasally and 'pushed back' in the orbit.
- C₁** The eye is brought temporally -- the surgeon 'feels' for the 'pop up' of the inferior oblique which is still present.
- C₂** If no 'pop' is felt, the inferior oblique has been effectively weakened.
- D** The eye normally recedes in abduction regardless of the state of the inferior oblique.

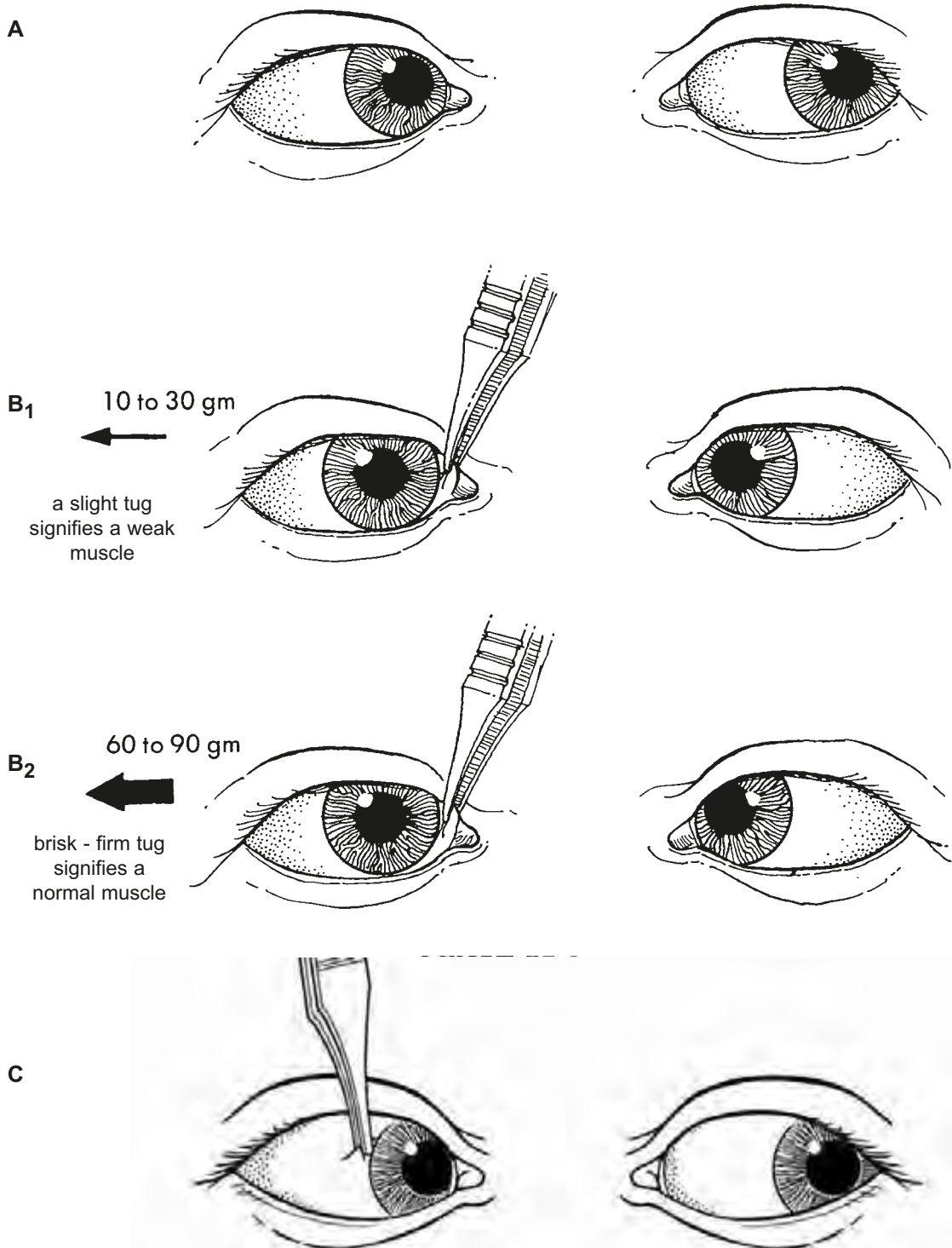


Figure 9

A To test abducting force in the right lateral rectus, the right eye is treated with appropriate topical anesthesia and the patient is instructed to look in extreme left gaze.
B₁ The right eye is grasped at the nasal limbus (or temporal limbus) with fine-toothed forceps. The patient is asked to look slowly to far right gaze. If only a slight tug is felt in the muscle tested (the right lateral rectus in this case), a paresis or paralysis is confirmed.

B₂ If the tug on the forceps is felt as strong then it confirms that the muscle is innervated - not paralyzed.
C If the examiner has difficulty fixing the eye nasally, the restraining forceps can be placed temporally (9 o'clock in the right eye). Great care must be exercised to avoid losing the firm grasp of the eye that could result in scratching the cornea. The tester should remain alert to pull the forceps away if the grip is loosening.

can be used in the evaluation of strabismus with restriction in a patient at any age, but it is especially useful in a patient who will not cooperate for other tests of generated muscle force. Patients with thyroid ophthalmopathy especially involving the inferior rectus often have chronic elevation of intraocular pressure by this mechanism. Optic nerve changes and visual field defects characteristic of glaucoma have been seen in such cases.

The eye normally rotates around its center, the antagonist relaxing and the agonist contracting with no increase in IOP until the extremes of duction have been encountered (Figure 10). When an ocular move-

ment is limited by a restriction, the point of restriction becomes a fulcrum, the eye is pulled backward, and the IOP increases. A longstanding right esotropia with normal lateral rectus function in the right eye but restriction of the antagonist right medial rectus is shown. This condition can occur after recovery from a sixth nerve palsy or with co-contraction in Duane. Orbital resistance meeting the backward-pulled eye produces an elevation in IOP, as recorded earlier in the primary position. If in the cases cited previously the limited abduction of the right eye were due to paresis of the right lateral rectus, no rise in IOP would occur on attempted abduction.

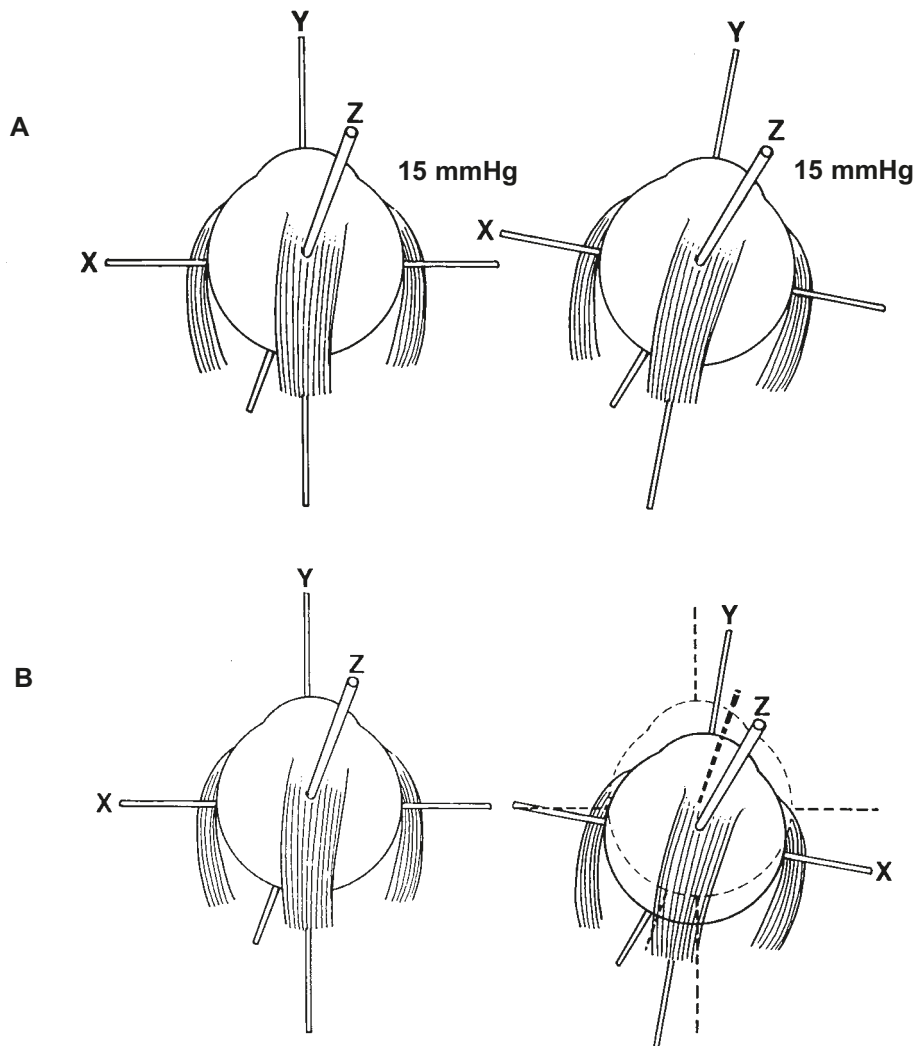


Figure 10

A As the eye rotates in adduction around the Z axis no additional pressure is exerted and intraocular pressure is unchanged.

B As the eye attempts to rotate in adduction a stiff, non-relaxing lateral rectus becomes a fulcrum, the globe retracts and pressure rises.

continued.

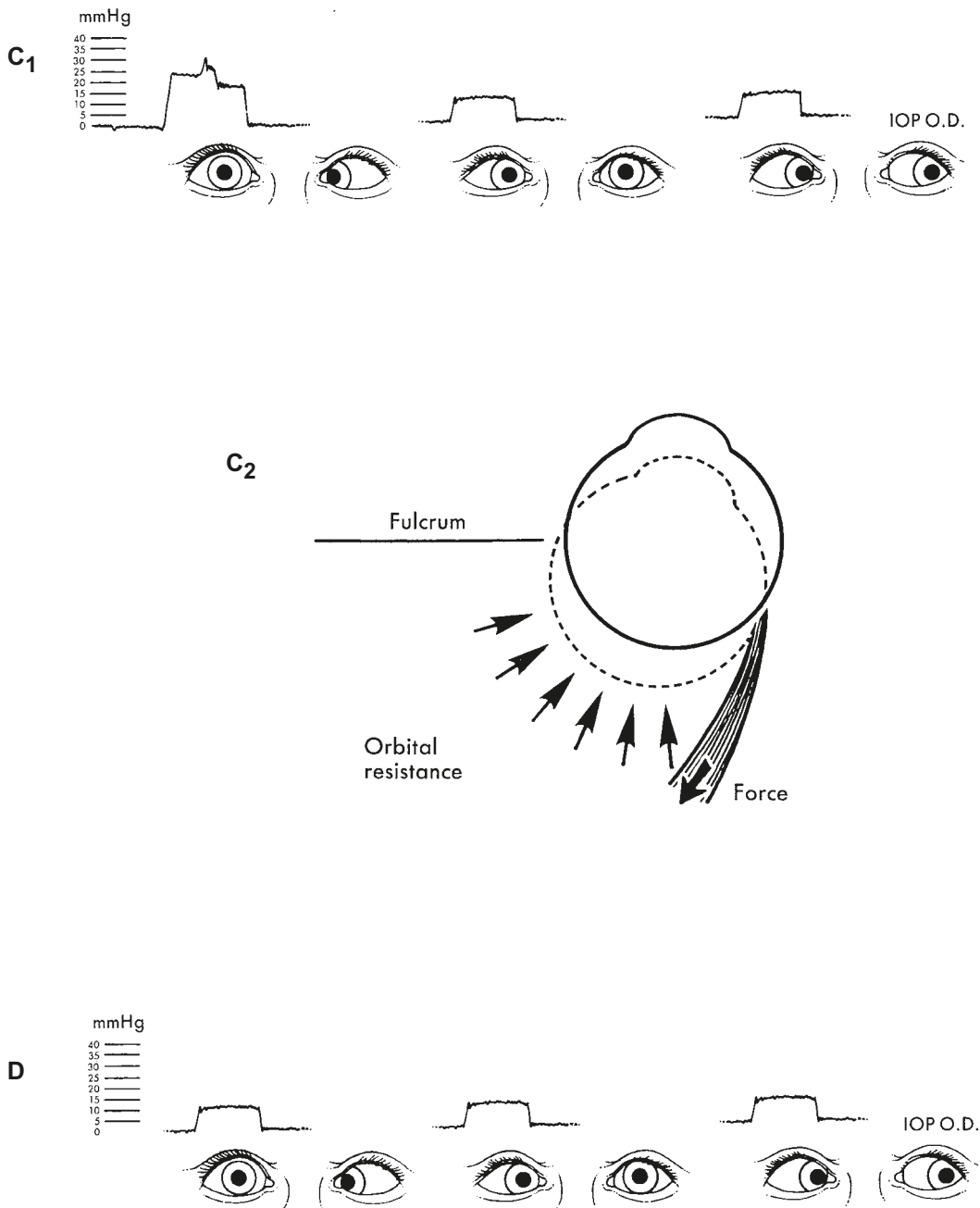


Figure 10, cont'd

- C₁** Intraocular pressure increases during attempted abduction in the right eye that has normal or near normal force generated in the lateral rectus in the presence of restriction to abduction.
- C₂** Force on the globe as it is pulled back against the orbital contents.

- D** In the absence of force toward abduction with or without associated restriction, no increase in pressure occurs.

A case posted on the pediatric ophthalmology list serve described a 49-year-old man who had a large left exotropia and limited adduction. On attempted adduction of the left eye intraocular pressure increased from 15 to 55 mmHg. The optic nerve demonstrated glaucomatous cupping and a typical glaucoma visual field defect was found. In this case, release of the restriction would relieve the increased pressure and slow or eliminate the glaucomatous process.

muscle insertions on the globe, the muscle's effect on movement, and considering potential passive mechanical restrictions to movement.

The globe moves around the x-, y-, and z-axes as shown in Figure 11. The eye abducts and adducts around the z-axis, elevates and depresses around the x-axis, and carries out intorsion and extorsion around the y-axis. The eye moves according to a combination of these factors in Listing's plane but for practical purposes, it is useful to think of these movements in isolation. The globes are shown in Figure 12 as viewed from above. They are divided into quadrants. The superior rectus (SR) elevates, adducts, and intorts the globe. The superior oblique (SO) depresses,

Motor physiology - 'The muscles' actions'

After the patient's ocular motility evaluation has been completed a decision is made which may include planning for extraocular muscle surgery. This plan for surgical treatment should be written on the patient's record when the patient is scheduled for surgery. In most instances, the specific muscles to be operated and the direction and amount they are to be weakened, 'strengthened', or shifted will have been decided. This plan is not usually influenced by the alignment of the eyes in the operating room after anesthesia has been obtained. However, in those patients with restricted motility, particularly those who have been operated on previously, the type and amount of surgery can be determined only after performing forced ductions while the patient is asleep and in some cases only after assessing the state of the muscles and associated restrictive fascia seen during dissection at the time of surgery.

When recording a plan for surgery, it is helpful to think in terms of the mechanical components. This may be accomplished by picturing the location of the

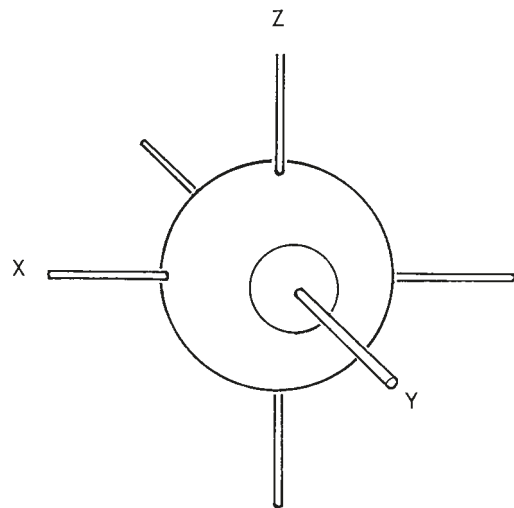


Figure 11 Fick's Axes

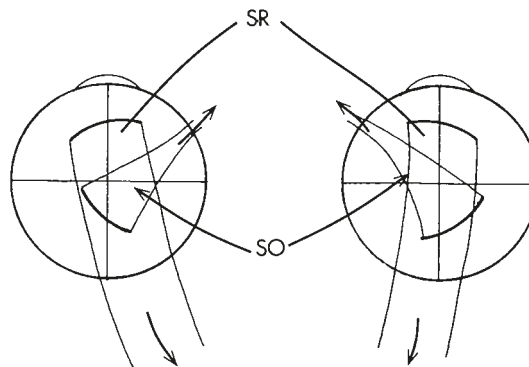


Figure 12
The superior oblique depresses, intorts and abducts. The superior rectus elevates, adducts, and intorts.

abducts, and intorts the globe. In addition, the anterior fibers of the superior oblique tendon are primarily responsible for intorsion and the posterior fibers for depression. If the superior oblique tendon is moved forward, it will increase intorsion. If the superior rectus is moved temporally, it will increase intorsion, and if it is moved nasally, it will decrease intorsion. Both of these superior muscles move the globe in the x-, y-, and z-axes.

The globes are shown as viewed from below in Figure 13. The inferior rectus (IR) depresses, adducts, and extorts the globe. Recessing the inferior rectus as done in thyroid restrictive disease can result in decreased adduction and an A pattern. This can be avoided by a nasal shift. The inferior oblique (IO) elevates, abducts, and extorts the globe. Both of these inferior muscles move the globe in the x-, y-, and z-axes.

In the primary position, the medial rectus (MR) and lateral rectus (LR) muscles adduct and abduct the globe, respectively (Figure 14). The eye is viewed from the lateral aspect. These muscles move the globe around the z-axis. With the eye elevated, both horizontal rectus muscles elevate the globe (Figure 15). This adds movement of the globe around the x-axis. With the eye depressed, both horizontal rectus muscles depress the globe. Both horizontal rectus muscles can be shifted upward to improve elevation or downward to improve depression (Figure 16). When the medial or lateral rectus insertion is shifted upward, the muscle becomes an elevator in part. When the medial or lateral rectus insertion is shifted downward, the muscle becomes a depressor in part.

Mechanical restrictions hampering ocular movements can be associated with the following: (1) conjunctiva, (2) anterior Tenon's capsule, (3) the muscle itself, (4) intermuscular membrane, and (5) orbital fat (Figure 17). All of these factors must be considered during surgery.

When a horizontal rectus muscle is shifted vertically, this muscle has less effect on the globe alignment in the same direction as the muscle is shifted. For example, when the medial rectus is shifted up, this muscle has less adducting effect in upgaze. When the medial rectus is shifted downward, adducting effect is less in down gaze. The same applies for the lateral rectus. This response is the basis of vertical shift of the horizontal recti to treat 'A' or 'V' pattern.

As a rule, all previously operated muscles that are being considered for surgery should be inspected under direct visualization before any strengthening, weakening, or transfer procedures are performed. In case of reoperation, findings at the time of surgery could lead to change in the surgical plan. For example, in a patient with secondary exotropia occurring after recession of the medial rectus and resection of the lateral rectus for esotropia, depending on the angles, the lateral rectus would require weakening and the medial rectus strengthening. If treated like a new case, the lateral rectus would be weakened first and then the medial rectus strengthened. This approach follows the rule of doing the recession first in a recession-resection procedure. However, in secondary cases where two muscles will be operated and forced ductions are unrestricted and ductions limited, the muscle to be strengthened is isolated first and tagged with a 4-0 silk suture. This is a good practice to follow because it allows the surgeon to determine if a previously operated muscle is indeed present or, if present, has slipped from the intended point of insertion. The condition of the muscle to be strengthened by advancement and resection may influence the amount of weakening that should be done on the antagonist, if any at all, or may indicate that a muscle transfer should be performed. For example, esotropia occurring after recession of the lateral rectus and resection of the medial rectus for exotropia and with

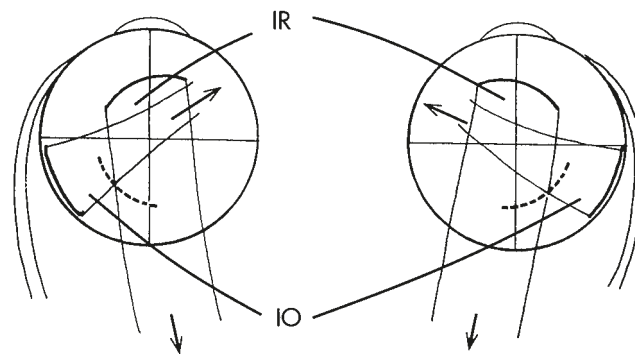


Figure 13

The inferior oblique elevates, extorts, and abducts. The inferior rectus depresses, adducts, and extorts.

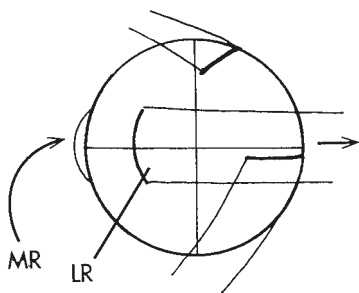


Figure 14
The lateral rectus abducts and the medial rectus adducts.

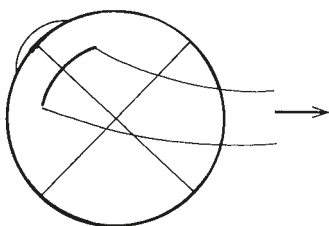


Figure 15
In upgaze the horizontal recti may contribute to elevation.

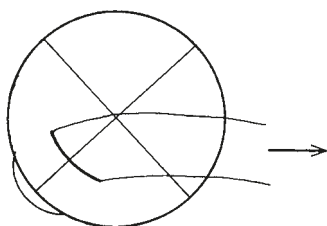


Figure 16
In downgaze the horizontal recti may contribute to depression.

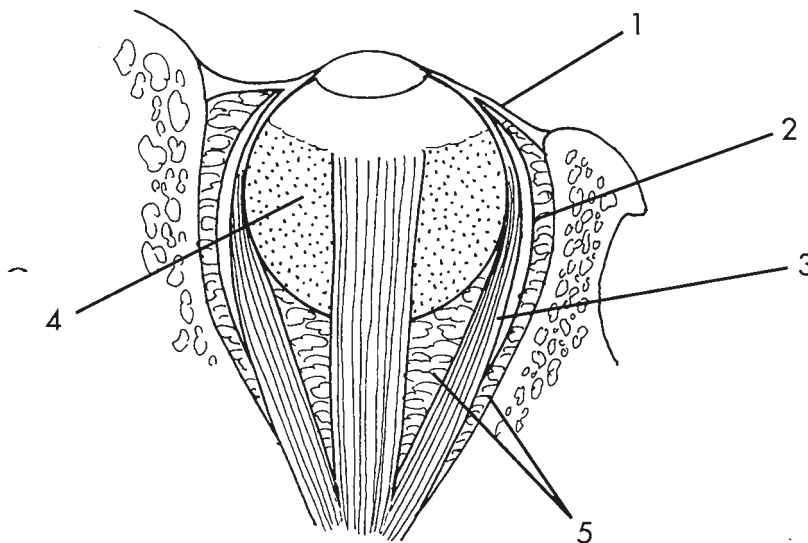


Figure 17
Mechanical restriction limiting eye movement can be associated with:

1 Conjunctiva	4 Intermuscular membrane (posterior Tenon's)
2 Anterior Tenon's	5 Orbital fat
3 The muscle	

limited forced (and voluntary) abduction may be treated with recession of a tight medial rectus alone (provided muscle-force generation of the lateral rectus is adequate). In reoperations it is essential to assess the relative roles played by weak or slipped muscles, tight muscles or adhesions, or both. In these cases surgery on a single muscle may be sufficient if significant muscle slippage or restriction is discovered.

Hering's law - yoke muscles

The extraocular muscles are yoked in their action according to Hering's law of distributed innervation. By this law, muscles in each eye are associated as by a yoke (as oxen in days of old and in some parts of the world now) and act together to move the eyes toward the object of regard while receiving equal innervation. Movements of the eyes together by the action of yoked muscles are called versions. This is in contrast to ductions or movements of just one eye. Surgical alteration of one extraocular muscle in the fixing eye always affects its yoked muscle. This must be considered in every patient undergoing extraocular muscle surgery. For example, deficient elevation of the right eye in adduction can be caused by underaction of the right inferior oblique muscle. If the surgeon wishes to enhance elevation of the right eye in adduction but does not wish to carry out a strengthening procedure on the right inferior oblique (not an easy or straightforward procedure), the yoke muscle of the right inferior oblique - the left superior rectus muscle - may be weakened. In this case the left eye will require more innervation to elevate in abduction. By

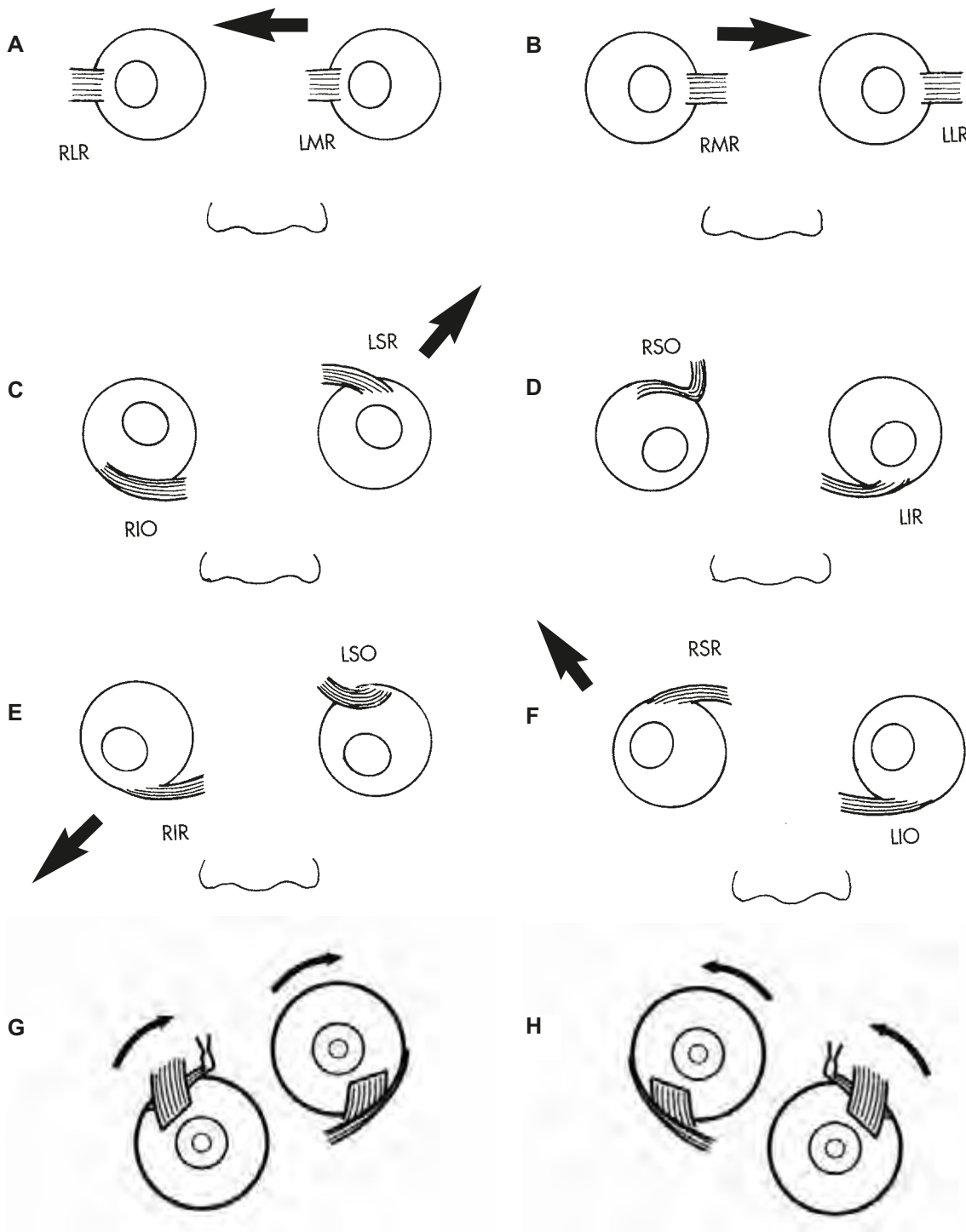


Figure 18 The Yoked Extraocular Muscles

- A** The right lateral rectus and left medial rectus muscles are yoked to produce dextroversion.
- B** The left lateral rectus and right medial rectus muscles are yoked to produce levoersion.
- C** The right inferior oblique and the left superior rectus muscles are yoked to produce elevation in up left gaze.
- D** The right superior oblique and left inferior rectus muscles are yoked to produce depression in down left gaze.
- E** The right inferior rectus and left superior oblique muscles are yoked to produce depression in down right gaze.

- F** The right superior rectus and the left inferior oblique muscles are yoked to produce elevation in up right gaze.
- G** With the head tilted 45° right, the right superior oblique and right superior rectus rotate the right eye clockwise. In the left eye, the left inferior oblique and left inferior rectus are clockwise rotators.
- H** With the head tilted 45° left the left superior oblique and left superior rectus rotate the left eye counter clockwise and the right inferior oblique and right inferior rectus are counter clockwise rotators.

Hering's law, the yoke of the muscle responsible for elevation in abduction (left superior rectus) which is the right inferior oblique will receive more innervation. By this technique the right inferior oblique can be 'strengthened'. If in this example the eye with the paretic muscle is used for fixation, weakening the yoke will simply move the fellow eye down to align with the eye with the underacting muscle. This principle is applied with the posterior fixation suture to produce a 'laudable' secondary deviation.

In addition to the six positions of gaze testing the action of these yoked muscles, the alignment of the eyes is observed in primary position with the head tilted 45° to the right and the left, and looking 30° up and 30° down.

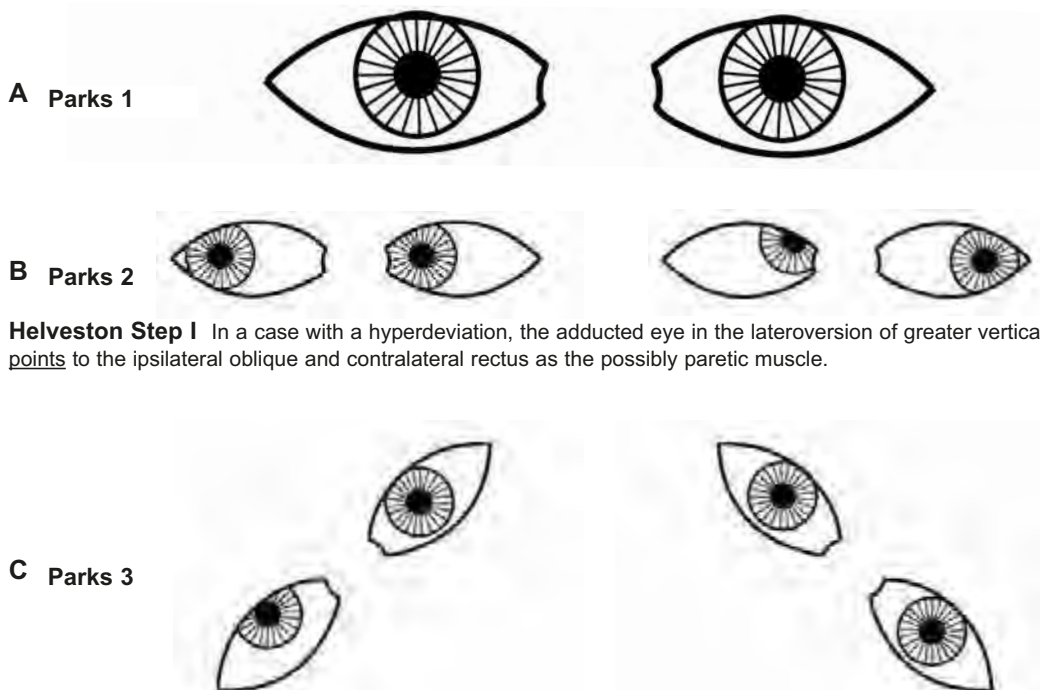
The fact that the oblique and rectus muscles are torsional synergists but vertical antagonists is the basis for the *Bielschowsky head tilt* test which demonstrates greater vertical deviation when the head is tilted toward the side of the paretic superior oblique. This is also the key step in the Parks 3-step

test that sorts out paretic obliques and vertical recti (Figure 19).

During upgaze the inferior oblique muscles can overact causing a 'V' pattern. The abducting force of the inferior obliques producing a greater exodeviation in upgaze results from weakness of the superior obliques, upward displacement of the medial pulleys or weakness of adduction after recession of the medial recti. Antimongoloid fissures are common in 'V' esotropia (Figure 20).

In downgaze, overaction of the superior obliques results in an 'A' pattern that is seen in both exo and esodeviations. Overaction of the superior obliques is seen with mongoloid fissures and with downward displacement of the medial pulleys.

As mentioned previously, non-surgical treatment will not be discussed in detail in this text. All appropriate nonsurgical treatment including glasses, prisms, anticholinesterase, occlusion, orthoptics, and the like should be carried out in appropriate cases before embarking on surgery.



Helveston Step I In a case with a hyperdeviation, the adducted eye in the lateroversion of greater vertical deviation points to the ipsilateral oblique and contralateral rectus as the possibly paretic muscle.

Helveston Step II If the vertical deviation is greater with head tilt toward the higher eye, the oblique from Step I is paretic. If the opposite is true; that is, the vertical deviation is greater with the head tilted toward the lower eye, the vertical rectus from Step I is paretic.

Figure 19 Positive Bielschowsky test in a patient with right superior oblique palsy

- A** Right hypertropia shown here latent because of vertical fusional amplitudes
- B** Overaction of the right inferior oblique in levoversion
- C** With head tilt to the right the hypertropia increases because of the weakly opposed elevating action of the right superior rectus as it responds to the need to intort the right eye. This is shown here as the 'Parks Three Step Test.'

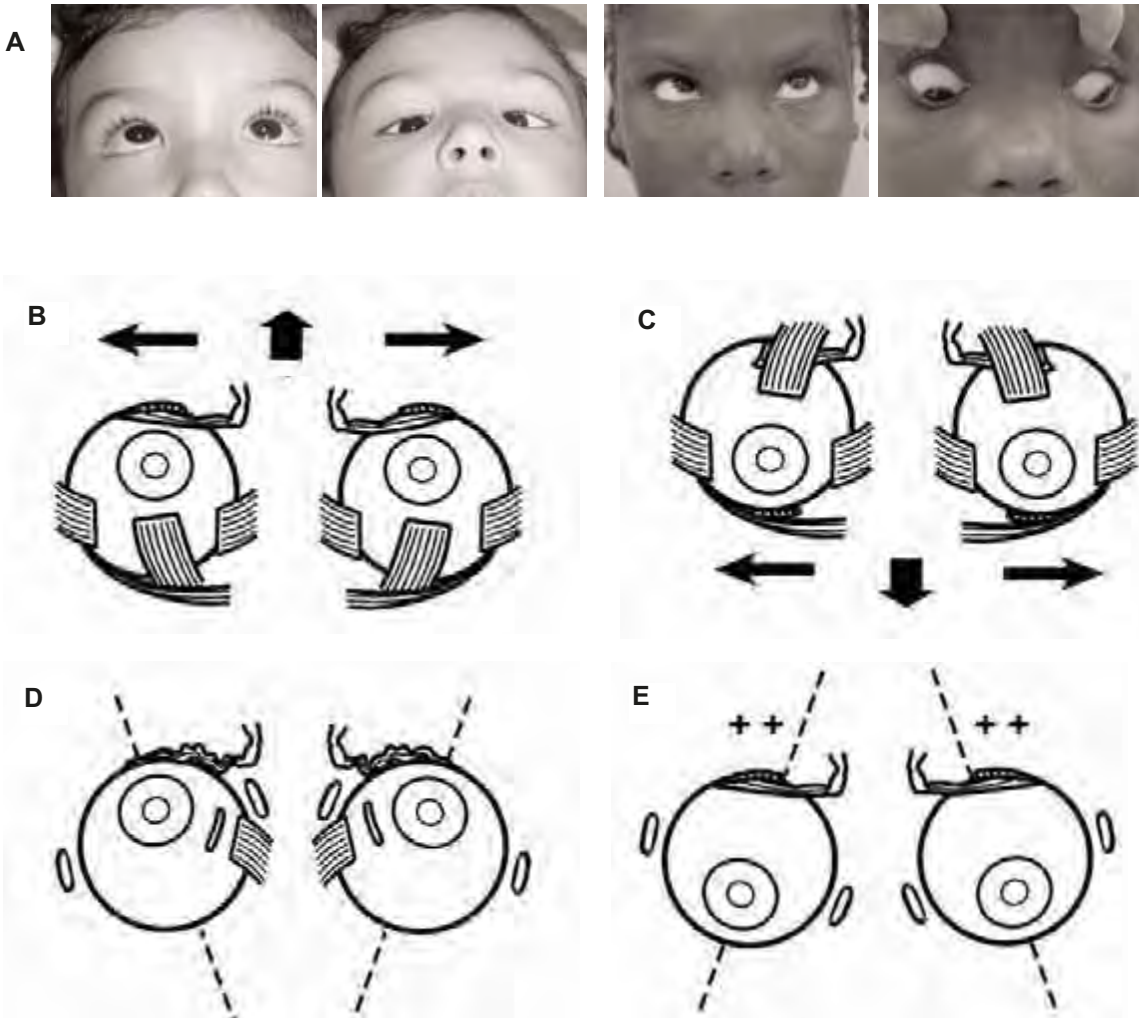


Figure 20

- A** Antimongoloid fissures are associated with 'V' pattern esotropia. Mongoloid fissures are associated with 'A' esotropia. Esotropia in this patient is in upgaze only. This 'rule' does not necessarily hold for exodeviations.
- B** Looking up the abducting action of the inferior obliques can produce a 'V'.

- C** Looking down the abducting action of the superior oblique can produce an 'A'.
- D** Lax superior oblique tendons, upward displacement of pulleys and recessed medial rectus contribute to a 'V'.
- E** Downward displacement of the pulleys contribute to an 'A'.

Step 2: Results to be expected from surgery

Each surgical procedure done on the extraocular muscles is unique. This surgery is influenced by factors related both to the patient and to the specific surgical procedure performed. These issues notwithstanding, it is possible to establish guidelines that can be useful in initial planning and proper execution of successful strabismus surgery. The guidelines presented here are only a launching pad for the surgeon who will gain experience in techniques of strabismus surgery. Once a surgical career has taken flight, each strabismus surgeon must apply his or her own valid personal modifications to the following.

Horizontal rectus surgery for esotropia



Single muscle procedure for esotropia:

Surgery on a single horizontal rectus muscle as primary treatment of esotropia should be employed sparingly and then only for special reasons. A special reason might be a patient with small-angle esotropia and fusion potential where a single medial rectus recession could promote fusion. A single medial rectus recession is usually performed because the patient has diplopia and/or asthenopia and has potential for bifoveal fusion.

Individuals with esotropia, who have an angle sufficiently small to be corrected by a single medial rectus recession, tend to have peripheral fusion and harmonious anomalous retinal correspondence and are included in the monofixation syndrome. Such patients are usually cosmetically acceptable and are often better without surgery. A single medial rectus recession performed for fear of producing an overcorrection is usually a manifestation of trepidation on the part of an overcautious surgeon. Single medial rectus recession for patients with limitation of motility such as Duane syndrome is worthwhile and is discussed elsewhere (see chapter 5).

Resection of a single lateral rectus muscle for esotropia is less effective than recession of a single medial rectus muscle and is less likely to be indicated except in specific cases such as a lateral rectus muscle that has slipped after prior surgery. Advancement of a previously recessed lateral rectus can be effective in cases of small angle incomitant esotropia with limited abduction after lateral rectus recession.



Two muscle surgery for esotropia:

Bimedial rectus recession measured from the insertion. A minimal bimedial rectus recession of 2.5 mm reduces an esodeviation approximately 15Δ to 20Δ . A maximum bimedial rectus recession of 7 mm* results in as much as 40Δ or more reduction in the esodeviation. Slightly more effect may be obtained in infants, but definitely less effect is produced in adults. Indications for bimedial rectus recession include:

1. Congenital esotropia up to 50Δ
2. Esotropia in an adult up to 40Δ
3. Equal vision
4. Esotropia greater at near (high AC/A)
5. Excess adduction

A bimedial rectus recession with vertical shift may also be performed in patients with an A or V pattern, especially in patients without oblique dysfunction. Lack of oblique muscle overaction is determined by noting absence of hyper- or hypo-deviation in the adducting eye in latero-version. In this case, the medial rectus muscles are shifted vertically toward the closed end of the pattern. This means that the recessed medial rectus muscles are shifted upward for an A pattern and downward for a 'V' pattern.

In patients with a 'V' pattern with 'inferior oblique overaction', a bimedial rectus recession and bilateral inferior oblique weakening is usually the preferred technique.

Upward displacement of the medial pulleys or downward displacement of the lateral pulleys or congenital laxity of the superior oblique tendons are also a likely cause of a 'V' pattern. In either case, the inferior oblique may apparently 'overact' but the real cause for hyperdeviation in adduction and for abduction in elevation (producing the 'V') is deficient checking with a lax tendon or shifted vectors with pulley displacement.

The desire for symmetry is not necessarily an indication for performing a bimedial rectus recession in every case of esotropia. A recession of the medial rectus and resection of the lateral rectus is indicated in cases with poor vision in one eye or with other reasons to limit surgery to one eye. In addition, some surgeons simply prefer to perform recession-resection and this is perfectly acceptable.

Bimedial rectus recession measured from the limbus. Since 1975 I have measured all bimedial rectus recessions using the limbus as the reference point. This is done for two reasons. First, the medial rectus insertion site was found to be extremely variable, ranging from 3.0 to 6.0 mm (average 4.4 mm) in a series of esotropic patients, with the insertion site having no relationship to the angle of deviation. Second, up to 50% of patients undergoing bimedial rectus recession for congenital esotropia before this time (when maximum medial rectus recession was 5.0 to 5.5 mm) required additional surgery because of undercorrection of the esodeviation. The unacceptable number of undercorrections suggested that a larger bimedial rectus recession should be performed provided it could be accomplished safely.

Rationale for measuring from the limbus. Assuming that the medial rectus muscles could be recessed to the equator without crippling the action of the muscle, we decided to move the medial rectus muscle to the equator and consider this a maximum recession for large-angle congenital esotropia. The medial recti could then be recessed a lesser amount for smaller angles while still measuring from the limbus. The easiest way to locate the equator is to use the limbus as a reference. Since the corneal diameter defined by the limbus as well as the axial length are fairly consistent according to patient age, it is relatively easy to calculate the distance of the equator from the limbus. In the infant between six months and one year, this value is approximately 10.5 mm. Between four and six months the maximum is 10.0 mm. In the child over one year, the equator is approximately 11.5 mm from the limbus. Therefore, these dimensions were utilized as guides for performing bimedial rectus recessions. These maximum recessions have been used for any large angle of congenital esotropia, even those in excess of 50Δ . On the

* This might be excessive in a normal or smaller eye with a medial rectus insertion 5.5 mm from the limbus.

Less than 1 year		More than 1 year	
ET	Medial rectus recession measured from limbus	ET	Medial rectus recession measured from limbus
25Δ	8.5 mm	25Δ	8.5 mm
35Δ	9.5 mm	35Δ	9.5 mm
45+Δ	10.5 mm	45Δ	10.5 mm
< 6 mo	10.0 mm	55+Δ	11.5 mm

Table 1

other hand, smaller deviations receive smaller recessions with a minimum bimedial rectus recession for congenital esotropia being 8.5 mm from the limbus. Intermediate deviations are titrated between these numbers and are described above (Table 1). It should be emphasized that these numbers are merely guidelines. The surgeon should individualize his/her surgical numbers according to experience.

Measuring from the limbus has proved to be an effective way of performing a larger bimedial rectus recession without crippling the effect of the medial rectus muscle postoperatively. This technique has resulted in 80% to 85% of patients being aligned satisfactorily after just one procedure. Other surgeons have equally good results performing bimedial rectus recessions of up to 7 mm (rarely more) measuring from the original insertion. However, I continue to use measurement from the limbus because of the wide variations in the medial rectus insertion site and because of the excellent results obtained with limbal measurements.

When bimedial rectus recession measured from the limbus was introduced, it included routine conjunctival recession and was called the en bloc or augmented recession. Analysis of results indicated that it was unnecessary to routinely recess the conjunctiva. We now perform conjunctival recession to the original medial rectus insertion site when performing a bimedial rectus recession only in cases where passive abduction is limited preoperatively by a tight conjunctiva that occurs in approximately 5% of cases. In

cases without tight conjunctiva, and this includes most cases with congenital esotropia, I use a cul-de-sac incision.



Bilateral lateral rectus resection. I seldom perform bilateral lateral rectus resection. It is used mostly as a second procedure by surgeons who routinely do a smaller bimedial rectus recession as an initial procedure for large-angle congenital esotropia and who decline re-recession of the medial rectus muscles. As a rule, a strengthening procedure of a rectus muscle without recession of its antagonist at the same procedure is less effective at reducing the angle of strabismus than a weakening procedure without strengthening of the antagonist. Resection is considerably less effective when done alone than the same resection combined with a recession of the antagonist performed at the same procedure. Two situations that call for bilateral lateral rectus resection are divergence insufficiency (paralysis) and residual esotropia in a patient who has undergone a maximum bimedial rectus recession. Approximately 20Δ of esodeviation is corrected with a minimal 5 mm bilateral lateral rectus resection and although good data are lacking, I estimate that up to 35Δ to 40Δ of esotropia could be corrected with a maximum 9 to 10+ mm bilateral lateral rectus resection.



Recession of the medial rectus - resection of the lateral rectus. A minimum recession-resection procedure for esotropia is 2.5 mm medial rectus recession and a 5 mm lateral rectus resection that could be expected to correct 20Δ to 25Δ of esotropia. But, if a smaller angle is treated, a single medial rectus recession could be considered. A maximum recession-resection procedure of 5 mm (10.5 mm from the limbus) medial rectus recession and 9 mm lateral rectus resection in a child less than 1 year of age and of 7 mm (11.5 mm from the limbus) medial rectus recession and 10+ mm lateral rectus resection in a child over 3 years corrects up to $50+$ Δ of esotropia. Increasing the minimum numbers or decreasing the maximum numbers can be done for deviations between 20Δ and 50Δ of esotropia and for children between the ages of 1 and 3 years.

The amount of surgery may be divided between the medial and lateral rectus muscles according to findings on ductions and versions as well as on differences between distance and near measurements. If excess adduction and/or greater deviation at near is found, more emphasis is placed on the medial rectus recession. If deficient abduction and/or greater deviation in the distance is present, more emphasis is placed on the lateral rectus resection. This represents the symmetrizing effect of the recession-resection procedure.



Three muscle surgery for esotropia:

Bimedial rectus recession and lateral rectus resection. When more than 50Δ of esotropia must be corrected, some surgeons believe strongly that surgery should be performed on three horizontal rectus muscles. This approach with maximum numbers could correct up to 75Δ of esotropia, especially in a younger patient. This maximum procedure consists of a 5.0 mm bimedial rectus recession and 9 mm resection of one lateral rectus in patients less than 1 year of age and a bimedial 7 mm (11.5 mm from the limbus) rectus recession and 10+ mm resection of one lateral rectus in patients over 3 years of age. Deviations between 50Δ and 75Δ are corrected by reducing maximum three muscle surgery by 0.5 to 1 mm per muscle. Three muscle surgery for esotropia had been criticized on the grounds that after such surgery only one unoperated horizontal rectus muscle remains. Under these conditions, it has been said that it is more difficult to correct any residual esodeviation

that might remain. However, residual esotropia in this case could be treated with a marginal myotomy of a previously maximally recessed medial rectus muscle combined with a resection of the unoperated lateral rectus muscle. This technique can, in my experience, be effective treatment for residual esotropia after previous three muscle surgery. However, the surgeon must remain alert for specific reasons why a patient does not respond in the way expected. Is unrecognized restriction, paralysis, or misdirection the cause? Is further evaluation required?



Four muscle surgery for esotropia:

Bimedial rectus recession - bilateral lateral rectus resection. Esotropia greater than 75Δ may be treated surgically with a bilateral recession-resection procedure. This four muscle procedure should be used with discretion and is not often indicated. Four muscle surgery should not be performed, except in special circumstances, in infants. However, certain adults and older children with esodeviations of between 75Δ and 100Δ , particularly with limited forced abduction usually from longstanding strabismus can benefit from a bimedial 7 mm rectus recession (11.5 mm from the limbus) and a 10 mm bilateral lateral rectus resection. Four muscle surgery should ordinarily be limited to these 'maximum' numbers.

Horizontal rectus surgery for exotropia



Single muscle surgery for exotropia:

Single lateral rectus recession or single medial rectus resection. A single lateral rectus recession or a single medial rectus resection for treatment of exotropia is rarely indicated. However, certain patients who have a very small incomitant exotropia and who have fusion potential, often with head turn, can be helped by this procedure. These patients are rare. In my experience, this condition is usually caused by insufficient initial surgery in which only one lateral rectus muscle was recessed. In such a case, either the medial rectus should be resected or the lateral rectus recessed to produce the most nearly comitant results. The findings on versions and ductions, as well as prism and cover measurements in the lateral versions, indicate what need be done to achieve comitance. For example, a tight lateral rectus after a recession and resection for esotropia or a case

of exotropic Duane syndrome might be treated with a single lateral rectus recession to relieve a small angle of exotropia. Usually no more than 15Δ of deviation can be corrected with single muscle surgery for exotropia. An exception would be a larger correction obtained in case of advancement of a slipped muscle.




Two-muscle surgery for exotropia:

Bilateral lateral rectus recession. A minimum bilateral lateral rectus recession of 5 mm will correct approximately 20Δ to 25Δ of exotropia. A maximum bilateral lateral rectus recession of 8+ mm can correct up to 50Δ of exotropia. The same angle would be corrected if the deviation were either manifest or latent. Bilateral lateral rectus recession is a common strabismus surgical procedure.



Bimedial rectus resection. Strengthening and weakening procedures of the extraocular muscles mainly improve ocular alignment while maintaining or creating comitance. These procedures do not ordinarily influence vergences. Nevertheless, certain patients demonstrating ‘intractable’ convergence insufficiency not helped by near point exercises or other orthoptic treatment may be helped some with a bimedial rectus resection. A 5 to 7 mm bimedial rectus resection can be considered reasonable treatment for a convergence insufficiency measuring between 12Δ and 25Δ of exotropia at near and with less or no exotropia in the distance and with a remote near point of convergence. Bimedial resection for convergence insufficiency can result in esotropia in the distance as the price for relieving near symptoms.

Intermittent exotropia persisting after bilateral lateral rectus recession with a significant exodeviation at distance and at near can also be treated with a bimedial rectus resection. In such a case, a minimum 5 mm bimedial rectus resection can correct approximately 20Δ of exotropia. A maximum 10+ mm bilateral medial rectus resection can correct up to 40Δ of exotropia.



Lateral rectus recession with medial rectus resection. A minimum recession-resection procedure for exotropia is 5 mm lateral rectus recession and 5 mm medial rectus resection. This approach will correct

approximately 20Δ to 25Δ of exotropia and produce about the same reduction in the exotropia in the distance and at near. A maximum recession-resection procedure for exotropia is 8 to 10 mm lateral rectus recession and 10+ mm medial rectus resection. This procedure would be expected to correct up to 50Δ of exotropia.

The majority of exotropic patients, in my experience, have basic exotropia (same exotropia distance and near) or simulated divergence excess exotropia (near exotropia equal to or nearly equal to distance exotropia after several hours occlusion of one eye). For this reason, a recession-resection procedure is arguably the most logical procedure. However, to avoid the necessity of resecting the medial rectus muscle, a procedure which may produce a reddened conjunctiva and sometimes limited abduction, it is common for the surgeon to choose a bilateral lateral rectus recession in most cases of intermittent exotropia.

A recession-resection procedure is an effective and predictable way to alter the alignment of the eyes to produce cosmetic as well as functional improvement. Surgically induced incomitance is infrequent and is not usually significant when it does occur. This incomitance can be of benefit for patients treated for convergence insufficiency because it allows them to find an area of fusion at near and at distance, even when a small overcorrection occurs, by assuming a face-turn.



Three-muscle surgery for exotropia:

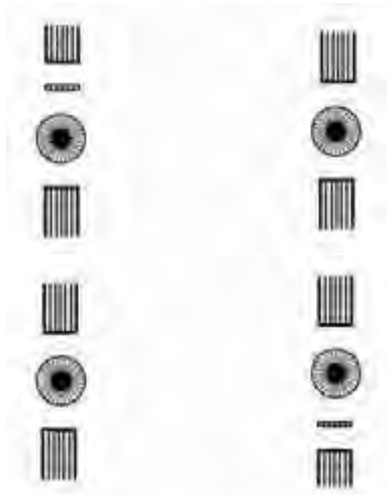
A maximum bilateral lateral rectus recession of 8 to 10 mm combined with a maximum medial rectus resection of 10+ mm in one eye will correct up to 75Δ of exotropia. To correct deviations between 50Δ and 75Δ maximum, three muscle surgery is reduced by 0.5 to 1 mm per muscle.



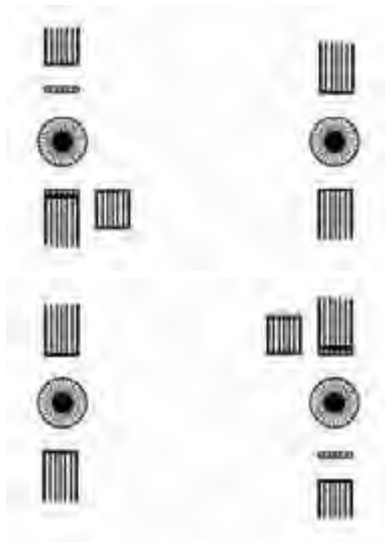
Four-muscle surgery for exotropia:

A maximum 8 to 10 mm bilateral lateral rectus recession combined with a maximum 10+ mm bimedial rectus recession will correct 90Δ to 100Δ of exotropia. If four muscle surgery is indicated for exotropia, a maximum approach is usually done.

Vertical rectus surgery



Single muscle surgery on the vertical rectus muscles can be effective and predictable in most cases. This is in contrast to single muscle surgery on the horizontal rectus muscles which is less effective and less predictable. A minimum 2.5 mm recession or resection of either the superior or inferior rectus will produce approximately 8 Δ of deviation reduction in the primary position. This results in slightly more correction in the field of action of the muscle after recession and in the field of action of the antagonist after resection. A 5 mm recession or resection of a vertical rectus muscle will produce up to 15 Δ of reduction in the primary position deviation and slightly more in the field of action of the muscle or of the antagonist.



A combined recession-resection of the vertical recti corrects with minimum numbers 15 Δ and with maximum numbers 25 Δ to 30 Δ of deviation in the primary position. The normal maximums for recession and resection of the inferior rectus can be exceeded in patients who demonstrate restriction on testing with forced ductions from such causes as thyroid myopathy, old blowout fractures, fibrosis syndrome, or pre-

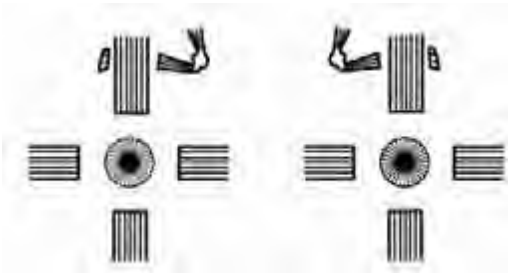
vious surgery. In selected cases, the inferior rectus can be resected up to 10 mm and recessed up to 10 mm or even more. With recession of the inferior rectus, the intermuscular membrane should be dissected to at least 10 mm from the insertion and Lockwood's ligament can also be brought forward to avoid lower lid ptosis.

I have performed a 'free tenotomy' of the inferior rectus with minimal dissection of the intermuscular membrane in patients with severe thyroid myopathy affecting the inferior rectus. This has produced marked improvement in motility. A drawback is the ptosis of the lower lid resulting in 2 to 3 mm widening of the palpebral fissure. This lower lid ptosis is less objectionable if the procedure is done bilaterally. These large recessions may be carried out more predictably using an adjustable suture. However, the inferior rectus is susceptible to early or late slippage resulting in overcorrection because of the 'destabilizing' effect of the inferior oblique, Lockwood's, and the lower lid retractors.

I have performed 9 mm resections of the inferior rectus without causing significant narrowing of the palpebral fissure. It should be emphasized, however, that patients should be selected very carefully before exceeding the usual limits of recession and resection on the inferior rectus. The superior rectus should not ordinarily be resected more than 5 mm. Ptosis involving the upper lid is easier to produce, harder to avoid, and cosmetically more objectionable than similar displacement of the lower lid.

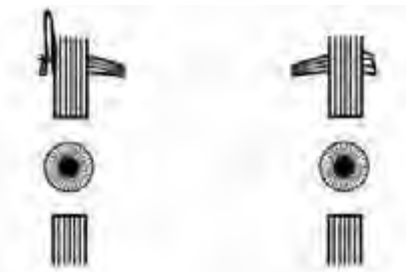
If the surgeon takes care when dissecting the intermuscular membrane and does not cut the superior oblique tendon, the superior rectus may be recessed 10 mm or more without causing bothersome retraction of the upper lid. When this very large superior rectus recession is carried out, it is usually for treatment of dissociated vertical deviation. If the superior rectus muscle is recessed more than 6 to 8 mm, theoretically it must be placed behind the superior oblique tendon as it passes beneath the superior rectus muscle between the insertion of the superior oblique and the trochlea. Most surgeons who claim to perform large superior rectus recessions do so with the hang-loose procedure. However, it cannot be guaranteed that the muscle will adhere to a given spot on the globe when a hang-loose suture is used. However, those surgeons who prefer this technique claim to have confirmed satisfactory position of the recessed superior rectus at reoperation. When recessing a rectus muscle, I prefer to suture the muscle to the globe at the determined spot to assure accurate postoperative muscle placement. However, Repka, et. al. have shown reliable muscle placement after hang-loose recession of the horizontal recti.

Surgery of the oblique muscles



Superior oblique weakening:

Tenotomy of the superior oblique muscle produces approximately 5Δ to 15Δ reduction in the hypodeviation in the primary position and slightly greater reduction in the field of action of the muscle. This procedure may be graded somewhat by shifting the site of the tenotomy closer to the insertion for less effect or closer to the trochlea for more effect. It may also be graded with a 'guard' suture which in effect produces a hang-loose tendon lengthening. This was called a 'chicken suture' by Phil Knapp. A 'hang loose' superior oblique tendon weakening can also be done from the insertion. If a tenectomy is done, the degree of weakening of the superior oblique is probably not affected by the amount of tendon removed but instead by the proximity of the nasal margin of the tenectomy to the trochlea. The fascia in the vicinity of the superior oblique tendon should be left as undisturbed as possible when doing a superior oblique tenotomy in order to achieve more predictable results. In practice, unilateral superior oblique weakening is seldom performed except in the case of Brown syndrome or superior oblique myokymia. Wright devised a system for weakening the superior oblique employing a silicone spacer. Bilateral superior oblique weakening is more common and is discussed in the section on surgery for 'A' and 'V' patterns (see chapter 16). In practice, bilateral weakening of the superior oblique tends to have greater effect in larger deviations and less effect in smaller deviations.



Superior oblique strengthening:

Strengthening of the superior oblique by a tuck at its insertion produces up to 15Δ reduction in the hyperdeviation in the primary position and a similar reduction in the hyperdeviation in the field of action of this muscle if the tuck is done properly producing normal symmetric tendon tension. The amount of the

superior oblique that should be tucked depends on how lax or redundant the tendon is at the time of surgery. This is determined by the superior oblique traction test (see page 95). This test should be done in both eyes during every procedure for superior oblique over or under action. It is done even if other muscles are treated. During surgery the tendon is brought up into the tucker or it is tucked 'free hand' until the tendon feels taut; at this point the tuck is secured but with a loop that allows for adjustment. The superior oblique traction test is then repeated. The tuck is then adjusted, if needed, and secured when the traction test is equal to or slightly tighter in the treated compared to the normal fellow eye. The size of the tuck may vary from 6 to 20 mm or more, but it is always dictated by the preoperative tendon laxity and the desired result is an equal or nearly equal superior oblique traction test. Tuck of a superior oblique tendon done in the presence of a normal or tight traction test preoperatively or performing too large a tuck of a lax tendon will result in an unwanted iatrogenic Brown.

Resection of the superior oblique tendon may be accomplished at the insertion in a similar amount to the tuck. In our experience, an effective superior oblique tuck or resection produces some Brown syndrome or mechanical restriction to elevation in adduction, at least in the early postoperative period. Strengthening of the superior oblique is usually performed in superior oblique palsy of the type which has recently been re-classified as congenital versus acquired. Of these two, the congenital palsies have been shown to have a high rate of abnormalities of the tendon. In most cases these are seen as a redundant tendon. With a loose tendon, a tuck or any other strengthening procedure is safe and effective (see chapter 16).

Anterior shift of the superior oblique:

The intorting power of the superior oblique may be enhanced by moving all or part of the effective insertion anteriorly and temporally. This is called the Harada-Ito procedure. In my experience, superior oblique tuck or resection improves both the torsional and vertical deviation. However, when a large torsional deviation of 10 to 15 degrees is present in a patient who has a small vertical deviation, anterior shift is a useful surgical tool. Anterior shift has been done with an adjustable suture technique but this has not become a popular procedure. Selective disinsertion of posterior tendon fibers weakens the depressor effect of the superior oblique, while selective disinsertion of the anterior fibers weakens intorsion.



Inferior oblique weakening:

Weakening of the inferior oblique muscle results in 5Δ to 10Δ reduction in hyperdeviation in the primary position and up to 20Δ less hyperdeviation in the field of action of this muscle. Inferior oblique weakening procedures may be graded, but the value of this is not firmly established. When a recession is performed it is usually ± 8 mm. Disinsertion merely frees the muscle from its insertion. With a myectomy, a 5 to 8 mm segment of muscle is excised a few millimeters below the inferior border of the lateral rectus in the inferior temporal quadrant. Marginal or incomplete myotomy (single or multiple) of the inferior oblique in the inferior temporal quadrant, in my opinion, is not effective. Some surgeons believe that this surgery is an effective weakening procedure. Denervation with extirpation of the inferior oblique seems to be an unnecessarily complicated and extensive way to treat a problem that already has a safe, simple, and effective solution although some prefer this procedure in cases of maximum inferior oblique overaction. A modification of inferior oblique weakening is anterior transposition. This technique weakens the inferior oblique as much as myectomy or 8.0 mm recession. In addition, it seems to tether the eye and reduce the hyperdeviation or sursumduction in patients with DVD. Anterior transposition of the inferior oblique is indicated in cases of DVD with overaction of the inferior oblique and 'V' pattern. This procedure should only be done bilaterally. If done in one eye, a restrictive hypotropia in upgaze is produced causing a secondary deviation.

Inferior oblique strengthening:

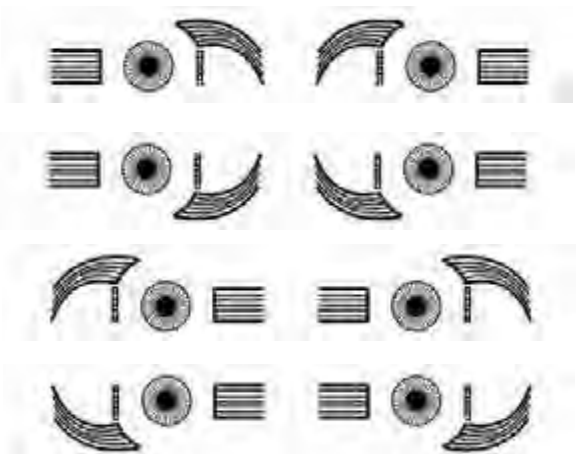
Strengthening procedures of the inferior oblique, in my experience, are seldom effective for treating vertical misalignment; therefore, no figures can be given for expected correction. If a tuck is performed, no less than 10 mm of the muscle should be included. If resection and advancement are undertaken, approximately 5 mm of the muscle should be resected and the muscle should be advanced 5 mm. I have done this once or twice in nearly 40 years. Recession of the yoke, contralateral superior rectus, is probably the most effective treatment for the rare case of inferior oblique palsy.

Surgery for vertically incomitant horizontal strabismus ('A' and 'V' patterns)

A more or less fixed amount of surgery is performed to treat vertical incomitance. This is accomplished by shifting the horizontal rectus insertions appropriately upward or downward or by weakening overacting oblique muscles.



Bilateral inferior oblique myectomy for treating a 'V' pattern produces on the average 20Δ less exotropia or more esotropia in upgaze. Bilateral superior oblique tenotomy for treating an A pattern produces from 7Δ to 70Δ less exodeviation or more esodeviation in downgaze. The average change of alignment in downgaze after bilateral superior oblique tenotomy is approximately 30Δ . With a fixed amount of either inferior or superior oblique weakening, more effect is produced in large A or V patterns and less effect in small 'A' or 'V' patterns. This effect represents a type of built-in safety factor for this surgery. Bilateral superior oblique weakening procedures produce approximately 6Δ of eso shift in the primary position. Bilateral inferior oblique weakening procedures produce little, if any, horizontal change in the primary position.



The horizontal rectus muscles may be shifted one-half to one muscle width upward or downward. This produces 10Δ to 15Δ , or more change in larger patterns of 'A' or 'V.' The medial rectus muscles are always moved in the direction of the apex of the 'A' or 'V' and the lateral rectus muscles are always moved toward the open end of the 'A' or 'V'. Vertical shift of the horizontal rectus muscles may be accomplished with symmetric surgery (bilateral recession or

resections) or when a recession-resection is performed. The horizontal rectus muscles also may be moved vertically without recession or resection in cases of 'A' or 'V' pattern without oblique dysfunction and when no horizontal deviation is present in the primary position.

Horizontal shift of the vertical rectus muscles can be done for treatment of 'A' and 'V' patterns. To decrease an esodeviation, the vertical recti are shifted temporally and to decrease an exodeviation, the vertical recti are shifted nasally. For example, temporal shift of the inferior rectus muscles can be done in 'V' pattern esotropia in patients without a deviation in the primary position and without oblique muscle dysfunction. The best use of this information is when recessing the inferior rectus in thyroid disease. Nasal shift of these muscles is done to avoid the postoperative unwanted 'A' pattern.

The faden operation (posterior fixation suture)

The so-called faden operation should be called posterior fixation suture or retroequatorial myopexy. This procedure has become a regular part of the surgical armamentarium for many strabismus surgeons. It was performed initially for treating the nystagmus blockage syndrome as suggested by Cüppers. Peters described essentially the same procedure earlier, but it did not catch on. Expanded use of the posterior fixation suture includes any condition in which a secondary deviation will promote comitance. This procedure weakens a muscle in its field of action but has little effect, at least theoretically, on the primary position deviation or the action of the antagonist of the operated muscle. In cases of esotropia with nystagmus blockage, the posterior fixation suture is performed alone or is combined with appropriate recession of the medial rectus muscles. Results of this surgery are good, according to some, but when this procedure is combined with a recession it is difficult to know which part of the procedure affects the deviation.

Adjustable suture

I use an adjustable suture, when indicated, on any of the rectus muscles and have attempted it without success in a few cases involving the superior oblique tendon. Indications for use of an adjustable suture are (1) restrictive strabismus in a patient with fusion potential (the patient with thyroid ophthalmopathy may be the prime example of such a patient); (2) any strabismus in which the outcome of surgery cannot be readily predicted (including patients who had previous unsuccessful surgery); and (3) when this technique is expected to produce better results according to the surgeon's experience.

While patients with mechanical restriction and fusion potential are prime candidates for an adjustable suture, fusion potential and diplopia are not absolute requirements. Cases not suitable for an adjustable suture are congenital esotropia, intermittent exotropia (some may disagree), dissociated vertical deviation, any inferior oblique surgery, and surgery for convergence insufficiency, etc.

An adjustable medial rectus recession may be combined with a muscle transfer procedure for treatment of sixth nerve palsy. Some patients may be adjusted at surgery 'on the table' when local anesthetic is used, in the recovery room, or in the clinic on the day following surgery. I have heard one very experienced surgeon describe adjustment done more than a week later! The alignment after adjustment may remain stable or the alignment may shift over time postoperatively, but this can occur with any type of strabismus surgery.

Adjustable sutures are useful, but they are only a small part of my surgical scheme. Some fine strabismus surgeons use an adjustable suture in nearly every case of rectus muscle surgery. Other surgeons never use an adjustable suture! Take your choice. When used, I prefer the tandem adjustable suture (see page 259).

Extraocular muscle transfer

Extraocular muscle transfer procedures are indicated in complete or near-complete paralysis of a rectus muscle. Passive ductions must be free before the transfer is done if optimal results are expected. The usual procedure in muscle transfer is to shift the insertion of the two antagonist rectus muscles to a point at or near the insertion of the paretic rectus muscle lying between them. The shift can be carried out in some fashion to make up for a paretic medial rectus, superior rectus, inferior rectus, or lateral rectus muscle. Superior oblique tendon transfer is more difficult to perform and frequently less effective. It is usually done to reduce the exodeviation in third nerve palsy. Botox, injection of the antagonist of the paretic muscle can be done in conjunction with a full tendon transfer. Although rare, anterior segment ischemia can occur when three rectus muscles are detached. Therefore, we like to avoid removing any extra rectus muscles; Botox can help with this.

Botox injection

Botox injection remains a viable option for several categories of strabismus. We use it for some cases of thyroid ophthalmopathy, persistent, residual, or secondary strabismus, some small-angle deviations, and in cases where the patient does not wish to have further incisional surgery. We do not use Botox for congenital-infantile esotropia or intermittent exotropia. Alan Scott has suggested that Botox will

be useful for about 15% of strabismus patients. I use it in 3% of cases. A few surgeons use Botox for treatment of congenital esotropia and claim good results. John Lee of Moorfields in London has more experience than anyone I know of when it comes to use of Botox for strabismus and he employs it successfully in a wide variety of cases. Emilio Campos has reported good results after treatment of congenital esotropia with Botox, but this method of treatment is not used widely.

Summary of steps 1 & 2 in the design of strabismus surgery

When an accurate workup has been completed and a pertinent history recorded, the surgeon should possess sufficient knowledge of the patient and the strabismus problem to have certain treatment goals in mind. In addition, the surgeon should also have realistic expectations of the results that could be expected from surgery. That is, the surgeon should know approximately how much change in ocular alignment is expected with muscle strengthening, weakening, or transfer procedures appropriate for the patient's strabismus. It is the union of these two factors, 1) patient findings and 2) results to be expected from surgery, that enables the surgeon to design each surgical procedure specifically for each patient. This combination of clinical findings and results expected is made more sensitive by the application of certain rules that help the surgeon predict how certain types of patients may respond to strabismus surgery and how selected variables could affect the outcome.

It should be re-emphasized here that orthoptic, optical, and to a lesser degree, pharmacologic therapy can be an alternative and in selected cases a better option than surgical therapy for strabismus in selected patients provided these nonsurgical methods result in comfortable fusion and the accompanying acceptable appearance. Surgery to restore ocular alignment or to enable enhanced binocularity including fusion should be reserved for patients who cannot be helped by other nonsurgical means alone.

Step 3: Guidelines for application of surgical options

The third component in the design of the surgical procedure joins Step 1 (the workup) and Step 2 (surgical options). The following aphorisms may be applied to help produce a successful union between the patient and his or her surgical plan:

1. If fusion is now or has ever been present, a cure with fusion may be expected. A slight overcorrection may help obtain this result.
2. If no fusion potential is present, a slight undercorrection is more likely to produce a stable, small angle residual deviation.

3. The surgeon should aim at a cure with first surgery, provided there are sufficient muscles to operate on without causing complications such as anterior segment ischemia.
4. Because no procedure is ever 100% successful, patients (parents) should be given a reasonable estimate of the likelihood that a second procedure will be required.
5. The surgeon should strive toward judicious boldness and not be excessively fearful of producing an overcorrection.
6. If the surgeon is doing the proper amount of surgery, he or she should expect some overcorrections and should not produce an excessive number of undercorrections with regard to intended results. For example, if a surgeon aims at a 5Δ undercorrection, a patient who is ortho in the early postoperative period represents a relative overcorrection.
7. More effect is produced per millimeter of recession or resection by strabismus surgery in a child or in a patient with a small eye; less effect is produced by strabismus surgery in an adult or in a patient with a large eye.
8. More effect is gained from strabismus surgery on a recent deviation than on a long-standing deviation.
9. Surgery for a small deviation ($\pm 25\Delta$) produces less effect per millimeter of surgery than that for a large deviation ($\pm 50\Delta$).
10. In patients with cerebral palsy and strabismus, the more cephalad the neurologic involvement, the longer surgery should be delayed. Patients with only limb involvement in which the cranial nerves are spared may be treated as otherwise normal strabismic children.
11. In partially accommodative esotropia, only the nonaccommodative part of the deviation should be treated surgically.
12. One 4 mm medial rectus recession corrects approximately 13Δ of esotropia.
13. Conjunctival recession is performed when conjunctival scarring causes restricted movement or unsightly appearance.
14. A minimal recession-resection for either esotropia or exotropia produces approximately 25Δ reduction in the esodeviation or exodeviation.
15. A maximum recession-resection procedure for either esotropia or exotropia produces approximately 50Δ reduction in the esodeviation or exodeviation.
16. Three muscle surgery for esotropia or exotropia may be required for deviations between 50Δ and 75Δ .
17. Four muscle surgery for either esotropia or

- exotropia may be required for deviations greater than 75Δ but rarely is performed in children.
18. Esodeviations or exodeviations greater than 50Δ in a patient with very poor vision in one eye should be treated with a supermaximal recession-resection of one eye to avoid surgery on the better eye.
 19. Surgery for esotropia in a hyperkinetic child produces less effect than the same amount of surgery in a placid child.
 20. Residual esotropia after a bimedral rectus recession that had been performed several years before may be treated with re-recession or a marginal myotomy of one previously recessed medial rectus and a resection of one lateral rectus if the deviation is $\pm 25\Delta$. This procedure should be bilateral if the deviation is $\pm 50\Delta$. For deviations between 30Δ and 50Δ , a resection of the lateral rectus alone may be performed in the second eye.
 21. Residual esotropia occurring weeks to months after a bimedral rectus recession should be treated with a bilateral lateral rectus resection or a re-recession of the already recessed medial rectus muscles.
 22. A double 80% marginal myotomy combined with a resection of the antagonist produces the same weakening effect as a maximum recession of that muscle. A marginal myotomy without resection of the antagonist is a less effective procedure.
 23. Secondary exotropia after medial rectus recession that demonstrates deficient adduction can be treated with medial rectus resection and advancement.
 24. A bilateral lateral rectus recession is performed for exotropia less than 40Δ that is greater at distance with excess abduction and equal vision.
 25. Exotropic patients who have lateral incomitance - that is, who have less exodeviation in lateral versions - tend to be overcorrected more easily than patients whose exodeviation is the same in the primary position as in lateral versions.
 26. Exotropic patients who have had extensive preoperative orthoptics, especially near point of convergence exercises, are prone to large overcorrections after surgery.
 27. The choice of muscles to be operated in the surgical treatment of intermittent exotropia is indicated by the pattern of deviation. Divergence excess exotropia is treated with bilateral lateral rectus recession; basic exotropia and simulated divergence excess exotropia are treated with a recession of the lateral rectus and a resection of the medial rectus or with bilateral lateral rectus recession. Convergence insufficiency is treated with bimedral rectus recession or recession-resection, in one eye.
 28. The timing of surgery for intermittent exotropia is dictated by how often the deviation is manifested rather than the deviation measurement.
 29. Once surgery has been decided on for a patient with intermittent exotropia, the amount of surgery is dictated solely by the angle of the deviation and is in no way influenced by the amount of time deviation is either latent or manifest.
 30. Bilateral inferior oblique myectomy produces 20Δ less exotropia or more esotropia in upgaze with no significant change of the alignment in the primary position or in downgaze.
 31. Unequal bilateral overaction of the inferior obliques causing a V pattern should be treated with an equal weakening procedure on the inferior obliques. If only the more overacting inferior oblique is weakened, a markedly unequal overaction of the obliques with the non-operated muscle becoming much more overactive may occur postoperatively.
 32. Bilateral superior oblique tenotomy produces a decrease in exotropia in downgaze between 7Δ and 70Δ . The average change is 30Δ . The smaller the 'A', the less the change in downgaze; the more the 'A', the greater the change in downgaze.
 33. Vertical shift of the horizontal rectus muscles for 'A' and 'V' patterns is accomplished as follows: the medial rectus muscles are shifted toward the apex of the 'A' or 'V'; e.g. up in 'A' pattern and down in 'V' pattern. Lateral rectus muscles are moved toward the open end of the pattern; e.g. downward in 'A' pattern and upward in 'V' pattern. Vertical shift of the horizontal rectus muscles (one-half to one muscle width) produces approximately 10Δ to 15Δ change in the 'A' and 'V' pattern. The greater the vertical incomitance, the more the effect.
 34. Horizontal shift of the vertical recti for treatment of 'A' and 'V' is done by shifting the muscles temporally to treat esodeviation and nasally to treat exodeviation.
 35. Acquired non-traumatic, small angle superior oblique palsy in an older patient should be evaluated according to the patient's needs. This can be treated with prisms or patching for 4 to 6 months, and, if necessary, can be treated surgically. A medical workup should be done.
 36. Bilateral superior oblique palsy frequently

- causes cyclotropia and cyclodiplopia that is measured at 15 degrees or greater with the double Maddox rod test. These patients typically have a chin down, eyes up head posture to obtain fusion or wear an eye patch.
37. When a large horizontal deviation and a small vertical deviation exist in a patient with no fusion potential only the horizontal deviation is treated surgically.
 38. A small vertical deviation in a patient with diplopia and fusion potential may be treated with surgery and/or prisms.
 39. An unacceptable vertical deviation with or without fusion potential is treated surgically by operating on the appropriate vertically acting muscles. The vertical rectus muscles have more effect on the primary position deviation than do the obliques.
 40. Brown's superior oblique tendon sheath syndrome is treated surgically only if a cosmetically unacceptable vertical strabismus or abnormal head position is present while the patient is fixing in the primary position.
 41. Lysis of adhesions around an extraocular muscle is usually ineffective unless it is accompanied by one or more of the following procedures: conjunctival recession, traction suture placement, marginal myotomy, re-recession, or re-resection.
 42. Replacing tight or scarred conjunctiva to its preoperative position can nullify the results of otherwise potentially successful strabismus surgery.
 43. When there is a doubt about whether restricted motility could be caused by scarred conjunctiva, a conjunctival recession should be performed, leaving bare sclera.
 44. Long-term traction sutures should be anchored securely in the sclera or placed in the horizontal rectus insertions to avoid unnecessary contact with the cornea. They should be tied over a bolster and left in place for several days and watched carefully with the eye fixed in the duction opposite the restriction several degrees past the midline.
 45. The functional improvement of straight eyes after surgery is compromised when red, unsightly scars remain in the conjunctiva. One should always attempt to retain a normal, white conjunctiva postoperatively. If this cannot be accomplished otherwise, conjunctival recession and/or excision should be performed.
 46. Manifest DVD may be treated surgically by recessing one or both superior rectus muscles and if the DVD persists resection of one or both inferior recti should be done.
 47. DVD with overaction of the inferior obliques and 'V' pattern is effectively treated with bilateral anterior transposition of the inferior obliques.
 48. Congenital superior oblique palsy frequently demonstrates no torsional response when testing with the double Maddox rod test. In addition, spontaneous torsional diplopia is not observed. Acquired superior oblique palsy that is unilateral usually demonstrates torsion with the double Maddox rod test but does not produce spontaneous torsional diplopia. The torsion measured in unilateral superior oblique palsy is less than 15°. Both congenital and acquired superior oblique palsy are frequently associated with an abnormal head posture. Bilateral superior oblique palsy causes torsional diplopia and torsion greater than 15 degrees with the double Maddox rod test. When greater than 15 degrees of torsional diplopia is found, the diagnosis is bilateral superior oblique palsy unless ruled otherwise. In addition, a spontaneous complaint of torsional diplopia is bilateral superior oblique palsy unless ruled out.
 49. The superior oblique muscle is the most commonly occurring anomalous extraocular muscle. If superior oblique palsy that is congenital is also associated with amblyopia, horizontal strabismus, anomalous structure or even absence of the superior oblique tendon should be suspected.
 50. Superior oblique palsy with facial asymmetry is likely to be congenital and to have an anomalous tendon. The 'larger' face is always on the side of the paretic superior oblique. The 'smaller' side of the face may be characterized by a smaller distance between the lateral canthus and the corner of the mouth.
 51. Superior rectus recession has virtually no effect on the palpebral fissure; superior rectus resection is likely to narrow the fissure.
 52. Inferior rectus recession can significantly widen the palpebral fissure and inferior rectus resection can narrow the palpebral fissure.
 53. Inferior rectus recession is commonly associated with slippage leading to excessive recession, especially in thyroid eye disease.
- Each surgeon should add his or her own personal guidelines for strabismus surgery to this list and should delete from this list those aphorisms that do not apply to his or her experience.

Step 4: Surgical technique

For successful strabismus surgery, the surgeon should adhere to the following guidelines:

1. Know the anatomy of all of the extraocular muscles and the surrounding fascial planes.
2. Carry out sharp dissection carefully. Avoid blunt dissection.
3. Respect the conjunctiva, paying special attention medially to the proper position of the caruncle and the plica semilunaris.
4. Observe strict hemostasis.
5. Keep tissue moist, but not 'flooded', with a physiologic salt solution.
6. Use appropriate magnification and proper illumination assists with visualization.

Step 5: Follow-up of the surgical patient

During the postoperative follow-up, the surgeon should:

1. Follow the patient postoperatively according to a regular scheme and according to each patient's unique needs. For example, my routine for congenital esotropia is to see children 1 week and 8 weeks postoperatively and then as needed with at least two additional visits in the first year after surgery. Additional examinations are scheduled as needed.
2. Answer promptly (or have a physician familiar with the case) any call about a patient during the first week to 10 days after eye muscle surgery, as if you suspected an infection. Be sure that office personnel are familiar with this policy.
3. Watch for amblyopia. Check visual acuity by the best means possible at each postoperative visit. Institute amblyopia therapy promptly, if needed.
4. Use prisms as needed, employing either Fresnel or permanent prism.
5. Use glasses or miotics as needed.
6. Do not procrastinate if reoperation is indicated.

Treatment of amblyopia

The use of occlusion for treatment of amblyopia in infancy before surgical treatment of congenital esotropia can be quick and effective. After a few days or weeks of occlusion, amblyopia can be eliminated in favorable cases and alternate fixation achieved. On the other hand, improperly applied, overzealous occlusion can produce amblyopia in the formerly preferred eye of the very young child. von Noorden suggests an occlusion ratio of 2, 3, or 4 days of occlusion for the sound eye and one day occlusion for the amblyopic eye with the caveat that one eye is occluded at all times. In addition to reducing the likelihood

of occlusion amblyopia, this program which occludes one eye at all times maintains a positive environment for development of best acuity by eliminating any need for suppression. Occlusion for treatment of amblyopia is an important immediate antecedent of surgical therapy. Surgery is performed in most cases after free alternation has been established.

Another scheme for amblyopia treatment is occlusion of the sound eye during all of the waking hours combined with daily observation of the fixation pattern by the parents. Parents are instructed to begin alternate patching if they observe free alternation and to continue this regimen until surgery. The important points to remember are that occlusion amblyopia can be produced quite rapidly in the infant and that suppression does not occur if one eye is occluded. When patching is restricted to the preferred eye, careful observation of the amblyopic infant should be maintained and alternate patching started when the child alternates fixation. This is continued until surgery is performed. Some prefer alternate day patching even in alternating strabismus to avoid anomalous binocular relationships. According to this theory, it is better to perform surgery with a more or less 'clean slate.' This scheme has no beneficial effect on motor response. A positive effect on sensory results has yet to be proven. Amblyopia treatment in the older child is not so intimately related to timing and techniques of surgery.

In recent national collaborative studies carried out by the Pediatric Eye Disease Investigator Group (PEDIG), shorter periods of occlusion and as an alternative treatment atropine penalization have been shown to be as effective as prescribed full-time occlusion. From these results it can be inferred that patching prescribed as full time is often carried out less rigorously than patients report. This has been corroborated by electronic patch time monitoring. These PEDIG studies compared 'line of improvement,' but did not require free alternation as the end point.

Refraction

Refraction is carried out in infants under 1 year of age, 20 to 40 minutes after instillation of one or two drops of 0.5% cyclopentolate hydrochloride (Cyclogyl) in each eye. After 1 year of age, 1% Cyclogyl is used. In heavily pigmented children, 1% atropine solution is used by parents at home beginning 3 days before the examination with a total of four drops being instilled in each eye. These parents are always warned of the signs of atropine systemic effects of flushing, fever, and hyperactive behavior. To avoid these problems, parents should use only one drop in each eye and should occlude the puncta for 30 seconds after the drops are given to avoid the child's

swallowing the medicine and experiencing systemic effect. It is also a good idea to put a drop in one eye in the morning and in the second eye in the afternoon to further reduce the chance of an unwanted systemic effect. If it would be difficult for a patient to return for a second visit for an atropine refraction, we add phenylephrine HCL 2.5% drops and repeat the Cyclogyl one or two times at 5- and 15- to 20-minute intervals, respectively. However, we are satisfied that Cyclogyl is adequate to determine refractive errors in most infants and children. We do not use 2% Cyclogyl because of concern about dose-related toxicity.

Spectacle prescription

Treatment of hyperopia with spectacles in the esotropic infant can identify refractive esotropia in a child as young as 6 months. Spectacles should be prescribed for all esotropic infants and children with greater than +3.00 refractive error. In some cases, +3.00 glasses or even plus correction of lesser strength is given if it is expected to reduce esotropia. Because this prescription is often not effective and the child will need surgery anyway and may not wear glasses afterward, a loaner glasses program can be instituted. Anticholinesterase drops in lieu of glasses can be used in these children. This medication can be used in patients with residual esotropia, particularly if a slight reduction in the angle will straighten the eyes sufficiently to produce improved binocular function.

A more difficult problem is the case of a young child with straight eyes but high hyperopia. For example, we occasionally see a child of 2 or 3 years of age with +4.00 hyperopia or greater and straight eyes. No definitive treatment regimen is appropriate in all cases, but some guidelines can be established: (1) if any esodeviation latent or intermittent is detected, glasses should be given or at least considered; (2) if glasses are considered but not given, the parents should be instructed to watch for and report any esotropia and an early follow-up appointment should be given; (3) if visual acuity is reduced in both eyes or if in the case of high hyperopia bilateral ametropic amblyopia is suspected, glasses should be given; (4) the higher the hyperopia, the greater the need for

glasses; and (5) patients with high or relatively high hyperopic refractive error will eventually require glasses.

Timing of surgical treatment

After deciding at what age the infant suspected of having strabismus is first seen and how amblyopia and refractive errors are to be managed, the timing of surgery must be considered. Unless one avoids seeing children early and/or opposes early surgery on theoretical grounds, any delay between completion of nonsurgical treatment (treatment of amblyopia and correction of hyperopia) and surgically straightening the eyes must be defended. More surgeons are now proceeding to early surgery for congenital esotropia. Surgical straightening of the eyes is done as soon as amblyopia has been treated and the refractive-accommodative component has been ruled out as the cause of the esodeviation, in any patient aged six months and older. Some surgeons, myself included, even consider four months an appropriate age for surgery to treat congenital esotropia.

A factor contributing to my enthusiasm for early surgery is the availability of competent pediatric anesthesia. Safe pediatric anesthesia includes positive airway control, use of agents that have a wide margin of safety, and constant monitoring of heart rate, oximetry, blood pressure, respiration, temperature, and expired CO₂. In addition, a continuous intravenous drip ensures required hydration for the preoperatively starved child. Even more important, the indwelling intravenous catheter drip allows a quick and reliable route for the emergency administration of medication. In the case of older children and adults, the timing of surgery depends for the most part on the wishes of the patient. When sufficient measurements have been obtained and the deviation has stabilized (as in acute cranial nerve palsy), surgery is offered to the patient and is scheduled at the most convenient time.

In adults and in cases of acquired strabismus, surgery is done when nonsurgical methods have accomplished all that they can, the patient's health permits, and when the patient wishes.

5

Diagnostic categories and classifications of strabismus

This chapter offers a comprehensive classification of strabismus and then provides a detailed description of the more common strabismus types including treatment options. My premise for what could be an unorthodox way to classify strabismus is that there are only *two* kinds of strabismus. These are congenital esotropia and its sequelae and *all the rest!* These two classes of strabismus are divided according to the presence or absence of an inborn motor fusion mechanism (Figure 1).

Claud Worth said that congenital esotropia results from a defect in the ‘fusion faculty.’ Whether this so-called fusion faculty refers to sensory fusion or motor fusion is not agreed upon by experts.

Sensory fusion is the simultaneous perception of slightly different images from the two eyes blending them into a single object. This object is seen in depth. Motor fusion is the alignment of the visual axes by action of the muscles so that an object is seen as one rather than doubled. This image seen as one by virtue of motor fusion may be seen ‘in depth’ as a result of sensory fusion or may not, at least with clinical tests such as the Polaroid vectograph test used in the clinical setting.

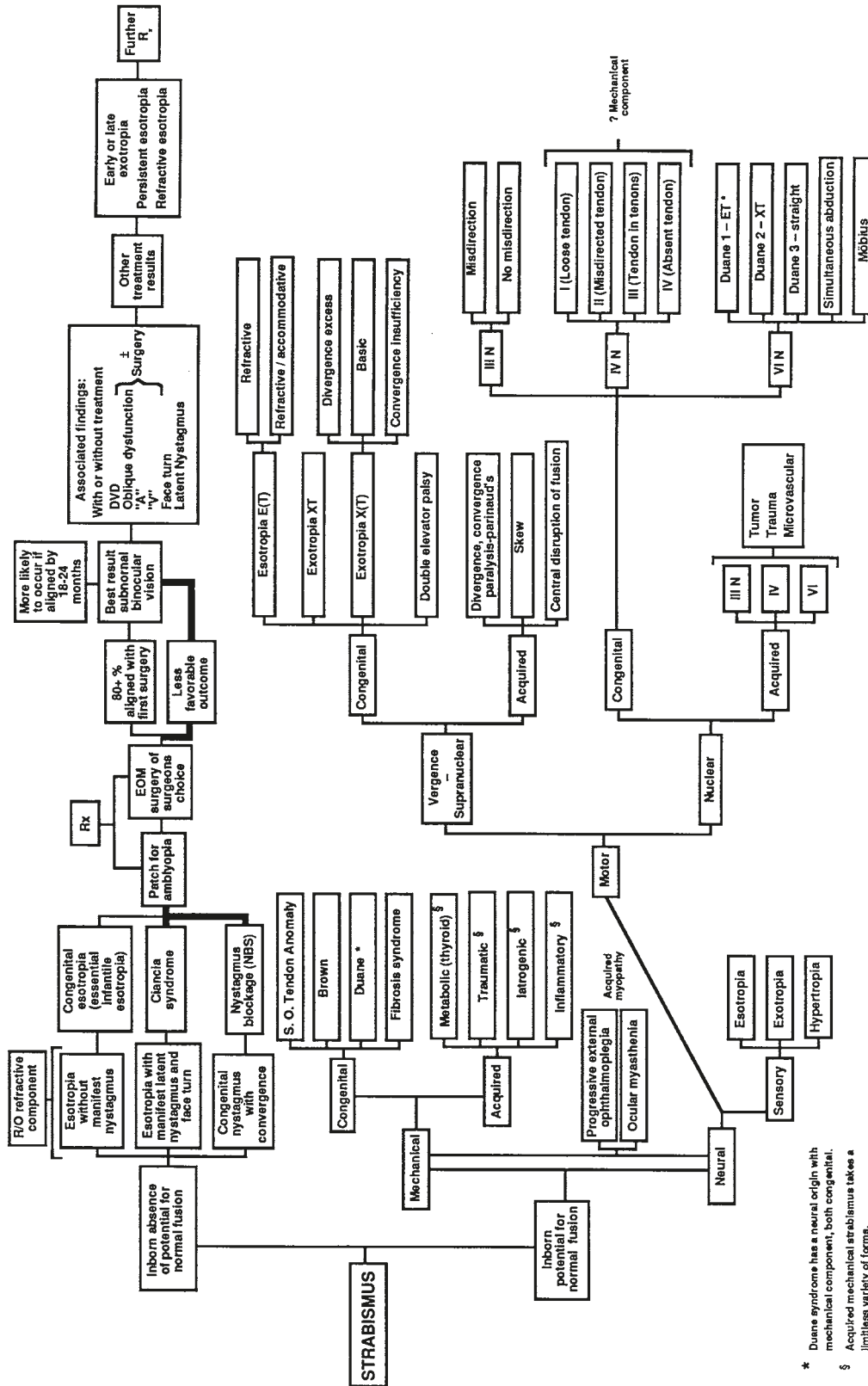
‘All the rest’ of the strabismus entities consist of those who have strabismus, but were born with, or presumably born with the potential for bifoveal fusion. In this category of strabismus, fusion is lost from a variety of causes other than a primary inborn deficiency in the central motor fusion mechanism. The individuals in the strabismus category, ‘all the rest,’ can be said to have either had the potential for fusion, but it was lost never to be regained; demonstrate fusion only part of the time; or appreciate fusion full time, or nearly so, by assuming a compen-

satory head posture. For example, those with congenital third nerve palsy, in most cases, never had normal fusion, but there is no reason to believe this is why the strabismus is present. On the contrary, motor fusion never developed or was ‘lost’ because the eyes were constantly misaligned because of the cranial nerve palsy. Individuals with intermittent exotropia have excellent fusion interspersed with periods of deep suppression. Patients with Brown syndrome or Duane syndrome can have a severe motor dysfunction that the patient responds to by assuming an anomalous head posture, allowing normal binocular vision - fusion. The reason for including in ‘all the rest’ acquired strabismus such as cranial nerve palsy, refractive esotropia, and mechanical causes such as blowout fracture, etc, is obvious.

This more or less arbitrary method of dividing strabismus has some value in that it helps predict outcome while guiding treatment. For example, congenital esotropia patients are not expected to have normal fusion, regardless of timing and type of treatment, and are subject to a variety of other strabismus conditions, most notable of which is dissociated strabismus.* In contrast, in the ‘all the rest’ category many other types of strabismus, depending on severity and duration, retain the potential for normal or a near normal sensory result after timely and effective treatment.

Later in Chapter 15 and 16, a wide variety of examples of strabismus will be presented describing clinical characteristics, treatment and results. These will include the more or less naturally occurring types as well as strabismus from trauma and after prior surgical treatment.

* Those cases of congenital esotropia who are said to have normal fusion do not, in my opinion, have *by definition* congenital esotropia.



* Duane syndrome has a neural origin with mechanical component, both congenital.
 § Acquired mechanical strabismus takes a limitless variety of forms.

Figure 1 A comprehensive classification of strabismus

Congenital esotropia

The most common form of strabismus is an esodeviation with onset during infancy occurring in an otherwise neurologically normal infant. It is labeled *congenital*, *infantile*, or *essential infantile esotropia*. These patients can have other physical signs including face turn and nystagmus. Although the clinical characteristics of this strabismus entity have been thoroughly described, many questions remain about: timing of onset, etiology, terminology, and treatment outcome. This is understandable because, for the most part, the earliest stages of this strabismus have been recorded mostly by parents or pediatricians. These esotropic infants had not been subjected to careful study in large numbers in the past by the ophthalmologist or the basic scientist studying infant psychophysics.

Now this is changing. The issues surrounding the causes and early findings in congenital esotropia are being discussed in a new light. The competing ideas that congenital esotropia is a *primary* defect of the fusion faculty (Worth) or that this condition develops as the otherwise normal binocular system is 'overcome' by esotropical factors causing a *secondary* esotropia (Chavasse) are being subjected to scrutiny in the laboratory and the clinic.

Whether the so-called fusion faculty of Worth is related to sensory fusion or motor fusion has never been clearly stated, but careful reading of Worth indicates, at least to me, that he was referring to *motor* fusion. This suggests that adequate treatment of congenital esotropia in the form of surgical realignment of the eye can improve alignment leading to excellent appearance and peripheral fusion or subnormal binocular vision but treatment cannot achieve normal motor or what depends on normal motor fusion, normal sensory function.

The theory of Chavasse suggesting that a timely reversal of esotropical factors could result in normal fusion although not in my opinion correct, was the impetus for earlier surgery for congenital esotropia. This was championed by Frank Costenbader and later Marshall Parks. Their efforts supported by improved surgical anesthesia, finer suture, sharper-finer needles, better instruments, and effective magnification, and carried on by a cadre of well-trained young strabismologists has resulted in many ophthalmologists treating congenital esotropia successfully with surgery at 6 months and even younger. Some have even claimed near perfect motor and sensory results in a few cases. These cases notwithstanding, the best results from treatment of congenital esotropia seems to be 'better but not perfect' and then only with close postoperative follow up and appropriate intervention.

The terms *congenital* and *infantile* have been vigorously debated mostly because of uncertainty

about the time of onset. The term *essential* has been added to make it clear that we do not know the cause of this esodeviation. A paucity of information about ocular motility in the normal newborn as well as in the newborn and infant with early onset esodeviation left strabismologists with several descriptive terms, but little understanding of mechanisms.

In the past ten years, new information has accrued from study of ocular motility in the normal newborn. In addition, a national collaborative study of the clinical behavior of esotropic infants beginning at just a few weeks of life has determined that the diagnosis of congenital esotropia can be made with confidence at 4 months. This study also suggests to me that surgery can be done as early as four months of age to treat a constant esodeviation. Supported by this type of information, surgery is now being done on infants as young as four months and in some cases, younger. Data generated from this experience has also provided information about the best treatment results that can be obtained. Now based on my own clinical experience and on interpretation of available clinical and laboratory data, I will present my view of the broad clinical picture or what I will call *congenital esotropia*.

Terminology

The term 'congenital esotropia' was popularized by Costenbader. However, the word 'congenital' has been challenged because this condition is not confirmed at birth, except, in some cases, by parents. In other words, the esotropia is not conatal, at least as confirmed by expert observation. To counter this objection it could be pointed out that other conditions termed congenital are not necessarily conatal. For example, so-called congenital subluxation of the hip is not manifest in most cases until several months after birth. However, it is arguable to label something as congenital if the hidden *precursor* of a later manifesting condition is said to be present at birth. This may be the case with 'congenital' esotropia. As an alternative, the term 'infantile esotropia' has been used because it more accurately describes the time of onset of the esodeviation, that is, during infancy, begging the question "When did the underlying cause originate?" Discouraging use of 'infantile esotropia,' Lang and Parks defend the term 'congenital esotropia.' Parks stressed that it is an established term describing an entity whose clinical characteristics and response to treatment are well known to all strabismologists.

Supporting use of the term 'infantile esotropia,' von Noorden said, "I prefer...infantile esotropia to describe a constant deviation with a documented onset during the first six months of life and add the prefix 'essential' to emphasize the unknown origin

and to distinguish it from other forms of esotropia that occur at birth or during infancy.” While I could defend the term ‘infantile esotropia,’ I am convinced that affected infants have an *inborn* defect in motor fusion.

Is this controversy regarding terminology important?

The crux of the argument regarding the validity of the terms ‘congenital’ versus ‘infantile’ may depend on when the *initial defect* leading to the strabismus occurs, rather than the timing of the manifest esotropia itself. The question is: “Does the infant who ultimately is diagnosed as ‘congenital’ or ‘essential infantile’ or simply ‘infantile’ esotropia start life with the potential for normal binocular vision and lose it because of acquired motor induced factors, or does the infant begin life with an inborn lack of normal binocularity because of a central defect that eventually causes an esodeviation by a failure to provide a ‘template’ in the central nervous system on which the normal binocular motor fusion develops?” This may be nothing more than a restatement of the arguments surrounding the Worth (fusion faculty) versus Chavasse (motor reflexogenic) theories for the origins of infantile esotropia.

Whether the esodeviation is called congenital or infantile may be considered unimportant provided the etiology remains unknown. On the other hand, the design of more effective treatment may depend on better understanding of etiology. von Noorden stated, “If etiology is implied, terminology is important,” and I tend to agree. Hereafter in this section, using von Noorden’s argument but coming to a different conclusion, I will use the term ‘congenital esotropia.’

Characteristics

According to results from the Pediatric Eye Disease Investigator Group (PEDIG), congenital (infantile) esotropia can be confirmed by a *reliable* observer by 4 months of age. The minimum required findings for diagnosis are as follows:*

1. Esotropia—usually 40 to 50 diopters, but with a range of 10 to 90 prism diopters.
2. Normal neurologic status (except for strabismus)
3. Refractive error expected for age (usually low to moderate hyperopia), correction of which does not eliminate esotropia.
4. Asymmetric optokinetic nystagmus characterized by robust temporal to nasal response and erratic nasal to temporal response.

In addition, it must be noted that the infant has either alternation, often with cross fixation or fixation preference for one eye, implying amblyopia. Other common clinical findings often present but not essential to the diagnosis are: manifest nystagmus, oblique muscle dysfunction, dissociated strabismus either vertical deviation (DVD) or a horizontal deviation, primarily an exodeviation of one eye (DHD), variable angle, latent nystagmus, manifest latent nystagmus, and torticollis.

All patients with congenital esotropia have compromised sensory functioning because the object of regard is seen by the fovea of one eye and nasal retina of the other eye. Stated another way, anatomically corresponding parts of the visual system will always be ‘seeing’ something different. This is the basis for development of anomalous retinal correspondence, which in my opinion is *always* harmonious (equal to the objective angle of strabismus) if tested with a minimally dissociating stimulus. Non-harmonious anomalous retinal correspondence, in my opinion, is a testing artifact, but this finding may have some use as a measure of the depth of adaptation.

Late sequelae of congenital esotropia with and without treatment include some or all of the following: secondary exotropia (large angle, late occurring), DVD, DHD, amblyopia, ‘overaction’ of the inferior obliques with V pattern, overaction of the superior obliques with A pattern, X pattern with the overaction of all obliques, and recurrent esodeviation with or without the influence of a refractive or accommodative component.† Individuals with congenital esotropia have asymmetric optokinetic nystagmus characterized by a normal nystagmus beat for nasally directed targets and an abnormal response to temporally directed targets both before and after treatment. Ciancia has also demonstrated a preponderance of response from crossing (nasal retinal) optic nerve fibers when comparing hemispheric visually evoked potential (VEP) response in congenital esotropia.

I have examined several patients with most of the typical characteristics of congenital esotropia, but with *no esotropia!* One patient was seen initially under a year of age with DVD but normally aligned eyes. She was followed until age 7 years at which time accurate sensory testing could be completed. This patient at this time had DVD, asymmetric OKN refractive esotropia and only gross stereo acuity. Another, a teenage boy, the sibling of a congenital esotropia patient, had DVD and OKN asymmetry, but his eyes were aligned and he demonstrated normal stereopsis! Patients with these characteristics have

* An infant with 40 prism diopters or more of constant esotropia at 4 months has a 100% chance of having esotropia at 7 months. If at 4 months the esotropia is less than 40 prism diopters or is intermittent, the likelihood of there being a constant esotropia at 7 months is 70%.

† It is unlikely that true overaction of the oblique muscles exists. Instead this could be ‘over expression’ because of a weak antagonist or deficient adduction allowing increased expression of the secondary abducting action of the oblique muscles.

been diagnosed as having ‘congenital esotropia sine (without) strabismus.’ This suggests that congenital esotropia exists on a continuum and is genetically influenced.

Treatment

While terminology and theories of origin may be debated, it is the nearly universal belief of strabismologists that surgery is the treatment of choice after refractive/accommodative components have either been ruled out or treated and after any amblyopia (if present) has been treated. Ideally these patients should alternate fixation before surgery, but surgery is often carried out before this is accomplished. Amblyopia therapy in such cases can be continued after surgery. The age chosen for surgery depends on the surgeon’s preference and varies from as early as 4 months to 3 years of age or more. The trend, however, is for surgery to be done at a younger age. Chemodenervation of both medial recti with Botox has been done, but has not achieved a prominent role. (see chapter 14).

Surgery for infantile esotropia consists of bimedial rectus recession, medial rectus resection, and lateral rectus resection of one eye, a three-muscle procedure combining a bimedial rectus recession with a resection of one lateral rectus or in a very few cases a four-muscle procedure consisting of a bilateral recession-resection. In cases with inferior oblique overaction and V pattern, both inferior oblique muscles may also be weakened at the initial surgical procedure. These patients often have lax superior oblique tendons that could be treated either with bilateral superior oblique tuck or bilateral inferior oblique weakening. Most cases of infantile esotropia, particularly those done at less than 1 year, have only horizontal rectus muscle surgery done at the initial procedure. Inferior oblique overaction may occur months to years after initial horizontal muscle surgery in which case inferior oblique weakening is done as a second procedure.

The best attainable result from treatment for congenital esotropia in my experience is subnormal binocular vision (Table 1). However, Kenneth W. Wright has reported a patient aligned at 2 months and 28 days who obtained alignment and stereo acuity of 40 seconds arc disparity. An acceptable but less desirable result is microtropia, and a still less desirable result is ‘small-angle’ eso- or exotropia. Large-angle eso- or exotropia, a still less desirable result, requires further surgery. We have found that 80%+ of patients treated surgically in our clinic for congenital esotropia have good initial results; that is, small-angle esotropia or exotropia of less than 10 prism diopters, microtropia, or subnormal binocular vision. With continuing treatment nearly 100% of congenital esotropia patients are aligned in the primary position by their teen years. von Noorden confirmed the ear-

Subnormal binocular vision*
Orthotropia or heterophoria Normal visual acuity in both eyes Fusional amplitudes Normal retinal correspondence Foveal suppression in one eye in binocular vision Reduced or absent stereopsis Stability of alignment Optimal treatment result for congenital esotropia
<small>*We have examined ‘normal’ parents of children with congenital esotropia and found that they have reduced stereo acuity indicating ‘subnormal binocular vision’.</small>
Microtropia†
Inconspicuous shift or no shift on cover test Mild amblyopia frequent Fixation central or parafoveolar in one eye Fusional amplitudes Anomalous retinal correspondence (if small shift on cover test) Reduced or absent stereopsis Fairly stable alignment No further treatment except amblyopia prevention Desirable treatment result
<small>† Microtropia with identity has harmonious anomalous correspondence between the eccentric fixation of the amblyopic eye and the fovea of the sound eye.</small>
Monofixation (Parks)
Esotropia (XT) < 10 prism diopters HARC‡ Alternation or amblyopia Fusional amplitudes Stable angle Good result
<small>‡According to Parks peripheral NRC.</small>
Small-angle esotropia/exotropia (<20 prism diopters)
Cosmetically acceptable? 80% have anomalous retinal correspondence§ Less stability of angle Further surgery based on appearance; amblyopia treatment as needed; may benefit from correction of hyperopia May be acceptable result
<small>§I believe that all strabismus patients have harmonious anomalous retinal correspondence if tested with tests which disassociate eyes less such as Bagolini glasses.</small>

Table 1 Results of treatment

Large-angle esotropia/exotropia (>20 prism diopters)

Usually cosmetically unacceptable
 Less chance for anomalous retinal correspondence, suppression prevails
 Unstable angle
 Unacceptable result
 Further surgery indicated

IHARC can be found.
 From von Noorden GK: A reassessment of infantile esotropia, XLIV Edward Jackson Memorial Lecture, Am J Ophthalmol 105:1-10, 1988

Table 1, cont'd Results of treatment

lier findings of Ing, Parks, and Costenbader that surgery done before 2 years of age produces better sensory results compared with surgery done between 2 and 4 years of age and surgery done after 4 years of age. In my experience, the best result from surgery for congenital esotropia falls short of *normal* binocular vision with perfect stereo acuity. That is, eyes may be aligned with equal vision but stereo vision is not normal. Anecdotal reports of infantile esotropia treatment resulting in normal stereopsis of 40 seconds of arc disparity beg the question, "Was this infantile esotropia?" I believe these patients could represent either early acquired esotropia in a child born with normal sensory potential or a 'rescue' of sensory function in an infant who could capitalize on being

given a second chance by having the eyes straightened early. Of the two, I believe the former alternative to be the most likely.

Results of early surgery for congenital esotropia

In an effort to learn more about the results that can be expected from early surgery for congenital esotropia we collected ten patients who underwent bimedial rectus recession between 83 and 159 days of age. The preoperative characteristics are shown (Table 2). These patients were examined initially between 55 and 150 days. They had an average deviation of 50 prism diopters with a range of 35 to 60 prism diopters. Most were noted by their parents to have crossed eyes at birth. The refractive error ranged from +1.00 to +3.00 diopters. Three patients demonstrated fixation preference suggesting the presence of amblyopia.

Initial surgery was bimedial rectus recession between 8.5 and 10.0 mm measured from the limbus. In each case the eyes were aligned in the immediate postoperative period (Table 3). These patients were followed, for a period of 8.3 years (the least) to 11.8 years (the longest). They were seen collectively a total of 221 times in follow up.

Only three of the ten patients remained aligned with a single surgery. The other 7 required a total of 11 additional surgical procedures. Three had just one additional surgery. Three needed two additional surgeries and one patient required three additional surgical procedures (Table 4).

Patient No.	ET First Noted	First Examination (days)	Deviation (prism diopters)	Refractive Error (diopters)*	Amblyopia
1	Birth	103	60	+2.00 +2.00	Yes
2	Birth	107	50	+1.00 +1.00	Yes
3	Birth	112	50	-2.00 -2.00	No
4	Birth	129	35	-1.50 -1.50	No
5	3 mos	152	60	-2.00 -2.25	No
6	Birth	91	60	-2.50 -2.50	No
7	6 wks	78	40	-2.50 -2.50	No
8	Birth	150	60	-3.00 -3.00	No
9	Birth	132	50	-3.25 -3.25	Yes
10	Birth	55	40	-2.25 -2.25	No

ET = esotropia.

* Spherical equivalent cycloplegic refraction.

Table 2 Preoperative Patient Characteristics

From Helveston EM, et al. Results of early alignment of congenital esotropia. Ophthalmology, 1999, 106(9):1716-1726. Used with permission.

Patient No.	Age at Surgery (days)	Deviation (PD)	BMR Recession (mm)*	Postoperative Tropia \leq 8 PD
1	123	60	8.5	Yes
2	124	50	8.5	Yes
3	143	50	10.0/9.0 [†]	Yes
4	137	35	8.0	Yes
5	159	60	10.0	Yes
6	120	60	9.5	Yes [‡]
7	114	40	9.5	Yes
8	153	60	10.0	Yes
9	140	50	10.0	Yes
10	111	40	8.5	Yes [§]

BMR = bilateral medial rectus; PD = prism diopters.

* Medial rectus recession measured from the limbus.

[†] Asymmetric insertions were found at the time of surgery; therefore, medial recti recessed unequally: 10.0 mm OD and 9.0 mm OS.

[‡] Loss of satisfactory alignment 6 months later.

[§] Loss of satisfactory alignment 7 months later.

Table 3 Initial Surgery

From Helveston EM, et al. Results of early alignment of congenital esotropia. *Ophthalmology*, 1999, 106(9):1716-1726. Used with permission.

Patient No.	Second Surgery		Third Surgery		Fourth Surgery	
	Surgery	Age (yrs)	Surgery	Age (yrs)	Surgery	Age (yrs)
1	LSR Recess	5.9				
2						
3						
4	BIO AT	3.8	LLR Recess	9.0		
5	BIO Myect	5.7				
6	BLR Resect	0.8	BIO AT	3.2		
7	BSR Recess					
	LLR Resect	2.2	LIO AT	3.7	RIO AT	4.2
8	BIO AT	2.9	BLR Resect	7.3		
9						
10	Re-Rec BMR	1.0				

L = left; R = right; B = bilateral; SR = superior rectus; LR = lateral rectus; MR = medial rectus; IO AT = inferior oblique anterior transposition; IO Myect = inferior oblique myectomy; Re-Rec = repeat/additional recession.

Table 4 Secondary Surgeries

From Helveston EM, et al. Results of early alignment of congenital esotropia. *Ophthalmology*, 1999, 106(9):1716-1726. Used with permission.

During the course of follow up, two patients required hyperopic correction to maintain alignment* and two patients required a short period of occlusion for amblyopia. At the end of the follow up period 19 of 20 eyes had visual acuity of 20/40 or better. All patients were aligned to within 10 prism diopters of orthotropia at distance, near, or both. Nine of 10 patients had dissociated vertical deviation and 4 had latent nystagmus. Four patients had measurable stereo acuity, two at 3,000 seconds (stereo fly), one at 400 seconds, and one at 140 seconds (Table 5).

All of the patients demonstrated optokinetic asymmetry which is characterized by smooth pursuit of stripes moving from temporal to nasal and jerky eye movement response to stripes moving from nasal

to temporal. This response seems to be a common denominator of congenital esotropia. That is, all congenital esotropia patients demonstrate this and conversely if a patient demonstrates asymmetric OKN response, he/she has congenital esotropia.

Looking at the results of surgical treatment for congenital esotropia reported by seven investigators, the following becomes clear: (Table 6)

1. Stereo acuity is attainable, but it is reduced.
2. Most patients require at least one additional surgery.
3. Dissociated vertical deviation occurs in most.

It has been suggested that early surgery in the patient with congenital esotropia might lead to a higher incidence of dissociated vertical deviation. To test

* Both had less than +3.00 refraction before surgery. The patient who was +3.00 before surgery was plano at the last visit.

Patient No.	Age at Initial Alignment (days)	Age at Last Examination (mos)	Deviation (prism diopters)		Amblyopia	Stereo (secs)*	Worth Four-dot		OKN Asymmetry	DVD	Refraction (diopters)†
			D	N			D	N			
1	123	95	XT 12	Ortho	No	400	NA	NA	Yes	Yes, DHD	Plano -0.50
2	124	111	Ortho	20 ET	No	—	F	F	Yes	Yes	+4.50 +4.50
3	143	107	ET 5	ET 7	No	3000	S	F	Yes	No	+2.50 +2.25
4	137	109	XT 2	ET 8	No	—	S	F	Yes	Yes, DHD	+0.75 +0.75
5	159	119	X(T) 7	X(T) 5	No	140	F	F	Yes	Yes	+4.00 +4.00
6	120	95	X(T) 25	X 6	No	3000	F	F	Yes	Yes	-0.25 -0.50
7	114	84	ET 10	ET 14	No	—	S	F	Yes	Yes	+1.75 +1.75
8	153	96	E(T) 14	E(T) 14	Yes	—	S	F	Yes	Yes	Plano Plano
9	140	85	Ortho	X 2	No	—	S	F	Yes	Yes	+2.75 +2.50
10	111	99	XT 8	XT 12	No	—	S	F	Yes	Yes	-1.00 -0.75

Amblyopia = difference of more than 1 line of Snellen acuity; XT = exotropia; X(T) = intermittent exotropia; X = exophoria; ET = esotropia; E(T) = intermittent esotropia; Ortho = orthotropia; DVD = dissociated vertical deviation; DHD = dissociated horizontal deviation; NA = information not available.

* Seconds of arc with Titmus test.

† Spherical equivalent cycloplegic refraction.

Table 5 Long-term outcome of early surgery for congenital esotropia

From Helveston EM, et al. Results of early alignment of congenital esotropia. *Ophthalmology*, 1999, 106(9):1716-1726. Used with permission.

Study	Age Aligned	Stereo		Stereo	Surgery	DVD (%)	Follow-up (yrs) (range)
		Titmus (%)	Random Dot (%)				
Wright (n = 7)	3 3/4 mos	70	42	40 (T) 250 (RD) 100 250 400 250 70	1.4 2H 1V	70	4 (2-8)
Birch (n = 73)	5-16 mos		41*	60'-<200' (RD)	1.7	50	5
Hiles (n = 54)	<11 mos	29			1.8 19H 24V	67	8 (4-11)
Kushner (n = 118)	<2 yrs	42		200'-3000' (T)			5
von Noorden (n = 190)	<2 yrs	3		800', 3000', 3000' (T)		51	(1-15)
Parks (n = 31)	<2 yrs	39		100'-3000' (T)			8.7 (6-20)
Ing (n = 106)	<2 yrs	66		40'-3000' (T)	1.8	63	1.1-23 Avg 7
Current study (n = 10)	4.2 mos	40		140', 400', 3000' 3000' (T)	2.1 4H 7V	90	10 (8-12)

DVD = dissociated vertical deviation.

* Stereo only in PTS aligned by 12 months.

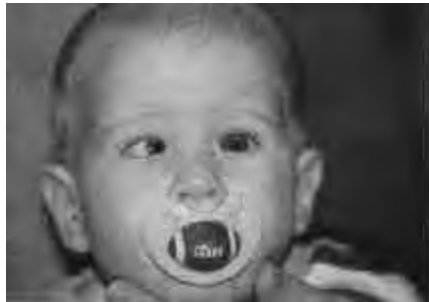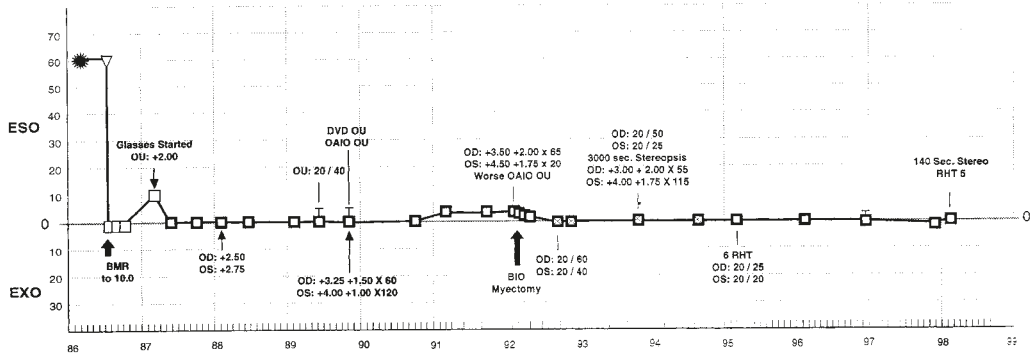
Table 6 Summary of results of treatment of congenital esotropia

From Helveston EM, et al. Results of early alignment of congenital esotropia. *Ophthalmology*, 1999, 106(9):1716-1726. Used with permission.

this, Neely, et. al. in a retrospective study demonstrated that DVD developed approximately 18 months after surgical alignment in congenital esotropia patients aligned both early and at a later time. This study concluded that the timing of surgery for congenital esotropia had no bearing on the occurrence of DVD. Rather, DVD occurs about one and a half years after surgery for esotropia, regardless of the surgery being done early or later.

The dynamic nature of congenital esotropia is demonstrated by the logs of four patients in this study. A record of each visit along with preoperative pictures and a picture at the end of follow up show the satisfactory cosmetic results obtained in these patients after a total of 97 visits and 17 interventions (including surgery, patching, and prescription of glasses). (Tables 7-10)

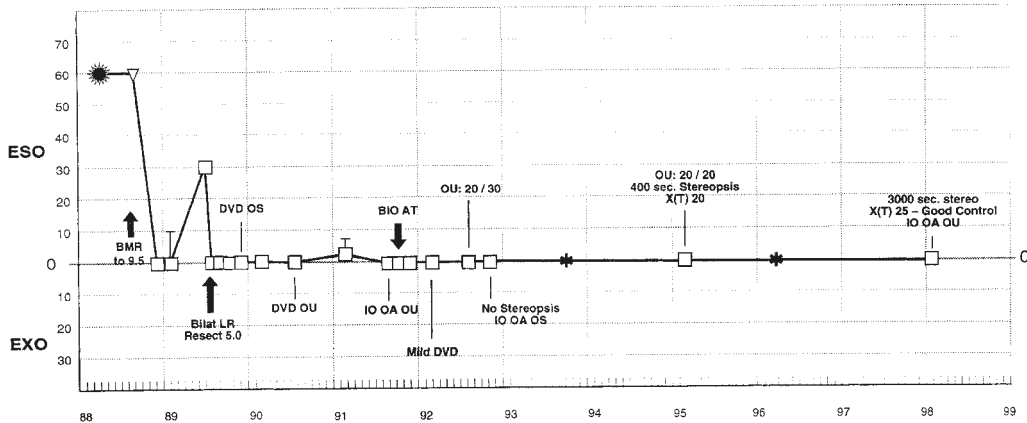
- = Birth
- ☀ = ET at Birth
- ☀ = ET First Noted
- ▽ = First Visit
- = Physician Visit
- ◻ = Preference One Eye
- ⊗ = Amblyopia
- ◻ = Wearing Glasses
- ◻ = Glasses - Preference One Eye
- ↓ = Surgery
- ↓ = Non-surgical Intervention
- | = Information About Visit
- * = Failed Visit (No Show)



Vision:	OD 20/40
	OS 20/40
Alignment:	D X(T) 7
	N X(T) 5
DVD:	Yes
Nyst:	No
Glasses:	OD +3.00 +2.00 x 45
	OS +3.00 +2.00 x 105
Stereo:	140 sec.
Worth:	D Fuses
	N Fuses

Table 7 Case #5

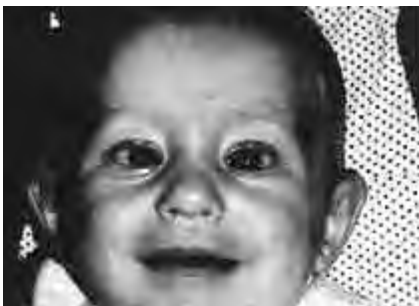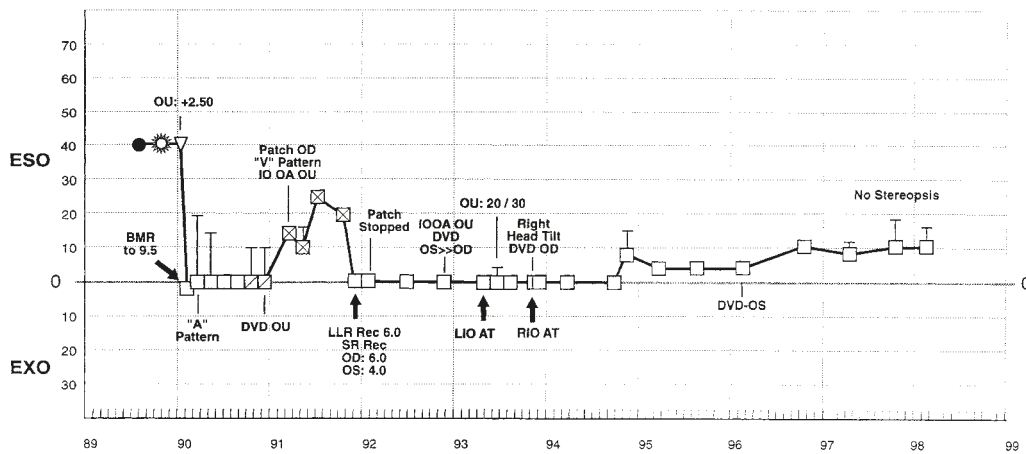
From Helveston EM, et al. Results of early alignment of congenital esotropia. Ophthalmology, 1999, 106(9):1716-1726. Used with permission.



Vision:	OD 20/20
	OS 20/20
Alignment:	D X(T) 25
	N X 6
DVD:	Yes
Nyst:	No
Glasses:	No
Stereo:	3000 sec.
Worth:	D Fuses
	N Fuses

Table 8 Case #1

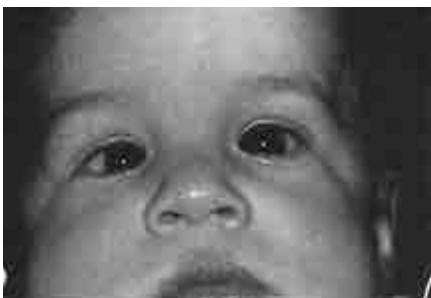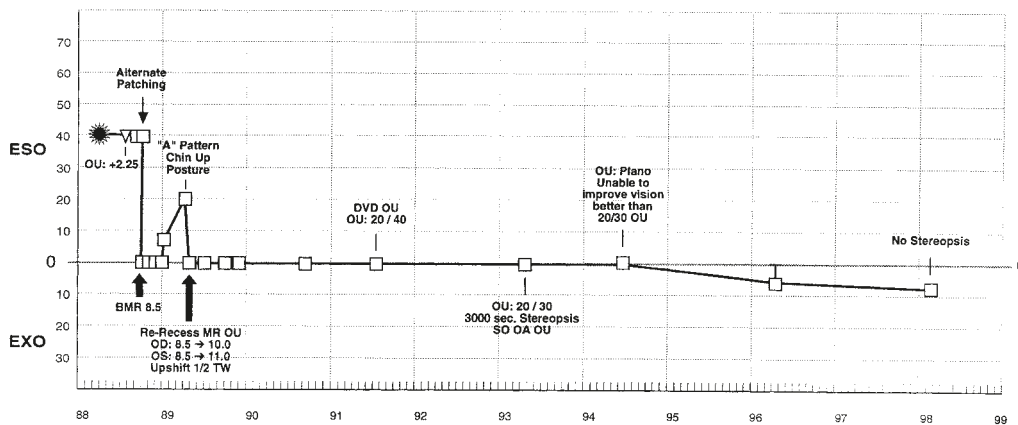
From Helveston EM, et al. Results of early alignment of congenital esotropia. Ophthalmology, 1999, 106(9):1716-1726. Used with permission.



Vision:	OD 20/25
	OS 20/30
Alignment:	D ET 10
	N ET 14
DVD:	Yes
Nyst:	No
Glasses:	No
Stereo:	No
Worth:	D Suppresses
	N Fuses

Table 9 Case #7

From Helveston EM, et al. Results of early alignment of congenital esotropia. Ophthalmology, 1999, 106(9):1716-1726. Used with permission.



Vision:	OD 20/40
	OS 20/30
Alignment:	D XT 8
	N XT 12
DVD:	Yes
Nyst:	Latent
Glasses:	No
Stereo:	No
Worth:	D Suppresses
	N Fuses

Table 10 Case #10

From Helveston EM, et al. Results of early alignment of congenital esotropia. Ophthalmology, 1999, 106(9):1716-1726. Used with permission.

Based on these findings and other clinical experience when discussing treatment options with the parent(s) of a patient with congenital esotropia, I say the following:

1. A diagnosis of congenital esotropia can be made with confidence by 4 months of age if the deviation is 40 prism diopters or more, is constant, and no other neurologic problems exist.
2. Surgery can be done safely in an infant at age 4 months if competent pediatric anesthesia is available.
3. An average of 2 surgical procedures is required to achieve stable alignment. Some patients are aligned with only one procedure, but others require more, even up to a total of 4 (possibly more?).
4. For best results, children treated for congenital esotropia should be followed closely until a time near the teen years.
5. Normal binocular function is not obtained from treatment of congenital esotropia, but about one half of children can appreciate some level of stereo acuity.
6. It has been my experience that alignment achieved by the teen years in patients treated for congenital esotropia tends to be stable.

done in the newborn nursery study. None of the newborns examined were found to have what could be called typical congenital or essential infantile esotropia. Freidrich and deDecker later did a comparable evaluation in 1000 newborns with similar results.

During periods of observation, infants were frequently noted to have *both* eyes crossed or *both* eyes diverged. This behavior was called convergence or divergence and not esotropia or exotropia. Strabismus was considered to be present only when at least one eye fixed on the examiner's face.

The conclusions from these newborn motility studies were as follows:

1. The clinical picture of 'congenital' or infantile esotropia is not present at birth.
2. Newborns seem to have an immature oculomotor system with inaccurate, unsteady, and nonmaintained fixation and they display a tendency toward exodeviation.
3. Newborns are mainly visually inattentive during short periods of observation and fix on the examiner's face only for brief intervals.

Ocular motility studies in the newborn

In an effort to learn more about the origins of infantile esotropia, I examined 500 newborns in the nursery as a pilot study to determine the status of ocular motility during the first few hours of life. Most of the newborns I observed either had straight eyes or were exodeviated. None had a picture compatible with as diagnosis or even a suspicion of 'congenital-infantile esotropia.' The study was continued with Robert Nixon as the principal nursery examiner, examining 1219 newborns (Figure 2). The alignment pattern in these infants was as follows: 48.6% were orthotropic, 32.7% were exotropic, 3.2% were exo- to esodeviated, and 15.4% were uncooperative and no statement was made about their motility.

In the third stage of the study, Archer, Sondhi, Helveston, and Miller examined 2917 newborns and found exodeviation in 66.5%, orthotropia in 29.9%, and eso- to exodeviation in 3.6% (Figure 3). With persistence and by using improved techniques carried out principally by Archer, nearly all newborns were sufficiently alert and cooperative to be examined during the third phase of the nursery study. The higher percentage of exodeviation is attributed to a longer, more thorough period of observation in the nursery. In total, more than 4000 infant examinations were



Figure 2
Examination of motility in a newborn.

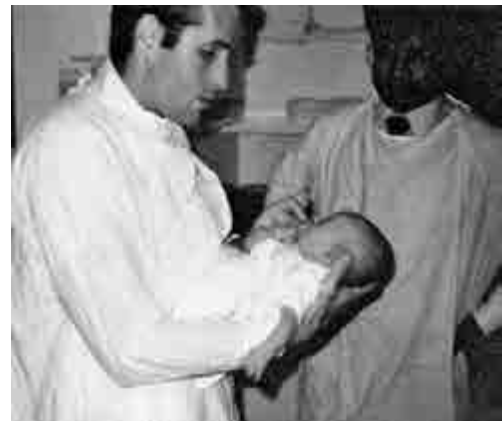

Figure 3
Follow-up motility evaluation in newborn at a clinic.

Follow-up evaluation of motility: The orthotropization curve

A follow-up study of motility was also conducted on this newborn population as they returned to the well baby clinic. In the entire study, which was led by the efforts of Archer, a total of 6228 examinations were performed on 4211 infants, of whom 3324 otherwise normal infants formed the population base. Of these, 922 were seen an average of 1.5 times in addition to the newborn examination and 582 had their last examination after 4 months. The purpose of this study was to determine the prevalence of various motility findings during this period of observation. The results showed that esodeviations were not seen in otherwise *normal* children after 2 or 3 months of age. Exodeviations disappeared by 6 to 8 months of age. The alignment between birth and 1 month was essentially the same. These overall findings were

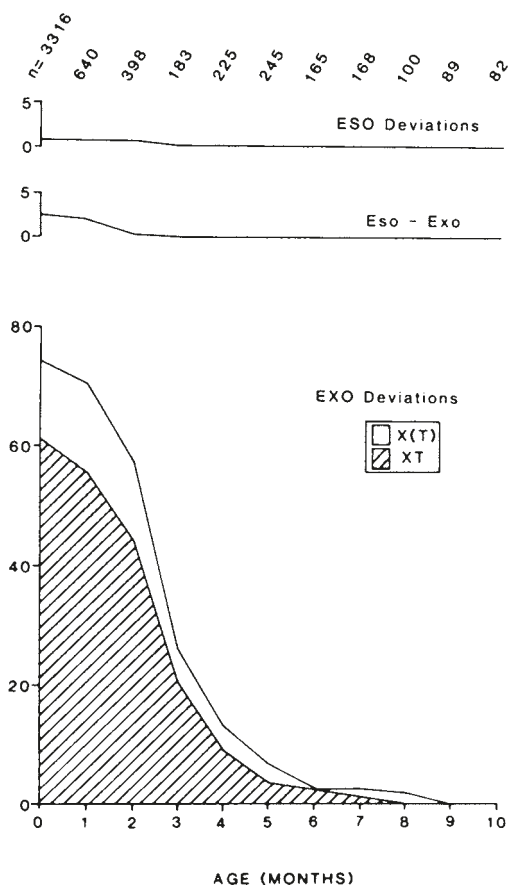


Figure 4
Orthotropization curve

described as an 'orthotropization curve' (Figure 4). During this study, the Bruckner test was done by observing the *binocular* pupillary reflexes indicating bifoveal fusion in the infants followed during this study. The Bruckner test is done by observing the *binocular* pupillary reflex with a plus lens in the direct ophthalmoscope. Equal pupillary reflexes indicate bifoveal fixation and therefore alignment of the visual axes. Unequal reflexes indicate central fixation with one eye and misalignment of the other eye. Unequal pupillary reflexes are also seen with straight eyes when anisometropia is present.

Three children seen in the newborn nursery and noted to have eyes that were straight or exotropic were found by age 6 months to have findings typical of congenital esotropia (Figure 5). Three patients with neonatal unilateral sixth nerve palsy reverted to normal within weeks to months. Another patient identified with Duane syndrome in the newborn nursery and followed for several months continued to manifest a typical type I esotropic Duane syndrome.

Conclusions from these observations of newborn were the following:

1. The clinical picture of 'congenital'-infantile esotropia was not present at birth in 4,211 infants.
2. The majority of newborns have an unstable ocular alignment biased toward an exodeviation, and this persists for the first few weeks of life.
3. Alignment at birth and at 1 month is similar.
4. There is a steady progression toward longer periods of straight eyes during the first six months of life.
5. Esodeviation persisting after two months of age is abnormal motility.
6. Normal infants do not seem to have a period of normal binocular stimulation prior to a presumed esotropial event such as early onset refractive esotropia or any presumed peripheral motor--induced esotropia.
7. Normal infants as well as infants who are destined to develop congenital esotropia may be indistinguishable in the first two months by clinic means.
8. Prolonged esotropia in the first weeks or months does not preclude normal binocularity later.
9. Exodeviation persisting beyond six to eight months is abnormal motility.
10. Duane can be diagnosed in the neonatal period.

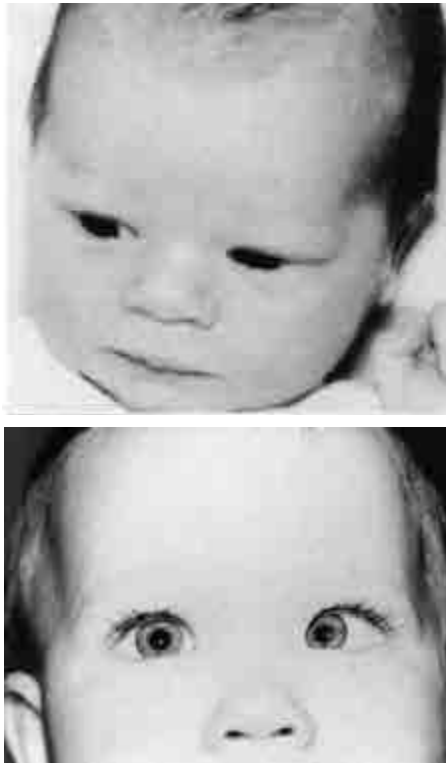

Figure 5
A A 1-day-old infant demonstrated slightly exodeviated eyes during examination
B At 6 months of age, this same child had 40 prism diopters of esotropia and presented the typical findings of congenital esotropia.

The newborn visual sensory system

It is well known that visual acuity of the infant is significantly below the level found in adults. This visual acuity improves rapidly over the first few weeks to months of life in the human, approaching adult visual acuity levels between six months and one year of age. Psychophysical studies using forced preferential looking techniques have shown that during the first month of life, infants prefer to look at stripes of 18 cy/degree, improving to a 6 cy/degree by six months. This is compared roughly to acuity of 20/800 and 20/100 in Snellen equivalents. However, this *recognition* acuity using high-contrast stripes is not the same as *resolution* acuity measured with Snellen optotypes, the latter being a more exacting measure. It has also been shown histologically that the macula is immature at birth, approaching a mature appearance in the second year and not developing full photoreceptor maturation until the fourth year. Newborns studied in the nursery support this finding by their fixation behavior. It appears, however, that accurate central fixation with visual acuity approaching 20/30 to 20/40 precedes histologic maturation.

Asymmetric optokinetic response is common in infants in the first three months of life. This response becomes symmetrical after three months in the nor-

mal infant, but asymmetry persists in infants who have congenital esotropia. It is not clear whether this is a purely sensory or combined sensory-motor response. It has been postulated that this response is mediated through the brain stem at the nucleus of the optic tract (NOT) based on anomalous cortical-retinal interaction to visual stimuli. Ciancia has shown what may be a purely sensory side of this phenomenon of OKN asymmetry by demonstrating asymmetric visually evoked potential in this type of patient.

Between two and four months of age a stereo response can be obtained for the first time using either stable targets or the dynamic random dot stereogram in infants with straight eyes. This stereo response is never found in an esotropic individual or in an infant less than two months old. According to Leguire and to Archer, in separate studies, a few infants who had their eyes surgically straightened at an early age demonstrated gross stereopsis while the eyes were perfectly straight but lost stereopsis as a small-angle esodeviation returned.

For approximately the first four months the infant's visual-sensory-fusion system and visual-motor systems are immature and relatively ineffective compared to adult standards of acuity and alignment. The system in the normal infant will not sustain straight eyes consistently until somewhere between two and four months of age.

What causes congenital esotropia?

A theory for the origin of congenital esotropia is proposed as follows:

1. At birth infants who are otherwise normal neurologically--and regardless of their ultimate ocular alignment--start with similar motor and sensory behavior. They have reduced visual acuity (sensory), unsteady ocular alignment (motor), and absence of stereopsis (sensory fusion) (Figure 6A). (Infants with obvious afferent defects such as cataracts, anatomic defects such as optic nerve hypoplasia, structural muscle or nerve defects, congenital motor nystagmus, sixth nerve palsy Möbius, Duane syndrome, etc., are considered separately).
2. The sensory and motor systems mature rapidly, concurrently, but independently. At approximately two months of age they are sufficiently developed to sustain normal binocular vision (Figure 6B).
3. When the sensory and motor functions are sufficiently mature, they interact, through the maturation of an inborn cortical fusion faculty that has both a motor fusion and a sensory fusion component. This is the 'keystone' of the 'arch' that has a sensory 'arm' and a motor 'arm.'

BEFORE 2 MONTHS

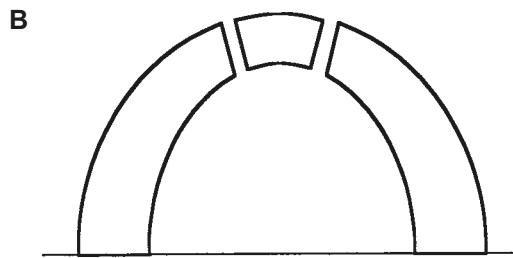
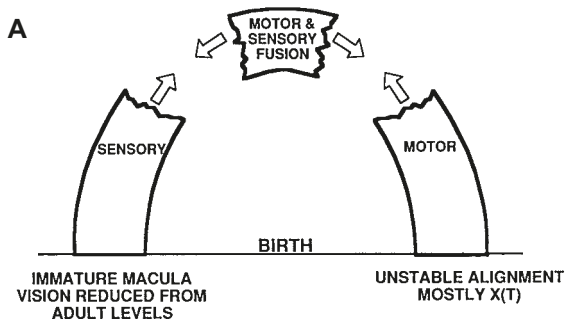


Figure 6

A Before 2 months of age, the motor and sensory systems are immature.

B Completed 'arch' between 2 and 4 months.

4. The motor fusion component of the 'keystone' uses images disparity as a stimulus for the acquisition of a single superimposed image from each of the two eyes. The sensory component of fusion recognizes small lateral displacement of these two images (within Panum's fusional space) and interprets them as a single image with stereoscopic depth perception. Motor fusion can be normal in the absence of sensory fusion, but sensory fusion is never normal in the absence of normal motor fusion (Figure 7).

5. The fusion 'arch' completes a stable union of sensory and motor function maintaining straight eyes.

If the 'keystone' of motor-sensory fusion is absent or defective, the developing system breaks down and the 'arch' collapses (Figure 8). The integrity is lost because of a lack of motor fusion (absence of the normal 'keystone' of the fusion arch). Strabismus occurs, and persists, in the absence of the motor fusion lock in the infant, usually beginning with a variable angle of strabismus and later developing into a stable angle. A secondary defect in the afferent system (amblyopia) may occur because the misaligned visual axes force one eye to be chosen to view the object of regard and in the process of retinal rivalry a stimulus for suppression occurs. Anomalous retinal correspondence (ARC) then occurs as an adaptive mechanism in response to misalignment of the visual axes. In my opinion, ARC is present in every case of misalignment of the visual axes without diplopia, but it may or may not be found clinically, or may be found as non-harmonious ARC, depending on the method of testing.

Other reasons for collapse in the arch can be defective sensory limb (congenital cataract) or motor abnormalities (congenital third nerve palsy) producing manifest strabismus during the period of susceptibility (Figure 9).

STEREO ACUITY

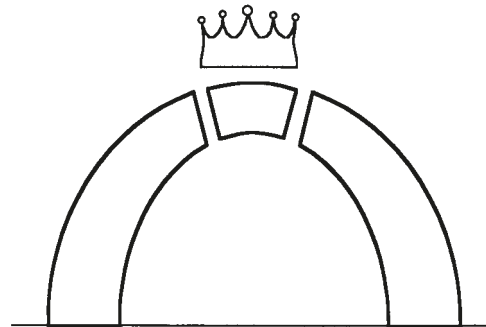


Figure 7

The completed 'arch,' 'crowned' with stereopsis.

CONGENITAL ESOTROPIA

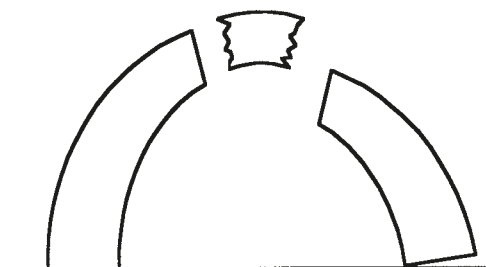


Figure 8

The absence of the 'keystone' of sensorimotor fusion causes a collapse of the forming arch of normal binocular vision resulting here in esotropia.

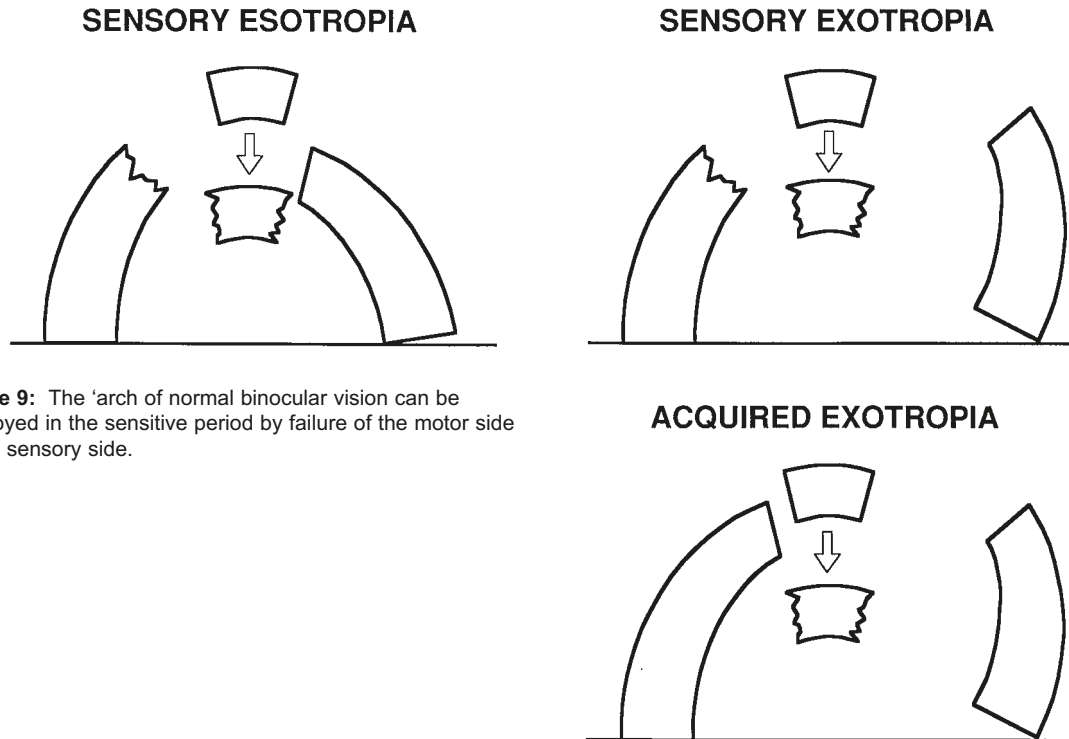


Figure 9: The 'arch of normal binocular vision' can be destroyed in the sensitive period by failure of the motor side or the sensory side.

Infantile esotropia with nystagmus as a prominent feature may be an example of a combined motor and brain stem--derived esotropia. Nystagmus blockage type esotropia with manifest latent or manifest nystagmus may represent a *secondary* defect (esotropia) occurring after convergence to damp nystagmus. Those cases of congenital esotropia without manifest nystagmus may be the only ones with a true congenital, occipital cortex--based, motor-sensory fusion defect.

When incomitant strabismus is present in a patient with normal motor fusion potential, it can be dealt with by assuming a head posture which results in alignment of the eye. In these cases, it is the head that moves while the eyes remain fixed with fusion on the object of regard. Examples of this strategy employed in Brown, superior oblique palsy, and Duane are shown in Figure 10.

I believe that the presence of the 'keystone' for motor and ultimately sensory fusion is genetically determined. Likewise, the absence of this keystone is genetic. The presence or absence of this characteristic cannot be uncovered by clinical means at our disposal until approximately two to four months of age when the system is programmed to complete the scheme for the development of binocular alignment.

Possible hereditary factors

In an effort to learn more about possible hereditary factors in congenital esotropia, we studied otherwise normal parents of children with congenital

esotropia. In spite of having at least 20/20 vision in each eye and no more than 2 prism diopters of phoria, these parents had a 16% incidence of reduced stereo acuity of 80 sec arc or less and could be classified as having subnormal binocular vision. This was in contrast to a control group of parents who had a 2% incidence of subnormal binocular vision. Adding to these statistics is the well-known fact that children with congenital esotropia are more likely to have a parent or first-order relative with esotropia compared to children without congenital esotropia. Following this study, we found no difference in the response to treatment in those children with or without a parent with subnormal binocular vision. This suggests to us that defective stereo acuity is a subtle inborn defect which could be a form fruste of congenital esotropia, but the true relationship between a minimal defect in stereo-acuity and normal alignment remains unexplained. On the other hand, asymmetric OKN is a *reaction* to ocular misalignment even as mild as minimal DVD and is therefore classified as a result, not a cause, of congenital esotropia. The stereo acuity defect is inborn and cortically based. The OKN defect is secondary and brain stem based.

Another way to look at the picture of congenital esotropia in a graphic way and still retain the elements of sensory (afferent), motor (efferent), and sensory-motor fusion (link or keystone) components of infantile esotropia is to picture a closed loop system (Figure 11).

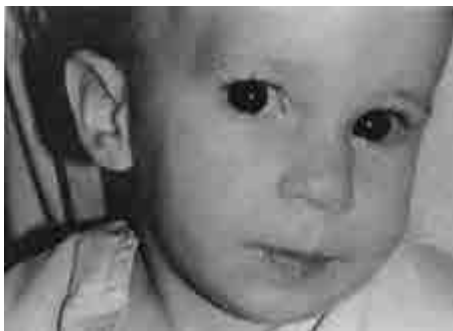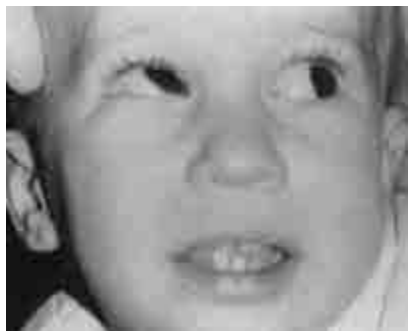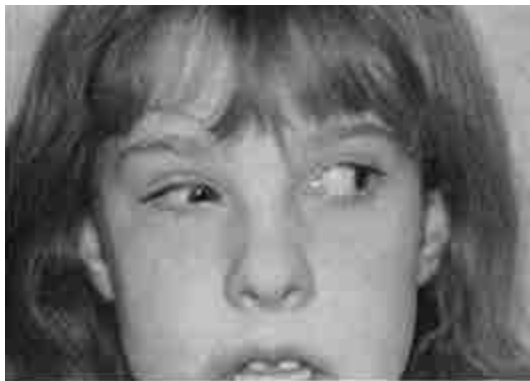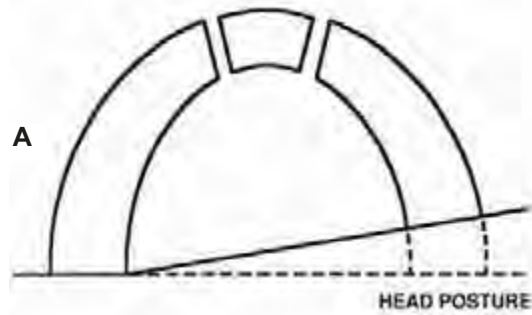


Figure 10

A By changing the 'foundation,' the 'arch' can maintain its integrity provided the 'keystone' of motor fusion is intact. This is done when patients assume an appropriate head posture in:
B Mild Brown syndrome, left eye
B₁ Eyes are aligned when head moves to position where strabismus is maximum in Brown.

C Duane syndrome, right eye
C₁ This girl with Class II Duane turns her head toward the normal side to achieve fusion.
D Right superior oblique palsy
D₁ A chin down, head tilt left is the head posture assumed to gain fusion by this child with congenital right superior oblique palsy.

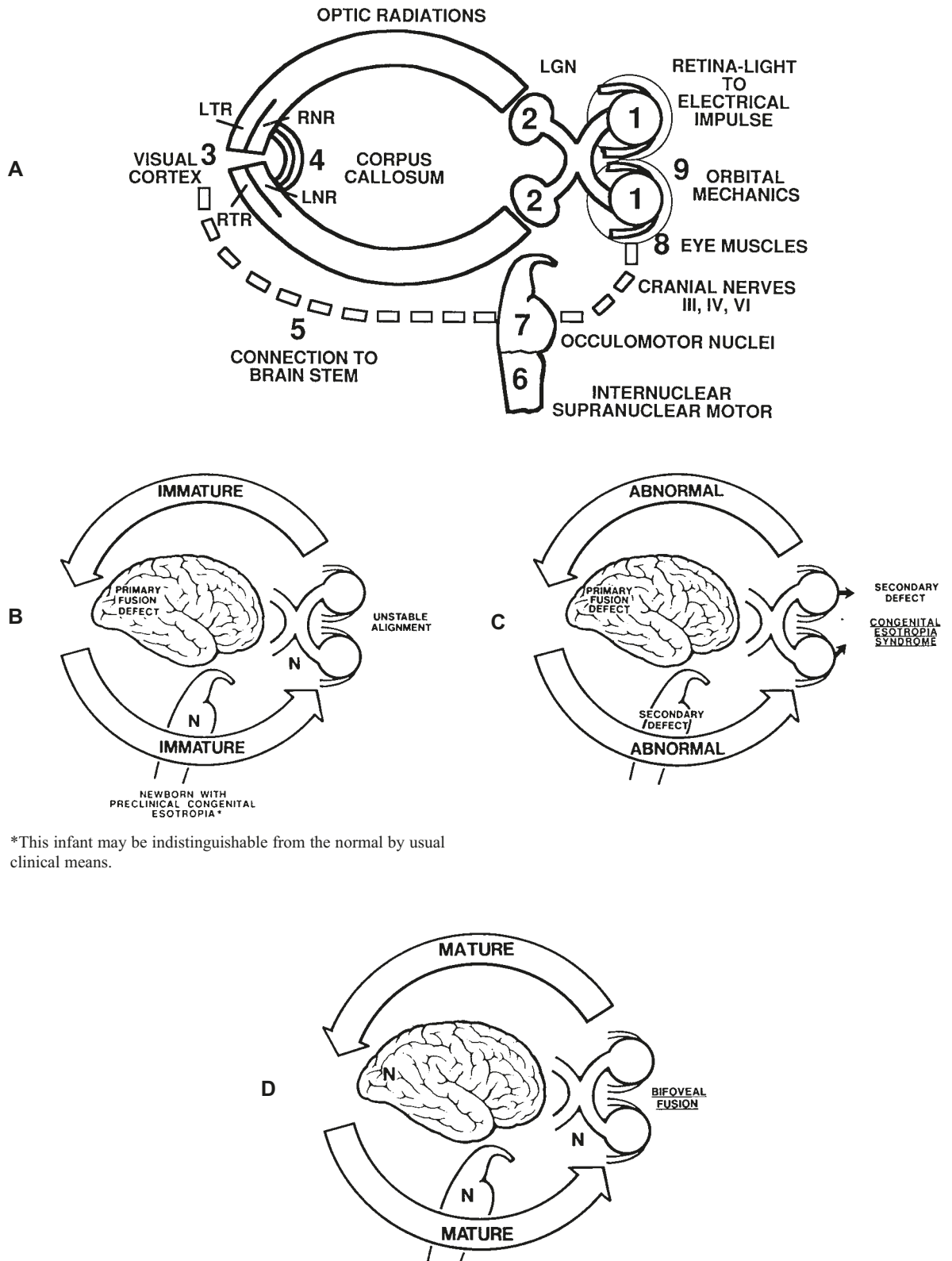


Figure 11

A The nine components of the complete closed loop of binocular vision.
B The immature 'open loop' demonstrating unstable alignment.

C Congenital esotropia with a pathologic 'open loop.'
D Mature 'normal' loop.

Characteristic	No.	(%)
Amblyopia	144	(35)
Anomalous head posture	26	(6)
Dissociated vertical deviation (DVD)	208	(51)
Overaction of inferior obliques (OAIO)	277	(68)
DVD and OAIO (combined)	171	(42)
Manifest nystagmus	62	(15)
Manifest-latent nystagmus	41	(10)

*Mean deviation at distance, 44 prism diopters (range, 5 to 100 prism diopters). Mean deviation at near, 49 prism diopters (range, 10 to 95 prism diopters)

Table 11 Characteristics of essential infantile esotropia* according to von Noorden (N=408)

The occurrence of associated finding with congenital esotropia has been described according their salient features by von Noorden (Table 11). He also offers a differential diagnosis (Table 12). Other descriptions of infantile esotropia have been offered by Lang, Adelstein, Cüppers, and Ciancia. Harcourt simply described congenital esotropia with and without nystagmus. I prefer to recognize Ciancia syndrome as congenital esotropia that has manifest latent nystagmus as the most prominent feature. Nystagmus blockage syndrome is manifest congenital nystagmus with a null in convergence. While several important characteristics are associated with different types of esotropia in infancy, important clinical features of congenital esotropia are *strabismus (always)*, *OKN asymmetry (always)*, *nystagmus*, and *abnormal head posture (sometimes)*. These features can be seen with some or all of the findings listed as characteristics of congenital esotropia in Table 11.

Early refractive esotropia, not included in this scheme, is usually easily distinguishable because of a later onset, better fusion potential, and response to correction of hyperopia. Other characteristics of congenital esotropia including amblyopia, DVD, and oblique muscle dysfunction are secondary. The principal characteristics of esotropia in infancy can be combined in a Venn diagram, which makes the relationships of the early onset esodeviations easier to understand (Figure 12) (Table 13).

Primary congenital esotropia has a moderate to large angle esotropia. The patient may alternate or prefer fixation with one eye (amblyopia). Nystagmus, manifest or latent, and anomalous head posture are usually not present at the outset but may occur later. The primary defect is presumed to be a congenital defect in the central, cortical motor fusion center.

Ciancia syndrome is esotropia with limited abduction and manifest latent nystagmus of the abducting eye. These patients fixate with the adducted eye and turn their face to the side of the fixing eye. This is called cross fixation. The primary congenital defect is in the cortical motor fusion center, seen as esotropia with manifest latent nystagmus secondary to brain stem response.

Nystagmus blockage syndrome is manifest congenital nystagmus damped by convergence. Both eyes are crossed. One eye is used for fixation and the face is turned toward the fixating eye. The primary defect is presumed to be in the brain stem.

Latent and manifest latent nystagmus, dissociated vertical deviation, and amblyopia can occur as later findings in any esotropia of infancy. In my experience, congenital esotropia without nystagmus is more likely to be aligned with one procedure consisting of an appropriate size bimedial rectus recession. Sprunger, et. al. have shown that in the presence

Essential infantile esotropia*
Sixth nerve palsy
Nystagmus dampened by convergence
Esotropia with central nervous system anomalies (Down's syndrome, albinism, cerebral palsy, mental retardation, and the like)
Refractive accommodative esotropia
Sensory esotropia
Duane syndrome, type 1
* congenital esotropia
± Möbius syndrome (EMH)

Table 12 Differential diagnosis of infantile esotropia according to von Noorden

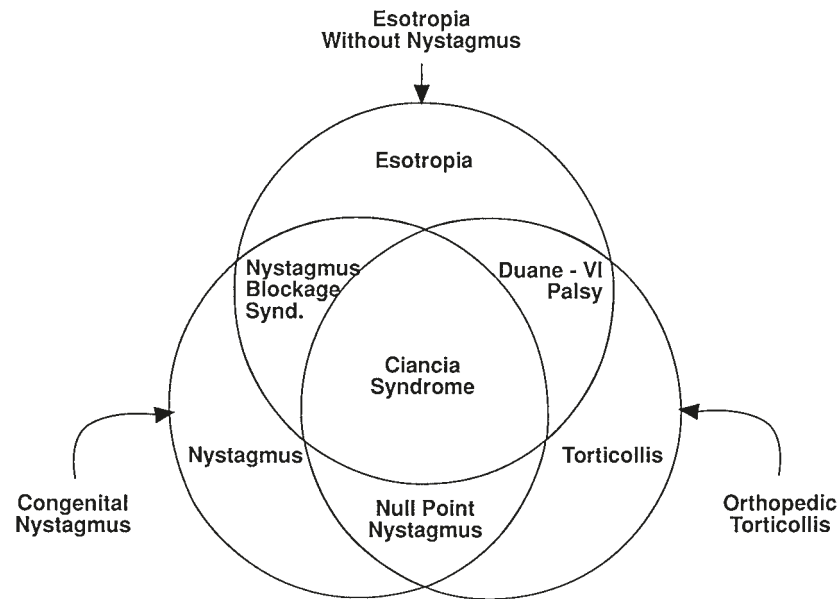


Figure 12 Venn diagram

Congenital esotropia syndrome (Lang)	
1. Esotropia of early onset	4. Excyclodeviation of the nonfixing eye
2. Alternating sursumduction (DVD)	5. Abnormal head posture
3. Nystagmus	6. Slight hereditary influence
Essential infantile esotropia (von Noorden)	
1. Onset--birth to 6 months	Excessive adduction
2. Large angle, >30 prism diopters	Dysfunction of oblique muscles
3. Stable angle	Dissociated vertical deviation
4. Normal central nervous system	6. Initial alternation with cross fixation; potential for normal binocular vision limited
5. May be associated with: Defective abduction	
Nystagmus blockage (Adelstein-Cuppers)	
1. Nystagmus on abduction	3. Straightening eyes under general anesthesia
2. Head turn in direction of fixing eye	
Nystagmus blockage (von Noorden)	
Manifest jerky nystagmus that decreases or disappears with esotropia, accommodative convergence when sustaining fixation on an object distance or near.	
Ciancia syndrome	
1. Esotropia early onset	in abduction and decreasing in adduction
2. Rather large angle deviation	5. Torticollis: the face is rotated toward the side of the fixing eye.
3. Bilateral limitation of abduction	6. Hyperopia generally moderate or absent
4. Jerk nystagmus (manifest latent) with the quick phase toward the side of the fixing eye increasing	

Table 13 Clinical Characteristics

of nystagmus, it is more difficult to achieve alignment in congenital esotropia. Both Ciancia syndrome and nystagmus blockage syndrome are more likely to require additional surgery to achieve horizontal alignment. Duane syndrome I is a truly congenital esotropia but has a normal sensorimotor status and with the proper head posture, in most cases, fusion is obtained. Surgery in cases of Duane syndrome is ordinarily done to improve head posture and primary position alignment. Even with successful surgery, some strabismus remains.

Intermittent exotropia

Intermittent exotropia is a common, though enigmatic, form of strabismus that presents only a modest diagnostic challenge but which requires considerable therapeutic acumen and tenacity. Patients with this type of strabismus, more than any other, demonstrate a duality of behavior in that they seem to be completely normal during orthotropic interludes and totally 'turned off' during periods of manifest exodeviation. At the outset it should be stated *exophoria*; that is, a latent and usually small-angle exodeviation, is not amenable to surgical treatment. This latent deviation, which by definition is kept in check under binocular conditions, can cause symptoms of asthenopia best treated with orthoptic exercises, but not prism wear which will be 'eaten up.' These exercises can enhance motor fusion amplitudes to control the deviation in both phoric and some intermittently tropic patients. In such cases, the greater the motor fusion response for convergence, the more effectively the deviation will be held in check with reduction or elimination of symptoms. Orthoptic exercises can consist of near point of convergence 'push up' maneuvers, used for convergence insufficiency that has a greater exodeviation at near, convergence enhancement with fusible targets, working against base-out prism, and use of over-minus lenses that invoke accommodative convergence.

In contrast to the exophoric patient, those patients with intermittent exotropia who are tropic demonstrating a manifest deviation part of the time and who require surgical correction occur in several forms. They are classified on the basis of when the eyes are deviated and in what field or distance of gaze the deviation is greater. However, a strong undercurrent of similarity connects all forms of intermittent and latent exodeviations.

Refractive error in intermittent exotropia

Patients with intermittent exotropia in our experience have a low refractive error, either 'plus' or 'minus,' with or without moderate astigmatism. This may be a valid observation, but it may also be due to

the fact that moderate amounts of uncorrected hyperopia are usually accompanied by accommodation to achieve a clear image, and this would automatically invoke accommodative convergence with the potential for elimination of or reduction of the exodeviation. Others have found a normal distribution of refractive errors in patients with intermittent exotropia. For whatever reason, those patients I have treated for intermittent exotropia tend to have very little, if any, hyperopia.

Age of onset

Clinically significant intermittent exotropia can be seen in infants 6 months of age or even younger. A more common age of onset is during the toddler period, between 1 1/2 and 3 years of age. Parents may observe that their child "does not look at me." It is usually difficult for parents to accurately describe this type of strabismus. They often say that the eyes of the child simply "don't look right." At other times, parents have said that they have seen their child's eyes turn *in*. After careful questioning it usually becomes clear that the parents are describing the *recovery* movement from the exodeviation to the straight position--therefore, the turning *in*. The pattern of exodeviation over time is usually characterized by a steady progression with increasing periods of tropia during the preschool years. However, in some cases the deviation remains stable and a few even improve. Paradoxically, it has been shown by Archer that giving full correction in some hyperopic patients can lead to control of intermittent exotropia.

Pattern of deviation in the young

Two characteristics of the intermittent exotropia deviation in the preschool years are (1) increasing likelihood of tropia when the child is fatigued, day-dreaming, or inattentive and (2) closing one eye in bright sunlight. The latter is an especially interesting phenomenon. von Noorden and Wiggins have shown that fusional amplitudes decrease in the majority of subjects, both strabismic and normal, when tested with increasing illumination. It is also a commonly observed phenomenon that most normal people when in bright sunlight outdoors will close the eye *nearer* to the sun, while unconsciously using the nose in part to shade the fixating eye. If the sunny-side eye were exotropic, it would be all the more exposed to the sun and therefore demanding closure for comfort. It is important to elicit this history of closing one eye in bright sunlight when confirming a diagnosis of intermittent exotropia in a young child. When this question is asked of a parent and they respond in the affirmative, it lends a measure of credence to you, the examiner, and tends to confirm that the exodeviation is present during these periods.

Exodeviation in the newborn

When considering the onset and frequent progression of intermittent exotropia in the young child, it is important to recognize that intermittent exotropia (with fixation of one eye) or divergence (without fixation) is seen almost routinely in the normal newborn and infant. Archer leading our nursery eye examination team found that two thirds of newborns demonstrated an exodeviation at some time during a motility examination. This exodeviation was seen in fewer children as examinations were done on older infants at monthly intervals. It was concluded from this study that exodeviations should not be considered clinically significant until after 6 to 8 months. Esodeviations, in contrast to exodeviations, occurred in fewer than 3% of newborns and this deviation resolved earlier. Any esodeviation persisting beyond 2 months is considered clinically significant. This pattern of development of normal alignment makes it difficult to make a firm diagnosis of intermittent exotropia before 6 to 8 months of age.

Pathophysiology of intermittent exotropia

Why do the eyes go out? What is occurring in the sensory system while the eyes are straight? When they are out? Some things we know can be listed: First, when the eye is exodeviated in the manifest phase of intermittent exotropia, the patient is symptom free. There is no diplopia. Second, the binocular peripheral field is enlarged when the eyes are deviated. However, this enlarged peripheral binocular field is more readily appreciated and potentially useful in adults with constant exotropia. Third, a large central scotoma is present in the deviating eye during the tropic phase. The suppression pattern and retinal correspondence have been studied by Pratt-Johnson and Tillson, who found consistent harmonious anomalous correspondence. The role of so-called hemiretinal suppression of the temporal retina has been stressed by Jampolsky. Older theories discuss anatomic orbital factors and the role of active divergence, the balance of forces at rest in the exodeviated position, and the role of the accommodative convergence/ accommodation ratio in overcoming an innate tendency toward exodeviation. None of these explanations is entirely satisfactory, though each may have some validity.

Racial predilection

Intermittent exotropia is slightly more common in the black race. This condition is also seen frequently in fair-haired, blue-eyed Scandinavians and in societies and cultures who are less involved in prolonged near work.

Classification of intermittent exotropia

Intermittent exotropia has been classically divided into four categories.

I. Basic type--The exodeviation after dissociation is the same at distance and at near.

II. Divergence excess type--The distance exodeviation is greater than the near deviation by 15 prism diopters. The near point of convergence in these patients is usually recessed.

III. Convergence insufficiency type--The near deviation intermittent exotropia is greater than the far deviation by 15 prism diopters. The near point of convergence in these patients is usually recessed.

IV. Simulated divergence excess type--The patient presents initially with a larger deviation at distance compared to near. However, the near deviation is reduced on the basis of the tonic near reflex and proximal convergence. In order to differentiate between true and simulated divergence excess intermittent esotropia, the patient should have one eye patched for 15 to 30 minutes, after which careful alternate prism and cover testing is carried out at near using an accommodative target without allowing the patient to use both eyes together. If the near deviation remains smaller, the individual has true divergence excess. On the other hand, if the deviation increases to equal or nearly equal the distance deviation, a diagnosis of simulated divergence excess--basic exotropia can be made.

In addition to these categories of intermittent exotropia, Knapp and Moore have emphasized the importance of lateral incomitance. These patients will demonstrate a smaller exodeviation when alternate prism and cover testing is carried out in lateral gaze to either side in spite of having full abduction. Recognition of this is important, according to Knapp and Moore, because patients with 20% or more reduction in exodeviation in lateral gaze are more likely to be overcorrected surgically if the amount of surgery is done purely on the basis of measurements made in the primary position. This finding of lateral gaze incomitance may be a measure of a patient's *convergence* response to the 'unnatural' exercise of fixation in extremes of lateral gaze maintained during prism and cover testing.

'A' and 'V' pattern with intermittent exotropia

Patients with intermittent exotropia also may have an 'A' or 'V' pattern and in some instances may have an associated hyperdeviation present in primary position when the eyes are dissociated. In other cases, an 'X' pattern may be present characterized by an increase in the exodeviation in both up- and

downgaze. The rules of treatment are consistent. If oblique dysfunction is a cause of the A or V pattern, the obliques may be weakened. However, the superior oblique should be weakened only if other surgical considerations such as downshift of the lateral or upshift of the medial rectus muscles would be considered ineffective, if no exodeviation is present in primary position and, of course, if definite overaction of the superior oblique is demonstrated. Bilateral superior oblique weakening should be avoided in most A pattern patients who demonstrate fusion. In most cases of intermittent exotropia with A or V, I prefer when possible to perform appropriate vertical shift of the horizontal recti, sometimes without recession if no deviation is present in the primary position. X patterns will usually resolve with correction of the primary position deviation after surgery done only on the horizontal recti. I have not found it necessary to weaken all of the obliques, as has been suggested. 'A,' 'V,' or 'X' pattern deviations are more likely to be seen in constant than in intermittent tropias.

Combined horizontal and vertical deviation with intermittent exotropia

If when the exodeviation is neutralized with base-in prism during the prism and cover test the vertical deviation is eliminated, the vertical deviation (which may be called a 'dissociation vertical') may be ignored at the time of surgical correction. On the other hand, if the vertical deviation persists after the horizontal deviation has been neutralized with prism, it deserves to be treated with appropriate vertical rectus or inferior oblique surgery. Persisting vertical deviation is more likely to occur with constant exodeviation. When combined vertical and horizontal surgery is done, this surgery usually consists of superior rectus recession on the appropriate side.

Work-up of the patient with intermittent exotropia

Evaluation of the patient with intermittent exotropia should be carried out according to the guidelines recommended (see chapter 4). Several characteristics unique to the intermittent exotropia patient and important in evaluation should be stressed. An accommodative target should be used when doing the prism and cover test both in the distance and at near with the patient also wearing full correction. The reason for this is that patients can employ accommodative convergence in the distance to maintain straight eyes at the cost a blurred image. While reading a 20/20 target and wearing proper correction, a patient will manifest the true exodeviation, free of the influence of accommodative convergence. Conversely, while fixing a distant fixation light (which is a nonaccommodative target) or a large target such as a 20/200 optotype, the eyes may be less

exodeviated or even straight during cover testing, at the expense of vision, which is fogged, though undetected, by accommodative convergence.

To obtain an accurate distance measurement some prefer to measure while a patient fixates on a far distant object at 'infinity.' To do this, the patient may be asked to look out of a window at a distant chimney, clock, tree, etc., while prism and cover testing is carried out to detect the maximum distance exodeviation.

A short-term use of a patch can differentiate simulated from true divergence excess. Use of alternate patching for days or weeks in patients with intermittent exotropia has been said to result in a reduction in the exodeviation, but I have not employed this technique often.

Parental observation

During the initial examination of a child with intermittent exotropia, an important part of the process is to actually demonstrate the deviation to the parents. They should be shown the misalignment of the eyes just after dissociation and while the eyes are exotropic. This is described to them as the 'deviation.' Next, the family observes the recovery movement. It has been important in our practice to send families home from an initial examination of a child with intermittent exotropia with instructions to keep a 'report card' of their child's ocular alignment. At subsequent examinations parents should report approximately how often the child's eyes are deviated, under what conditions the child's eyes are deviated, how readily the child's eyes can be straightened or recovery takes place, etc. Without this type of demonstration parents may bring such a child for repeated examinations without ever really understanding the true nature of the deviation!

Nonsurgical treatment of intermittent exotropia

Intermittent exotropia is amenable to orthoptic exercises in certain cases. Convergence insufficiency in a teenager or an adult can be helped with conscientious performance of near point of convergence exercises, or in some cases, base-out prism may be used to stimulate convergence. On the other hand, base-in prisms play only a small role in the treatment of most cases of true intermittent exotropia because the patient usually has no symptoms, (except in cases of convergence insufficiency) only a deviation with suppression. Overcorrecting minus lenses may be used as an exercise to stimulate convergence to overcome an intermittent exotropia. This type of treatment would more likely be used in a case that has been undercorrected at surgery in an effort to rescue a surgical attempt. Overcorrecting minus lenses used in place of surgery are a form of procrastination.

Symptomatic convergence insufficiency may be treated with base-in prism. While of theoretical value, I have not used weak or incomplete cycloplegia to stimulate accommodative convergence.

Surgical treatment of intermittent exotropia

The surgical treatment of intermittent exotropia presents some philosophical problems. These patients have a lot going for them before anything is done. Vision is usually equal and normal in each eye, sensory fusion with stereopsis and motor fusion amplitudes are present, and versions and ductions are intact. In other words, the 'good' intermittent exotropia patient is very, very good. On the other hand, at times when the eyes are exodeviated, central field binocular cooperation seems to be 'turned off.' One eye drifts out, suppression of the central field is profound, and that part of the visual experience is essentially ignored. The motility and sensory condition in intermittent exotropia is certainly dynamic, varying between having one 'turned off' exodeviated eye and having perfectly normal binocular cooperation. At the same time, a 'static' surgical procedure is used for treatment. By static I mean that muscles are recessed or shortened (resected) to alter an alignment that is orthotropic much of the time. There is no evidence that this surgery has any specific effect on vergences or fusional ability. With this apparent illogical application, the 'fit' is not always perfect. Some flexibility in treatment plan and diligence in the follow-up, especially with regard to nonsurgical intervention as well as surgical treatment, is necessary.

Timing of surgery

Strabismologists disagree on the best time for surgery. Some prefer early surgery for intermittent exotropia, saying that it is important to avoid prolonged periods of suppression that can lead to deterioration of the normal fusion substrate. On the contrary, others believe it is safe to follow these children with observation, stressing that patients are as good as they are at their best; 'the glass is half full, not half empty.' Two arguments for delay are (1) overcorrection is easier to deal with in an older, more cooperative patient and (2) some intermittent exotropia patients remain the same and a few even improve. The great fear in surgical treatment of intermittent exotropia is overcorrecting a very young patient and converting this patient into a small-angle esotropia with loss of stereopsis and possibly producing amblyopia. The majority of strabismologists do not consider intermittent exotropia in the young patient between ages approximately 1 and 3 years to be an emergency.

Most surgeons prefer to establish a course of progression of the intermittent exotropia and then perform surgery at the mid-preschool years, between 2 1/2 and 4 years of age or even later. However, exceptions to this rule do occur; I have operated on a few patients with intermittent exotropia who were under the age of 1 year of age. In older children and adults with basic intermittent exotropia, and adults with convergence insufficiency, surgery is done when the patient wishes, either because of problems with appearance or from asthenopia, or both.

Choice of muscles and amount of surgery

Basic intermittent exotropia and pseudodivergence basic intermittent exotropia are treated the same way. The main choices surgically are between bilateral lateral rectus recession and lateral rectus recession combined with medial rectus resection. While individual surgeons may have strong preferences for one technique. No strong evidence exists to support one technique over the other.

For most cases, I prefer bilateral lateral rectus recession over recession-resection. The reason for this is that the recession procedure is slightly more physiologic than the resection procedure. In addition, medial rectus resection can produce a lump under the conjunctiva. For larger deviations, it is necessary to add to bilateral lateral rectus recession a medial rectus resection or even bimedial rectus resection.

A useful table for surgical 'numbers' follows:*

Bilateral lateral rectus recession

- 5.0 mm OU/20-25 prism diopters
- 6.0 mm OU/25-30 prism diopters
- 7.0 mm OU/30-40 prism diopters
- 8.0 mm OU/40-50 prism diopters

Recession lateral rectus--resection medial rectus

- 5.0 mm--*5.0 mm/20-25 prism diopters
- 6.0 mm--*6.0 mm/25-30 prism diopters
- 7.0 mm--*8.0 mm/30-40 prism diopters
- 8.0 mm--*10.0 mm/40-50 prism diopters

Three-muscle surgery

- 8.0 mm--*6.0 mm--8.0 mm/50-60 prism diopters
- 8.0 mm--*8.0 mm--8.0 mm/60-75 prism diopters

Four-muscle surgery

- 8.0 mm--*8.0 mm--*8.0mm/70-85prism diopters
- 8.0 mm--*10.0 mm--*10.0 mm--8.0 mm/85-100 prism diopters

In most cases of intermittent exotropia requiring surgery, the deviation is 50 prism diopters or less.

* Any time you read surgical 'numbers' in this book, be aware that these are only my best approximation - a place to start. Each surgeon's numbers must be his or her own! The second asterisk refers to medial rectus resection.

Therefore, two-muscle surgery--either bilateral lateral rectus recession or recession of one lateral rectus and resection of the same medial rectus muscle of the same eye--is sufficient.

Divergence excess intermittent exotropia

This condition is best treated with bilateral lateral rectus recession. A table for surgery follows:

- 5.0 mm OU/20-25 prism diopters
- 6.0 mm OU/25-30 prism diopters
- 7.0 mm OU/30-40 prism diopters
- 8.0 mm OU/40-50 prism diopters

This surgery is done without regard for the near deviation. In most cases, correction of the distance deviation has no adverse effect on the near deviation. However, in two very intense, highly motivated, teenage female patients the distance deviation could be repaired only at the expense of the near deviation. One patient requested to have her eyes over-corrected to an esotropia when she was in college so that she could read. She wore base-out prism for driving. After she finished school and began to work as a nurse she did the opposite--that is, wanted her eyes placed straight in the distance while she wore base-in prism for reading at near.

Results of surgery for intermittent exotropia

The treatment results for intermittent exotropia are not as easy to assess as in other forms of strabismus treatment. In general, success is defined as converting an intermittent tropia to a phoria. Simply reducing the angle of a persisting intermittent tropia is not much help since the same sensory pattern, suppression when tropic, persists. In addition, the size can increase postoperatively.

A desirable, but also sometimes worrisome, early postoperative result is to convert an intermittent exotropia into a constant small angle esotropia. These patients experience diplopia postoperatively, which may be treated with patching for a short time or base-out prism if a longer period of treatment is needed. These overcorrections eventually revert to stable surgically corrected status in most cases. Any patient (or parent) must be alerted to the fact that diplopia from postoperative esotropia can be a good sign. These patients are also given full plus glasses if they have any hyperopia. Patients may also be given phospholine iodide to reduce accommodative convergence.

This treatment of the postoperative esotropia is continued for several weeks or months. If the esotropia with diplopia persists, it is treated with fully correcting Fresnel base-out prism on their present glasses or on plano loaner glasses which are provided. If neces-

sary, these may be replaced with permanent prisms. Prolonged prism treatment of overcorrected intermittent exotropia can produce excellent results. One patient who was initially undercorrected with bilateral lateral rectus recession had bimedial rectus resection as a second procedure that produced 14 prism diopters of esotropia postoperatively. She wore steadily decreasing base-out prisms for *three years* before reverting to orthophoria with normal stereopsis. Her father, a university professor of philosophy anxiously followed this long drawn out process, making it unforgettable. It is rare that a patient requires reoperation for overcorrection in cases where surgery has been done properly and ductions are full. However, incomitant esotropia occurring after surgery for intermittent exotropia, especially after recession and resection has been done, may require recession of a tight medial rectus muscle or advancement of a weak lateral rectus muscle.

Undercorrection of intermittent exotropia calls for reoperation based on the alignment with knowledge of the muscles previously operated. In general, if the laterals have been recessed less than maximum, they may be re-recessed. If the laterals have been recessed maximally, the medials may be resected, etc.

Convergence insufficiency

Convergence insufficiency intermittent exotropia is an entirely different situation. I have had some success in treating this with bimedial rectus resection, but in other cases results have been disappointing, with virtually no change in alignment after surgery even in cases where an early overcorrection occurred. The amount of bimedial rectus resection should be small and symmetrical, ranging from 4 to 6 mm. Some prefer a small recess-resect procedure to treat convergence insufficiency. Although this could cause the patient to assume a slight face turn at near to maintain comfortable single binocular vision while reading, the reward is that the patient *can* find an area of fusion because the deviation is incomitant.

Does intermittent exotropia progress to constant esotropia?

Intermittent exotropia can proceed to a constant deviation in some cases. This may be a reason to perform surgery in a timely manner. Perhaps in no other kind strabismus is the surgeon more obligated to make informed decisions ahead of time and to follow the patient diligently postoperatively instituting appropriate and timely re-treatment. It cannot be overstressed that these patients are completely normal during periods of alignment. The surgeon is obligated to remedy the condition occurring when the patient is abnormal but to leave undisturbed the alignment present during periods of normalcy. Herein lies the challenge of the surgical treatment for intermittent exotropia.

A professional football player who I examined had a large angle intermittent, nearly constant, exotropia at a routine eye examination. He was told that his eyes could be straightened. 'No, Doc', he replied, 'I like the way my eyes are because I can see people running up behind me.' At the next year's eye examination he said, 'Doc, could I catch a pass better if my eyes were straight?' When the answer was yes, he consented to have his eyes aligned surgically.

This story points out the plus of exodeviation, the enlarged binocular visual field. It also points out the downside of exodeviation, reduced binocular cooperation - fusion. Adults having surgical treatment of constant exotropia should be told that they will experience 'tunnel vision' with straight eyes, but this is transient.

Brown syndrome

Brown syndrome, characterized by a mechanical limitation of elevation in adduction, was originally described by H.W. Brown in 1950 as the superior oblique tendon sheath syndrome. Brown syndrome is now more broadly considered as an inability to fully elevate the eye in adduction, and to a lesser extent in the primary position and sometimes abduction. This is caused in most cases, but not exclusively by a restriction related to the superior oblique tendon and/or trochlea. Because of this, the chin may be habitually elevated to capitalize on normal binocularity in gaze down and toward the affected side. Brown syndrome is differentiated from inferior oblique palsy (which is rare) on the basis of restricted passive elevations on attempted elevation in adduction occurring in Brown syndrome. Brown syndrome can be unilateral or bilateral and may be associated with superior oblique overaction. Some patients with mild congenital Brown syndrome have normal head posture and are symptom free.

While originally thought to be due to a short superior oblique tendon sheath, the collective experience of many surgeons gained during surgical treatment of Brown syndrome has cast doubt on this etiology even to the point of denying that the superior oblique tendon even has a sheath. Instead of having a true sheath, the tendon passes obliquely through Tenon's fascia between the trochlea and the union of the superior oblique tendon with the capsule of the superior rectus before inserting into the sclera. This passage through multiple orbital fascial layers presents many opportunities for anomalous tissue relationships, but actual orbital facial abnormality as a cause of Brown syndrome is rare in my experience.

The mechanical restriction to elevation in adduction causing Brown syndrome may occur on a congenital unknown basis, after trauma, from iatrogenic causes, with a cyst of the tendon, and with inflammation (see page 232). In essence, Brown syndrome can result from anything that prevents the normal increase in the trochlear--superior oblique tendon insertional distance, even including mechanical restriction elsewhere on the globe.

Brown syndrome may have a hereditary basis in some cases. It has been reported in a parent and child and in siblings. I examined a young woman with Brown syndrome who stated that her maternal aunt and grandmother were similarly affected.

Acquired Brown syndrome caused by inflammation is usually associated with pain or tenderness in the area of the trochlea. Brown syndrome may also occur because of a painless cyst around the trochlea. Brown syndrome caused by a cyst or inflammation may be intermittent, recurrent, or episodic. Palpation in the area of the trochlea may reveal a cyst or tenderness typical of an inflammatory mass. In some cases a click can be heard, usually by the patient, with the 'click' occurring as the cyst or mass on the superior oblique tendon passes into or out of the trochlea. Such a click has been reported in an eye that had been enucleated! In this case, removal of the eye did not change the tendon-trochlea relationship sufficiently to stop the click. Brown syndrome from an inflammatory response can be treated with injection of soluble steroid into the trochlear area (but not into the trochlea). This can produce dramatic relief, but the Brown syndrome can recur, requiring repeat treatment. Fortunately, in most cases, inflammatory Brown syndrome is self-limiting. On the other hand, recurring Brown syndrome from a palpable cyst tends to persist. We have successfully treated such cases by excision of a cyst of the reflected tendon. Rao has reported Brown syndrome occurring from a parasite - worm - lodging in the trochlea. This worm has been confirmed by MRI. This condition responds favorably to antihelminthic treatment.

I have *not* exposed the trochlea itself in any surgery for Brown syndrome. Surgery for Brown syndrome is limited to the reflected tendon, up to but not including the trochlea.

Most Brown syndrome is idiopathic and congenital. Surgical treatment is indicated for the following: (1) chin elevation, (2) hypotropia in primary position, (3) diplopia, or (4) marked shutdown with adduction. As children with Brown syndrome grow taller, more of their world is straight ahead and below, meaning the implication of Brown syndrome is less. Patients with untreated mild congenital Brown syndrome are seldom bothered by this condition as adults. The same degree of acquired, especially iatrogenic, Brown syndrome usually causes bothersome symptoms in adults. Patients with congenital Brown

syndrome are in marked contrast to patients with Duane syndrome who tend to become increasingly troubled by their strabismus in adulthood, far out of proportion to what seems a minimal deviation while patients with congenital Brown syndrome are not particularly bothered as adults.

When treating congenital Brown syndrome surgically we do a 'cuffed' limbal incision, hook the superior rectus, and inspect the superior oblique tendon carefully, beginning at the insertion and continuing to the trochlear cuff. In most cases, in order to have better exposure, it helps to disinsert the superior rectus and replace it later. Forced ductions are repeated often during the process of identifying the tendon to determine the cause of limited elevation. The best treatment for congenital Brown varies according to the surgeon's experience and may be one of the least agreed upon aspects of strabismus surgery. This is not too surprising because freeing a mechanical restriction while simultaneously maintaining adequate rotations in all directions may be the strabismus surgeon's greatest challenge. Most surgeons believe that the least amount of surgery that will free ductions is the best. For example, one surgical option is disinsertion of the posterior seven-eighths of the superior oblique insertion at least as a first try. If this frees passive ductions at surgery, no more surgery is done. This works very well in a few cases, probably because the posterior-medial fibers of the tendon have mainly a vertical effect, but the procedure can fail with return of the Brown in spite of demonstrating free forced ductions at the conclusion of surgery. Other surgical options, all involving the superior oblique complex, include freeing the fascia surrounding the tendon, recession of the tendon, tenotomy near the insertion, tenotomy between the superior rectus and trochlea, and use of a silicone expander. All techniques have their advocates. The fact that there are so many choices leads to the undeniable conclusion that no specific alternative is the best for all cases.

Regardless of how the superior oblique is weakened, the risk of postoperative superior oblique palsy exists. Crawford found this frequently. Parks suggests simultaneous inferior oblique weakening to treat the presumed superior oblique palsy caused by superior oblique weakening to treat the Brown syndrome. However, Sprunger et al., found only a third of patients having superior oblique tenectomy for Brown syndrome had superior oblique palsy requiring inferior oblique weakening. They suggest doing inferior oblique weakening at a second procedure and only if needed.

Iatrogenic Brown syndrome results from excessive shortening the superior oblique tendon when treating superior oblique palsy with a resection or a tuck. It occurs because the distance between the trochlea and the superior oblique insertion cannot be

increased normally in upgaze during elevation in adduction. During a period of 10 years, I treated 59 patients with tuck or resection of the superior oblique. Nine of these 59 or 17% had a postoperative Brown syndrome so severe that a second surgery was needed to take down the tuck. Since that series of cases, I have learned about the wide variation in the superior oblique tendon, especially in congenital superior oblique palsy. With this knowledge, superior oblique tuck and resection are done on a more selective basis, being reserved for congenital superior oblique palsy with a loose or anomalously inserted tendon confirmed by the superior oblique traction test and reconfirmed at surgery.

Traumatic Brown syndrome is difficult to treat. The scarring associated with trauma in the area of the superior oblique tendon and trochlea is difficult if not impossible to totally eradicate to produce free movement because of the mechanical restriction which usually affects both up- and downgaze. Traumatic Brown syndrome coexisting with superior oblique underaction has been called canine tooth syndrome by Knapp. It is due to (1) local trauma restricting both upgaze and downgaze, (2) local trauma restricting upgaze and fourth nerve palsy restricting downgaze, or (3) iatrogenic Brown syndrome restricting upgaze and residual fourth nerve palsy restricting downgaze (Figure 13).

Before undertaking surgery for Brown syndrome, the surgeon must first confirm the diagnosis by demonstrating restricted forced ductions at elevation in adduction then:

1. Make sure there is a good reason for undertaking surgery, such as diplopia, hypertropia, or a bothersome head posture
2. Prepare the patient to have lowered expectations
3. Be ready for a possible second surgery, including treatment for iatrogenic superior oblique palsy, especially if a superior oblique tenectomy is done.
4. Do not weaken the inferior oblique at the first procedure.
5. Remember that the little people grow up, meaning that restricted upgaze could become less of a factor.
6. Apply any other good points that experience has taught.

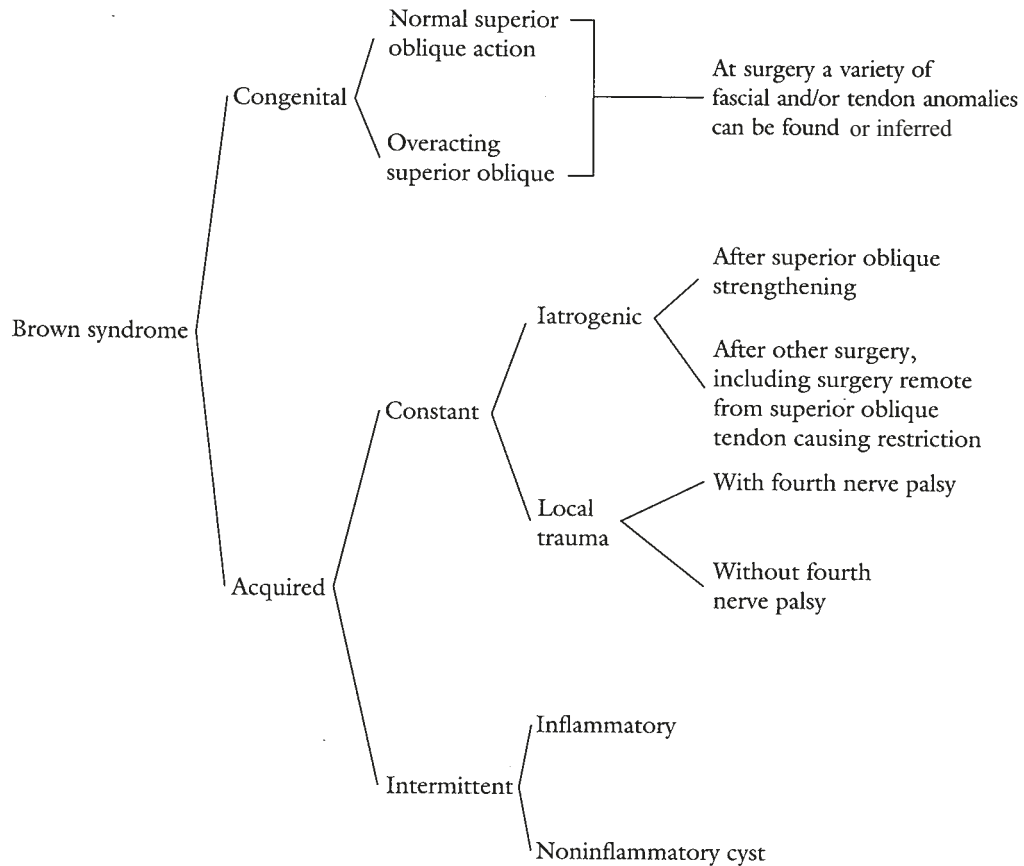


Figure 13 Scheme of Brown Syndrome

Duane syndrome

Duane syndrome, or Stilling-Turk-Duane syndrome, was described before the turn of the 20th century. It is characterized by limitation of abduction or adduction, narrowing of the fissure with enophthalmos, and face turn all of which vary according to the class of Duane. The etiology of Duane syndrome is agenesis of the sixth nerve nucleus in the brain stem on the involved side plus misdirection of the third nerve innervation to the medial rectus. This misdirected medial rectus innervation goes to the lateral rectus in the orbit. The sixth nerve nucleus pathology was found originally in an autopsy specimen obtained at his request from an ophthalmologist, Otto Pranjén, of the Mayo Clinic. Pranjén, who had Duane syndrome, willed his brain for study. Later, Miller and Green confirmed the third nerve misdirection. They found third nerve fibers intended for the medial rectus going to the lateral rectus in the orbit during post-mortem studies of a patient examined before death and confirmed to have Duane. Earlier, Huber had demonstrated co-firing of the medial and lateral recti with electromyography.

Duane syndrome has been classified by Huber according to alignment and ocular rotations into classes I, II and III.

- I. Marked limitation of *abduction* (or absence), normal or slightly defective adduction, narrowing of the palpebral fissure and retraction of the globe on adduction, widening of the fissure on attempted abduction with esotropia in the primary position, and head turn toward the involved side.
- II. Limitation or absence of *adduction*, exotropia of the affected eye, normal or reduced abduction, narrowing of the fissure on attempted adduction, often with upshoot or downshoot, and face turn toward the normal eye.
- III. Limited abduction and adduction, retraction of the globe, and narrowing of the fissure on attempted adduction with straight or nearly straight eyes in the primary position and often with upshoot or downshoot. There is usually no face turn.

It may be easier to keep the different types of Duane syndrome in mind by simply describing the primary position alignment. The majority of patients with Duane syndrome have an esotropia of the involved eye when the head is straightened. When the patient is allowed to assume the most comfortable head posture, the face invariably turns toward the involved

side and the eyes toward the opposite side. In most cases, these patients are able to recognize normal or near-normal stereopsis and rarely have amblyopia. Enophthalmos with fissure narrowing usually occurs in the involved eye only during attempts to extreme adduction. Abduction in the involved eye is typically just beyond the midline. Upshoot and downshoot are not a prominent feature.

Other patients with Duane syndrome are either orthotropic in the primary position or have an exotropia in the primary position. The primary position alignment seems to depend on the tightness or tone of the lateral rectus muscle. The tighter the lateral rectus muscle the less esotropic the patient (the straighter or more exotropic the involved eye), and the greater the enophthalmos on attempts at adduction in the involved eye. These patients with a tight lateral rectus are also more likely to have up and/or downshoot of the involved eye in adduction. This holds true except in patients who have a very large-angle exotropia with Duane syndrome. These patients can demonstrate simultaneous *abduction* when looking toward the sound eye. This is presumably due to the mechanical advantage assumed by the lateral rectus during co-contraction with the eye already widely exodeviated. This could be called class IV.

The upshoot or downshoot in Duane is not due to over- or undercorrection of the oblique muscles but is instead caused by a ‘taut wire’ effect with the eye either slipping above or below the midline under the influence of the extreme tension produced by medial rectus contraction against a co-contracting lateral rectus. The extreme type of exotropic Duane syndrome with simultaneous abduction was originally called ‘perversion’ of the extraocular muscles. It is more accurately described as simultaneous abduction. This condition is rare, but I have seen a half dozen cases.

Regardless of the variations in clinical appearance, all Duane syndrome patients appear to have a common etiology, just a varied expression. The condition seems to be slightly more prevalent in girls and in the left eye. It is usually unilateral but may be bilateral. In bilateral Duane the ‘rules’ for head position do not follow. Duane syndrome has been described as a genetic condition occurring in siblings and in consecutive generations. Duane syndrome is also associated with craniofacial-mandibular cleft anomalies including Goldenhar and Wildervanck syndromes. Children with Duane syndrome rarely complain. They are usually brought in for examination because of the head turn or strabismus, but often parents are really unsure about the specific problem. They simply suspect that there is ‘something wrong.’ On the other hand, adults with Duane syndrome often complain bitterly of asthenopia, intermittent diplopia, and a general feeling of being ill at ease.

Indications for surgery for Duane syndrome include strabismus in the primary position, unaccept-

able head posture, severe up- and downshoot of the affected eye in adduction, and severe enophthalmos. The most common type of Duane syndrome--the type with moderate esotropia in the primary position along with face turn toward the involved eye--is best treated with a small recession of the medial rectus of the involved eye. Other types of Duane syndrome are treated with the aim of aligning the eyes in the primary position. It is a good rule to avoid resection of the lateral rectus muscle in Duane syndrome. This can lead to worsening of enophthalmos and up- and downshoot. Some have advocated modified full tendon transfer of the superior and inferior rectus to the lateral rectus to increase the field of binocular vision. I have not done this procedure, but it has been done safely and there could be indications for doing this. When up- and downshoot are the main problems, it may be appropriate to recess both the medial and lateral recti of the involved eye and also the medial or lateral rectus of the fellow eye. Other techniques for treating the up- and downshoot include posterior fixation suture of the lateral rectus muscle to keep it from slipping upward and downward and also Y split of the insertion of the lateral rectus muscle (Table 14).

When treating Duane syndrome, it is essential to know and also to inform the patient that this condition cannot be eliminated; however, the signs and symptoms can be improved by appropriate surgery.

Practical classification of Duane syndrome

Esotropic Duane - Huber I

1. Esotropia with head straight
2. Face turn to involved side
3. Limited abduction
4. Near normal adduction
5. Mild enophthalmos and fissure narrowing on adduction (but may be severe)
6. Sensory examination usually normal

Exotropic Duane - Huber II

1. Face turn toward normal side
2. Limitation of adduction and no or minimal limitation of abduction
3. Marked upshoot and downshoot on attempted adduction
4. Enophthalmos and fissure narrowing on attempted adduction, usually with upshoot and downshoot
5. More likely to suppress

Straight Duane - Huber III

1. Limited abduction and adduction
2. Marked narrowing of fissure on attempted adduction with enophthalmos
3. Upshoot and downshoot on attempted adduction

<i>Diagnosis</i>	<i>Surgery</i>
Esotropic Duane I	Recess medial rectus on involved side* -- consider posterior fixation suture contralateral medial rectus
Esotropic Duane with severe enophthalmos I	Recess medial and lateral recti of involved eye, medial rectus recession or posterior fixation suture on contralateral eye if larger esotropia
Straight-eye Duane with up- and downshoot III	Recess medial and lateral recti of involved eye if enophthalmos severe; consider Y split of lateral rectus or posterior fixation suture of lateral rectus (both with or without recession)
Exotropic Duane II	Recess lateral rectus of involved eye; can add Y split; may require larger lateral rectus recession of uninvolved eye.
Simultaneous abduction IV	Recess both lateral recti; emphasis on the involved side; may need to resect medial rectus of involved eye

* Extraocular muscle transfer shifting the vertical recti adjacent to the lateral rectus insertion of the involved eye has been done and may be a viable option for mild esotropic Duane.

Table 14 Duane treatment guidelines

4. Straight or nearly straight head posture
5. Normal or near normal sensory examination

Simultaneous abduction - EMH IV

1. Large-angle exotropia
2. Face turn to uninvolved side
3. No adduction
4. Simultaneous abduction looking toward uninvolved side
5. Usually suppresses

Superior oblique palsy

Superior oblique palsy is the most commonly occurring isolated cranial nerve palsy seen by the strabismologist. However, I do not know of any reliable figures comparing the relative occurrence of fourth and sixth nerve palsies. Certainly, third nerve palsy is rarer than either fourth or sixth nerve palsy. In some practices, particularly those of the neuro-ophthalmologist, sixth nerve palsy may be the most common.

Superior oblique palsy can occur from trauma, congenital causes, a microvascular accident, and from a mass lesion. These etiologies are differentiated primarily on the basis of history with additional information obtained from physical and imaging findings.

Most common findings of Duane syndrome in 50 consecutive cases seen in consultation with ORBIS Telemedicine

Female	32/50
Left eye	25/45*
'V' pattern	21/50
Upshoot	24/50
Minimal amblyopia	6/50
I Head turn toward involved side	
II Head turn toward normal	
III Head posture straight	
IV Head turn toward normal	
Class I common	25/50
Class II nearly as common	16/50
Class III less common	8/50
Class IV rare	1/50
Hyperopia	23/50
Right eye	20/50
Bilateral	5/50

*excluding 5 bilateral cases

The fourth nerve nucleus is in the rostral part of the brain stem in the tectum. The nerve fibers emerge from the nucleus dorsally and decussate. The fibers then pass through the tentorium as delicate fibrils. They course into the orbit through the superior orbital fissure where they have as their sole purpose the innervation of the superior oblique muscle. These delicate fibrils are vulnerable to violent to-and-fro motion of the brain, such as occurs with a sudden deceleration in an automobile accident or similar head trauma.

Patient presentation

History. The patient or parents of the patient frequently either describe an acute event (such as a motor vehicle accident) that is likely to be the cause of a traumatic fourth nerve palsy or report a history of diplopia, asthenopia, or anomalous head posture, often present for many years or for life. Occasionally, old pictures demonstrating a head tilt and chin depression are useful in supporting the diagnosis of congenital superior oblique palsy.

Head posture. The usual head posture in superior oblique palsy is the head tilted to the opposite side with the chin depressed. Actually, the head moves where the eye cannot be moved by the paretic superior oblique. This is the rule when fusion potential is present in a person with incomitant strabismus. With the head in this posture, the eyes look upward and to the opposite side, completely out of (opposite) the field of action of the paretic muscle. In a very small percentage of patients, the head posture may be in the opposite direction, presumably to maximize the separation of diplopia and make it easier to suppress.

Torticollis. Neck contracture can occur in very young children with superior oblique palsy. However, neck contracture from superior oblique palsy does not occur before the child sits up and/or walks. The head tilt from superior oblique palsy does not occur with the child supine or prone but only when the child is vertically oriented, sitting, standing up or walking.

Motility. Versions are an extremely important part of the diagnosis of superior oblique palsy. The most tell-tale finding is inferior oblique overaction, and to a lesser extent superior oblique underaction, which occurs to varying degrees. Sometimes the superior oblique underaction is slight or undetectable.

Diplopia. Vertical diplopia is a common complaint in adult patients but rare in children. Asthenopia is also common in adults. This may take the form of *neck ache* while reading.

Chin depression. In the presence of a V pattern the chin is often down. This occurs with bilateral superior oblique palsy.

Cyclodiplopia. Spontaneous complaint of cyclodiplopia is a common sign of acquired bilateral superior oblique palsy. It also occurs in iatrogenic

Brown syndrome after superior oblique strengthening.

Double Maddox rod torsion. Seeing a tilted line on testing with double Maddox rod is very supportive of the diagnosis of superior oblique palsy. This usually means that the superior oblique palsy is acquired.

Overaction of the contralateral superior oblique. Underaction of the ipsilateral inferior rectus (so-called fixation duress because it is working against a contracted antagonist) and overaction of the contralateral superior oblique, its yoke, occurs in longstanding superior oblique palsy with contracture of the ipsilateral superior rectus.

Double Maddox rod torsion greater than 15 degrees. This is a strong indication of bilateral superior oblique palsy.

Bielschowsky head tilt test. This test is considered positive for superior oblique palsy when the vertical deviation increases with the head tilted toward the higher eye. If the Bielschowsky head tilt test reverses, then a bilateral superior oblique palsy is suspected. If the Bielschowsky head tilt test does not reverse but is reduced to no or very little hypertropia in the same direction on tilt to the side opposite the paretic superior oblique, a masked bilateral superior oblique palsy may be suspected.

Fundus torsion. Torsion may be noted during examination with the indirect ophthalmoscope. If the macula is rotated downward or clockwise in the left eye and counterclockwise in the right eye, so that the macula is below a line drawn parallel to the orbit floor and temporal from the lower disc margin, torsion can be inferred. This is confirmed if the macula is also shown to be roughly equidistant between the temporal arcades while in its lower position.

Inhibitional palsy of the contralateral antagonist. When the eye with the paretic superior oblique is used for fixation the yoke inferior rectus in the contralateral eye receives extra innervation. Its antagonist, the superior rectus and also the levator palpebrae on that side are inhibited resulting in hypotropia and more importantly, pseudoptosis. When the normal eye takes up fixation, the ptosis disappears.

Other indicators.

1. Diagnostic position prism and cover testing is more important for quantification of the deviation than it is for diagnosis.
2. Facial asymmetry is seen commonly in cases of *congenital* superior oblique palsy. The face is always fuller on the side of the paretic muscle. The reason for this is the abnormal head posture assumed to maintain single binocular vision.
3. Horizontal strabismus can occur in addition to the superior oblique palsy.
4. Amblyopia in the presence of congenital superior oblique palsy may indicate an abnormal or even absent superior oblique.

When the preceding considerations have been dealt with and when full measurements have been completed, especially prism and cover testing in the diagnostic positions, double Maddox rod testing, and the head tilt test, it is possible to diagnose, classify, and establish a treatment plan for a patient with superior oblique palsy.

Acquired superior oblique palsy

Patients with acquired unilateral palsy will usually have the following characteristics:

- A discrete history of onset
- Complaint of intermittent vertical diplopia
- Head tilt and chin depression with a comment, "I see better if I assume this head position"
- Measurable torsion with the double Maddox rod, less than 15 degrees
- A vertical deviation usually less than 20 prism diopters (deviation may be greater at near and in longstanding cases).

Bilateral acquired superior oblique palsy differs in that a 'V' pattern is the rule; single vision is more likely to occur in upgaze with chin down; Bielschowsky test is bilaterally positive; that is, right hyper with right tilt and left hyper with left tilt or the hyper may disappear or nearly so on head tilt to one side; and the Maddox rod frequently shows a cyclotropia of greater than 15 degrees.

Unilateral superior oblique palsy from a microvascular accident is usually much smaller amplitude than unilateral superior oblique palsy from trauma. These patients usually have a vertical deviation in the neighborhood of 5 to 10 prism diopters and are older, being more often in the seventh or eighth decade, and they complain of diplopia. They may not demonstrate a head tilt. These patients deserve a medical/neurological work up for hypertension, diabetes, etc.

In the operating room, patients with acquired superior oblique palsy, either unilateral or bilateral, will usually be found to have a normal superior oblique tendon on the traction test. The tendon is very easily felt, and the traction test is usually bilaterally symmetrical in unilateral disease.

Congenital superior oblique palsy

- There is usually no history of trauma.
- The condition is long-standing and characterized by a large head tilt and supported by family pictures showing a head tilt.
- In cases of absence of the superior oblique tendon, amblyopia and horizontal strabismus are common.
- Facial asymmetry is common in all types of congenital superior oblique palsy. The face is fuller on the involved side.
- There is frequently no torsion measured with the double Maddox rod.
- There are fewer complaints of diplopia in congenital compared to acquired superior oblique palsy.

In the operating room, patients with congenital superior oblique palsy are frequently found to have a lax superior oblique traction test (see page 97). At exploration of a superior oblique tendon that was found to be loose or lax with the traction test, an anomalous superior oblique tendon will be noted to be either too long, inserted in the wrong place, or absent.

Superior oblique treatment classification

Treatment is based on prism cover measurement findings, torsion, and the results of superior oblique traction testing indicating the state of the tendon. Hatched areas shown in the diagrams on the following pages represent the field of greater deviation and assume left superior oblique palsy. The pattern of deviation is the examiner's view.

The scheme described here is that proposed by Philip Knapp in 1971. It remains, with a few modifications, valid today (Figure 14).

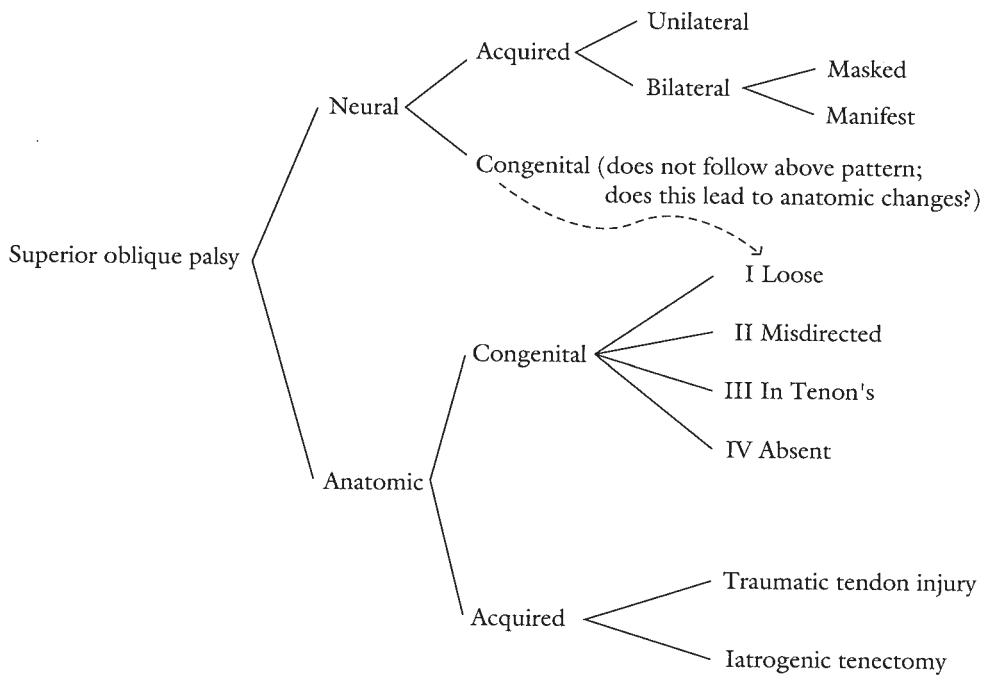
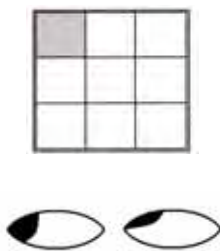


Figure 14 Superior oblique palsy -- scheme for etiology

Class I

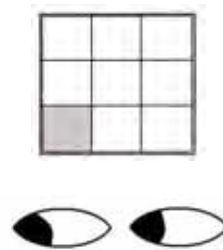
Knapp I--*overaction of antagonist inferior oblique* with deviation about 20 prism diopters or less in the field of action of the antagonist; this is a common pattern for both acquired and congenital superior oblique palsy

Surgery. Weaken antagonist inferior oblique. This is the 'safest' surgical procedure for any superior oblique palsy.



Class II

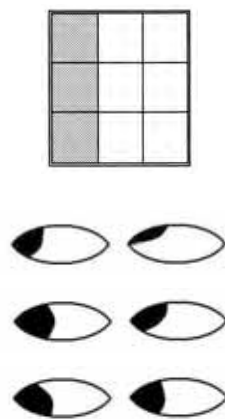
Knapp II--*underaction of the paretic superior oblique* with the deviation greater in the field of action of the paretic superior oblique seen mostly in smaller angle, acquired microvascular superior oblique palsy. This is best treated with prism and time. A larger angle deviation with this pattern can occur in congenital absence of the superior oblique tendon. If a pattern like this emerges in a congenital superior oblique palsy with facial asymmetry and pronounced superior oblique underaction, superior oblique traction testing followed by exploration of the superior oblique will lead to the appropriate surgical plan which could include superior oblique tuck, inferior oblique weakening, or yoke inferior rectus weakening depending on the angle and the state of the superior oblique.



Class III

Knapp III--In this class, the deviation is approximately equal in the field of the paretic superior oblique and the antagonist inferior oblique.

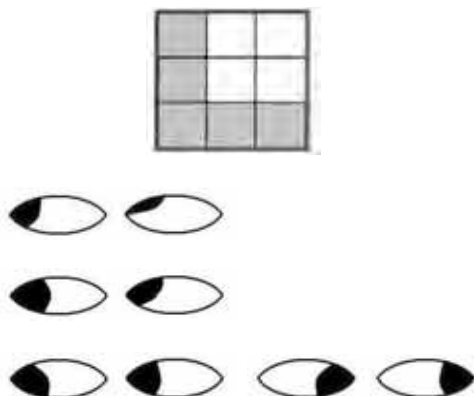
Surgery. If the deviation is less than 20 prism diopters in the field of greater deviation, only the antagonist inferior oblique weakening is done. If it is greater than 20 prism diopters and the superior oblique traction test reveals a lax tendon, and congenital superior oblique palsy is diagnosed, a tuck of the superior oblique can be performed; if the superior oblique tendon is tight, the yoke muscle, the contralateral inferior rectus, is recessed. If the surgeon chooses not to tuck the superior oblique tendon, even though lax, recession of the yoke can be done.



Class IV

This common pattern of hyperdeviation which is class III demonstrates a spread of hyperdeviation 'across the bottom' occurring because of tightness of the ipsilateral superior rectus.

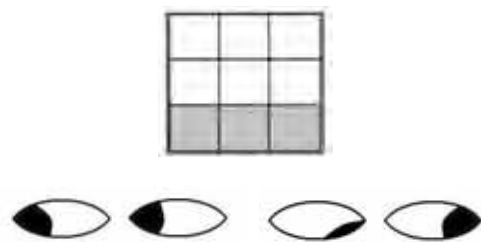
Surgery. If the deviation is 20 prism diopters or less, weakening of the antagonist inferior oblique and ipsilateral superior rectus is effective. If the deviation is greater, the superior oblique tendon can be tucked if it is loose or the yoke inferior rectus can be recessed if the superior oblique tendon is normal.



Class V

A hyperdeviation 'across the bottom' can be the pattern in a long-standing acquired superior oblique palsy pattern.

Surgery. If the vertical deviation is around 20 prism diopters, the ipsilateral superior rectus is recessed and either the superior oblique is tucked, the yoke inferior rectus is recessed or the ipsilateral inferior oblique is weakened. The recommendation to weaken the contralateral superior oblique along with a tuck of the involved superior oblique originally recommended by Knapp is a *bad idea*. Only a lax tendon should be tucked and be wary of weakening the normal superior oblique in a fusing patient!



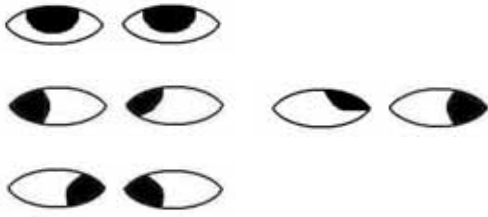
Class VI

Bilateral superior oblique palsy

This condition is characterized by:

1. History of trauma
2. Spontaneous torsional diplopia
3. Usually >15 degrees torsion with double Maddox rod testing
4. V pattern
5. Reversing Bielschowsky (or nearly reversing Bielschowsky) test

Surgery. There is little agreement among experts when it comes to surgical treatment of bilateral superior oblique palsy. Bilateral weakening of the yoke inferior obliques is favored by some to treat the 'V' and the torsion. Others do a bilateral recession of the inferior recti. The strength of either procedure is that the weakening is done on a normal muscle, one is a yoke and the other an antagonist. Bilateral weakening of the antagonist inferior obliques likewise treats the 'V' and the torsion, but depends on getting more out of a paretic muscle. Antero-lateral shift of the superior oblique (Harada-Ito) treats the torsion. For the 'V,' downshift of the medial recti can be done. The superior oblique tendon should not be tucked.



Class VII

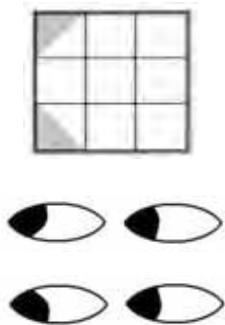
Brown syndrome with superior oblique underaction ('canine tooth')

This condition is characterized by:

1. History of trauma to the trochlea with mechanical restriction in upgaze and downgaze.
2. Trauma to the trochlea restricting upgaze and residual superior oblique palsy restricting downgaze.
3. Can occur as an iatrogenic Brown after superior oblique tuck with residual superior oblique underaction.

This problem is difficult to treat. My 'treatment' suggestions are:

1. None -- if eyes are aligned around primary
2. Yoke inferior rectus recession -- if ipsilateral hyper
3. Take down tuck, if caused by a 'too tight' tuck
4. Free superior oblique restriction if ipsilateral hypo



Congenital superior oblique palsy on an anatomic basis

When a congenital superior oblique palsy with an anomalous tendon is encountered first by finding a loose superior oblique traction test and then after the tendon is exposed, 'strengthening' of the tendon is carried out on the basis of what is found.

In 190 cases of superior oblique palsy treated by our group, 87% of those diagnosed as congenital had an anomalous superior oblique tendon. The majority of these had a redundant tendon that is class I anatomic superior oblique palsy. These are the superior oblique palsy patients who may be treated with superior oblique tuck or resection if the tendon is sufficiently loose or lax. A legitimate question is, "When lax tendons are found in cases of 'V' pattern congenital esotropia is this a form of bilateral congenital superior oblique palsy?" (Figure 15). Congenital 'anatomic' superior oblique palsy is always associated with a lax superior oblique traction test.

The patient with superior oblique palsy *must* be managed with a *comprehensive* program of diagnosis and treatment.

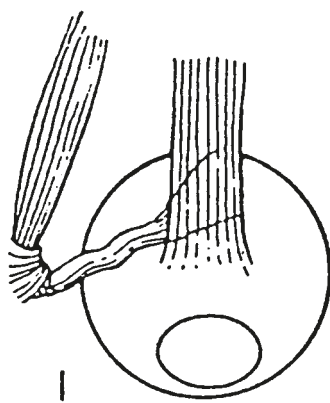
In summary, superior oblique palsy treatment consists of:

1. Fresnel prism for acute symptomatic microvascular fourth nerve palsy
2. Permanent prism for selected small-angle acquired small angle fourth nerve palsy
3. Surgery according to angle and pattern for unilateral *acquired* fourth nerve palsy; avoid superior oblique tendon tuck; an anterior transfer may be done if torsion is the main problem
4. In congenital superior oblique palsy with tendon anomaly surgery is concentrated on the antagonist, the yoke, and the lax superior oblique tendon.
5. The safest surgical procedure in any superior oblique palsy is weakening of the antagonist inferior oblique
6. In longstanding superior oblique palsy weaken a tight ipsilateral superior rectus if there is underaction of the ipsilateral inferior rectus and/or overaction of the contralateral superior oblique.
7. Bilateral superior oblique palsy can be treated with weakening of the yoke, weakening of the antagonist, and antero-lateral shift of the superior oblique.

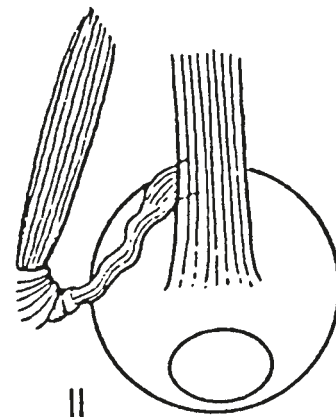
8. Be aware of the possibility of masked bilateral superior oblique palsy. If the Bielschowsky head tilt reverses, or nearly does, be suspicious. Either treat this as a unilateral superior oblique palsy and expect to do a second procedure or do two muscles on the more involved side and one muscle on the masked side according to the scheme presented.

Work-up of a patient with acquired superior oblique palsy should in most cases be kept to a minimum. The etiology is usually clear-cut trauma, well-

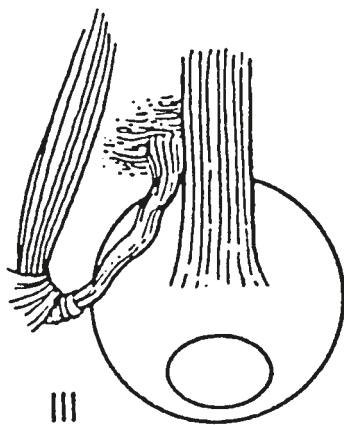
established congenital disease, or less clear presumed microvascular disease in an elderly individual. In the last instance, an evaluation by an internist for hypertension and/or diabetes is needed. Extensive imaging with CT or MRI or lumbar puncture and EEG studies *rarely* accomplish anything useful for the usual superior oblique palsy patient. In my opinion, extensive testing of the patient with fourth nerve palsy should be done *only* if indications other than the fourth nerve palsy itself are noted. By that I mean other significant neurologic signs or symptoms.



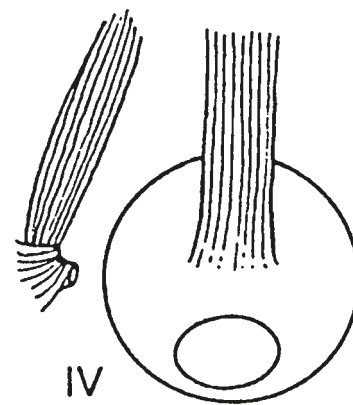
Class I. Redundant tendon



Class II. Misdirected tendon



Class III. Tendon in Tenon's



Class IV. Absent tendon

Figure 15

Description of the superior oblique tendon in 'anatomic' congenital superior oblique palsy.

TABLE I: PATIENT DEMOGRAPHICS AND PREOPERATIVE DATA FOR 190 CASES OF SUPERIOR OBLIQUE PALSY

Sex			
Male:	105		
Female:	85		
Age			
Range:		6mo-79yr	
Mean:		28.8+/-22.2 yr	
Mean for congenital group:		24.1+/-21.1 yr	
Mean for acquired group:		40.9+/-20.5 yr	
Refraction			
Mean:	-0.49+/-3.04 diopters		
Visual Acuity			
Mean:	20/25		
Median:	20/20		
Congenital/acquired			
Congenital:	137		
Acquired:	53		
Origin:	Trauma	29	
	iatrogenic	12	
	Vascular	7	
	Tumor	5	
Knapp Classifications			
Class I:	28		
Class II:	13		
Class III:	65		
Class IV:	53		
Class V:	5		
Class VI:	19		
Class VII:	1		
Class VIII:	6*		
Laterality			
Right:	92		
Left:	79		
Bilateral:	19		
Facial asymmetry			
Present:	56	51 congenital	5 acquired
Absent:	69	40 congenital	29 acquired
Unknown:	65	46 congenital	19 acquired
Abnormal head posture:			
Right tilt:	55		
Left tilt:	70		
Others (eg, head turn, chin down):	10		
No abnormal head posture:	39		
Unknown:	16		
Forced duction tests			
Tests performed:	161		
Tendon laxity:	95	83 congenital	12 acquired
No tendon laxity:	66	37 congenital	29 acquired

*Type VIII = comitant vertical deviation

Table 15

Patient demographics and preoperative data for 190 cases of superior oblique palsy. From Helveston EM, et al. Surgical treatment of superior oblique palsy. Transactions of the American Ophthalmological Society, Vol. XCIV, 1996, pp. 315-334. Used with permission.

TABLE II: SURGICAL PROCEDURES PERFORMED ^o	
Inferior oblique surgery: 177	
Myectomies and recessions: 175	
Anterior transpositions: 2	
Contralateral inferior rectus recession: 36	
Ipsilateral superior rectus recession: 32	‡
Superior oblique surgery: 50	
Superior oblique tuck: 26	
Superior oblique resection: 9	
Harada Ito procedure: 15	
Horizontal muscle surgery: 19	
Horizontal shifts of vertical recti or vertical shifts of horizontal recti: 3	
Number of surgeries: †	
Mean: 1.26±/0.61	
Range: 1-6	

^o When procedures were performed bilaterally, they have been noted only once.

‡ Number of times the patient went to the operating room, rather than number of different strabismus procedures performed.

Table 16

From Helveston EM, et al. Surgical treatment of superior oblique palsy. Transactions of the American Ophthalmological Society, Vol. XCIV, 1996, pp. 315-334. Used with permission.

Section 3

Chapter 6: Mechanics of surgery

Chapter 7: Recession of a rectus muscle

Chapter 8: Resection of a rectus muscle

Chapter 9: Surgery of the obliques

Chapter 10: Marginal myotomy: technique and considerations

Chapter 11: Faden operation (posterior fixation suture)

Chapter 12: Adjustable sutures: techniques for restriction

Chapter 13: Muscle transposition procedures

Chapter 14: Botox (Botulinum A toxin)

The mechanics of surgery

Techniques of exposure

Conjunctival incision

Overview

The conjunctival incision for strabismus surgery has two main requirements: 1) it should provide adequate exposure to the muscle(s) to be operated on, and 2) it should avoid excessive scarring and leave the conjunctiva in the palpebral opening white and smooth after healing has taken place. A technique for incising the conjunctiva satisfying the first requirement was devised by Swan who described doing extraocular muscle surgery *beneath Tenon's capsule*. With this technique, conjunctiva and anterior Tenon's capsule are incised isolating the muscle in the plane of *posterior* Tenon's capsule. This tissue layer makes up the intermuscular membrane and the muscle's capsule. Posterior Tenon's capsule is incised separately to expose sclera. This provides access to the muscle in a physiologic "compartment" lying between anterior Tenon's capsule and sclera. Swan's contribution was significant because it introduced a logical approach to the tissue planes around the rectus muscles. The drawback is that the Swan incision is made *over* the muscle's insertion and thereby in the palpebral opening where it could heal as a raised, reddened ridge.

The techniques currently used for conjunctival incision like that of Swan adhere to the principle of operating beneath anterior Tenon's capsule, but they differ in location of the initial incision through conjunctiva and in the degree of exposure of the muscle.

Techniques achieving suitable exposure of the extraocular muscles include the following:

1. Transconjunctival incision in the cul-de-sac (Parks)
2. Limbal incision in the palpebral opening
3. Retropalpebral transconjunctival incision
4. Superior 'cuffed' limbal incision

All of these techniques have in common an incision through *conjunctiva, anterior Tenon's capsule, and posterior Tenon's capsule* exposing bare sclera. Each

of these steps must be accomplished before attempting to engage the extraocular muscle on a hook. Once sclera has been identified, the tip of the muscle hook slightly indents sclera at the muscle border and is then passed gently behind the muscle insertion, or in the case of the inferior oblique, behind the muscle's belly. Any impedance of the passage of the hook behind the muscle insertion suggests that the hook is in the wrong plane. Clean engagement of the extraocular muscle on the muscle hook is necessary for the start of successful strabismus surgery

Start of the surgical procedure

Surgery on the extraocular muscles starts with the placement of a lid speculum between the lids for exposure to the front of the eye. A light, adjustable solid bladed speculum is ideal. A standard adult size is used for adults and a pediatric size for children (see Chapter 2). With the speculum in place, it is now possible to see the insertion of the rectus muscles through the conjunctiva in most cases. These appear beneath the conjunctival surface as a subtle elevation slightly darker than the surround. Rotation of the eye at this point enhances the view of these muscles and also in some cases the anterior ciliary vessels further delineating the rectus muscles. Seeing these muscle insertions aids in orientation for the placement of the incision, especially when the eye has undergone torsion as it sometimes does with general anesthesia. Next, it is important to perform forced or passive ductions in abduction, adduction, elevation and depression testing for restrictions. The superior oblique traction test is done if there is any question about laxity of the superior oblique tendon (see page 97).

Traction sutures

At this time traction sutures, usually 4-0 silk, are placed if that is the surgeon's choice. They are put in episclera at the 6 and 12 o'clock limbus for surgery on the horizontal recti and at the 3 and 9 o'clock positions for surgery on the vertical recti (Figure 1). A locking forceps, preferably curved, can be placed at the limbus at the appropriate position to achieve retraction and stabilization for surgery on any of the muscles (Figure 2).

Choice of incision

Limbal incision

The limbal incision provides the best exposure to *any* of the extraocular muscles but especially the rectus muscles (Figure 3A). This incision is easy to make and manage while working on the muscle. The disadvantages of this incision are: 1) it requires careful closure, 2) some bleeding can occur from episcleral vessels, and 3) a ridge can be seen at the limbus postoperatively if tissue edges have not been closed

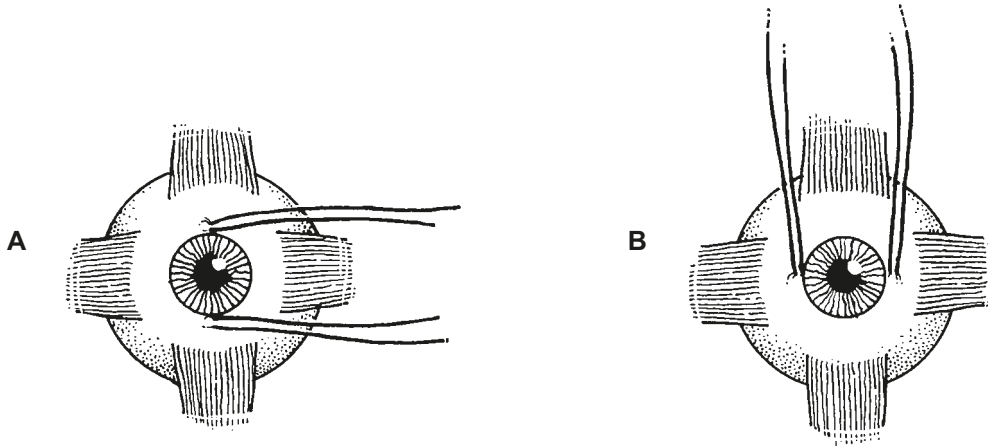


Figure 1

A Four-0 black silk sutures are placed in episclera at the 12 o'clock and 6 o'clock limbus for traction to rotate the eye medially or laterally for exposure with the limbal incision.

B Four-0 black silk sutures are placed in episclera at the 3 o'clock and 9 o'clock position to rotate the eye upward or downward for exposure with the limbal incision.

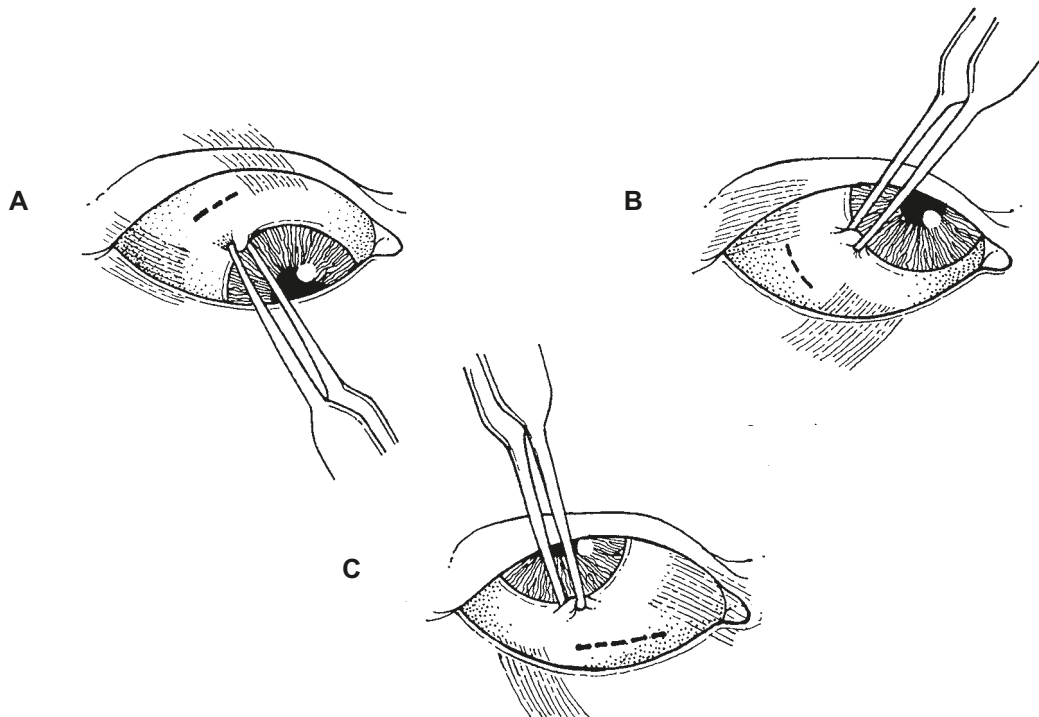


Figure 2

A locking forceps is placed at the limbus of the right eye grasping conjunctiva and episclera to rotate the eye:

A down and in to expose the superior temporal quadrant;

B up and in to expose the inferior temporal quadrant;

C up and out to expose the inferior nasal quadrant prior to the cul-de-sac incision to expose the medial rectus.

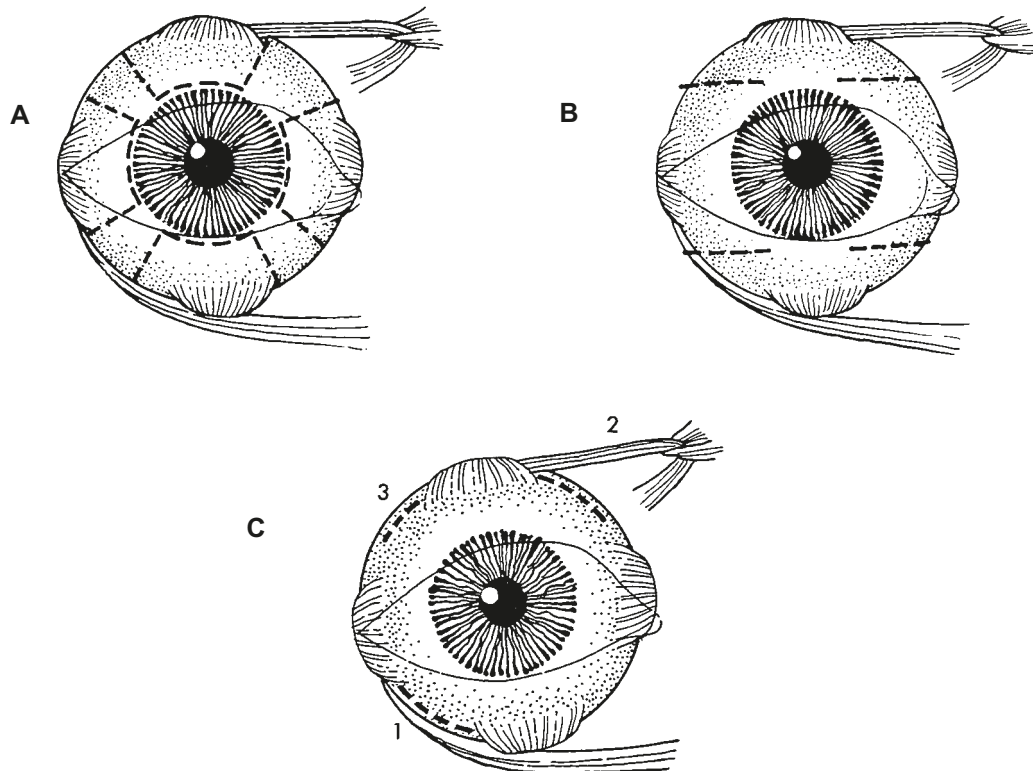


Figure 3

- A** The locations of the limbal incision for exposure of each of the rectus muscles.
- B** The locations of the cul-de-sac incision. The most useful one is in the inferior nasal quadrant for exposure of the medial rectus.
- C** Locations of the conjunctival incision for exposure of the oblique muscles: 1) inferior oblique, 2) superior oblique (trochlea) nasal to the superior rectus, 3) superior oblique tendon at the insertion.

properly. While these disadvantages may sound daunting, they can be managed easily with sufficient care on the part of the surgeon. Those who routinely use the limbal incision can manage the bleeding when it occurs and tend to become skilled at conjunctival closure. Above all, these surgeons appreciate the excellent exposure leading to what some believe is more accurate surgery. The limbal incision has the advantage of making postoperative handling of an adjustable suture much easier. This incision is also important in that it allows for removal of scarred and unsightly conjunctiva in some cases of reoperation, and most important the limbal incision allows for recession of tight, restrictive conjunctiva, with or without scarring, in cases of strabismus influenced by these mechanical factors.

Cul-de-sac incision

The cul-de-sac incision devised by Parks has the advantage of being hidden behind the lid. (Figure 3B) In addition, it usually requires no suture for closure at least inferiorly where it is used most. The patient may be more comfortable in the immediate postoperative period if no excessive swelling occurs

over the muscle. Disadvantages of the cul-de-sac incision are the following: 1) it is more difficult to perform; 2) exposure is less than with other incisions especially the limbal incision. The view with the cul-de-sac incision has been described as 'peek a boo;' 3) there is no opportunity for recession of the conjunctiva; 4) fragile conjunctiva such as is present in older* people can tear as the incision is stretched over the muscle's insertion; 5) postoperative handling of an adjustable suture can be more difficult.

After listing all of these disadvantages, it should be stated clearly that the cul-de-sac incision is ideally suited for use with recession of the medial rectus muscle in young children. The thick Tenon's capsule and healthy conjunctiva in the young stretch readily over the muscle insertion providing good exposure for surgery. At the conclusion of the procedure, the young firm tissue slides behind the lid and remains hidden completely if the procedure has been done properly. Observing such a patient immediately after surgery it may be difficult to detect that surgery has been done. This appearance changes slightly a few hours later when some swelling usually becomes

* In this case, 'older' can refer to patients as young as late teens or early twenties.

evident. Although the cul-de-sac incision can be used to expose the lateral rectus and is also used superiorly, the usefulness in these locations is far less than for exposure of the medial rectus, especially in the young.

Conjunctival incision for exposing oblique muscles

The conjunctival incision to expose the inferior oblique is made in the middle of the inferior temporal quadrant about 8 mm from the limbus. It is essential that this initial incision be *posterior* to the line of insertion of posterior Tenon's capsule that describes the spiral of Tillaux. An incision so placed goes through conjunctiva, anterior Tenon's capsule, and posterior Tenon's capsule (intermuscular membrane) exposing bare sclera after which the inferior oblique can be seen as it passes in posterior Tenon's capsule.

A similar conjunctival incision can be made just medial to or just lateral to the insertion of the superior rectus, but also posterior to the insertion of posterior Tenon's capsule to expose the superior oblique medial to the superior rectus, near the trochlea, or at the insertion of the superior oblique (Figure 3C).

Conjunctival incision and reoperation

Reoperation can be done after either a limbal or a cul-de-sac incision. The ease of re-operation in either case depends more on the care exercised by the original surgeon and the particular nature of healing in the individual than on the type of incision.

- The ideal conjunctival incision should have the following characteristics:
1. Minimal scar in the palpebral opening after surgery
 2. Adequate exposure
 3. Ease of performance
 4. Absence of excessive adhesions between Tenon's capsule, muscle sheath, and sclera
 5. Ease of reoperation
 6. Able to allow relaxation of restrictive scar tissue
 7. Allows excision of excessive scar tissue
 8. Postoperative comfort
 9. Allows for postoperative adjustment when called for.

Unique characteristics of each extraocular muscle in terms of initial exposure after the conjunctival incision

Each of the rectus muscles has its own special characteristics or 'personality.' The surgeon should have knowledge of this in advance for the best chance of success at any surgical undertaking.

Medial rectus

Of the rectus muscles, the medial rectus inserts closest to the limbus. In the esotropic patient this distance can vary from 3.0 to 6.0 mm with the stated normal being 5.5 mm. This variation in insertion site, along with the fact that there seems to be no relationship between the distance of the insertion from the limbus and the angle of esotropia in esotropic patients, is a reason for measuring medial rectus recession from the limbus rather than the original insertion. The medial rectus has no other muscle or orbital fascial structure associated with it other than the intermuscular membrane to stop its retraction back into the orbit when it is detached. For this reason, the medial rectus is the most likely of any of the rectus muscles to fall back into the orbit if a suture breaks causing what is referred to as a 'slipped' or 'lost' muscle.

When looking at the orbital surface of the medial rectus muscle, the origin of anterior Tenon's capsule can be seen as it joins the medial rectus capsule. Just outside of anterior Tenon's capsule, toward the medial orbital wall, is the medial rectus pulley. If a hole is made in the undersurface of anterior Tenon's capsule at this point fat will prolapse. It is also possible with more dissection to disengage the medial rectus from its pulley. Disruption of fat is to be avoided! This can cause unwanted adhesions and worse. Muscle immersed in fat after surgical intervention can result in the muscle dissolving! Surgeons differ in their approach to the intermuscular membrane when operating on the medial rectus. Minimal dissection of the tissue seems to be the best choice in my opinion. In summary, surgery on the medial rectus should be carried out anterior or distal to the origins of anterior Tenon's capsule with avoidance of any fat prolapse. The surgery should avoid disruption of the pulleys unless this is a stated aim as might be so with a muscle transfer procedure. Minimal dissection of intermuscular membrane should be carried out unless there is a specific reason to do otherwise.

Superior rectus

This muscle is located farthest from the limbus of the rectus muscles and has the broadest insertion. It is, in my experience, the most difficult of the rectus muscles to engage on the muscle hook, especially when introducing the hook from the temporal side. It is common to unintentionally split this muscle inser-

tion. When attempting to hook the muscle from either side, especially temporally, be certain to identify bare sclera posterior to the insertion of posterior Tenon's capsule. Once engaged on the muscle hook, it becomes clear that fat is not likely to be encountered, even with intermuscular membrane dissection more than 10 mm posterior to the superior rectus insertion. The superior oblique tendon is fused to the undersurface of the superior rectus by a common 'capsule'. If this connection is not severed it should reduce the effect of a large recession of the superior rectus done for treatment of dissociated vertical deviation. This is disputed by some who claim the superior rectus remains recessed the very large (intended) amount in spite of not being freed from the underlying superior oblique. Recession of the superior rectus can cause retraction of the upper lid and widening of the palpebral fissure and, conversely, resection of the superior rectus can cause forward movement of the upper lid and narrowing of the palpebral fissure.

Lateral rectus

The lateral rectus muscle is easy to hook and is usually found, as stated in anatomy books, 6.9 mm from the limbus. On the lower border of the lateral rectus and about 12 mm from the muscle's insertion the anterior corner of the inferior oblique insertion is found. This is an important relationship. Surgery on the lateral rectus, either recession or resection, can result in inadvertent inclusion of the anterior fibers of the inferior oblique which attach along the lower border of the lateral rectus. This usually goes unrecognized at the time of surgery. The result is an unexpected postoperative hypodeviation, hyperdeviation or exodeviation or a combination of these. Simply freeing this attachment at reoperation does not always cure the problem. It is best to avoid the complication by making sure that the inferior oblique is not included.

Inferior rectus

This muscle is very easy to engage on a hook and is usually found where it should be, 6.5 mm from the limbus. Overlying the inferior rectus about 10 mm behind the insertion is a thick mass of fascia which comprises Lockwood's ligament with the inferior oblique included. This tissue is also connected to the lower lid retractors. In addition at one or sometimes both inferior rectus borders about 10 mm from the insertion are found large vortex veins lying on sclera. These may be seen for several millimeters on sclera before going through Tenon's capsule and into the orbit. The relationship of the inferior rectus with Lockwood's is especially important when dealing with thyroid ophthalmopathy patients requiring large inferior rectus recession. Some surgeons dissect intermuscular membrane well posterior to Lockwood's, even encountering fat, in order to achieve a large inferior rectus recession with minimal

lower lid retraction. Others place a suture in this tissue tying it forward on the globe to keep Lockwood's and the lower lid retractors forward and thereby reducing the retraction effect on the lower lid. The unique relationship of the inferior oblique and inferior rectus may contribute to 'destabilization' of the inferior rectus-scleral union causing this muscle to 'slip' after it has been detached and reattached at surgery. This occurs far more frequently with the inferior rectus than other rectus muscles. A less important but nonetheless present occurrence is the elevation of the lower lid with narrowing of the fissure with inferior rectus resection.

Inferior oblique

The inferior oblique is engaged in the inferior temporal quadrant through an incision made just anterior to the mid portion of the distal half of the muscle. The belly of the inferior oblique is embedded in Tenon's capsule and must be shelled out. This is not difficult, but care must be exercised to avoid splitting the muscle. At the mid portion of the exposed muscle a large vortex vein is seen exiting sclera and entering the orbit passing through Tenon's. This is a nearly 100% occurrence. Exposure of the inferior oblique is helped by triangulating the opening by placing a muscle hook behind both the lateral and inferior rectus muscles and then using a retractor to pull back the posterior edge of the conjunctival incision with Tenon's included. Inferior oblique anatomy is quite reliable although there have been reports of cases of bifid insertion.

Superior oblique

The superior oblique muscle is not seen during strabismus surgery but can be seen in some cases of medial orbitotomy. Neither is the trochlea seen except for the cuff of tissue where the superior oblique tendon exits. It is the 30 mm tendon of the superior oblique that is dealt with during strabismus surgery. This tendon can be extremely variable in its site of insertion, tension, and even presence! Absence of the superior oblique tendon, while not common, is the most frequently noted absent extraocular muscle (tendon). Most cases where the superior oblique tendon is encountered in surgery are cases of superior oblique underaction or palsy. A superior oblique traction test done before an incision is made will give strong evidence of a tendon anomaly. Since there is the chance of significant variation with the superior oblique either contributing to underaction as in superior oblique palsy or rigidity as in Brown syndrome, good exposure is required. For this reason it is a good idea to consider a superior limbal incision to achieve a thorough look at the superior oblique tendon. An even better idea is to do the cuffed superior limbal incision which is described on page 176. For successful superior oblique tendon surgery a good rule is to obtain good exposure and to expect the 'unexpected.'

Parks cul-de-sac incision

The cul-de-sac incision of Parks is carried out behind the usual position of either the upper or the lower lid. This procedure may be accomplished medially or laterally, superiorly or inferiorly. The illustrations show the incision being made inferiorly and nasally in preparation for surgery on the right medial rectus muscle viewed with the patient upright. The rationale for this approach is that the space beneath posterior Tenon's capsule provides access to the rectus muscles posterior to the line of rectus muscle insertion (spiral of Tillaux) for 360 degrees. Shift of the incision which is behind the lids to over the muscle's insertion is possible because the conjunctiva and anterior Tenon's capsule are relatively mobile tissue planes. At the conclusion of an eye muscle operation done with the cul-de-sac incision, the incised tissue should slide back completely behind the lid. This procedure is designed to offer an improved appearance. Drawbacks of the cul-de-sac incision include inability to recess the conjunctiva and anterior Tenon's capsule, limited exposure of the extraocular muscles, and greater difficulty. However, in instances where good assistance is available and when it is not necessary to recess the conjunctiva, this procedure can be performed effectively. The surgeon must compare these advantages with the greater versatility of the limbal incision along with greater ease of performance.

The cul-de-sac incision for medial rectus surgery is made approximately 4 mm below the limbus (Figure 4). It extends 8 mm medially from the junction of the middle and medial thirds of the cornea, stopping just short of the base of the plica. A snip incision is made through the conjunctiva and anterior Tenon's capsule. A second snip incision through intermuscular membrane exposes bare sclera. A small segment of anterior and posterior Tenon's capsule may be excised at this point. The tip of a large muscle hook is placed on bare sclera and the hook is guided upward along bare sclera until it is beneath the medial rectus muscle or the rectus muscle intended. The hook is then drawn toward the limbus to engage the muscle at its insertion. A large Green's hook with a 3 mm tip at right angles at the toe of the hook may be placed behind the rectus insertion to keep it from slipping off. A second large muscle hook is placed beneath anterior Tenon's capsule and is guided superiorly over the original hook. The second hook is then moved back and forth over the first hook to free the fine attachments between anterior Tenon's capsule and the muscle sheath. During this maneuver the muscle, in its sheath, lies between the two hooks.

The second muscle hook, having loosened the fascial connection between anterior Tenon's capsule

and the muscle sheath, is used to retract anterior Tenon's capsule and the conjunctiva upward (superiorly), exposing the tip of the first muscle hook, which is now seen at the superior border of the muscle. A snip incision through the intermuscular membrane with scissors may be required to fenestrate the intermuscular membrane, exposing the tip of the Green's (or equivalent) muscle hook. The intermuscular membrane is dissected from the muscle borders according to the surgeon's preference. With the muscle exposed, sutures may be placed for a recession procedure. If a resection is planned, an additional muscle hook or muscle clamp must be inserted to expose the tendon and muscle posteriorly. It is customary to use one double-arm suture when carrying out recession of a rectus muscle using the cul-de-sac incision, although two single-arm sutures can be used. After suture placement for recession, the muscle should be severed from the globe. It is essential to use two fixation forceps, preferably the curved self-locking type, at the corners of the insertion to stabilize the globe and keep the incision centered over the operative site. It is useful to place the first locking forceps on the stump of the insertion when half of the muscle insertion is cut free. This allows the assistant to stabilize the globe when the muscle is cut entirely free. At the conclusion of the procedure, the conjunctiva and anterior Tenon's capsule are allowed to relax and slide back to the original incision site behind the lid. When performed properly, this procedure results in a very benign appearance of the eye in the immediate postoperative period because the lower lid hides the incision.

An inferior incision may be closed with interrupted, absorbable sutures or it may be left unsutured. A superior incision is usually closed because of the possibility of prolapsed Tenon's capsule hanging down in the palpebral space. The cul-de-sac incision does not allow for conjunctival recession but can be used for reoperations where conjunctival recession is not indicated. In infants and young children with healthy conjunctiva and Tenon's and where the conjunctiva is not restricted, I have used the cul-de-sac incision routinely. I have also used this incision for re-recession of the medial rectus in both adults and children. It has been suggested that by leaving the perilimbal conjunctival circulation undisturbed, the cul-de-sac incision could reduce the incidence and severity of anterior segment ischemia after rectus muscle surgery. A diffuse but benign subconjunctival hemorrhage occurs in about 10% of cases after the cul-de-sac incision.

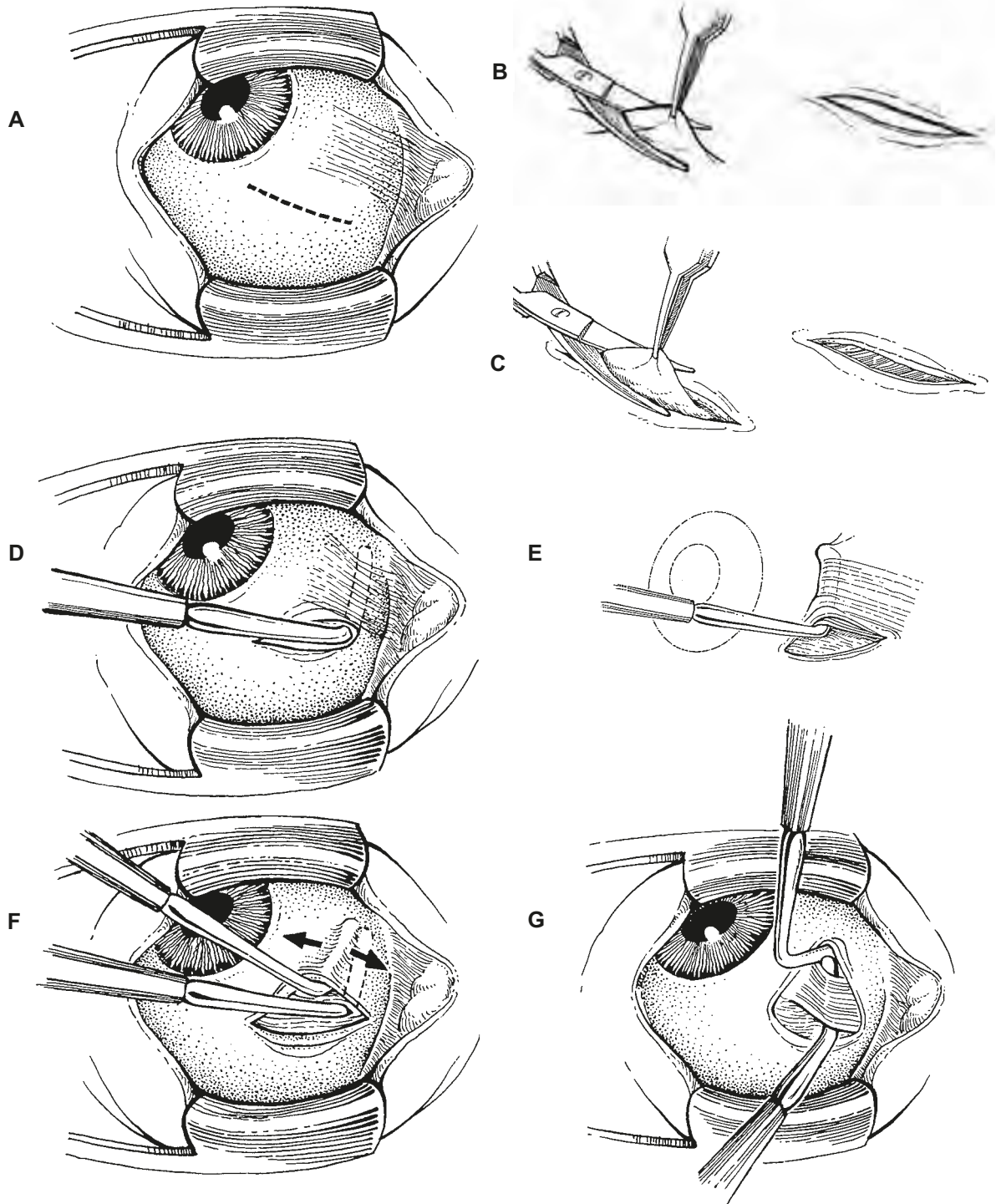


Figure 4

- A** The site of the inferior cul-de-sac incision for approaching the right medial rectus muscle
- B** The conjunctiva is tented and scissors cut down through the conjunctiva, anterior, and posterior Tenon's to bare sclera.
- C** The initial incision can include only conjunctiva. With forceps grasping anterior and posterior Tenon's these tissues are tented up and excised.
- D** A muscle hook enters the incision and with its tip slightly indenting sclera the hook passes beneath the rectus muscle.
- E** The initial hook may be replaced with a Green hook that has a prominent tip. Any muscle hook with a knob at the tip is suitable for this maneuver.
- F** A second hook is placed in the incision but on top of the muscle. It is moved back and forth to free the muscle in its capsule from overlying anterior Tenon's capsule. This motion should extend several millimeters anterior to the muscle insertion.
- G** The muscle hook that was used to separate the muscle from anterior Tenon's capsule is then used to pull the conjunctival incision over the tip of the muscle hook that is engaging the muscle.

continued.

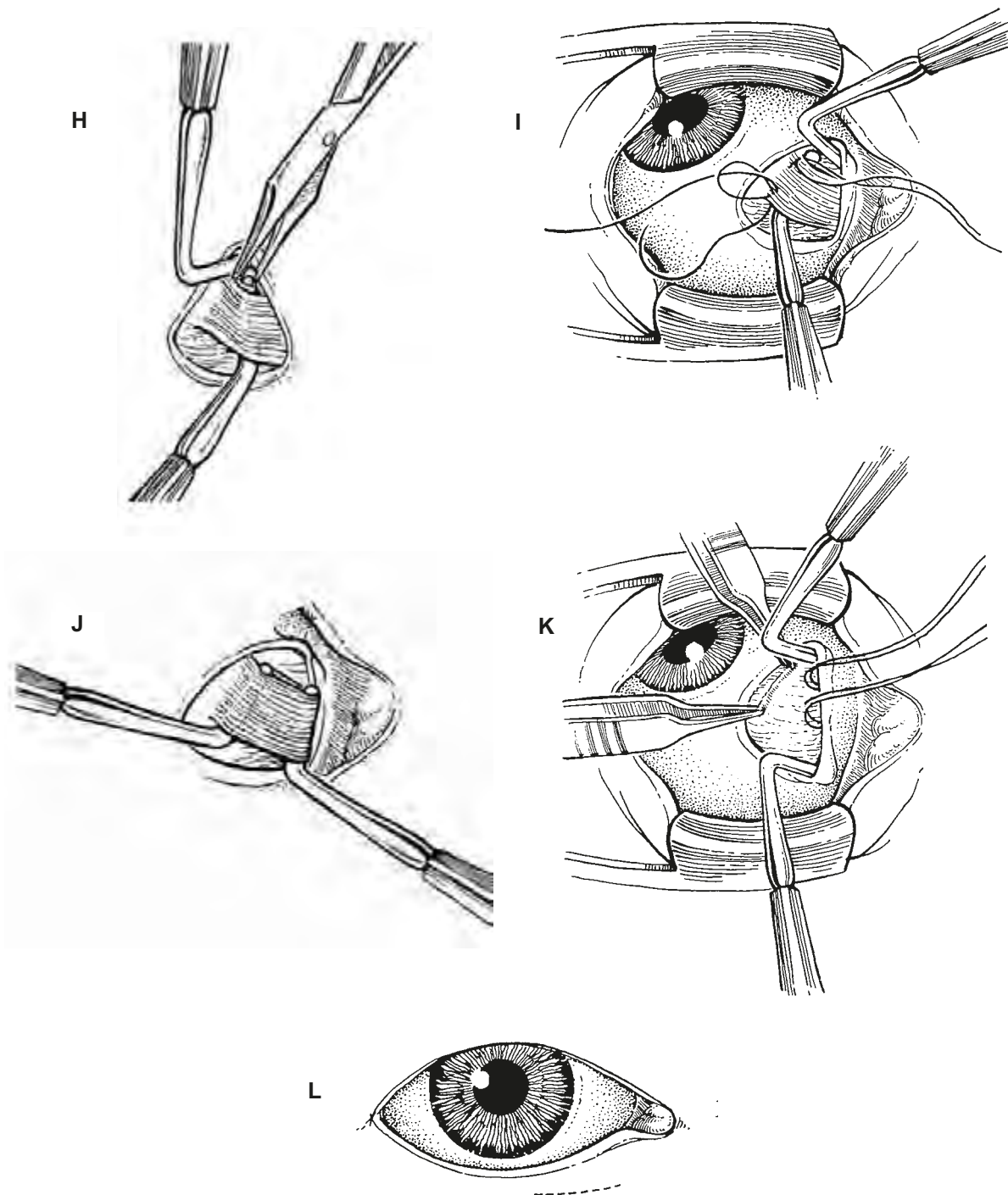


Figure 4, cont'd

H A small snip through intermuscular membrane exposes the tip.
I With the muscle so exposed and after sufficient dissection of the intermuscular membrane at the border of the muscle, sutures are placed. If a resection is to be performed, a second hook under the muscle exposes sufficient muscle tissue to allow placement of sutures for resection.

J Putting a second hook under the muscle provides better exposure.
K The muscle is completely detached after curved locking forceps are placed on the stump, the first when half of the muscle is freed and finally the second just before the last fibers are cut.
L The location of the incision when the eye and lids are in the physiologic state.

Limbal incision

The limbal incision in the conjunctiva for surgical exposure of the rectus muscles is probably the easiest to perform and the most versatile of the exposure techniques for strabismus surgery. Wide exposure of the muscle and adjacent sclera with the incision placed directly over the area of surgical activity makes suture placement in the muscle and needle placement in the sclera easier than with the cul-de-sac incision. When muscle transfer or insertion shift is done up or down, this wide exposure is especially beneficial. The relaxing incisions may be extended 10 mm or more without penalty because the additional length of these incisions is hidden behind the lids. The limbal incision also enables the surgeon to carry out conjunctival recession or conjunctival excision of scarred tissue when necessary and also debulking of anterior Tenon's capsule in selected cases. A drawback of this procedure is that an incision is made in

the palpebral opening. If this incision is not closed very carefully with a smooth approximation of the conjunctiva - anterior Tenon's capsule layer with the limbus, an unsightly ridge could result. This ridge can also cause inefficient wetting of the peripheral cornea resulting in dellen formation. The neophyte strabismus surgeon should, in my opinion, learn the limbal incision first.

The site of the limbal incision for medial rectus surgery is centered at the insertion of the rectus muscle and extends 2 to 3 clock hour positions. The fusion of conjunctiva and anterior Tenon's capsule is grasped with fine-toothed forceps and tented up, and subanterior Tenon's capsule is entered with a No. 15 Bard-Parker blade (Figure 5) scissors may also be used as shown (Figure 5B). This blade incision is a puncture, not a dissection. The blade should not dig into the episclera or sclera. Scissors should be used

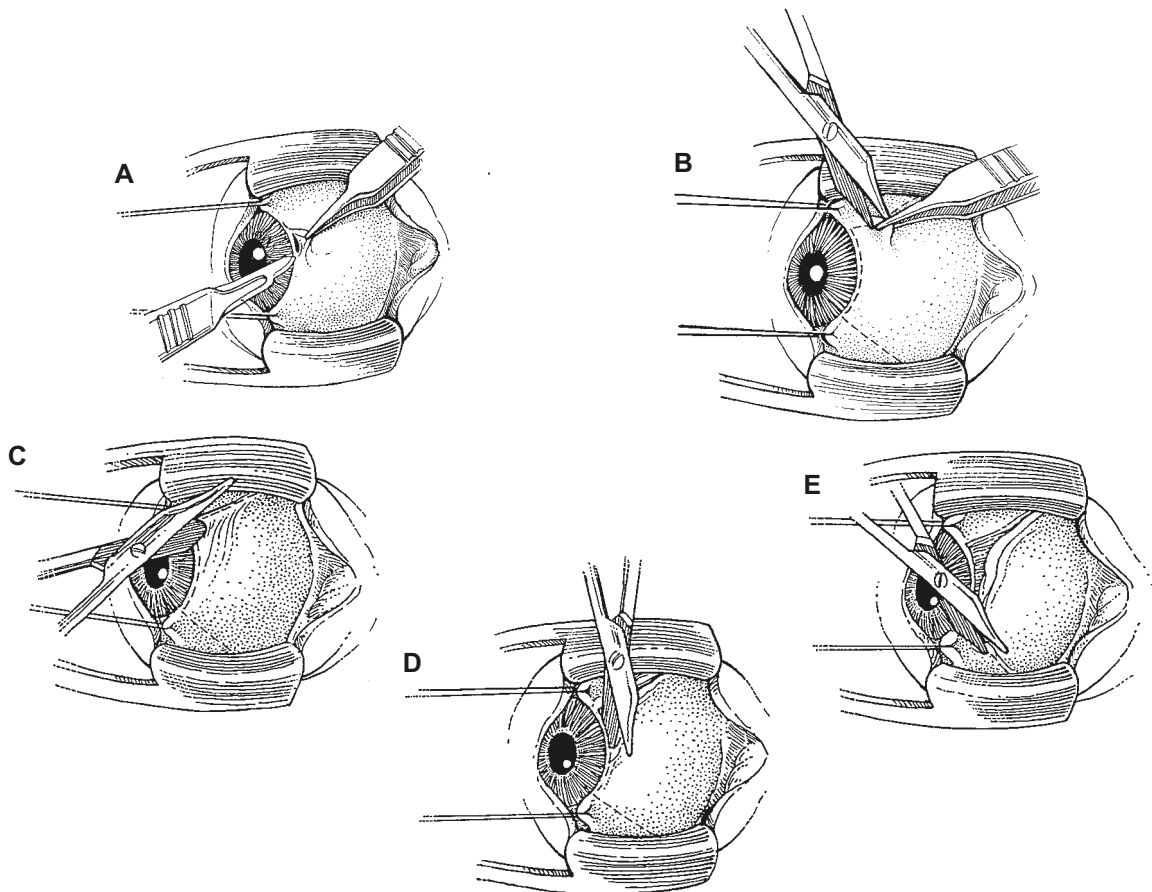


Figure 5

- A** The conjunctiva at the limbus is tented and a sharp blade passes beneath anterior Tenon's capsule.
- B** Scissors may be used to initiate the limbal incision. The conjunctiva is tented and the scissor tips cut down along the line of the radial incision through conjunctiva and anterior Tenon's capsule.
- C** First, the radial incision is made,
- D** then the limbal incision,
- E** and then the second radial incision.

to extend one relaxing incision. Scissors are then used to complete the limbal peritomy and then the second radial relaxing incision is made. These relaxing incisions are carried to but not through the plica when the incision is made medially. Scissors and sharp dissection are used to sever the attachments between the muscle sheath and the undersurface of anterior Tenon's capsule. Bare sclera is exposed at one or both borders of the muscle's insertion by piercing the intermuscular membrane at each edge of the muscle's insertion (Figure 6). It is imperative that bare sclera be identified during this maneuver to allow smooth passage of the muscle hook behind the insertion of the rectus muscle. Dissection of the muscle capsule itself should be avoided and the muscle should remain in its capsule. Failure to maintain this technique produces unnecessary bleeding.

When bare sclera is identified at each border of the muscle, a muscle hook is passed easily behind the insertion. It is also acceptable to pass the muscle hook behind the insertion after exposing bare sclera at one border and 'cut down' on the tip of the hook at the

other border. Care should be exercised to avoid forcing the hook past or through an incompletely dissected plane. The intermuscular membrane is dissected from the borders of the muscle and the attachments between the muscle sheath and the undersurface of anterior Tenon's capsule are dissected according to the surgeon's preference. Sutures are placed and the muscle is recessed as shown (Figure 7) or the intended procedure is done. The limbal flap is closed at the apices with interrupted 8-0 absorbable sutures. An additional suture may be placed in each of the radial incisions.

The limbal flap may be recessed 5 mm using three sutures. Two of the sutures join the tips of the flap at the base of the relaxing wing incisions, and the third suture secures the center of the flap to the superficial sclera or the muscle stump. The knot securing the conjunctival flap at the limbus may be buried by passing the needle from beneath the conjunctiva at the limbus, and then from the conjunctival surface on the flap, and finally tying the knot down tightly so that it slides under conjunctiva.

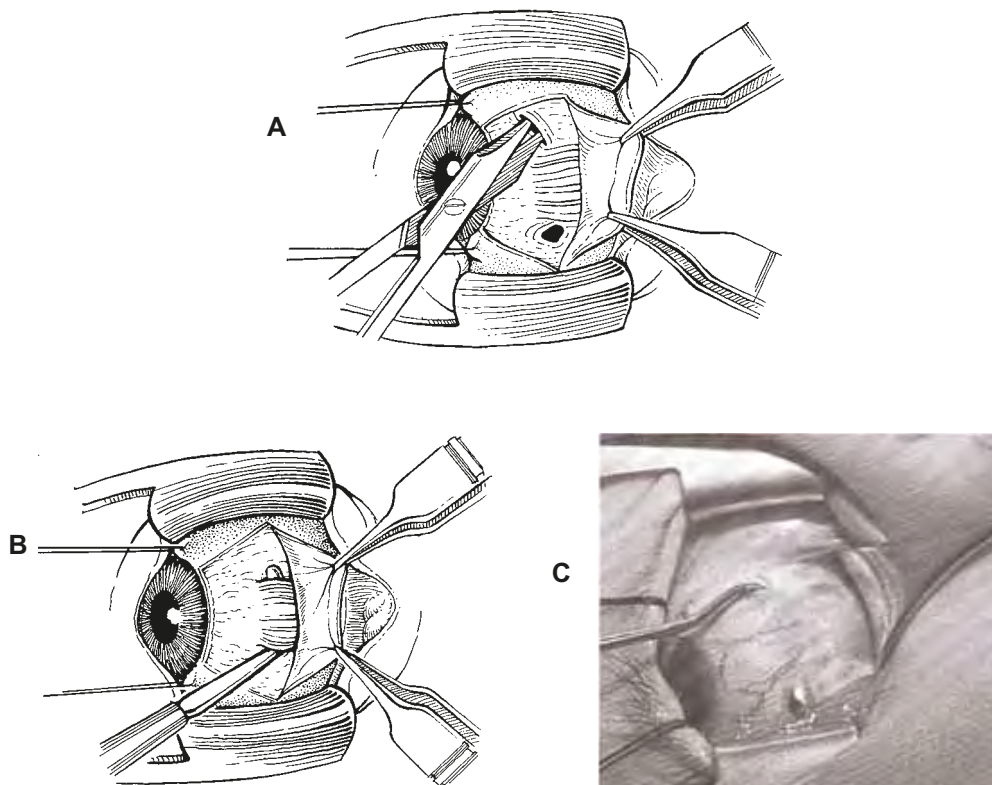


Figure 6

A The conjunctiva-anterior Tenon's flap is retracted and scissors are used to penetrate posterior Tenon's capsule exposing bare sclera at each muscle border.

B A muscle hook is passed behind the muscle insertion.

C Shown here at surgery

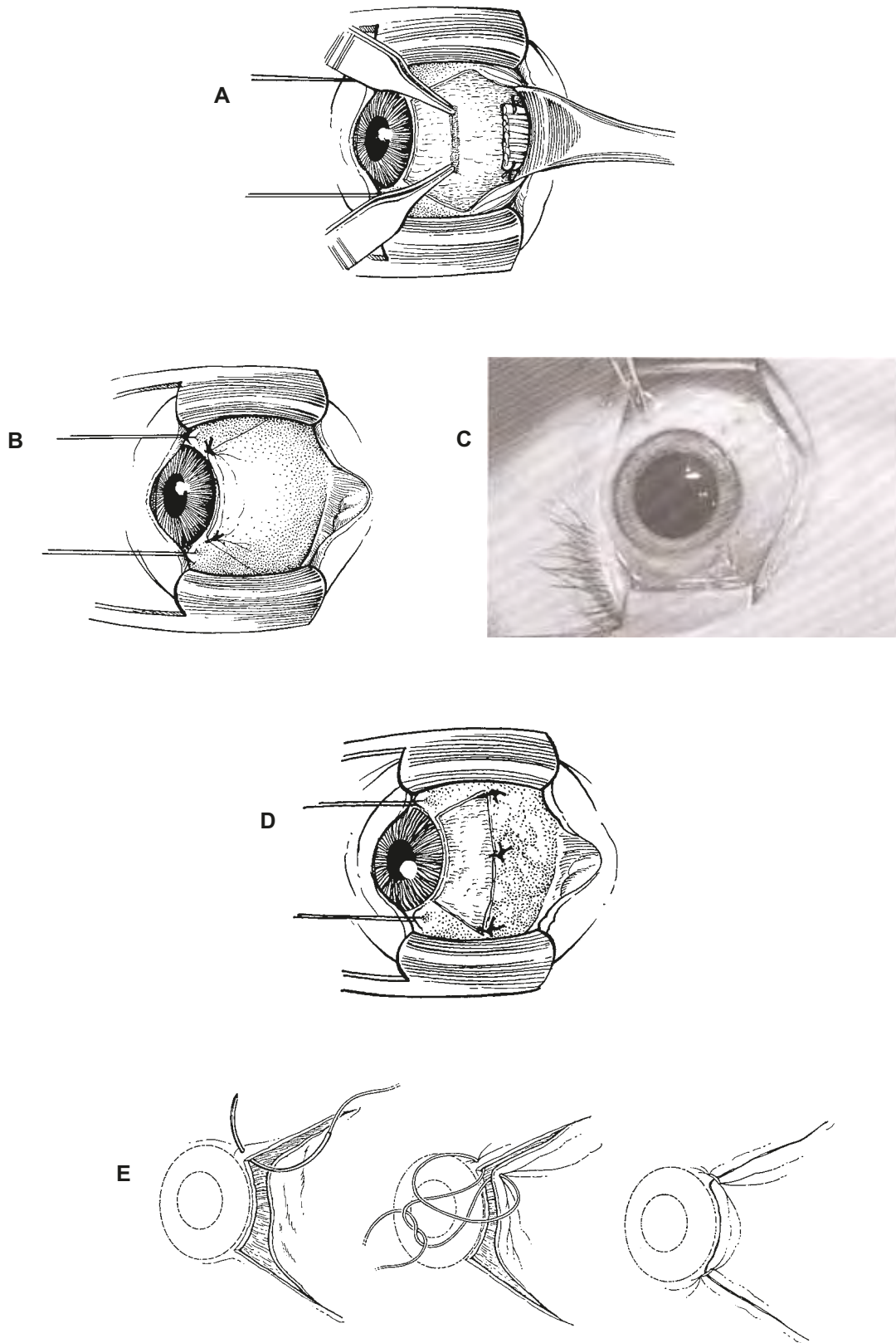


Figure 7

A After suture placement the muscle is recessed (or the intended procedure is completed) and the surgical site is observed.
B The incision is closed with fine absorbable suture joining the corners at the limbus.

C Shown here at surgery.
D The conjunctiva may be recessed.
E The sutures may be placed to bury knots for more comfort in the immediate postoperative period.

Incisions for exposing the obliques

Exposure of the oblique muscles (tendon in the case of the superior) can be obtained effectively by using a tranconjunctival incision behind the lids (Figure 8). When one is making this incision, it is imperative to make it approximately 8.0 mm from the limbus to ensure that the subposterior Tenon's space will be entered. When operating on the inferior oblique, an effective technique is to hook both the lateral and the inferior rectus muscles and retract conjunctiva-Tenon's before hooking the inferior oblique. When operating on the superior oblique, the superior and medial rectus muscles may be hooked before hooking the superior oblique. In cases where the superior oblique is to be exposed prior to a strengthening procedure or in cases of Brown syndrome, I use the 'cuffed' limbal incision in order to carry out a more orderly exploration of the superior oblique tendon, which is frequently anomalous in congenital superior oblique palsy.

The incision for exposure of the superior oblique tendon medial to the superior rectus is begun

at the medial aspect of the insertion of the superior rectus muscle (approximately 8 mm from the limbus) and extends through the conjunctiva, anterior Tenon's capsule, and intermuscular membrane for 8 mm medially, concentric with the limbus. The incision for exposure of the superior oblique tendon at its insertion is begun at the lateral corner of the superior rectus insertion (approximately 8.5 mm from the limbus) and extends through the conjunctiva, anterior Tenon's capsule, and intermuscular membrane laterally for 6 mm, concentric with the limbus. The incision for exposure of the inferior oblique is made 8 mm from the limbus, is approximately 8 mm long, and is centered in the inferior temporal quadrant, concentric with the limbus. The incision is carried through the conjunctiva, anterior Tenon's capsule, and intermuscular membrane to bare sclera. The incision for a combined procedure on the lateral rectus and inferior oblique is a standard limbal incision that is extended inferiorly one additional clock hour.

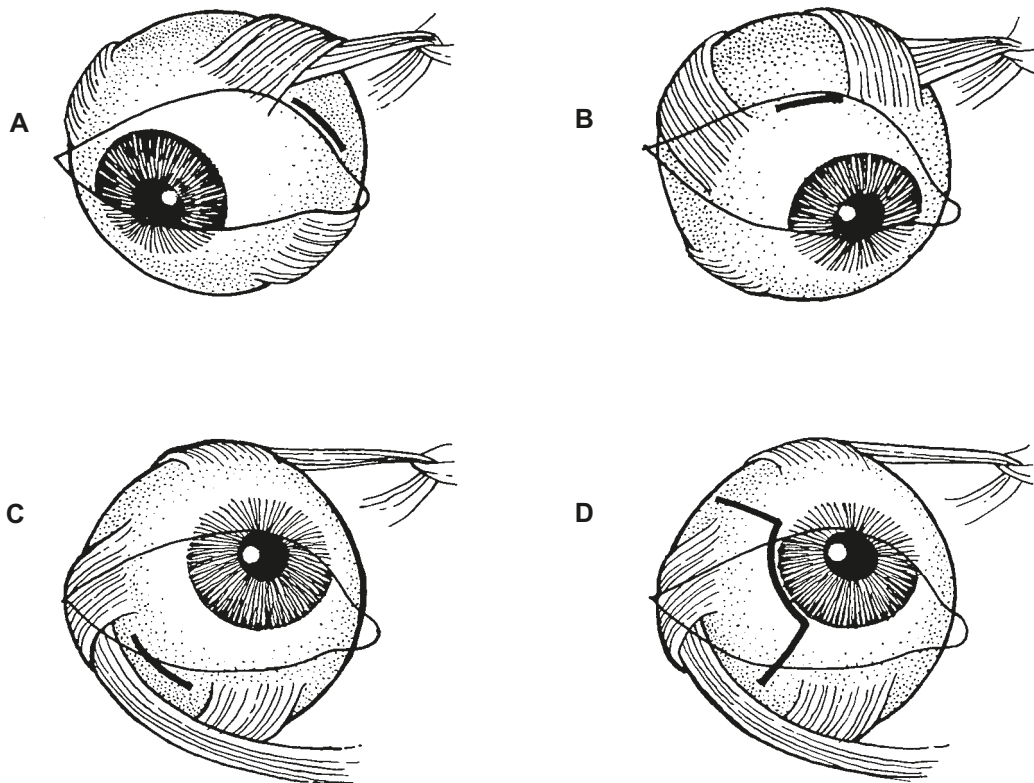


Figure 8

- A Location of the conjunctival incision to expose the superior oblique medial to the superior rectus
- B Location of the conjunctival incision to expose the superior oblique tendon at its insertion
- C Location of the conjunctival incision to expose the inferior oblique
- D An enlarged limbal incision to expose both the lateral rectus and inferior oblique

Obtaining improved exposure

Improved exposure can be gained by enlarging a limbal incision as needed.

A new retractor designed specifically for extraocular muscle surgery is called the Barbie. This was named in reference to the popular Barbie doll when a scrub nurse suggested that the new retractor looked like something Barbie could use to flip a hamburger. The Barbie retractor comes in three sizes and

they are regular 7 mm, large 9 mm, and extra large 11 mm wide respectively. Each have a blade length of 15 mm.

This retractor is designed to replace the bulky Desmarres (vein) retractor and the heavier ribbon or maleable retractors - both 'borrowed' from general surgery (Figure 9).

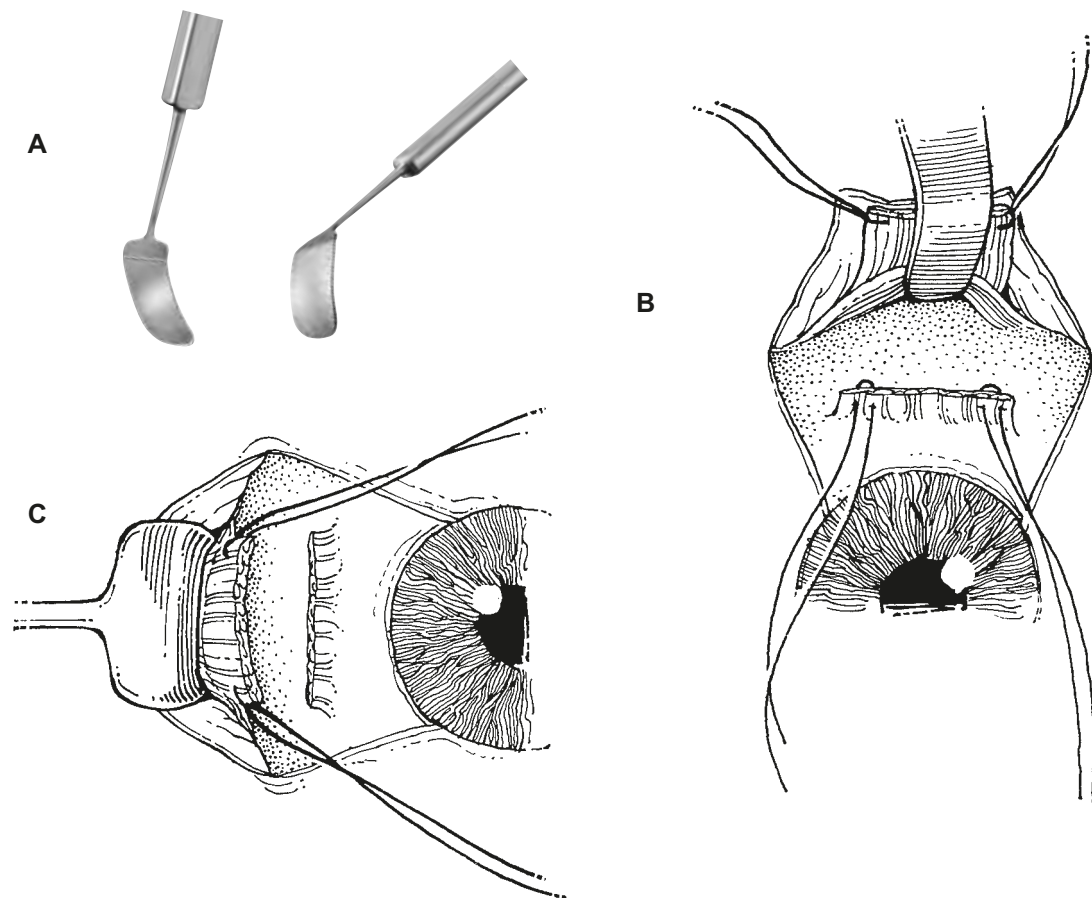


Figure 9

A The Barbie retractor

B A ribbon-maleable retractor elevating the superior oblique tendon and superior rectus

C A wide Desmarres retractor retracting Tenon's and conjunctiva over a horizontal rectus muscle

Cuffed superior limbal incision

The superior limbal quadrant differs from the other 270 degrees in that it is less distinct and is traversed by multiple fine blood vessels going from the conjunctiva to the cornea. This quirk of anatomy makes it more difficult to achieve a clean limbal incision superiorly and it also leads to peripheral opacification of the superior cornea when a standard limbal incision is done. To avoid this complication the cuffed limbal incision can be made. This consists of a curvilinear incision in conjunctiva about two mm above the superior limbus. The incision should be

about 4 to 5 clock hours centered over the superior rectus. Two lateral 'wing' incisions are made for 6-8 mm as in the standard limbal incision and surgery is carried out in the usual way. The incision is closed meticulously with several interrupted 8-0 absorbable sutures with the knot buried. This incision heals in just a few days with virtually no trace of surgery having been done. It is possible that the 'molding' effect of the upper lid as it moves over the incision line contributes to this healing effect (Figure 10).

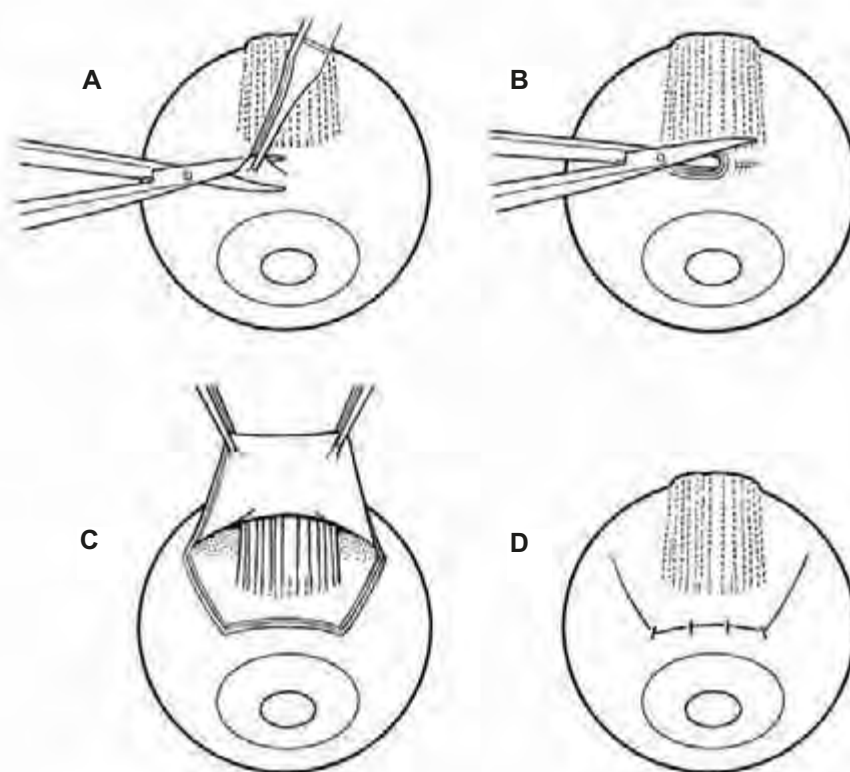


Figure 10

- A** The initial conjunctival incision is made temporally at the 10 o'clock right eye and 2 o'clock meridian left eye 2 mm posterior from the limbus.
- B** The incision is continued through conjunctiva and anterior Tenon's for 4 or 5 clock hours leaving a 2 mm cuff on the limbal side.
- C** The incision is carried out in the usual manner for the limbal incision exposing the superior rectus and later the superior oblique tendon if that is the aim.
- D** The cuffed limbal incision is closed with several interrupted absorbable 8-0 sutures with the knots buried.

Recession of a rectus muscle

Overview

Measured retroplacement or recession is the standard technique for weakening a rectus muscle. However, the term weakening or reducing the effect of a muscle may be a misuse of terms. Instead, retroplacement of a rectus muscle provides a new *starting place* or static alignment for the eye. In this new position, the muscle's attachments to both anterior and posterior Tenon's capsule, the muscle pulleys, and adjacent structures continue to affect both static and dynamic factors in eye movement. The muscle's effect on the globe is mediated through these attachments as well as through the muscle's scleral insertion. Unless the rectus muscle is recessed excessively, placing the new insertion behind the equator along with extensive Tenon's dissection, the muscle's action will not be compromised significantly in its field of action.

Both saccadic velocity and generated force will be the same after the usual recession. Excessive recession, either by design as in special cases or as a complication, will result in decreased excursion of the globe in the field of action of the muscle. These large recessions can be used when treating patients with conditions such as; fibrosis syndrome, third nerve palsy, thyroid ophthalmopathy, nystagmus, or with a variety of complicated reoperations, and in the case of a slipped or lost muscle. Underaction occurs not because of any change in the contractile power of the muscle, but because of the alteration of mechanics of the muscle-Tenon's-globe relationship. A muscle inserting behind the equator of the globe will not exert its full effect on globe rotation on a purely mechanical basis.

Excessive recession

In addition to underaction, excessive recession of the medial rectus will produce a widened medial palpebral-canthal area. Excessive recession of the inferior rectus causes ptosis of the lower lid resulting

in vertical widening of the palpebral fissure. Excessive recession of the superior rectus can cause retraction of the upper lid and a widened palpebral fissure. The unique relationship of the inferior rectus to Lockwood's ligament and the inferior oblique causes the inferior rectus, after recession, to be prone to both early and late posterior migration (slippage). This results in undesirable overcorrection-hyperopia, underaction of the muscle, and lower lid ptosis.

To avoid this complication, the inferior rectus should be securely reattached to the globe. The problem of lower lid ptosis after inferior rectus recession can be reduced if not completely eliminated by taking two precautions. First, the intermuscular membrane (posterior Tenon's capsule) dissection should be carried back 10 to 14 mm posterior from the inferior rectus insertion. In most cases this maneuver requires careful dissection to a point several millimeters posterior to the entrance of the vortex veins. These are found on one or both borders of the inferior rectus. These tortuous dark red veins, 1 mm in diameter, are visible lying on sclera traveling for 5 mm or more before piercing posterior Tenon's capsule and entering the orbit. Vortex veins bleed briskly if cut. *Do not cut or tear them!* If this happens, pressure should be applied and then the veins cauterized after bleeding has slowed. Second, the attachments of Lockwood's ligament to the inner surface of the inferior oblique should be dissected carefully to the same level as the dissection of the intermuscular membrane. All of this dissection is carried out without exposing fat. Another technique for avoiding lower lid ptosis is to mark the relationship of Lockwood's ligament to the inferior rectus before dissection and muscle recession and then to suture Lockwood's to the inferior rectus in the same relative position after recession as it was before - effectively pulling the lower lid forward and upward.

Recession of the superior rectus has recently been modified in some cases by use of excessively large recessions to treat large-angle dissociated vertical deviation. Although in the past it was considered dogma to restrict vertical rectus recession to relatively smaller amounts, such as 5 mm or less, some surgeons now believe that excessive recession of the superior recti, usually via hang-back recession, is both safe and effective. This raises the question: Where does the superior rectus reattach when a hang-back recession is done? It has been shown clearly that the firm attachment of the superior oblique tendon to the undersurface of the superior rectus theoretically limits the extent of superior rectus retroplacement when using the hang-back technique. In order to truly 'hang back' the superior rectus muscle, it seems the surgeon should detach the superior oblique tendon from the undersurface of the superior rectus. Even with this accomplished, the surgeon cannot be assured that the superior rectus will remain recessed to the degree that the hang back implies. Hang-back recession of as great as 15 mm from the insertion or approximately 5 mm behind the equator has been claimed. Because of the attachment of the superior rectus to underlying superior oblique this amount of recession can be seen with the eye rotated downward. However, when the eye rotates back to the primary position, the superior rectus moves closer to the insertion along with the attached superior oblique tendon. Recessions of the superior rectus muscle by measured recession or by the hang-back technique that exceeds 5 or 6 mm could result in limited elevation. But since this surgery is usually done for dissociated vertical deviation (DVD) in patients who have effective suppression the resulting incomitance does not lead to diplopia and the limitation of supraduction is not significant.

Recession of the lateral rectus is more or less limited by the insertion of the inferior oblique found 12 mm from the lateral rectus insertion. However, in hang-back recession, or in excessive recessions of the horizontal recti carried out to treat nystagmus, this limit may be exceeded with the new lateral rectus inserted at or behind the anterior edge of the inferior oblique insertion. For the usual strabismus surgery, the lateral rectus is recessed from a minimum of 4 to 5 mm to a maximum of 8 to 10 mm. Recession of the lateral rectus in excess of 8 to 10 mm can result in some limitation of abduction.

Recession of the lateral rectus can be complicated by inadvertent inclusion of the inferior oblique. This complication can be reduced if not eliminated if the surgeon is certain that the inferior oblique is not brought forward when hooking the lateral rectus and second by carefully inspecting the lateral rectus reinsertion site and removing any inferior oblique fibers or intermuscular membrane that may be pulling the inferior oblique forward.

Recessions measured from?

The question, "Where should a rectus muscle recession be measured from?" has not been answered fully. Gillies and McIndoe advocated the use of axial length measurement to produce more accurately dosed surgery. This approach certainly makes sense on two counts. First, a smaller axial length means a smaller globe, which in turn means that theoretically more effect is produced per millimeter of recession. Second, knowing the axial length allows the surgeon to know where the equator of the globe is and, therefore, to recess the muscle maximally with more precision and still avoid excessive recession.

Since 1974, I have used the limbus as the reference point for medial rectus recession. The globe undergoes a more or less orderly enlargement with age in patients with refractive errors ± 4.00 D or less. The corneal diameter also increases in a predictable way and that is why we choose the corneoscleral limbus as a reference for medial rectus recession. A maximum recession of 10.0 mm from the limbus is performed on eyes of infants under 6 months of age, 10.5 mm under 1 year, and 11.5 mm on eyes of patients over 1 year (Figure 1). In addition to providing a standard of measurement related to globe size and, therefore, adhering to geometric factors, measurement from the limbus is a convenient way to avoid using the variable medial rectus insertion site as the reference for recession measurement. We found the medial rectus insertion site to vary from 3.5 to 6.0 mm with an average of 4.4 mm in a group of esotropic patients. In these patients there was no relationship between the medial rectus insertion site and the angle of strabismus.

Our initial motivation for using the limbus was that an all too common result of surgery for infantile esotropia in the 1960's and 1970's was undercorrection. To reduce this unacceptably high percentage, which resulted in nearly 50% of surgically treated esotropia patients requiring a second operation after bimedial recession, surgeons gradually began increasing the amount they recessed the medial rectus while still measuring from the insertion. The largest medial rectus recession as measured from the limbus for many surgeons had been 5.0 mm in the 1960's. This amount gradually was increased to 5.5 mm, 6.0 mm, and finally 7.0 mm. By ignoring the insertion site of the medial rectus and using instead the limbus as a reference, I decided to establish for my surgery a maximum and a minimum recession. A recession of 8.5 mm from the limbus, which was determined to be the minimum, could actually be a maximum recession if the medial rectus was inserted 3.5 mm from the limbus and if the surgeon used 5.0 mm as the maximum medial rectus recession. The strategy of medial rectus recession measured from the limbus has resulted in fewer patients having an unintended under

recession and resultant undercorrection. By measuring from the limbus when recessing the medial recti, more than 80% of patients treated by me for infantile esotropia with a bimedian recession have a residual strabismus (almost entirely esodeviation) of less than 10 prism diopters, and just fewer than 10% require surgery for early postoperative undercorrection.

Does the amount of shortening of the muscle, or rather the amount of shortening of the distance the muscle travels from origin to the new insertion site, dictate the postoperative effect of the muscle? Are the sarcomeres more lax and less vigorous in their effect on rotation of the globe? The lack of postoperative change in saccadic velocity and generated muscle force suggests this is not a major factor and certainly not the principal factor in altering the position of the eye after recession. Does the new position of the muscle on the globe dictate the new alignment on a purely mechanical basis? The fact that alignment does not change in the case of a 'hang-back' recession between the initial alignment when the suspending sutures are the effective insertion and the time when the muscle attaches to the globe makes this doubtful. The truth may be that both factors have some influence. The fact that the posterior fixation suture is effective in reducing movement of the globe in a muscle's field of action certainly speaks for the importance of a recessed muscle's insertion site. The muscle length remains unchanged with the posterior fixation suture and in most cases the primary position remains unchanged. In addition, this procedure has no effect on alignment in gaze in the direction opposite the side of the procedure.

Four important points to remember when doing rectus muscle recession are: (1) do enough recession to achieve the intended result; (2) do not recess the muscle so far as to produce an undesired result such as deficient duction, widened fissure, or lower lid ptosis; (3) be consistent; and (4) make adjustments in the amount of recession done in subsequent patients based on your past surgical results.

A small change in the medial rectus insertion location relative to the limbus when measured before and after detachment of the muscle has been described. Although this change may be of some theoretical interest, it does not represent an important clinical consideration. The medial rectus insertion site has been said to shift 0.3 mm closer to the limbus after detachment of the medial rectus and when the eye is abducted with forceps. This factor is another, albeit minor, factor that makes recession measurement from the limbus logical for medial rectus recession. For recession of the other rectus muscles, I

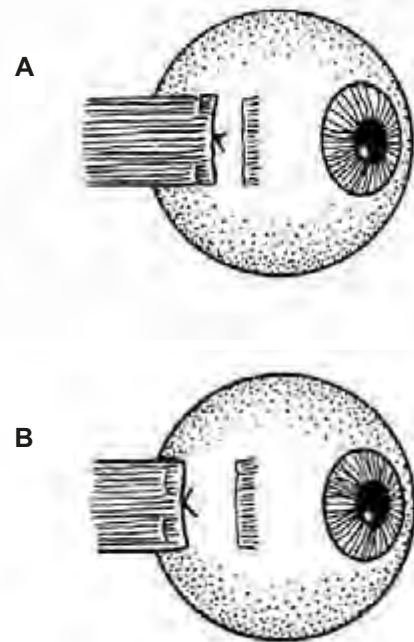


Figure 1

- A** Minimum medial rectus recession is 2.5 mm from the insertion or 8.5 mm from the limbus
B 'Maximum' medial rectus recession less well defined (could be 6-7 mm from insertion or 11.5 mm from the limbus).

measure from the insertion site. This technique for these other rectus muscles allows sufficient recession amount with or without resection of the antagonist according to the patient's needs. I do not encounter chronic undercorrections after recession of the other rectus muscles, as had been the case with medial rectus recession.

Medial rectus recession

Measured recession or retroplacement of the medial rectus is the procedure of choice for weakening this muscle in esodeviations. In certain situations, marginal myotomy is a satisfactory and even preferred technique for weakening any of the rectus muscles, but marginal myotomies should be reserved for specific indications (see chapter 10). A modified recession procedure is accomplished with the hang-back technique. I prefer to dissect intermuscular membrane a minimal amount, just enough to place sutures in the case of a first surgery. Reoperations are dealt with on a case by case basis but, there is probably not much value in carrying the dissection any further in these cases.

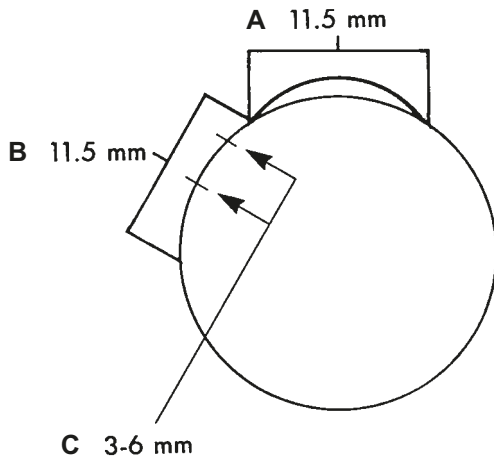


Figure 2
Dimensions related to medial rectus recession measuring from the limbus
A Corneal diameter
B Distance of equator from limbus
C Variation in medial rectus insertion in patients with esotropia

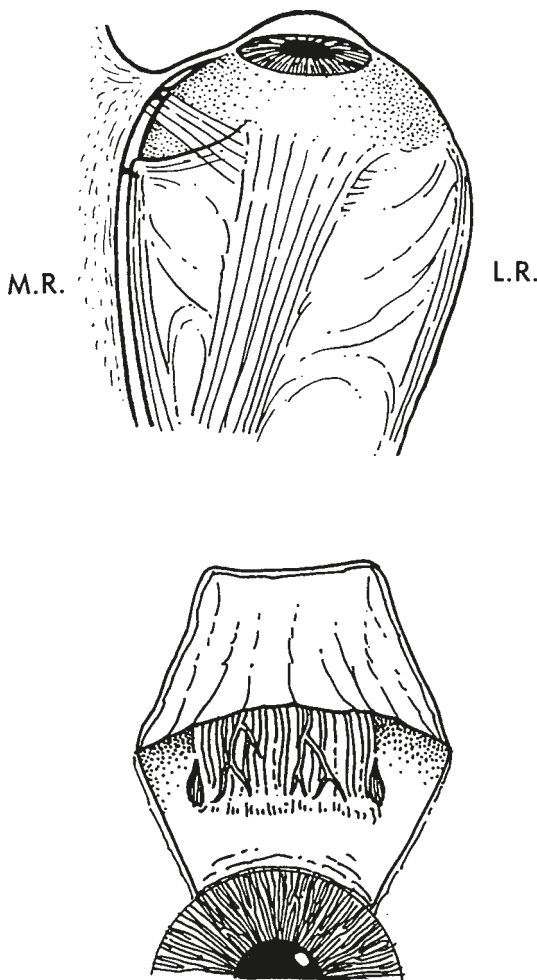


Figure 3
Medial rectus recession with minimal dissection of intermuscular membrane

A minimum medial rectus recession for those who measure from the insertion is 2.5 mm. This is a reliable figure and should not be violated. A medial rectus recession of less than 2.5 mm is rarely, if ever, justified. The ‘resection-effect’ of suture placement and the fibrosis of healing tend to nullify any expected muscle weakening effect if a recession smaller than 2.5 mm is performed. An exception to this is the proposed modifying effect that is said to occur from simply detaching and reattaching a muscle. This procedure has been suggested by Hertle done on the four horizontal recti for damping nystagmus.

A maximum medial rectus recession measured from the limbus had traditionally been 5.0 or 5.5 mm. This figure is based on the fact that moving the medial rectus farther than 5.5 mm posterior to its normal insertion places the new insertion behind the point of tangency with the globe. This point of tangency is anterior to the equator of the globe because the origin of the medial rectus at the ligament of Zinn is medial to the anteroposterior axis of the globe. If the contracting medial rectus acts on the globe as if it were a string attached to a ball, no unwrapping or rotational effect would be expected if the muscle attached behind the point of tangency. The muscle in such an instance would act more as a retractor than an adductor. However, because medial rectus action on the globe is mediated through attachments to the intermuscular membrane (posterior Tenon's capsule and the pulleys), certain cases requiring extra weakening effect of the medial rectus can be treated with a recession larger than 5.5 mm, or even with a free tenotomy in extreme cases. Many surgeons who perform medial rectus recession measured from the muscle's insertion exceed this 5.5 mm recession ‘rule’. They recess the medial rectus 6 or even 7 mm or possibly more from the original insertion. Because of variations in the point of insertion of the medial rectus (average 4.4 mm - range 3 to 6 mm) I perform medial rectus recession using the limbus as the point of reference. These recessions range from 8.5 mm to 11.5 mm (Figure 2). In selected cases this upper limit of recession is exceeded, such as in cases of nystagmus where the medial rectus has been recessed up to 14.0 mm from the limbus, and therefore behind the equator when the ‘four-muscle’ recession procedure is done. These large recessions produce limitation of ductions.

Even when the medial rectus is recessed to its functional point of tangency, attachments to the intermuscular membrane, which in turn attach to the globe well anterior to the point of tangency and medial to the globe's vertical axis, can facilitate adduction. The lever arm is reduced, but adducting power remains. The extent to which the intermuscular membrane is severed at the muscle border can influence the degree of weakening accomplished by a given medial rectus recession (Figure 3). An extreme example is the case of a slipped or lost muscle that has had extensive free-

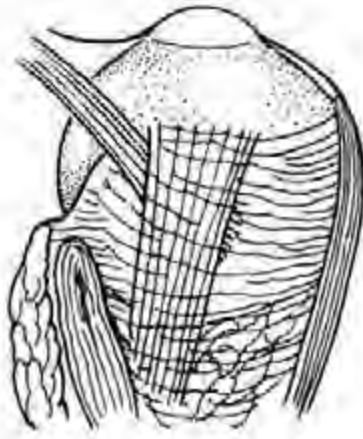
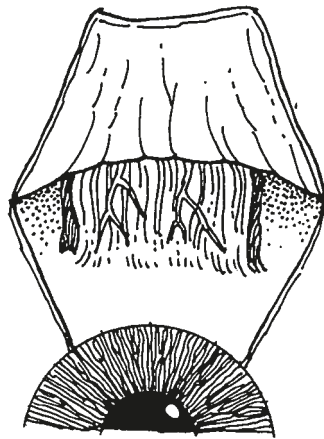


Figure 4
After extensive dissection of the intermuscular membrane the medial rectus, if it becomes detached from the globe, can retract into the fat of the muscle cone resulting in a 'lost' muscle.

ing of the intermuscular membrane from the muscle borders. In such a case little, if any, adduction is present postoperatively. On the other hand, free tenotomy performed with minimal dissection of the adjacent intermuscular membrane leaves the patient, in most cases, with some adduction. Free tenotomy may be an unsound procedure more because it is unpredictable than because it is crippling.

Minimum dissection of the intermuscular membrane and overlying Tenon's capsule would theoretically lessen recession effect and lessen the likelihood of a 'lost' muscle. Maximum dissection of the intermuscular membrane would theoretically maximize the recession effect and could with suture failure result in a 'lost' muscle (Figure 4).

Lateral rectus recession

Measured recession or retroplacement of the lateral rectus is the procedure of choice for weakening this muscle in exodeviations. In certain instances, a marginal myotomy is a satisfactory and even desirable procedure for weakening the lateral rectus muscle, but this procedure should be reserved for specific cases (see Chapter 10). A modified recession procedure is accomplished by the hang-back technique.

A minimum lateral rectus recession is 4 mm. Less recession should not be undertaken if surgery to weaken the lateral rectus is justified. The maximum measured lateral rectus recession had been 7 mm in adults and 6 mm in children. However, most surgeons now perform 8 mm and even up to 10 mm or even larger recessions of the lateral rectus without crippling the muscle's effect (Figure 5).

Large recessions of the lateral rectus may be performed in certain cases without severely restricting motility because the muscle continues to act through attachments to the intermuscular membrane. The lever arm is reduced, but abducting power

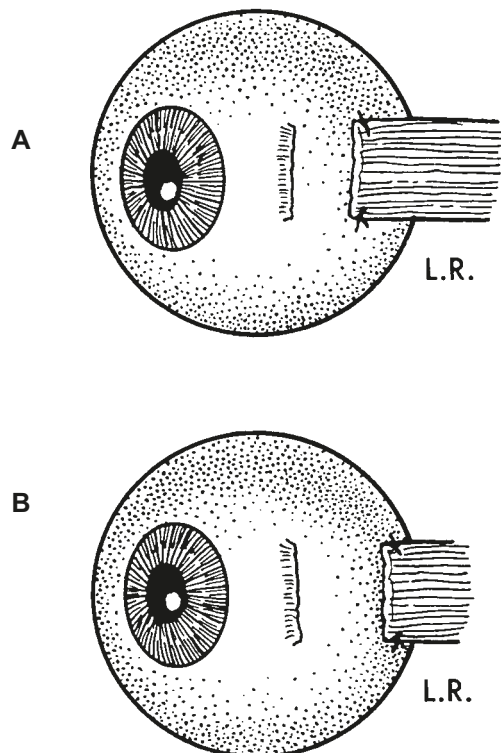


Figure 5
A Minimum lateral rectus recession, 4.0 mm
B 'Maximum' lateral rectus recession, 8.0 mm

remains. The extent to which the intermuscular membrane is severed from the muscle border can influence the degree of weakening accomplished by a given lateral rectus recession (Figure 6). As with the medial rectus, an extreme example is the case of a slipped or lost muscle that has had extensive freeing of the muscle borders from intermuscular membrane. In these cases little, if any, abduction is present postoperatively. On the other hand, free tenotomy, which is always performed with minimal dissection of the adjacent intermuscular membrane, in most cases leaves the patient with some abduction. Free tenotomy is infrequently done. It is often unpredictable and can be crippling. However, in some cases of large angle exotropia in a previously operated patient who may have mechanical restrictions, free tenotomy or one guarded by an adjustable suture may be done. This may also be considered a type of hang-loose procedure with more posterior globe-suture attachment. In extreme cases where lateral rectus function needs to be eliminated, the lateral rectus is detached and reattached to the lateral orbital periosteum.

When attempting to engage the lateral rectus with a muscle hook, care should be taken to avoid inadvertently including all or part of the inferior oblique muscle at its insertion (Figure 7). This complication can be avoided by making the initial sweep of the hook from above. If the hook is passed upward from below, it must not be thrust too deeply into the orbit. Inclusion of the inferior oblique in lateral rectus recession will, if undetected, lead to unpredictable surgical results accompanied by restrictions in motility. This has been called the inferior oblique inclusion syndrome.

When the lateral rectus is detached from the globe, the muscle should be lifted and the undersurface and the inferior border of the lateral rectus should be freed from the inferior oblique muscle (Figure 8).

Superior rectus recession

A minimum recession of the superior rectus is 2.5 mm. A recession smaller than this would be ineffective and should not be performed. A maximum recession of the superior rectus had been thought to be 5 mm, although some surgeons routinely exceed this figure placing the superior rectus at 10 mm and up to 15 mm from the original insertion, especially in cases of DVD (Figure 9). Large recessions of the superior rectus muscle can cause retraction of the upper lid leading to widening of the palpebral fissure. The superior oblique tendon passes beneath the superior rectus approximately 5 mm posterior to the nasal aspect of the superior rectus insertion. A recession of the superior rectus greater than 5 mm would place the new insertion of the superior rectus at the superior oblique tendon if the tendon were dissected free or

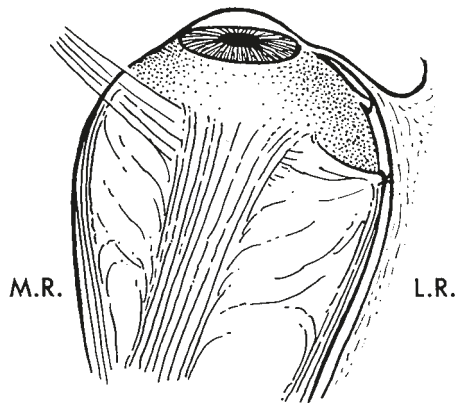


Figure 6
Lateral rectus recession with minimal intermuscular membrane dissection

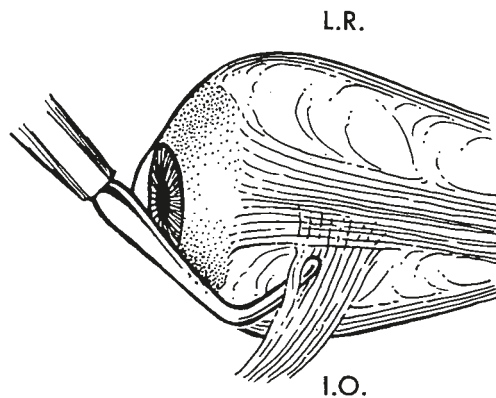


Figure 7
Care should be exercised to avoid unintended inclusion of the inferior oblique when hooking the lateral rectus

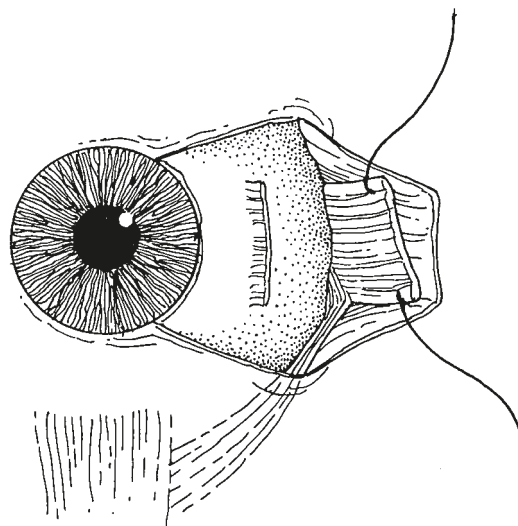


Figure 8
It is good practice to lift the lateral rectus to confirm that the inferior oblique is not attached to the lateral rectus or included in the suture. The relationship of the lateral rectus and inferior oblique makes it unlikely that the lateral rectus will be 'lost.'

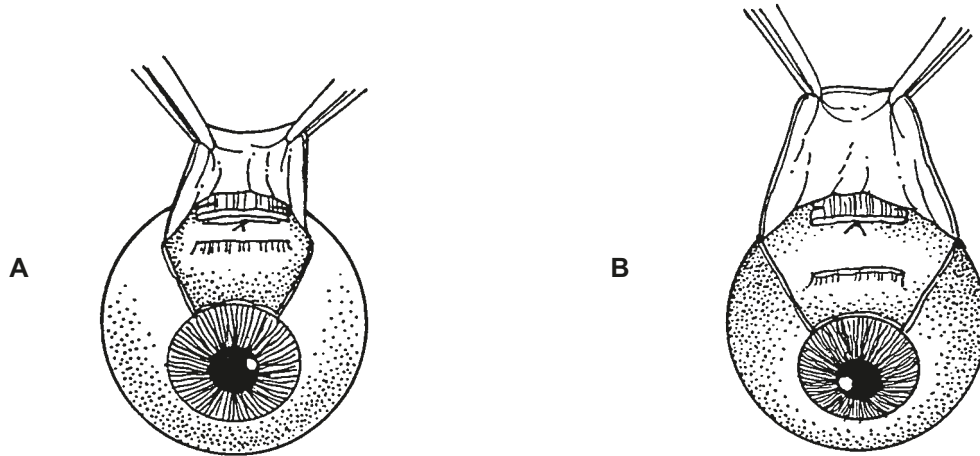


Figure 9

A Minimal superior rectus recession is 2.5 mm

B Maximum superior rectus recession is not established. A 5.0 mm recession will place the new insertion anterior to the superior oblique tendon.

would deflect the tendon posteriorly if this freeing had not been done.

The superior rectus insertion can be engaged from the medial or the lateral side (Figure 10). Careful dissection exposing bare sclera should be completed before inserting the muscle hook. To avoid engaging the superior oblique tendon, an incision is made to enter subposterior Tenon's space medial to the insertion of the superior rectus. The tip of the muscle hook gently indents bare sclera and is

guided just behind the superior rectus insertion. In spite of efforts to avoid this complication, the superior oblique tendon may be inadvertently included with the hook which is intended to engage only the superior rectus. If this inclusion goes unrecognized, the superior oblique tendon may be reattached at the new insertion of the recessed superior rectus (Figure 11). We have seen this complication at reoperation. If the surgeon observes or suspects this unintended superior oblique inclusion, a second muscle hook is passed

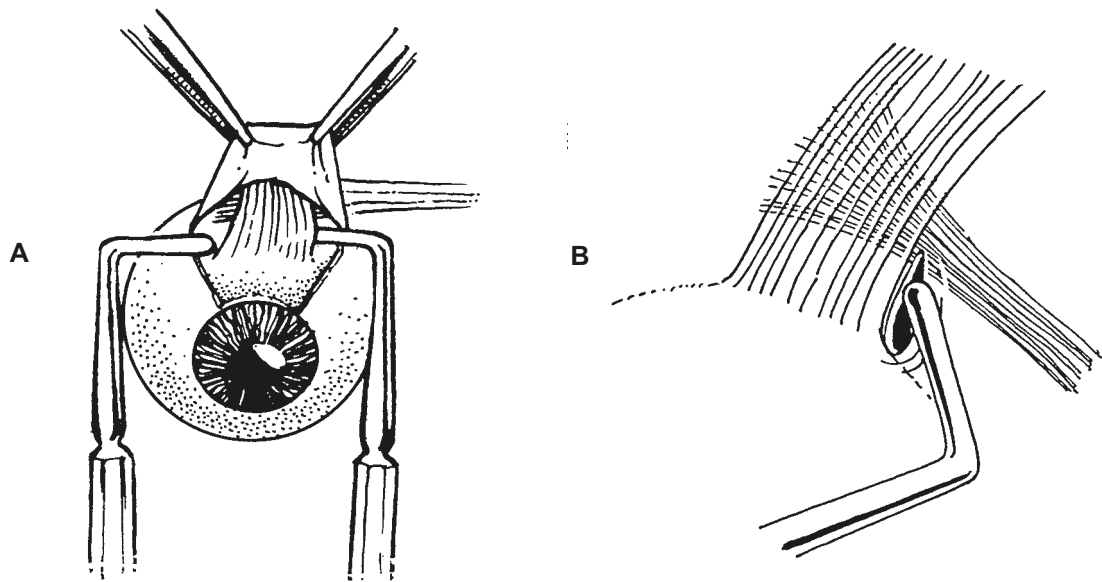


Figure 10

A When identifying the entire superior rectus insertion it may be necessary to pass a hook from either border and sometimes several times.

B The initial attempt to hook the medial rectus can be made from the medial side.

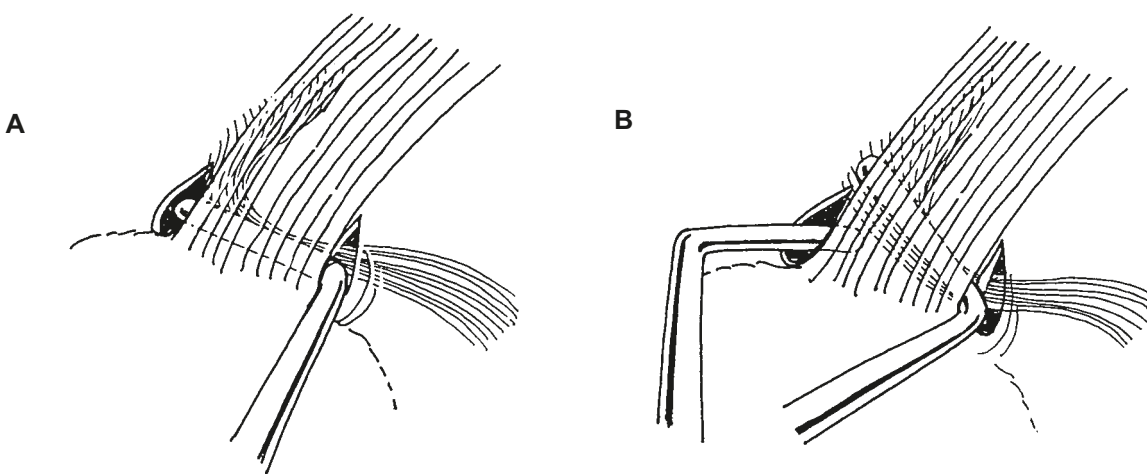


Figure 11
A Hooking the superior rectus from the nasal side can inadvertently include the superior oblique tendon.

B A second hook introduced from the temporal side can free the superior oblique tendon. The first hook is then removed.

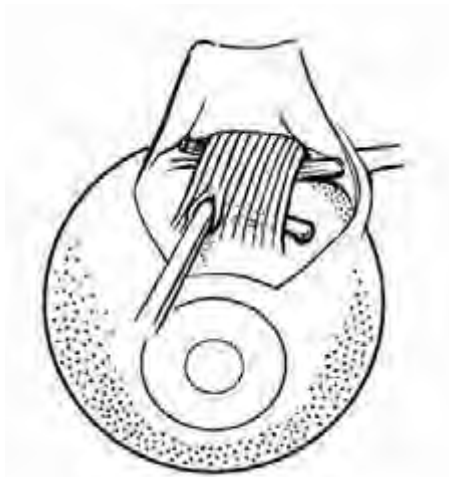


Figure 12
 Hooking the superior rectus from the temporal side can split the insertion.

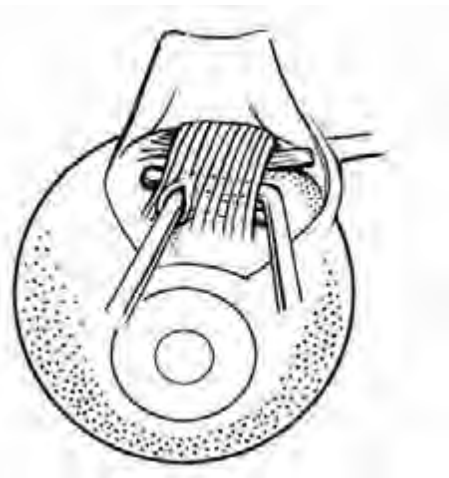


Figure 13
 A second hook introduced from the nasal side can include the entire tendon. The first hook is then removed.

from the temporal border of the superior rectus after the tip of the first hook has been rotated backward. As the second hook is inserted, the first hook is withdrawn. With the superior oblique tendon freed from the hook engaging the superior rectus, another hook may finally be placed from the medial side or from the lateral side of the insertion. In my experience, the superior rectus insertion is the most likely of the rectus muscles to be 'split' when attempting to engage it on a muscle hook (Figure 12). This is more likely to occur when hooking the muscle from the temporal side because the insertion tends to curve posteriorly. If this occurs, re-hooking from the other border will allow inclusion of the total muscle (Figure 13).

Inferior rectus recession

A minimum recession of the inferior rectus is 2.5 mm. A recession smaller than this would probably be ineffective and should not be performed. A maximum recession of the inferior rectus under most circumstances is 5 mm (Figure 14). This amount is not ordinarily exceeded because an excessively large recession of the inferior rectus causes a pulling down or ptosis of the lower lid resulting in a cosmetically objectionable widening of the palpebral fissure. These problems of the lower lid are caused by the fact that the capsule of the inferior rectus is attached to Lockwood's ligament and the inferior oblique muscle, which in turn are attached to the inferior orbital septum and tarsus of the lower lid. Careful dissection of the intermuscular membrane of the inferior rectus and of the fascial attachments between the inferior rectus and Lockwood's ligament can minimize the effect of a large inferior rectus recession on the lower lid. Inflammatory changes in the extraocular muscles associated with Graves' disease have a predilection

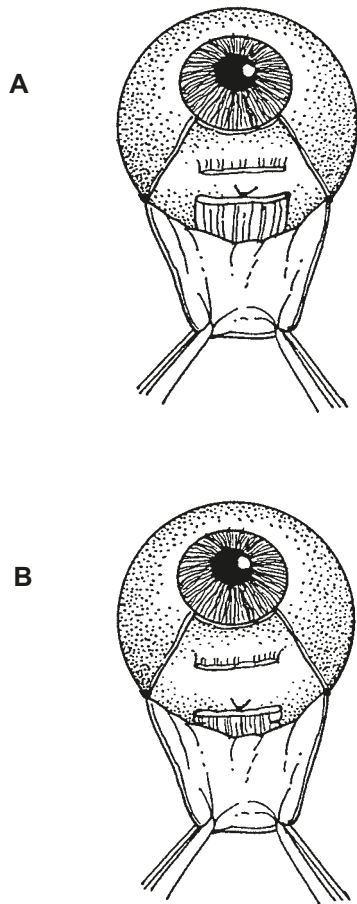


Figure 14
A A minimum inferior rectus recession of 2.5 mm
B A 'maximum' inferior rectus recession of 5.0 mm. This number is exceeded in cases of restriction and in special circumstances.

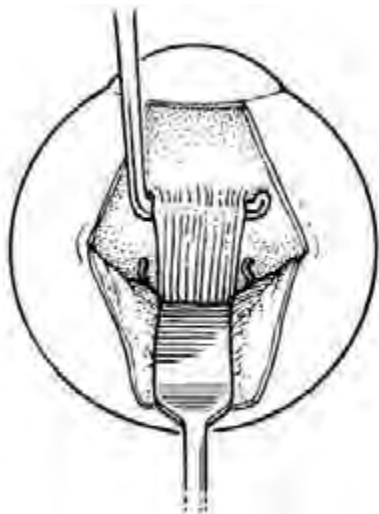

Figure 15
 Vortex veins are seen on both borders of the inferior rectus when dissection is carried back 10 mm or more.

for the inferior rectus. When these changes cause a hypotropia with restriction of forced elevation of the globe, the usual maximum inferior rectus recession often must be exceeded to obtain adequate elevation of the 'bound down' globe. In such a case, inferior rectus recession with an adjustable suture may be done. However, adjustable inferior rectus recession may be complicated by early or late slippage of the inferior rectus with widened fissure, ptosis of the lower lid, and deficient depression (see page 403).

When dissecting the inferior rectus in cases with or without restriction, care should be taken to avoid cutting the vortex veins that lie at each border of the muscle between 8 and 12 mm behind the insertion (Figure 15). Also, Lockwood's ligament should be dissected carefully with small scissor snips under direct vision for a distance of 12 mm or slightly more posterior to the insertion. This careful technique reduces bleeding and the likelihood of lower lid retraction with recession or lower lid advancement with resection.

Lockwood's ligament encasing the inferior oblique has a firm attachment to the inferior orbital septum and the lower lid tarsus (Figure 16). The distance between Lockwood's ligament and the lower lid

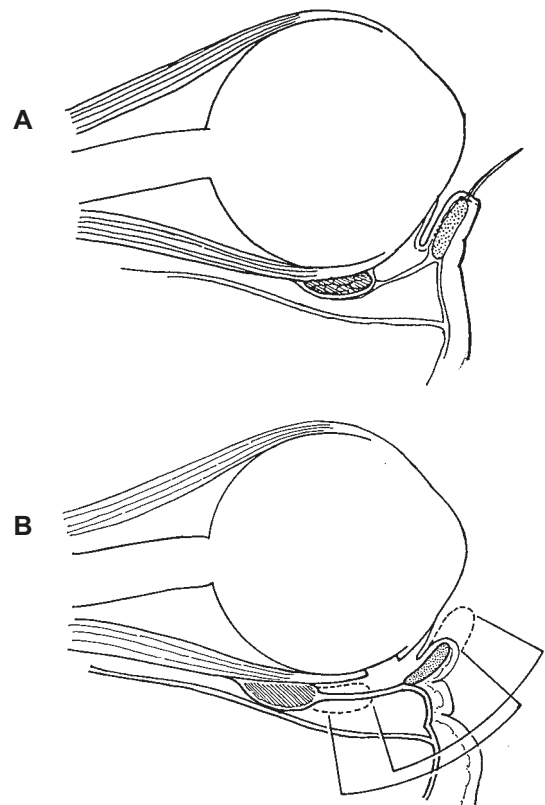


Figure 16
 The connections between the inferior rectus - inferior oblique - Lockwood's ligament and the lower lid cause the structures to move together.
A Normal
B Lower lid ptosis after inferior rectus recession without advancement of Lockwood's.

border tends to remain constant. As the inferior rectus is recessed and Lockwood's ligament follows the muscle, the lower lid tends to drop lower producing lower lid ptosis and widening of the palpebral fissure. This problem can be avoided or at least reduced if Lockwood's ligament is brought forward and sutured to the inferior rectus so that it is the same distance from the original insertion of the inferior rectus as before recession (Figure 17). Lockwood's ligament is sutured to the surface of the inferior rectus with 6-0 absorbable suture at the same distance from the original insertion as it was preoperatively.

Rectus muscle recession technique

The standard technique for recession of each of the rectus muscles is the same. Differences in maximum and minimum amounts and management of the intermuscular membrane and check ligaments were discussed previously. Because of the strength and uniformity of synthetic absorbable suture, I prefer to recess a muscle using one double-arm suture. However, two single-arm sutures may be used.

The rectus muscle is exposed by carefully incising the intermuscular membrane and posterior Tenon's capsule at 2 or 3 mm from the muscle border with sharp dissection. Anterior Tenon's capsule arises from the outer surface of the muscle sheath and is outside of posterior Tenon's capsule. Anterior Tenon's capsule is dissected with scissors from the outer surface of the muscle until suitable exposure is obtained. This varies according to each muscle. No fat should be exposed. Large vessels bridging from the muscle capsule surface to the undersurface of anterior Tenon's capsule may be simultaneously severed and sealed with cautery (see chapter 3). A

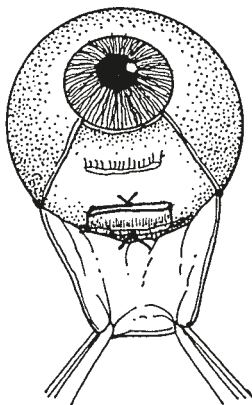


Figure 17
To assist in reducing lower lid ptosis when recessing the inferior rectus the tissues around Lockwood's ligament are pulled anteriorly and sutured to the inferior rectus at the same distance from the inferior rectus insertion as in the preoperative state.

Barbie or other suitable retractor is used to provide adequate exposure. When the muscle is properly exposed, it is stabilized with a muscle hook. The border of the rectus muscle is elevated with a small hook to facilitate passage of the needle between the large hook stabilizing the muscle and the small hook. The needle passes through the tendon avoiding the anterior ciliary vessels. The anterior ciliary vessels should not be severed by the needle but should be included in the suture (Figure 18).

After passing through the tendon, the needle is brought again through the tendon including the anterior ciliary vessels. The suture is then locked* (Figure 19). This technique for suture placement

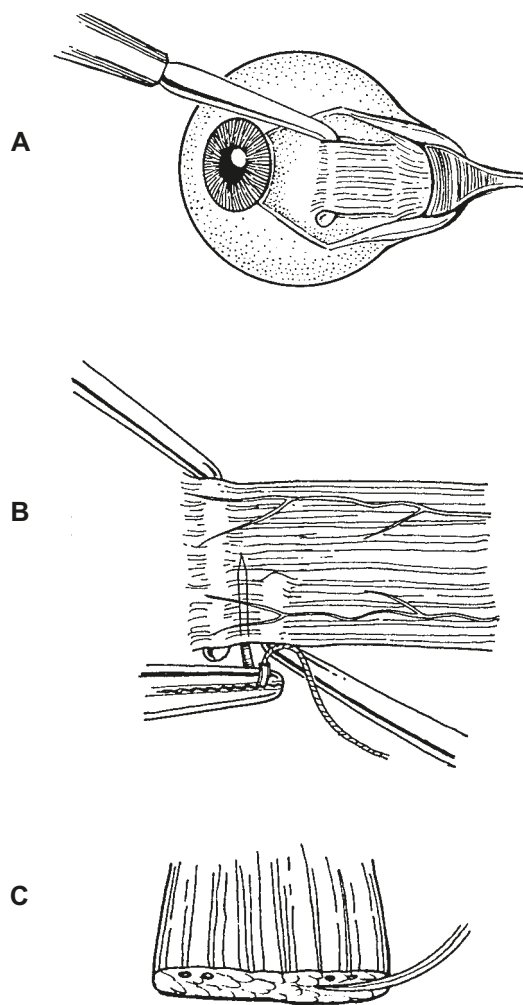


Figure 18
A Exposure of the rectus muscle insertion includes freeing the insertion and proximal muscle borders sufficiently to place the sutures.
B A small hook elevates the muscle border to facilitate placement of the needle through the muscle.
C The needle is passed through the tendon avoiding the anterior ciliary arteries.

* Mims has made specific recommendations for placing a secure locking bite, which is actually a true knot, at the rectus muscle border.

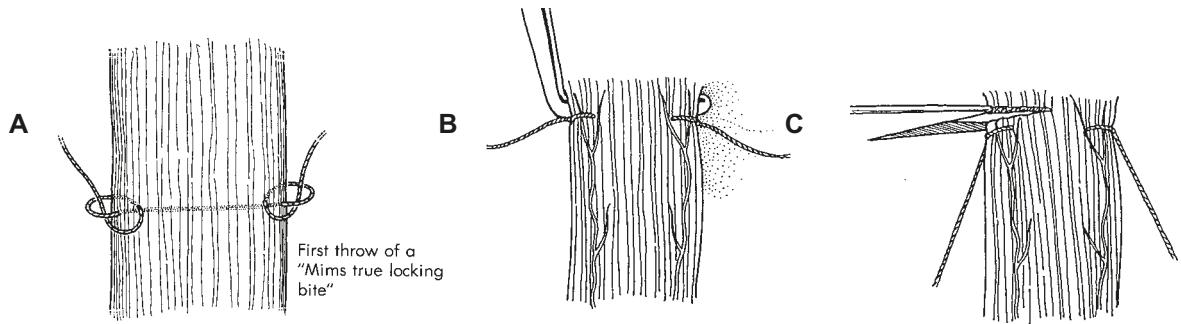


Figure 19

- A** If the sutures are passed as shown a true knot is formed.
- B** The anterior ciliary arteries are ligated the hook is aimed back toward the orbit (not shown).
- C** The muscle is detached.

behind the first hook reduces the likelihood of inadvertently cutting the suture when detaching the muscle and reduces bleeding by ligating the anterior ciliary vessels. The resection effect is negligible in my opinion. After the sutures have been pulled posteriorly from the insertion, the muscle is cut off flush with the sclera using scissors and taking small snips. Several footplates may need to be severed before the muscle retracts freely. The muscle hook is now behind the suture line for cutting the muscle free, whereas it was in 'front of' or closer to the insertion when the sutures were placed.

A caliper or scleral ruler is used to measure the amount of recession. Measurements may be taken from the original insertion or the limbus. I prefer to measure most medial rectus recessions from the limbus. The surgeon should decide on one method of

measuring medial rectus recessions and continue to use it. When comparing measurement from the limbus with measuring from the insertion, the distance between the insertion and the limbus should be added to the intended amount of recession. When measured from the limbus, a traditional 4 mm recession of the medial rectus would indicate that the new insertion should be 9.5 mm from the limbus, assuming that the medial rectus insertion is 5.5 mm from the limbus. Clinical experience has shown that the average medial rectus insertion in esotropia is 4.4 mm with a range of 3 to 6 mm. Measuring from the limbus opposite the corner of the insertion advances the muscle a bit (decreasing the recession) and measuring a chord produces excess recession. These factors are offsetting (Figure 20).

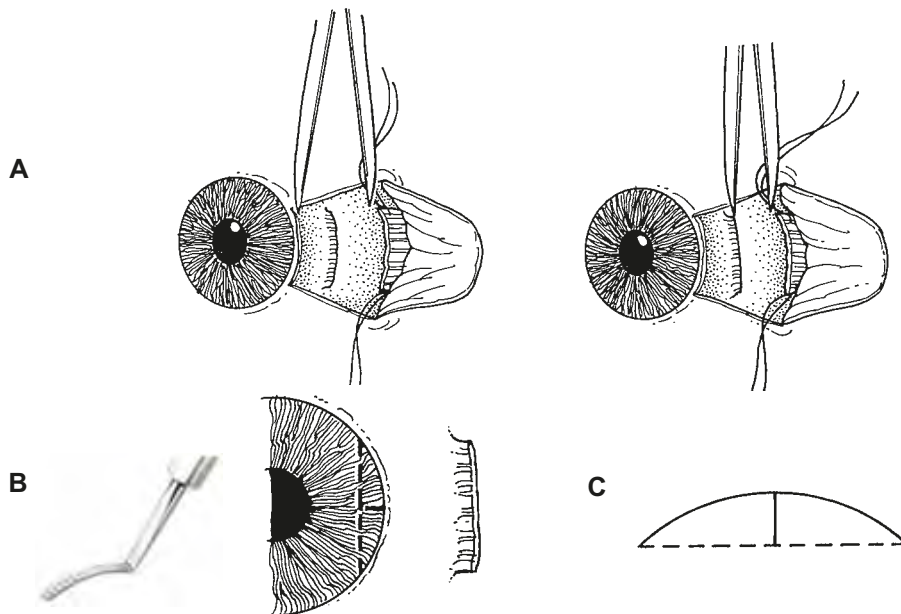


Figure 20

- A** A caliper measures from the limbus or the original insertion.
- B** A scleral ruler modified from William Scott is also useful for this measurement.
- C** The scleral ruler measures the true distance over the scleral surface while calipers measure the chord.

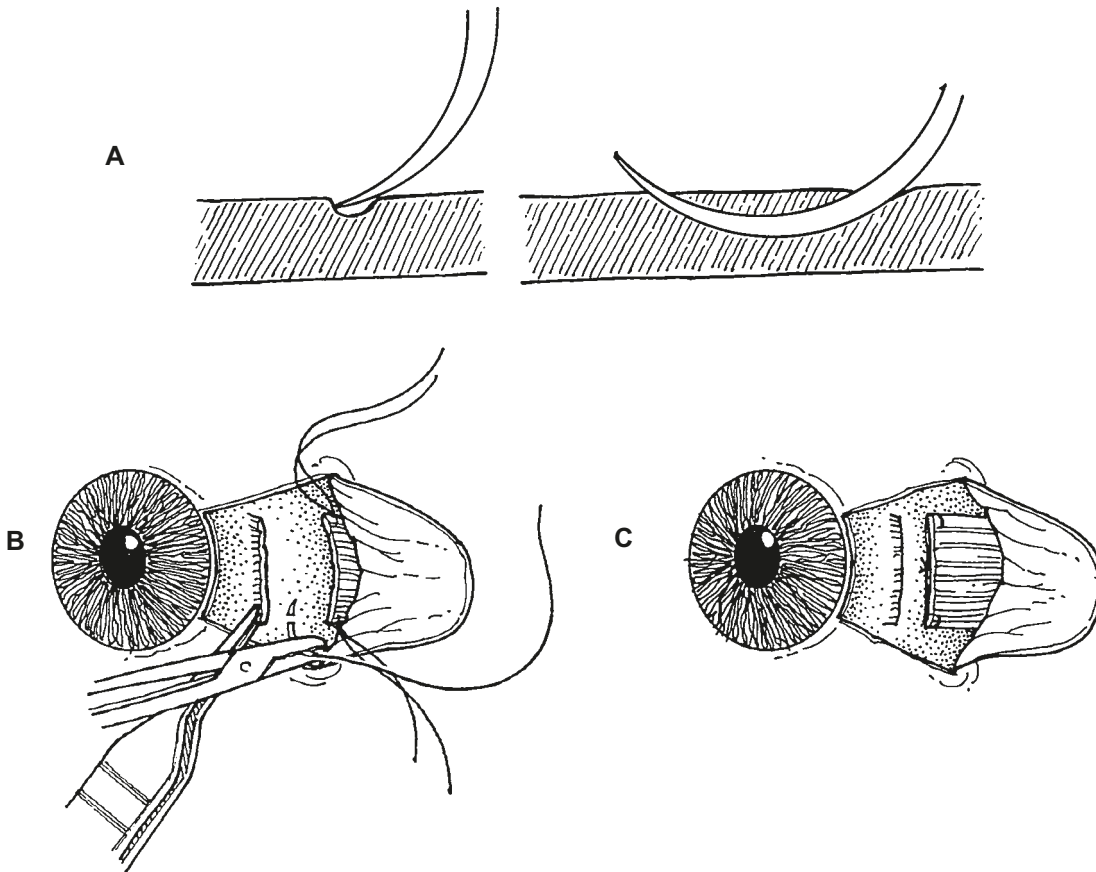


Figure 21

A A passage of the needle through sclera.
B The scleral tunnel should be 1.5 mm or more.

C The recessed muscle is ideally parallel to the old insertion (or nearly so).

The tip of the caliper or scleral ruler may be used to make a dimple in the sclera. This provides a point indicated by a blue mark which is the uvea showing through the sclera. This dimple can be used as a means of engaging scleral tissue with the needle tip. The thin, spatulated needle displaces tissue and should be in the superficial one-third to one-half of the scleral thickness. During experiments in the laboratory, Coats and Paysse found that a scleral bite 1.5 mm long and .2 mm deep is sufficient to secure the muscle to sclera. This bite had a 'pull out strength' in excess of 200 gm. This is greater than the physiologic muscle force exerted on this reattachment. A longer, but not deeper scleral bite can be taken to produce friction in the scleral suture tunnel. This holds the muscle in place during suture tying.

The needle is inserted at the caliper mark (Figure 21). A scleral bite of 1.5 mm or more is taken, but care should be exercised to ensure that the needle is always in sight through the scleral lamellae and does not perforate the sclera. The globe is stabi-

lized with a utility forceps, which may be of a locking variety, grasping the insertion stump opposite the site of needle placement. Care should be taken to space the two suture bites in the sclera approximately 10 mm apart and equidistant from the limbus or insertion. This maneuver ensures that the new insertion will be parallel with the limbus, smooth, and flat. The sutures are tied with a surgeon's knot, and a total of three throws are taken. The knots should be tied carefully, using smooth-tying forceps, grasping the suture very close to the knot.* This approach ensures secure knots and reduces the possibility of a broken suture.

Variations in suture and needle placement

A wide variety of techniques may be used to secure the suture to the tendon and then to reattach the tendon to sclera. The overriding principles are security, consistency, and safety. The suture must be securely attached to the tendon to avoid slippage of the tendon-muscle. The muscle and tendon must be

* Some surgeons with smaller hands than mine prefer to tie sutures using their fingers rather than forceps.

securely attached to sclera to avoid pulling free from sclera and producing muscle slippage. Finally, the needle track in sclera must be deep enough and long enough to secure the tendon-muscle to sclera without going too deeply and entering the eye by passing through choroid and retina into the vitreous.

As a variation of the double-arm suture technique, a single suture may be used, taking a bite into the central tendon and then tied. Additional bites then are taken at the muscle borders and locked loops are

placed. The scleral bite is taken and the suture is tied. The 'crossed swords' technique of Parks may also be used. The first needle is left in the long scleral tunnel which angles toward the insertion while the second needle is placed in the sclera, crossing the first. Both needles are advanced carefully pulling the first suture through only when the round part of the other needle remains in the track. This maneuver prevents the second needle from cutting the first suture while in its scleral track (Figure 22).

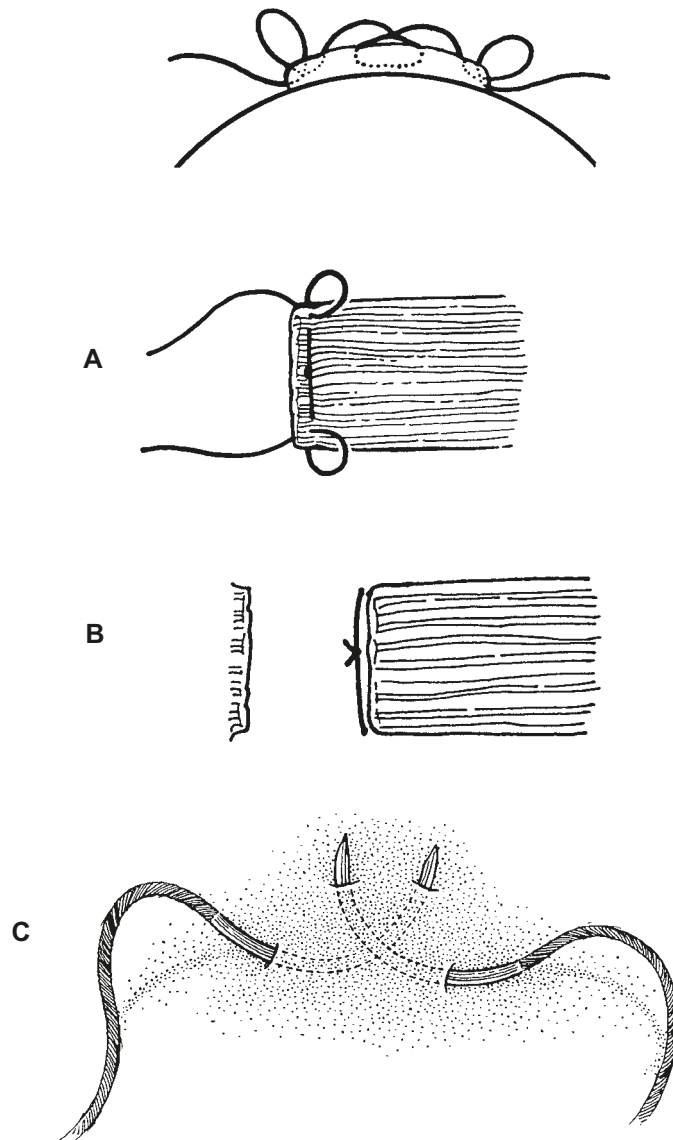


Figure 22

A A bite secured with a knot can be taken at mid-muscle and sutures brought out the borders and locked for added security.

B The properly recessed muscle with a double arm suture.

C Needles can be placed in the 'crossed swords' technique producing a longer scleral tunnel. This holds the muscle in place while the suture is being tied.

Vertical displacement of the horizontal rectus

In cases of vertically incomitant strabismus ('A' or 'V' pattern) without apparent overaction or underaction of the oblique muscles, vertical displacement of the rectus muscles is effective in reducing or eliminating the vertical incomitance (Figure 23). The muscles are moved vertically to produce more or less relative strengthening or weakening in upgaze or downgaze. For example, a horizontal rectus muscle that has been recessed or resected is relatively weakened in the field of action corresponding to the vertical direction in which its insertion has been moved. A resected medial rectus that has been moved downward has relatively less strengthening effect in downgaze and relatively more strengthening effect in upgaze. A recessed medial rectus that is moved downward is weakened more in downgaze and weakened less in upgaze.

Miller has suggested horizontal displacement of the vertical rectus muscles for treatment of 'A' and 'V.' The superior rectus muscles are moved nasally to close a 'V' pattern (reduce abduction) or temporally to open an 'A' pattern (increase abduction). The inferior rectus muscles are moved medially to close an 'A' pattern (decrease abduction) or temporally to open a 'V' pattern (increase abduction). The most common use of horizontal displacement of a vertical rectus muscle is the nasal shift, which is usually performed when recessing an inferior rectus muscle. This maneuver will eliminate or reduce an unwanted postoperative 'A' pattern.

To know the proper direction for vertical displacement, the surgeon needs to remember that the medial rectus muscles are always shifted to the closed end and the lateral rectus muscles are shifted to the open end. This assumes the obvious that the surgeon recesses the medial rectus for esodeviations and resects it for exodeviations and recesses the lateral rectus for exodeviations and resects it for esodeviations.

In 'A' esotropia the medial rectus muscles are shifted upward at least 5 mm (approximately half the muscle width) and no more than 10 mm (approximately one muscle width). It is not firmly established that graded amounts of vertical displacement result in graded amounts of 'A' or 'V' pattern reduction. In this type of recession it is important to place the new insertion concentric with the limbus. Therefore, it is probably best to use calipers or a scleral ruler to measure from the limbus. In cases of 'A' or 'V' pattern without strabismus in the primary position, the horizontal rectus muscles may be shifted upward or downward with only enough recession to offset the resection effect of suture placement. In 'V' pattern esotropia the medial rectus muscles are recessed and shifted downward. In 'V' pattern exotropia the lateral rectus muscles are recessed and shifted upward. In 'A' pattern exotropia the lateral rectus muscles are recessed and shifted downward. Vertical shifting of the horizontal rectus may be carried out when a recession-resection procedure is performed. In this case, the same rules apply.

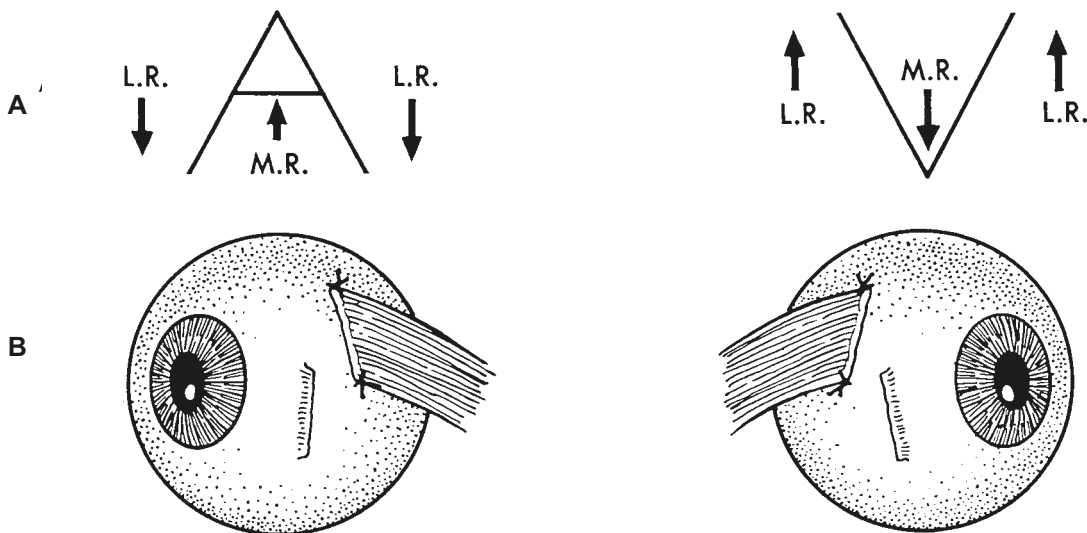


Figure 23

A For treatment of 'A' and 'V' the medial recti are shifted to the 'closed' end and the lateral recti are shifted to the 'open' end. This assumes that the proper horizontal surgery has been done.

B The medial recti are recessed and shifted up to treat an 'A' esotropia.

continued.

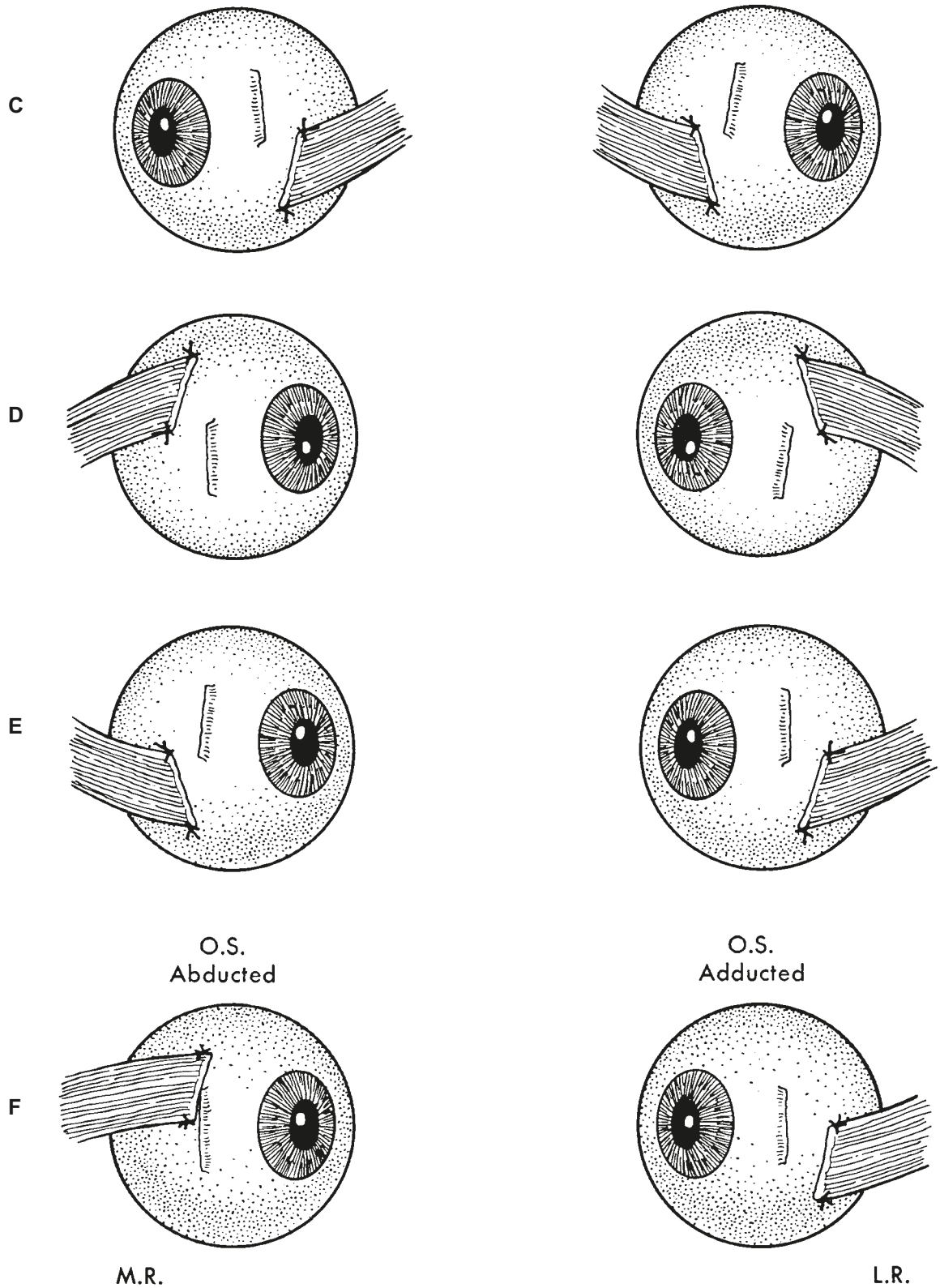


Figure 23, cont'd

C The medial recti are recessed and shifted down to treat 'V' esotropia.
 D The lateral recti are recessed and shifted up to treat 'V' exotropia.

E The lateral recti are recessed and shifted down to treat 'A' exotropia.

F In the left eye, the medial rectus is resected and shifted up and the lateral rectus is recessed and shifted down to treat a 'A' exotropia.

Resection effect of suture placement posterior to the muscle hook

Traditionally the suture is placed as near as possible to the muscle's insertion during recession before cutting the muscle from the globe to avoid the unwanted resection effect. It is thought that this resection effect will nullify a certain but unspecified amount of the intended recession. I place the suture about 1 mm behind the insertion to avoid the possi-

bility of cutting the suture when detaching the muscle. This also ensures a more secure union of suture and muscle. I believe that the new point of muscle attachment on the sclera is more important than the muscle tendon length when the recession is large and the resection effect is small (Figure 24).

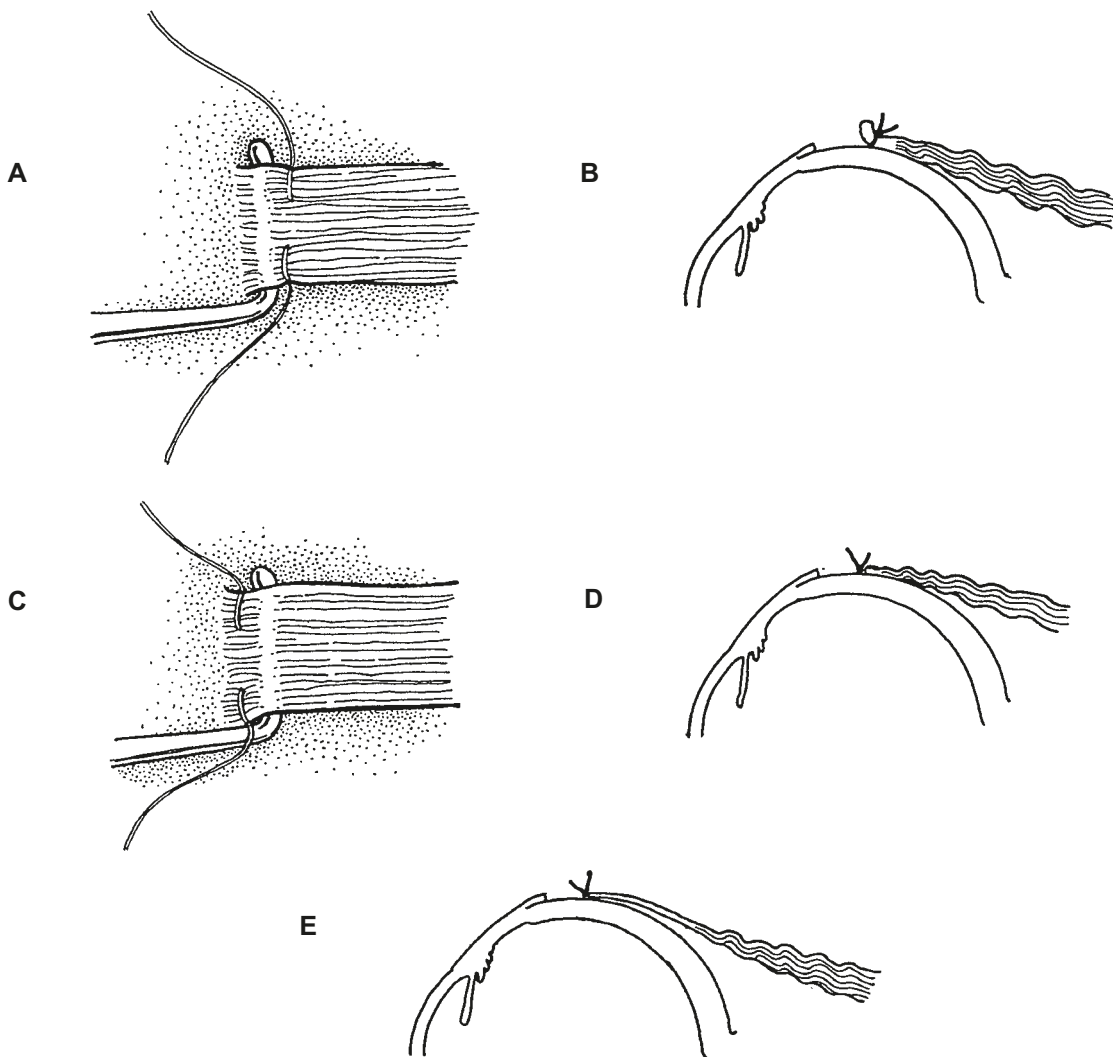


Figure 24

- A** 1 mm resection effect with a posterior ('safe') suture placement.
- B** With a small resection effect, the new point of insertion is more important than the slight reduction in the redundant muscle.
- C** If the suture securing the muscle before it is detached from the globe is placed distal to the muscle hook (closer to the insertion), the resection effect is avoided or at least diminished.
- D** With no (or minimal) resection effect the same point of reattachment is achieved, but the muscle is a bit 'longer' or more redundant.
- E** A potential pitfall of reducing the resection effect by placing the suture as near as possible to the distal end of the muscle before detaching it from the globe is slippage of the tendon and muscle in the capsule. This complication, called a slipped muscle is responsible for some early and late overcorrections, particularly after medial rectus recession for infantile esotropia.

Hang-back recession

The hang-back recession has been described as "a simple, safe alternative to conventional recession." The procedure is said to be less likely to result in scleral perforation because needles are placed through relatively thicker sclera near the insertion site. Another reported safety factor is that because the suture placement site is more anterior, it is more accessible to the surgeon. Results are said to be comparable to conventional recession when appropriate doses are used. The attachment site has been shown to be about where it was intended on studies carried out on monkeys who had horizontal recti recessed

with the hang-back technique. In humans who had hang-back recession of the superior rectus, reattachment 11.5 and 12.0 mm from the insertion (as intended by the surgeon) was confirmed by x-ray study of a stainless steel suture placed at the end of the superior rectus. Hang-back recession of the inferior rectus is likely to result in the complication of lower lid ptosis and muscle slippage. The inferior rectus muscle may be least suitable for hang-back recession, except in desperate cases as might occur in some cases of fibrosis syndrome and severe thyroid ophthalmopathy (Figure 25).

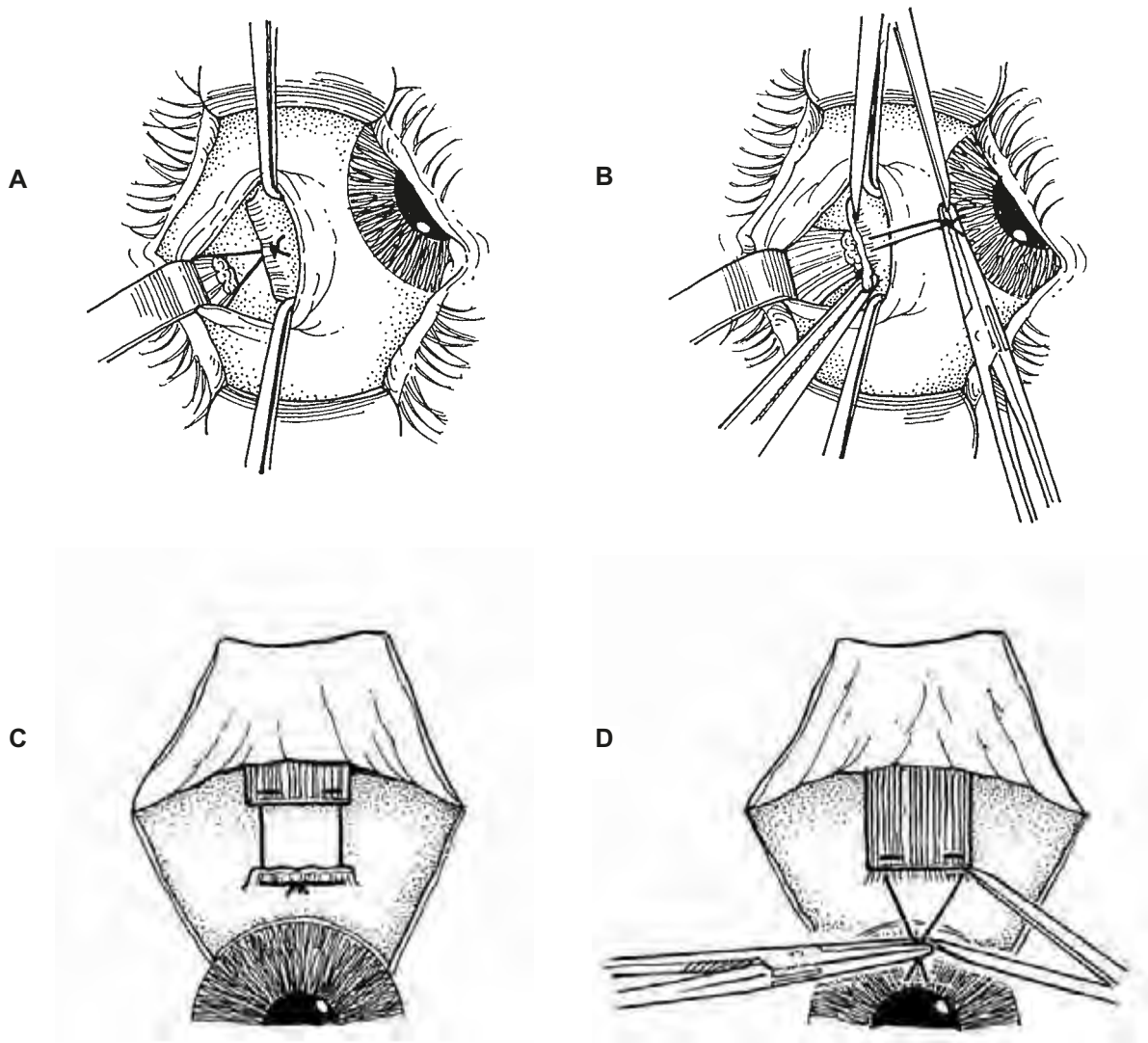


Figure 25

- A** Hang-back recession of the lateral rectus muscle through a cul-de-sac incision. 6-0 synthetic absorbable suture is used.
- B** The knot in the suture is pulled to bring the cut end of the muscle to the muscle stump. The suture is measured with calipers to determine the distance the muscle is recessed from the insertion.

- C** Sutures may be brought through the muscle stump at the width of the muscle. A limbal incision is used.
- D** The amount of 'hang back' recession is measured for the superior rectus.

Partial disinsertion

Spielmann has described 'slanted recession' of the rectus muscles for treatment of head tilt without oblique muscle dysfunction. This procedure involves recession of part of the insertion of the eight rectus muscles. Because all rectus muscles are operated on, great care must be exercised to preserve the anterior ciliary artery in each muscle that is not involved in suture placement and partial muscle detachment. von Noorden accomplishes the 'torsional Kestenbaum' by moving the entire superior and inferior rectus insertion to rotate the eye in the direction of the head tilt (see chapter 13). In cases of strong fixation preference, only the fixing eye need be done. DeDecker accomplishes the 'torsional Kestenbaum' by recessing and resecting the four oblique muscles, a daunting task in most hands (Figure 26).

Recession of a rectus muscle with sparing of the anterior arteries

Detaching a rectus muscle irrevocably destroys the ciliary artery circulation carried with that muscle to supply the anterior segment of the eye. As a means of detaching a rectus muscle without compromising anterior segment circulation, rectus muscle detachment with sparing of the anterior ciliary arteries has been described. This technique is accomplished with magnification supplied by the operation microscope or by loupes. Pre-placing the sutures in the muscle and also in sclera at the point of intended reattachment is recommended to avoid stretching and possible breaking of the anterior ciliary arteries when the muscle is detached.

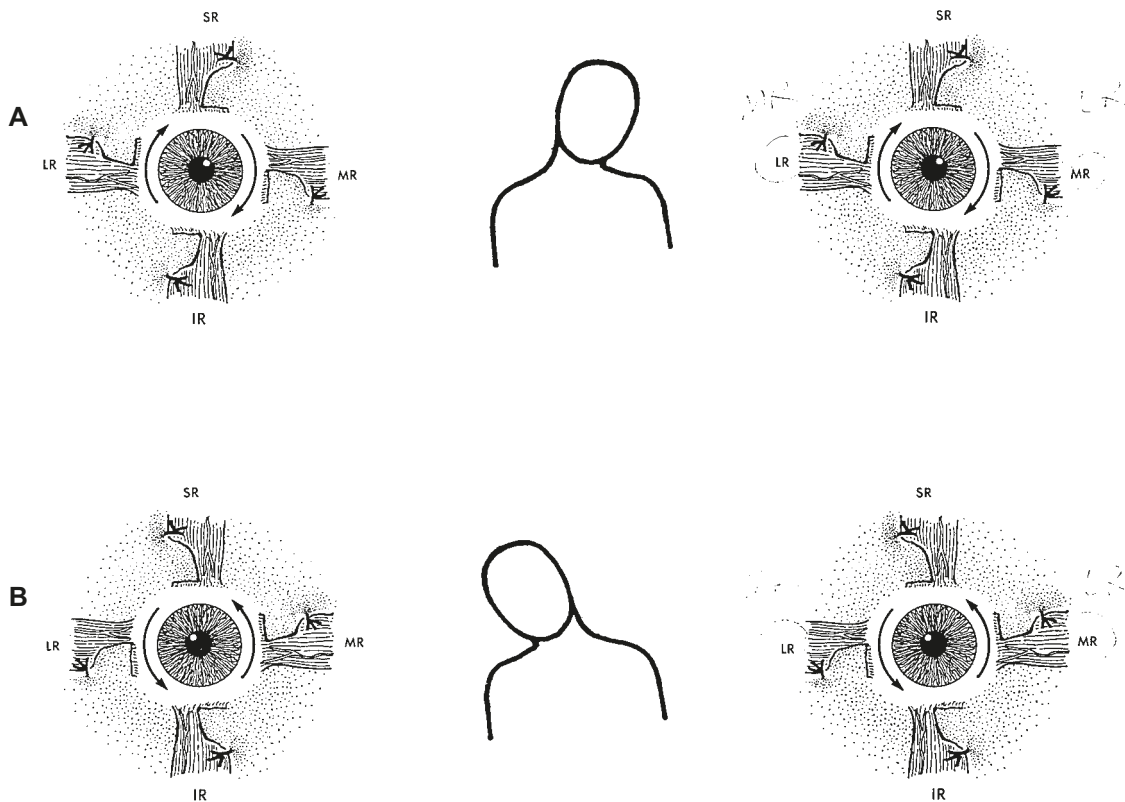


Figure 26

A For head tilt to the left, the nasal half of the right superior rectus and the temporal half of the left superior rectus is recessed and this procedure is continued around the globe to rotate the eye in the direction of the head tilt.

B For head tilt to the right, the temporal half of the right superior rectus and the nasal half of the left superior rectus is recessed and this procedure is continued around the globe.

In addition to a recession, muscle transfer procedure may be carried out with sparing of the anterior ciliary arteries. When muscle transfer is done even more of the anterior ciliary arteries must be freed from the substance of the muscle to avoid excess traction on these delicate vessels.

After the muscle has been exposed, the anterior ciliary arteries are lifted up very gently with a fine blunt muscle hook or cannula. A small snip incision must be made in the muscle capsule with delicate blunt dissection parallel to the anterior ciliary artery.

A fine suture is placed very gently around the anterior ciliary artery and the artery is lifted away from the muscle. The artery should be dissected free from the muscle several millimeters farther than the muscle is to be recessed. For example, if the muscle

is to be recessed 5 mm, 7 to 8 mm of anterior ciliary artery should be freed from the muscle. Two single-arm sutures are then placed at the muscle's edge 1 mm behind the insertion and separated from the intact anterior ciliary arteries.

The sutures are put in sclera (pre-placed) at the intended point of recession to prevent the muscle from retracting so far into the orbit that the fragile anterior ciliary arteries are ruptured (Figure 27).

With the anterior ciliary arteries retracted away from the muscle and with the pre-placed recession sutures in place but looped away from the insertion, the muscle is detached from its scleral insertion.

The muscle is tied down to sclera at the intended point of recession. The intact anterior ciliary arteries continue to function uninterrupted.

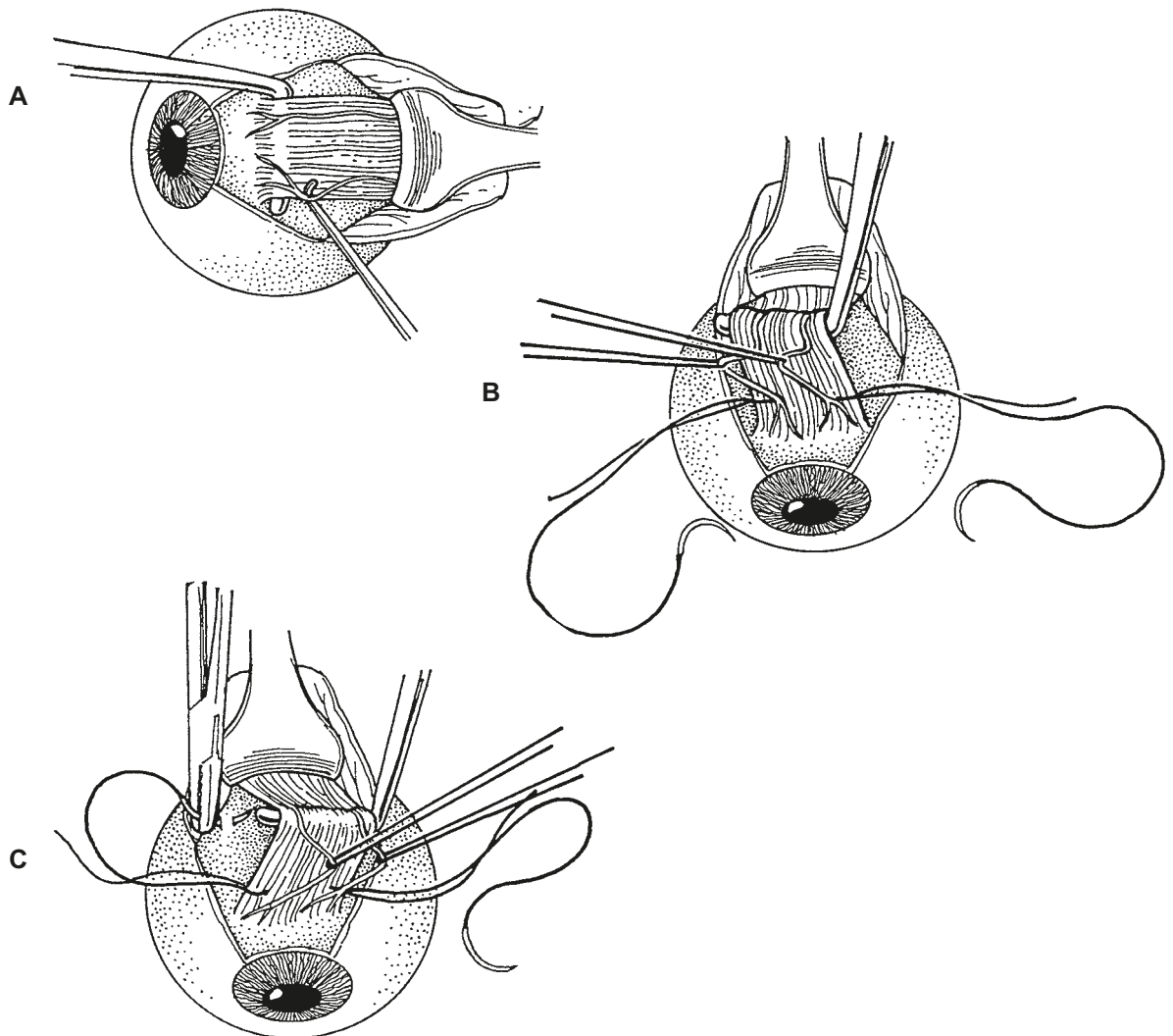


Figure 27

- A** The anterior ciliary artery is dissected from the muscle substance and is lifted on a small hook or cannula.
- B** Sutures are placed at the borders of the muscle while the arteries are lifted.

- C** Sutures are placed in sclera at the point of intended recession.

continued.

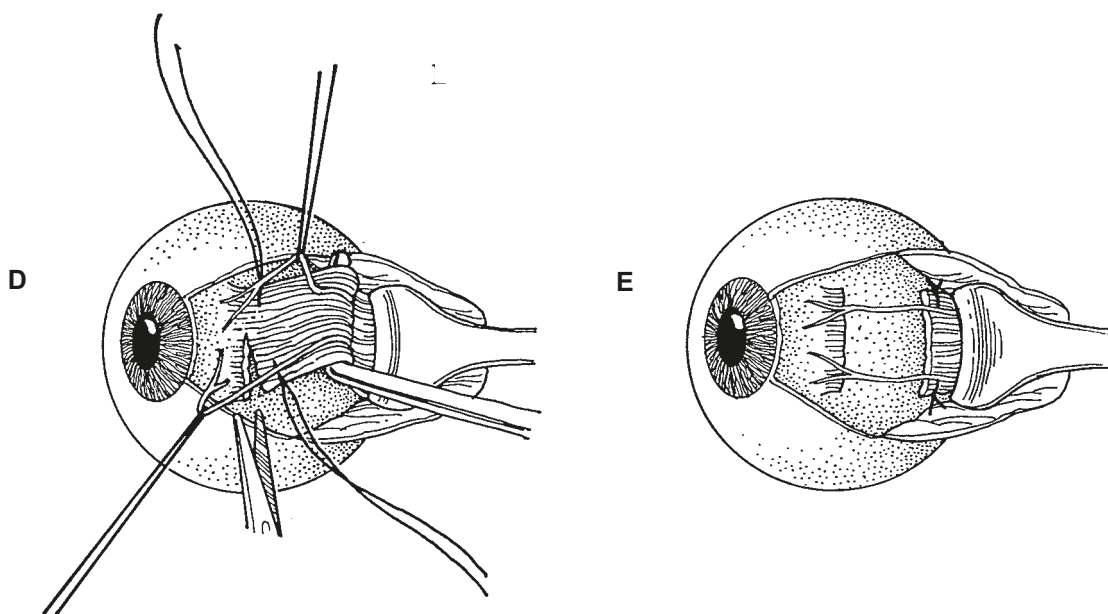


Figure 27, cont'd

- D The muscle is cut from its scleral insertion.
- E The muscle is attached to sclera, the ciliary arteries remaining intact.

Slanted recession

Slanted reattachment of a recessed horizontal rectus muscle suggested by Nemet has been used for treatment of 'A' and 'V.' The muscle edge that is to be weakened more is recessed farther back compared to the other edge. This follows the principle of selective weakening by moving the entire muscle in the direction that you intend to weaken the muscle (Figure 28).

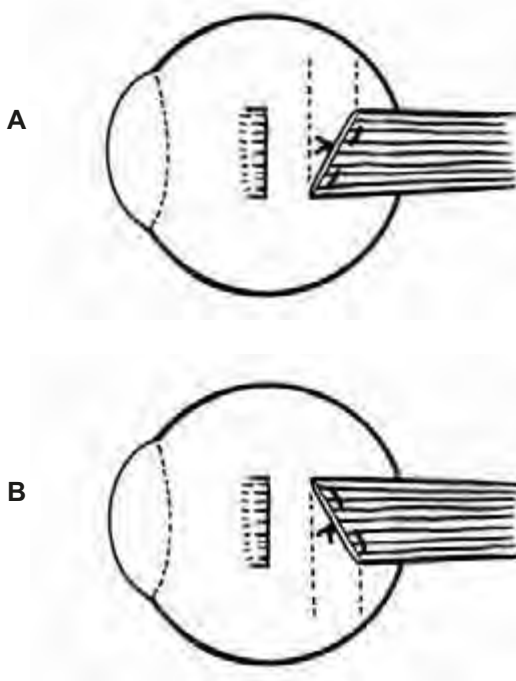


Figure 28

- A Medial rectus top edge recessed 5 mm farther for treating an 'A' esotropia.
- B Medial rectus recession with the lower edge recessed 5 mm farther back to treat a 'V' esotropia.

‘Y’ split of the lateral rectus

In cases of Duane syndrome with a tight lateral rectus co-contraction of the medial and lateral recti can cause the eye to ‘shoot’ up or down as you would pinch a slippery pumpkin seed through your fingers. The up and down shoot is caused by the ‘knife edge’ effect of the taut lateral rectus. To lessen this ‘knife edge’ effect, a ‘Y’ split can be employed to effectively broaden the lateral rectus insertion. To accomplish this, the muscle is isolated in the usual way. It is then split along the long axis for approximately 15 mm. Sutures are then placed in each of the isolated muscle halves. These muscle halves are detached and reattached to sclera with adjacent borders separated by 10 mm. The ‘Y’ split may be done with or without recession (Figure 29).

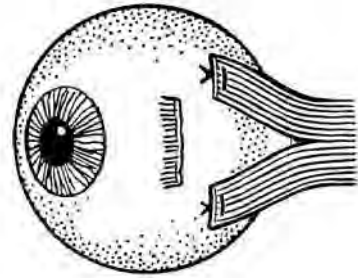


Figure 29

‘Y’ split of the lateral rectus can be done with or without recession in cases of tight lateral rectus muscle in Duane syndrome.

Resection of a rectus muscle

Overview

Resection of an extraocular muscle is generally classified as a strengthening procedure. But removal of all or part of a muscle's tendon with or without inclusion of some muscle fibers merely shortens and does not actively strengthen a muscle, at least after the initial reflex spasticity subsides. The principal benefit of a resection may be to enhance the effect of a recession procedure done on the antagonist muscle. Actually, if muscle fibers are removed at the time of resection, theoretically the muscle should be weaker! In the clinical setting, this does not seem to be the case. As I became more aware of the relationship between passive mechanical factors and dynamic neural factors in the surgical management of strabismus, I performed more recessions and fewer resections.

Although resection procedures are relatively easy to perform, they can result in more redness and 'lumpiness' of the conjunctiva, particularly in the area of the medial rectus. Natural barriers to orbital fat are also brought more anteriorly around the medial rectus, promoting the possibility of unsightly fullness after resection. Nevertheless, resection of a rectus muscle is indicated in many strabismus cases.

In addition to conjunctival problems that occur after resection of the medial rectus, palpebral fissure narrowing can occur after inferior rectus resection, and some ptosis of the upper lid, which is manifested by narrowing of the palpebral fissure, after superior rectus resection.

The inferior oblique may be included inadvertently during resection of the lateral rectus. This avoidable complication can cause limited elevation and/or depression in the involved eye, often with mechanical restriction causing unexpected horizontal and vertical strabismus. This complication occurs

more often than we had suspected. In a recent series of patients undergoing reoperation of the lateral rectus for both overcorrection and undercorrection and after resection or recession, 38% of patients had the inferior oblique included at the inferior border of the lateral rectus. Of course, this series studied only those patients needing reoperation; nonetheless, this specific surgical complication is one we encounter frequently in our practice.

As an alternative to rectus muscle resection, there has been a revival of the tucking procedure for these muscles. An advantage of tucking is that the anterior ciliary circulation of the tucked muscle can remain patent. I have used this technique on the 'last' rectus muscle in a patient who had had the other three rectus muscles detached.

Horizontal rectus resection (medial and lateral rectus muscles)

The minimum amount of resection of either a medial rectus or a lateral rectus muscle is 5 mm, regardless of the age of the patient (Figure 1). In general, a resection of a horizontal rectus muscle is less effective in altering ocular alignment than a recession of the same amount; hence the larger relative minimal values for horizontal rectus resection.

The maximum resection for a horizontal rectus muscle is 8 mm for infants less than 1 year and ordinarily 10+ mm for older children and adults. However, upper limit figures for resection procedures are very loosely adhered to, in contrast to the minimum figures which tend to be strictly followed. In a patient with a very large deviation and a reason to limit surgery to one eye, horizontal rectus resection of

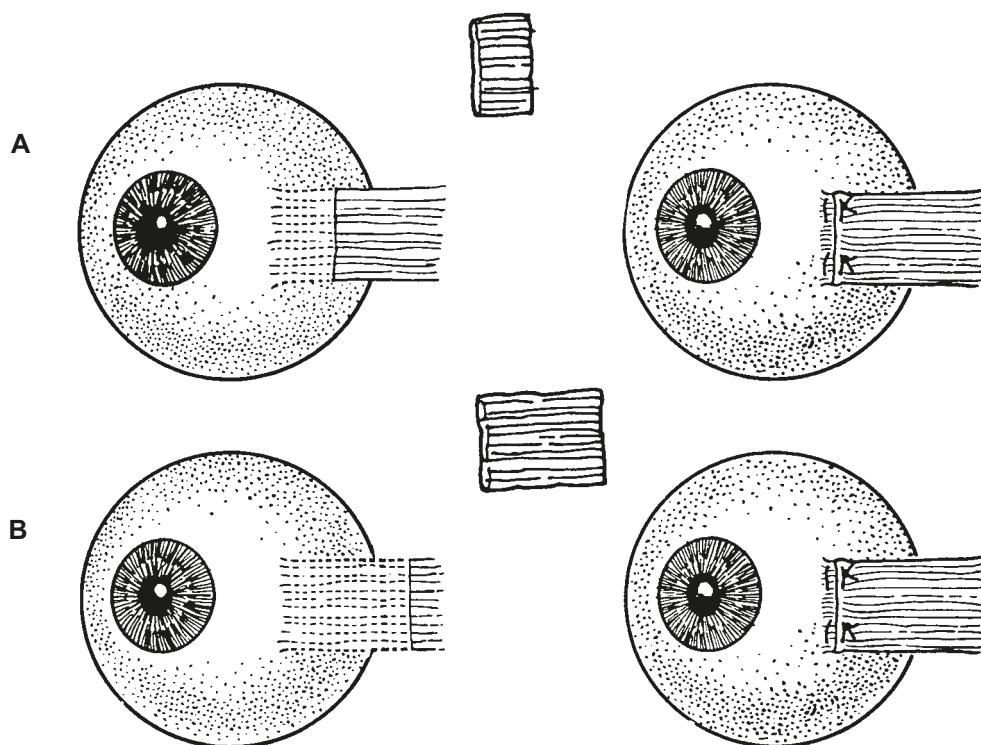


Figure 1

A Minimum dissection of a horizontal rectus muscle is 5 mm.

B Maximum resection of a horizontal rectus is 10 mm (in special cases this can be increased to 14 mm).

up to 14 mm may be performed. Some incomitance may result in these cases, but the benefits can outweigh the consequences of incomitance. For example, a blind eye with 90 prism diopters of exotropia occurring in a patient who wishes no extraocular muscle surgery on the seeing eye can be treated with a large resection of the medial rectus and a large recession of the lateral rectus, perhaps combined with a marginal myotomy. This maneuver will result in straighter eyes in the primary position, and, in my experience, the incomitance produced is not bothersome to the patient and is not a cosmetic defect. It is likely that more problems are created by horizontal resections that are too small than by those that are too large.

Management of the intermuscular membrane in horizontal rectus resection

Fifty consecutive horizontal rectus resections were performed using minimum and maximum dissection techniques alternately. It was found that a slightly greater effect and slightly more predictable resection results were obtained after maximum dissection of the intermuscular membrane. This finding is contrary to what was a popularly held belief that leaving as much of the intermuscular membrane as possible intact produces more effect with rectus muscle shortening or strengthening.

At the conclusion of the rectus muscle resection but before the conjunctiva is closed, additional dissection of the intermuscular membrane may be carried out. These attachments along with overlying tissue attachments to anterior Tenon's capsule are freed to allow these tissues to recede normally, reducing the bulky tissue over the resected muscle and increasing the likelihood of free ductions after surgery. During this dissection, care should be exercised to avoid entering the orbital fat space, which is just behind Tenon's capsule at the midpoint of the muscle (Figure 2).

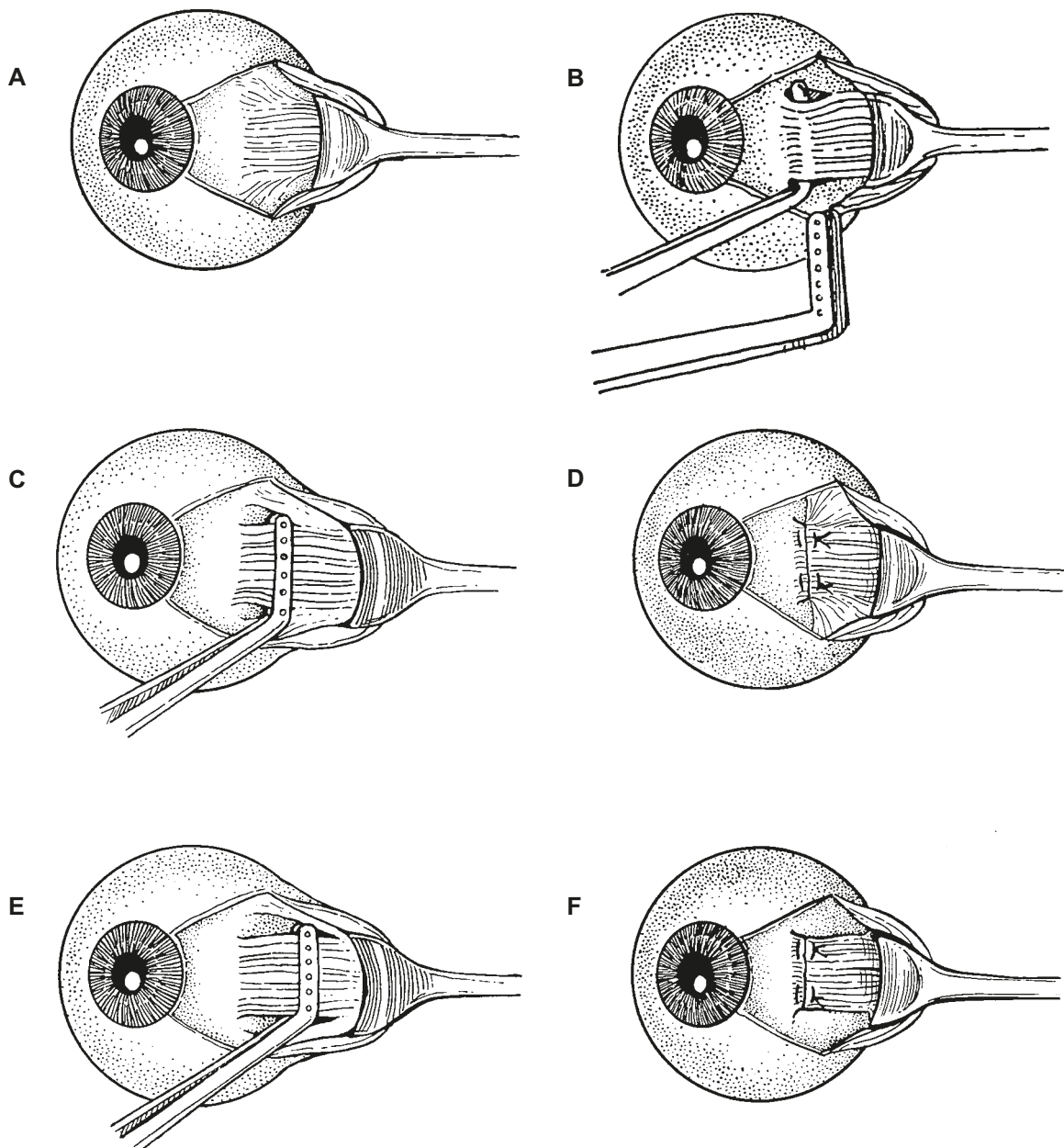


Figure 2

- A The rectus muscle in its capsule with intermuscular membrane intact.
- B Intermuscular membrane is dissected to the extent of the resection.
- C The resection clamp is placed - sutures are placed according to the surgeon's preference.
- D After resection the intermuscular membrane is at the level of the new insertion.
- E Or, the muscle clamp is placed after intermuscular membrane is dissected several mm posterior to the extent of resection.
- F The new insertion is free of intermuscular membrane. Be sure the muscle is firmly attached to avoid a possible 'lost' muscle!

Resection clamp technique for rectus muscle resection

The technique for resection of the medial and lateral rectus is identical. Our choice for suture material is 6-0 braided, coated synthetic absorbable with a .203 mm wire diameter spatula needle.

The muscle is exposed and the intermuscular membrane and check ligaments are dissected accord-

ing to the surgeon's preference. A muscle clamp is placed across the muscle to include the amount of muscle and tendon the surgeon intends to resect. A caliper is used to measure from the muscle hook, which is behind the insertion of the muscle, to the anterior edge of the clamp. Adjustments to the posi-

tion of the clamp are made if necessary. The muscle should not be stretched at this time. Some surgeons prefer to measure from a point just anterior to the muscle hook behind the insertion, to a point just posterior to the muscle clamp, the point where the sutures are eventually placed. Larger numbers will result when this type of measurement is made, but the same size resection will be accomplished. An important thing to remember when measuring a resection or any extraocular muscle strengthening or weakening procedure is that consistent technique by the surgeon is the only way to achieve predictable results. Because of likelihood for variations in technique, one surgeon's numbers do not transfer to another.

Suture placement

After the muscle clamp has been placed according to the measured amount of the intended resection, the tendon is severed from its insertion. A 1 mm tendinous stump should be left at the insertion to serve as an anchoring place for sutures. The sclera immediately behind the insertion of the rectus muscles is only 0.3 mm thick so this tendinous stump provides a safety factor during suture placement (Figure 3).

Double-arm sutures are inserted in a backhand manner through the tendinous insertion. At this time care should be taken to free the under surface and inferior border of the lateral rectus from the inferior oblique. If this is not accomplished, the inferior oblique could be brought forward to the new insertion of the resected lateral rectus, causing inferior oblique inclusion which produces a postoperative vertical and sometimes horizontal deviation.

The sutures are carried through the muscle behind or posterior to the resection clamp. The assistant grasps the needle tip and pulls the suture through. The two double-arm sutures are placed in a horizontal mattress fashion, first through the insertion, and then through the muscle behind the clamp (Figure 4).

After the sutures have been placed through the muscle, the resection clamp is loosened and moved to the tip of the tendon. A Nugent or other suitable forceps is used to hold the tip of the tendon while the resection clamp is advanced. Traction is placed on the muscle clamp to advance the muscle so that the point of passage of the sutures through the muscle is directly over the line of the original muscle insertion. The sutures are tied securely with a surgeon's knot. A hemostat is used to crush the tendon just anterior to the point where the sutures are tied. A battery-operated cautery is used at this point to cauterize the 'crush line' on the muscle to control bleeding before cutting off the muscle-tendon to be resected. Scissors are used to excise the excess tendon (Figure 5).

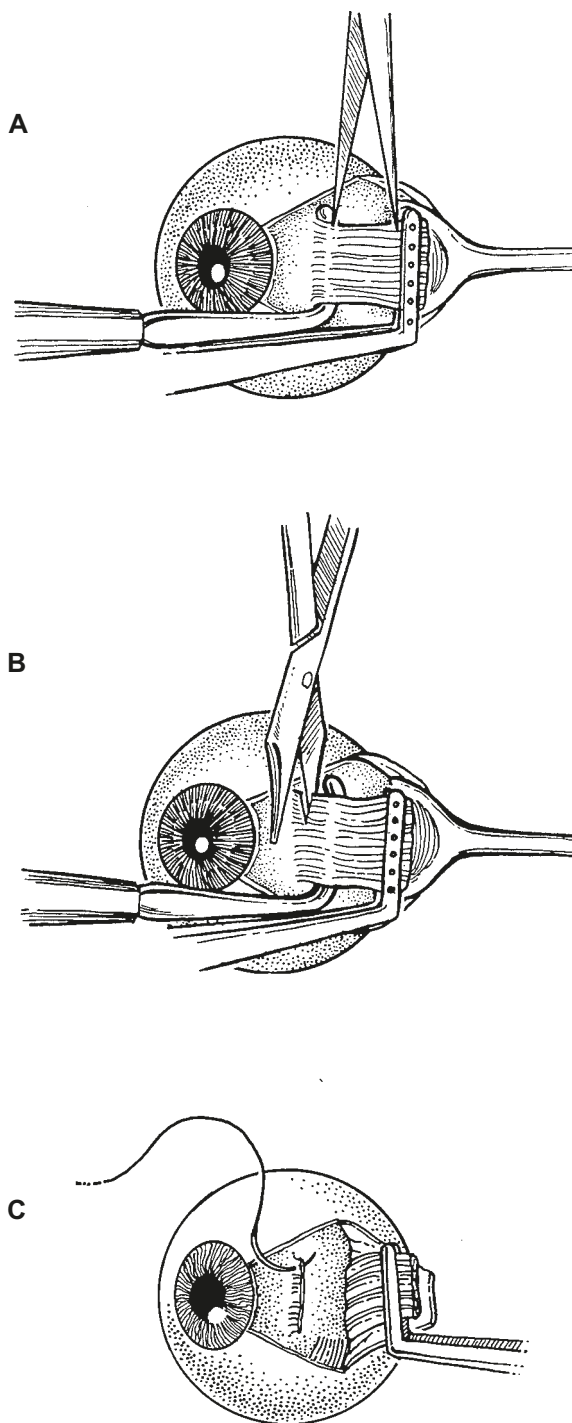


Figure 3

- A** Measuring the resection
- B** Cutting the muscle from the globe. Leave a 1 mm stump.
- C** A suture is placed 'backhand' through the stump.

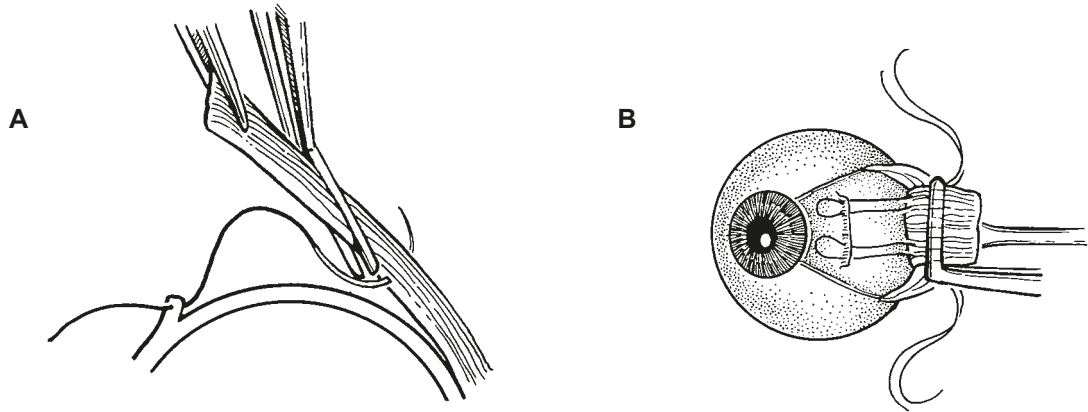


Figure 4

A The needle passes through the muscle behind the clamp.

B The process is continued with two double armed 'mattress' sutures in place.

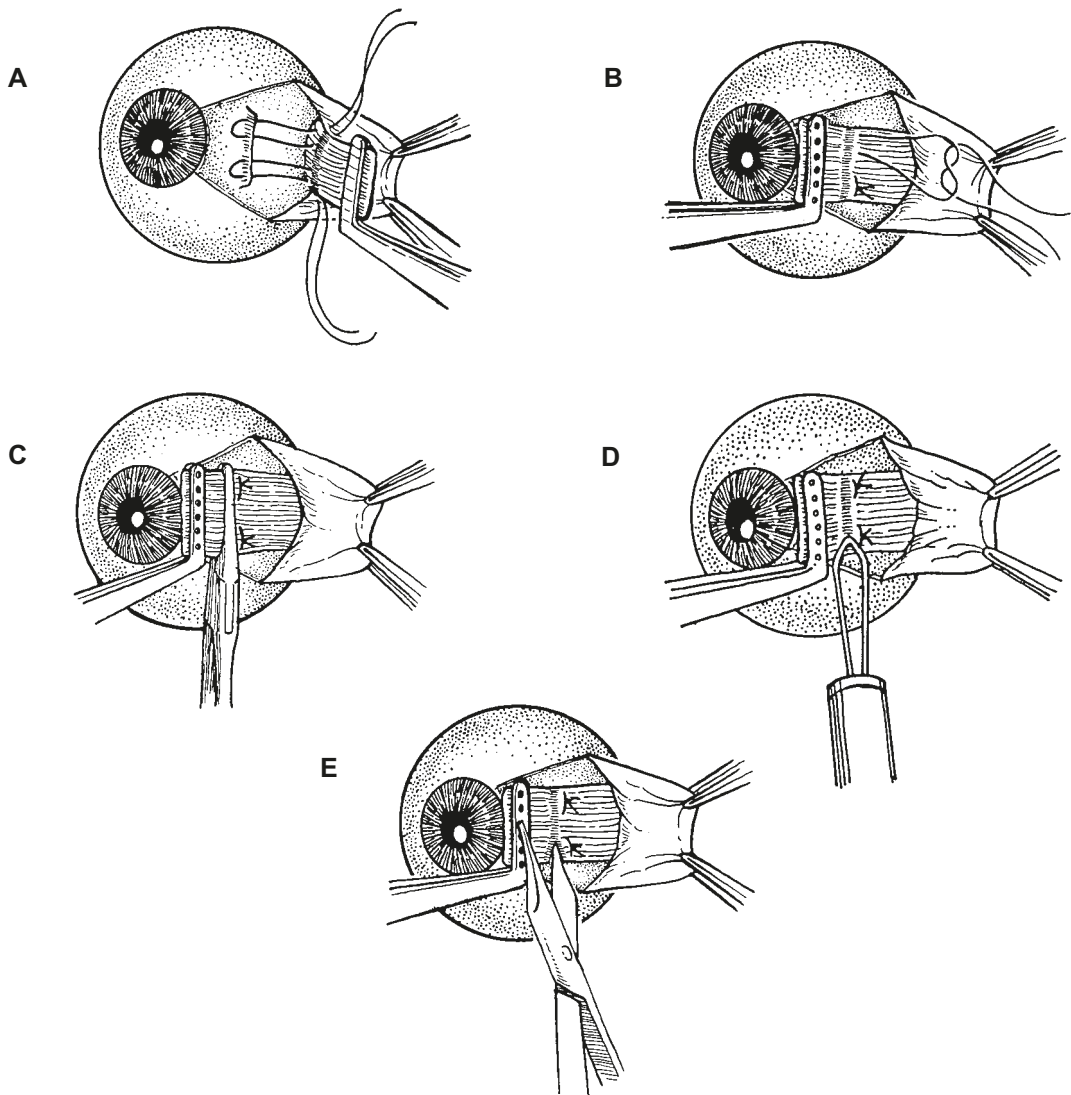


Figure 5

A The muscle clamp is advanced to the end of the muscle.
B The sutures are tied securely as the resection line is brought over the stump.

C The muscle is crimped just anterior to the sutures with a hemostat.
D The 'crimped line' is cauterized.
E The excess muscle tissue is excised.

With the excess tendon removed, the shortened muscle abuts the point of the original tendinous insertion. The double horizontal mattress sutures with bites several millimeters apart afford a secure union of the resected muscle across its entire width. A cross section at the point of union shows that the tendon stump and muscle are joined in a slightly puckered butt joint. This gradually settles over several weeks,

producing a smooth appearance to the conjunctiva overlying the resected muscle insertion. Sutures may be placed through the stump of the muscle from the muscle side. A lap joint is produced. It is also possible to put the needles through the muscle first and then through the insertion producing a butt joint (Figure 6).

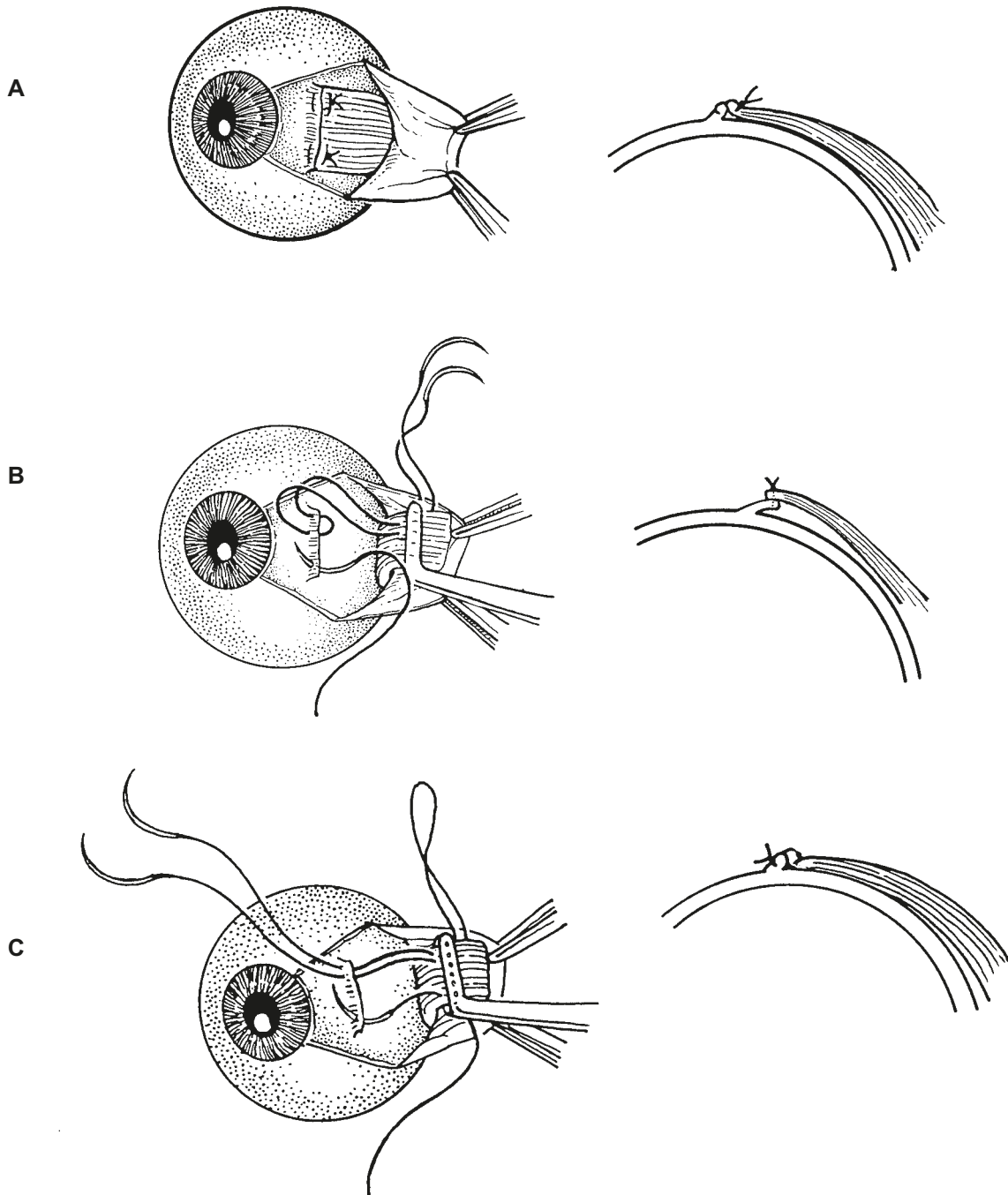


Figure 6
A A butt joint.
B A lap joint.

C Sutures brought through the muscle and then through the stump produce a butt joint.

Double-arm suture technique for rectus muscle resection

Some surgeons prefer to resect the rectus muscles, either horizontal or vertical, using one double-arm suture. This technique lacks some of the 'insurance' factors of using two separate horizontal mattress sutures, but, according to those surgeons who prefer this technique, it is completely safe.

The muscle is exposed and, after measurement, the extent of tendon and muscle resection is determined. A 6-0 synthetic absorbable suture is used to split the muscle at this point from edge to edge. A 3 mm loop is then taken slightly behind this suture line at each muscle border and the loops are locked. These loops should include the anterior ciliary vessels. The section of the muscle to be resected is

excised with scissors after the muscle is crushed with a hemostat just behind the insertion and just in front of the suture line. Each arm of the suture is brought out through the edge of the stump of the muscle's original insertion, and the suture may be tied to itself. For more security and to prevent sag of the muscle's new insertion, each suture may be brought back through the insertion near its center. The sutures are then brought through the central portion of the muscle from beneath. The suture is gently 'sawed' to bring the remaining muscle up to the original insertion. A surgeon's knot is tied, securing the resected muscle in place (Figure 7).

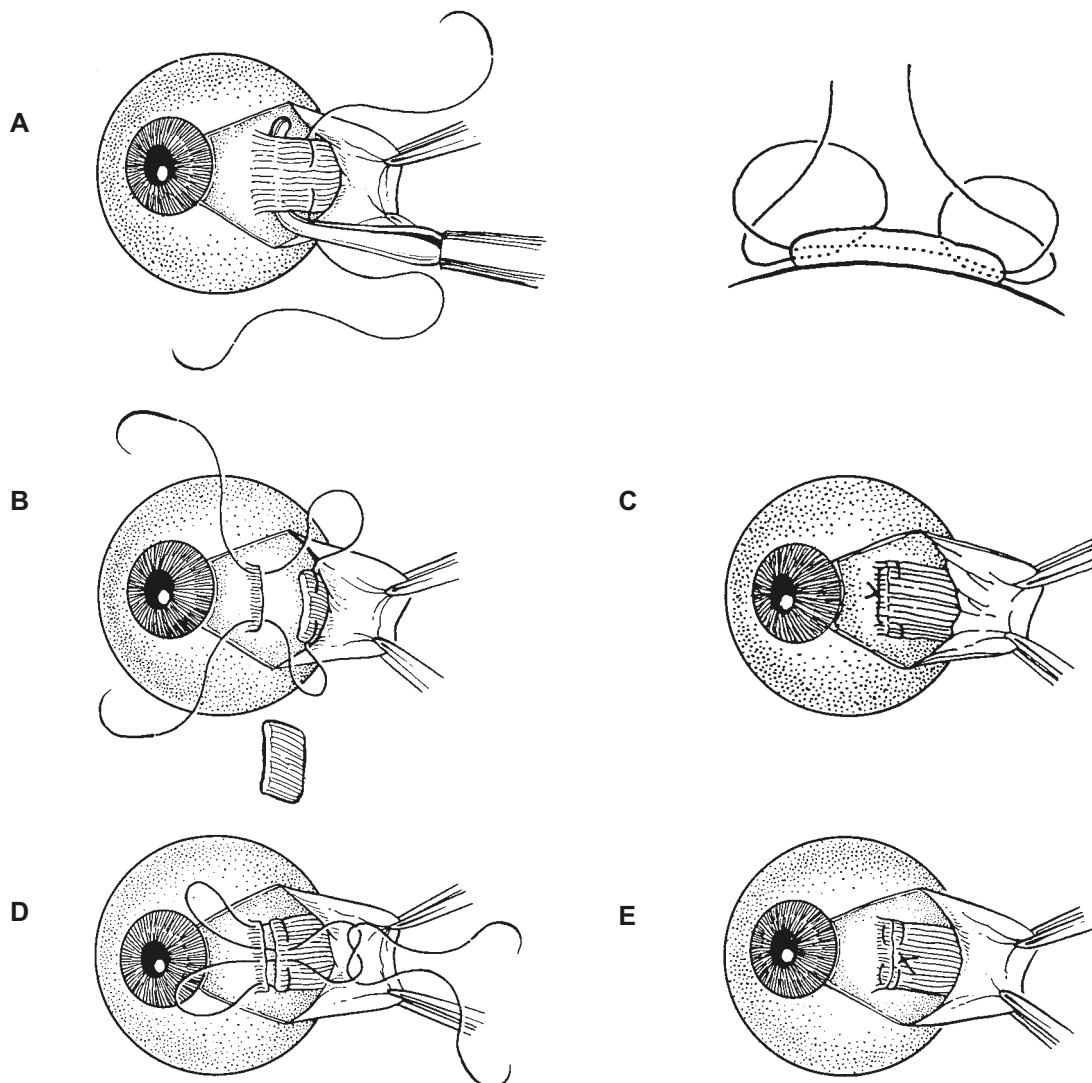


Figure 7

A A single double arm suture is placed suitable for the intended resection. Locking bites are then placed immediately behind the suture.
B After cutting out the section of muscle to be resected, the sutures are brought through the stump.

C The sutures are tied.
D For added security the sutures can be brought back through the stump and muscle...
E ...and tied securely.

Resection of the superior rectus

The minimum superior rectus resection is 2.5 to 3 mm and the maximum is 5 mm. Resection of less than 2.5 to 3 mm is probably ineffective, and resection of more than 5 mm causes a forward and downward shift of the upper lid, creating ptosis.

Because of the proximity of the superior oblique tendon to the insertion of the superior rectus, dissection of the intermuscular membrane of the superior rectus before resection must be performed carefully. This dissection should be carried back only a millimeter or so beyond the extent of the intended resection. The limited room available in the area of the superior rectus makes a free suture technique for resection preferable to the muscle clamp technique used by some for horizontal rectus resection.

After exposing the muscle, a single arm suture is placed at each muscle border at the intended point of resection. These sutures are tied with a square knot

ligating the anterior ciliary vessels. A hemostat is used to crush the tendon just anterior to the point of suture placement. A hot tip electrocautery can be used to seal off the vessels and reduce bleeding when the tendon is cut. Scissors sever the tendon along the crushed line just anterior to the point of suture placement. The tendon is trimmed from its insertion, leaving a 1 mm stump. The previously placed sutures are used to reattach the tendon to the muscle stump at the point of the original insertion. Very frequently a gap exists in the center of the muscle. A third suture placed at the center of the insertion eliminates the gapping and provides a more secure union of the muscle and insertion. A single double-arm suture or a tandem suture may be used in place of the two single-arm sutures according to the surgeon's preference (Figure 8).

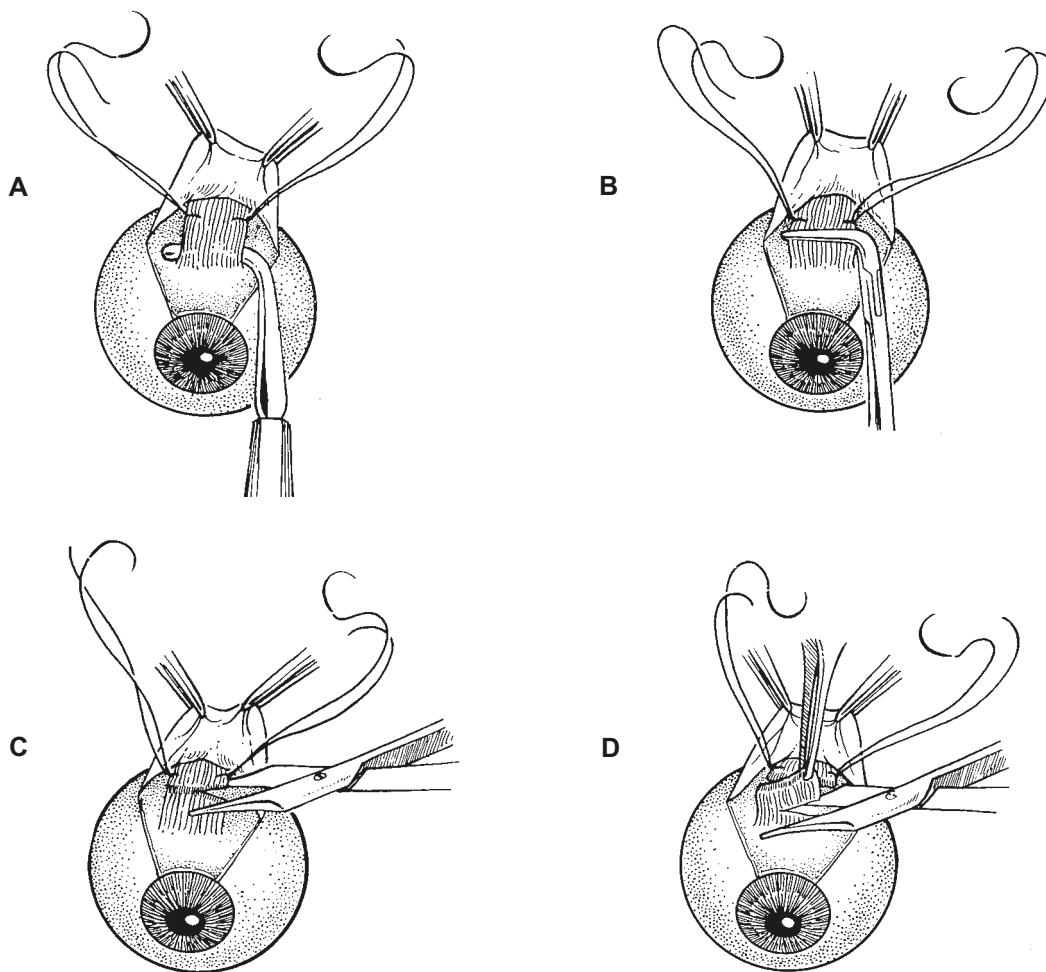


Figure 8

A Two single arm sutures are placed at the muscle border and are secured with a square knot.
B The muscle is crimped.

C The muscle is cut anterior to the sutures.
D The resected muscle is cut leaving a 1 mm stump.

continued.

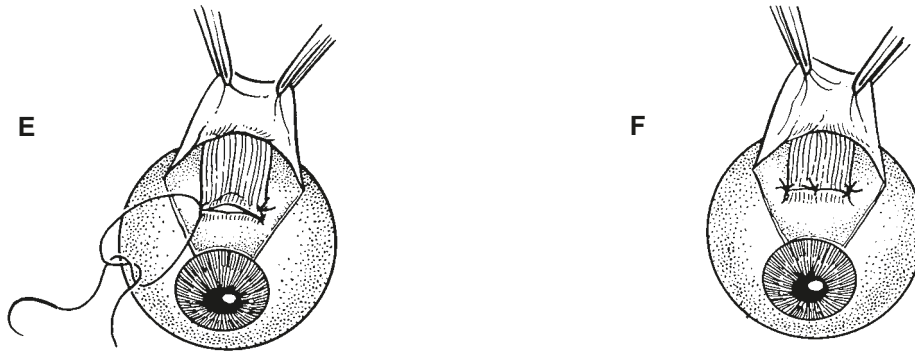


Figure 8, cont'd
E The sutures are tied

F An optional third suture is placed at the middle of the insertion to close any gap.

Inferior rectus resection technique

The minimum inferior rectus resection is 2.5 to 3 mm and the maximum is 5+ mm, under ordinary circumstances. However, when a very large hyperdeviation is present, the surgeon may in some instances safely resect up to 9 mm or more of the inferior rectus. The inferior rectus must be dissected carefully from its attachments to Lockwood's ligament. Also, between 8 and 12 mm posterior to the inferior rectus insertion, a vortex vein pierces the sclera adjacent to the inferior rectus muscle border. Great care should be exercised to avoid cutting a vortex vein.

To expose more of the inferior rectus muscle when a large resection is intended, two muscle hooks

are used to expose the area of the resected muscle and tendon before placing the sutures. After measurement with calipers, two single arm sutures are placed at the borders of the muscle. After a second pass through the muscle border these sutures are tied with a square knot. The anterior ciliary vessels should be ligated with this suture. The muscle is clamped just anterior to the line of suture. The tendon and muscle to be resected are excised using scissors. The two sutures are used to reattach the tendon to the original insertion and usually a third central suture is required to prevent gapping in the center (Figure 9).

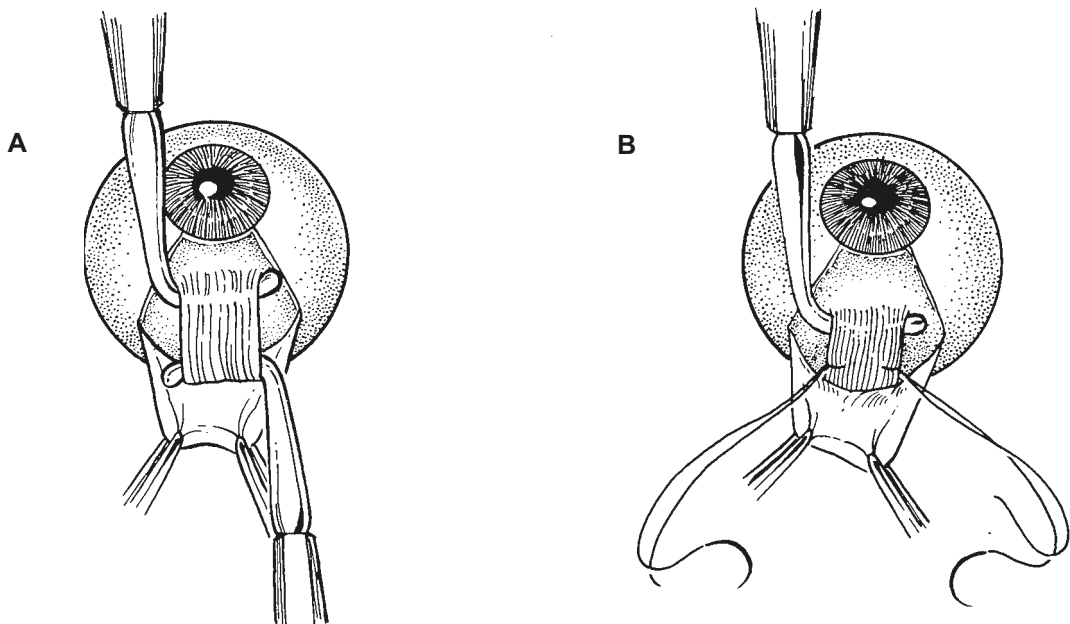


Figure 9
A A second hook exposes the inferior rectus back to Lockwood's ligament.

B Two double arm sutures are placed at the muscle borders, a second loop is added and secured with a knot.
continued.

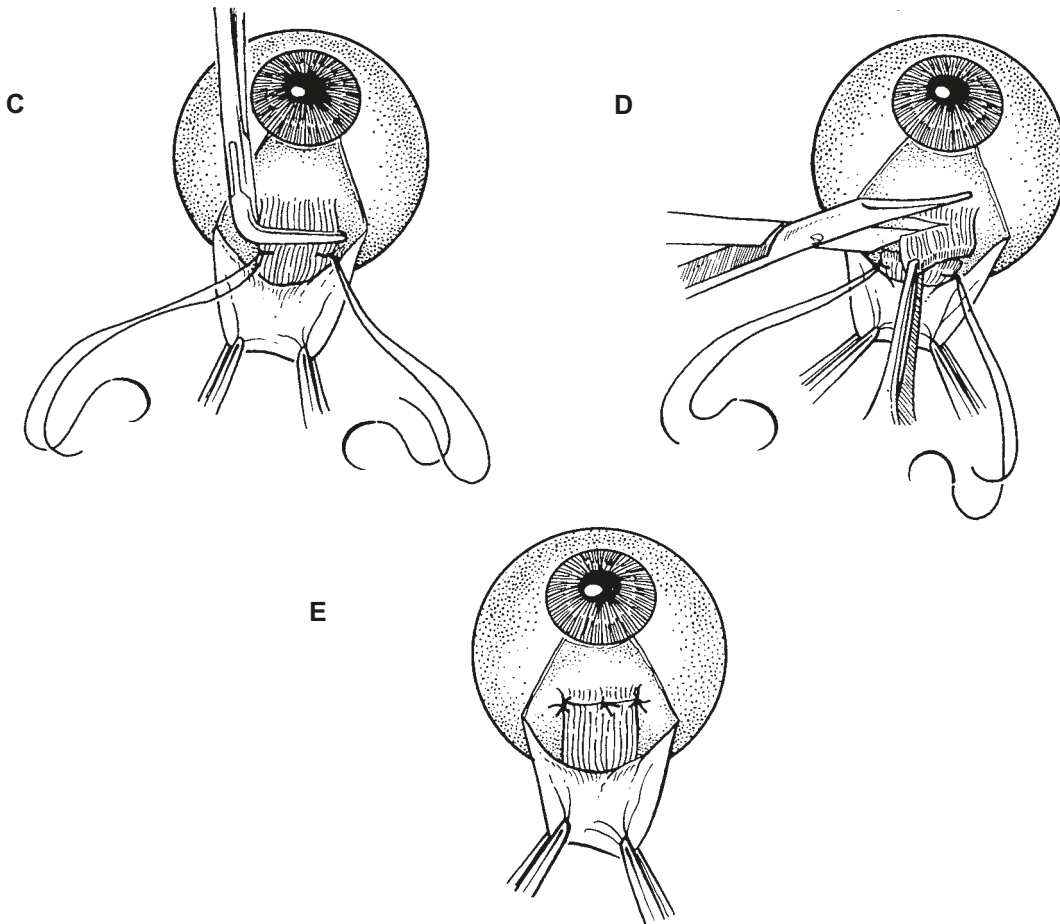


Figure 9, cont'd

C The muscle is crimped anterior to the sutures.

D The muscle is cut in front of the sutures and then at the insertion leaving a 1 mm stump.

E The muscle is sutured to the globe with a central suture added.

Tandem suture technique for rectus muscle resection

A reliable technique for rectus muscle resection is the tandem suture. With this technique, two separate double-arm sutures are woven through the muscle's thickness and are then locked at the muscle edges. This procedure is identical to placing a single double-arm suture for resection except that two double-arm sutures are used. The sutures are placed in the muscle stump and tied. The tandem suture produces a very tidy resection with the resected muscle abutting the resected muscle's insertion stump. Doubling the suture creates a secure reattachment. Also for adjustable resections and recessions, the tandem suture is effective (see chapter 12). I also use the tandem suture technique occasionally for horizontal rectus recession.

After the muscle has been exposed by adequate dissection, two double-armed 6-0 Vicryl braided, coated synthetic absorbable sutures with a 0.203 mm wire diameter spatula needle are woven through the muscle, splitting its thickness. They are locked with

3 mm locking bites at the muscle's border. The posterior suture is placed first, just behind the intended point of resection. The anterior or proximal suture is placed at the intended point of resection. This order of suture placement cuts down on bleeding because the posterior suture ligates the anterior ciliary vessels or at least most of them. A clamp is placed across the muscle to crush it, promoting hemostasis. A hot tip electrocautery is applied to the crush line to help ensure hemostasis.

After the muscle has been crushed and cauterized at the line of intended transection, the muscle is cut. The cut end of the muscle recedes and the proximal stump is held up with forceps and is cut from the globe, leaving a 1 mm stump of tendon at the insertion. The sutures are then brought through the muscle's stump with about 1 mm separating the sutures at the respective borders of the insertion. The suture ends are then tied producing a secure reapproximation of the cut ends of the muscle (Figure 10).

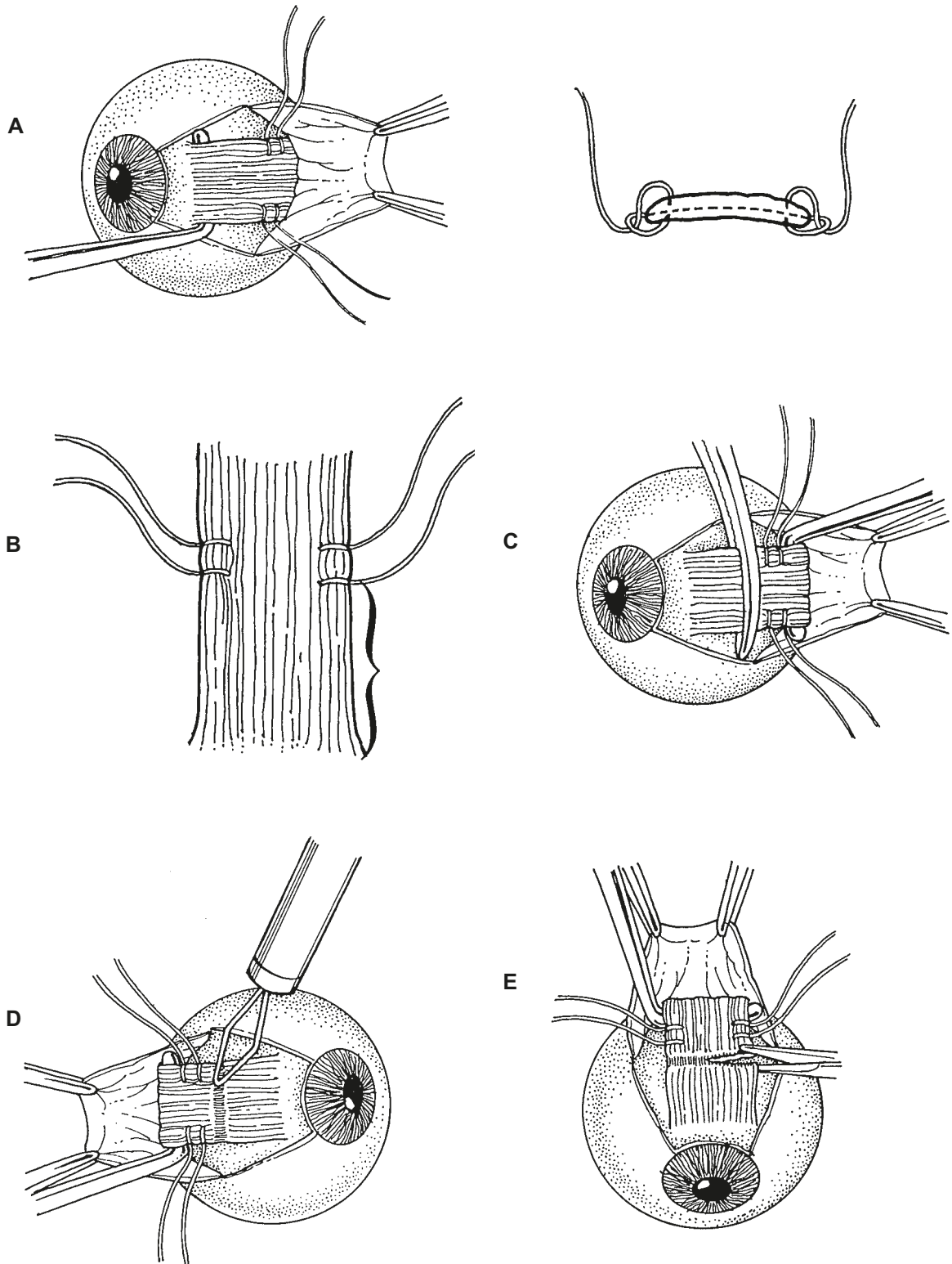


Figure 10

A Two double arm sutures are placed about 1 mm apart with an added loop secured with a knot.
B The anterior suture is at the point of intended resection.

C The muscle is crimped anterior to the suture.
D Cautery is placed on the crimped line
E The muscle is cut.

continued.

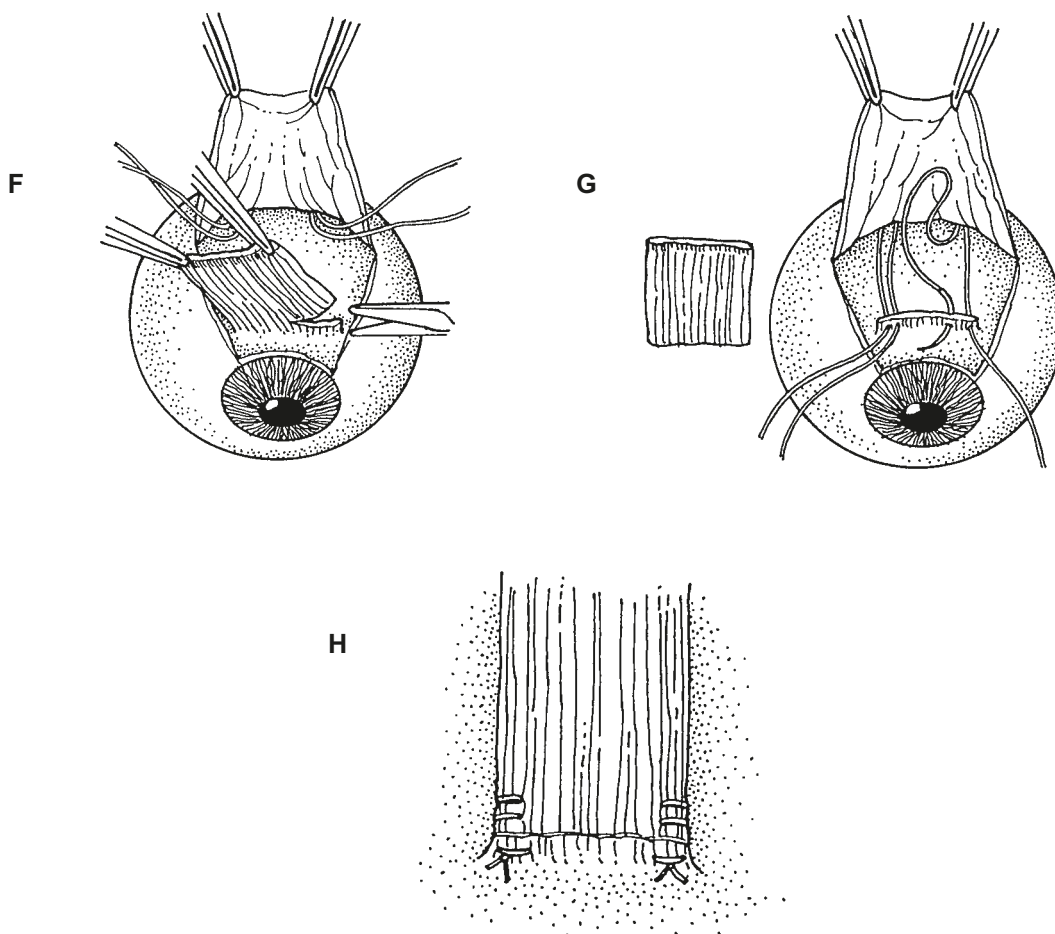


Figure 10, cont'd

F The excised muscle is cut from sclera leaving a 1 mm stump.

G Sutures are brought through the stump...
H ...and tied.

Plication (tuck) of a rectus muscle

When a rectus muscle is to be strengthened (shortened), an alternative method is the plication or tuck. This procedure has the advantage of retaining an undisturbed or less disturbed anterior ciliary circulation at least compared to the standard resection which transects these vessels. Some say that the plication when performed carefully produces less post-operative tissue reaction. Others say that an unsightly lump is produced. I use this procedure when it is necessary to preserve anterior segment circulation for any reason. Theoretically, a plication should be as effective as a similar sized resection. I have performed too few of the procedures to personally confirm this, but I believe it is true. This technique can be used on any of the rectus muscles.

After exposing the muscle, a double-arm suture is placed near each muscle border using a locking bite. The ciliary arteries are avoided. The sutures are placed a distance from the insertion equal to the intended amount of muscle shortening. A spatula or fine muscle hook lifts the muscle about halfway between the sutures and the muscle's insertion. The needles are then passed through the tendon at the insertion. The sutures are tied, bringing the point of suture placement up to the insertion creating a loop of redundant muscle-tendon and shortening of the muscle. The redundant loop of muscle-tendon is sutured to the muscle to reduce the bulk (Figure 11).

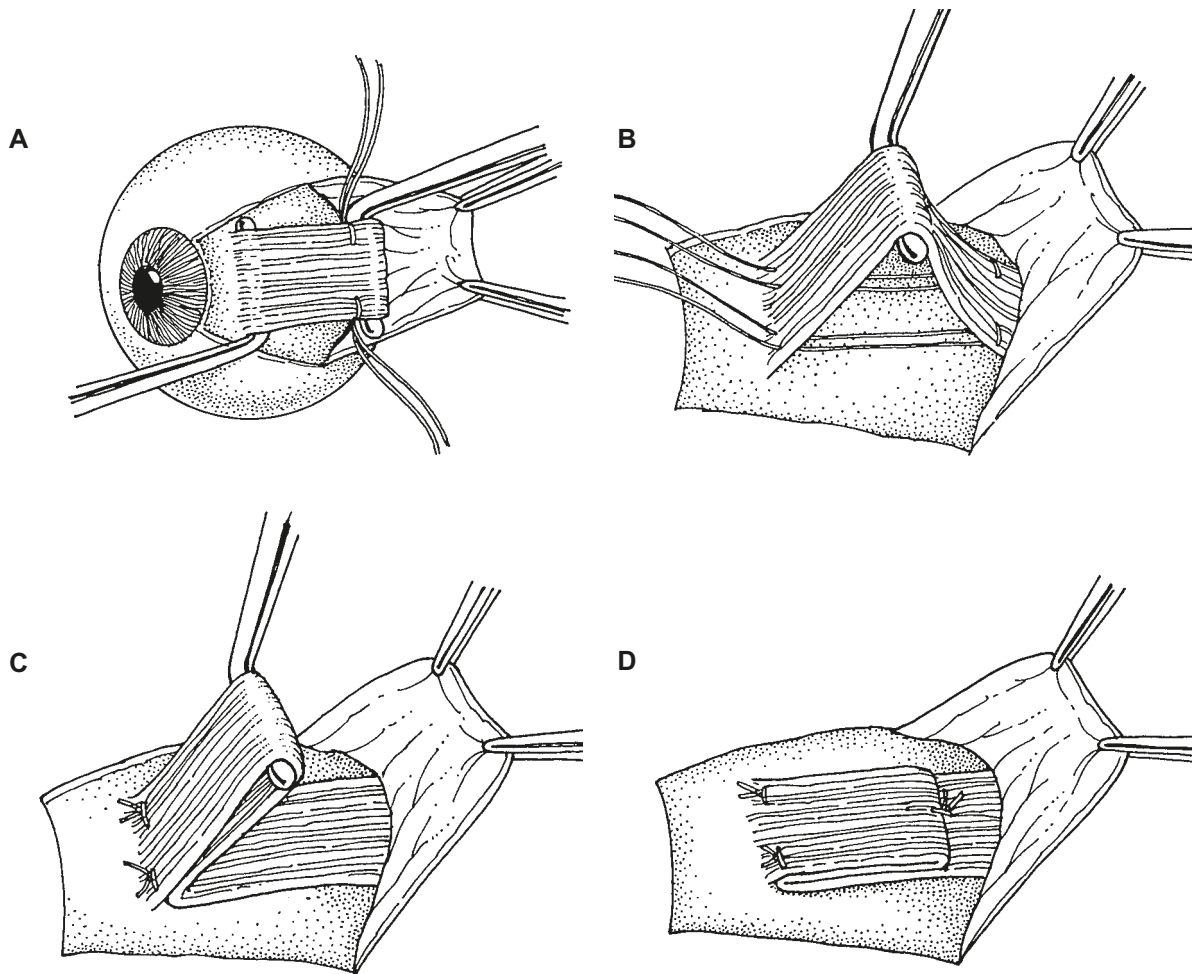


Figure 11

- A** A double arm suture is placed at each muscle border at the point equal to the intended muscle shortening and are secured with a knot.
B The sutures are brought through the insertion of the muscle.

- C** The sutures are tied creating a loop.
D The tip of the loop is secured to the top of the muscle.

Displacement of horizontal rectus muscles with resection for 'A' and 'V' patterns

As with all vertical displacements of the horizontal rectus for treatment of vertically incomitant strabismus, the lateral rectus muscles are moved toward the open end of the pattern, and the medial rectus muscles are moved toward the closed end of the pattern. The surgeon needs to remember that medial rectus muscles are weakened and the lateral rectus muscles strengthened for esodeviations; conversely, the medial rectus muscles are strengthened

and the lateral rectus muscles weakened for exodeviations.

A recession-resection procedure is carried out on the left eye of a patient with a V pattern exotropia. The resected left medial rectus is shifted one-half muscle width downward, and the recessed left lateral rectus is shifted one-half muscle width upward (Figure 12).

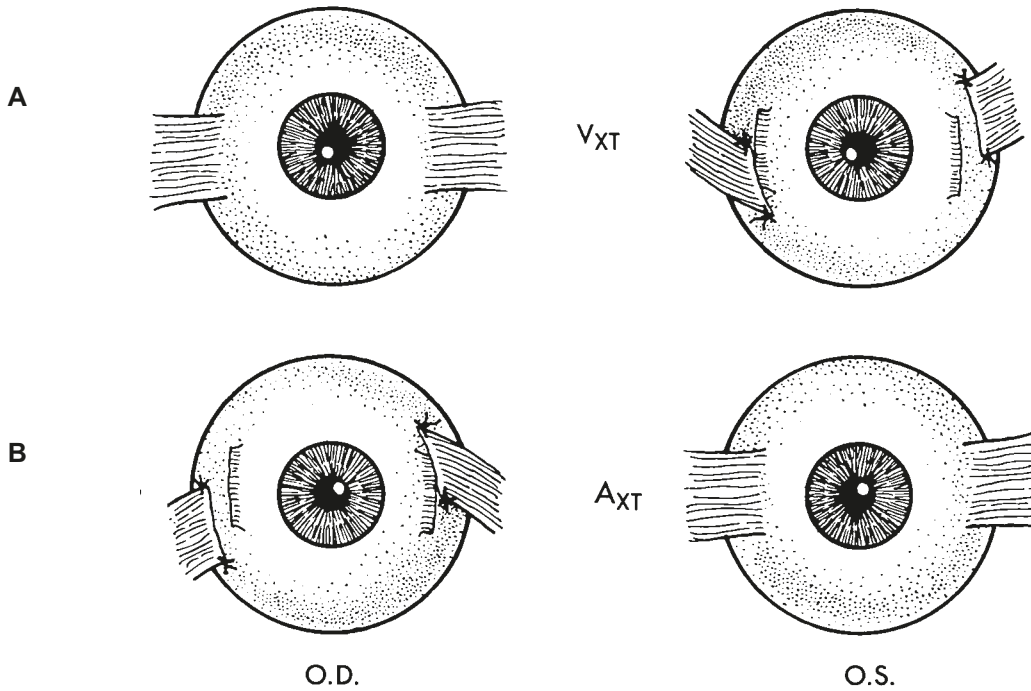


Figure 12

A The medial rectus is resected and moved down while the lateral rectus is recessed and moved up to treat a 'V' XT.

B The resected medial rectus is moved up and the recessed lateral rectus is moved down for an 'A' XT.

Vertical effect from horizontal rectus resection and recession

When performing a resection-recession procedure on a patient who also has a small to moderate vertical deviation, both rectus muscles may be shifted vertically in the same direction. This approach can treat the vertical deviation without altering the effect of the procedure for the esodeviation or exodeviation.

The muscles are moved upward one-half muscle width or more if the eye is hypodeviated and downward one-half muscle width or more if the eye is hyperdeviated (Figure 13).

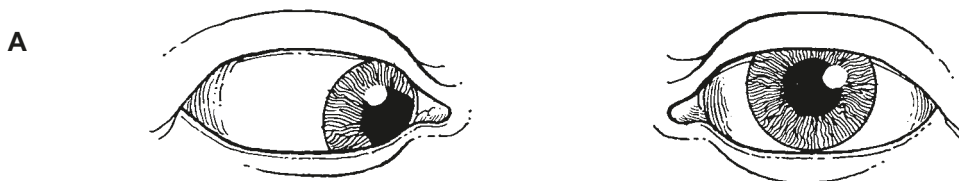

Figure 13

A The eyes are ET 40D with a right hypotropia of 15D.

continued.

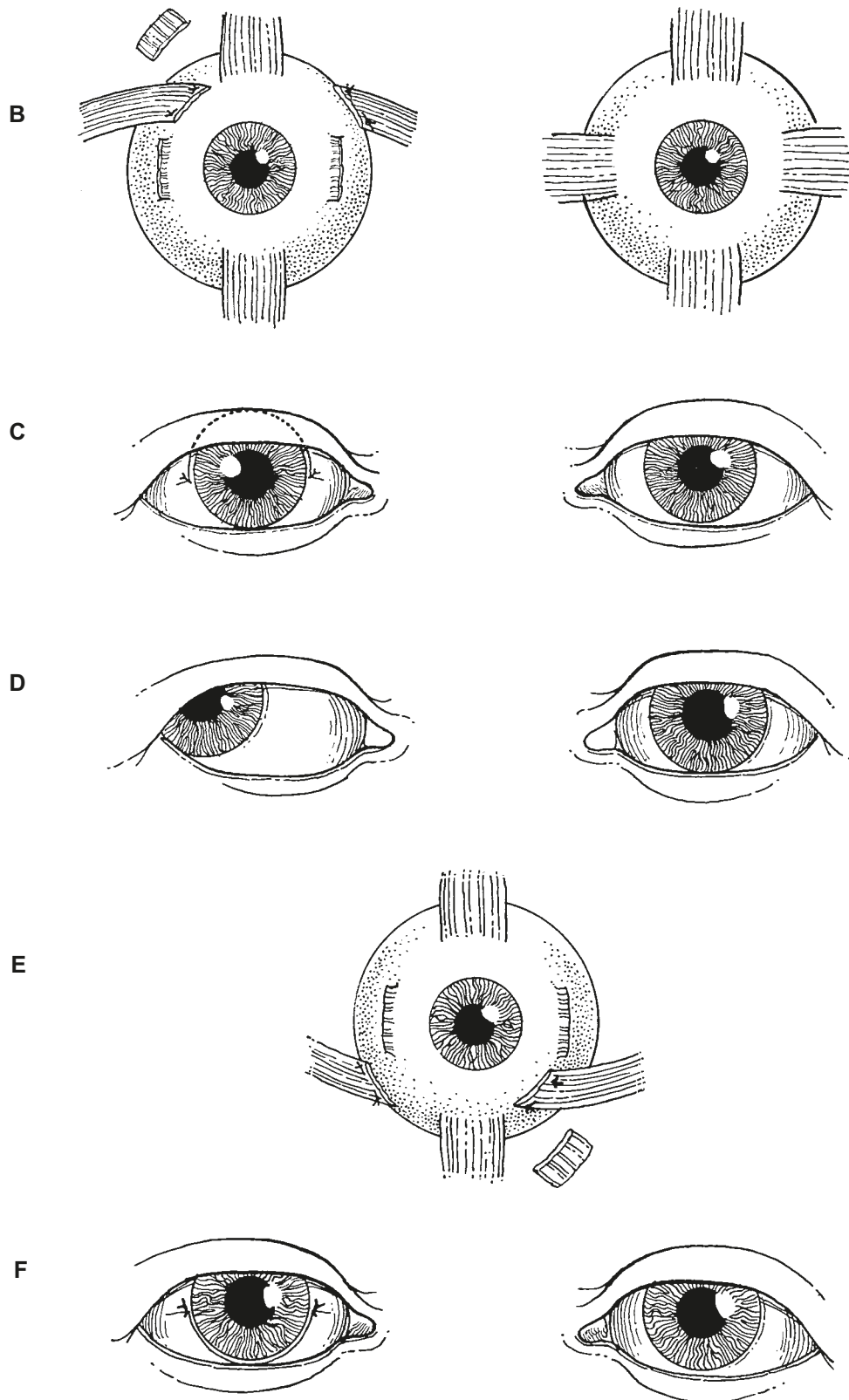


Figure 13, cont'd

B The medial rectus is recessed 5 mm (or approximately 10.5 mm from the limbus) and the lateral rectus is resected 8.5 mm. Both muscles are shifted one-half muscle width upward.

C The eyes should be better aligned vertically and horizontally after surgery.

D The eyes are XT 40D with a right hypertropia of 15D.

E The lateral rectus is recessed 7 mm and the medial rectus is resected 8 mm. Both muscles are shifted downward.

F The eyes should be better aligned vertically and horizontally after surgery.

Surgery of the obliques

Oblique muscle surgery

The superior oblique is the muscle most frequently affected in acquired extraocular muscle palsy at least as seen by the strabismologist. In the treatment of superior oblique palsy most of the surgical activity involves the other oblique muscle, the inferior oblique. For most indications, myectomy, recession, or anterior transposition of the inferior oblique are the most commonly performed oblique muscle surgical procedure. Inferior oblique weakening is commonly performed, usually bilaterally, to treat what is called 'primary' overaction of the inferior obliques and also for inferior oblique overaction after bimedial rectus recession. Both demonstrate strabismus sursoadductorius (elevation in adduction) and produce a 'V' pattern.

There are two important reasons why inferior oblique weakening is the surgery of choice in superior oblique palsy. The first and most important reason is to avoid attempts at 'strengthening' the superior oblique. Because the reflected tendon of the superior oblique has a limited potential amount of slack or redundancy, especially in acquired superior oblique palsy, tuck or resection of this tendon can cause an iatrogenic Brown's syndrome (restricted elevation in adduction). The second reason is that weakening of the inferior oblique muscle is simple, effective and predictable.

Surgical treatment of superior oblique palsy is usually indicated in unilateral cases because of asthenopia or constant or intermittent diplopia with or without head tilt. Bilateral superior oblique palsy is treated surgically because of nonfusible torsional diplopia and/or severe chin depression to deal with the 'V' pattern.

The superior oblique is the extraocular muscle most likely to be anomalous. These anomalies range from laxity or redundancy to a misdirected insertion or even absence of the reflected tendon and trochlea,

as occurs in some cases of congenital superior oblique palsy. This phenomenon was initially noted in cases with severe craniofacial abnormality. Later it was found in patients who were thought simply to have congenital superior oblique palsy. Patients with congenital superior oblique palsy who are subsequently found to have absence of the superior oblique tendon are likely to have one or more of the following features: horizontal strabismus, head tilt, amblyopia, facial asymmetry (with the fuller face on the side of the absent tendon), and marked underaction of the superior oblique.

In addition to these clinical findings that suggest a tendon anomaly, traction testing of the superior oblique tendon in the operating room at the time of surgery must be done to further identify tendon laxity. This test should be done in all patients with superior oblique palsy undergoing surgery. The superior oblique traction test provides reliable information about the state of the superior oblique tendon; information that is essential for the design of the appropriate surgical procedure. In cases with laxity of the tendon, which is the hallmark of congenital superior oblique palsy, the superior oblique traction test will be positive for a loose tendon. This test is deemed positive if the globe is retroplaced easily in the orbit and the normal taut superior oblique tendon with the globe 'popping' over is not felt. Instead, a less distinct or 'soft' tendon band or perhaps no tendon band at all is felt. Strengthening procedures on the superior oblique should be done only in cases where laxity of the tendon can be confirmed by this test or in selected cases with severe torsion. A positive (loose) traction test followed by exploration confirming that the tendon is anomalous confirms that the superior oblique palsy is of congenital origin, in my opinion. However, the question remains in the mind of some: Could prolonged paresis lead to secondary laxity or

elongation of the tendon? For congenital superior oblique palsy with a lax or misdirected tendon, I do a strengthening or shortening procedure of the superior oblique tendon. If the tendon is absent, the antagonist, or yoke muscle, is weakened and, in some cases, the ipsilateral superior rectus is weakened.

A newer oblique muscle procedure is the anterior transposition of the inferior oblique. This procedure is performed in cases of overaction of the inferior obliques with 'V' pattern and dissociated vertical deviation. The new insertion of the inferior oblique is placed just anterior to the temporal corner of the inferior rectus insertion. In addition to weakening inferior oblique action, it seems to have a tethering effect on the upward movement of the globe and therefore lessens the amplitude of vertical deviation of the DVD.

Stager has devised a procedure placing the new insertion of the inferior oblique *nasal* to the inferior rectus. This changes the inferior oblique from an extorter to an intorter and is therefore potentially useful in cases with large extorsion.

Other surgical procedures of the obliques include weakening procedures of the superior oblique usually performed by means of tenectomy, tenotomy, or disinsertion. Marginal tenotomy of the superior oblique has been described, but it is not a logical choice because it is either not effective or it becomes a complete tenotomy because of the cable-like makeup of the tendon. A few surgeons prefer to weaken the superior oblique by recession. No clear-cut difference in results of these weakening procedures has been provided. The complex anatomy of the superior oblique tendon as it relates to the superior rectus and superior orbital fascia contributes to the differing results from the various weakening procedures.

Transfer of the superior oblique tendon, without fracture of the trochlea, is accomplished in some cases of third nerve palsy. Fracture of the trochlea to achieve removal of the tendon is, in my opinion, not practical and should not be attempted. Shift of the anterior insertion fibers (or the entire insertion) is performed to enhance intorsion in selected cases of superior oblique palsy, especially in bilaterally involved individuals with torsional diplopia.

A technique for treating Brown syndrome employs a band of silicone used as an expander to lengthen the superior oblique tendon nasal to the superior rectus. A variety of procedures for weakening the superior oblique in cases of Brown syndrome are done, ranging from disinsertion of the posterior seven-eighths of the insertion to tenectomy near the trochlea. However, any technique can fail in some cases and succeed in others. This tells us that no surgical procedure or strabismus surgeon (at least that I have heard of) has the surgical answer for all cases of Brown syndrome.

A half century ago, the superior oblique was described as "nolo tangere" or "do not touch." This advice is no longer valid, but I would replace this advice with the recommendation for superior oblique surgery, 'handle with care.' In contrast, the inferior oblique is weakened frequently and in most cases results are good. While the superior and inferior are both oblique muscles, the similarity ends there.

Weakening the inferior oblique

Inferior oblique myectomy

When performed carefully, an inferior oblique myectomy can be completed with little or no bleeding and fat should never be encountered. Because the inferior temporal vortex vein may be encountered, it must be dealt with carefully to avoid rupture. If the vein is severed, copious bleeding will occur. This would be controlled with tamponade and/or cautery. Given the more or less blind sweep of the hook it is a pleasant and certainly welcome occurrence that vortex vein rupture in this area occurs so infrequently. In nearly 40 years, I have not seen this.

Persistent inferior oblique overaction can result if a slip of muscle is not cut or if the proximal cut end of the inferior oblique attaches to the sclera resulting in scarring and fibrosis. This is avoided by tucking the proximal end of the inferior oblique behind posterior Tenon's capsule.

The incision for exposure of the inferior oblique muscle is approximately 8 mm long. It is located 8 mm from the limbus and is concentric with it. It is also anterior to the inferior fat pad (Figure 1). The eye is stabilized in elevation and adduction with a locking forceps. One or two fine-toothed forceps are used initially to elevate the conjunctiva, Tenon's capsule, and intermuscular membrane, and a snip incision is made between the forceps, exposing bare sclera (Figure 2). Blunt-tipped Wescott scissors are inserted into the incision against bare sclera and the scissors tips are spread to separate with blunt dissection the filamentous attachments between the sclera and posterior Tenon's capsule.

To expose the anterior border of the inferior oblique muscle, the surgeon first places a large muscle hook behind the insertion of the lateral and the inferior rectus muscles. Then a third muscle hook is used to elevate the posterior border of the conjunctiva - Tenon's capsule incision. Deep in the incision at the junction of the sclera and posterior Tenon's capsule, the anterior border of the inferior oblique will be seen.

A small hook is placed flat against sclera, indenting it slightly with the tip toward the inferior rectus (or toward the lateral rectus). The hook is gently slid beneath the inferior oblique muscle until the orbital wall is felt. The tip of the hook is then rotated

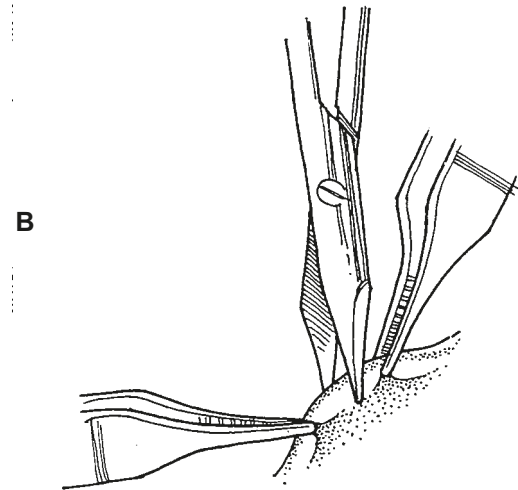
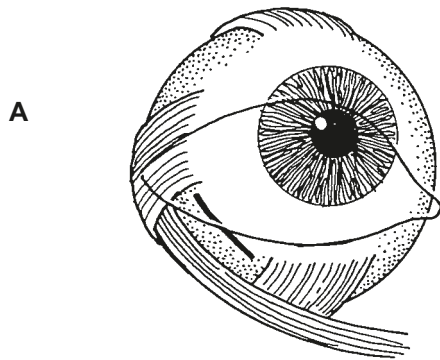


Figure 1

A The site of the incision for exposing the inferior oblique.

B A snip incision going through conjunctiva, anterior Tenon's capsule, and intermuscular membrane exposes bare sclera.

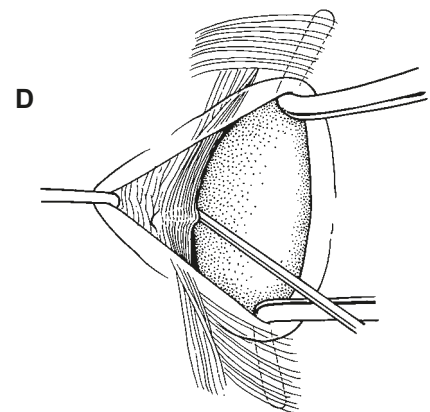
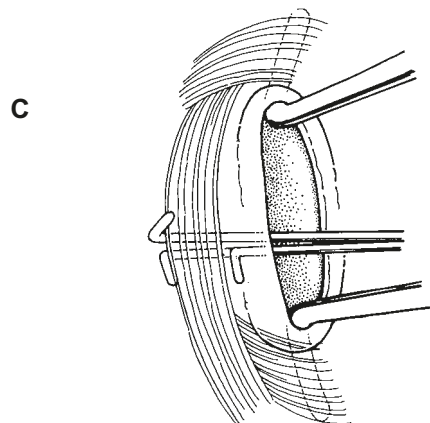
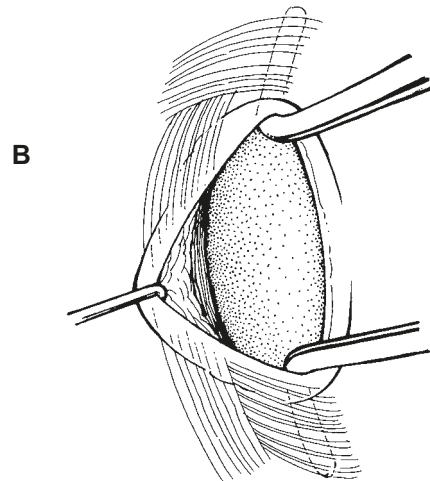
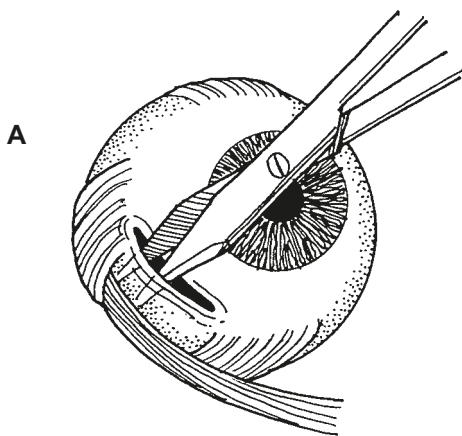


Figure 2

A Blunt dissection frees intermuscular membrane from sclera.

B Large muscle hooks are placed behind the insertion of the lateral and inferior rectus and a small hook lifts intermuscular membrane exposing the anterior border of the inferior oblique.

C A small hook slides posteriorly along sclera and is rotated when it is behind the posterior border of the inferior oblique.

D The small hook brings the inferior oblique forward.

until it points at the junction of the lateral and inferior orbital rim. As the inferior oblique is engaged, the hook retracting conjunctiva is pulled back to expose the tip of the small hook that shows through Tenon's fascia and is beyond the posterior muscle border. When the inferior oblique muscle is engaged on the teaser hook, the surgeon must take great care to bring the muscle forward, making sure that only the muscle

is included and avoiding making a hole in the intermuscular membrane (posterior Tenon's capsule) which would result in prolapse of orbital fat (Figure 3). Fortunately, the inferior temporal vortex vein is very infrequently ruptured. However, excess blind manipulation in this area should be avoided to lessen the chances of this annoying complication.

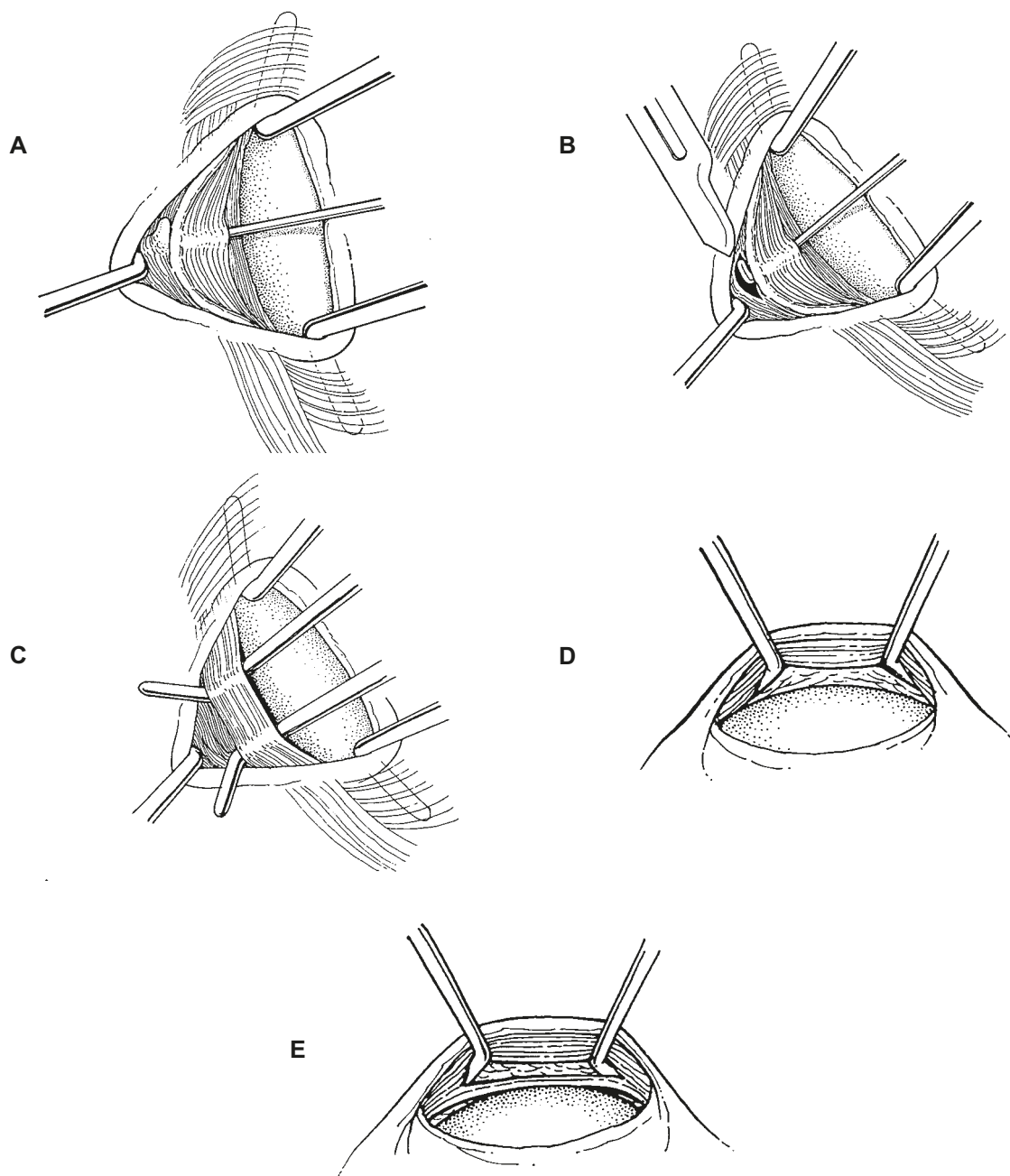


Figure 3

A The tip of the small hook is seen behind the posterior border of the inferior oblique.
B A knife or scissor exposes the tip of the hook.
C A second hook is introduced.

D The hooks, or larger hooks that have replaced the small hooks, are rotated to inspect the inferior oblique posterior edge of the inferior oblique with the under surface of posterior Tenon's capsule behind.
E If some inferior oblique muscle is seen behind the hooks, it is carefully included by placing a second pair of hooks.

A scissors or a scalpel blade is used to cut down on the tip of the small hook, exposing it behind the inferior oblique. A second hook is placed and the fascial layers associated with the muscle are dissected from the muscle, exposing 5 to 8 mm of the inferior oblique. The muscle hooks behind the insertions of the lateral and inferior rectus muscles may be removed as soon as the second hook is placed under the inferior oblique. The small hooks under the inferior oblique are replaced by two larger hooks, which are rotated away from the scleral surface and the undersurface of the inferior oblique. At this time it can be determined whether the entire inferior oblique has been engaged. A clearly defined border of the inferior oblique with white Tenon's capsule below

indicates that the entire inferior oblique has been engaged. At this point a vortex vein will be seen leaving sclera and passing through intermuscular membrane. If the inferior oblique has been hooked incompletely, a red stripe will be seen horizontally below the hooks. This strip of muscle should be picked up gently with two small hooks, repeating the procedure until the entire inferior oblique muscle has been engaged. Two hemostats placed 5 to 8 mm apart are used to clamp the inferior oblique muscle belly. With scissors or a scalpel blade, a 5 to 8 mm segment of the inferior oblique muscle belly lying between the hemostats is excised. Cautery is then applied heavily to each cut end for hemostasis (Figure 4).

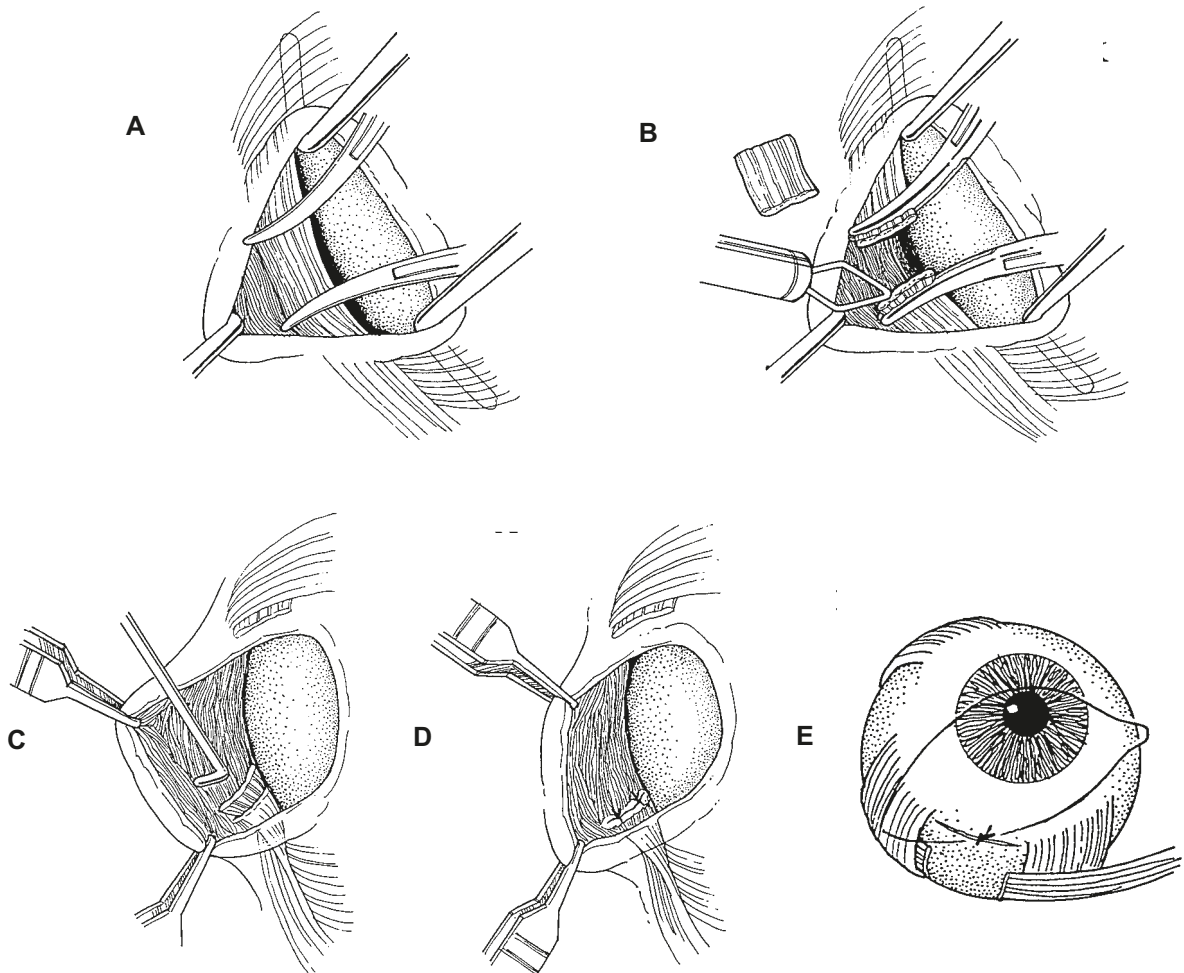


Figure 4

- A** Hemostats are placed with a 5-8 mm segment of muscle between.
- B** After the segment of muscle has been cut out with scissors or a scalpel, the cut ends are cauterized.
- C** The inferior oblique is allowed to retract or the inferior oblique may be 'nudged' into the hole in Tenon's.

- D** The small hole in posterior Tenon's capsule can be closed with an 8-0 absorbable suture.
- E** Conjunctiva is closed with an 8-0 absorbable suture.

After the hemostats are removed, the inferior oblique muscle is allowed to retract and the conjunctival incision is closed with either interrupted or running sutures, or this incision may be left unsutured, depending on the surgeon's preference. If the proximal cut end of the inferior oblique fails to retract into the space outside posterior Tenon's capsule, it can be 'nudged' into the space with the tip of a muscle hook or forceps. As the inferior oblique retracts into the defect in Tenon's capsule and approaches the lateral border of the inferior rectus, a small slit in posterior Tenon's capsule can be seen. This slit can be closed with one or two 8-0 Vicryl sutures.

A common complication of inferior oblique weakening and how to avoid it

As is the case with any of the extraocular muscles, the function of the inferior oblique depends on its having some tissue connecting the origin and insertion. Contraction of the muscle causes these two points to be brought closer together. The muscle's effect is manifested through movement of the globe toward the fixed point or origin of the muscle.

If in the process of performing a myectomy or any weakening procedure of the inferior oblique muscle the clamps or recession sutures exclude a portion of the muscle, a band of uninterrupted muscle tissue with associated intermuscular membrane remains connecting origin and insertion. A portion of the inferior oblique coursing uninterrupted between origin and insertion acts somewhat like a tendon. Inferior oblique weakening would then be less than expected.

This complication which causes undercorrections can be avoided. Careful inspection of the posterior aspect of the inferior oblique muscle reveals any remaining bands. These bands are engaged on muscle hooks and a myectomy is repeated on this smaller segment of the inferior oblique muscle. For an inferior oblique myectomy to be effective, a segment of inferior oblique that includes its entire width must be removed. A partial myotomy of the inferior oblique in my experience is ineffective. When disinsertion of the inferior oblique is chosen for weakening this muscle, care must be taken to sever the entire insertion. Some surgeons perform marginal myotomy of the inferior oblique and claim good results. I do not recommend this procedure.

Alternative weakening procedures of the inferior oblique: recession and disinsertion

Two other techniques for weakening an overacting inferior oblique are recession and disinsertion. Recession of the inferior oblique can be graded and is especially useful in cases where a minimal amount of weakening is required. Because the new inferior oblique insertion is placed at a specific point on the globe after recession, finding the inferior oblique at a subsequent operation is easier to accomplish than after myectomy or disinsertion.

The incision, localization, and exposure for recession or disinsertion of the inferior oblique muscle are the same as described previously for a myectomy. Recession of the inferior oblique muscle is begun by placing either two single-arm sutures or a single double-arm suture through the inferior oblique muscle near the lower border of the lateral rectus. (Figure 5). The suture is therefore placed approximately a millimeter from the muscle's broad insertion. To ensure inclusion of all of the muscle fibers at this point, careful inspection of the posterior border of the inferior oblique insertion should be carried out. The surgeon must detach the entire width of the inferior oblique muscle, freeing the muscle completely from the sclera for the recession to be effective.

The inferior oblique is reattached to the sclera at a point that depends on the amount of recession intended. Fink described an instrument for locating the point of reinsertion (see page 12), but recession is now usually accomplished by reattaching the inferior oblique in relation to existing landmarks. For example, Parks reattached the anterior corner of the inferior oblique 2 mm lateral and 3 mm posterior to the lateral border of the inferior rectus insertion. The posterior scleral reattachment is placed according to the width of the inferior oblique muscle. Other techniques reinsert the inferior oblique slightly more posteriorly. Regardless of the intended amount of recession, when the 'line of pull' of the inferior oblique is maintained the new effective insertion is at the lateral border of the inferior rectus. Changing the 'line of pull' of the inferior oblique, as in anterior transposition, both weakens the 'pull' of the inferior oblique and tethers or mechanically limits elevation.

Another technique for weakening the inferior oblique is disinsertion. In this procedure, after identifying and hooking the inferior oblique in the usual manner, the insertion of the inferior oblique is exposed while the lateral rectus is elevated on two muscle hooks. The inferior oblique is detached from the sclera. The muscle is allowed to retract and the incision is closed (Figure 6).

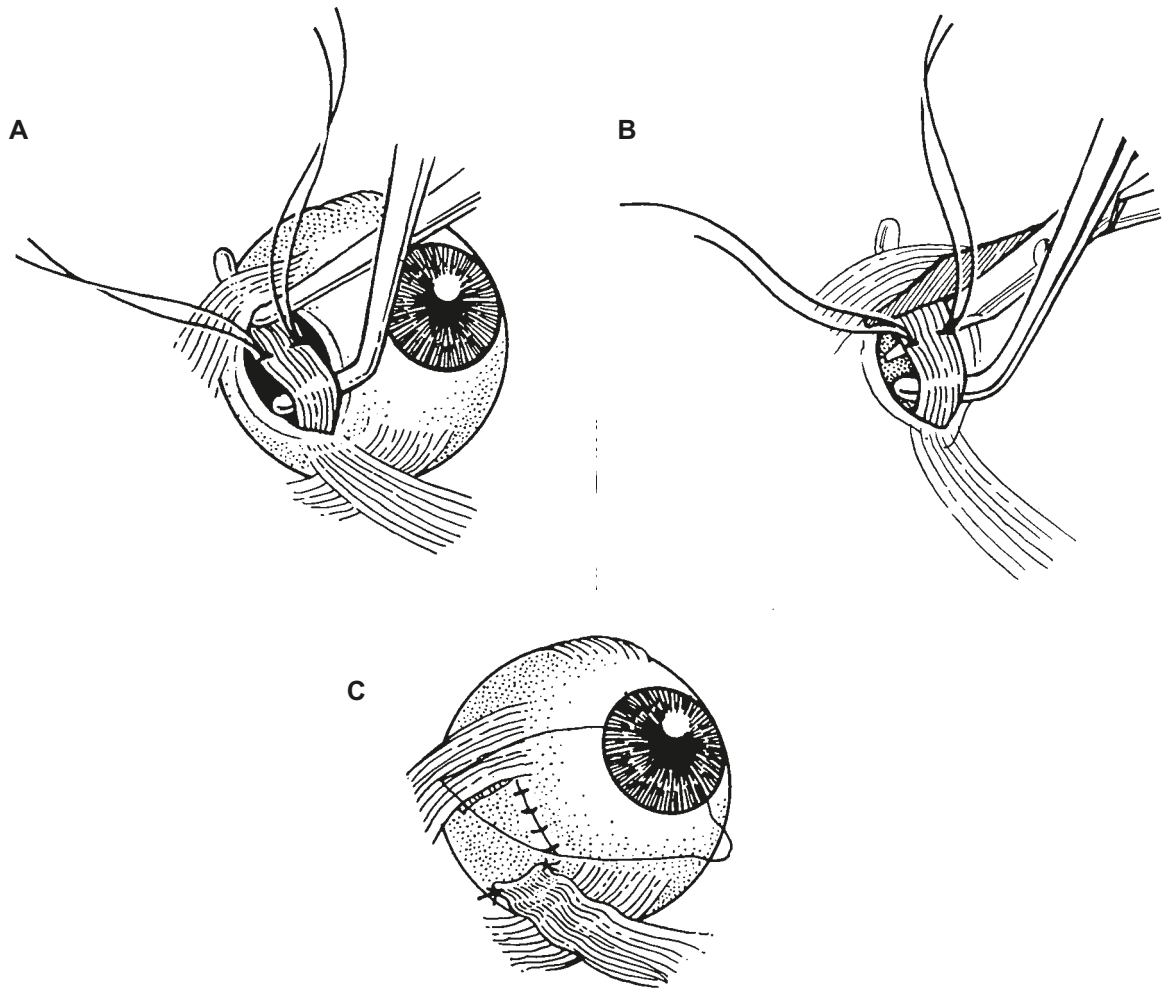


Figure 5

A For recession, after exposing the inferior oblique, the lateral rectus is lifted and one or two sutures are placed in the inferior oblique one or two millimeters from the insertion.

B The muscle is cut from the globe.

C The muscle is reattached along 'the line of pull' approximately 6 to 8 mm from the insertion.

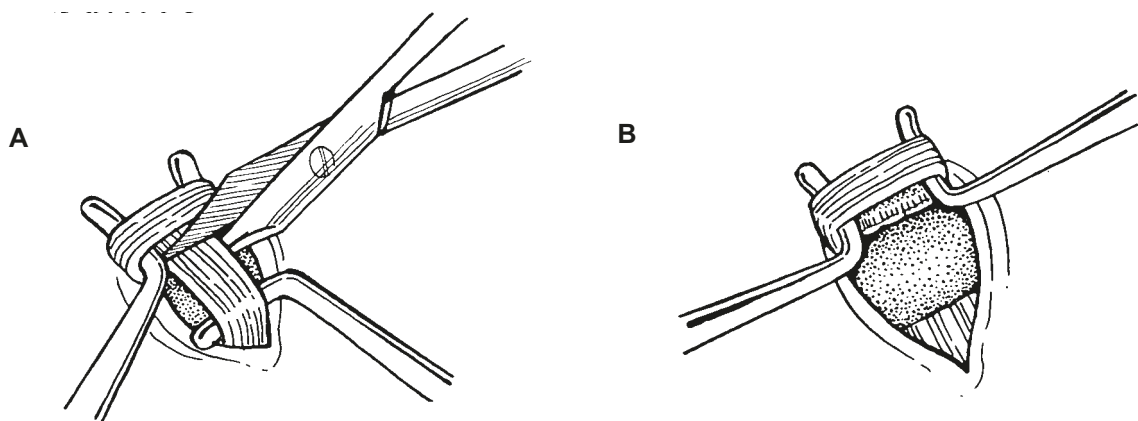


Figure 6

A For disinsertion, after exposing the inferior oblique in the usual way, the lateral rectus is elevated on two hooks exposing the inferior oblique insertion.

B The inferior oblique is cut at its insertion and is allowed to retract.

Extirpation of the inferior oblique

Gonzales described an alternative technique for weakening the inferior oblique that involved severing the nerve, a heavy structure that enters the inferior oblique at its posterior border as it crosses the inferior rectus. This nerve was cut and cauterized, but it grew back with time and inferior oblique function returned. Realizing this, he took the next step and removed as much of the distal inferior oblique as possible resulting in what was called denervation and 'extirpation.' The procedure was designed to treat and or prevent persistent overaction of the inferior oblique.

It did not gain widespread popularity. A possible reason is that other surgeons may not have had the same experience with persistent overaction of the inferior oblique after weakening. Parks redescribed extirpation of the inferior oblique in a manner nearly identical to that of Gonzales. It has been suggested that what some surgeons diagnose as persistent overaction of the inferior oblique actually may be unrecognized dissociated vertical deviation.

Extirpation of the inferior oblique which is really removal of the distal muscle and nerve seems unnecessarily ambitious when a simple procedure produces excellent results. Stager has added myectomy of the nasal portion of the inferior oblique to anterior transposition to weaken the inferior oblique while retaining depressor effect to treat dissociated vertical deviation.

Suture traction for exposure

For any procedure on the inferior oblique including extirpation, measured recession, or anterior transposition, exposure can be obtained using a heavy traction 4-0 or 5-0 silk suture under the lateral rectus insertion. It is placed behind the insertion of the lateral rectus with the heavy needle brought through the incision, behind insertion, and then through Tenon's capsule and the conjunctiva above (Figure 7).

To gain better exposure of the inferior oblique at the insertion, two large hooks spread the insertion, traction is placed on the black silk traction suture, and a spatula is used to indent sclera enabling placement of a small hook which will engage the inferior oblique. The inferior oblique muscle is dissected and pulled out of the incision (Figure 8). The insertion of the inferior oblique muscle is exposed and a hemostat is placed across the muscle. At this point the inferior oblique is detached flush with sclera. If recession or anterior transposition is performed, a suture (6-0 Vicryl) is placed and the procedure is carried out as described. If extirpation and denervation is the choice, the inferior oblique and its nerve are cut. The nerve retracts and the muscle is removed. The defect in Tenon's capsule may be closed with one or two fine absorbable sutures.

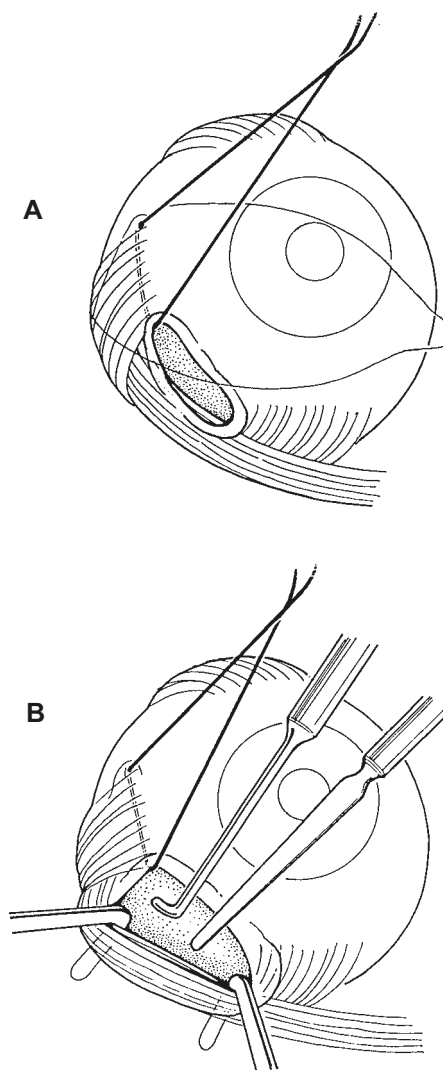


Figure 7

- A** After incision through the layers overlying sclera, a 4-0 black silk suture is placed behind the lateral rectus.
B Two hooks lift the inferior oblique, a spatula indents sclera, and a small hook slides behind the inferior oblique.

Anterior transposition of the inferior oblique

Anterior transposition of the inferior oblique was described by Elliott and Nankin. The effect of this procedure is, first, to weaken the inferior oblique eliminating so-called overaction that causes strabismus surso adductorius (elevation in adduction) and 'V' pattern; and, second, to restrict the supraduction from dissociated vertical deviation. This surgery shifts the new insertion of the inferior oblique adjacent and just anterior to the ipsilateral inferior rectus insertion. The most likely reason for the reduction of the dissociated vertical deviation after anterior transposition of the inferior oblique is the mechanical or tethering effect of the newly placed inferior oblique insertion mediated by the stout nerve to the inferior

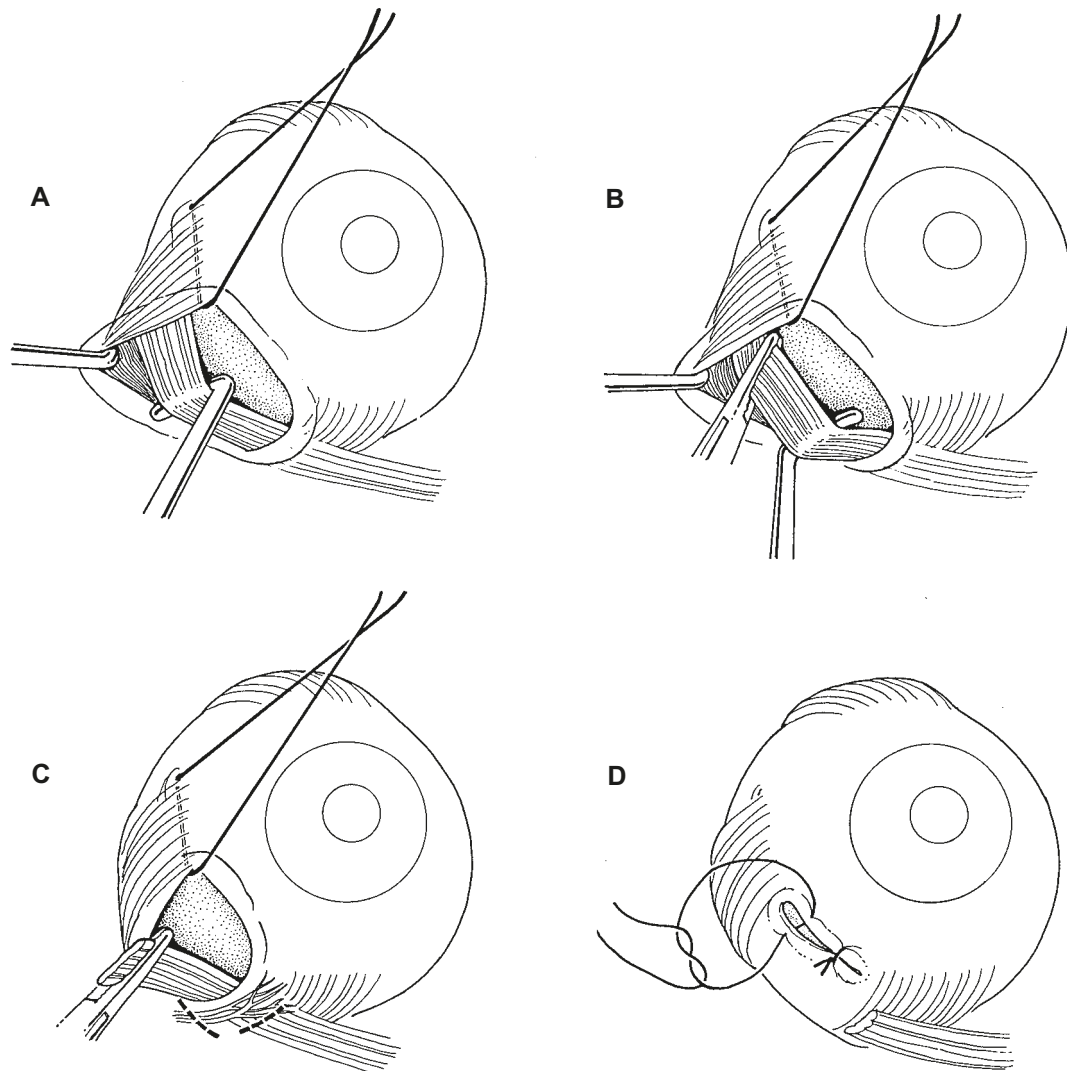


Figure 8

A The insertion is exposed.
B The muscle is clamped near the insertion.

C The muscle is detached and from here disinsertion, recession, myectomy or anterior transposition can be done.
D conjunctiva is closed.

oblique. It is unlikely, in my opinion, that the inferior oblique is actually converted to a depressor.

The indication for anterior transposition of the inferior oblique is overaction of the inferior obliques causing excess elevation in adduction and a 'V' pattern plus dissociated vertical deviation. This procedure should not ordinarily be performed on just one eye because of the possibility of producing a large secondary deviation. I have done it in one patient, but soon after this procedure did it in the other eye.

To perform anterior transposition, the inferior oblique muscle is isolated and a 6-0 Vicryl suture is placed at the distal end of the inferior oblique (Figure 9). A large hook is then placed to expose the sclera

just temporal and anterior to the inferior rectus insertion. The tip of the inferior oblique is sutured to sclera 1 or 2 mm anterior to the lateral border of the inferior rectus insertion, immediately adjacent to the inferior rectus.* The new inferior oblique insertion should be just anterior but parallel to the inferior rectus insertion. The conjunctiva may be closed with one or two 8-0 Vicryl sutures. A mound of inferior oblique muscle, obvious just behind the limbus immediately after surgery, subsides in a few weeks and does not present a problem. But, fullness of the lower lid persists in some cases.

*Surgeons differ in their choice for positioning the new insertion of the inferior oblique, placing it even with the inferior rectus or a millimeter behind.

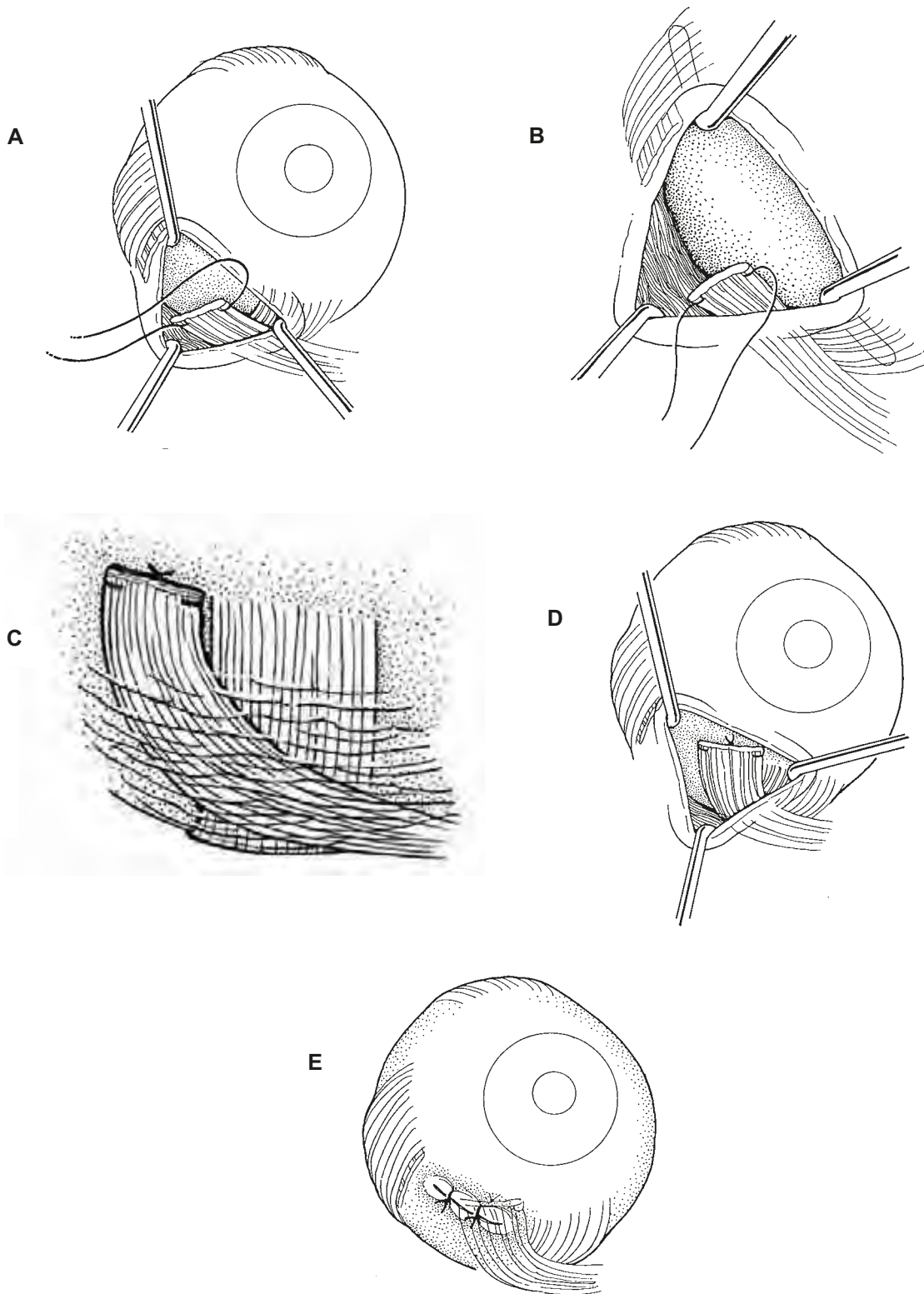


Figure 9

A A suture is placed at the distal inferior oblique and the muscle is detached.
B A hook is placed behind the inferior rectus insertion...
C ...and the inferior oblique is secured to sclera.

D The level of attachment of the inferior oblique can vary from a few millimeters ahead of to a few millimeters behind the level of the inferior rectus insertion.
E The conjunctiva is closed.

Strengthening the inferior oblique

Inferior oblique tuck: resection and advancement of the inferior oblique

Strengthening procedures on the inferior oblique are the least effective types of surgery for the vertically acting muscles and are rarely indicated. However, the procedure is performed occasionally in the rare case of inferior oblique palsy that is not adequately treated by weakening the yoke superior rectus. Two techniques for strengthening the inferior oblique, tuck and resection with advancement, have been described.

To tuck the inferior oblique, the muscle is first localized and engaged in the inferior temporal quadrant exactly as it is done before performing a myectomy (Figure 10). A tuck is then made in the muscle using a Fink tucker or a freehand technique can be used. Nonabsorbable suture such as 5-0 Mersilene is used to secure the tuck. When a tuck is made, no less

than 10 mm (5 mm up and 5 mm down) of the muscle should be included.

For resection and advancement of the inferior oblique, two single-arm sutures are placed at the borders of the inferior oblique muscle just below the inferior border of the lateral rectus - approximately 5 mm from the insertion (Figure 11). The muscle is clamped with a hemostat and is severed just distal to the sutures. The muscle stump is cut free from the globe at the insertion and is discarded. The inferior oblique is reattached to the sclera at the upper border of the lateral rectus. The anterior suture is placed 12 mm posterior to the lateral rectus insertion and the posterior suture is placed slightly more posterior. This produces approximately 10 mm or slightly more resection effect.

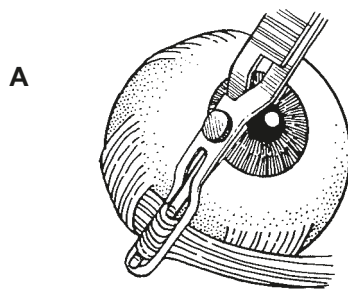
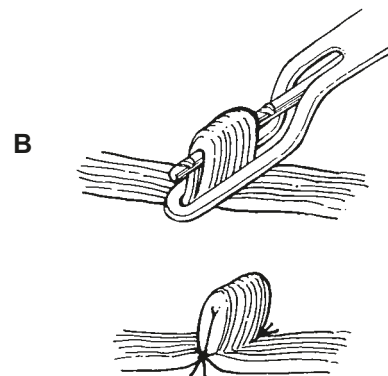


Figure 10
A A tucker is placed.



B The loop is 5 mm on each side of the tucker (10 mm total). It is secured with 5-0 non-absorbable suture.

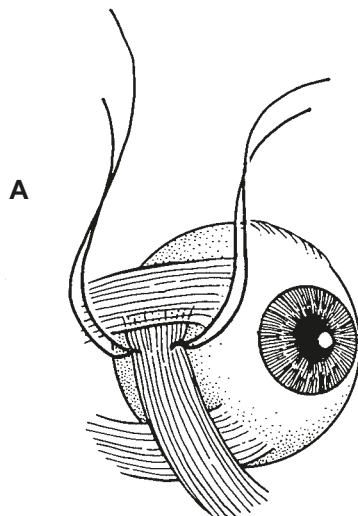
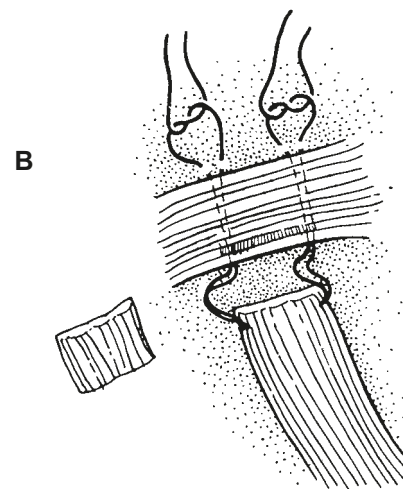


Figure 11
A Sutures are placed at the borders of the inferior oblique.



B The inferior oblique is detached and reattached at the upper border of the lateral rectus.

Weakening procedures of the superior oblique/tenotomy

The superior oblique is effectively weakened by a tenectomy, tenotomy, or recession. For best results, these procedures should be performed with minimal disruption of the orbital fascial layers surrounding the superior oblique tendon.

The incision for exposure of the superior oblique tendon medial to the superior rectus is begun at the medial aspect of the superior rectus muscle insertion and extends through the conjunctiva, anterior Tenon's capsule, and intermuscular membrane 8 mm from and concentric with the limbus (Figure 12). When bare sclera is exposed, moderate-sized muscle hooks are placed behind the insertion of the superior rectus and the medial rectus and a third muscle hook is placed beneath the posterior free edge of the incision to retract the intermuscular membrane, anterior Tenon's capsule, and conjunctiva. These three muscle hooks are held under slight tension to produce an incision the shape of an equilateral triangle. The surgeon then observes the undersurface of posterior Tenon's capsule. A whitish band will be seen; this is the superior oblique tendon encased in orbital fascia. The width of the superior oblique tendon here is approximately 3 mm. A small right angle hook is placed into the incision to engage the superior oblique tendon with a minimum of associated fascia. The tip of the hook is dissected free with scissors or a scalpel blade so that it projects cleanly behind the posterior aspect of the superior oblique tendon (Figure 13).

A second hook is placed beneath the superior oblique tendon. The anterior aspect of the associated fascia is dissected from the tendon along the long axis of the tendon. A third hook is placed beneath the tendon but remains superficial to the associated fascia. Another teaser hook engages only the tendon and the two hooks beneath the combined tendon and fascia are removed. Scissors are used to cut the superior oblique tendon.

Before cutting the superior oblique tendon, the surgeon must decide on the degree of weakening intended. A tenotomy adjacent to the medial border of the superior rectus muscle, closer to the insertion, results in less weakening. A tenotomy carried out closer to the trochlea produces more weakening. Grading of a superior oblique weakening procedure is achieved in this manner rather than by varying the size of a tenectomy. The actual degree of weakening in a superior oblique tenectomy is governed by the proximity of the nasal end of the tenectomy to the trochlea rather than by the size of the segment of tendon removed. Therefore, a tenotomy is sufficient. With the tenotomy completed, the tendon retracts. The incision is closed with one or more absorbable sutures.

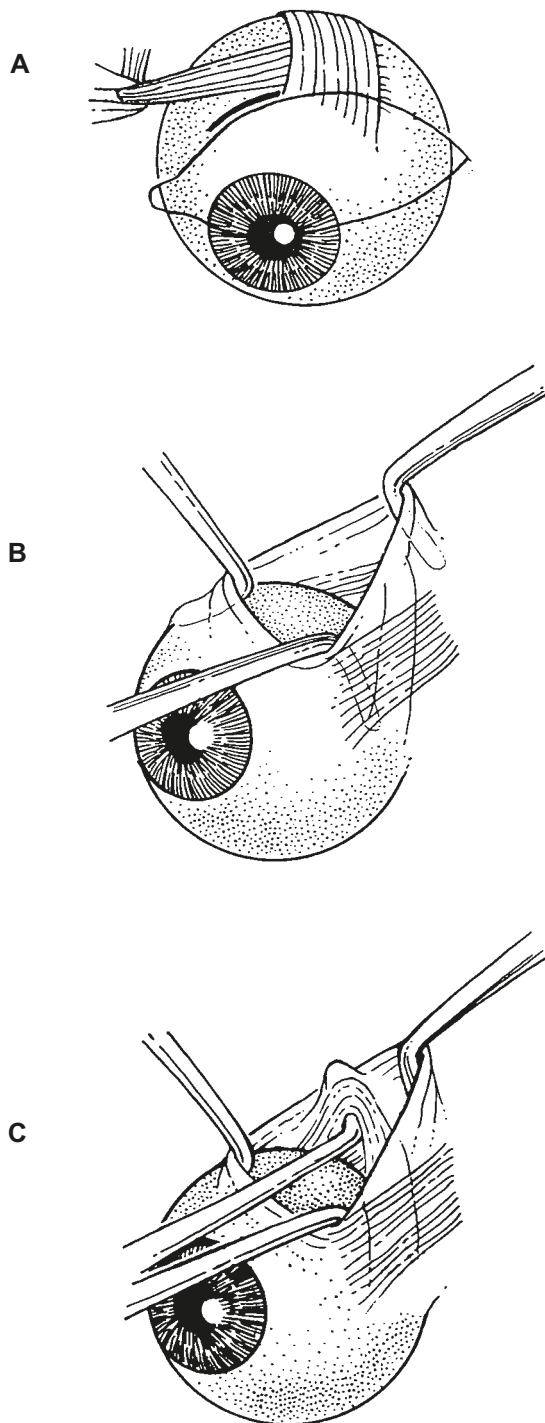


Figure 12

- A** Site of the incision for exposing the superior oblique nasal to the superior rectus in the left eye.
- B** Hooks are placed behind the superior and medial recti and elevating intermuscular membrane. The white band of the superior oblique tendon is 'imbedded' in the fascia seen through intermuscular membrane.
- C** A small hook picks up the superior oblique tendon. The tip of the teaser hook is covered by orbital fascia.

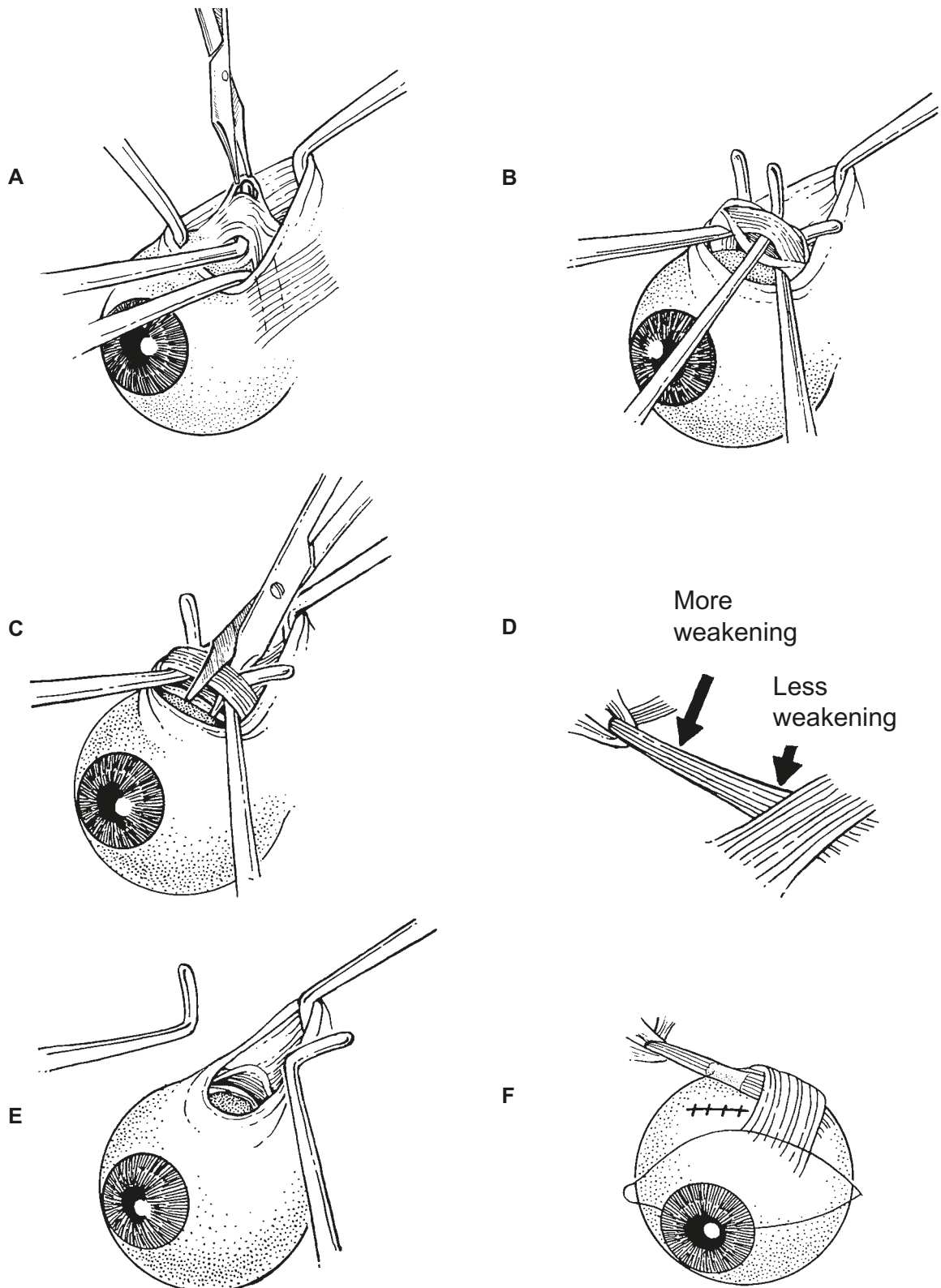


Figure 13

- A** The tip of the hook behind the tendon and fascia is exposed with a scissors or scalpel blade
- B** The fascia is carefully separated from the tendon fibers and a hook is placed behind the isolated tendon.
- C** A second hook is placed behind the tendon and the tendon is cut.

- D** The location of the cut influences the amount of weakening.
- E** The tendon retracts.
- F** The conjunctiva is closed.

Superior oblique tenotomy after a temporal approach

An alternate method for performing tenotomy of the superior oblique uses exposure of the superior oblique tendon at its insertion. The superior oblique tendon insertion is usually found only after careful study of the scleral surface reveals the delicate tendon fibers as they blend into sclera. A fine hook rubbed over the scleral surface can aid in identifying these fibers. They are located approximately 6 to 12 mm posterior to the lateral corner of the superior rectus insertion, almost parallel to the lateral border of the superior rectus, approximately at the lateral margin of the muscle.

For minimal weakening procedures, especially to reduce a small 'A' pattern bilateral disinsertion of the posterior seven-eighths of the superior oblique insertion can be effective. Preito-Diaz recommends removing a triangle of superior oblique insertion with the apex pointing toward the trochlea. This procedure may also be used in selected cases of Brown's syndrome, provided this minimal procedure allows free, unrestricted passive elevation in adduction confirmed at surgery.

To carry out surgery on the superior oblique at the insertion, the superior rectus tendon is engaged from its temporal side with a large muscle hook. A second muscle hook elevates the superior rectus muscle approximately 5 to 8 mm posterior to its insertion and a third muscle hook retracts the conjunctiva and anterior Tenon's capsule and intermuscular membrane laterally and backward (Figure 14). The insertion of the superior oblique tendon is searched for carefully. At this point a minimum of manipulation should be carried out. Careful blotting with a cotton-tipped applicator and slight manipulations of the globe will reveal the insertional fibers of the superior oblique tendon fusing with the sclera approximately at right angles to the superior oblique insertion.

Anterior fibers of the superior oblique insertion are engaged with a small muscle hook. Hooking at least part of the superior oblique tendon allows the tendon to be pulled temporally while the superior rectus is pulled nasally, exposing the thin cord-like proximal portion of the superior oblique tendon that can be engaged with a small hook. The first hook is removed after a second hook has been placed behind the proximal portion of the superior oblique tendon.

A larger muscle hook replaces the two small hooks and is then used to engage the superior oblique tendon and bring it temporally. At this point scissors can be used to dissect the superior oblique tendon free from the intermuscular membrane fibers and the infe-

rior muscle capsule beneath the superior rectus muscle. Because the superior oblique tendon is fanned out at its insertion some fibers may be missed if the only attempt to engage the tendon is made at the insertion. Careful observation and dissection beneath the superior rectus will allow complete inclusion of the more compact superior oblique tendon beneath the superior rectus muscle.

The superior oblique tendon can be brought temporally while the superior rectus muscle is pulled nasally so that the doubled-over tendon is exposed up to 20 or more mm from the insertion. The tenotomy may now be carried out. The principle of obtaining more effect from tenotomies closer to the trochlea and less effect from tenotomies farther from the trochlea remains valid using the superior oblique exposure from the temporal approach. Because up to 20+ mm of the superior oblique tendon can be exposed temporal to the superior rectus, measuring or estimating the distance from the insertion to the point of tenectomy actually gives a more reliable measure of the tenotomy. Because the superior oblique tendon will not stretch, the surgeon should be able to perform a reproducible tenotomy using a temporal approach.

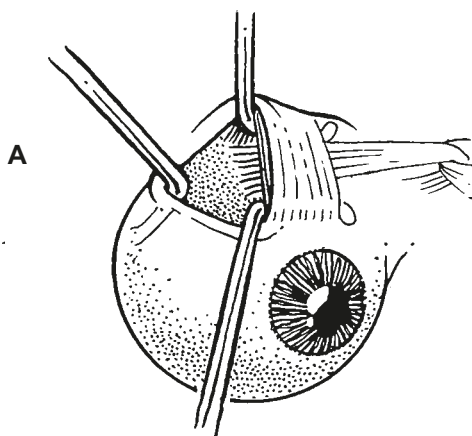


Figure 14

A The three hooks create a triangular incision exposing the site of the superior oblique insertion.

continued.

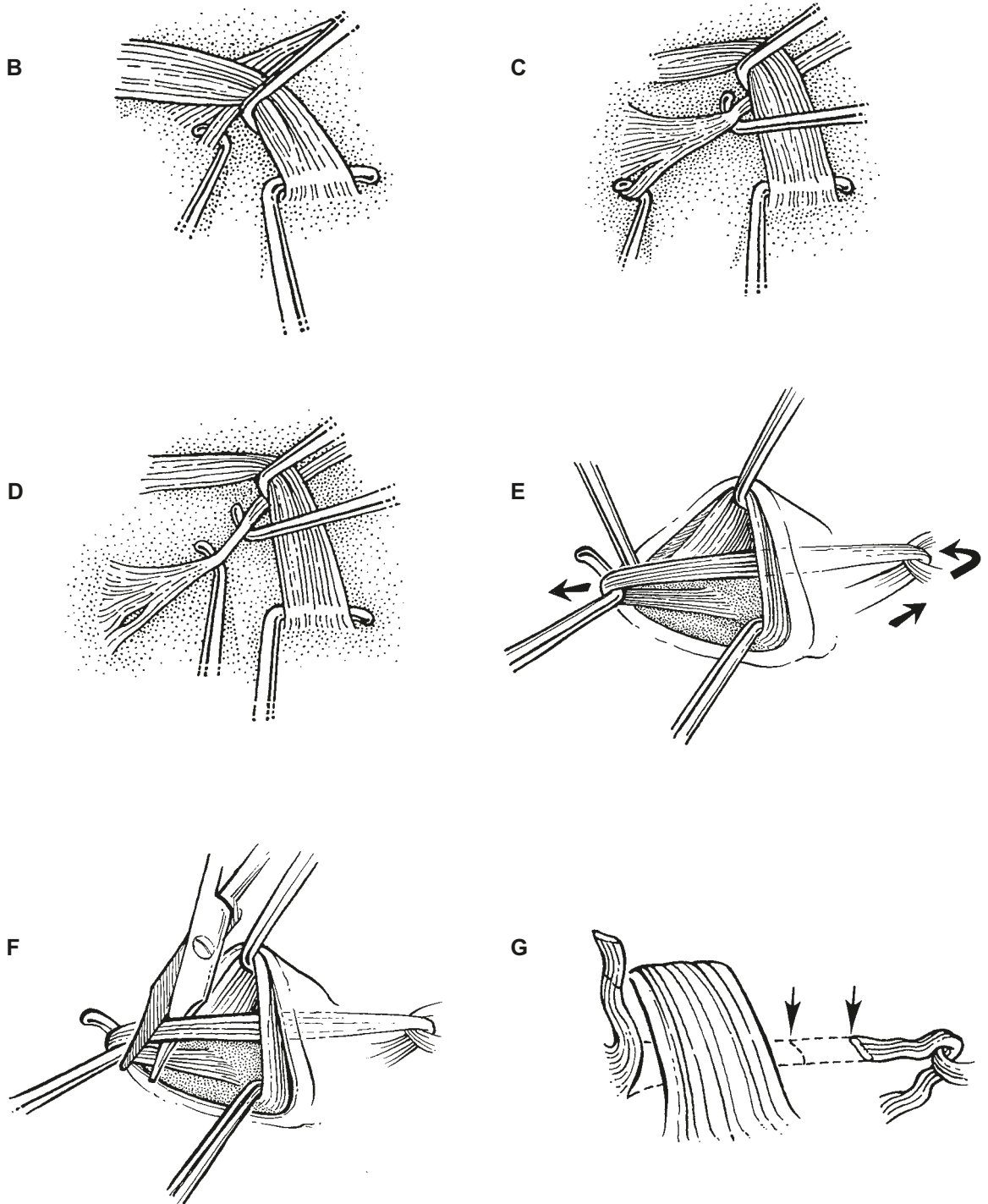


Figure 14, cont'd

- B** The tendon (or at least the anterior part of it) is hooked.
- C** A second hook engages the round tendon proximally.
- D** Another hook is placed under the tendon.
- E** After a larger hook replaces the two smaller ones, the tendon is pulled temporally while the superior rectus is pulled nasally.

- F** The tendon is cut.
- G** The farther the tenectomy from the insertion (closer to the trochlea), the greater the weakening.

7/8 tenotomy/disinsertion

After exposing the insertion of the superior oblique tendon, scissors are used to disinsert the tendon or to carry out a 7/8 posterior tenotomy of the superior oblique tendon with excision of a triangle shape portion of the tendon at the insertion (Figure 15).

Recession of the superior oblique

For a more controlled, weakening of the superior oblique tendon, recession in the place of tenotomy can be done. Split tendon lengthening of the superior oblique tendon nasal to the superior rectus has been described and is performed by some surgeons in selected cases. It has also been performed and abandoned by other surgeons. While this technique is theoretically possible, it is difficult to perform. I see no reason to use it in place of other available superior oblique weakening procedures and for that reason it will not be illustrated.

In preparation for recession, the superior oblique tendon is located and engaged at its insertion temporal to the lateral border of the superior rectus. A double-arm 5-0 Mersilene or 6-0 Vicryl suture is placed through the superior oblique tendon 4 mm

from its insertion, and a surgeon's knot is tied. This is to ensure that the suture is placed in solid tendon. The tendon is then transected between the suture and the tendon's insertion. The tendon is allowed to retract beneath the superior rectus for a distance of 8 to 20 mm, according to the intended amount of recession, and the suture is tied in a 'hang loose' fashion at the tendon insertion (Figure 16).

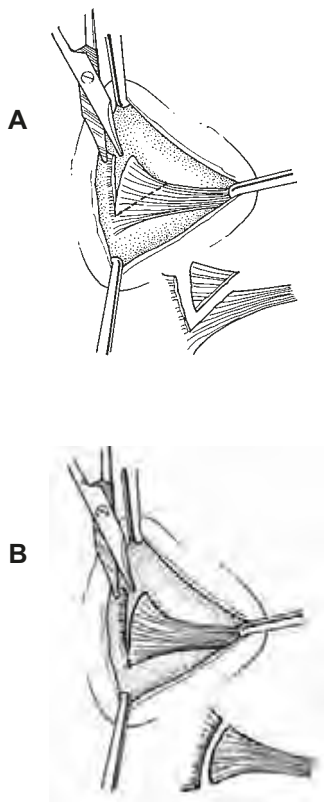


Figure 15
Disinsertion - 7/8 tenotomy
A Posterior 7/8 tenotomy
B Disinsertion

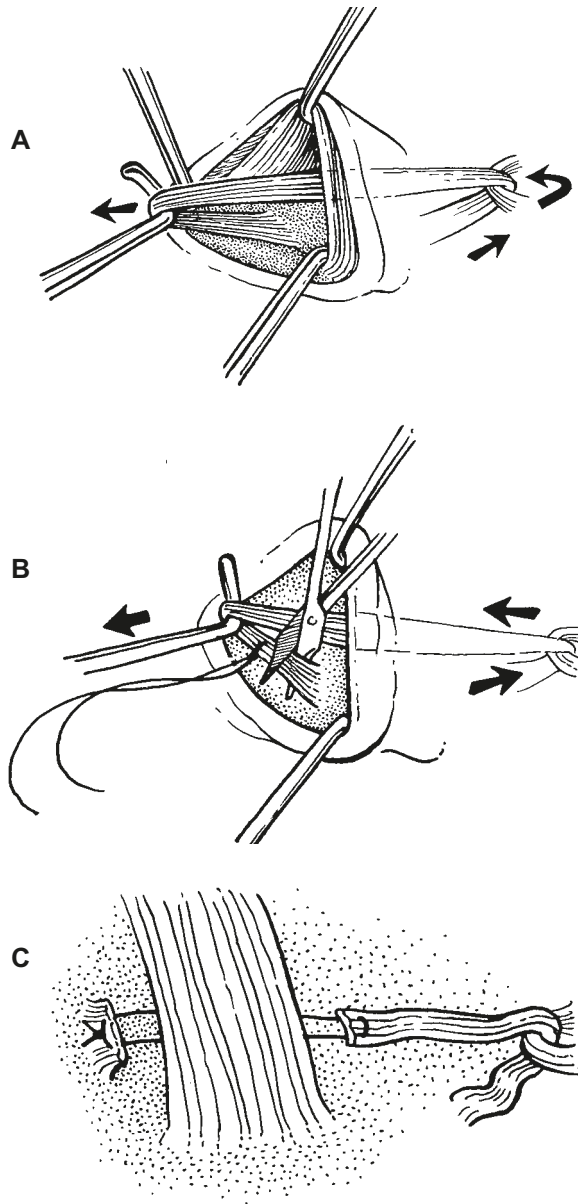


Figure 16
A The superior oblique tendon is exposed at the insertion temporal to the superior rectus.
B A double arm suture is placed 4 mm from the insertion and the tendon is cut free of sclera at the insertion.
C The needles are brought through the insertion. After the tendon is allowed to retract a graded amount according to the amount of weakening needed, the suture is tied.

Sagittalization of the superior oblique

Anterior shift of the superior oblique tendon insertion has been advocated for treatment of the torsional diplopia resulting from some superior oblique palsy. Harada and Ito are given priority for describing this technique. The intorting power of the superior oblique is increased by: anterior and temporal shift of the anterior part of the insertion; anterior shift of the entire insertion; or anterior shift of the tendon without disinsertion. This moves the superior oblique insertion so that it has more effect temporal to the 'Y' axis of the eye, thereby increasing the superior oblique's effect as an intorter.

The superior oblique tendon normally inserts in the posterotemporal quadrant of the top of the globe. It functions as a depressor, abductor, and intorter. By shifting the anterior half of the tendon 5 to 8 mm anteriorly and a few millimeters temporally, the intorting action of the superior oblique is enhanced without affecting appreciably the other superior oblique functions.

The superior oblique tendon is exposed at its insertion and a small hook engages all or part of the insertion. The superior rectus is retracted medially, a 6-0 Vicryl or 6-0 non-absorbable suture is tied to the superior oblique tendon close to its insertion, the superior oblique tendon is split, and the anterior half of the superior oblique tendon is detached from the globe (Figure 17). The anterior half of the superior oblique tendon is sutured to the sclera 5 to 8 mm anteriorly near the temporal aspect of the superior rectus or it may be placed near the superior border of the lateral rectus for more effect. The anterior superior oblique fibers are probably more effective intorters and the posterior superior oblique fibers are more effective depressors. A specific and selective weakening of depression effect can be obtained, at least theoretically, by performing a disinsertion of the posterior fibers of the superior oblique tendon's insertion. Wheeler suggested this procedure in 1935. Metz suggested an adjustable anterior shift and advancement of the superior oblique tendon.

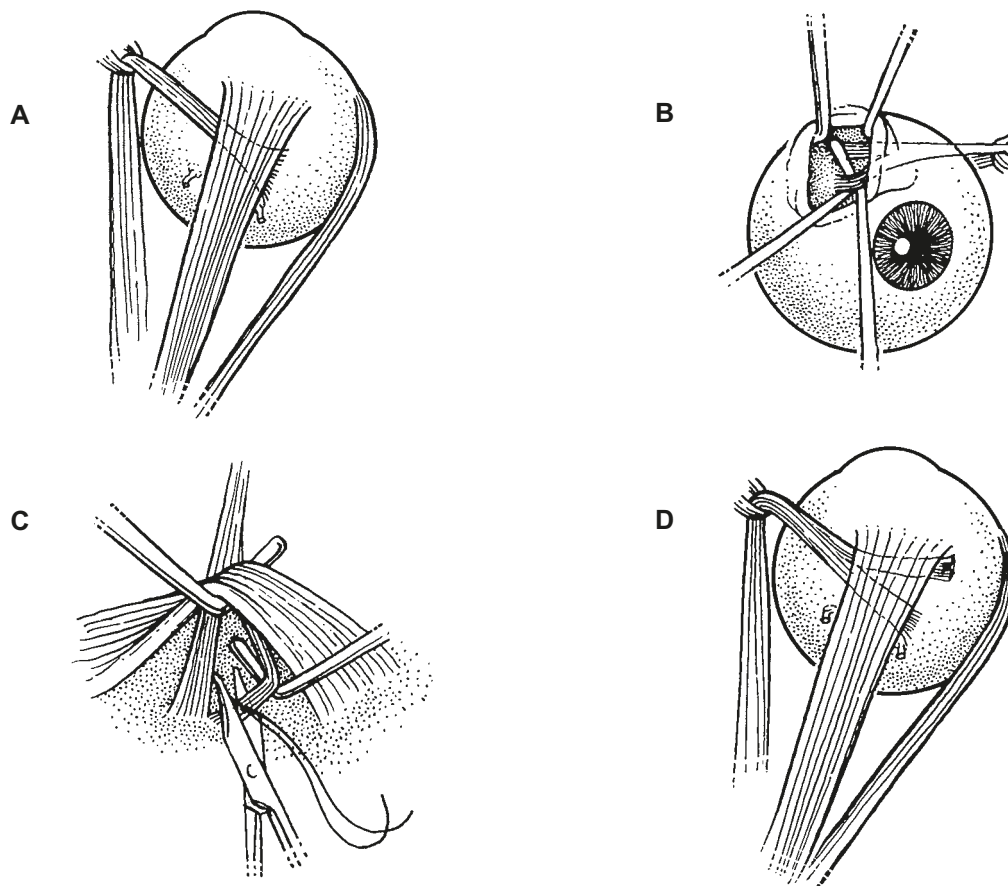


Figure 17

- A** The superior oblique inserts in the posterior temporal quadrant.
B The anterior (or if you choose the entire) tendon is engaged on a hook (right eye, surgeon's view).

- C** A double arm suture is placed into the tendon (right eye, surgeon's view).
D The tendon is secured to sclera

Brown's superior oblique tendon sheath syndrome

Brown's superior oblique tendon sheath syndrome or simply Brown syndrome (eliminating the reference to etiology) is characterized by inability on a *mechanical* basis of the eye to elevate normally in the adducted position. It is usually unilateral and sporadic but it may occur in one or both eyes and has been seen in blood relatives. This condition is also associated with widening of the palpebral fissure on attempted elevation and occasionally there is downshoot of the eye in adduction. The diagnosis is confirmed only after demonstration of limited forced elevation, especially in adduction. This is done at the time of surgery since most patients treated surgically for Brown are younger. Brown syndrome may be congenital or acquired and results from a variety of causes, but the net result is an inability of the superior oblique tendon to pass freely in its normal range of motion (16 mm, or 8 mm toward upgaze and 8 mm in downgaze) through the trochlea - the upgaze motion being necessary to allow the eye to elevate in adduction. Unless the superior oblique tendon can pass freely through the trochlea, the distance between the trochlea and the insertion cannot increase and the eye cannot be elevated in adduction.

The surgical treatment of Brown syndrome can be one of the more frustrating of the extraocular muscle procedures because surgical attempts designed to reduce the mechanical restriction are often nullified by postoperative adhesion formation. On the other hand, when successful, surgery can result in underaction of the muscle. In rare instances the adhesions that limit elevation in adduction may be associated with structures other than the superior oblique. Brown syndrome has been cured by releasing restrictions associated with the inferior oblique and also by lysing a fibrous band along the inferior border of the lateral rectus.

As a minimal superior oblique weakening procedure to treat Brown syndrome, posterior 7/8 superior oblique fiber disinsertion may be performed with or without removal of a piece of the tendon. I have treated intermittent Brown syndrome successfully by excising a clear fluid cyst of the reflected tendon of the superior oblique near the trochlea, removal of a fibrous mass at the insertion, tenectomy, and with a spacer.

Since Brown syndrome represents a wide array of pathology, no *single* superior oblique weakening procedure could be expected to cure or significantly improve all cases. Actually, some Brown cases could not and indeed *should not* be treated with superior oblique weakening. An array of potential causes of Brown are shown (Figure 18). Each of these causes of Brown has a unique 'personality' and requires unique treatment.

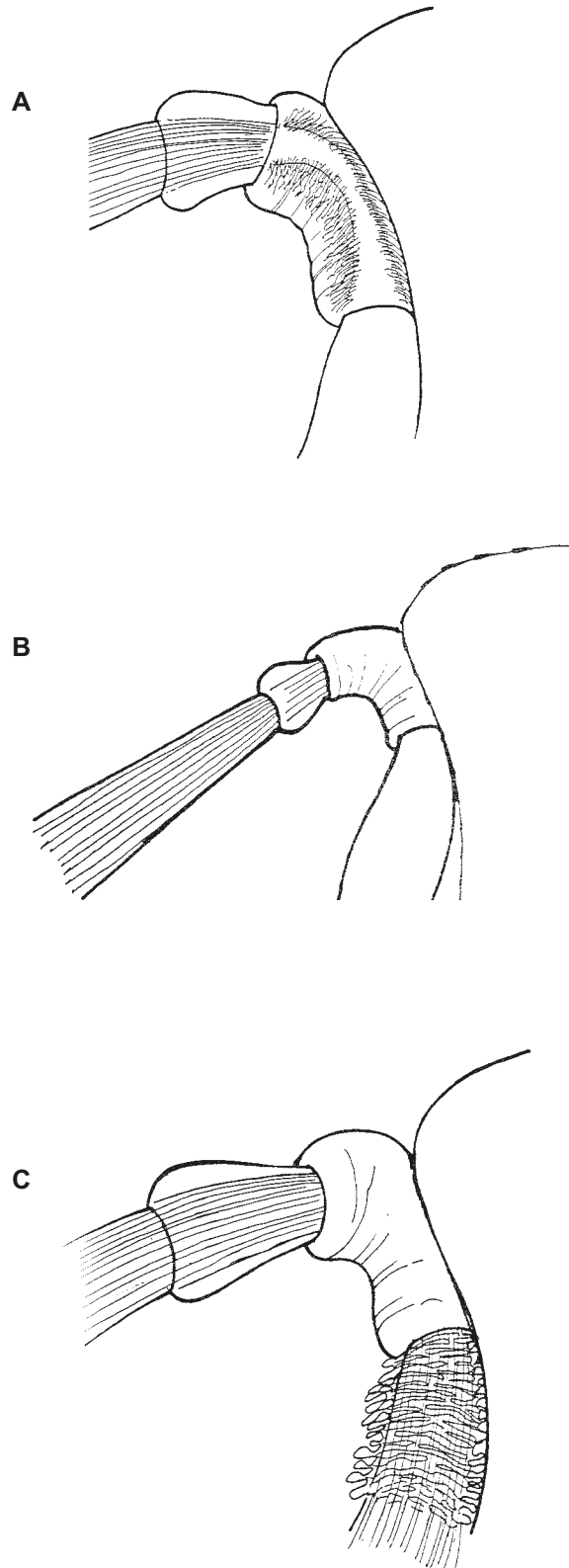


Figure 18

- A** Intratrochlear adhesions.
- B** Tendon shortness - restriction
- C** Restriction at entry of tendon to trochlea.

From Helveston EM. Brown syndrome: anatomic considerations and pathophysiology. *American Orthoptic Journal*, 1993, 43:31-35. Reprinted by permission of the University of Wisconsin Press.

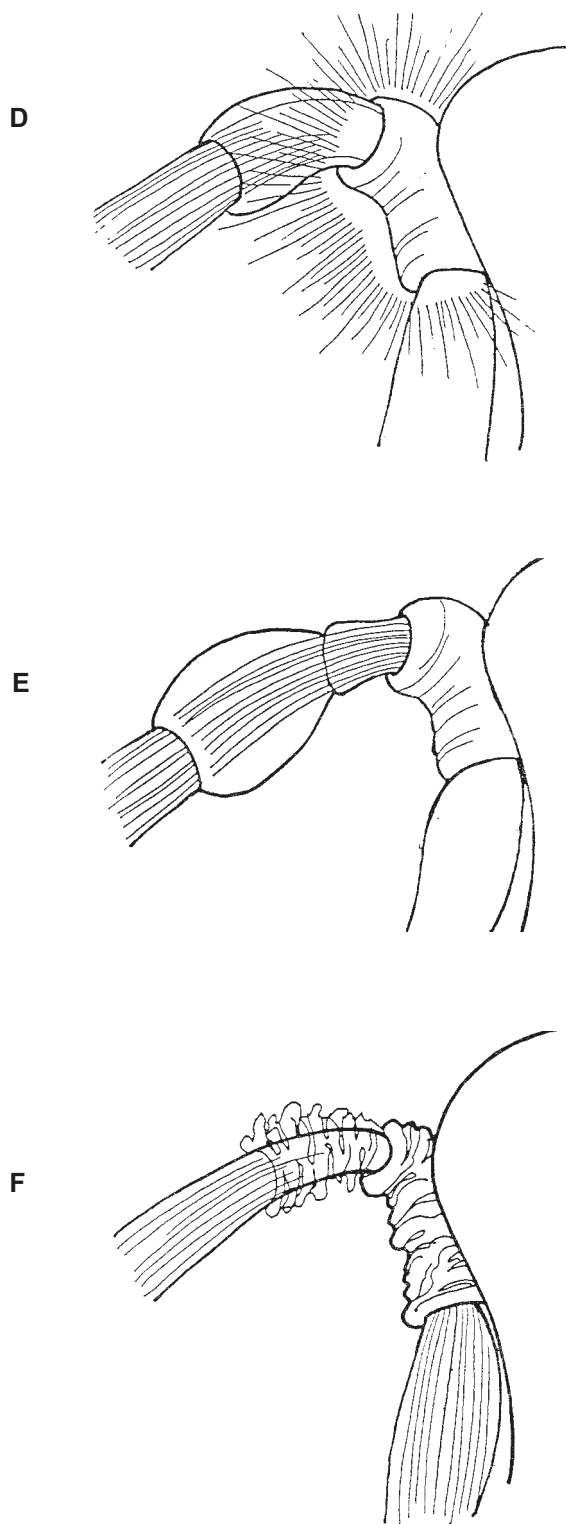


Figure 18, cont'd

D Inflammation, swelling restriction in trochlea.

E Cyst at exit of trochlea.

F Trauma to trochlea - 'canine tooth.'

From Helveston EM. Brown syndrome: anatomic considerations and pathophysiology. *American Orthoptic Journal*, 1993, 43:31-35. Reprinted by permission of the University of Wisconsin Press.

Directed treatment of Brown syndrome

Brown syndrome should be treated with the specific technique that would be most likely to effectively address the unique pathology and after treatment to enable free elevation in adduction. The important thing for the surgeon to realize is that simply cutting or lengthening the superior oblique tendon is not always the answer to Brown syndrome.

Intratrochlear adhesions will impede free passage of the superior oblique tendon and therefore restrict elevation in adduction. This is a diagnosis of exclusion. Weakening of the superior oblique tendon would be the most appropriate treatment. Superior oblique palsy is a likely result of freeing elevation in adduction in a case like this.

Tendon anomaly. This can be a 'short tendon,' fibrosis of the tendon, or another discrete tendon abnormality. This is treated by surgery aimed at 'undoing' the abnormality. This could range from cutting a fibrous band to cutting the tendon.

Restriction to the tendon entry to the trochlea will impede free movement of the tendon through the trochlea. This is another diagnosis of exclusion. The eye will not go up in adduction even with forced ductions, but the tendon is normal. Lengthening of the tendon is the treatment. This is another case where superior oblique underaction will result after elevation in adduction is restored.

Inflammation of the trochlea. This is best treated by the injection of soluble steroid into the region of the trochlea.

Cyst of the tendon can be treated effectively with excision of the cyst.

Trochlear trauma (canine tooth syndrome) is characterized by mechanical limitation of elevation in adduction and limitation of depression from superior oblique palsy. There is no sure treatment. Superior oblique tenectomy can free elevation in adduction, leaving superior oblique palsy to be treated.

Because those causes of Brown that require surgery on the tendon need such varied procedures I prefer a surgical approach that allows a clear look at the entire reflected tendon of the superior oblique. This starts with the cuffed limbal incision and continues with tagging and detachment of the superior rectus (Figure 19 and see page 176). With this exposure, the required surgery can be done under direct vision. Operating with limited exposure and/or simply cutting or otherwise lengthening the superior oblique tendon for all cases of Brown syndrome will produce disappointing results in selected cases. To make this surgery even more frustrating, forced duction can be free at surgery only to become restricted again in days or weeks after surgery.

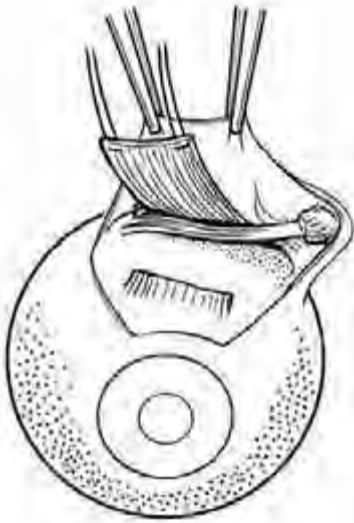

Figure 19
Exposure of the superior oblique from the trochlear cuff to the insertion after a cuffed limbal incision and tagging and disinsertion of the superior rectus.

Superior oblique tendon expander

A technique for weakening the superior oblique tendon using a silicone expander has been described by Wright. The length of the expander varies from 4 to 7 mm in 1 mm increments. A 4 mm expander is used for 1+ and the 7 mm for 4+ superior oblique overaction. This technique has been employed for any type of superior oblique overaction including Brown syndrome.

The superior oblique tendon is isolated under direct vision nasal to the superior rectus. The superior oblique tendon is shelled out of the orbital fascia which is carefully preserved as shown in Figure 13. Two double-arm 5-0 Mersilene sutures are placed at mid tendon a few millimeters apart. The superior oblique tendon is cut between these sutures. A No. 240 silicone band is secured with the needles of both double-arm 5-0 Mersilene sutures. The Mersilene sutures are tied to secure the silicone expander between the cut ends of the superior oblique tendon. This lengthens the tendon. The orbital fascia is closed over the silicone with 8-0 Vicryl suture.

The 'chicken' suture

A procedure for doing a more or less guarded superior oblique lengthening employs a suture dubbed by Phil Knapp the 'chicken suture.' This is in effect creating controlled tendon expansion with a suture and muscle contraction in place of the silicone spacer (Figure 20).

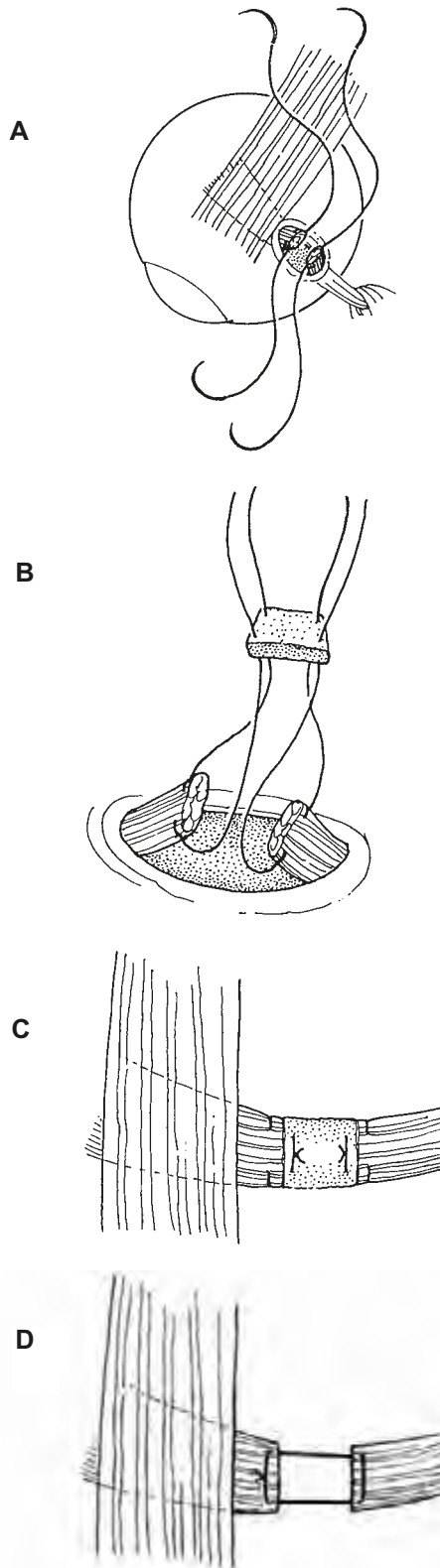


Figure 20
A The superior oblique tendon is isolated and two double arm mersilene sutures are placed a few millimeters apart.
B The sutures are placed in the ends of a #240 silicone band.
C The band is secured in place. After this, fascia is closed with a 8-0 absorbable sutures.
D The so-called 'chicken suture' keeps the tendon lengthening at a specified maximum.

Strengthening the superior oblique

Superior oblique tuck at the insertion

An effective and safe technique for strengthening the superior oblique is a tuck of the tendon at its insertion. This procedure maintains the normal action of the superior oblique muscle and reduces the incidence, severity, and persistence of postoperative Brown syndrome if appropriate precautions are taken. Tuck of the superior oblique tendon should be performed only if a loose, lax, or redundant tendon is confirmed, first at the superior oblique traction test and then by direct observation. A loose tendon is seen in congenital superior oblique palsy, but usually not in acquired superior oblique palsy. After the tuck has been secured, passive ductions should be performed testing elevation in adduction. If the superior oblique traction test is too tight when comparing it to the fellow eye, the suture securing the tuck should be released and the size of the tuck reduced. The tuck should be secured only when passive elevation in adduction is equal or slightly tighter on the tucked side. The size of the tuck depends entirely on the laxity of the tendon. I once made a 22 mm tuck on a lax tendon without producing Brown syndrome in a congenital superior oblique palsy. On the other hand, I have produced severe Brown syndrome after a 6 mm tuck in a case of acquired superior oblique palsy, performed before I became aware of the pitfalls of iatrogenic Brown syndrome after tucking a normal (nonredundant) tendon.

The incision for exposure of the superior oblique tendon at its insertion is begun at the lateral border of the superior rectus insertion and extends temporally for 8 mm parallel with the limbus. The initial incision is carried through the conjunctiva, anterior Tenon's capsule, and intermuscular membrane. A muscle hook is inserted behind the insertion of the superior rectus muscle and a second hook retracts the posterior border of the incision at the lateral border of the superior rectus muscle. This maneuver exposes the insertional fibers of the superior oblique tendon. A muscle hook is inserted behind the insertion of the superior oblique tendon and the tendon is brought out from beneath the superior rec-

tus (see page 229). If a tendon tucker is used, the hook is replaced with the hook portion of a Bishop or equivalent tendon tucker.

The knurled knob at the head of the tendon tucker is screwed down until the slack has been taken out of the superior oblique tendon. The total amount of tendon tucked is *twice* the amount shown on the tucking instrument because the tendon is doubled on itself during the tucking procedure. It is impossible to give a number in millimeters for the correct amount of superior oblique tucking in a given case. However, it is safe to say that more errors are committed by doing too large than too small a tuck. In general, the more vertical deviation to be treated and the more lax the superior oblique tendon the greater the tuck required. When a sufficient amount of superior oblique tendon has been brought into the tucker to take out the slack in the tendon, Nonabsorbable suture (my choice is 5-0 Mersilene) is then used to anchor the tuck of the superior oblique tendon. A loop may be left in the knot securing the tendon at the base of the tuck to facilitate suture release and replacement if needed. Passive ductions are then performed. The tuck is reduced if passive elevation in adduction is limited. The tuck is made larger if the tendon remains lax on superior oblique traction testing.

Each border of the tendon is secured when the tuck is just right, the tucker is removed and the tuck remains intact. A third suture is placed at the apex of the tucked tendon, and this tip is attached to the sclera in line with the normal pull of the superior oblique tendon. The needle should be placed into very superficial scleral fibers because the sclera can be extremely thin in this area. The conjunctiva is closed with several interrupted sutures.

A tuck of the superior oblique tendon can also be carried out with a free hand technique. With this technique, the surgeon simply pulls the redundant tendon up with a hook and places the sutures through the superior oblique tendon at the level of sclera, producing the intended amount of tuck (Figure 21). This is my preferred technique.

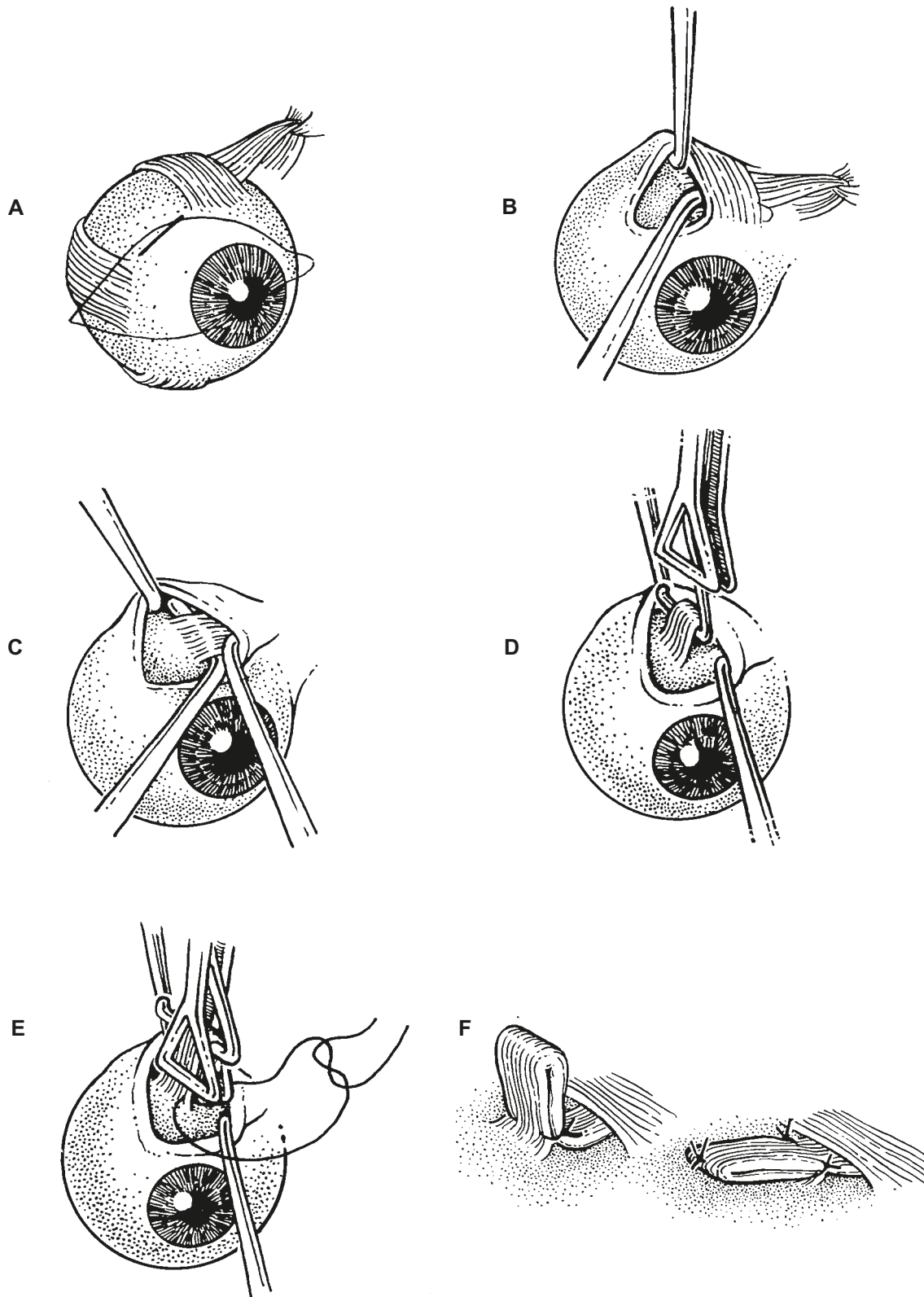
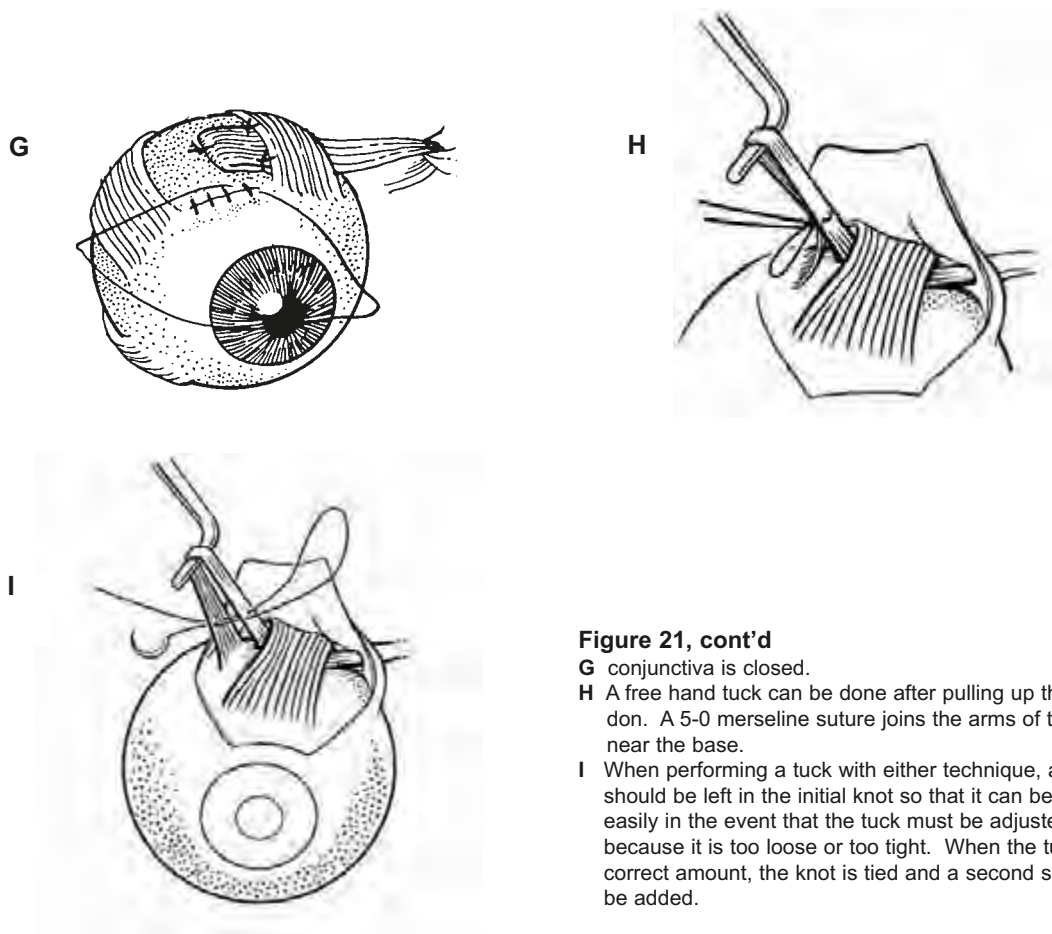


Figure 21

A Incision for exposure of the superior oblique tendon at the insertion.
B Exposing the superior oblique insertion.
C The superior oblique insertion is engaged on a hook.
D The hook of the tucker engages the tendon.

E The tucker is adjusted pulling the loop of the tendon up until the intended amount of tuck is achieved and a suture secure the tuck at the borders of the tendon. The intended amount of insertion is determined after confirmation that the superior oblique traction test is equal or slightly tighter on the operated side.
F A second suture secures the tuck and the tip of the loop is sutured to sclera.

**Figure 21, cont'd**

- G** conjunctiva is closed.
- H** A free hand tuck can be done after pulling up the lax tendon. A 5-0 merseline suture joins the arms of the loop near the base.
- I** When performing a tuck with either technique, a loop should be left in the initial knot so that it can be undone easily in the event that the tuck must be adjusted because it is too loose or too tight. When the tuck is the correct amount, the knot is tied and a second suture may be added.

Superior oblique resection and advancement

Other techniques for strengthening or shortening the superior oblique tendon are resection, advancement, or resection and advancement. For superior oblique resection, I prefer to attach the proximal tendon to the middle, posterior, or anterior insertion with placement depending on the amount of preoperative torsion. One reason for choosing tuck over resection for the superior oblique is that it can be difficult to place sutures in the thin superior oblique tendon.

The superior oblique tendon is exposed at the insertion (Figure 22). The tendon is engaged on a hook near its insertion and the superior rectus muscle is retracted medially. A 6-0 Vicryl or 5-0 merseline suture is woven through the tendon 6 to 10 mm or more from the insertion. The distance may be greater with a very loose tendon and less for a tendon that is not so loose. A hemostat is placed across the tendon toward the insertion a few millimeters from the suture and the tendon is cut between the hemostat and

suture. The hemostat holds the distal superior oblique tendon, stabilizing the insertion. The double-arm Vicryl suture attached to the proximal tendon is brought through the insertion at the middle, posterior edge, or anterior edge. The middle is selected if the torsional and vertical defects are proportional, posterior if the vertical defect is greater, and, as occurs more commonly, anterior if extorsion is the main preoperative problem. The tendon can be advanced (attached farther temporally) or shifted anteriorly if more torsional effect is needed. Also, any of these procedures can be performed with an adjustable suture. Anteriorly placed sutures are more readily adjusted than posteriorly placed sutures.

As with any procedure to 'strengthen' the superior oblique, passive ductions should be tested and the tightness of the tuck adjusted to a point where the two sides are equal or the treated side just slightly tighter.

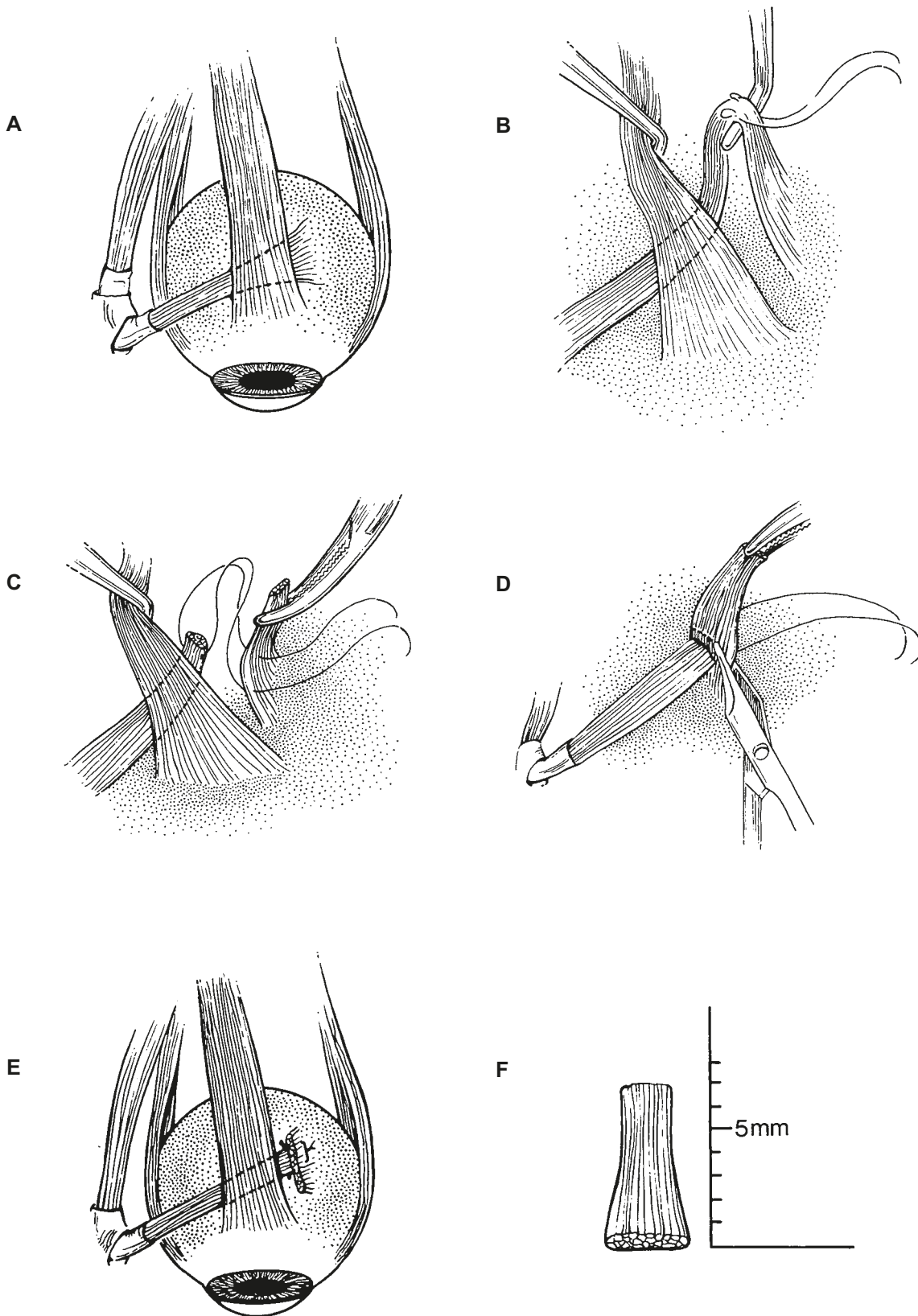


Figure 22

- A The superior oblique tendon.
- B After the loose tendon is elevated, a double arm suture is placed at the intended amount of resection.
- C The tendon is cut distal to the suture and the suture is passed through the tendon insertion.

- D The distal tendon is excised.
- E The tendon is tied securely to the insertion, after adjustment, if needed, based on superior oblique traction testing.
- F The excised tendon.

continued.

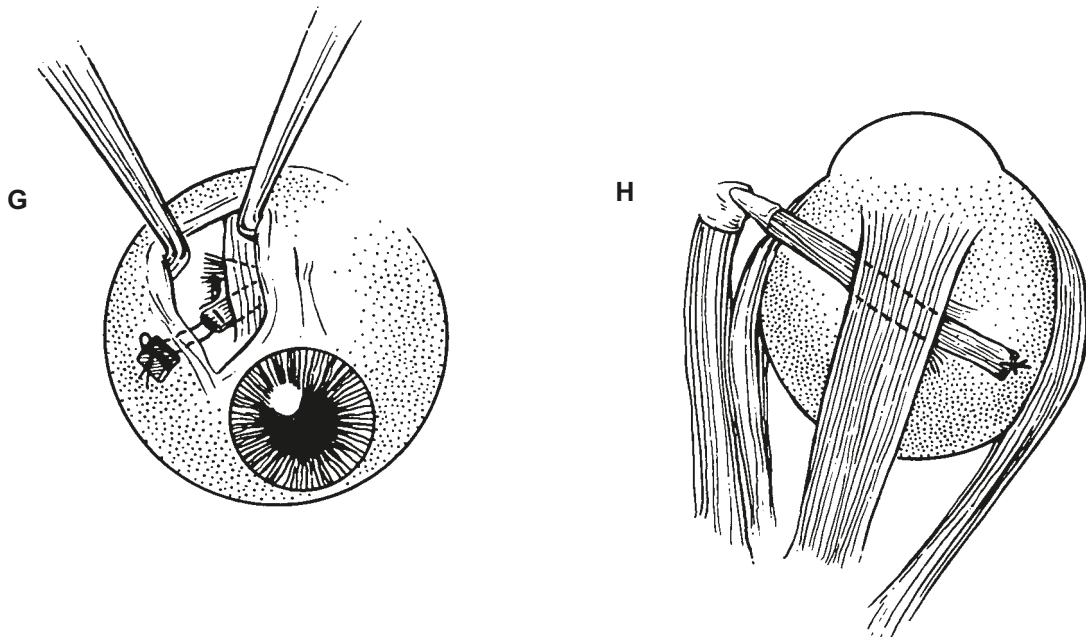


Figure 22, cont'd

G The tendon can be shifted anteriorly if more effect on torsion is required. It may also be tied over a bolster if adjustment is planned.

H The tendon may also be advanced.

10

Marginal myotomy: technique and indications

Historical review

Before the advent of uniform, strong, fine-gauge sutures with sharp swaged-on needles, partial or incomplete myotomy was a commonly employed technique for weakening an extraocular muscle. This technique has now been superseded by measured recession, which is the method of choice now for weakening the rectus muscles in all but a few specific instances. It is important, however, for the strabismus surgeon to understand the principle of marginal myotomy and to be familiar with this technique for use in special cases.

Six types of myotomy that have been employed for reducing the effect of a rectus muscle are shown in Figure 1. Three of the procedures (1, 3, and 5) fail to cut all of the fibers of the muscle and therefore would not be expected to lengthen the muscle. In contrast, techniques 2, 4, and 6 interrupt all of the muscle fibers at some point and would be expected to lengthen the muscle.

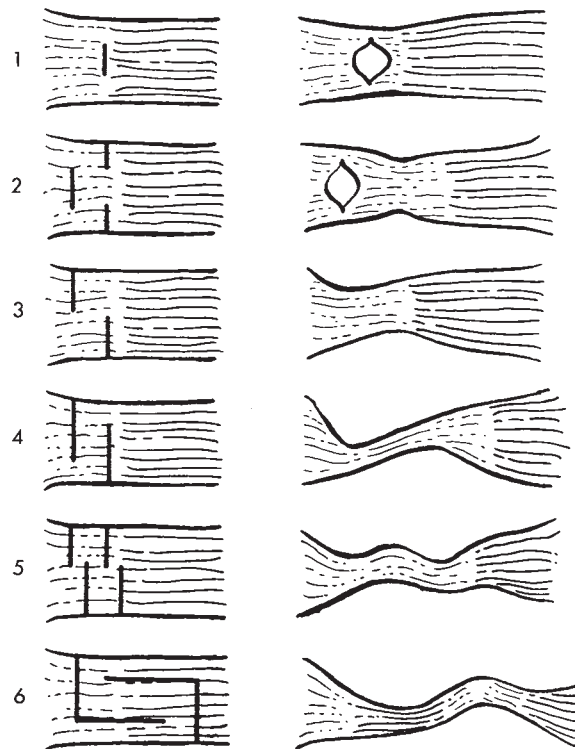


Figure 1

- 1 Central myotomy
- 2 O'Connor "triple cut" myotomy
- 3 Incomplete marginal myotomy
- 4 Overlapping marginal myotomy
- 5 Multiple incomplete marginal myotomies
- 6 L-shaped overlapping double marginal myotomy

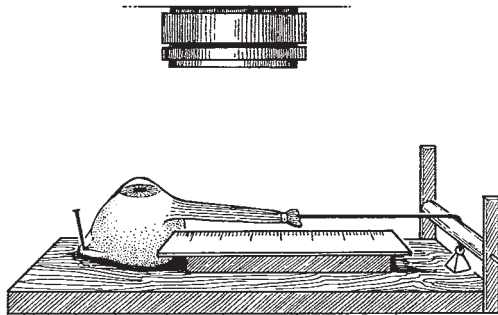


Figure 2
The preparation for recording the muscle lengthening effect of a marginal myotomy.

Quantifying the marginal myotomy

Since, the amount of lengthening produced by specific marginal myotomy techniques remained unknown, we attempted to quantify the marginal myotomy in vitro using freshly prepared rabbit eyes. These eyes were enucleated after euthenizing the animals. Between 10 and 20 mm of rectus muscle remained attached to the globe in the specimens used. The preparation was mounted as shown in Figure 2 with a weight holding the muscle taut and a camera situated above to record the lengthening effect of the myotomies performed. A black silk suture was placed on the distal muscle as reference to show change in muscle length after the myotomy. The four techniques for myotomy shown in Figure 3 were performed five times each and the results were recorded photographically.

Typical results of the experiment are shown in Figure 4. As would be expected, those myotomy techniques that cut across *all* fibers were effective at lengthening the muscle and those not cutting across the muscle did not lengthen the muscle significantly. This leads us to conclude that if lengthening a rectus muscle is more or less equivalent to recessing the muscle as a means of “weakening” the muscle then only those marginal myotomy techniques that lengthen the muscle are effective.

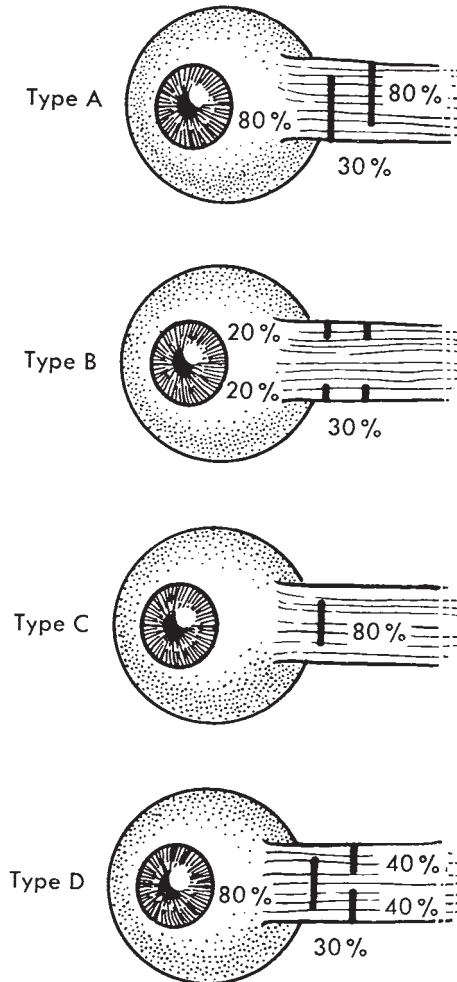


Figure 3
The configurations of the myotomies were as follows:
A The muscle was cut from each border 80% of the muscle width with cuts separated by 30% of the muscle width.
B The muscle was cut twice at each border for 20% of the width with cuts separated by 30% of the muscle width.
C The muscle was cut at its center 80% of the muscle width.
D The muscle was cut at its center 80% of the muscle width and cuts were made at each border 40% of the muscle width and separated from the central cut by 30% of the muscle width.




Figure 4

A Double 80% overlapping marginal myotomies separated by a distance equal to 30% of the muscle's width produced lengthening of 0.9 times the muscle's preoperative width.

B Multiple, nonoverlapping marginal myotomies produced lengthening of 0.03 times the muscle's width.

C A central 80% tenotomy produced lengthening of 0.06 times the muscle's width.

D Two incomplete marginal myotomies, each including 40% of the muscle's width combined with an 80% central tenotomy displaced from the two previous myotomies by 30% of the muscle's width, produced lengthening of 0.5 times the muscle's width.

Technique for a “double 80%” marginal myotomy

The most useful marginal myotomy in my experience is the “double 80%” configuration. To carry out the procedure, the muscle is first engaged on a hook, usually after a limbal incision has been performed to obtain the best exposure. The intermuscular membrane at the borders of the muscle should be dissected only far enough to allow placement of the distal cut. A hemostat is placed across 80% of the muscle width just behind the insertion and a second hemostat is placed at the opposite muscle border across 80% of the muscle with the hemostats separated by 30% of the muscle’s width. (As shown in Figure 5, I have bent a standard hemostat so that the jaws are at right angles to make placement of the instrument easier.) The distal cut is made first.

If the eye is hyperdeviated the proximal cut should come down from above to effectively shift the new insertion down and if the eye is hypodeviated, just the opposite should be done. If marginal myotomy is to be done in a very tight rectus muscle, the proximal cut can be made with a scalpel which cuts against the muscle hook behind the muscle’s insertion. This is done as a safety precaution to guard against inadvertently cutting through sclera that is typically thin in such cases.

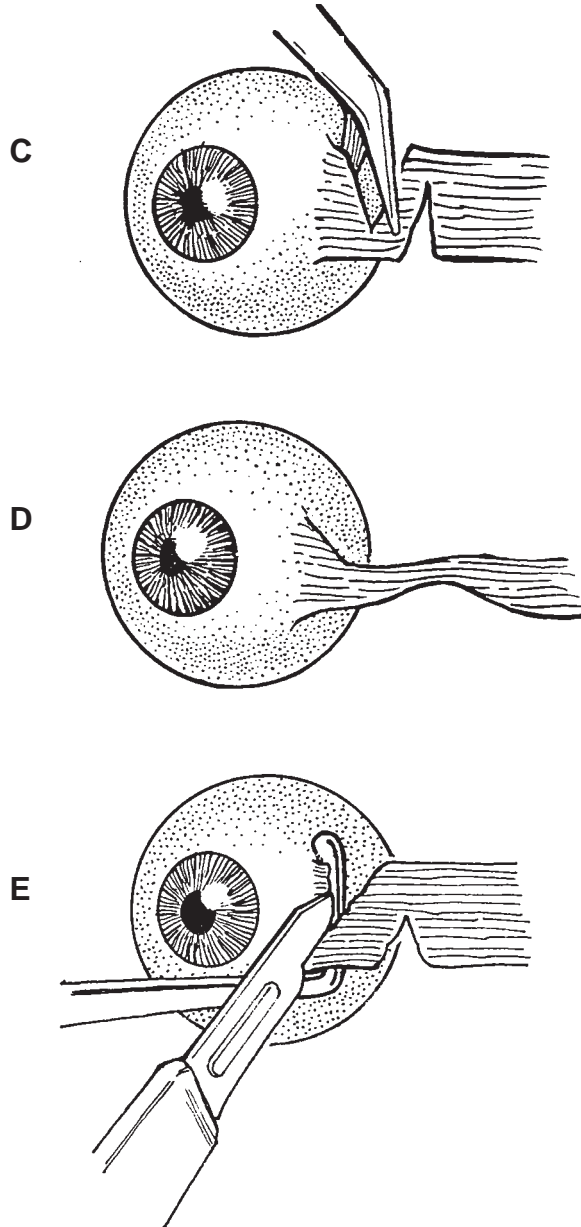
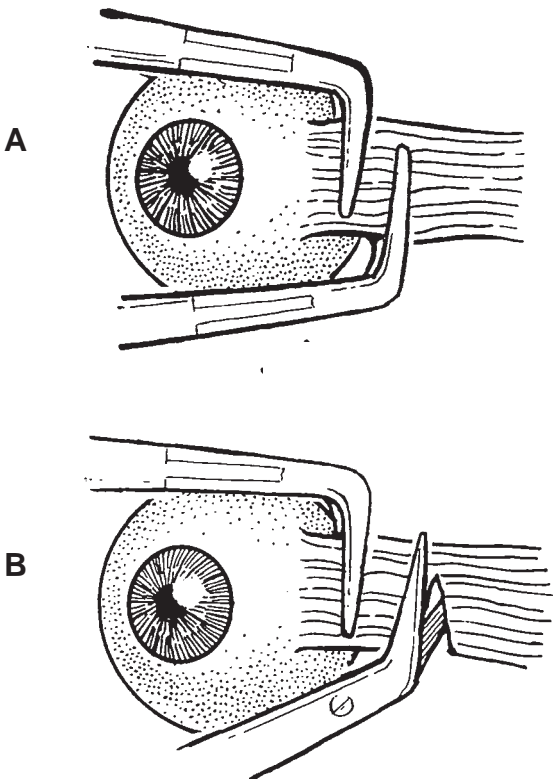


Figure 5

- A** The muscle is exposed in the usual manner and two hemostats are each placed 80% of the way across the muscle (or tendon) from opposite borders. The hemostats are placed 3 or 4 mm apart.
- B** The posterior hemostat is removed, and scissors are used to cut across the muscle in the crushed area. By cutting the muscle in the crushed area, bleeding is kept to a minimum.
- C** The hemostat nearer the insertion is removed, and the muscle is cut along the crushed area using small snips with scissors.
- D** Noticeable lengthening of the muscle will occur. Any bleeding is controlled with pressure.
- E** After the distal myotomy has been performed, in a very tight muscle, a No. 15 Bard Parker blade can be used to divide the tendon fibers, cutting against the muscle hook. This can be accomplished with a scraping motion with the knife blade at nearly right angles to avoid scleral perforation.

Indications for a marginal myotomy

Four reasons for doing a marginal myotomy for the treatment of strabismus include the following:

1. To further weaken a previously operated rectus muscle that has already been recessed to what is considered the maximum amount.
2. When combined with a recession to obtain a “double” weakening effect while retaining a physiologic arc of contact.
3. To weaken a rectus muscle that has at or near its insertion an implant, exoplant, or encircling element used in retinal detachment repair or for glaucoma filtration.
4. To weaken a rectus muscle in a patient who has excessively thin sclera (but a “hang loose” recession would probably be better).

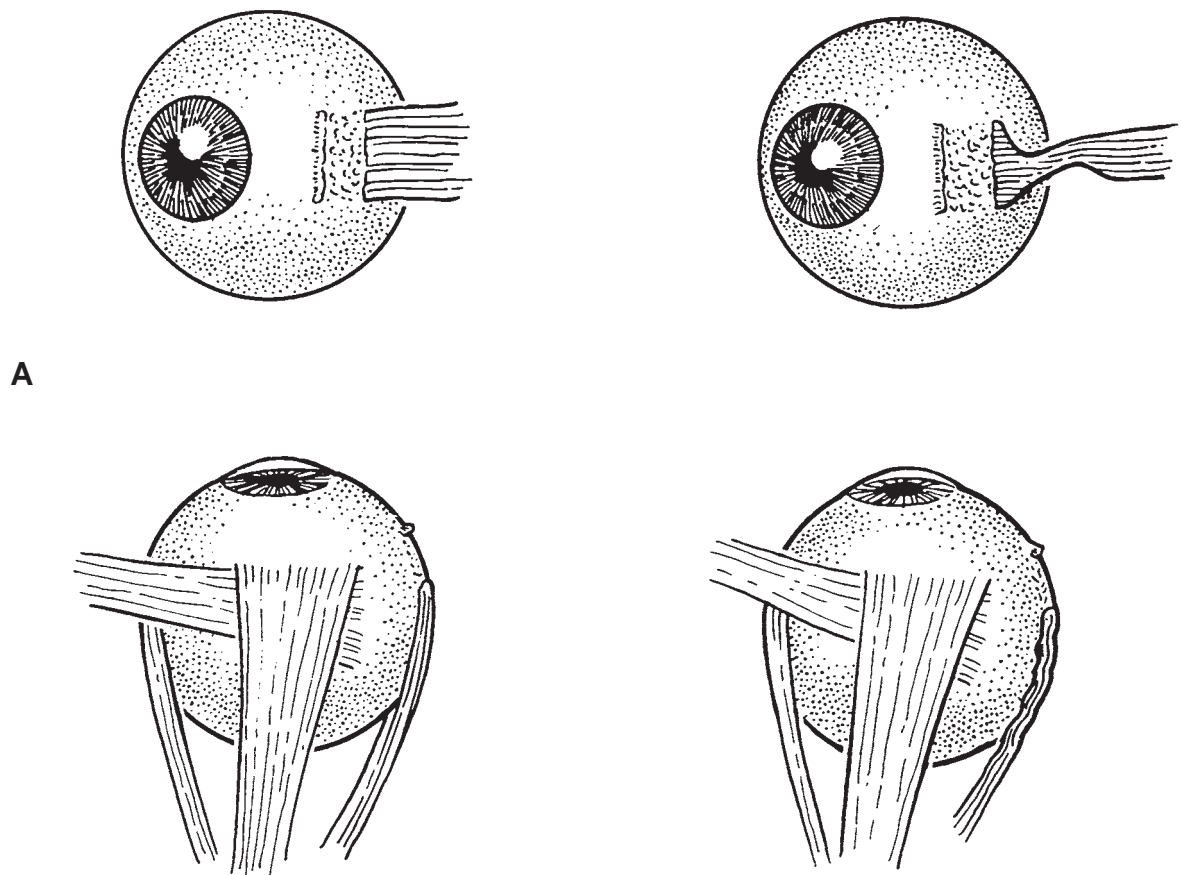


Figure 6

A Marginal myotomy performed on an already recessed lateral rectus muscle provides muscle lengthening without sacrificing the arc of contact.

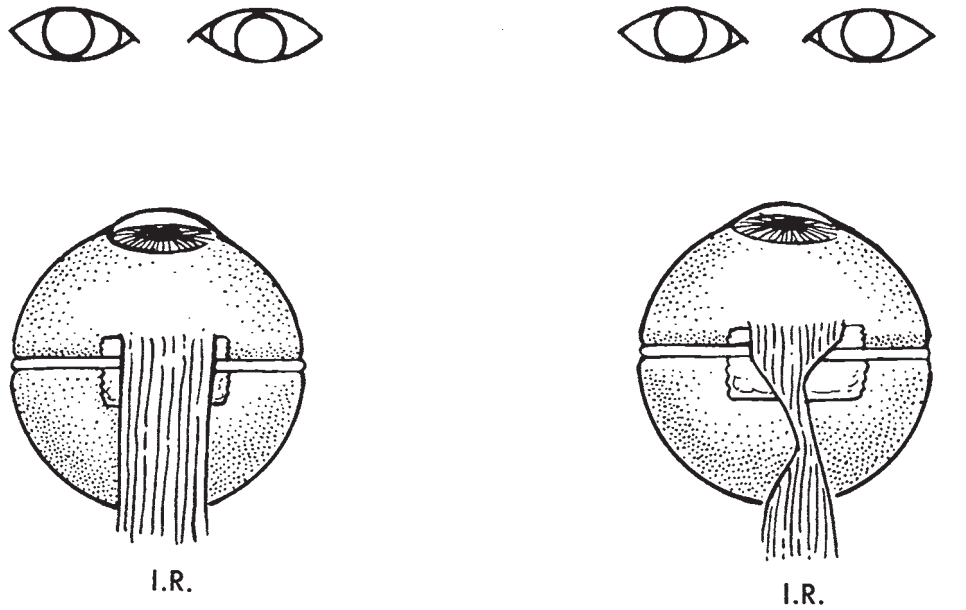


Figure 6, cont'd

B Left hypotropia has occurred after placement of an exoplant and encircling band near the inferior rectus insertion of the left eye. It has been treated with a double 80% marginal myotomy of the left inferior rectus.

Other considerations

The concept that myotomy is effective only if the muscle is effectively lengthened is being challenged. Hertle and associates have demonstrated a damping effect on nystagmus after detaching and reattaching the four rectus muscles.

Alan Scott described graded rectus muscle tenotomy (disinsertion) for treatment of small angle vertical strabismus. He made successive small cuts until the desired results were achieved. Biglan performed a 60% disinsertion of the superior rectus muscle, mostly from the temporal border, in 24 patients

with vertical tropia and diplopia.* The average pre-operative deviation was 8 prism diopters. The average correction at six weeks was 5 prism diopters. Diplopia was relieved in 70% of patients.

I continue to believe that for myotomy to be effective for larger angles and for the longer term, lengthening of the muscle is required. But these observations of expert strabismologists must be taken seriously when considering the effectiveness of partial myotomy for relieving symptoms of small angle strabismus.

* Yim Bin Hye, Biglan A, Cronin TH. Graded partial tenotomy of the vertical rectus muscles for treatment of hypertropia. *Trans Amer Ophthalmol Soc*, Vol 102, 2004, pp. 169-176.

Faden operation (posterior fixation suture)

Posterior fixation suture (retroequatorial myopexy, faden operation)

The modern posterior fixation suture (PFS) was described by Cüppers in Germany. It was done initially in the United States in 1975 after being introduced by Mühlendyck. The procedure has been popularly called the ‘faden operation.’ Faden in German means suture or string. However, more descriptive names, posterior fixation suture or retroequatorial myopexy more appropriately describe the procedure.

The aim of the posterior fixation suture is to shift the effective insertion of a rectus muscle posteriorly employing a principle that was described first by Peters more than forty years before. This posterior shift of the muscle’s insertion theoretically reduces the effect of the muscle only in its field of action. The posterior fixation itself is designed to have little if any effect in the primary position. However, if the muscle posterior to the suture is on a stretch while the suture is placed, redundant muscle between the origin and the fixation suture may effect the muscle’s action in primary position. This may be the reason for reports saying that PFS done on the medial recti are effective in reducing an esodeviation (Figure 1).

The PFS has no effect on the initiation of eye movement or on the behavior of eye movement in the field opposite the muscle having the PFS. The principal effects of the PFS are to somewhat limit the movement of the eye in the field of action of the muscle treated and to cause increased innervation to this muscle and its yoke by Hering’s law as the eye attempts to move in the field of muscle with the PFS.

At the outset, the indication for the PFS was to treat the nystagmus blockage syndrome. This condition has been said to be characterized by: (1) manifest nystagmus damped by convergence, (2) variable angle esotropia, (3) pseudoparalysis of both lateral

rectus muscles with nystagmus on attempted abduction, and (4) preference for fixation in adduction while the head turns in the opposite direction, with or without occlusion of the opposite eye, or for fixation with asymmetric convergence while the head remains straight. Most of these characteristics are shared by the Ciancia syndrome patients as a manifestation of congenital esotropia.

The posterior fixation suture has also been used on the superior rectus muscles to treat dissociated vertical deviation done with or without recession of the superior rectus. However, this procedure did not seem to have sufficient ‘power’ and has been replaced by large recession of the superior recti, and in selected cases anterior transposition of the inferior obliques and, in persistent cases, inferior rectus resection.

Another indication for the PFS, and in my opinion the very best and most useful, is to weaken the sound yoke of an underacting muscle in order to create a secondary deviation which both boosts the action of the weak muscle and slightly limits the action of the sound muscle. This is what I call a *laudable* secondary deviation. Here is an example: A patient has a weak left lateral rectus muscle with limited abduction of the left eye and diplopia in levoversion beginning just a few degrees beyond the midline. With a posterior fixation suture placed on the *right* medial rectus two things happen. First, the right medial rectus works harder to move toward levoversion and therefore sends more innervation to the left lateral rectus by Herring’s law (a secondary deviation). Second, the right eye cannot go as far in levoversion because of the PFS and therefore is less likely to exceed the excursion of the left eye in usual

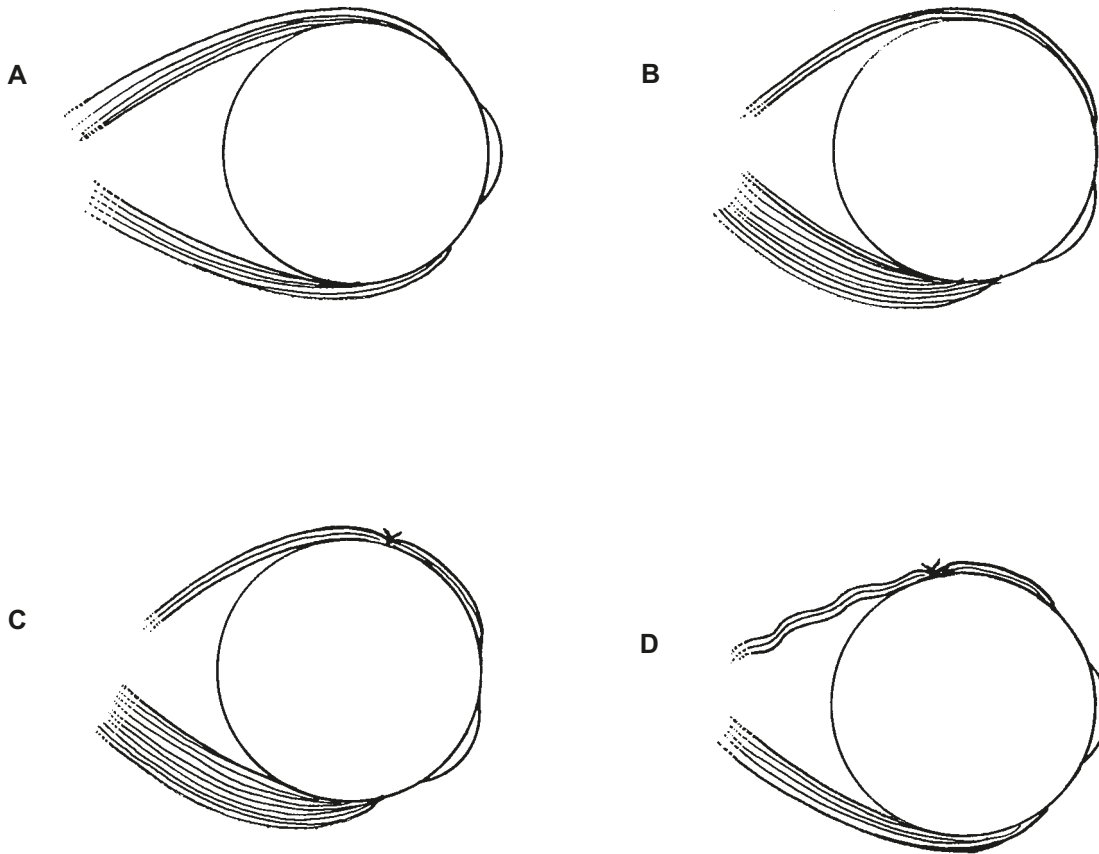


Figure 1

A The eye is shown from above the medial rectus on top.
B With the eye in abduction, the medial rectus is stretched.
C The posterior fixation suture is placed with the medial rectus on the stretch.

D As the eye moves back to the primary position, the medial rectus *behind* the suture is loose or redundant. This would theoretically weaken the effect of the medial rectus in the primary and thereby reduce the esodeviation.

visual activity thereby reducing the likelihood of diplopia (Figure 2).

Although not treating yoke muscles, a PFS may be placed on the normally acting inferior rectus in case of weakness of the other inferior rectus. In this example, there is no secondary deviation effect, only the pure limitation of movement or 'pseudoparalysis' of the sound muscle treated with the PFS. This would result in the two eyes being more nearly matched in down gaze thereby avoiding or at least reducing diplopia. Because far up gaze is

less important than down gaze including the reading position (except in certain exceptions) this procedure is less likely to be indicated for the superior rectus (Figure 3).

I have used a posterior fixation on the four horizontal rectus muscles as a means of treating nystagmus. The few cases that I treated were not successful. Recession of the four horizontal rectus muscles has been effective for treatment of nystagmus, and Hertle has reported success with simple disinsertion and reinsertion of the muscles.

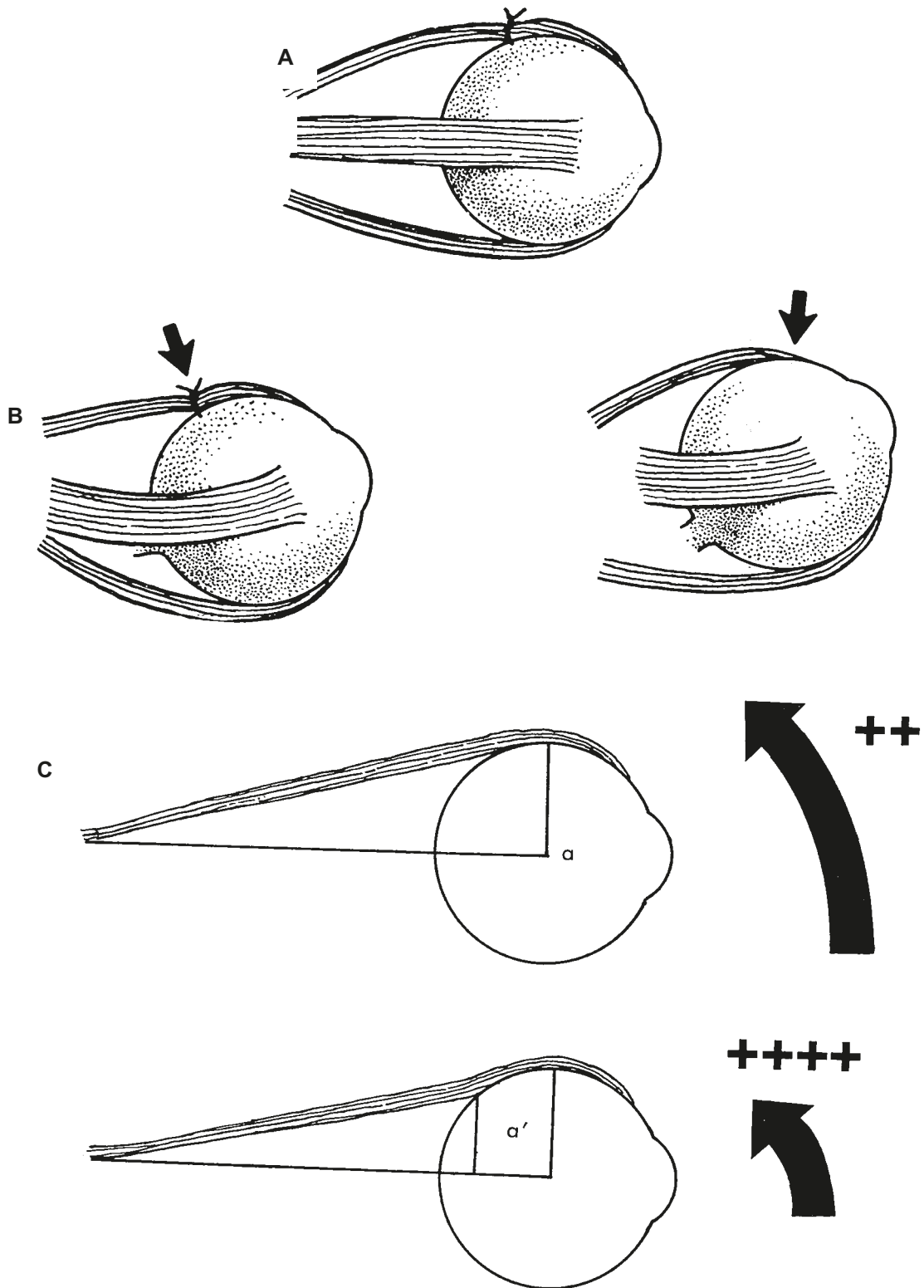


Figure 2

A The muscle is secured to underlying sclera at or just behind the equator.
B The extent of rotation of the eyeball is restricted by the suture compared to movement without the suture in place.

C The new effective insertion creates a reduced lever arm for the muscle. This reduced lever arm results in the need for increased innervation for the muscle to achieve its full (though reduced) rotation.

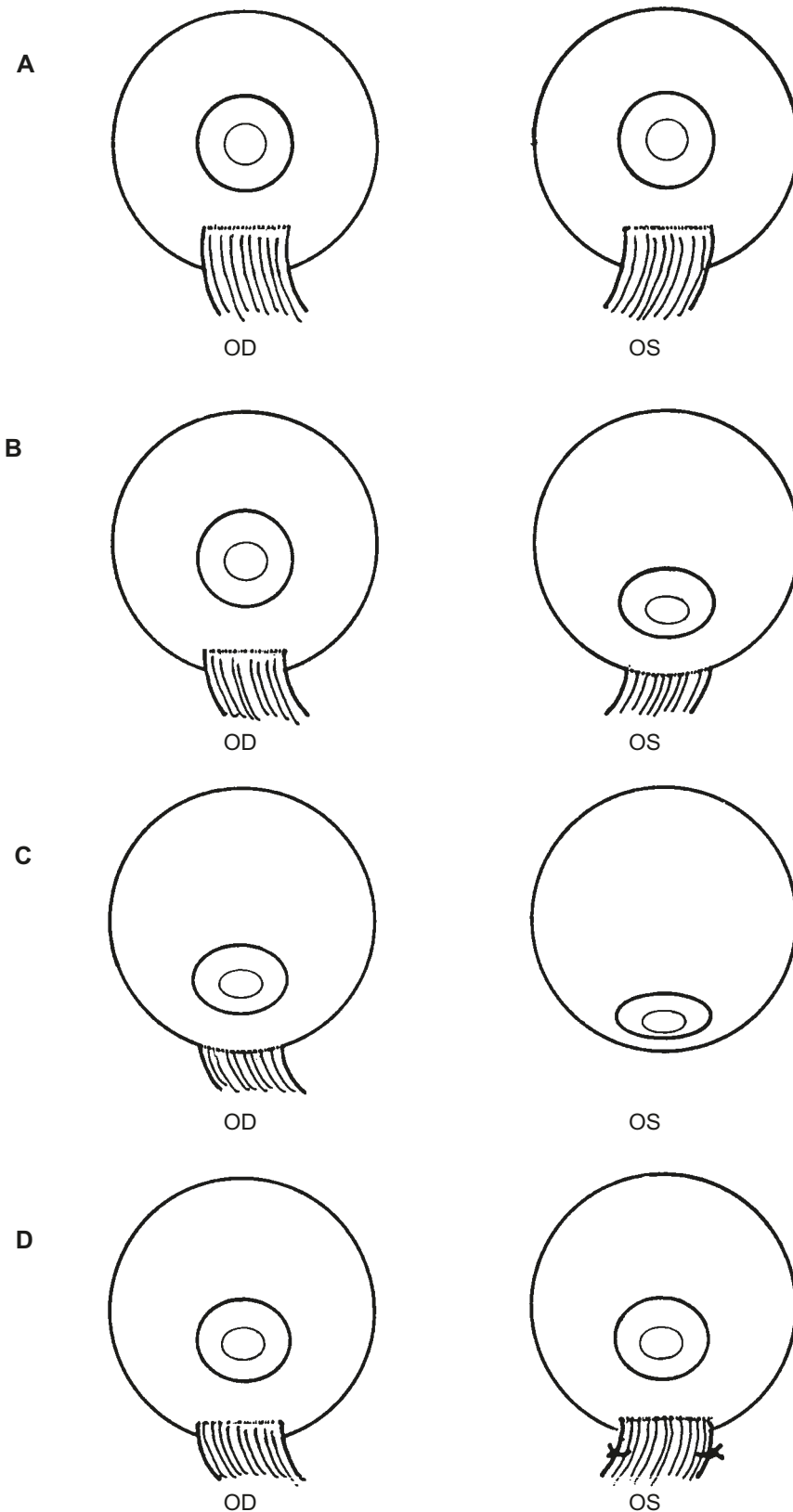


Figure 3

A The eyes are aligned in the primary position.
B The right eye has deficient depression from a right inferior rectus paresis.
C In far down gaze, the left eye moves normally, resulting in an increasing right hypertropia and diplopia in the reading position.

D With a posterior fixation suture placed on the normal left inferior rectus, the movement downward in this eye is somewhat limited making it more nearly match the right eye. The yoke of the left inferior rectus, the right superior oblique, a depressor of the right eye, would also receive more innervation to down gaze.

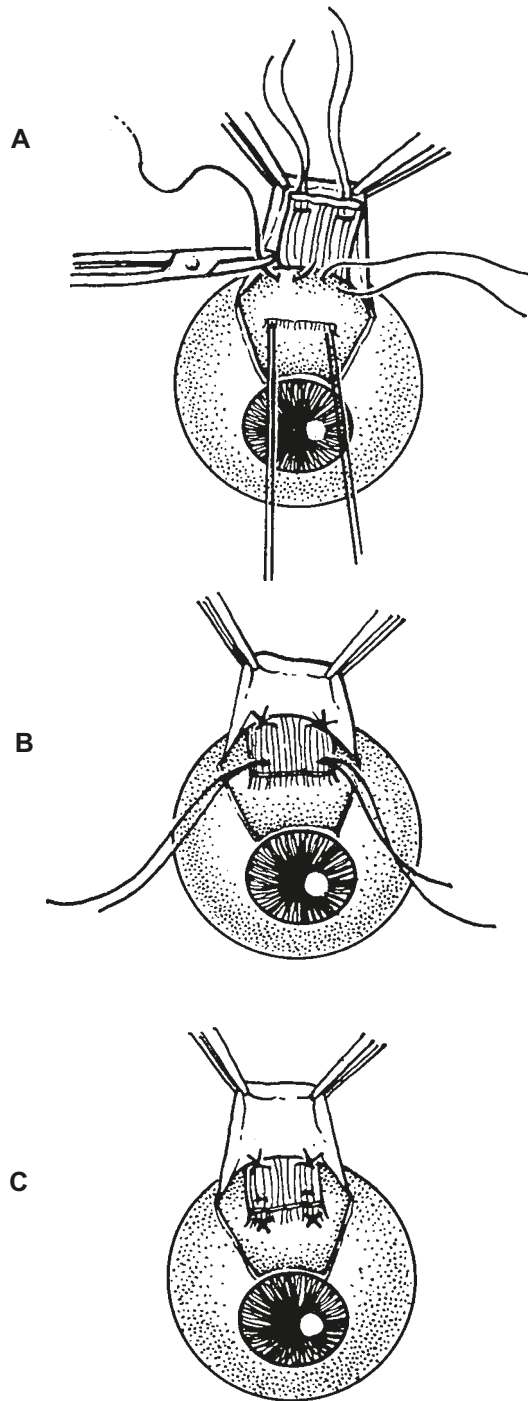


Figure 4

- A** The rectus muscle may be tagged with sutures at the insertion and detached. Two sutures are then placed in sclera at or just behind the equator to secure the muscle at the borders. Non-absorbable suture, 5-0 or 6-0 is used.
- B** The posterior fixation suture sutures are tied securely.
- C** The muscle is reattached at the insertion.

Placement of the posterior fixation suture after detaching the muscle

To be effective, it has been said that the posterior fixation suture should be placed at or just behind the equator. However, recent description of the muscle pulleys has led to a concept that the PFS need not be placed behind the equator to be effective. In either case, the placement of the suture can be challenging and requires good exposure (Figure 4).

Placement of the posterior fixation suture without detaching the muscle

A posterior fixation suture may be placed without recession of the muscle in cases where no effect is needed in the primary position. This is usually done with placement of sutures at each muscle border (Figure 5).

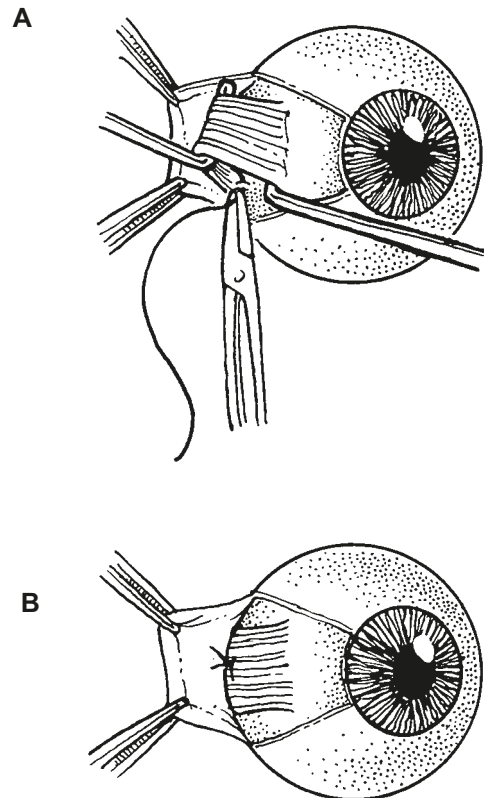


Figure 5

- A** After obtaining adequate exposure, the muscle is retracted and a 5-0 or 6-0 non-absorbable suture is placed at the muscle border at or just behind the equator. A limbal incision is a good choice to gain best exposure. The flap is being held with forceps. Better exposure is obtained with a Barbie retractor.
- B** After placement of the sutures, the muscle looks relatively undisturbed. (An optional single central suture is shown)

‘Reinforced’ posterior fixation suture

The purpose of the posterior fixation suture is to produce a firm adherence of the undersurface of the muscle to sclera beneath and thereby create a new effective insertion for the muscle. To accomplish this, some surgeons prefer to make several passes through sclera and muscle. When multiple suture passes are employed, the suture is placed in the usual manner except that two or three bites are taken in sclera and after each of these bites, the suture is brought through the muscle. The potential problem with this is that the chance of scleral perforation is increased. This problem is accentuated by the fact that needles usually found on 5-0 or 6-0 non-absorbable sutures are often heavier cutting needles that increase the likelihood of inadvertent scleral perforation. To avoid this, the surgeon should exercise great care in placing the needle in sclera (Figure 6).

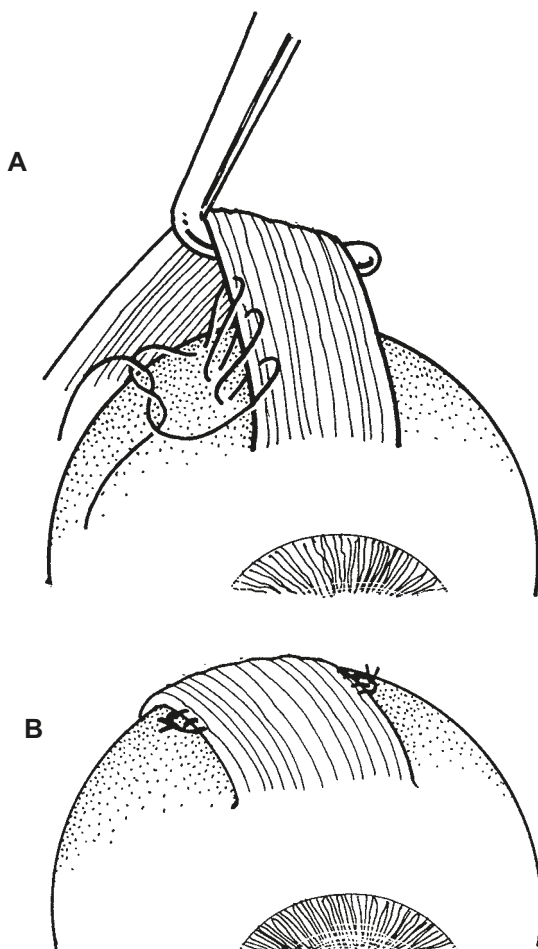


Figure 6

- A** For a ‘reinforced’ posterior fixation suture, the belly of the muscle is elevated and two or three suture passes go through sclera and muscle.
B After the identical suture placement is carried out on the other border of the muscle, the sutures are tied securely.

Combined posterior fixation and recession

When recession of a rectus muscle is combined with placement of a posterior fixation suture, the recession should be carried out *before* the posterior fixation suture is placed. This ensures that the recession will be effective. If this were not done, redundant rectus muscle would be *distal* to the posterior fixation suture that would be the new effective insertion, reducing or nullifying the recession effect (Figure 7).

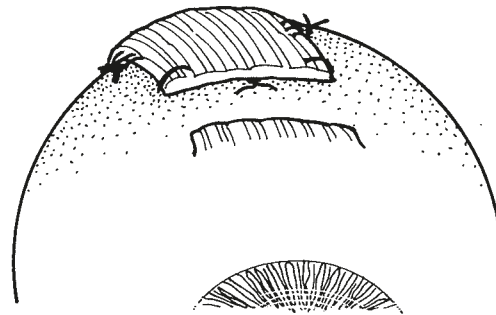


Figure 7

Recession has been carried out and then the posterior fixation suture is placed. This means that the length of muscle between the PFS and the muscle origin is longer, thereby achieving both the recession effect *and* the posterior fixation suture effect.

Adjustable ‘faden’

Alan Scott has suggested a novel method for creating a posterior fixation suture in a way that is potentially adjustable. To do this, a double arm suture is placed in the muscle at about the point where a posterior fixation suture would be placed. The muscle distal to this suture is then excised! This means that the muscle is not shorter, it just inserts closer to the origin as with the posterior fixation suture. The sutures are then brought through the muscle’s original insertion and a suitable temporary knot is placed. The theory behind this technique is that the muscle distal to the suture placement of the posterior fixation suture is probably irrelevant anyway (Figure 8).

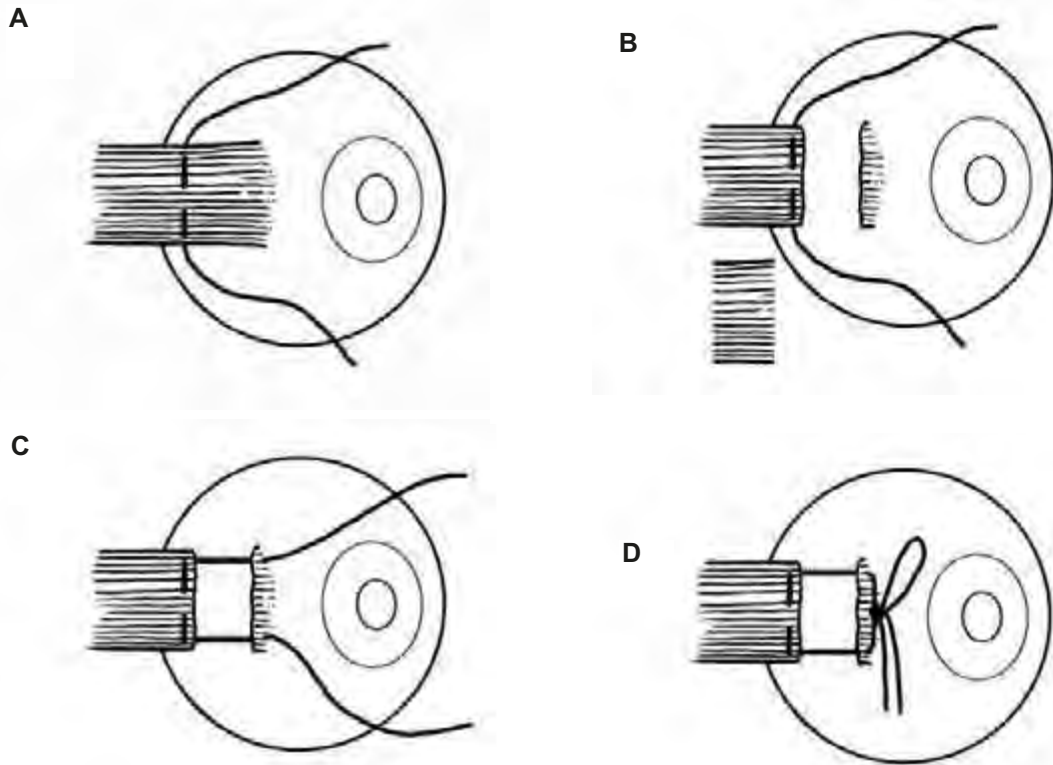


Figure 8

- A** A double arm suture is placed 12 to 14 mm from the insertion, or at the point on the muscle where the posterior fixation suture would be placed.
- B** The muscle/tendon distal to the suture is excised.

- C** Suture ends are brought through the original insertion.
- D** A knot that can be released for adjustment and tied securely later is placed.

Adjustable sutures: techniques for restrictions

Overview

Adjustable sutures were used commonly in the early years of strabismus surgery. They were used out of necessity rather than choice. Sutures were coarse and needles were heavy with the result that muscles could not be attached to sclera either accurately or safely. Sutures were anchored in conjunctiva and Tenon's with the muscle lying on but not attached to sclera. Adjustments may not have been precise in these patients, but were necessary to obtain the best possible results.

When catgut sutures with swaged-on needles became the standard for strabismus surgery, adjustable sutures were no longer employed. These sutures had the advantage of being absorbable and the needles were finer making for more accurate surgery. The disadvantage of catgut sutures was that they broke easily making them unsuitable for the adjustable technique. Actually a suture broke once in almost every case during the course of surgery, especially when an assistant was allowed to tie a knot. During the 1960's when I started doing strabismus surgery adjustable sutures were neither done widely nor talked about.

Adjustable sutures were 're-discovered' and popularized by Jampolsky after synthetic absorbable sutures became available in the 1970's. This technique is currently used widely for treatment of a wide variety of strabismus conditions. Their use, however, is not universal. Some surgeons use adjustable sutures for nearly every case stating that better results are achieved if a 'second chance' is available or saying that better results can be achieved if the postoperative alignment can be determined with the patient awake and cooperating. Other surgeons use them either sparingly or not at all. The belief among these surgeons is that in most (all) cases more precise surgery can be accomplished by attaching the

muscle securely to sclera at a predetermined point based on patient history, work-up, and intra-operative findings.

I use adjustable sutures in fewer than 10% of cases. This is actually an increase from about 3% earlier. This increase is due to the use of the tandem adjustable that actually requires adjustment only 25% of the time. When adjustable sutures are used they are limited to older children and adults with conditions including: previous unsuccessful surgery, thyroid myopathy, diplopia after successful cataract surgery, strabismus after trauma, restrictive strabismus, etc. For treatment with an adjustable suture, a muscle should have contractile power to rotate the eye and should be working against an antagonist muscle capable of relaxing.

Technique for the adjustable suture

There are several effective techniques for placement of an adjustable suture. Regardless of the technique used, the following principles remain constant.

1. The muscle is secured with suture that is sufficiently strong to withstand postoperative manipulation.
2. The muscle is attached to the globe usually at the muscle's insertion stump in a 'hang loose' manner.
3. The suture anchoring the muscle is secured in a way that it can be easily loosened and then re-tied at the time of adjustment.
4. The suture is able to slide through the site of attachment to the globe allowing the muscle to slide back or be pulled forward.

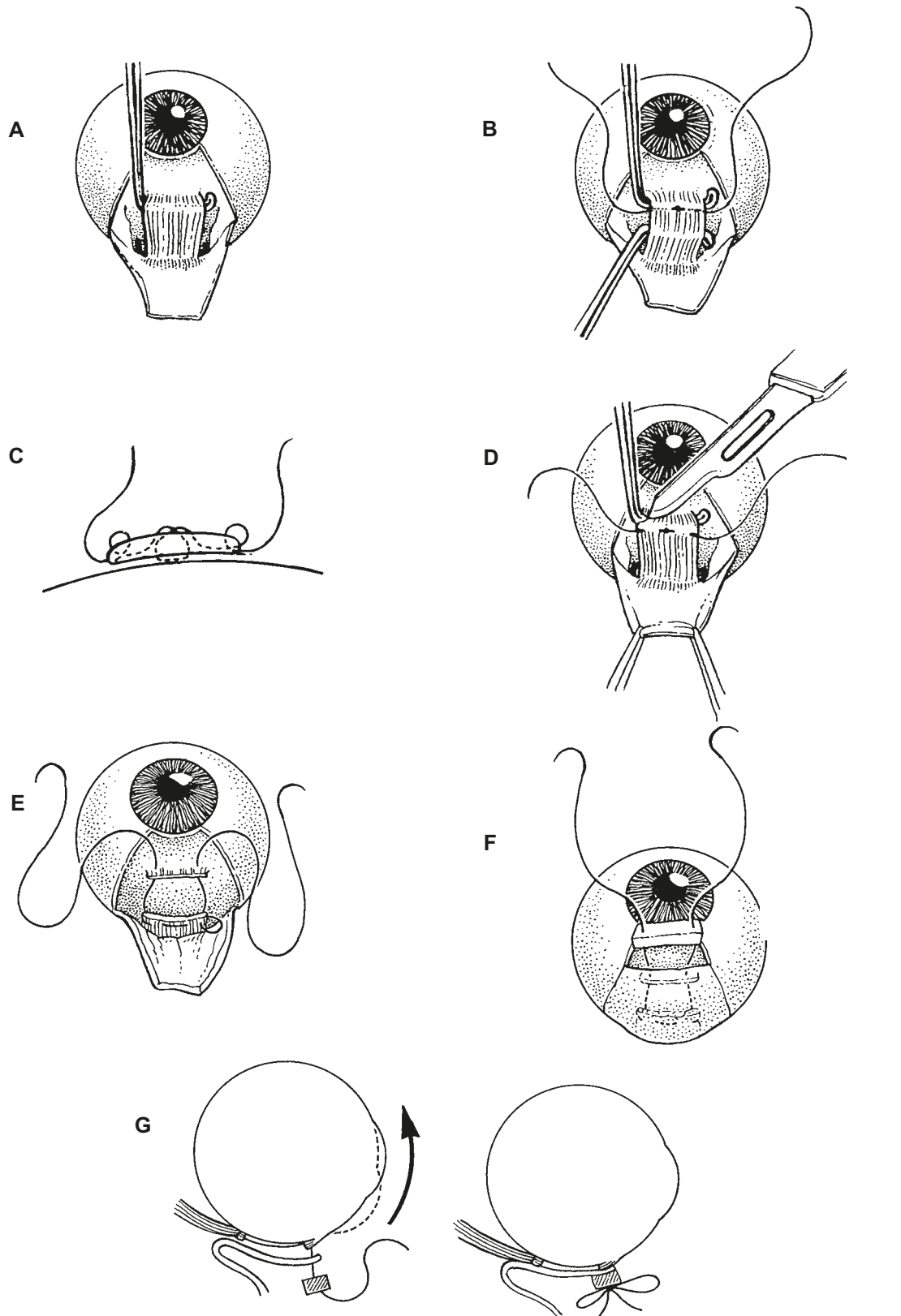


Figure 1

- A** The muscle is exposed.
- B** The suture is placed 1 to 1.5 mm from the insertion (a 'handle-suture' as shown in Figure 2 is placed in all cases).
- C** The suture is secured with a central bite which is tied and locking loops are placed at the borders.
- D** If the muscle is tight, it is cut from the globe with a scalpel, cutting against a muscle; otherwise scissors are used.

- E** The sutures are brought through the muscle's stump.
- F** If a bolster is used, the suture is brought through after putting the needles through conjunctiva to produce a conjunctival recession (as shown) or through conjunctiva overlying the stump.
- G** The suture is tied over the bolster (if used) or on conjunctiva.

5. The incision in conjunctiva should be made so that the surgeon can access the suture at the time of adjustment and then close the conjunctiva satisfactorily with the patient awake.
6. The use of adjustable sutures are effectively limited to the rectus muscles (Figure 1).

In every case of adjustable suture, a so-called 'handle suture' is placed in superficial sclera usually near the limbus. This is used for stabilizing the eye, securing the muscle, and in rotating it at the time of adjustment. The suture can be temporarily tied with a bow knot, a slip knot, or a 'noose like' cinch knot that can be secured tightly or loosened to slide up and down the suture as needed during adjustment.

Use of an adjustable suture begs the question, "Where should the eyes be placed at the time of adjustment?". While there is no reliable answer to this question, I tend to leave the eyes in the alignment I would like to achieve at the same period postoperatively if the muscle had been firmly attached to sclera at the time of operation. Patients with postoperative diplopia are adjusted to a diplopia-free position. Non-fusing exotropic patients are left straight or slightly exotropic; non-fusing esotropic patients are left straight or slightly esotropic. Because I never use an adjustable suture in a patient treated surgically for intermittent esotropia, I can

only suggest leaving the eye in the same alignment that is preferred when standard surgery is performed; that is, a slight overcorrection.

A 'handle' of 6-0 Vicryl placed in sclera at the limbus as a means of grasping and manipulating the globe during adjustment is shown in Figure 2. The 'handle' must be exposed at the conclusion of surgery regardless of which type of incision has been used. A forceps grasping the handle allows relatively easy rotation and stabilization of the globe during surgery and during adjustment. A three-cornered limbal incision may be used that can be taken down at the time of adjustment and repaired when the adjustment is completed. A sliding knot over the sutures suspending the muscle can be helpful during adjustment. The sliding knot is secured at surgery when the muscle is at the intended position and the suture ends are tied. At adjustment, the knot may be loosened and slid toward the cornea while the patient looks in the opposite direction as the globe is stabilized with the handle suture if the recession effect is to be increased. If the recession effect is to be lessened, the suture holding the muscle is pulled up and the slip knot is slid toward the muscle. When a cul-de-sac incision is used, a handle suture is placed at the upper insertion in case of an inferiorly placed incision. For adjustment, this suture is pulled up to center the incision over the muscle stump.

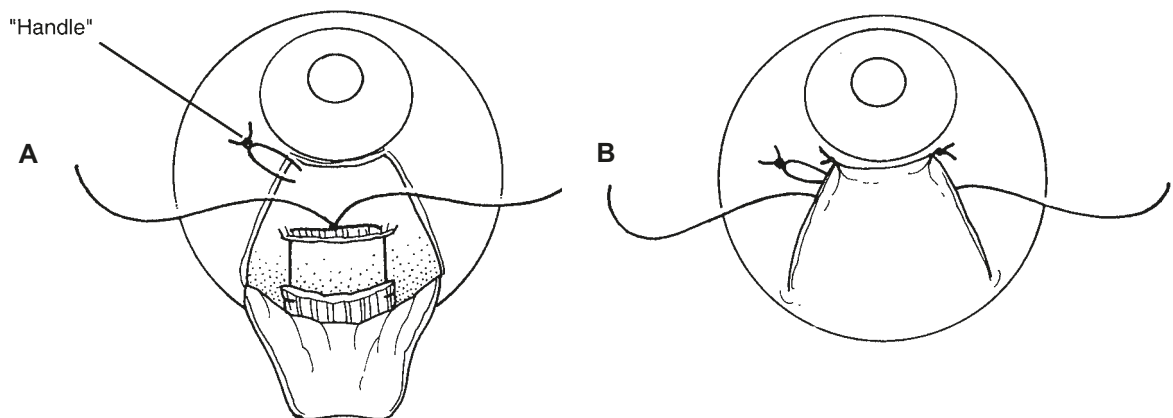


Figure 2

A The 'handle' suture.

B The suture ends must be retrievable.

continued.

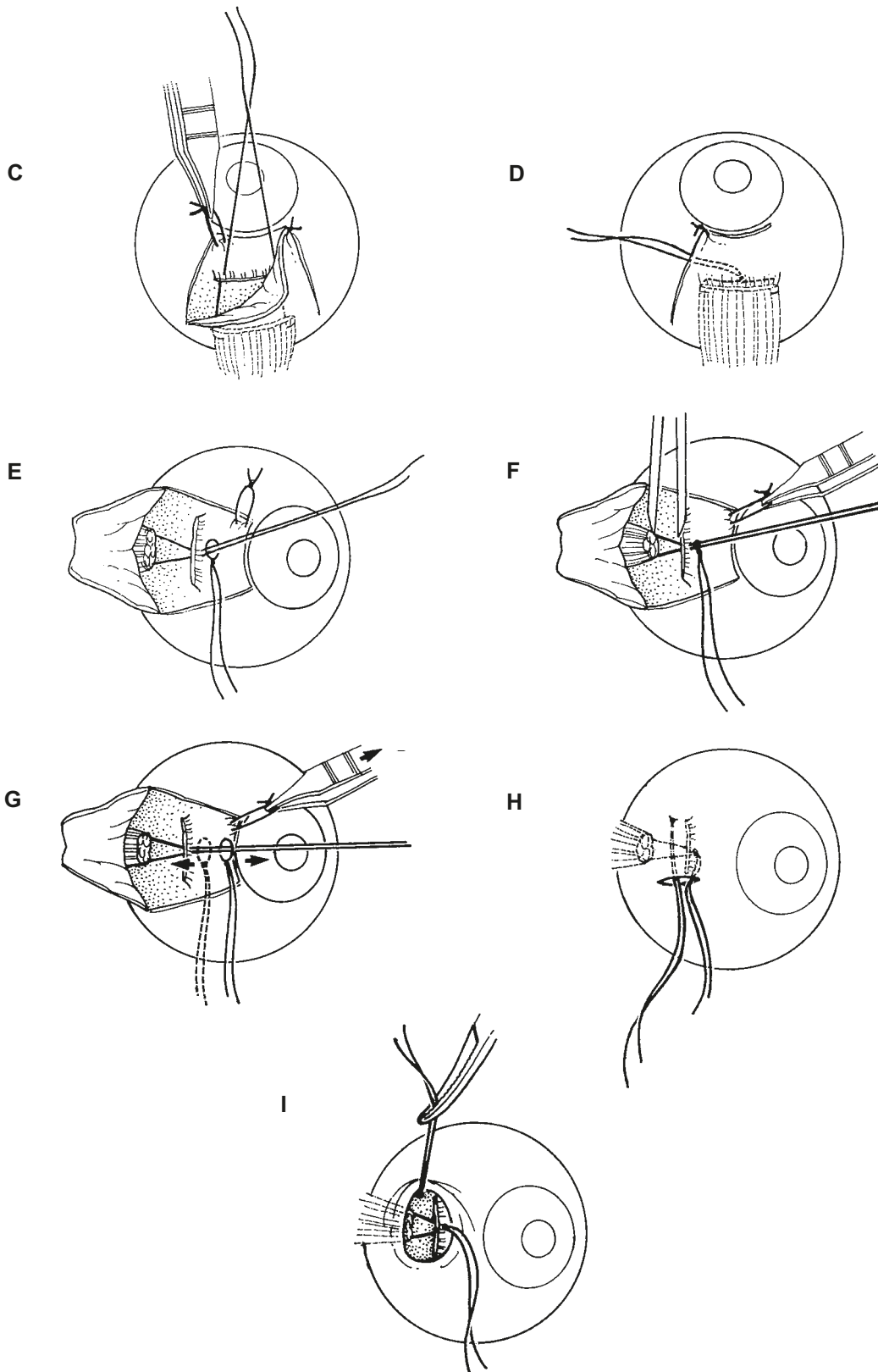


Figure 2, cont'd

C The handle suture stabilizes the globe during adjustment.
D A 'three cornered' limbal incision may be used.
E The sutures may be secured with a slip knot.
F The amount of 'hang back' can be measured.

G The muscle is advanced or it drops back sliding through the slip knot which is tightened when the muscle is in the intended position.
H Both the handle suture and the adjustable suture are led out through the cul-de-sac (inferior) incision shown.
I The handle suture lifts the incision over the muscle insertion.

Tandem adjustable suture

A useful modification of the adjustable suture is the tandem adjustable suture. It combines the 'hang back' suture with the adjustable suture (Figure 3). Using this technique a 'static' hang back suture is placed putting the eye at the position the surgeon thinks will be most likely to achieve the desired alignment. If that is the case, a stable situation prevails and there is no need to manipulate the suture in the process of re-tying, and securing as would be required if a single suture capable of adjustment were used. If the muscle is too far back,

the second or tandem suture is simply tied tighter without the risk of the muscle slipping back and the possibility of the surgeon losing track of where the muscle is at the start of adjustment. If the muscle needs to be let back farther, the first or 'hang back' suture is cut and the second tandem suture is used in the usual manner for an adjustable suture. In my experience, the tandem suture needs adjustment less than 25% of the time. This makes the tandem suture, in my experience, the most convenient technique to use when an adjustable suture is called for.

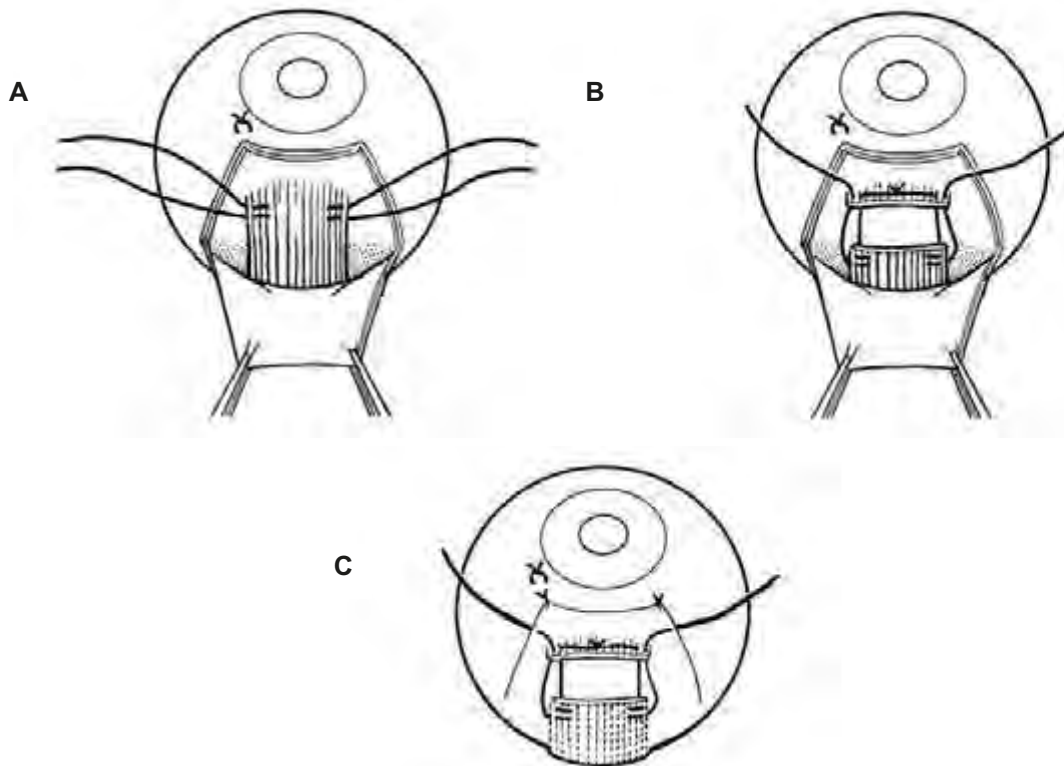


Figure 3

- A** Two 6-0 vicryl sutures are placed 1.5 and 2.5 mm from disinsertion.
- B** The muscle is detached and the proximal (nearer the insertion) sutures pass through the stump producing a 'hang loose' recession, placing the muscle where the surgeon thinks best. The distal sutures are brought through the stump outside the first sutures - they are left untied.

- C** The incision is closed with the adjustable suture ends exposed. If no adjustment is needed the adjustable sutures are cut.

continued.

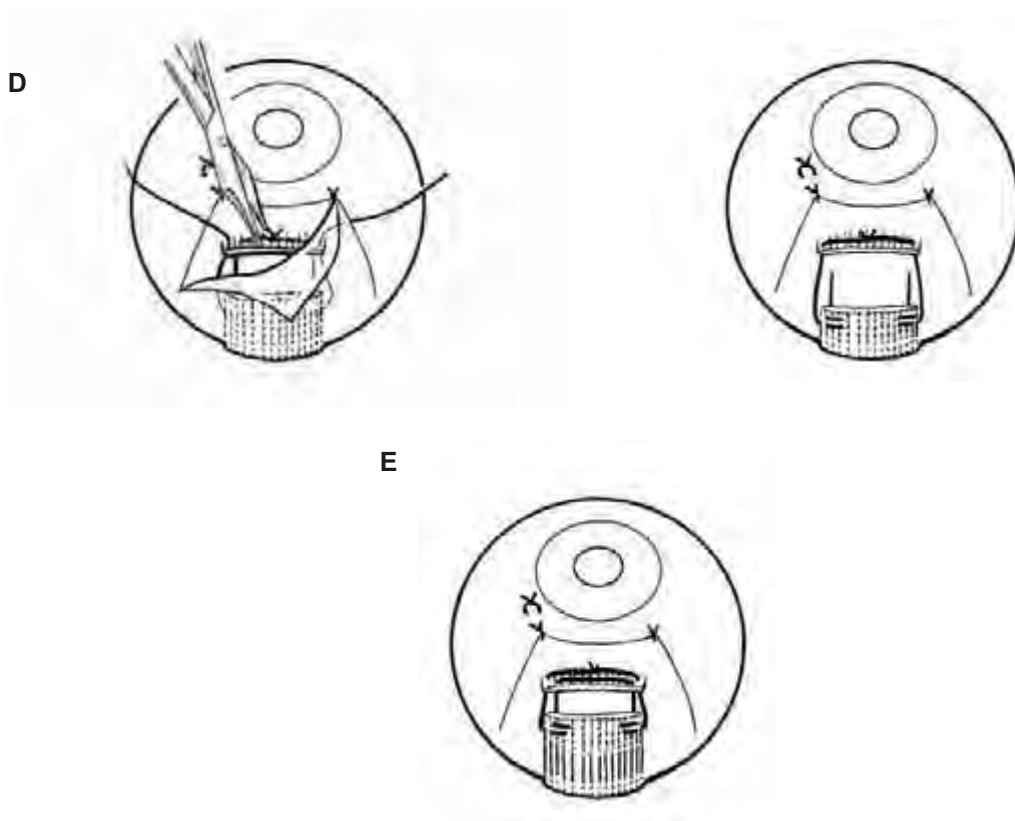


Figure 3, cont'd

D If at adjustment the muscle is to be let back the first suture is cut and the muscle is adjusted using the second suture.

E If the muscle is to be adjusted closer to the insertion, it is simply pulled up with the adjustable suture. The first suture is redundant.

Adjustable suture considerations

Important considerations for the adjustable suture technique are ease of adjustment, accuracy of final alignment, and patient comfort during and after surgery and during adjustment. Enthusiasm for use of adjustable recession and resection varies widely among even the most experienced surgeons. Some never use this type of surgery stating that the technique is absolutely unnecessary and that excellent results can be obtained without using adjustable sutures. Other equally experienced and competent surgeons use adjustable sutures in every patient who will cooperate for adjustment with few exceptions. The majority of surgeons probably occupy the middle ground, using the adjustable suture technique only in selected cases. I perform adjustable suture surgery on less than 10% of adult patients undergoing strabismus surgery.

As with the use of adjustable sutures, timing of adjustment varies widely among surgeons. When a patient has topical or perilimbal anesthesia with minimum sedation, I prefer to carry out the adjustment while the patient is on the operating table, positioning

the eye appropriately and then carrying out cover testing. If the patient is able to respond, I ask whether the patient sees two and by careful adjustment work to eliminate the diplopia. If general anesthesia is used, I merely attempt to center the eye and carry out the adjustment later. The suture may be adjusted on the day of surgery, or in the recovery room an hour or more after surgery if the alignment is significantly different than intended. The most common and most productive time for adjustment is approximately 24 hours after surgery, either at the bedside for those patients who are admitted to the hospital or in the clinic for outpatients. Topical anesthesia with proparacaine hydrochloride, tetracaine, or 5% Xylocaine may be used. A lid speculum is helpful to give exposure while picking up the suture ends. Tying forceps are used to grasp the suture holding the muscle and a fine utility forceps is used to grasp the handle suture. Scissors are used to trim the suture ends after the adjustment has been completed. One surgeon I know claims to be able to adjust a muscle as late as 10 days after surgery. Although I believe her,

I would not attempt an adjustment that long after surgery. From experience with a few cases of early reoperation, I believe that a fairly firm myoscleral union is formed in just a few days. Rather vigorous manipulation of the globe is required to accomplish late muscle adjustment. As with surgery performed with topical or local anesthesia, the pain during adjustment comes mainly from traction on the muscle and is deep in the orbit. This can cause syncope and nausea. For adjustment it is a good idea to either have the patient lying down or have a bed available nearby. The patient may take a mild oral analgesic a few hours before the adjustment to make them more comfortable.

Conjunctival recession

When the conjunctiva is recessed because of tightness that restricts free movement of the eye, it is usually necessary to move the limbal margin of the conjunctiva back 5 to 7 mm or to the insertion site of the recessed muscle. In the rare case where conjunctival recession is performed without recessing the rectus muscle, the limbal margin is moved to a point just covering the insertion of the muscle. When the conjunctiva is severely scarred it may be excised and the cut edge of conjunctiva attached to underlying sclera. This step may be carried out medially as far as the plica semilunaris. Because the medial conjunctiva containing the plica semilunaris and caruncle has more tissue and because the medial recti are the most frequently operated extraocular muscles, medial conjunctiva is the area most frequently in need of revision. In contrast to reddened scars of the conjunctiva, clear subconjunctival cysts which occur occasionally after eye muscle surgery can be removed, sometimes intact, without the need to recess the conjunctiva provided the overlying conjunctiva remains elastic.

When reoperating a patient who has undergone a previous conjunctival recession, it is necessary to enter sub-anterior Tenon's space at the point where conjunctiva had been recessed. The sclera in the area of conjunctival recession becomes re-epithelialized with a thin layer that adheres tightly to underlying sclera. It should not be disturbed. Patients are usually comfortable after conjunctival recession. Ointment is used twice a day after surgery (switching to drops in the morning if ointment causes blur) and no patching is necessary. It is also important to remember that conjunctiva becomes extremely thin and friable in older patients. Even some patients in their 20's may have very thin conjunctiva. Nearly all patients 30 years and older have very thin conjunctiva. Therefore, it is impractical to attempt a cul-de-sac incision in an older patient unless the surgeon has inspected the conjunctiva and has determined that it could withstand the necessary manipulation.

Eyes with longstanding esotropia usually have a foreshortened conjunctiva that restricts abduction. A limbal incision is made in the usual manner encompassing approximately 2 to 3 clock hours centered over the muscle's insertion with radial relaxing incision approximately 10 mm long. For closure with recession, conjunctiva-Tenon's is sutured to sclera with three interrupted 8-0 Vicryl sutures used. With the conjunctiva sutured in place, the bare sclera is left to re-epithelialize in a day or so.

With a severely scarred conjunctiva, the entire conjunctival flap may be excised and the cut end of conjunctiva sutured to underlying sclera and the relaxing incision sites sutured to adjacent conjunctiva-Tenon's. When medial scarring is extensive, the medial conjunctiva can be excised as far medially as the plica semilunaris. The plica is then sutured directly to underlying sclera far medially (Figure 4).

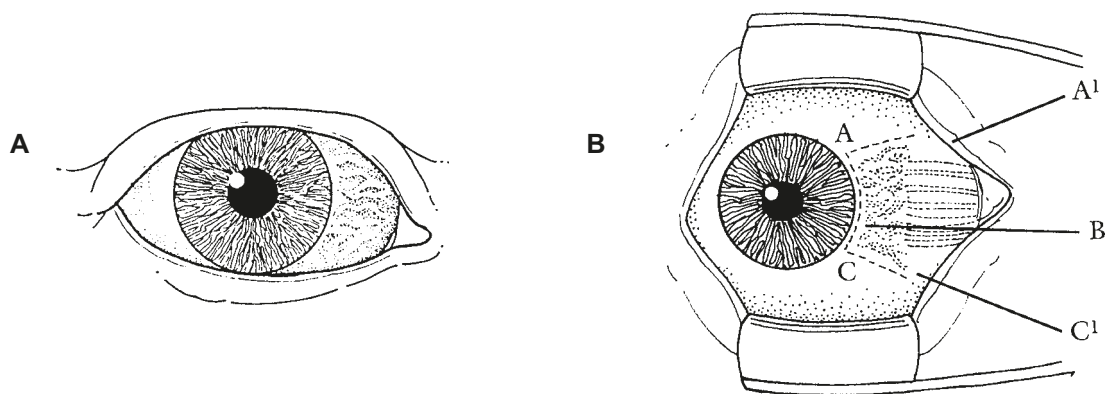


Figure 4

A Tight, scarred conjunctiva

B For conjunctival recession A is attached to A₁ and C to C₁. A third suture is placed in the center.

continued.

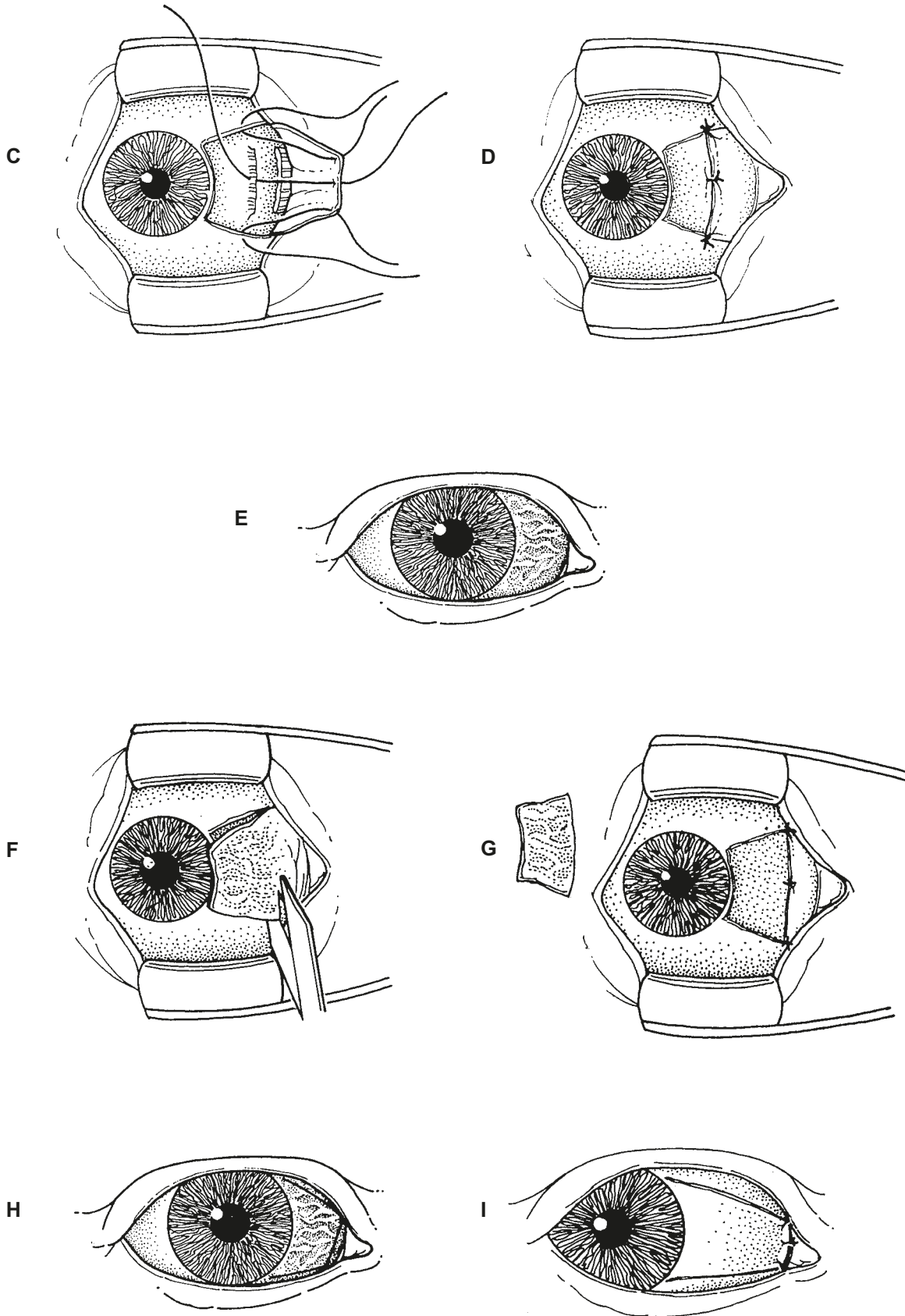


Figure 4, cont'd

C Conjunctival recession sutures are placed.
 D The conjunctival recession is completed.
 F Very thick conjunctiva can be excised,

E Scarred medial conjunctiva
 G and the cut edges of conjunctiva sutured to sclera.
 H In extreme cases of conjunctiva scarring,
 I Pratt-Johnson has excised conjunctiva to the caruncle.

Traction sutures

When the surgeon is concerned that postoperative adhesions may cause the globe to remain fixed in an undesirable position, traction suture placement may be used. The eye should always be placed in a position opposite the undesirable fixation. A chronically esodeviated eye with restricted abduction should be fixed in abduction, a Brown syndrome should be fixed in adduction and sursumduction, and so on.

In Figure 5, the right eye is to be placed in forced abduction. Two scleral bites are taken near the nasal limbus with 4-0 silk sutures. The sutures are brought out through the upper tarsus and tied over a rubber or silicone peg with the eye in several degrees of abduction. The sutures are removed in 5 to 7 days. Because the eye is rotated, corneal contact by the suture is kept to a minimum. To place the eye in forced adduction, suture placement is reversed. To fix the eye in sursumduction, two scleral bites are

taken at the 6 o'clock limbus position and the 4-0 silk sutures are taken out through the upper tarsus and tied over a rubber or silicone peg. To fix the eye in deorsumduction, the two bites are taken at the 12 o'clock position with 4-0 silk sutures, and the sutures are brought out through the lower tarsus and tied over a rubber or silicone peg.

Some surgeons prefer to anchor traction sutures through the tendinous insertion of the rectus muscles. The attachment to the globe is more secure with this technique. The traction sutures are placed at the insertion of the superior and inferior rectus before fixing the eye in abduction or adduction. Traction sutures are placed at the insertion of the horizontal recti to fix the eye in sursumduction or deorsumduction. The right eye is fixed in abduction and the sutures are brought out through the temporal aspect of the upper lid, fixing the eye in the abducted position.

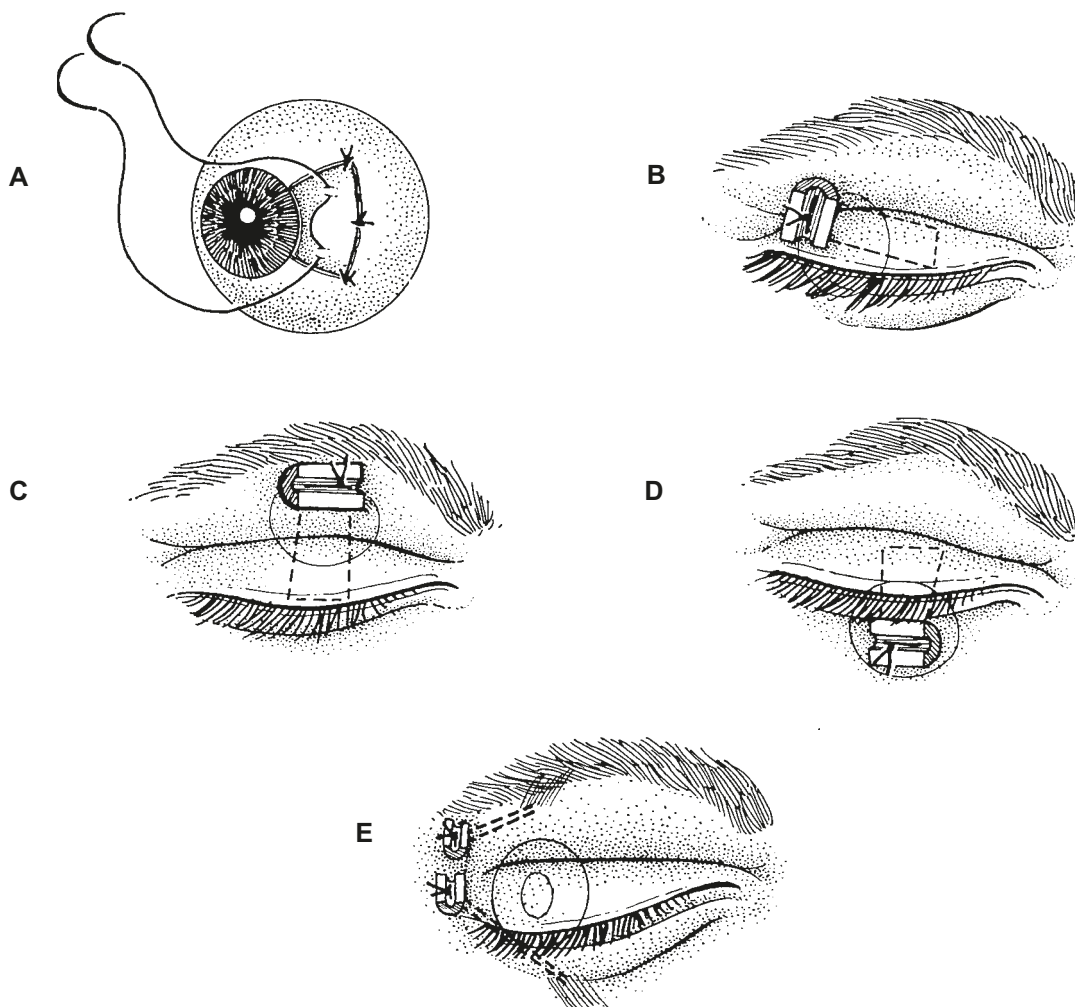


Figure 5

A A 4-0 black silk suture is secured to sclera.
B The eye anchored in adduction.
C The eye anchored in elevation.

D The eye anchored in depression.
E The eye anchored in elevation and adduction with two traction sutures placed in the insertion of the superior and inferior rectus.

13

Muscle transposition procedures

Overview

When an extraocular muscle is paralyzed it has lost the ability to contract. The usual 'strengthening' techniques such as resection, advancement, or tuck (actually 'shortening' procedures) do not restore the muscle's potential for normal ocular rotation. A new, more favorable, static position of the globe may be accomplished after a large recession-resection procedure, but movement in the field of action of the paralyzed muscle is not accomplished. To remedy this, Hummelsheim in 1907 devised a procedure to transfer part of the action of the superior and inferior rectus muscles to the field of action of the lateral rectus muscle in cases of sixth nerve palsy.

This procedure has undergone numerous modifications in the last century, but most retain the basic principle of the technique as introduced by Hummelsheim. The principle is that action of muscles that are normally antagonists are transferred to the field of action of the muscle lying between these antagonists. For example, the superior and inferior rectus muscles are transferred to a point adjacent to the lateral rectus muscle in sixth nerve palsy or to the medial rectus in case of medial rectus palsy. The horizontal recti are likewise shifted adjacent to the superior rectus in superior rectus palsy and to the inferior rectus when this muscle is paralyzed.

Muscle transposition may be indicated in any case where paralysis of a muscle is associated with an unacceptable deviation in the primary position and/or bothersome diplopia. This can occur in unilateral or bilateral sixth nerve palsy, double elevator palsy, inferior rectus palsy, with an irretrievable lost muscle, and other causes. It should be emphasized that in cases of extraocular muscle paralysis, especially those of longstanding, mechanical restriction can be present in the antagonist. When paralysis and mechanical restrictions limiting free movement coex-

ist, the mechanical restrictions must be eliminated before carrying out the extraocular muscle transfer. This release of mechanical restrictions can be done with surgery or to some extent by chemodenervation with Botox.

Extraocular muscle transfer achieves a change in the mechanics of a given muscle but innervation to this muscle remains the same as preoperatively, and the muscle continues to obey Hering's law. A successful extraocular muscle transfer procedure has most of its effect in changing alignment in the primary position with only a limited effect in the field of action of the paralyzed muscle. This movement may be due to a 'spring load' effect created by the transferred muscles and activated when the antagonist relaxes according to Sherrington's law during attempts to look in the field of action of the paralyzed muscle. Some patients with acquired sixth nerve palsy and also some with acquired vertical rectus palsy can achieve expanded areas of diplopia-free vision after muscle transfer, and others just look better in the primary position while retaining large areas of diplopia.

A review of muscle transposition procedures

In Hummelsheim's original transplant procedure, the lateral halves of the tendons of the superior and inferior rectus muscles are attached to the tendon of the lateral rectus (Figure 1A). In O'Connor's modification of the Hummelsheim procedure the entire tendons of the superior and inferior rectus muscles are sutured to the sclera adjacent to the insertion of the lateral rectus and a cinch is performed on the lateral rectus (Figure 1B). In a further modification of O'Connor's technique the nasal halves of the superior

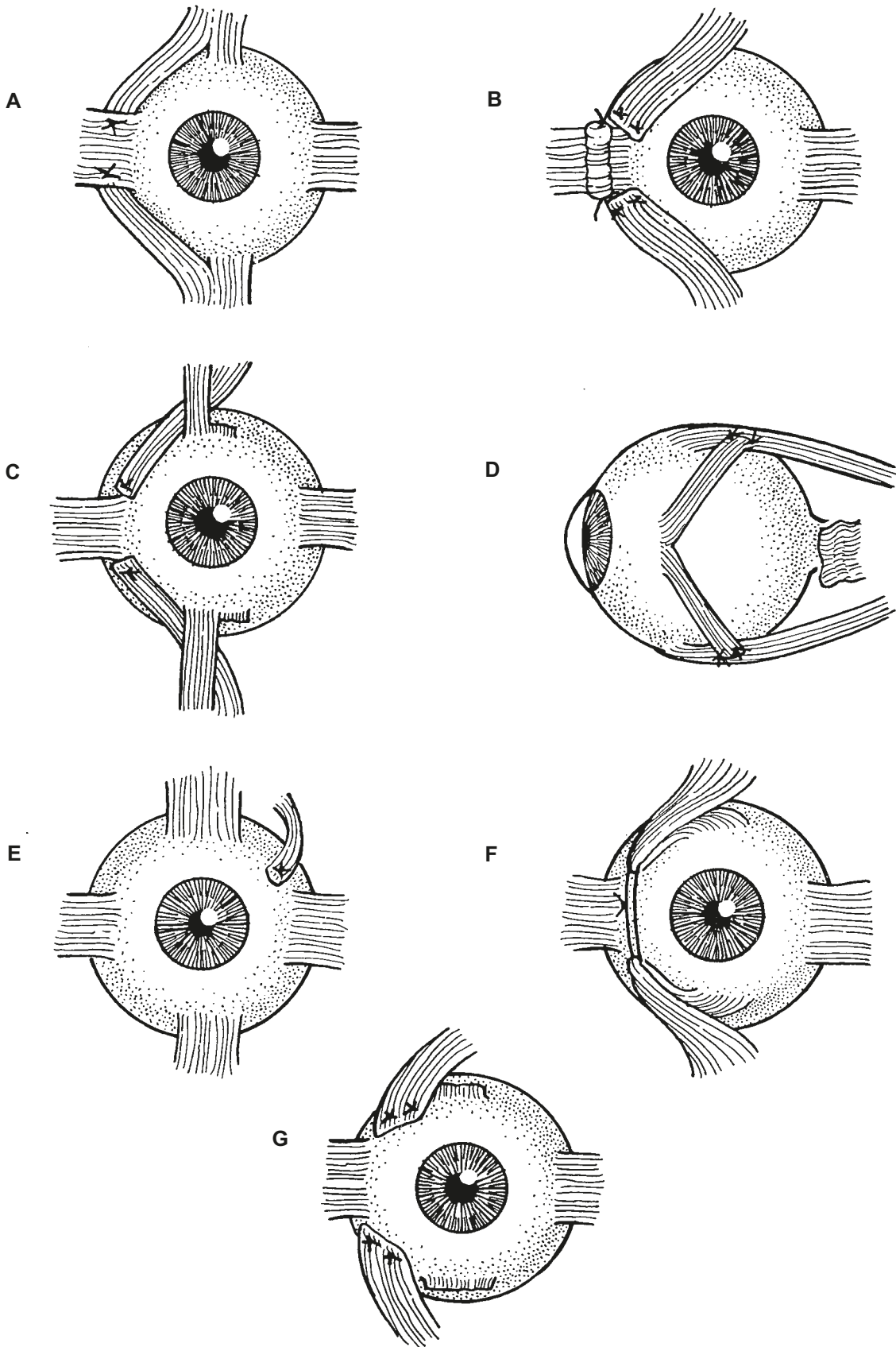


Figure 1 Muscle transposition procedures

- A Hummelsheim
- B O'Connor
- C Modified O'Connor
- D Wiener

- E Peter
- F Hildreth
- G Schillinger

continued.

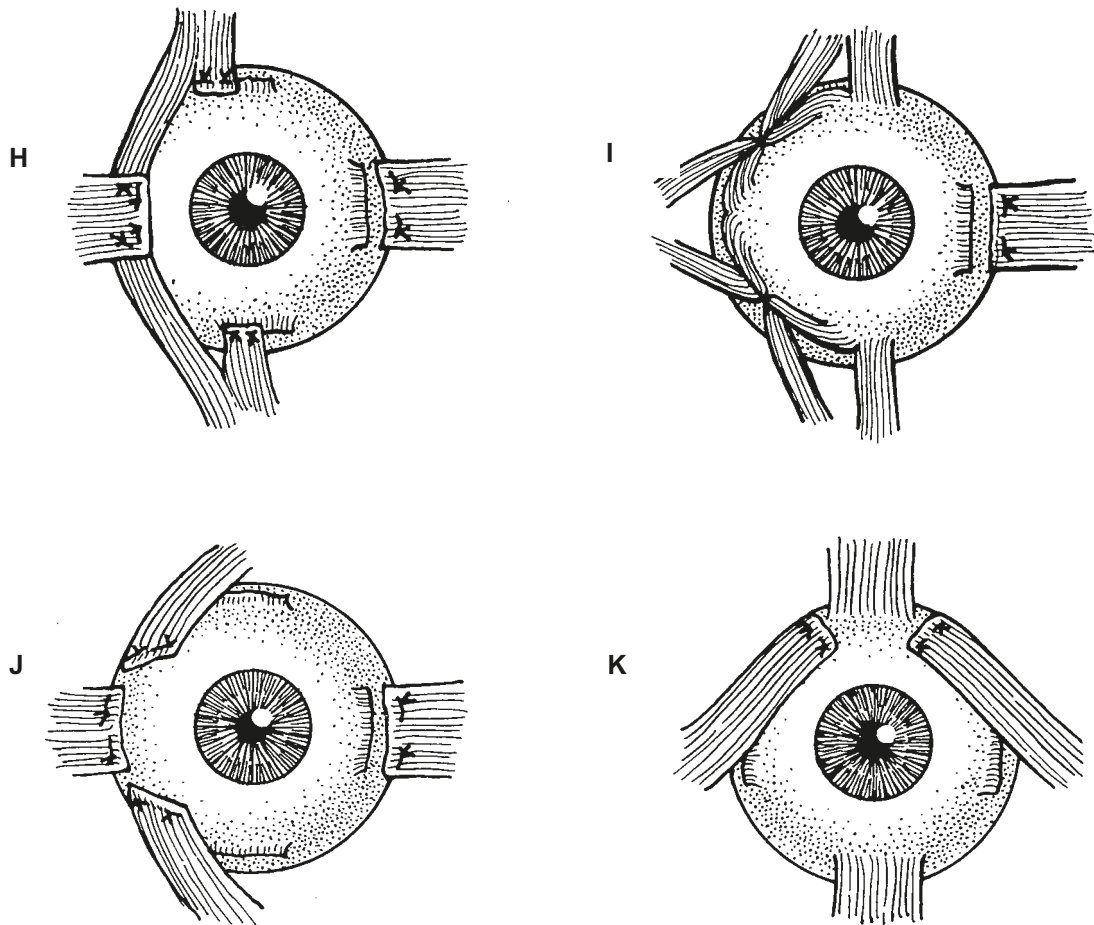


Figure 1, cont'd Muscle transposition procedures

H Beren-Girard

I Jensen

J Uribe

K Knapp

and inferior rectus tendons are passed beneath the temporal halves of the insertions and attached to the sclera adjacent to the lateral rectus tendon (Figure 1C). In Wiener's procedure the paralyzed lateral rectus is transected and the proximal tendon is split and joined to the adjacent superior and inferior rectus muscles (Figure 1D). In Peter's procedure for third nerve palsy, the trochlea is fractured and a shortened superior oblique tendon is sutured to the sclera near the insertion of the medial rectus (Figure 1E). In Hildreth's procedure the entire tendons of the superior and inferior rectus muscles are joined with nonabsorbable suture (Figure 1F).

In Schillinger's procedure the entire tendons of the superior and inferior rectus muscles are sutured to the sclera near the insertion of the lateral rectus (Figure 1G). In Beren's and Girard's technique the medial rectus is recessed, the lateral rectus resected, and both superior and inferior rectus muscles shifted one-half width temporally, with the temporal half of each muscle sutured to the resected lateral rectus

(Figure 1H). In Jensen's technique the superior rectus, inferior rectus, and lateral rectus muscles are split along their long axes. The lateral half of the superior rectus is joined to the superior half of the lateral rectus and the inferior half of the lateral rectus and the lateral half of the inferior rectus are joined in a similar fashion with nonabsorbable sutures. The medial rectus may or may not be recessed. This procedure performed on appropriate muscles also has been suggested for double elevator palsy, medial rectus palsy, and double depressor palsy (Figure 1I). In Uribe's technique the medial rectus is recessed, the lateral rectus resected, and the entire tendon of the superior and inferior rectus muscles sutured to the sclera adjacent to the resected lateral rectus insertion (Figure 1J). In Knapp's technique for double elevator palsy the entire tendon of the medial and lateral rectus muscle is shifted and sutured to the sclera adjacent to the insertion of the superior rectus. The inferior rectus may also be recessed. This full tendon transfer may be used for any of the rectus muscles (Figure 1K).

Rectus muscle transfer

Transfer of antagonist rectus muscles to a position near the insertion of the paralyzed rectus muscle lying between is the technique currently used for most extraocular muscle transposition. This can be carried out for any of the rectus muscles. It is done most frequently shifting the superior and inferior rectus muscles to the lateral rectus muscle for sixth nerve paralysis to offset, at least in part, absence of abduction. This type of transfer is also used for the superior, inferior and less often for the medial rectus muscle when function is lost because of paralysis or physical damage to the muscle.

The entire muscle or just one half of the muscle is shifted in this procedure. Full tendon transfer is more powerful, but it sacrifices both anterior ciliary arteries in the transferred muscle. Shifting only one half of the muscle spares one anterior ciliary artery in each of the transferred muscles if care is exercised. To add more power to the transfer, the border of the transferred muscle can be sutured to the paralyzed muscle as described by Foster or adjacent to it as described by Buckley. In addition, the antagonist can be weakened by recession at the time of surgery or by Botox a week or two before surgery or sometimes after.

This surgery is begun with a limbal incision that extends for 180 degrees (Figure 2). The muscles to be transferred are isolated on a muscle hook and the intermuscular membrane on both borders is freed from the muscle border fifteen or more millimeters from the insertion. Either the entire muscle is hooked and one or two sutures are placed 1 or 2 mm behind the insertion or the muscle is split making sure that the anterior ciliary artery in the half of the muscle remaining remains undisturbed. Suture(s) are then placed in the muscle half. The muscles are detached and reattached to sclera just touching the paralyzed muscle between with the transferred insertion placed concentric with the limbus.

The antagonist rectus may be recessed leaving only the remaining anterior ciliary vessel(s) in the paralyzed muscle if a full tendon transfer has been done, or at least three if a half tendon transfer has been performed. In selected cases the antagonist may be temporarily paralyzed at surgery by injecting up to 5 units of Botox.

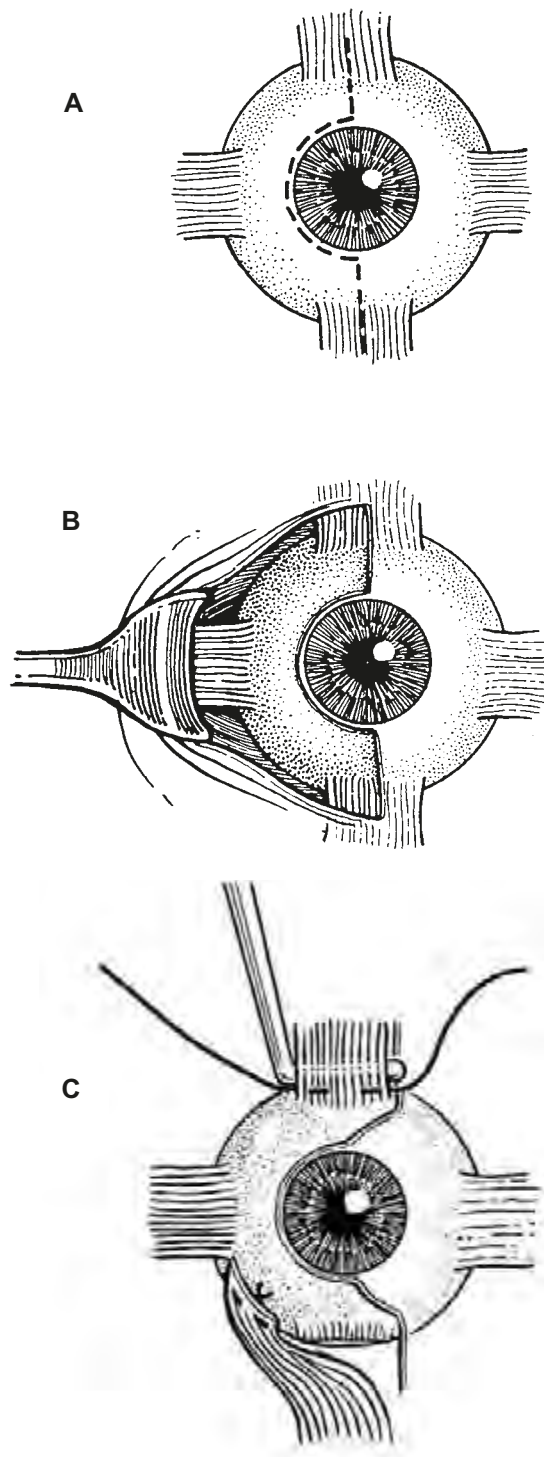


Figure 2

- A** A limbal incision is made for 180 degrees. This procedure is shown for transfer of the superior and inferior rectus to the lateral rectus, but it may be done for any of the rectus muscles.
- B** The three rectus muscles are exposed.
- C** For a full tendon transfer, one or two sutures are placed 1 or 2 mm behind the insertion of the muscle to be transferred using one double arm or two single arm sutures.

continued.

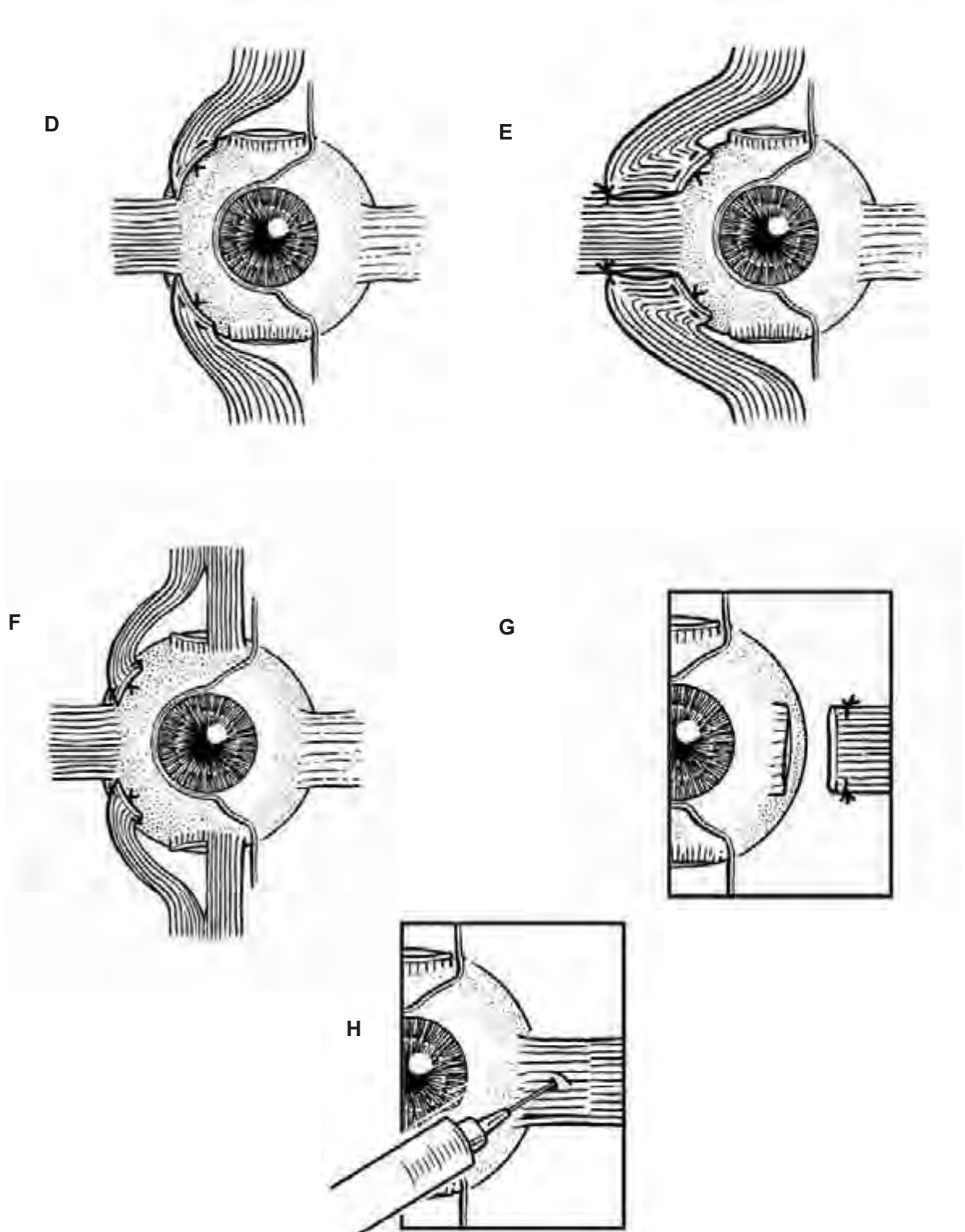


Figure 2, cont'd

- D** After detaching the muscles, they are reattached to sclera concentric with the limbus with one border of the muscle just touching the edge of the insertion of the paralyzed muscle.
- E** For a half muscle transfer, the muscle is split with a muscle hook and is separated backward for 15 mm. A suture is placed in the half of the muscle to be transferred, the muscle is detached and reattached just touching the edge of the insertion of the paralyzed muscle. Care should be exercised to spare the remaining ciliary artery.
- F** For a more powerful muscle transfer, the borders of the muscle can be joined with a non-absorbable suture 8 mm behind the insertion of the paralyzed muscle, or these transferred edges can be sutured to sclera adjacent to the paralyzed muscle. This can be done with a full or a half tendon transfer.
- G** The antagonist rectus may be recessed.
- H** Botox may be injected in the antagonist.

Scleral augmented muscle-tendon transfer

In cases of strabismus where a rectus muscle is missing because of trauma, previous surgery, or congenital absence, a traditional muscle transfer procedure cannot be performed. In cases such as this where the antagonist is tight, it must be recessed. This in turn rules out a full tendon transfer of the two remaining rectus muscles because of the chance of anterior segment ischemia after detachment of all the rectus muscles of a given eye. A Jensen procedure cannot be performed because the absence of a rectus muscle rules out rectus muscle union. With the advent of Botox the tight antagonist can be injected, but this neurotoxin treatment cannot be expected to release tightness associated with a chronic deviation caused by secondary structural changes in the muscle, in the conjunctiva, anterior Tenon's capsule, and intermuscular membrane (posterior Tenon's capsule), and it cannot change movement in the field of action of the missing muscle.

The scleral augmented muscle-tendon transfer avoids the condition that could cause anterior segment ischemia; that is, removal of all remaining rectus muscles with their anterior ciliary arteries - and at the same time allows completion of the equivalent of a Jensen procedure. The scleral augmented muscle-tendon transfer is accomplished by first recessing the tight antagonist and then suturing a 1.5 mm wide band of preserved sclera to host sclera approximately at the site of the normal insertion of the missing muscle. The long (approximately 100 mm) strip of sclera is threaded through the two adjacent rectus muscles that are divided along their long axes. The ends of the scleral strip are then drawn together, pulling the muscle slips toward the area of the missing muscle. When the eye is slightly past the midline, the scleral strip ends are joined with nonabsorbable 5-0 suture. We have used this procedure successfully in cases where a large horizontal strabismus was caused by a

missing medial or lateral rectus muscle. I have also threaded 5-0 nonabsorbable suture in the scleral strip for added strength.

A 54-year-old woman with a large left exotropia who had undergone two previous procedures for esotropia is shown (Figure 3). Both eyes had been operated on at each procedure. The last operation had been performed when the patient was 17 years old and resulted in this large exotropia. The left eye could not move even to the midline, passive ductions were severely restricted in the direction of adduction, and no generated muscle force was measured in attempted adduction. At surgery, no medial rectus was found. A 1.5 x 100 mm strip of glycerin preserved human sclera was prepared. The middle of the scleral strip was sutured at the point where the medial rectus muscle would have inserted. One end of the scleral strip was passed beneath the medial half of the superior rectus that had been split along its long axis (Figure 4). The inferior rectus muscle was also split along its long axis and the other end of the scleral strip was placed around the medial half of the inferior rectus. One anterior ciliary artery was left undisturbed in both the superior and inferior rectus muscle. The tight lateral rectus was then recessed. After this, the scleral strips were drawn toward each other, pulling the split halves of the rectus muscles toward the area on the globe usually occupied by the insertion of the missing muscle. The scleral strip ends were sutured together with 5-0 nonabsorbable suture with the eye in a slightly overcorrected position. The thin scleral strip may be passed beneath the split muscle or over the outer surface of the split muscle, as shown here, without altering the outcome of the procedure. A satisfactory primary position alignment after scleral augmented extraocular muscle transfer was accomplished. Adduction was achieved but the eye could move only a few degrees (Figure 5).




Figure 3

A large exotropia in a patient who at surgery was found to have no left medial rectus.

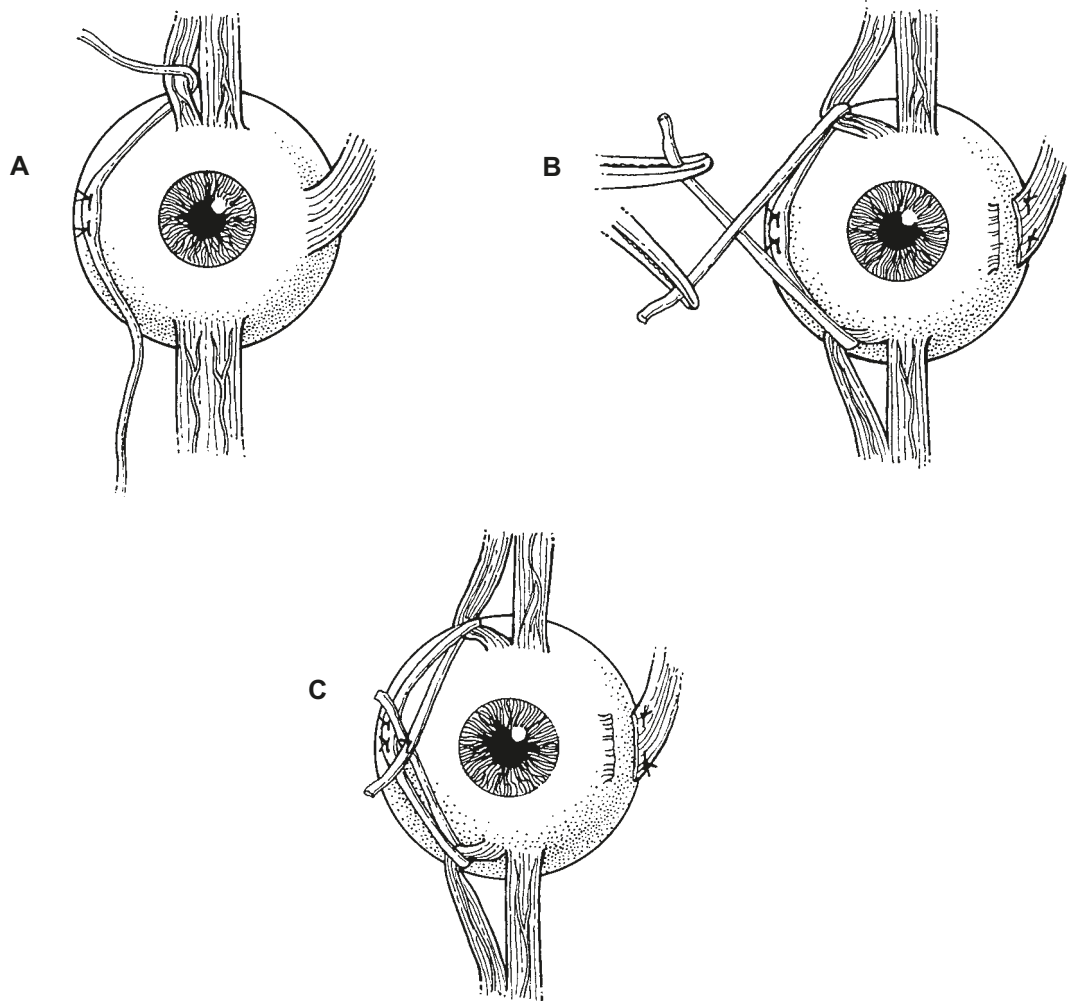


Figure 4

A The scleral strip is sutured 5.5 mm from the limbus, the vertical rectus is split, and the scleral strip is passed through the split muscle.

B The scleral strip pulls the vertical recti toward the empty medial rectus insertion site. The antagonist is recessed.

C The ends of the scleral strip are joined with non-absorbable sutures.



Figure 5

Postoperative alignment is good.

Knapp procedure

The Knapp procedure remains a popular technique for muscle transposition. It is useful for treating double elevator palsy especially when there is no mechanical restriction to elevation. This technique employs upward shift of the medial and lateral rectus muscles to a point adjacent to the corners of the insertion of the superior rectus muscle. It differs from other transpositions of the full tendon in that the line of insertion of the transposed muscles is more or less parallel to the borders of the superior rectus. This is in contrast to those full tendon transfer procedures that have the new insertion of the transferred muscles concentric with the limbus. This may make a difference in the pull of the transposed muscle, especially if the concentric insertion transfer is reinforced with a suture joining the transposed muscle to the paralyzed muscle 8 mm posterior to the insertion.

The procedure starts with a large limbal incision or equivalent (Figure 6). The medial and lateral rectus muscles are secured with two single arm or one double arm suture, are detached and reattached at the corner of the superior rectus insertion. Subtle differences in the alignment of the insertions of the transferred muscles can be employed to modify both the horizontal and the vertical pull. In theory the higher the placement of the new insertions, the more the upward pull on the eye. In addition, location of the placement of the new insertions, especially that of the lateral rectus muscle can affect the horizontal alignment. I produced a large transient exodeviation in one patient after doing this procedure for double elevator palsy. The conjunctiva is closed in the usual manner.

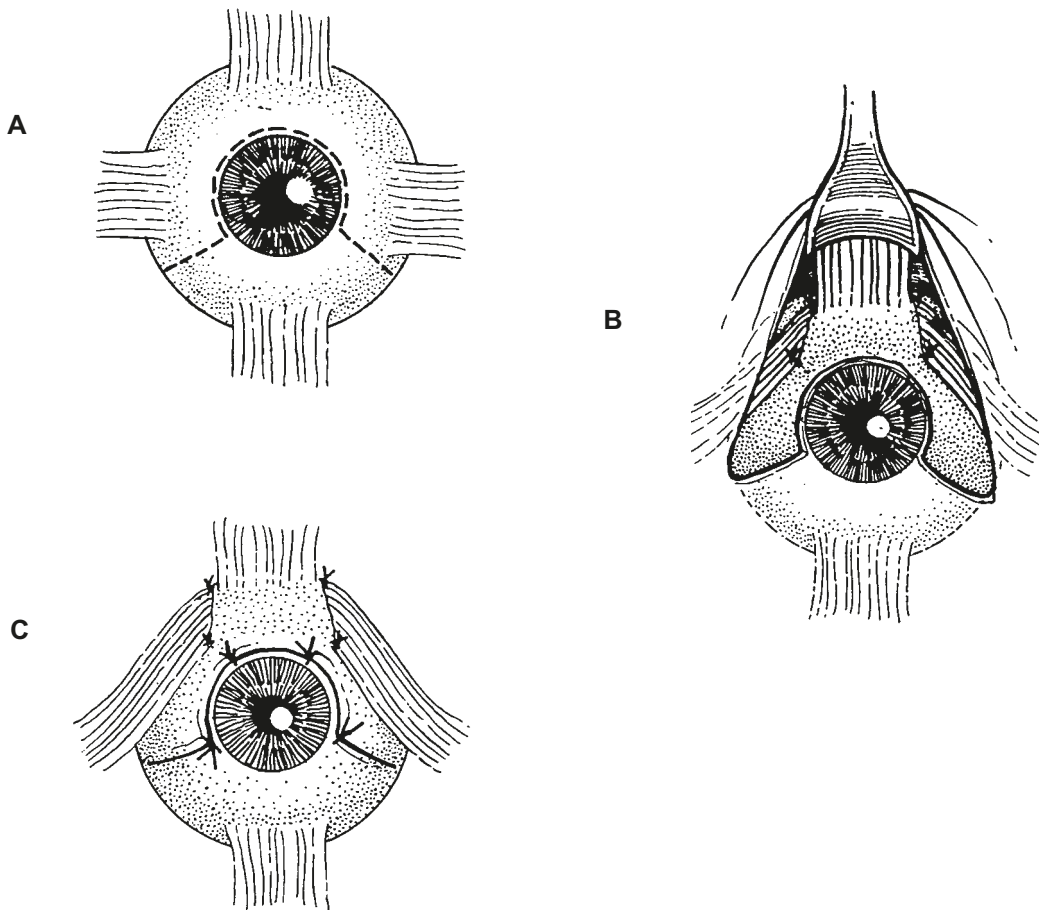


Figure 6

A A large limbal incision (or equivalent) is made.
B After placing one or two sutures in the medial and lateral rectus muscles, these muscles are detached and reattached adjacent to the border of the superior rectus muscle.

C The incision is closed with 8-0 absorbable suture.

Superior oblique tendon transfer

Superior oblique tendon transfer can be a useful procedure in cases of complete third nerve palsy. Theoretically the transferred muscle should act more like a tether holding the eye in adduction than as a functioning rotator. Nevertheless, the improvement in alignment that results from this procedure resulting in improvement in the patient's appearance has kept superior oblique tendon transfer in the strabismus surgeon's armamentarium. In the past I have attempted to fracture the trochlea in order to bring the superior oblique tendon forward from the apex of the orbit producing a more physiologic pull for adduction. However, this resulted too often in either inability to fracture a tough trochlea, cutting the superior oblique tendon near the trochlea or both! I now recommend transfer of the superior oblique tendon without attempting to fracture the trochlea. While this is not a perfect procedure, nothing that I know of can be expected to yield a perfect result in cases of third nerve palsy.

The procedure begins with a large limbal incision exposing the adjacent corners of the medial and superior rectus muscles (Figure 7). The superior oblique tendon is seen nasal to the superior rectus muscle as it passes in Tenon's capsule toward its insertion. The tendon is engaged on a small hook and is 'shelled out' of Tenon's as described in chapter 9. The tendon is pulled forward and is cut as near the insertion as possible in order to have sufficient tendon length. A small clamp should be placed on the superior oblique tendon before the tendon is transected. The tendon is then pulled to meet the upper corner of the medial rectus while the eye is rotated medially. A suture, preferably, 5-0 non-absorbable, is placed in sclera and is brought through the tendon securely attaching the tendon to sclera with the eye in slight adduction.

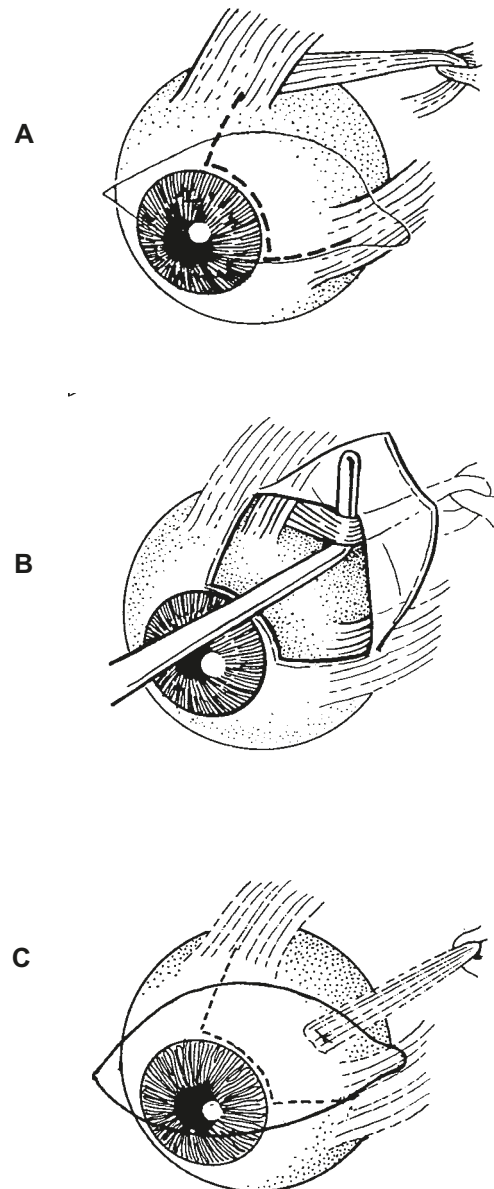


Figure 7

- A** The location of the limbal incision.
- B** The superior oblique tendon engaged on a muscle hook. At this time a small clamp is placed on the superior oblique tendon and it is cut as close to the insertion as possible.
- C** The tendon is sutured to sclera at the upper border of the medial rectus muscle.

Transposition for head tilt without oblique muscle dysfunction

An uncommon but challenging clinical problem is posed by the patient who assumes a head tilt to achieve his/her null point of nystagmus and thereby realize better vision. Other patients, still rarer, assume a head tilt to gain more comfortable vision who have neither nystagmus nor oblique muscle dysfunction. In cases like these, the principal espoused by Kestenbaum in the United States and Anderson in Australia is invoked. That is, the eyes are shifted in the direction of the head tilt. In the original description of surgery for null point nystagmus, Anderson recessed yoke horizontal recti, and Kestenbaum performed *recession and resection* on each eye to accomplish the same. For example; if the null point of a patient's nystagmus occurred with right face turn and eyes left, Anderson's procedure would recess the left

lateral and right medial rectus. In Kestenbaum's procedure, to this would be added resection of the left medial rectus and resection of the right lateral rectus. Of these two procedures, I prefer the Anderson procedure or perform a recession of all four horizontal recti (see page 446).

von Noorden recommends what he calls a 'torsional Kestenbaum' to treat this head tilt without oblique muscle dysfunction. With this procedure, the eyes are rotated in the direction of the head tilt and just as in Anderson's and Kestenbaum's procedures, the eyes are moved in the direction of the face turn by shifting the insertion of the vertical rectus muscles according to the scheme shown in Figure 8 (also see page 194).

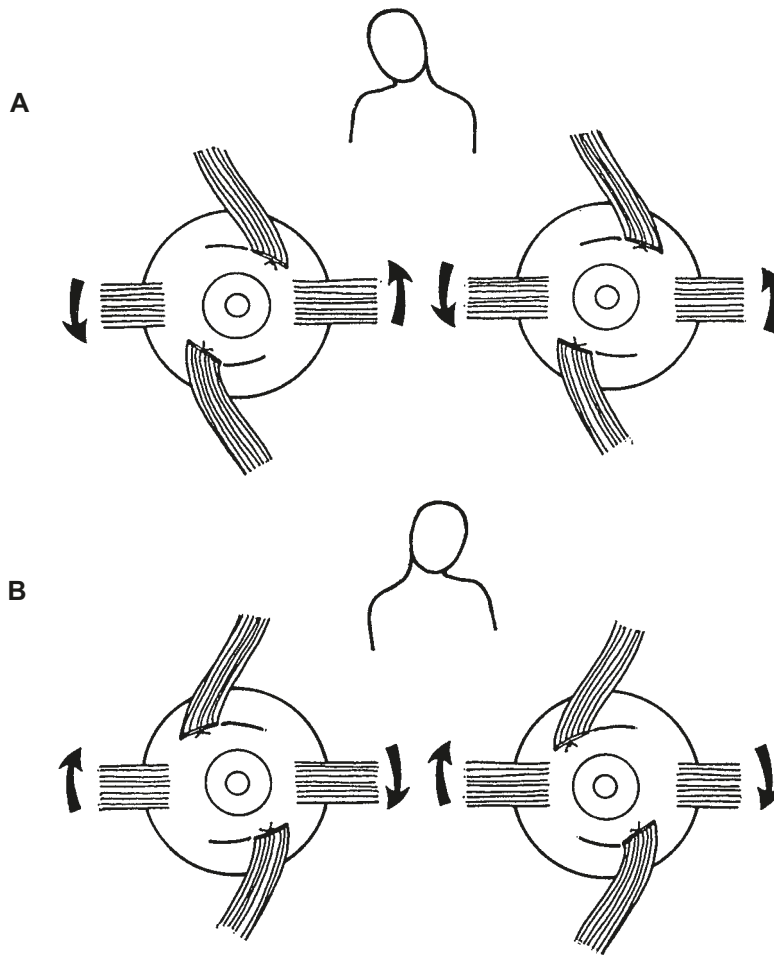


Figure 8

A For treatment of a chronic right head tilt without oblique muscle dysfunction, in the right eye, the superior rectus is shifted one muscle width nasally and the inferior rectus is shifted one muscle width temporally. In the left eye, the superior rectus is shifted one muscle width temporally and the inferior rectus is shifted one muscle width nasally.

B For treatment of chronic left head tilt without oblique muscle dysfunction, in the right eye, the superior rectus is shifted one muscle width temporally and the inferior rectus is shifted one muscle width nasally. In the left eye, the superior rectus is shifted one muscle width nasally and the inferior rectus is shifted one muscle width temporally.

Botox (Botulinum A toxin)

Overview

Extraocular muscle action must be altered in some way in order to change alignment of the eyes when treating strabismus. This is done by surgery usually in the form of recession, resection, transfer, myotomy and tenotomy. Ocular alignment may also be influenced by optical correction with plus lenses to reduce an esodeviation in refractive esotropia and high AC/A and also minus lenses in excess of the patient's refractive error to reduce an exodeviation. Cholinesterase inhibitors used topically can increase the efficiency of accommodation and thereby reduce accommodative convergence and the associated esodeviation.

Another way of weakening the effect of an extraocular muscle is the injection of a selected drug into the muscle itself. This had been tried in the past using agents such as alcohol or local anesthetics which were either too 'successful' causing irreversible muscle paralysis or transient. Then in 1972 Alan Scott began injecting extraocular muscles in the laboratory in search of a clinically effective agent. He tried several including Cobra toxin, finally settling on botulinum toxin (type A). Human studies began in 1977. The drug was first released for investigational use and was finally placed on the market in 1989 for the treatment of blepharospasm and strabismus in patients over 12 years. The sales and distribution of botulinum A toxin was taken over later by Allergan Pharmaceutical and is now marketed for a wide variety of uses under the name Botox®.

The drug

Clostridium botulinum is a large, aerobic, gram positive, rod shaped organism. Of the eight immunologically distinguishable exotoxins three types (A, B, and E) are commonly associated with human toxicity. Paralysis of a muscle by botulinum is caused by the inhibition of the release of acetylcholine (ACh). In the case of accidental intoxication, death is caused by

a general neural 'shut down.' The therapeutic paralytic effect of botulinum toxin on extraocular muscle function is dose related with minuscule doses producing maximum effect in 5 to 7 days after injection of the drug. Although 6 to 9 months may be required to recover completely from the effects of the toxin, the useful effect may be much shorter for a variety of reasons including toxin integrity, administration technique, and severity of disease. The effect of the toxin can be reduced by the early injection (within thirty minutes) of antitoxin. However, I do not know of clinical facilities having this drug on hand. Repeated injections of botulinum toxin tend not to be recognized by the human immune system, but antibodies have been found in some patients. I have personally injected more than 1,000 cumulative units of Botox into several blepharospasm patients over the course of several years with no apparent adverse side effect. The local effect of the toxin can be prevented by prior toxoid immunization.

The large botulinum molecule is fragile and is susceptible to damage from shaking and frothing; therefore, it should be reconstituted, drawn up, and injected gently. Botox is supplied in vials that contain 100 units of freeze-dried toxin. Each unit contains about 0.25 ng (billionths of a gram) of toxin. The toxin is stored in a freezer until used.

The freeze-dried drug is reconstituted with non-preserved normal saline. Four ml of 0.9% NaCl are injected into the bottle with the toxin. When reconstituted according to specific dilution instructions present on each vial, the concentration is 25 U/ml (or 2.5 U/0.1ml). The reconstituted Botox should be used within a few hours of mixing to retain its maximum therapeutic effect. The human LD/50 for Botox is approximately the full contents of 20 vials, making this drug potentially less dangerous than aspirin!

Indications for Botox

The following indications for the use of botulinum toxin are modified from a summary by Osako and Keltner:

1. Strabismus
 - Horizontal nonparalytic strabismus less than 40 PD
 - Surgical undercorrection and overcorrection
 - Sensory deviation
 - Preoperative evaluation for diplopia
 - Vertical, nonparalytic, nonrestrictive strabismus
 - Acute and chronic third and sixth nerve palsy
 - Thyroid ophthalmopathy
 - Strabismus after retinal detachment repair
 - Incisional surgery contraindicated or refused
2. Acquired nystagmus
3. Essential blepharospasm
4. Hemifacial spasm
5. Aberrant regeneration of the seventh nerve
6. Myokymia
7. Corneal exposure producing pathology

The following complications of Botox treatment also taken from Osako and Keltner include:

1. Ptosis
2. Induced deviations (overcorrection, new deviation)
3. Undercorrection
4. Diplopia
5. Pupillary dilatation
6. Reduced accommodation
7. Hemorrhage (subconjunctival, Retrobulbar)
8. Scleral perforation
9. Corneal exposure
10. Upper lip droop

Since this list was compiled, several new uses for Botox have been described. These include treatment for dysphonia, for relief of long muscle spasm from a variety of conditions, and even in the treatment of hemorrhoids! Probably the most novel new use of Botox has been for cosmetic purposes. The injection of small doses of the drug has achieved wide spread use for reducing facial wrinkles. This activity is heralded in aggressive advertising. So-called 'Botox parties' are held where groups assemble to receive the treatment in a more-or-less social atmosphere. The media has referred to Botox as the most rapidly growing 'medical' treatment in the United States.

Use of Botox in treatment of strabismus

Botox for the treatment of strabismus is widely accepted by strabismologists. However, there also appears to be a wide range of level of usage with some using it sparingly and other using it in nearly every case that has any indication. I personally believe that this drug has an important but limited role to play. Some others use it in a similar manner while a few use Botox for a wide variety of strabismus. My recommendation for use of Botox include: 1) injection of the medial rectus in acute sixth nerve palsy, 2) injection of the sound antagonist in cases of extraocular muscle transfer when recession of the antagonist would present a risk for anterior segment ischemia, 3) injection of a horizontal rectus in case of small angle strabismus where incisional surgery was declined or considered not the best alternative, 4) injection of tight muscles in cases of thyroid ophthalmopathy, and 5) other indications that could arise on a case by case basis.

Campos reports injecting both medial rectus muscles with 3 units of Botox for the treatment of 'infantile esotropia' in infants 5 to 8 months of age. He does this after general anesthesia and using minimal incisional surgery to expose the muscle allowing injection under direct vision. He reported "stable correction of the strabismus" in 53 of 60 patients with an average follow up of 10 years. Stereopsis tested with the TNO test was not present in any case. These results were achieved according to Campos after only one injection. Other optimistic reports of the treatment of congenital esotropia with Botox are from McNeer and Magoon.

It could be argued that if anesthesia were required to expose the muscle for injection, the muscles could be recessed in the traditional way with just a few more minutes of surgery. If results were equal, in my mind there would be little to choose between the two methods. However, the question remains, is it better for the long run to leave the medial rectus insertion in its physiologic state as with Botox? This question at the present is not answered. We do know that bimedial rectus recession can achieve gross stereo acuity in some cases but this takes, on average, two surgeries before a stable alignment is achieved. In my mind, the 'jury is still out' in the case of Botox for the treatment of congenital esotropia.

Retrobulbar Botox for treatment of nystagmus

I have treated several patients who suffered from disabling nystagmus with retrobulbar Botox injection. These patients sustained a brain stem stroke leaving them with long track paralysis, but also with nystagmus. The typical patient is confined to a wheelchair, or at least has limited mobility, and suffers the additional handicap of oscillopsia from the nystagmus. These patients are able to obtain most of their pleasure from reading and watching television, both of which are ruled nearly impossible because of the moving images.

Initially I attempted injecting the four horizontal muscles with small doses of Botox, but without success. I next injected 25 units of Botox into the retrobulbar space in the identical manner of a routine retrobulbar injection of anesthetic agent. In a matter of days the nystagmus quieted completely and visual acuity improved from less than 20/200 to 20/30 and the patient was happy. Since we injected only one orbit and the other eye continued to experience nystagmus, this eye had to be covered for this patient to enjoy good vision. The second patient we treated this way was blind in the other eye because of corneal scarring from exposure secondary to a seventh nerve palsy incurred at the time of the stroke. She had been diagnosed with Foville syndrome. This patient received more than twenty retrobulbar injection over the course of nearly ten years always obtaining good results for from three to six months. Four other nystagmus patients received similar treatment by me. These cases ranged from patients with multiple sclerosis (one successful and the other not) to a young man with nystagmus from poor vision from retinopathy of prematurity (not successful).

Retrobulbar injection of Botox is extremely useful for a very small, select group of patients. Several things that I have learned regarding this treatment are:

1. The injection is given exactly as you would a retrobulbar injection of anesthetic agent.
2. The patient should be made to sit up immediately after the injection to avoid post injection ptosis (when this was done none of our injections produced ptosis)
3. Be sure that the patient realizes that if the other eye can 'compete' it must be covered for the patient to achieve comfortable vision
4. The pupil after injection remains mid dilated and accommodation is reduced (since most patients suitable for this treatment are presbyopic this is not a significant point)
5. The effect of the injection lasts for three to a maximum of six months and must be repeated
6. There seems to be no ill effect from repeated injections, up to at least 20 in my experience.
7. Retrobulbar hemorrhage that I produced on one occasion resolved without ill effect for the patient. The injection, however, had no beneficial effect.

I injected the superior oblique muscle in one patient on two occasions to treat superior oblique myokymia. In each case the injection was done with general anesthesia and as would be expected, complete ptosis resulted. The first time the myokymia was unchanged, after the second injection it was gone. The question remains. Was it the result of the injection or just time?

Botox for treatment of benign essential blepharospasm

The most common use for Botox in our clinic is for the temporary relief of benign essential blepharospasm. These patients are usually in the seventh decade and beyond although we have treated patients who were in their 40's. A total of up to 50 units of Botox (and occasionally more) is injected into the subcutaneous space at strategically located areas around the face including the specific areas of muscle spasm. This treatment is repeated as necessary. That usually means that patients return on a regular basis averaging two to six month intervals. Two areas of injection to avoid when treating blepharospasm are the area below the nasolabial fold (injection here causes lip droop leading to biting the lip), and the mid upper lid area near the innervation of the levator palpebri (injection here causes ptosis).

Technique of injection

Based on clinical experience dating to the beginning of the clinical trials in the early 1980's, about 3% of the strabismus patients treated in our clinic receive Botox. This is in contrast to a strabismologist like John Lee of Moorfields Eye Hospital who uses Botox frequently and expertly for a wide variety of cases. Of the strabismus patients treated by us, about two-thirds of the patients are treated by injection of the sound antagonist of a paretic muscle. This is done in the acute stage to prevent contracture and in chronic paralysis before during or after surgery. Reasons for injecting the antagonist after surgery are to avoid the possible spread of toxin that can occur at the time of surgery, and to assess the results of surgery and therefore adjust the dose of Botox.

To begin the injection process, Botox is removed from the freezer and unpreserved NaCL 0.9% is drawn into a 10 ml syringe (Figure 1). Four ml are injected into the bottle that contains 100 units of freeze-dried toxin. This creates a solution with a strength of 2.5 units per 0.1 ml. The bottle should not

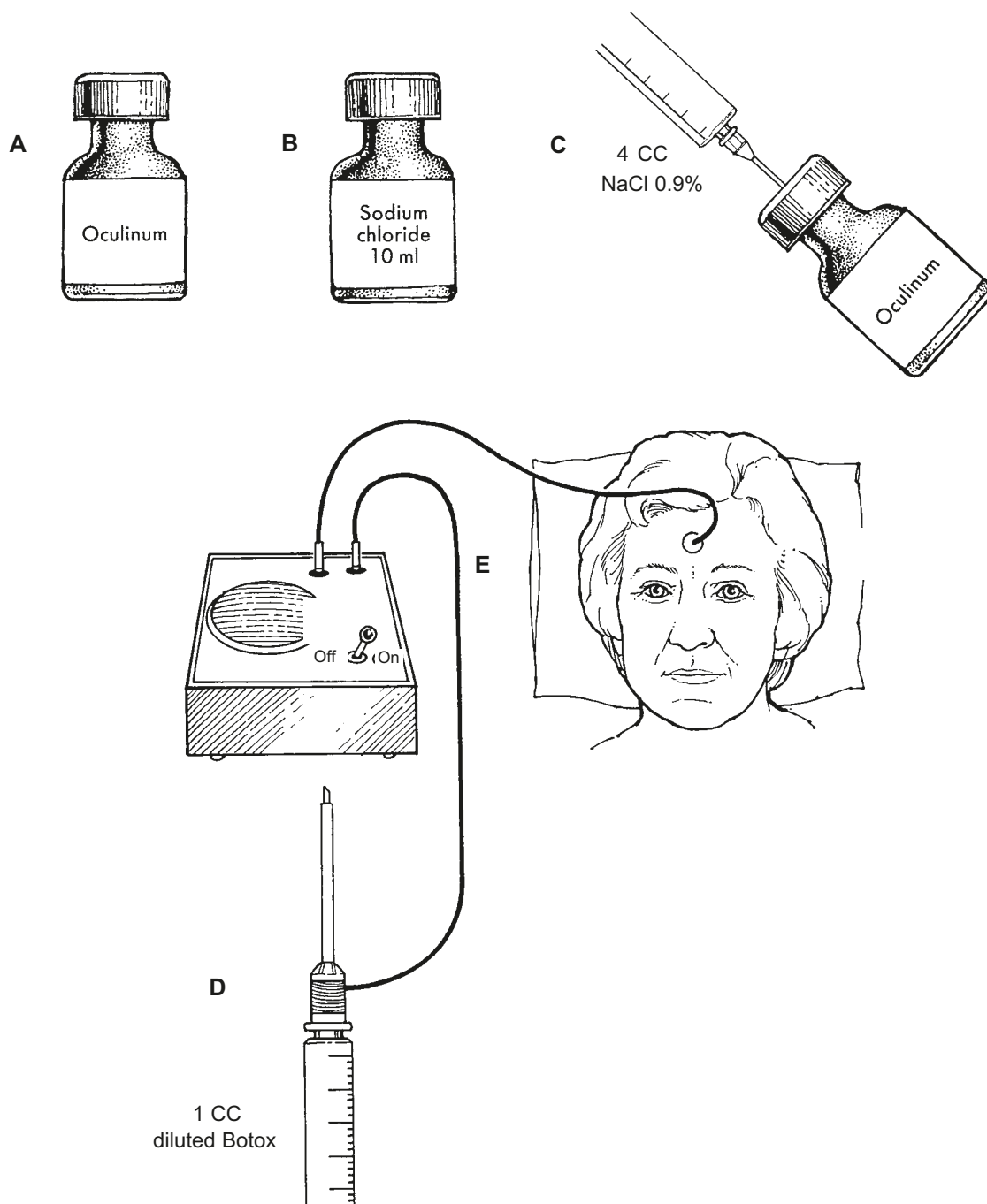


Figure 1

- A** The vial of Botox contains 100 units of freeze dried toxin.
- B** NaCl 0.9% without preservative is used for dilution.
- C** Four ml of the NaCl 0.9% is drawn up in a small syringe using a 27-gauge disposable needle and is then injected slowly into the bottle of freeze dried toxin. The bottle is not shaken and the liquid is not frothed.

- D** The appropriate amount of toxin is drawn up into a tuberculin syringe with another 27-gauge needle which is then exchanged for a 2 inch Teflon-guarded 27-gauge needle.
- E** The needle hub is connected to a lead from the EMG recorder and the second lead is attached to the patient's forehead. (If injection is done for blepharospasms there is no need for EMG control and a regular 27-gauge disposable needle may be used).

be shaken or frothed because this will destroy the delicate botulinum molecules.

To prepare for injection the appropriate amount of Botox is drawn into a tuberculin syringe using a disposable 27-gauge needle which is discarded. The vial of Botox is intended for single use. If more than one patient is treated with the contents of a single vial, all of the Botox should be withdrawn in separate syringes consecutively and used within approximately 30 minutes. Unused prepared Botox has been stored in a freezer for future use with anecdotal reports that the toxin retains its strength.

Before injection into the muscle, a 27-gauge needle, Teflon-sheathed and 2 inches long, is placed on the syringe. The hub of the needle is then connected to a portable electro-myography (EMG) recorder. The other lead of the battery operated EMG recorder is attached to the patient's forehead in an area that has been wiped with an alcohol sponge. At this point it is necessary to turn off any fluorescent light that might interfere with the EMG signal.

The 27-gauge, Teflon-guarded needle is then thrust carefully through the previously anesthetized conjunctiva at a point just posterior to the muscle's insertion. A fine-toothed forceps may be used at this time to stabilize the eye (Figure 2). During the advance of the needle the patient is asked to look

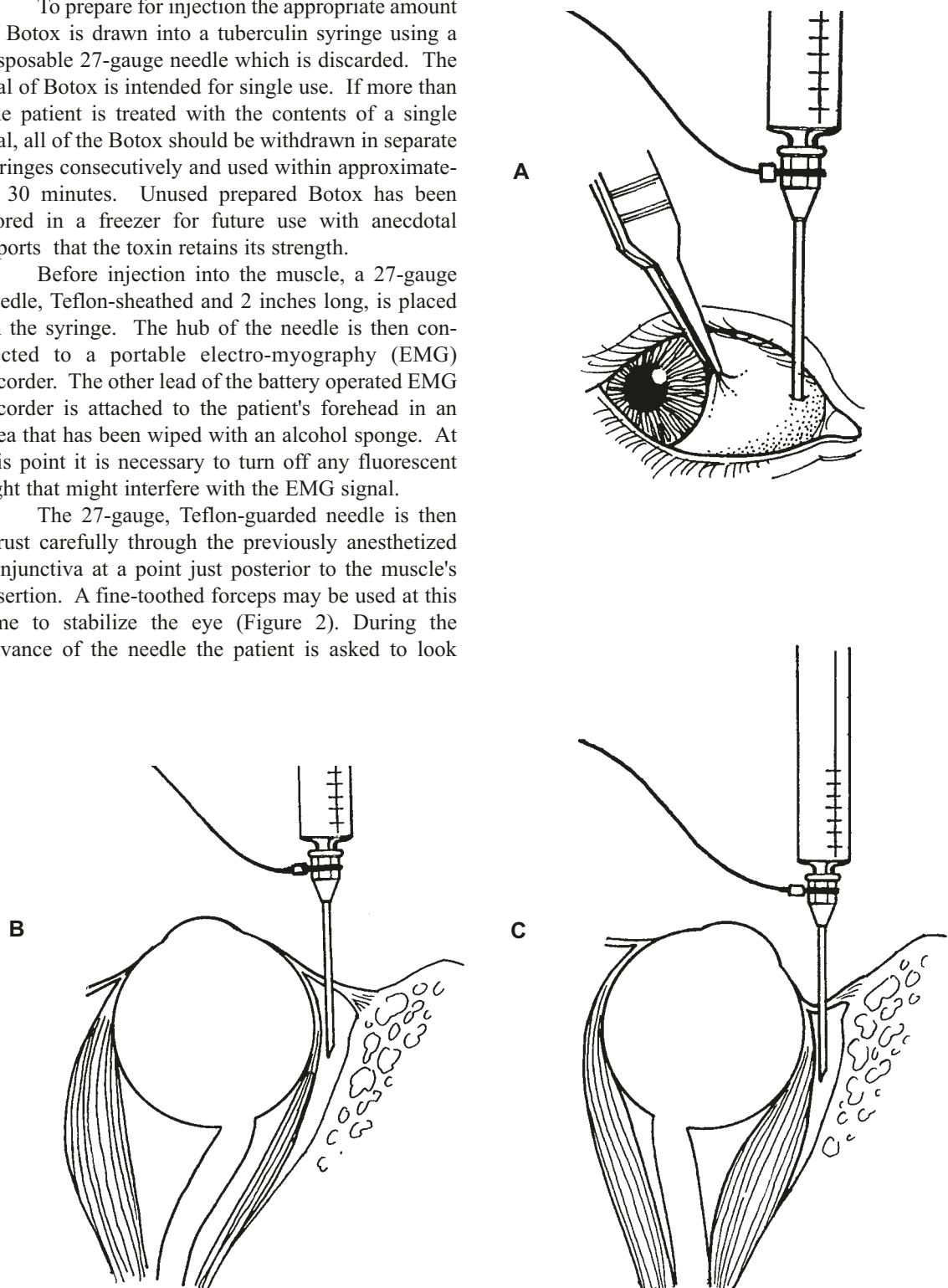


Figure 2

A With the eye stabilized with fine-toothed forceps and the patient looking away from the muscle to be injected. The Teflon-guarded needle is thrust through conjunctiva just behind the level of the muscle's insertion.

B The patient continues to look away from the muscle to be injected while the needle is advanced about one inch.
C With the needle advanced to this point the patient is asked to move the eye slowly in the direction of the muscle to be injected while the surgeon listens for the 'crackling' indicating neural activity.

continued.

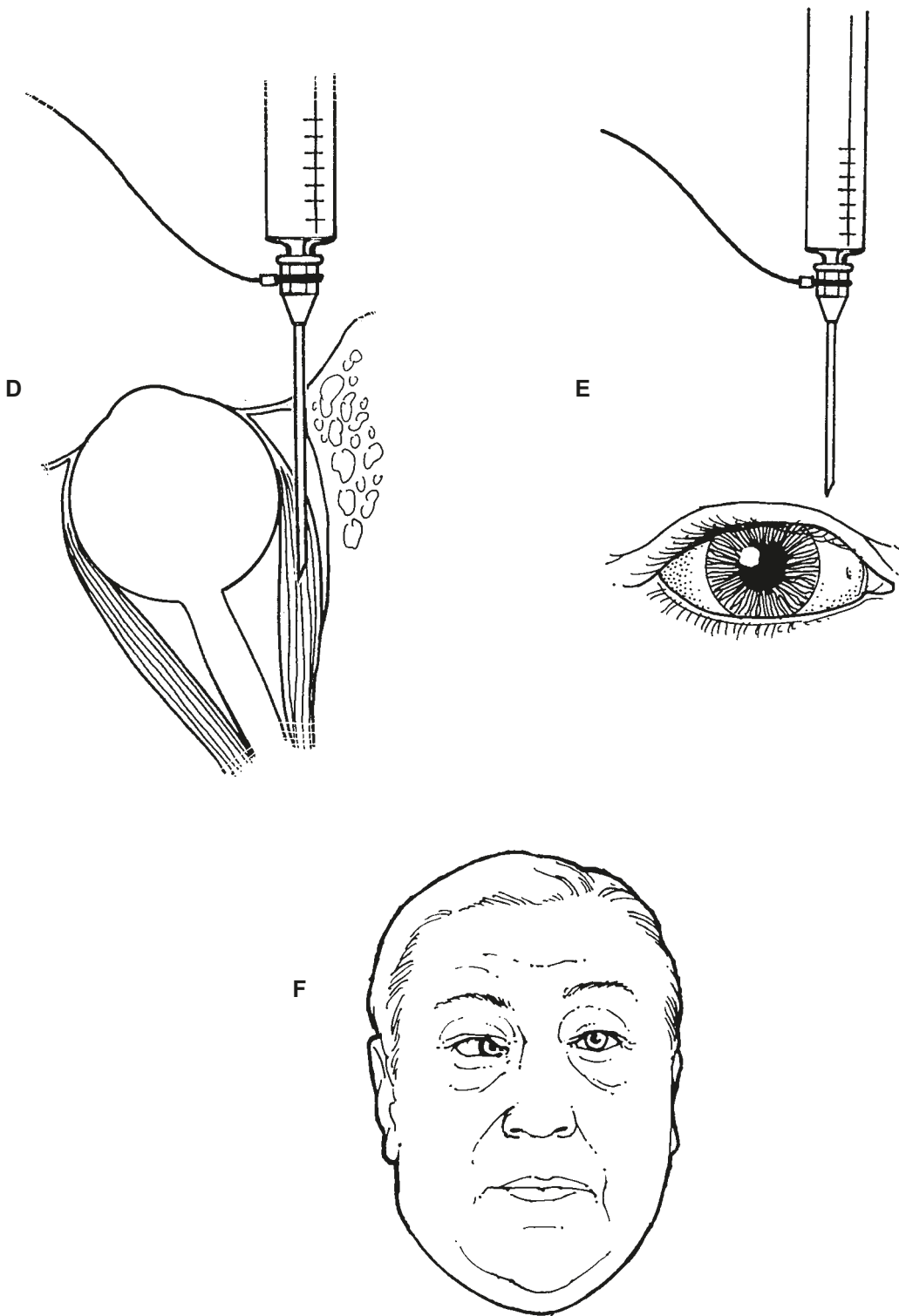


Figure 2, cont'd

D The patient is then asked to look slowly away from the muscle to be injected while the surgeon advances the needle tip carefully into the muscle and injects the toxin.

E Immediately after this, the needle is removed.

F A patient with right sixth nerve palsy would look like this before injection of the right medial rectus.

away from the muscle being injected. After the needle has entered the sub-conjunctival space the EMG recorder is turned on. The needle is advanced slowly and steadily with the bevel facing away from the scleral surface. The surgeon during this maneuver listens carefully for the 'crackling' sound indicating nerve activity. When the needle has been advanced approximately one inch or when the surgeon first hears the 'crackling' sound, the patient is asked to look slowly in the field of action of the muscle being injected. A sharp increase in the audible electrical activity indicates that the bare metal tip of the needle is adjacent to the muscle's motor end plate. It takes a 'practiced ear' to differentiate 'noise' from the muscle's neural activity. At this point, the patient can be asked to look away from the muscle to be injected. A very short advance of the needle will result in the needle entering muscle substance at which time the toxin is injected. This can mean an injection from as little as 1 unit to a dose of as much as 5 units. I have not exceeded this upper limit. The level of neural activity 'crackling' diminishes dramatically upon injection. I am not sure whether this is from the mechanics of injection or from the cessation of neural activity. Since the muscle continues to act normally for hours to days after injection I suspect it is the former. The patient ordinarily has no discomfort after injection, but a small subconjunctival hemorrhage may occur.

Before injecting a strabismus patient with Botox, the patient (or parents) should understand that the benefits of this treatment depend on an early over-correction that could be alarming if forewarning had not been provided. Patients should also be warned that unintended toxin spread could cause other strabismus and even ptosis on a temporary basis. Also, the beneficial results of Botox treatment for strabismus may be only temporary. A woman I treated successfully with Botox for small angle strabismus, went to the bus station and in a photo kiosk took pictures of her alignment on a weekly basis recording the return of the original angle of strabismus over a period of a few months and sending them to me!

Botox for the treatment of blepharospasm

The most common use of Botox in our clinic has been for treatment of benign essential blepharospasm and other annoying, even disabling facial spasms and ticks. Between 80 and 100 patients seen on a regular basis receive a total of more than 300 Botox injections each year. Satisfactory results are obtained in nearly every case allowing the patient to engage in normal life activities without the embarrassing spastic movement of their facial muscles. The beneficial effect of Botox injection lasts on average 3 to 6 months. Patients have received repeat injection up to 30 or more times without apparent adverse effect.

Because blepharospasm and facial myokymia can be associated with brain stem disease and multiple sclerosis among other serious neurologic disease, we require that patients be under the supervision of their family physician or a neurologist before providing Botox treatment for blepharospasm.

The surgical treatment of blepharospasm is a formidable undertaking with potential complications including facial paralysis and corneal exposure. With the advent of Botox, the indications for surgical treatment of blepharospasm are less.

Injection techniques for blepharospasm and facial spasm

Benign essential blepharospasm is treated with five 2.5 unit doses of Botox injected subcutaneously at the medial and lateral aspect of each lid and at the lateral canthus (Figure 3). Care should be exercised to avoid injecting the mid portion of the upper lid so as to avoid paralyzing the levator palpebri and causing ptosis. In cases where the spasm spreads to other facial muscles and even to the neck, similar 2.5 unit injections are given subcutaneously at the site of the spasm. I have give up to 50 units at one treatment. Injection should not be made inferior to the nasolabial fold! Injections here cause lip droop that in turns leads to very annoying lip biting by the patient.

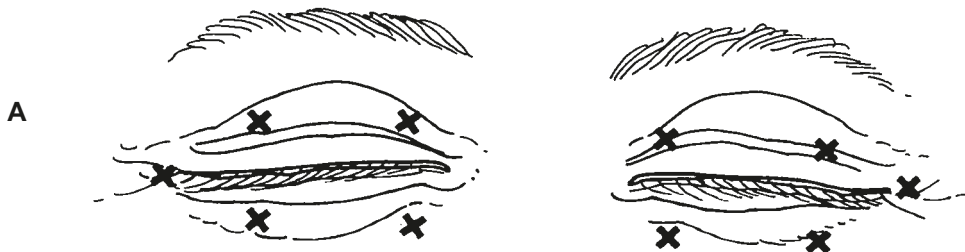


Figure 3
A The site of subcutaneous injection for blepharospasm.

continued.

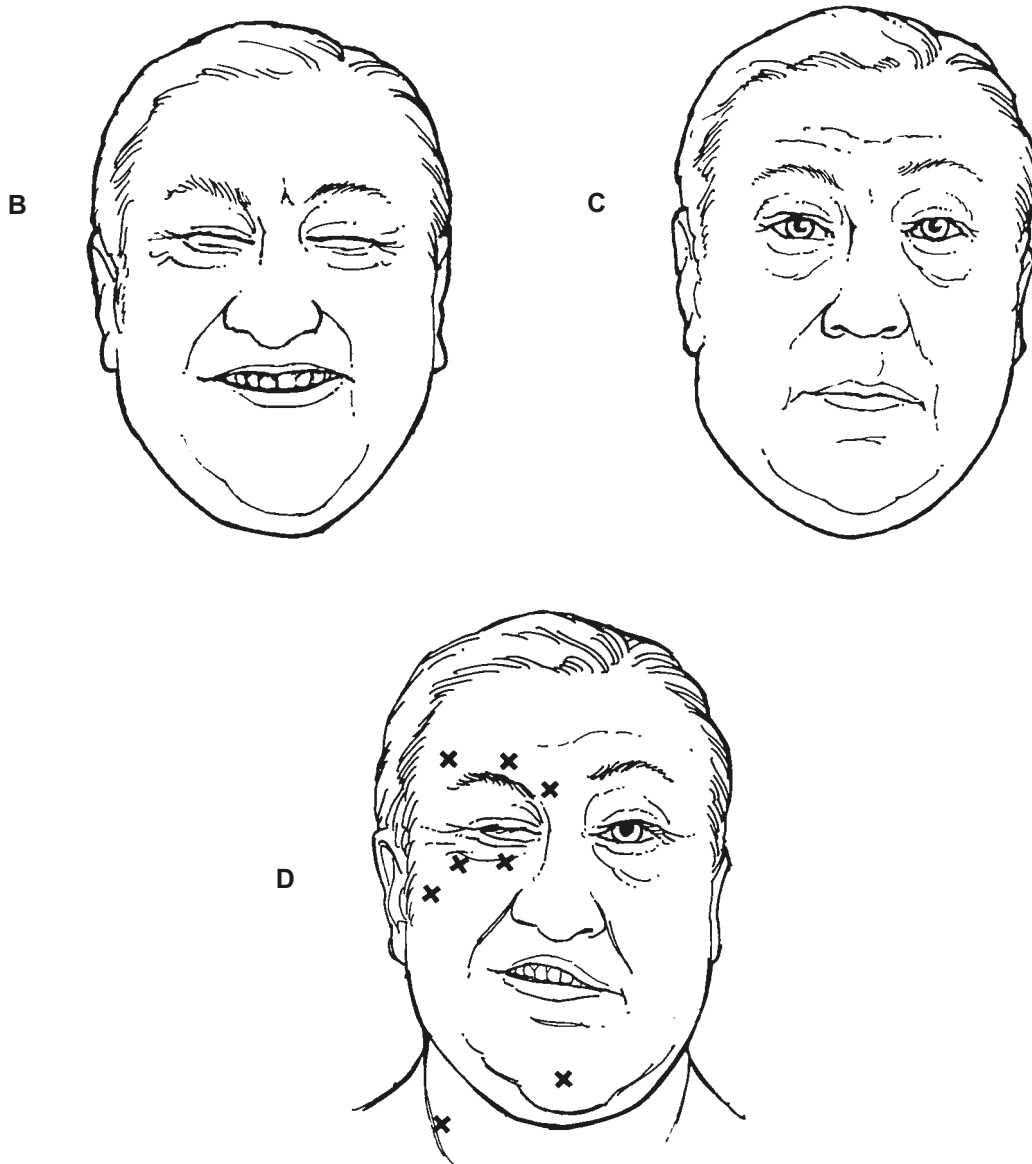


Figure 3, cont'd

B A typical appearance before injection.

C A typical appearance a few days after injection.

D An example of sites around the face that would be injected in a typical case of hemifacial spasm.

Section 4

Chapter 15: Telemedicine: distance medicine

Chapter 16: Strabismus case management

Chapter 17: Complications of strabismus surgery

15

Telemedicine: distance medicine

'Tele' denotes distance and medicine is the science and art dealing with the prevention and healing of disease - helping people.

Telemedicine is a combination of the two, carried out in a variety of ways. The differences in the methodology of telemedicine have had a significant impact on its success or failure. The basic forms of telemedicine are as follows:

Real time vs. store and forward

Real time is just what it says. The events taking place occur simultaneously in the distance and at the point of consultation. The doctor or team of caregivers on both the requesting end and the serving end must be on duty at the same time. This might not have a great deal of effect along meridians, where the time is the same, but it has a huge implication along the parallels where time is divided into zones. For example, if someone from India were seeking consultation in the United States, an 8-10 or more hour time difference would mean that one of the parties involved would be functioning at a non-typical time for the practice of medicine. In addition, real time consultation usually means that a picture, usually moving, of both the patient and the doctors involved will be transmitted. This places great demands on instrumentation, equipment, and transmission.

An alternative to real time is the store and forward technique. With this, images are captured, retained, and stored digitally by the individual requesting a consultation. These stored images can be sent immediately or at some future time. Likewise, the individual receiving the images can look at them immediately and answer or can view the images stored on the server and available for viewing and respond at some appropriate future time. The store and forward technique has obvious advantages. It is more convenient for both parties and demands less capacity for transmission.

Moving or still

Further divisions in telemedicine techniques are between moving images and still images. Moving images such as would be obtained with a digital video camera require considerably more storage space and bandwidth for transmission. Still images in contrast can be much smaller and therefore more easily transmitted. For strabismus, the usual response is that "I can learn so much more from a moving image compared to a still image that I think a moving image is necessary." While this seems to make sense on the surface, this has not been the case in my experience. A consultant with considerable experience in the management of strabismus can virtually fill in the movement on the basis of history and evaluation while viewing appropriate still images.

In summary, real time telemedicine while most nearly simulating a real patient encounter is logistically difficult and, in my opinion, neither necessary nor advisable. In some ways the insistence on real time may have delayed acceptance of telemedicine as a valid procedure. Moving pictures can be informative, but since they offer very little in addition to well-taken and well-formatted still images for an experienced observer, they are probably not necessary. As a compromise, moving images can be done in short strips which are not too difficult to store and forward but again, in my opinion, are not really necessary.

Image size

Another question which routinely arises in the issue of telemedicine is image size. This has to do with the number of pixels or dots which make up a picture. Image sizes are measured by multiplying the horizontal and vertical dot density. For example, the smallest image is 640 x 480 which produces what is considered a 'small' picture; that is one that always loses quality if enlarged. However, this 640x480 size

image is the *largest* picture that can be imaged on a computer screen. For telemedicine carried out on the internet there is no need to have a denser image. The issue is complicated by the fact that most digital cameras are considered better or more valuable if they are able to take pictures with higher pixel numbers. For example, we see cameras with 3.0, 4.0, or 5.0 or more megapixel capacity. Of course, these pictures will be of higher quality and will provide clearer printed pictures, particularly if enlarged but they offer absolutely nothing in terms of a better picture for internet-based telemedicine conducted on a computer screen. Actually, these pictures with high number of pixels are a great detriment to telemedicine because they demand so much space that transmission time is slowed and storage space is used up. Some large images are even blocked. For strabismus management it is important to place the digital camera on the lowest setting which is 640 x 480 or sometimes listed as 'TV', or 'PC'. These pictures have even been used for textbook illustrations (throughout this book for example, especially chapter. 15) and are perfectly adequate as long as enlargements are not too great.

These low pixel pictures have the ability to capture close-up pictures that allow enough detail for external and in some cases, even anterior segment evaluation. We have evaluated, for example, worms in the anterior chamber, uveitis, cataract, corneal dystrophies, and more.

Computer

The computer for telemedicine can have a processor of moderate speed and a RAM of between 128 and 512 MB. An adequate RAM is 256 MB. For the hard drive, a capacity of 20-80 gigabyte is ideal, but lower storage capacity computers are certainly useable since the process depends more on transmission than storage. Internet connectivity works better, of course, with broadband connection with 100 kilobytes per second, but I have used dial-up connections at 19.2 kilobytes per second successfully. It is much more important to use small file pictures than it is to have an ultra fast connection.

Start of Cyber-Sight

How did I personally start with telemedicine? I visited Havana, Cuba in 1998 with an ORBIS hospital based program. While there it occurred to me that even with a successful 5 day visit, maintaining connection with the doctors would be difficult. At a first visit, I was able to determine specific equipment needs. This prompted a second visit approximately two weeks later. With additional equipment, it was possible to complete the surgery schedule. However, even this was unsatisfying in that there still was no

mechanism for follow up. At a third visit two weeks after this, the local doctors were given a simple computer, and a digital camera. The doctors were instructed to obtain digital images of patients in the nine diagnostic positions, plus head tilt to the right and left, and other pictures showing head posture, etc. They were instructed to send these pictures via email along with a brief clinical history. At the consultant's (my) end, these pictures were arranged in an album and then printed out as shown in the Figure 1. A diagnosis, suggestions for further evaluation when indicated and example of a treatment plan were sent back via email for each of these patients, but the doctors were advised to withhold any specific treatment based on my diagnoses and opinions.

At a fourth visit, 15 patients who had received consultation via telemedicine were examined and a diagnosis and treatment plan for each was arrived at by me. These were then compared with the telemedicine diagnoses and treatment plans and it turned out that the agreement was nearly perfect.

As a means of further confirmation, ten patient consultation requests with the history and complete clinical pictures were sent to a panel of ten strabismus experts. They were asked to make a clinical diagnosis and suggest a treatment plan. The clinical diagnoses agreed in more than 90% of cases and treatment plans were virtually identical in 50% of the patients and were similar and logical in the others. Based on this information, the doctors in Cuba were advised to continue to send patients and to work with the telemedicine program regarding diagnosis and treatment.

New programs using email and digital images were then established in Romania, India, Albania, and the Dominican Republic. By the fall of 2002, approximately 2,000 communications had taken place with the telemedicine partners. At this time, the program was given to ORBIS International. It was adopted as a formal ORBIS program called Cyber-Sight. In order to facilitate the transfer of patient information, a server-based patient submission format was established (see Figure 2). Beginning in the spring of 2003, consultations were submitted using this format. Between the spring of 2003 and the summer of 2005, nearly 1,700 patients and 4,000 communications were carried out using this new technique.

The format for patient presentation is shown in Figure 3. This includes a greeting to the person submitting the consult and space for the patient's name, gender, birth date, visual acuity, and refraction. The partner requesting the consultation also has the opportunity to select from a pull-down box the subspecialty most appropriate for the patient. In addition to strabismus, consultation is offered in glaucoma, retina, cataract, neuro-ophthalmology, uveitis,




Figure 1 Typical case presentation using e-mail for telemedicine

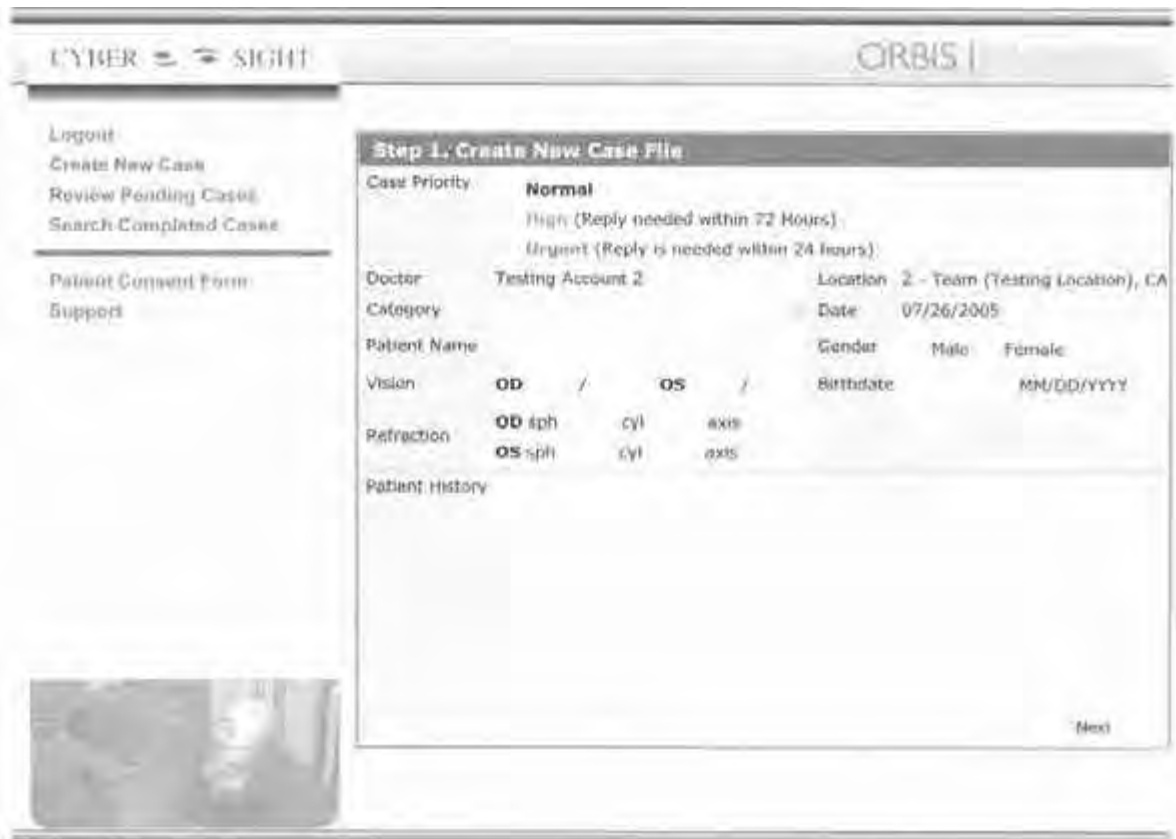


Figure 2 The formatted page used for initiating a consultation with Cyber-Sight

retinoblastoma, ophthalmic genetics, oculoplastics, cornea, and more. In this program, the majority of the patients, especially at the beginning, were in the category of pediatric ophthalmology and strabismus.

A space below this section is reserved for a patient history. This includes chief complaint, prior medical history, a narrative of the measurements and evaluation, family history, prior surgery, etc. The next repository for information includes a series of cartoons which allow for the uploading of 17 images. The first nine images are of the diagnostic positions. Below that are images of the head tilt, 45° right and left, and notation of the patient fixing with a translucent occluder placed over the right eye and then the

left eye. The final four pictures are for other views that could include head posture or other significant characteristics of the strabismus. After these pictures are uploaded three at a time, the submitting partner provides a diagnosis and a tentative treatment plan and optional further comments (Figure 3). The case is then submitted. At this time the consulting mentor is alerted by email. The mentor then sees a screen which provides a complete patient presentation including narrative and appropriate pictures (see Figure 4). The mentor provides an answer, starting a dialogue that could include several additional communications. The case is closed eventually by the partner.

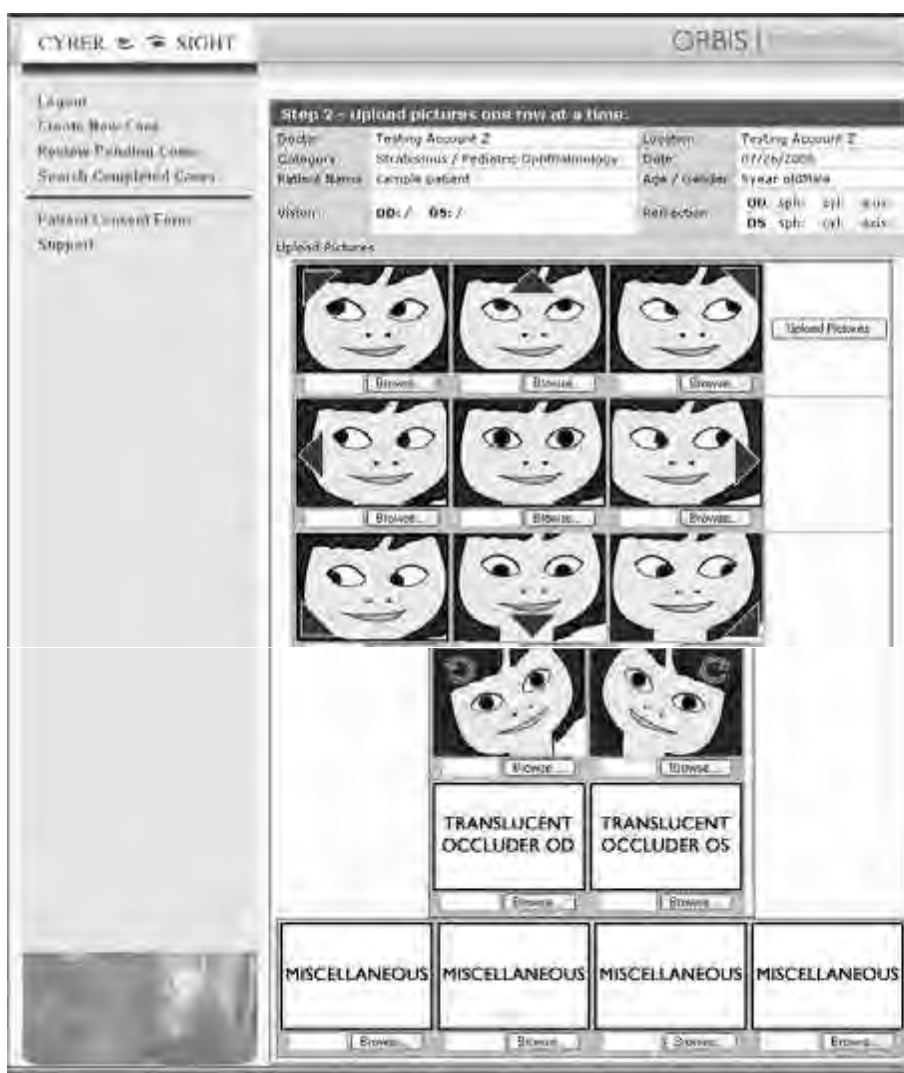

Figure 3 For the submission of a strabismus patient, Cyber-Sight partners are prompted to upload up to 17 images. These are low density 640 x 480 pixel images.

CYBER  SIGHT ORBIS | 

Logout

[Review New Cases](#)

[View Active Cases](#)

[Search Completed Cases](#)

[Support](#)

 [Print View](#)

Case #TEST0347

Doctor	Testing Account Z	Location	Z - Team (Testing Location), CA
Category	Strabismus / Pediatric Ophthalmology	Date	07/26/2005
Patient Name	Sample Patient	Age / Gender	5year oldMale
Vision	OD: / OS: /	Refraction	OD sph: cyl: axis: OS sph: cyl: axis:

Patient History example

Pictures



Partner Diagnosis

Current Diagnosis	strabismus
Tentative Plan	consult

Special Questions or Comments

[Respond to this Case](#)



Figure 4
The array of patient pictures

The strabismus database as of the summer of 2005 contains 1320 strabismus patients. Diagnoses of these patients are broken down in the Table 1.

I believe that with practice, an experienced strabismologist can, in nearly every case, establish a correct diagnosis and offer a reasonable treatment plan after study of a case submitted in the Cyber-Sight format. But, the main goal of Cyber-Sight is to help the partner develop the skills to enhance patient care, while learning from this experience so that this knowledge can be applied to the *next* patient. About half of the mentor responses include advice for additional workup, further tests, etc. With appropriate application, this technique of telemedicine will be useful for diagnosis and treatment, but more important it will also be an extremely valuable tool in the learning process for partners in developing countries. This technique can also increase efficiency, cut costs, and improve the quality of care for patients in currently underserved areas.

A selection of cases seen in consultation via Cyber-Sight is presented in the remainder of this chapter. An explanation of the format for these case presentations is in Figure 5.

Strabismus cases seen in consultation on Cyber-Sight between February, 2003 and July, 2005

Total number of cases	1320
Esotropia	29%*
Exotropia	16%
Unspecified vertical	7%
Superior oblique palsy	10%
Third nerve palsy	9%
Sixth nerve palsy	4%
Duane	15%
Brown	6%
Strabismus after trauma	4%
	100%

* These percentages represent the distribution of 663 of the total number of cases.

Table 1

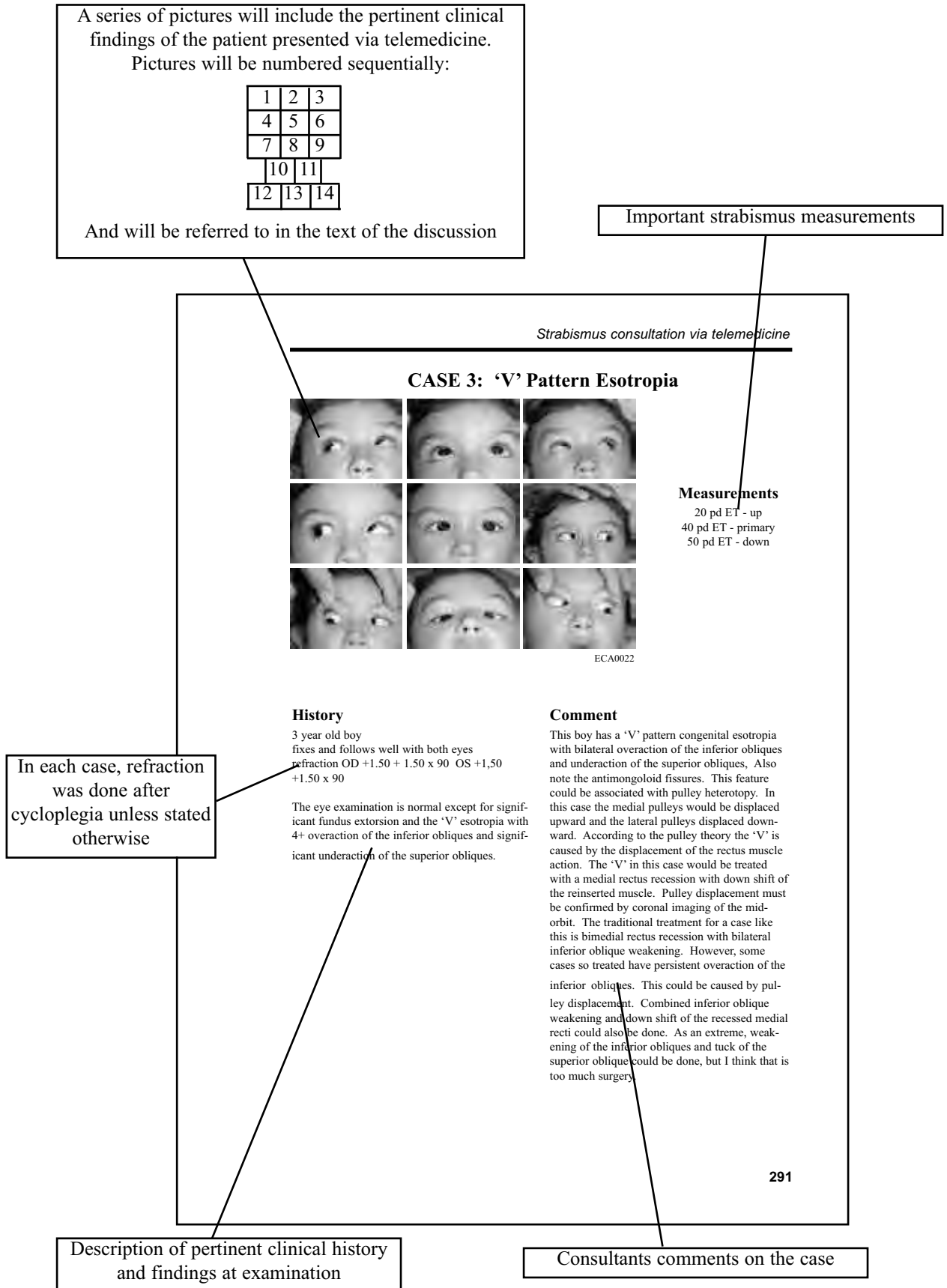


Figure 5 Explanation of case discussion of patients seen in telemedicine consultation

Telemedicine consultation cases

- CASE 1** Pseudo strabismus, 293
CASE 2 Congenital esotropia, 294
CASE 3 'V' pattern esotropia 295
CASE 4 'V' pattern esotropia with amblyopia, 296
CASE 5 'V' pattern esotropia, 297
CASE 6 'V' pattern esotropia, 298
CASE 7 'V' pattern esotropia, 299
CASE 8 'V' pattern - refractive esotropia, 300
CASE 9 'A' pattern esotropia, 301
CASE 10 'A' pattern esotropia with right hypertropia, 302
CASE 11 'A' pattern esotropia, 303
CASE 12 'A' pattern esotropia with chin elevation, 304
CASE 13 Congenital exotropia, 305
CASE 14 Congenital exotropia with 'V' pattern, 306
CASE 15 Congenital exotropia with 'V' pattern, 307
CASE 16 Intermittent exotropia, 308
CASE 17 Congenital exotropia, 309
CASE 18 'A' pattern, overaction of the superior obliques and DVD, 310
CASE 19 'V' pattern exotropia, 311
CASE 20 'X' pattern exotropia, 312
CASE 21 Sensory exotropia, 313
CASE 22 'X' pattern exotropia with DVD, 314
CASE 23 'A' pattern esotropia with DVD, 315
CASE 24 'A' pattern, 316
CASE 25 Consecutive esotropia, 317
CASE 26 Esotropia and hypotropia in a blind eye, 318
CASE 27 'A' pattern esotropia - mongoloid fissures, 319
CASE 28 Consecutive exotropia, 320
CASE 29 Acquired Third nerve palsy, 321
CASE 30 Congenital third nerve palsy, 322
CASE 31 Acquired third nerve palsy, 323
CASE 32 Bilateral congenital third nerve palsy, 324
CASE 33 Acquired third nerve palsy, 325
CASE 34 Traumatic third nerve palsy, 326
CASE 35 Class I superior oblique palsy, 327
CASE 36 Class II superior oblique palsy, 328
CASE 37 Class III superior oblique palsy, 329
CASE 38 Class III superior oblique palsy, 330
CASE 39 Class III superior oblique palsy, 331
CASE 40 Class IV superior oblique palsy, 332
CASE 41 Class V superior oblique palsy, 333
CASE 42 Class V superior oblique palsy, 334
CASE 43 Class III superior oblique palsy with pseudo ptosis, 335
CASE 44 Superior oblique palsy - head posture normalized, 336
CASE 45 Congenital superior oblique palsy, 337
CASE 46 Congenital superior oblique palsy, 338
CASE 47 Bilateral sixth nerve palsy, 339
CASE 48 Bilateral sixth nerve palsy, 340
CASE 49 Sixth nerve palsy, 341
CASE 50 Sixth and seventh nerve palsy, 342
CASE 51 Bilateral sixth nerve palsy, 343
CASE 52 Duane class I, 344
CASE 53 Duane class II, 345
CASE 54 Duane class III, 346
CASE 55 Duane class III, 347
CASE 56 Duane class II, 348
CASE 57 Duane class II, 349
CASE 58 Duane class I (orII), 350
CASE 59 Duane class IV, 351
CASE 60 Brown, 352
CASE 61 Brown (three examples), 353
CASE 62 Hypotropia (trauma), 354
CASE 63 Traumatic disinsertion of the inferior rectus, 355
CASE 64 Third nerve palsy with aberrant regeneration, 356
CASE 65 Traumatic subconjunctival hemorrhage, 357
CASE 66 Conjunctival laceration, 357
CASE 67 Dissociated vertical deviation (two examples), 357
CASE 68 Heimann-Bielschowsky phenomenon, 358

CASE 1: Pseudo strabismus



GUM0060

Measurements

Orthotropic by light reflex

History

This six month old girl was presented by her parents because they were concerned about the eyes turning in. She is otherwise healthy and there is no family history of strabismus. The eye examination is normal and cycloplegic refraction is OD +1.00 D and OS 1.00 D.

Comment

In a case like this it is difficult to do a cover test to confirm the alignment. In place of a cover test it is important to observe the corneal light reflex. If the light reflex is in the center of the pupil it is likely that the eyes are aligned in spite of the apparent esotropia that is caused by the wide nasal skin folds obliterating view of the nasal conjunctiva. Pulling the skin over the bridge of the nose forward will have an instant 'straightening' effect, but it usually causes an infant to become fussy. It is difficult to photograph, but it can be shown to parents. In a case like this, it is important to do a thorough eye examination and to offer the family a plan to follow this infant.

CASE 2: Congenital esotropia



AL0004

Measurements

40 pd ET - primary

History

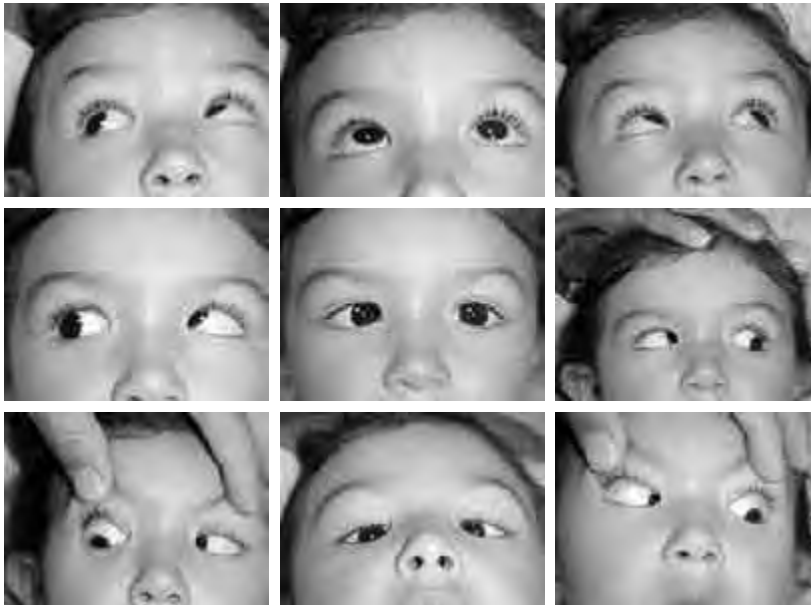6 month old boy
Vision: fixes and follows with both eyes
Refraction: OD +1.00
OS +1.00

This six month old boy was noted by his parents to have crossed eyes beginning shortly after birth. The pregnancy and delivery were normal. He is developing normally. The eye examination is normal except for the esotropia.

Comment

The diagnosis of congenital esotropia is straightforward. This infant fits the criteria for this diagnosis. The deviation is constant, 40 prism diopters and the child is over four months of age. The pictures indicate the likelihood of cross fixation, but it is the examiners responsibility to demonstrate the infant's willingness to take up fixation with either eye to rule out amblyopia, and to confirm abduction in both eyes. At this time a 'V' pattern (rarely an 'A') is looked for. The presence of manifest or latent nystagmus is also noted. Picture 7 shows fairly good abduction in the right eye and picture 8 shows excellent abduction in the left eye. These ductions are best demonstrated with the doll's head maneuver (see p. 85). This child is a candidate for surgery. In my hands this would be a bimedral rectus recession putting the muscles back 10 to 10.5 mm from the limbus (or an appropriate amount from the insertion).

CASE 3: 'V' pattern esotropia



ECA0022

Measurements

20 pd ET - up
40 pd ET - primary
50 pd ET - down

History

3 year old boy

Vision: fixes and follows well with both eyes

Refraction: OD +1.50 +1.50 x 90 degrees

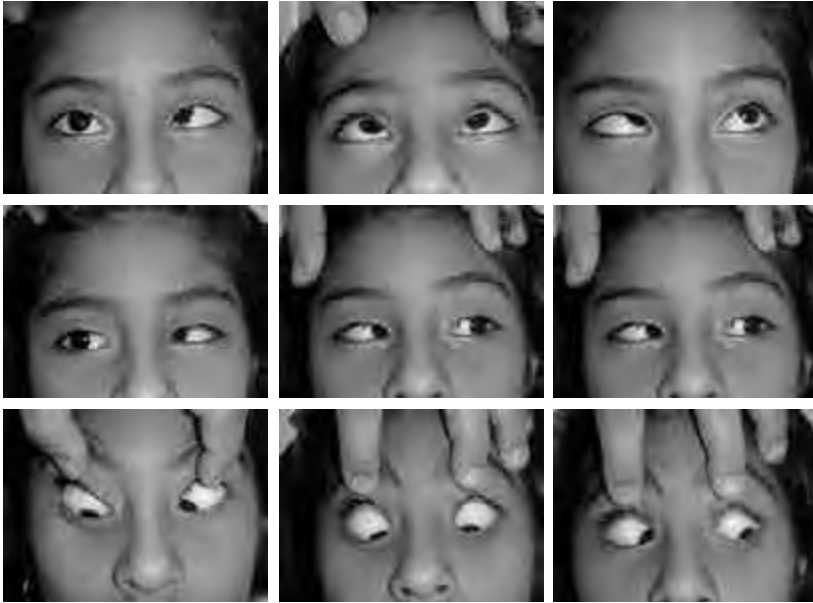OS +1.50 +1.50 x 90degrees

The eye examination is normal except for significant fundus extorsion and the 'V' esotropia with 4+ overaction of the inferior obliques and significant underaction of the superior obliques.

Comment

This boy has a 'V' pattern congenital esotropia with bilateral overaction of the inferior obliques and underaction of the superior obliques. Also note the antimongoloid fissures. This feature could be associated with pulley heterotopy. In this case the medial pulleys would be displaced upward and the lateral pulleys displaced downward. According to the pulley theory, the 'V' is caused by the vertical displacement of the horizontal rectus muscle action, relatively weakening them in the direction of the displacement. The 'V' in this case would be treated with a medial rectus recession with down shift. Pulley displacement must be confirmed by coronal imaging of the mid-orbit, but this is not readily available at this time because of cost, availability, and patient cooperation. The traditional treatment for a case like this is bimedial rectus recession with bilateral inferior oblique weakening. However, some cases treated this way have persistent overaction of the inferior obliques. This could result from unrecognized, or untreated, pulley displacement contributing to the vertical incomitance. Combined inferior oblique weakening and down shift of the recessed medial recti could also be done. As an extreme, weakening of the inferior obliques and tuck of the superior oblique, if they are loose, could be done along with bimedial rectus recession, but I think that is too much surgery for this boy.

CASE 4: 'V' pattern esotropia with amblyopia



EC0024

Measurements

50 pd ET - up
60 pd ET - primary
70 pd ET - down

History

12 year old girl
Vision: OD 20/200, OS 20/20
Refraction: OD +.50
OS +.25

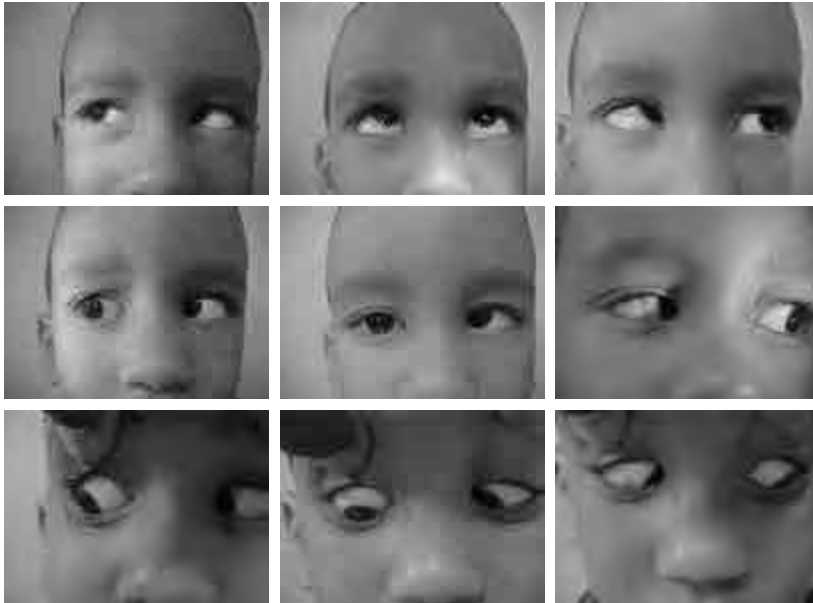This 12 year old girl has deep amblyopia in the right eye that has been refractory to patching. A mild 'V' pattern is present with moderate overaction of the inferior obliques and underaction of the superior obliques. Except for the strabismus and amblyopia the eye examination was normal including a normal fundus exam.

Comment

Of course, the amblyopia treatment should be continued if at all possible. However, the odds of success are reduced as the child grows older for reasons of cooperation if not for reasons related to the amblyopia itself.

In order to avoid surgery on the better seeing eye and still deal with the 'V' pattern, this child could benefit from recession of the right medial rectus with one half muscle width down shift and resection of the right lateral rectus with one half muscle width up shift. Another option would be bimedial rectus recession with bilateral inferior oblique weakening, but this would require surgery on the normal seeing eye and is not a good idea. The recession and resection should both be maximum.

CASE 5: 'V' pattern esotropia



DR-Aybar0016

Measurements

40 pd ET - up
40 pd ET - primary
60 pd ET - down

History

4 year boy

Vision: OD 20/40, OS 20/40

Refraction: OD + 3.00

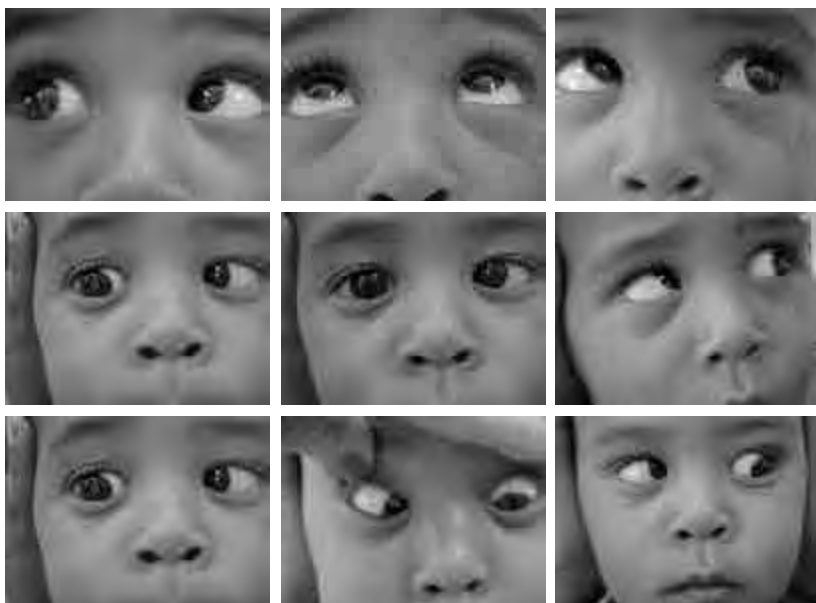OS + 3.00 (wears glasses but they have little effect on the angle)

This boy was noted to have crossed eyes since shortly after birth. His health is good and there is no family history of strabismus. The eye examination was normal except for the strabismus. The superior obliques appear to underact to a greater degree than the inferior obliques overact.

Comment

This pattern of 'V' esotropia demonstrates underaction of the superior obliques to a greater degree than the overaction of the inferior obliques. Pictures 3 and 5 show only mild strabismus surso-adductorius or elevation in adduction. This boy has normal palpebral fissure configuration suggesting that there is no pulley heterotopy. The superior oblique traction test may demonstrate a lax tendon. This would suggest that a superior oblique tuck along with a bimedial rectus recession placing the medial recti 10 to 10.5 mm from the limbus or an appropriate distance from the insertion would be appropriate. However, most surgeons would weaken the antagonist inferior obliques even in the presence of a lax tendon.

CASE 6: 'V' pattern esotropia



Measurements

Ortho - up
 35 pd ET - primary
 55 pd ET - down

DRD0021

History

3 year old boy

Vision: OD poor fixation, OS fixes and follows

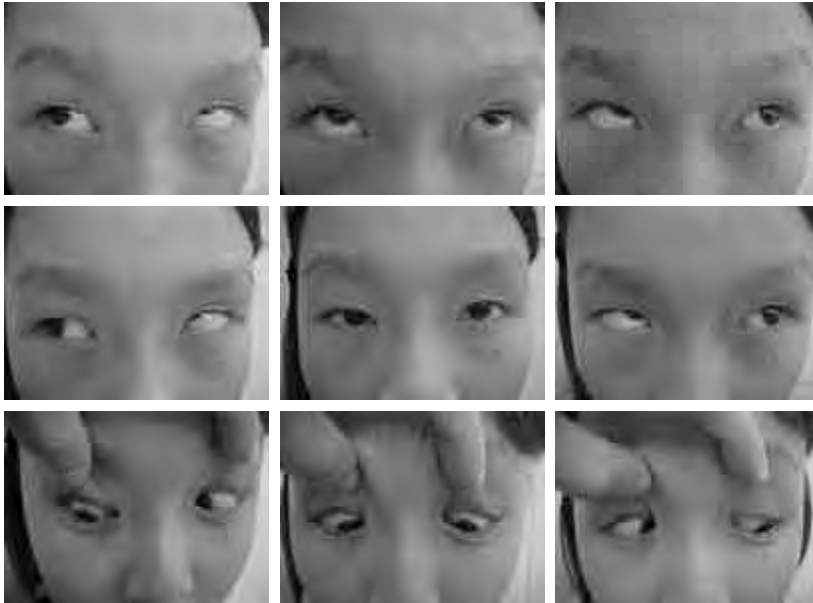Refraction: OD +2.00
 OS +2.00

This boy has amblyopia of the right eye 'V' pattern, overaction of the inferior obliques, and underaction of the superior obliques. The remainder of the eye examination is within normal limits. He also demonstrates chin depression preferring up gaze where his eyes are aligned, this in spite of the amblyopia in the right eye.

Comment

This boy has a 'V' pattern which goes from ortho in up gaze to 55 prism diopters of esotropia in down gaze. The inferior oblique overaction and superior oblique underaction are apparent. With the amblyopia in the right eye note in picture 4 that the adducted left eye takes up fixation so that the strabismus sursoadductorius or elevation in adduction is manifested as a hypotropia of the abducted eye. The first order of treatment is to deal with the amblyopia. Then surgical treatment could consist of weakening of the inferior obliques along with a moderate medial rectus recession with down shift. This down shift is because of the likelihood of pulley heterotopy suspected because of the slight antimongoloid fissure.

CASE 7: 'V' pattern esotropia



HAN0061

Measurements

10 pd XT - up
20 pd ET - primary
45 pd ET - down

History

13 year old girl

Vision: OD 20/20, OS 20/30

Refraction: OD +1.50 +0.75 x 90 degrees

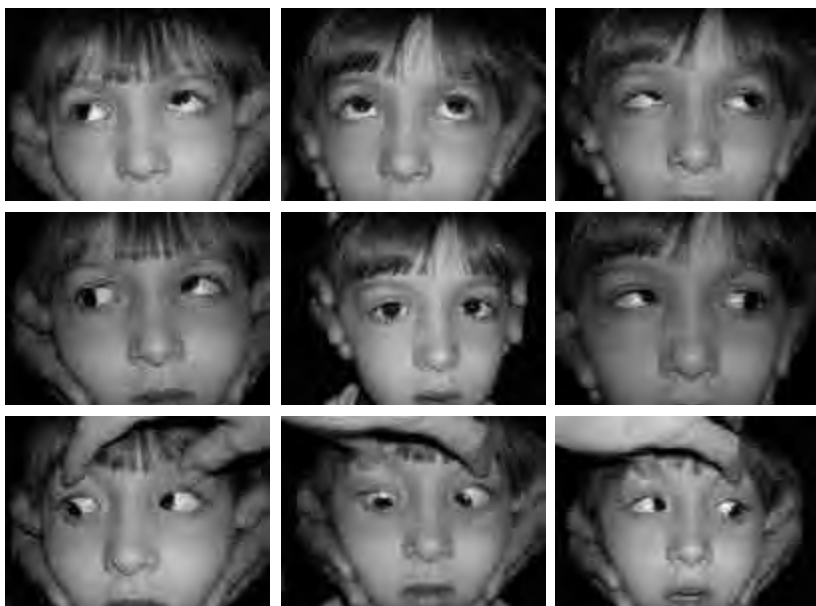OS +2.00 +0.50 x 90 degrees

This girl has very big overaction of the inferior obliques and underaction of the superior obliques. A moderate esotropia in the primary position actually becomes an exodeviation in up gaze. The down gaze deviation is a larger esotropia.

Comment

At surgery this girl should have a careful superior oblique traction test. If the tendons are loose or lax, a bilateral superior oblique tuck could be done along with a moderate bimedial rectus recession moving the medial recti 8.5 mm from the limbus or an appropriate amount from the insertion. For those not inclined to do a superior oblique tuck, bilateral inferior oblique weakening could be done. It is important in cases like this to perform the superior oblique traction test even if you would have no intention of doing a superior oblique tuck. Only by doing this test will you get a 'feel' for what is normal and what is abnormal.

CASE 8: 'V' pattern esotropia - refractive esotropia



Measurements

5 pd XT - up
 30 pd ET (14 pd ET with Rx)
 - primary
 50 pd ET - down

RO - CHB0005

History

6 year old girl

Vision: OD 20/25, OS 20/25

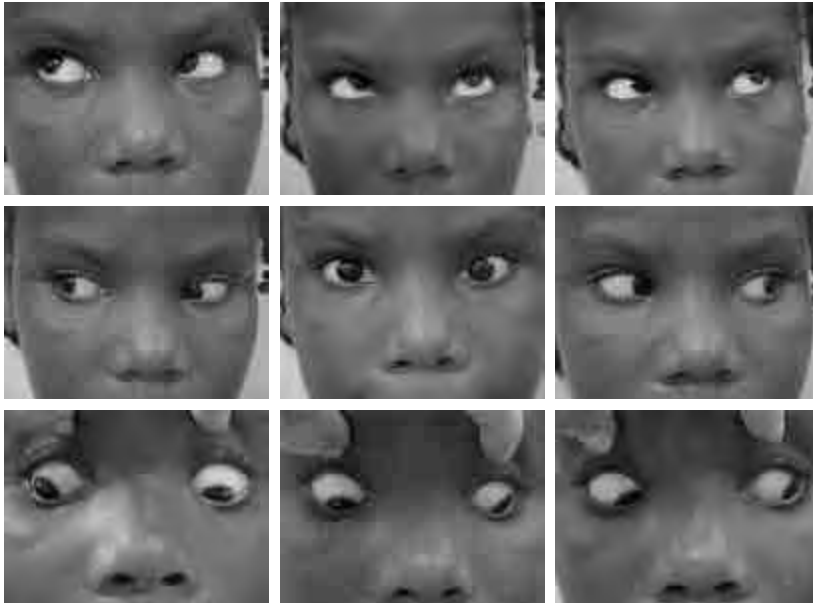Refraction: OD +4.50 +1.00 x 100 degrees
 OS +4.50 +1.00 x 80 degrees

This girl has an esotropia somewhat responsive to her hyperopic correction plus a 'V' pattern with inferior oblique overaction superior oblique underaction and antimongoloid fissures suggestive of possible pulley heterotopy.

Comment

Since the esodeviation is only 14 prism diopters in the primary position with glasses, only a single medial rectus should be recessed to 8.5 mm from the limbus or an appropriate amount from the insertion. For the 'V' pattern two options are possible. Either the inferior obliques can be weakened or lax superior oblique tendons, if found at traction testing, can be tucked. In addition, the recessed medial rectus can be displaced downward 1/4 muscle width and the other medial rectus also moved down 1/4 muscle width without recessing it. Extreme 'V' pattern with evidence of pulley heterotopy suggests the possible need for a 'double' procedure to treat the 'V.' This is the type of case that could have persistent inferior oblique overaction after proper weakening has been done. The reason for this could be superior oblique tendon laxity occurring on a congenital basis.

CASE 9: 'A' pattern esotropia



DRD0014

Measurements

35 pd ET - up
20 pd ET - primary
55 pd ET - down

History

11 year old girl
Vision: OD 20/20, OS 20/20
Refraction: OD +1.00
OS +1.00

This girl demonstrates an 'A' pattern with an esotropia in upgaze and a large exotropia in downgaze. Very evident mongoloid fissures are also present. What is usually called overaction of the superior obliques is also present

Comment

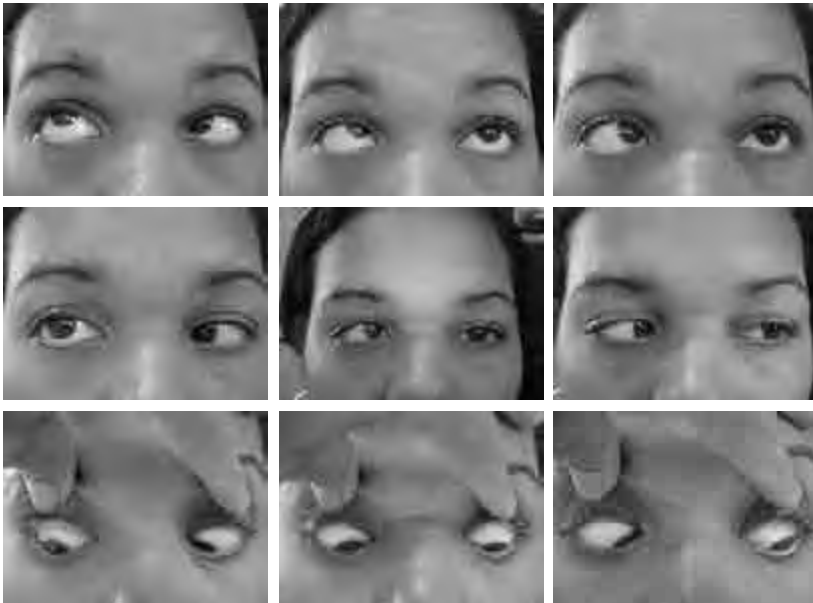This girl demonstrates vertical incomitance that changes from esotropia in primary position and upgaze to large angle exotropia in down gaze. This is present along with pronounced mongoloid fissures. The exotropia in down gaze seems to be caused by the exaggerated abducting action of the superior oblique muscles. This behavior is likely to be caused by *downward* displacement of the medial pulleys and *upward* displacement of the lateral pulleys as would be expected to occur with a mongoloid fissure.

Treatment in this case could be:

- 1) Recession of both medial rectus muscles to 10.0 mm from the limbus or an appropriate amount from the insertion with 1/2 muscle width *upshift*
- 2) Recession of both lateral rectus muscles 5.0 mm with 1/2 muscle width *downshift*

Some surgeons might choose bilateral superior oblique weakening with tenectomy or recession combined with a bimedial rectus recession with or without upshift

CASE 10: 'A' pattern esotropia with right hypertropia



DRR0015

Measurements

60 pd ET - up
50 pd ET 25 pd R hyper -
primary
20 pd ET - down

History

23 year old female

Vision: OD 20/50, OS 20/20

Refraction: OD plano -1.50 x 180 degrees
OS +1.00 -1.00 x 180 degrees

This woman has had an esotropia since birth. She has a mild amblyopia in the right eye, and a right hypertropia. The oblique muscles do not overact and the palpebral fissures are normal.

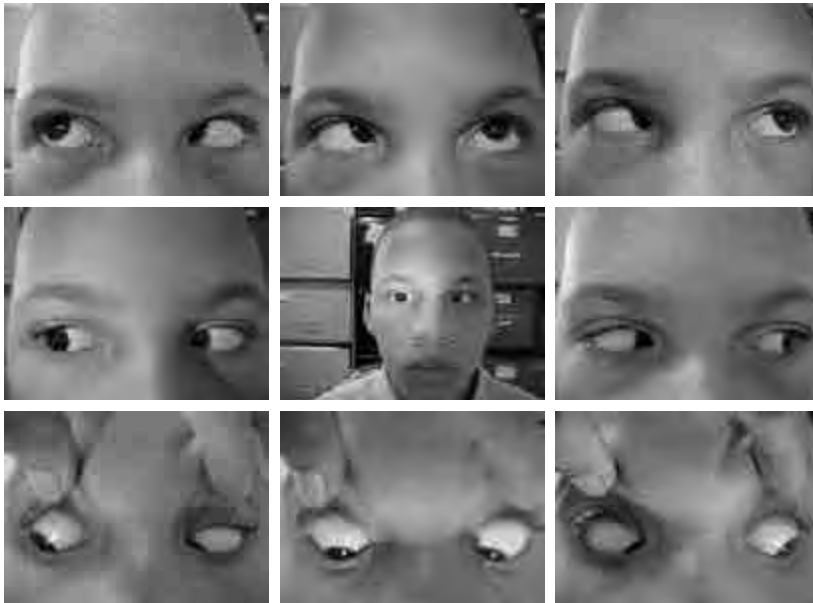Comment

A surgical plan for this woman could avoid surgery on the oblique muscles and include the following:

- 1) Right eye: recess the medial to 10.0 mm from the limbus or an equivalent from the insertion with 1/2 muscle width upshift and recess the superior rectus 5.0 mm
- 2) Left eye: recess the medial rectus 10.0 mm from the limbus or an equivalent amount from the insertion with 1/2 muscle width upshift and resect the lateral rectus 6.0 mm with 1/2 muscle width downshift.

Even though there is no fissure obliquity suggesting pulley heterotopy the fact that the obliques do not appear to be overacting suggests that vertical displacement of the horizontal recti would be best.

CASE 11: 'A' pattern esotropia



DRR0017

Measurements

80 pd ET - up
75 pd ET - primary
40 pd ET - down

History

11 year old boy
Vision: OD 20/20, OS 20/20
Refraction: OD +1.00 -1.50 x 180 degrees
OS +1.50 -0.75 x 180 degrees

This boy developed an esotropia about age 5 years according to his parents. The 'A' pattern is present without apparent superior oblique overaction or inferior oblique underaction. There is no explanation why the deviation started so late.

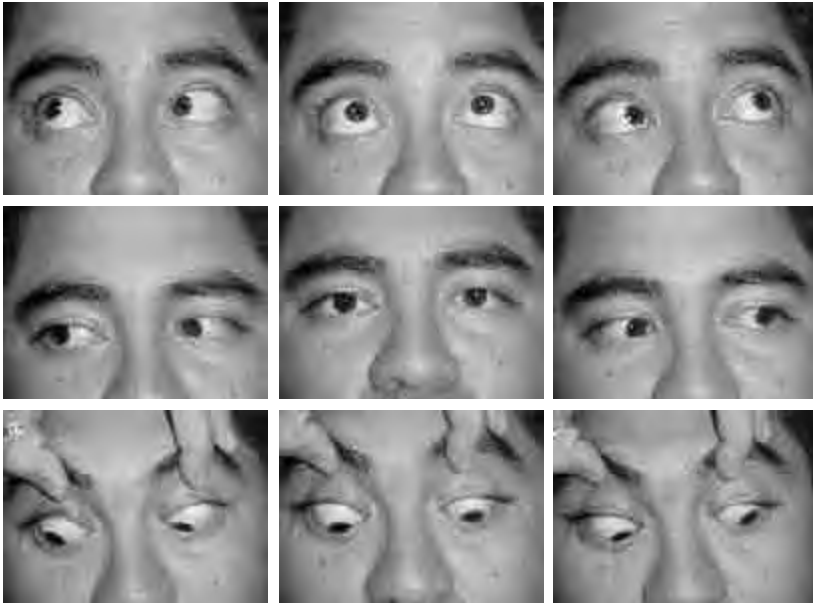
Comment

Treatment of this 'A' pattern could consist of the following:

- 1) Bimedial rectus recession to 11.0 mm from the limbus or equivalent distance from the insertion with 1/2 muscle width upshift
- 2) Bilateral lateral rectus resection 5 or 6 mm with 1/2 muscle width downshift

The patient should be tested for optokinetic asymmetry to determine if the likely etiology is congenital esotropia

CASE 12: 'A' esotropia with chin elevation



ECA0026



Measurements

40 pd ET - up
30 pd ET - primary
20 pd E(T) - down

History

34 year old male
Vision: OD 20/20, OS 20/30
Refraction: OD -0.50 -0.50 x 171 degrees
OS plano -0.75 x 180 degrees
Fuses: Worth four-lights in down gaze; no stereopsis measured

This man suffers from chronic neck ache from holding his chin up and looking down to avoid diplopia. He has an 'A' pattern esotropia. He avoids diplopia with the head posture and even demonstrates some fusion ability in down gaze. To avoid double vision he pays the price of physical discomfort.

Comment

A logical treatment plan for this man includes:
1) Bimedial rectus recession 11.0 mm from the limbus or equivalent amount measured from the insertion
2) Upshift of the recessed medial rectus muscles 1/2 to 3/4 muscle width.
Postoperative pictures show the man with an improved head posture.

CASE 13: Congenital exotropia



DRR0018

Measurements

60 pd XT - up
60 pd XT - primary
60 pd XT - down

History

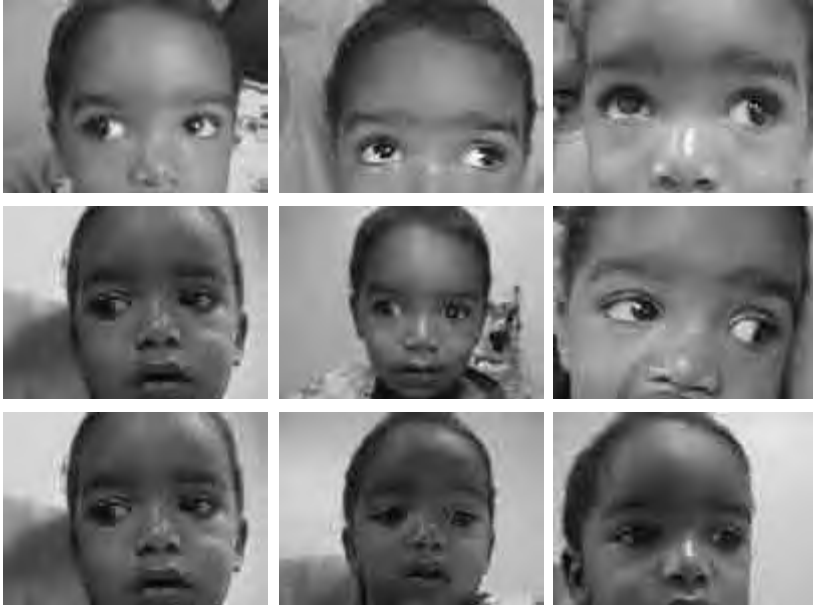10 month old boy
Vision: fixes and follows well with each eye
Refraction: OD +1.50
OS +1.50

This 10 month old boy has congenital exotropia. His past medical history is unremarkable and the eye examination is normal except for the exotropia.

Comment

Treatment of congenital exotropia in this case can be managed with a bilateral lateral rectus recession of 7.0 mm. To this could be added a moderate resection of one medial rectus.

CASE 14: Congenital exotropia 'V' pattern



DRR0034

Measurements

90 pd XT - up
70 pd XT - primary
50 pd XT - down

History

3 year old boy

Vision: fixes and follows well with both eyes

Refraction: OD +1.00 -2.00 x 90 degrees
OS +1.00 -0.50 x 90 degrees

The family noted an exodeviation at 3 months. The child's general health is good and the eye examination is normal except for the 'V' pattern exotropia. There is significant overaction of the inferior obliques.

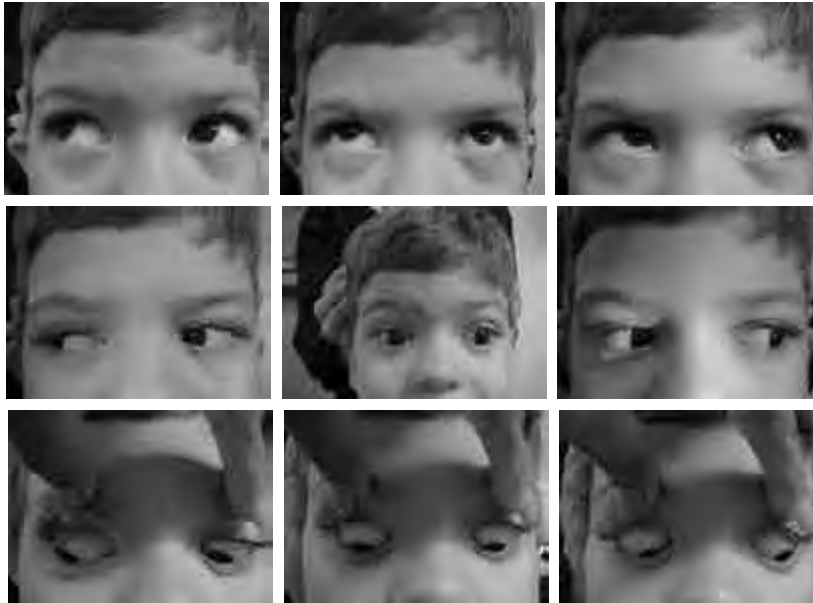Comment

This large angle 'V' pattern congenital exotropia could be treated with the following:

- 1) Bilateral lateral rectus recession 7.5 mm
- 2) Resect one medial rectus muscle 5.0 mm
- 3) Bilateral inferior oblique weakening

The recessed lateral rectus muscles could also be shifted up 1/2 muscle width and the resected medial rectus muscle shifted down 1/2 muscle width and the inferior oblique weakening omitted.

CASE 15: Congenital exotropia 'V' pattern



DRR0013

Measurements

70 pd XT - up
50 pd XT - primary
50 pd XT - down

History

5 year old boy

Vision: OD 20/20, OS 20/20

Refraction: OD plano -0.75 x 180
OS plano -0.75 x 180

This 5 year old boy started with an intermittent exotropia which gradually became constant. There is moderate overaction of the inferior obliques with a 'V' pattern. The remainder of the eye examination is within normal limits. The child is otherwise healthy.

Comment

This may be an example of an intermittent exotropia progressing to a constant exotropia over time. Some surgeons feel strongly about operating earlier on exodeviations in infants and toddlers to avoid this. The surgical treatment for this would be:

- 1) Large bilateral lateral rectus recession 7.0 to 8.0 mm with 1/4 muscle width up shift - or
- 2) Recesson one lateral rectus 7.0 to 8.0 mm with 1/4 muscle width upshift and resection one medial rectus 7.0 mm with 1/4 muscle width down shift.

CASE 16: Intermittent exotropia



AL0014

Measurements

30 pd X(T) - up
20 pd X(T) - primary
15 pd X(T) - down

History

13 year old girl
Vision: OD 20/20, OS 20/20 (with correction)
Refraction: OD -3.00 -1.00 x 165 degrees
OS -1.00 2.00 x 20 degrees
Fuses: 9/9 stereo (40 sec.)

This girl has been noted by her parents and her friends to have an eye that wanders out when she is tired or when she is 'day dreaming'. She habitually closes one in bright sunlight. The girl has no awareness of this unless it is called to her attention. She is symptom free.

Comment

This is a straightforward case of intermittent exotropia. There is no urgent need for surgery, but on the other hand it could be done at any time. A bilateral lateral rectus recession of 5.0 to 6.0 mm with 1/2 muscle width up shift would be sufficient. In the event that surgery is not done at this time, regular follow up at no longer than 6 month intervals is recommended.

CASE 17: Congenital exotropia



ECX0032

Measurements

25 pd XT - primary

History

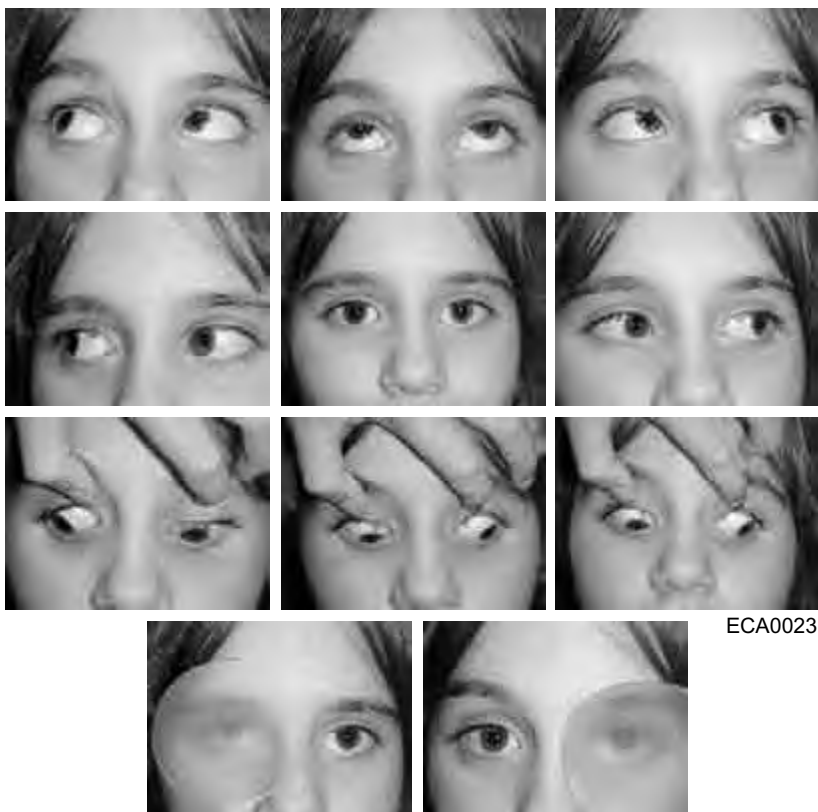16 month old girl
Vision: fixes and follows well with both eyes
Refraction: OD + 2.00
OS + 2.00

This child was brought to the ophthalmologist at age 10 months with the complaint that one eye was drifting outward. Pictures from the newborn nursery show that the eyes appeared to be aligned or possibly converged.

Comment

This child will benefit from surgery. This could be a moderate bilateral lateral rectus recession with the muscles recessed 5.0 or 6.0 mm with a 1/2 muscle width upshift to treat the 'V' pattern. It is very possible that this treatment could result in normal or near normal binocularity if this deviation did begin as an intermittent exotropia.

CASE 18: 'A' pattern, overaction of the superior obliques, and DVD



Measurements

ortho - up
 20 pd XT - primary
 45 pd XT - down

History

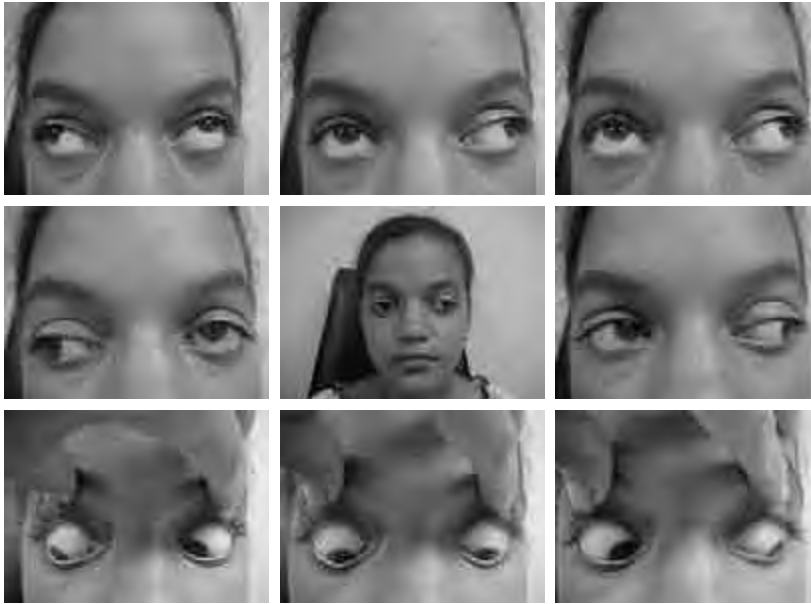11 year old girl
 Vision: OD 20/20, OS 20/20
 Refraction: OD plano +2.75 x 65 degrees
 OS plano +3.50 x 115degrees
 Stereo: nil

This girl had a bimedial rectus recession for congenital esotropia at age 9 months. At age 3 years the mother noticed the eyes beginning to deviate mostly 'outward'.

Comment

Study of these pictures reveals some interesting findings. The motility looks normal in pictures 1-6 with a small XT in the primary position, right and left gaze and eyes nearly aligned in up gaze. However in pictures 7-8-9 we see 'overaction' of the superior obliques and a big 'A' pattern. Added to this in pictures 10 and 11 we see DVD. This is the triad: 'A' pattern, overaction of the superior obliques, and DVD. In this case I believe the DVD is a carry over of congenital ET and the 'A' pattern is due to the superior obliques abducting action influenced by the retroplacement of the medial recti. Surgical options for this patient include: 1) bilateral superior rectus recession for the DVD 2) advancement of one medial rectus for the primary position XT and to reduce the down gaze XT by altering the Superior oblique action. As an alternative a small recession of one or both lateral rectus muscles with downshift 1/2 muscle width could be done. In this case I think it is important to avoid the temptation of doing a bilateral superior oblique weakening procedure. I say this because I believe that the superior obliques are 'allowed' to manifest their abducting action because of the position of the globe resulting from the medial rectus recession.

CASE 19: 'V' Pattern exotropia



DRR0045

Measurements

95 pd XT - up
45 pd XT - primary
ortho - down

History

17 year old female
Vision: OD 20/20, OS 20/20
Refraction: OD +0.75
OS +1.00

This patient has a huge 'V' pattern with what we call 'overaction' of the inferior obliques. Note in pictures 3 and 5 that adduction is limited and that in lateroversions the eyes move up and abduct as though the inferior obliques were exerting their secondary action of abduction. In addition there is a moderate antimongoloid fissure suggesting that the medial pulleys may be dislocated upward and the lateral pulleys downward! In spite of having eyes that are aligned in far down gaze, this patient demonstrates no fusion and has no diplopia. No prior surgery had been done.

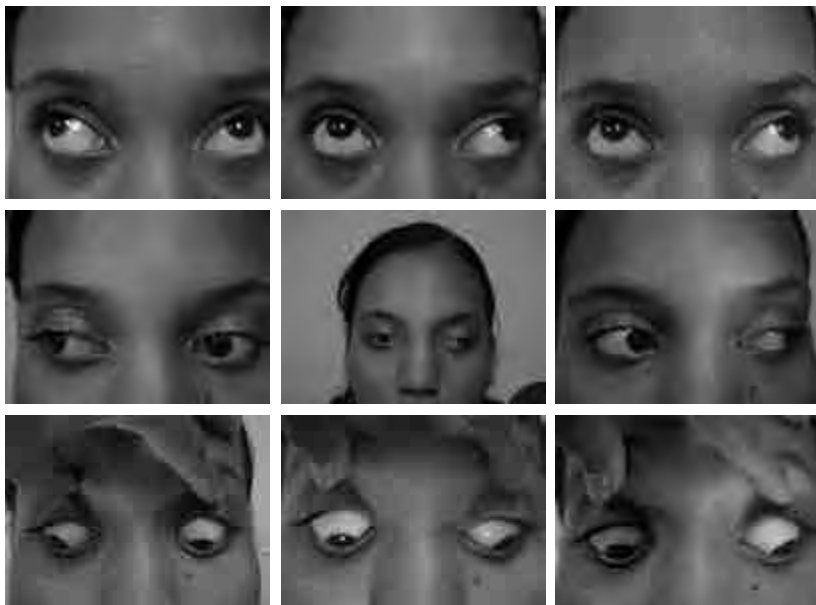Comment

Surgery in this case could included the following:

- 1) Bilateral lateral rectus recession 7.0 or 8.0 mm with 1/2 to one full muscle width upshift
- 2) Resection one medial rectus 8.0 mm with 1/2 muscle width downshift
- 3) Bilateral inferior oblique weakening (myectomy or recession)

As with any case where pulley heterotopy is suspected, coronal imaging of the orbit with CT or MRI would aid in the diagnosis and plan, but expense and availability make this impractical at this time.

CASE 20: 'X' pattern exotropia



Measurements

80 pd XT - up
 50 pd XT - primary
 75 pd XT - down

DRR0051

History

14 year old girl
 Vision: OD 20/20, OS 20/20
 Refraction: OD plano
 OS plano
 Stereo: nil

This girl has had an exotropia since age 1 year. The angle in the primary position is large, 50 prism diopters but it is even larger in both up and down gaze. Note that in pictures 3 and 5 there is no apparent elevation in adduction, the usual sign of oblique overaction. The eyes 'take off' while moving up or down demonstrating the secondary abducting action of both the inferior and superior obliques creating what is called an 'X' pattern.

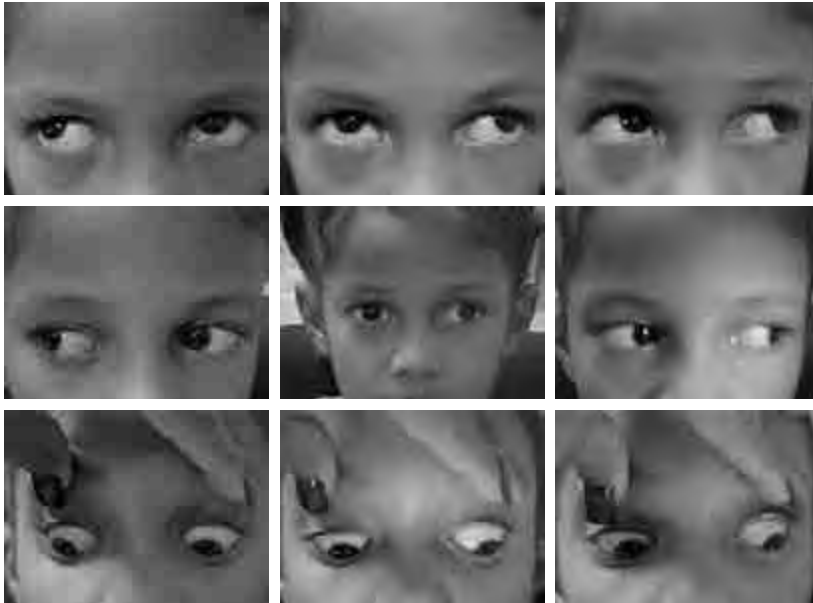Comment

With an 'X' pattern like this only horizontal surgery is required. There is no need to weaken all of the obliques as has been suggested. Surgery could include the following:

- 1) Bilateral lateral rectus recession 7.5 mm
- 2) Resection of one medial rectus 6.0 mm

If the surgeon chooses, one of the muscles could be placed on an adjustable suture. If this were done, I would elect the lateral rectus in the eye not having the medial rectus resection.

CASE 21: Sensory exotropia



DR-Aybar0013

Measurements

35 pd XT - up
30 pd XT - primary
35 pd XT - down

History

6 year old girl
Vision: OD 20/70, OS 'counts fingers'
Refraction: OD +2.50 -3.00 x 180 degrees
OS -10.00 sph.

This girl has a dense amblyopia in the left eye probably because of the high anisomyopia. It would be a good idea to check the axial length of the left eye and also to take a careful look at the retina. This girl could develop the 'heavy eye' complication of high myopia in later years. I do not know a way of keeping this from happening.

Comment

Because of the poor vision in the left eye, surgery for the exotropia should be limited to this eye. A recession of the left lateral rectus muscle of 7.5 mm and a resection of the left medial rectus of 5.0 mm would be safe and not likely to produce an over correction.

CASE 22: 'X' pattern exotropia with DVD



DRR0036

Measurements

70 pd XT - up
60 pd XT - primary
95 pd XT - down
20 pd L hyper OD fix
30 pd R hyper OS fix

History

34 year old female

Vision: OD 20/25, OS 20/70

Refraction: OD -0.5 -0.50 x 90 degrees
OS -0.50 sph

This woman has had a life long exotropia which has increased in the past 5 years. She would like to improve her appearance and is eager to have surgical correction for the exodeviation.

Comment

This is a large angle with, an 'X' pattern and the patient also has DVD. The DVD is manifest and the patient states that this bothers her. A possible surgical approach is the following:

- 1) Bilateral lateral recession 8.0 mm
- 2) Vessel sparing tuck of the left medial rectus (6.0 mm)
- 3) Bilateral superior rectus recession 6 mm OD and 5.0 mm OS)

The medial rectus tuck is suggested to avoid severing the anterior ciliary vessels of three rectus muscles in one eye.(see p. 211) An adjustable suture could also be added to the recession of the left lateral rectus.

CASE 23: 'A' pattern esotropia with DVD



Measurements

20 pd XT - up
 5 pd XT - primary
 25 pd XT - down
 DVD both eyes
 OS >> than OD

DR0003

History

5 year old boy
 Vision: OD 20/25, OS 20/25
 Refraction: OD +2.00 sph
 OS +2.00 sph

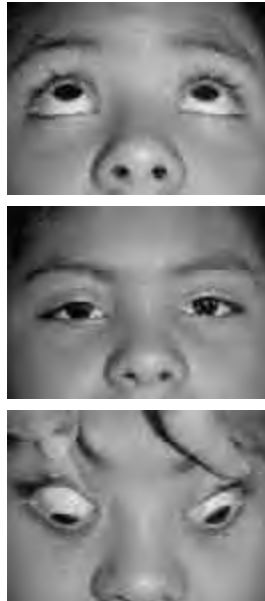
This child has had an esodeviation noted by the parents since about for months of age. He demonstrates a mild 'A' pattern and has a left hyperdeviation that behaves like dissociated vertical deviation (DVD). The right eye is said to also demonstrate a hyperdeviation but only under cover, a small amount, and with a rapid recovery when the cover is removed. This could not be captured with a picture. In contrast, the left hyperdeviation is becoming manifest more often according to the parents.

Comment

This patient presents a challenge when it comes to arriving at a plan for surgery. The primary position deviation is small, hardly noticeable and the DVD seems to be manifest in only one eye with the other eye never being seen up except under cover and then only a small amount. A logical plan would be:

- 1) Move both medial rectus muscles up 3/4 muscle width without recession (being careful to offset any resection effect resulting from suture placement) or move both lateral recti down taking the same precaution.
 - 2) Recess the left superior rectus 4.0 to 5.0 mm.
- Watch for a manifest hyperdeviation from the DVD occurring later in the right eye.

CASE 24: 'A' pattern



GUM0039

Measurements

ortho - up
ortho - primary
50 pd XT - down

History

9 year old boy

Vision: OD 20/30, OS 20/30

Refraction: OD +2.25 -1.00 x 180 degrees
OS +1.75 -1.25 x 180 degrees

Fuses: stereo fly (3,000 sec.)

This boy is having difficulty in school with reading and doing work at the board. His handwriting is said to be 'terrible'. The parents deny any abnormal head posture. He was not observed at this examination to assume a chin down posture that would be expected in this type of strabismus. There is what is described as overaction of the superior obliques. The boy is otherwise healthy and there is no family history of strabismus.

Comment

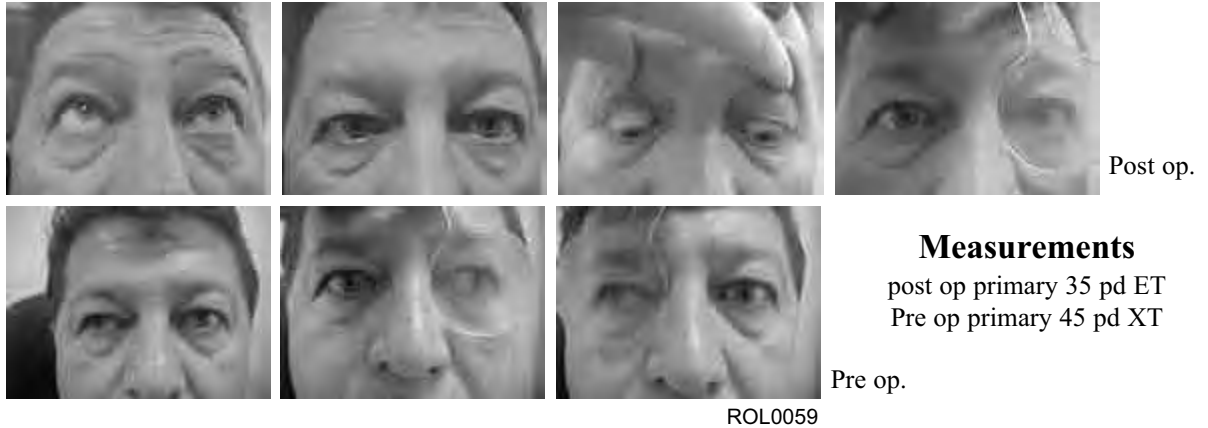A patient like this who has some fusion but who is very troubled by an 'A' pattern with 'overaction' of the superior obliques raises the question, "is it safe to weaken the superior obliques in a fusing patient?"

This can be done, but it could be risky because it is difficult to perform symmetrical weakening of the superior oblique. There is always the chance of creating a postoperative vertical deviation that would spoil fusion. In this case the two choices for surgery are;

- 1) Down shift of the lateral recti without recession
 - 2) Bilateral weakening of the superior obliques
- Another option that I have not done is bilateral nasalward shift of the inferior rectus muscles.

This case differs from case 59 in chapter 16 in that the boy is having a great deal of trouble in school.

CASE 25: Consecutive esotropia



Measurements

post op primary 35 pd ET
Pre op primary 45 pd XT

History

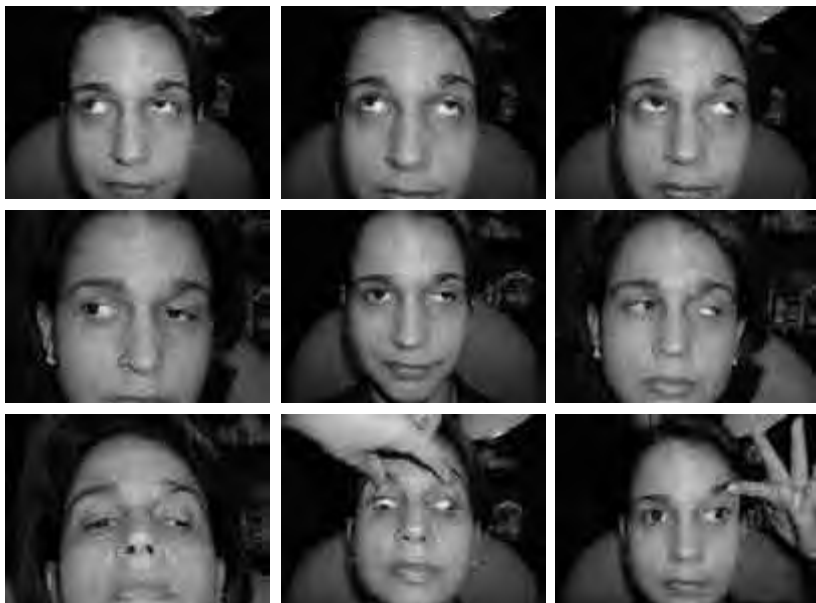42 year old male
Vision: OD 20/30, OS 20/30
Refraction: OD +1.25
OS +0.75

This man has a history of what appears to be congenital esotropia. He had a bimedian rectus recession at age 22. Because of a residual esotropia he later underwent bilateral lateral rectus resection. This resulted in a large angle consecutive exotropia. Because of apparent thin sclera medially a bilateral lateral rectus recession (of the previously resected muscles) was done. The right lateral rectus was recessed 10.0 mm and the left lateral rectus was recessed 7.0 mm. This resulted in 35 prism diopters of esotropia. The patient (and the surgeon) are eager to have the eyes aligned.

Comment

The surgery for the consecutive exotropia avoided the medial recti because of what was thought to be thin sclera. This surgery for the consecutive esotropia could do likewise. A surgical option for this case would be advancement of the of previously resected and later recessed lateral recti. This advancement could be done with a tandem adjustable suture placed on one of the advanced muscles. My recommendation is that the lateral rectus muscles be advanced 6.0 or 7.0 mm. With the tandem adjustable suture, the muscle would be 'strengthened' the maximum amount that could be anticipated. The second or 'tandem' suture could be used to 'weaken' the muscle by 'hanging it back' if needed.

CASE 26: Exotropia and hypertropia in a 'blind' eye



DR-Aybar0003

Measurements

30 pd XT, 10 L hyper - up
 35 pd XT 25 L hyper -
 primary
 55 pd XT 25 L hyper - down

History

42 year old female
 Vision: OD 20/20, OD light perception
 Refraction: OD plano
 OS +8.50

This woman had a traumatic cataract of the left eye removed as a child. She never regained good vision. Shortly after she had an 'intraocular tumor' removed from the superior aspect of the left eye. Now she has an exotropia and hypertropia of the left eye. She would like to have her eyes 'straightened.'

Comment

Aligning a non-seeing eye is a legitimate undertaking using the dictum 'every humans has the right to look like a human'. Surgery should be restricted whenever possible to the poorer seeing eye. In this case it is wise to avoid the left superior rectus because of concerns about thin retina as a result of prior tumor surgery in the area. A logical choice for surgery would be:

- 1) Recession of the left lateral rectus 8.0 mm with 1/2 muscle width down shift
- 2) Resection of the left medial rectus 8.0 mm with 1/2 muscle width downshift
- 3) Left inferior oblique weakening (myectomy or recession)

The downshift of both of the horizontal recti in the left eye will have some effect on lowering the hyper deviated left eye. The inferior oblique is not the most effective muscle to weaken for treating this kind of hyperdeviation, but there is very little downside in this case. If needed a left levator resection could be done after the results of the muscle surgery are known.

CASE 27: 'A' pattern exotropia, mongoloid fissures



DRR0035

Measurements

60 pd XT - up
70 pd XT - primary
95 pd XT - down

History

29 year old male
Vision: OD 20/25, OD 20/20
Refraction: OD +2.00 -1.50 x 15
OS +1.50 -1.25 x 180

This man has a life long history of exotropia. He had surgery for this at age 3 years but there is no record of what was done. He would like to have his eyes straightened now. He has no double vision or other visual symptoms.

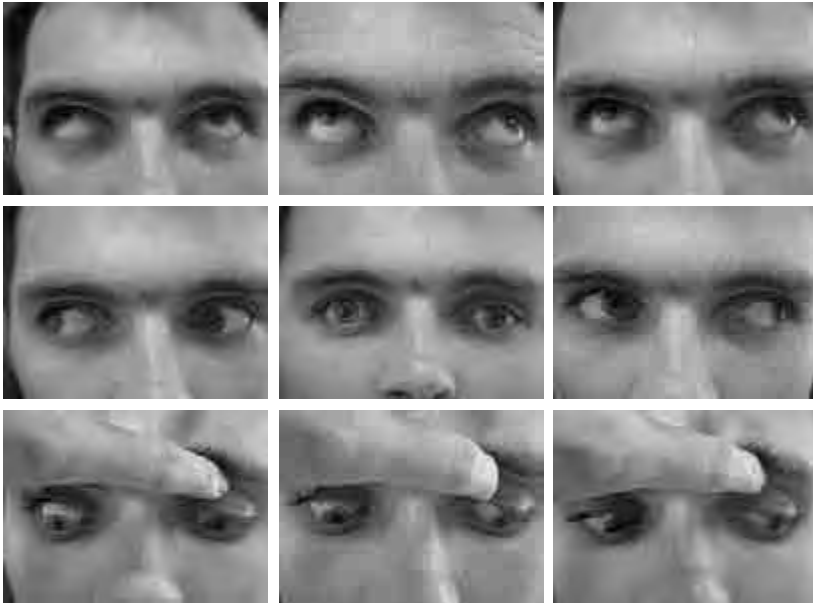Comment

The obvious mongoloid fissures suggest the possibility of pulley heterotopy contributing to the 'A' pattern. Disregarding the first surgery, at least for now, a logical surgical plan would be the following:

- 1) Recess both lateral rectus muscles 8.0 mm with 1/2 muscle width downshift
- 2) Resect both medial recti 8.0 mm width 1/2 muscle width upshift.

One of the lateral rectus muscles could be placed on an adjustable suture.

CASE 28: Consecutive exotropia



ROD0047

Measurements

60 pd XT - up
45 pd XT - primary
65 pd XT - down

History

27 year old male

Vision: OD 20/25, OS 20/30

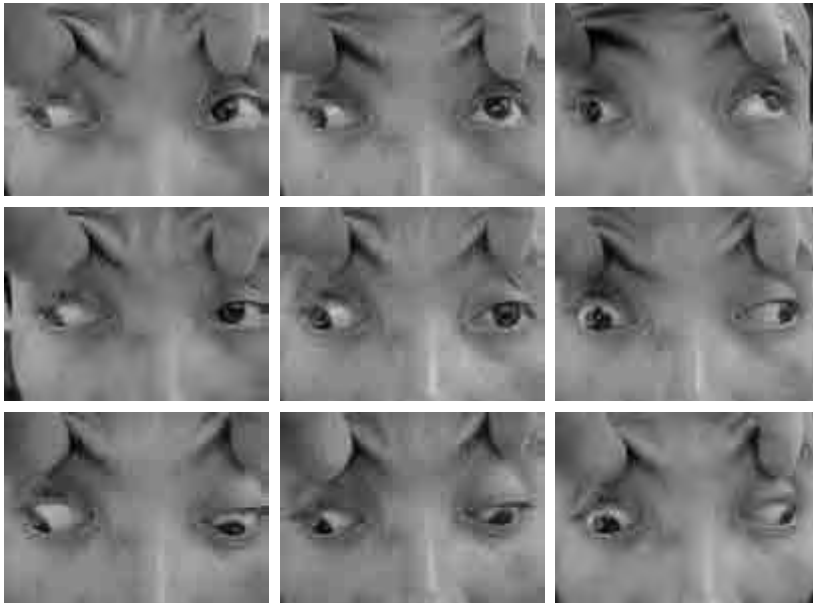Refraction: OD plano +0.75 x 90 degrees
OS plano +0.50 x 80 degrees

This man had surgery for congenial esotropia at age 4 years according to history obtained from the patient. Scars over the medial aspect of the globe support this. He denies double vision. Adduction is limited in both eyes, more so in the right. The patient would like to have his eyes aligned and is eager for surgery.

Comment

The best option for surgery in a case like this is advancement and resection of the previously recessed medial rectus muscles. This presents the challenge of finding the muscles that in this case are likely to be easily found because adduction is present though diminished. When advancing previously recessed muscles, it is the rule to find them 'stiff' making it impossible to pull them up to the original insertion. Given this, it is useful to combine resection with advancement arriving at a surgical 'number' that is a combination of the two. In this case; for example, 8.0 mm of surgery on each medial rectus muscle could mean a 5 mm advancement and a 3.0 mm resection. In this case it might be prudent to place one of the muscles on an adjustable suture.

CASE 29: Third nerve palsy



HAN0148

Measurements

60 pd XT and
15 pd R hypo -
primary position

History

30 year old male
Vision: OD 20/20, OS 20/20
Refraction: OD plano
OS plano

This man sustained closed head injury in an auto accident 9 months earlier. He was comatose for 2 days. His motility has remained stable since that time with a large right exotropia and hypotropia, with ptosis of the right upper lid. The right pupil responds to light and accommodation. When he raises his lid, he sees double. The Bell phenomenon is absent.

Comment

This case demonstrates complete third nerve palsy with pupil sparing and without aberrant regeneration. The only extraocular muscles functioning in the right eye are the lateral rectus and the superior oblique. The action of these muscles drives the eye downward with incycloduction and out. Surgical treatment would include:

- 1) Large recession of the right lateral rectus of 10+mm, disinsertion, or attachment to the lateral periostium
- 2) Transposition of the right superior oblique to the superior border of the insertion of the right medial rectus holding the eye in slight adduction and done without fracture of the trochlea.
- 3) Brow suspension of the right upper lid, under-correcting to avoid corneal exposure.

CASE 30: Congenital third nerve palsy



HAN0172

Measurements

35 pd XT
15 pd L Hypo

History

11 year old girl
Vision: OD 20/20, OS 20/200
Refraction: OD plano
OS plano

This girl has had the left eye down and out with ptosis since birth. The pupil in the left eye remains reactive. A dense amblyopia is present in the left eye. No prior treatment for the amblyopia had been given. The lids are being held up to show motility in down gaze. No aberrant regeneration of the levator or the other extraocular muscle is seen.

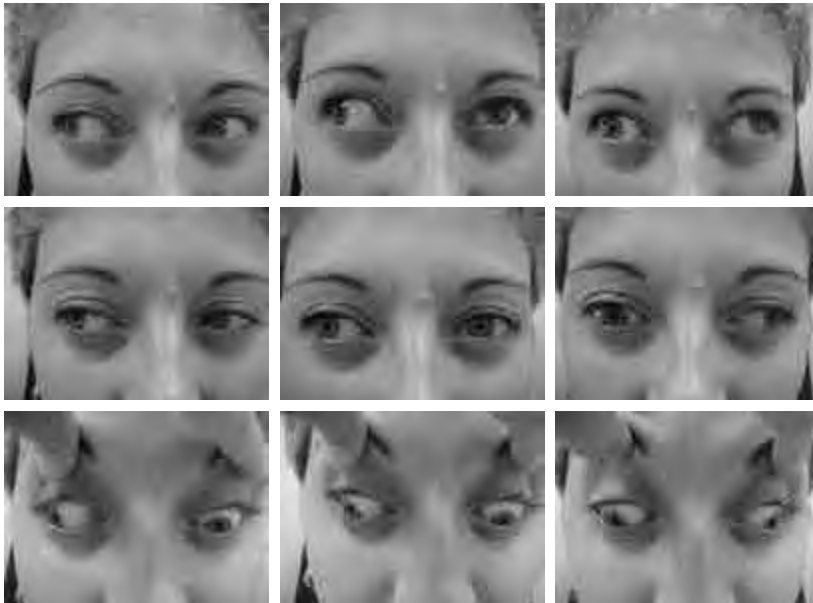Comment

An attempt at patching the right eye for treatment of the amblyopia would be a good place to start. This would require that the girl assume a chin up and face turn to the right. However, this treatment has a possible downside. At present she has no diplopia. If amblyopia treatment improves vision in the left eye sufficiently to make it difficult to suppress, then the patient will be bothered by diplopia when her eyes are better aligned and the left upper lid is raised at surgery.

Surgery in this case would be:

- 1) Maximum recession of the left lateral rectus
- 2) Transfer of the left superior oblique tendon to the superior border of the left medial rectus without fracture of the trochlea.
- 3) frontalis suspension of the left upper lid in a slightly under corrected position to protect the left cornea.

CASE 31: Acquired third nerve palsy



ROL0089

Measurements

45 pd XT
5 R hypo primary

History

30 year old female
Vision: OD 20/25, OS 20/20
Refraction: OD plano -1.50 x 10
OS plano -1.50 x 10

This woman suffered a cerebral hemorrhage when giving birth one year ago. Her right eye is 'down and out' with evidence of only the right lateral and right superior oblique muscles functioning. The right pupil is slightly dilated, but the right levator palpebrae seems to function normally. This woman is bothered by constant diplopia. She has had no other signs or symptoms from the apparent 'stroke'. There is no evidence of aberrant regeneration.

Comment

In this case of partial third nerve palsy without aberrant regeneration, there appears to be some function of the right medial rectus. For this reason the following could be reasonable surgical option:

- 1) Large recession of the right lateral rectus
- 2) Large resection of the right medial rectus
- 3) Tenectomy of the right superior oblique

In addition both the medial and lateral rectus muscles could be shifted up 1/2 muscle width.

CASE 32: Bilateral congenital third nerve palsy



HANOI0035

Measurements

80 pd XT

History

20year old male
Vision: OD 20/20, OS 20/20
Refraction: OD -0.50
OS -0.75

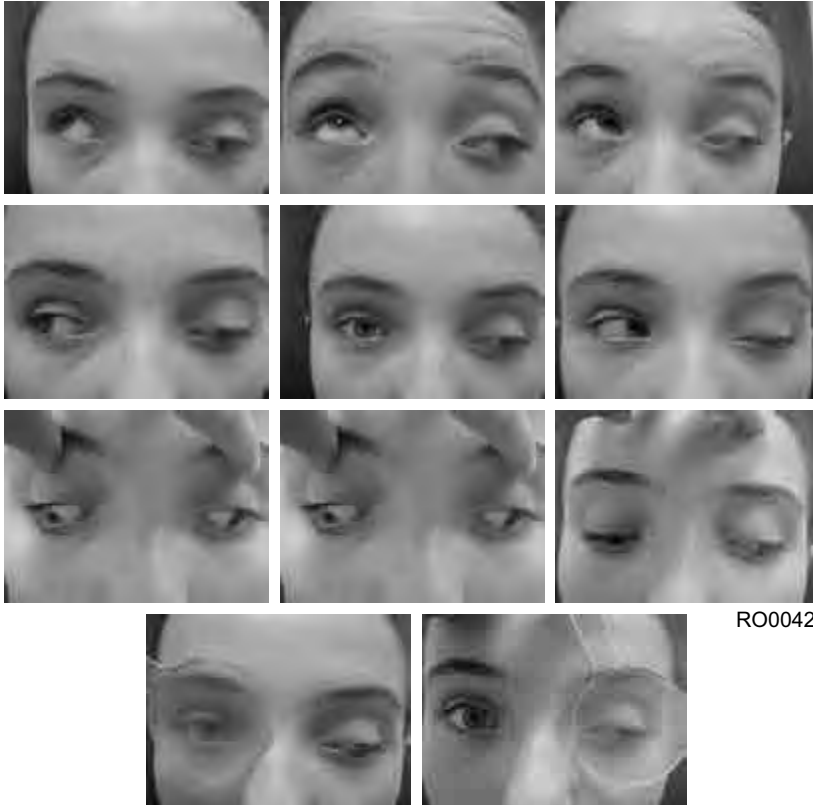This man was presented for consultation with a presumptive diagnosis of bilateral third nerve palsy with sparing of the lids and pupils.

Comment

With absent adduction, elevation, and depression even without lid and pupil involvement, this appears to be bilateral congenital third nerve palsy. However, since there appears to be telecanthus present, the inter canthal distance should be measured. If this distance is more than 1/2 the value of the pupillary distance, telecanthus with the strong possibility of a midline defect can be suspected. Imaging with a CT scan should be obtained. If a midline defect were seen, it would not necessarily change the treatment, but it is information that should be known.

Surgery in this case would be large bilateral lateral rectus recession and bilateral superior oblique tendon transfer to the medial rectus insertion without trochlear fracture. However this would depend on findings after additional work up that could possibly demonstrate missing muscles and more.

CASE 33: Acquired third nerve palsy



Measurements

50 pd XT
20 L Hypo

History

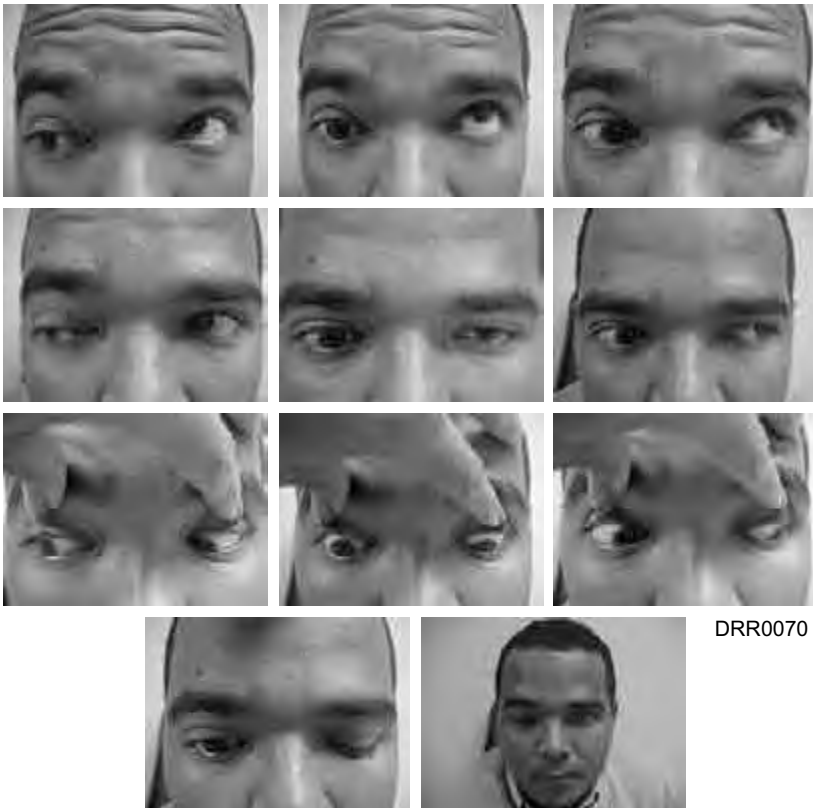14 year old girl
Vision: OD20/20, OS 20/40
Refraction: OD -0.50
OS -1.25

This girl suffered encephalitis at age 1 year. After that she developed a left third nerve palsy that has remained unchanged until the present. She denies diplopia, but has retained good vision in the left eye.

Comment

This is another example of third nerve palsy with the typical findings of the affected eye being down and out with ptosis and in this case a dilated pupil. This girl is fortunate to have both good vision in the involved eye and no diplopia. As in other cases described, this girl would benefit from a large left lateral rectus recession, transfer of the left superior oblique to the medial rectus insertion without fracture of the trochlea, and frontalis suspension of the left upper lid with a slight under correction to protect the cornea.

CASE 34: Traumatic third nerve palsy



Measurements

10 pd ET
15 R hypo primary

History

34 year old male
Vision: OD 20/20, OS 20/15
Refraction: OD plano +1.25 x 90 degrees
OS plano +1.25 x 90 degrees

This man suffered severe head trauma in a motor vehicle accident. He presents with a right eye that is down, but not necessarily out! Some of the features of a third nerve palsy are present. The right eye is hypotropic, elevation is restricted, there is some ptosis, and the right pupil is dilated. Also there appears to be some lid elevation of the right eye on down gaze. However the right eye adducts well, and there is more depression than can be attributed to the superior oblique acting as the sole right eye depressor.

Comment

This case will definitely benefit from a CT scan of the orbit. This is necessary to determine whether or not a blowout fracture is present. This could account for the limited elevation. There also remains the possibility of there being two problems, a partial third nerve palsy and a blowout fracture of the right orbit. No treatment plan can be formulated until further evaluation is completed.

CASE 35: Class I superior oblique palsy



History

11 year old female
 Vision: OD 20/20, OS 20/20
 Refraction: OD +1.50
 OS +1.50
 Motility:

↖	25 LHT*	10 LHT*	8 LHT*	↗
←	20 LHT	15 LHT	10 LHT	→
↙	8 LHT	5 LHT	6 LHT	↘

* A moderate XT measured in upper fields

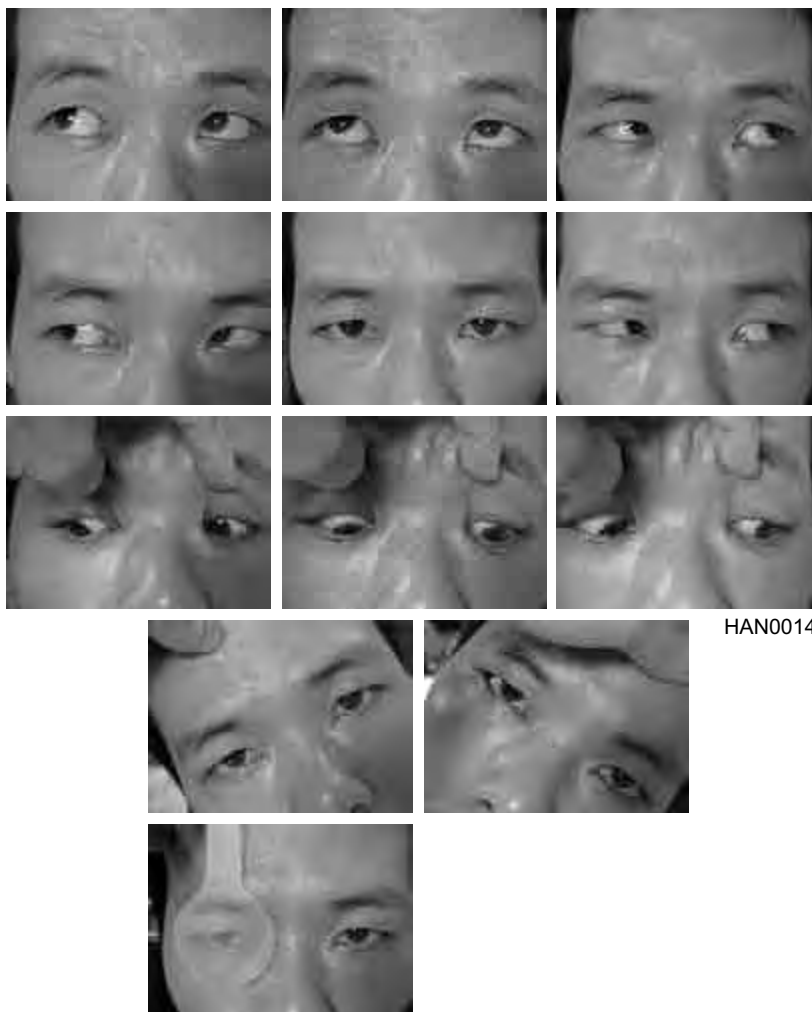Right Tilt 10 LHT
Left Tilt 20 LHT

Head posture: right head tilt
 Fusion: stereo acuity 100 sec.
 Double maddox rod: no torsion

Comment

In cases of class I superior oblique palsy with a maximum hyperdeviation of no greater than 25 prism diopters weakening of the antagonist inferior oblique is effective. The left hyperdeviation in left head tilt, picture 11 (positive Bielschowsky test) is difficult to appreciate in the pictures because the patient is fixing with the left eye resulting in a less noticeable right hypotropia with the lid following the globe to further obscure the difference in the level of the eyes.

CASE 36: Class II superior oblique palsy



HAN0014

History

30 year old male
 Vision: OD 20/20, OS 20/20
 Refraction: OD plano
 OS plano
 Motility:

↖	5 LHT	5 LHT	0	↗
←	15 LHT	20 LHT	5 LHT	→
↙	20 LHT	20 LHT	20 LHT	↘

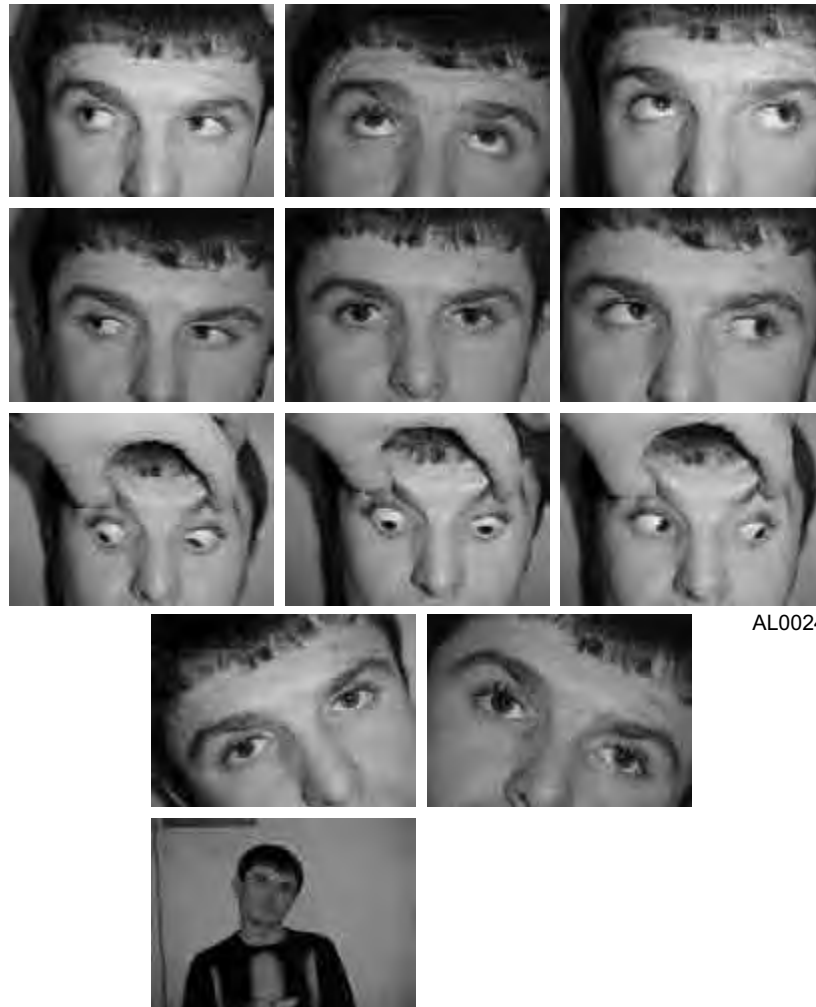Right Tilt 2 LHT
Left Tilt 10 LHT

Head posture: right head tilt
 Fusion: stereo acuity 40 seconds
 Double maddox rod: 5° excyclo OS

Comment

This man began noticing occasional diplopia one year ago. He denies any trauma. His health is good and his eye examination is otherwise normal. The most significant motility feature is underaction of the left superior oblique. The greatest vertical deviation is in the field of action of the paretic superior oblique. This results in a Class II superior oblique palsy. If at surgery a lax left superior oblique tendon were found, a small tuck could be done. If the superior oblique traction test were normal, a weakening of the yoke to the left superior oblique, the right inferior rectus could be effective.

CASE 37: Class III superior oblique palsy

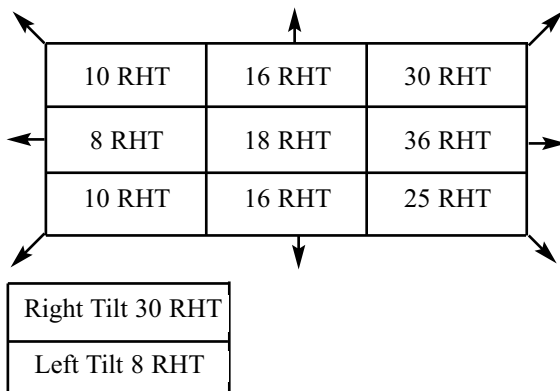


AL0024

a History

15 year old male
 Vision: OD 20/20, OS 20/20
 Refraction: OD +1.00
 OS +.75 (no glasses worn)

Motility:

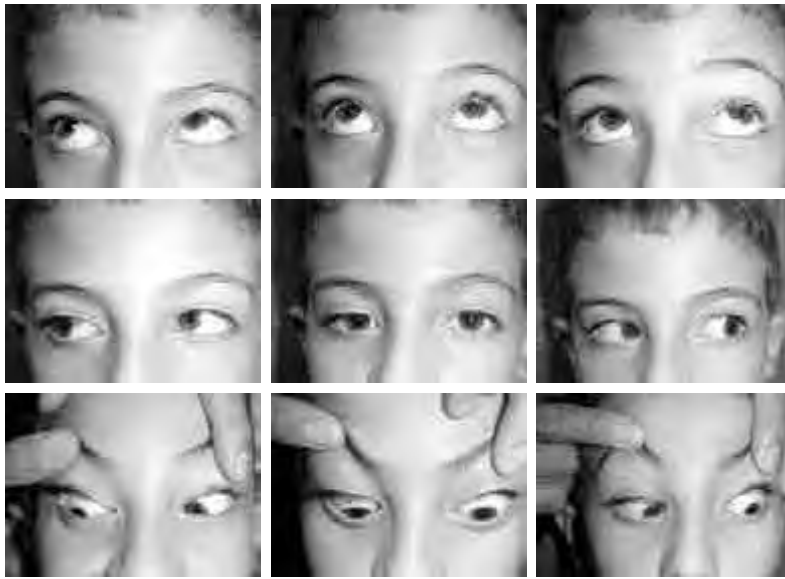

Comment

This patient had significant head trauma one year ago with a brief period of loss of consciousness. After that he noticed frequent double vision and increasing head tilt. His condition has remained stable for the last six months. With a vertical deviation largest in the fields opposite the paretic eye; that is, in left gaze in the case of a right superior oblique palsy, a Class III superior oblique palsy is diagnosed. Since the deviation is greater than 25 prism diopters in the field of greatest deviation two vertical muscles need to be treated. In this case the right inferior oblique would be weakened along with either a right superior oblique tuck (very unlikely in the case of an acquired superior oblique palsy because the tendon is expected to be normal) or a left inferior rectus recession. The latter being the yoke of the paretic right superior oblique.

Head posture: large left head tilt with chin depression
 Fusion: stereo acuity 3000 seconds with head tilt
 Double maddox rod: 10° excyclo OD

CASE 38: Class III superior oblique palsy



Congenital absence of the left superior oblique



History

9 year old male
 Vision: OD 20/20, OS 20/20
 Refraction: OD plano +.75 x 90 degrees
 OS plano

Motility:

	↑			
↙	20 LHT*	15 LHT	10 LHT	↘
←	40 LHT	30 LHT	23 LHT	→
↙	35 LHT	35 LHT	25 LHT	↘
	↓			

* A small ET was measured in all fields


Right Tilt 0
Left Tilt 10 LHT

Head posture: large right head tilt - chin depression
 Facial asymmetry: much fuller face on the left
 Fusion: nil
 Double maddox rod: no torsion

Comment

This nine year old male had a life long history of a large right tilt. He also was noted by his family to have a much fuller face on the left. The size of the deviation, the facial asymmetry and the pronounced head tilt led to the suspicion that there may be an absent left superior oblique tendon. A coronal CT confirmed this. Note that the superior oblique is seen in the right orbit but not the left. This finding was later confirmed at surgery. The pattern of the deviation indicates a Class III or possibly IV superior oblique palsy. Because there is no superior oblique to strengthen on the left, surgery for this deviation would consist of weakening the left inferior oblique, and recession of the right inferior rectus with the possible addition of a small to moderate left superior rectus recession.

CASE 39: Class III superior oblique palsy



History

12 year old female
 Vision: OD 20/20, OS 20/35
 Refraction: OD + 2.00
 OS + 2.00

Motility:

↖	28 LHT*	12 LHT	12 LHT	↗
←	25 LHT	18 LHT	6 LHT	→
↙	20 LHT	10 LHT	4 LHT	↘

* A small XT in upgaze

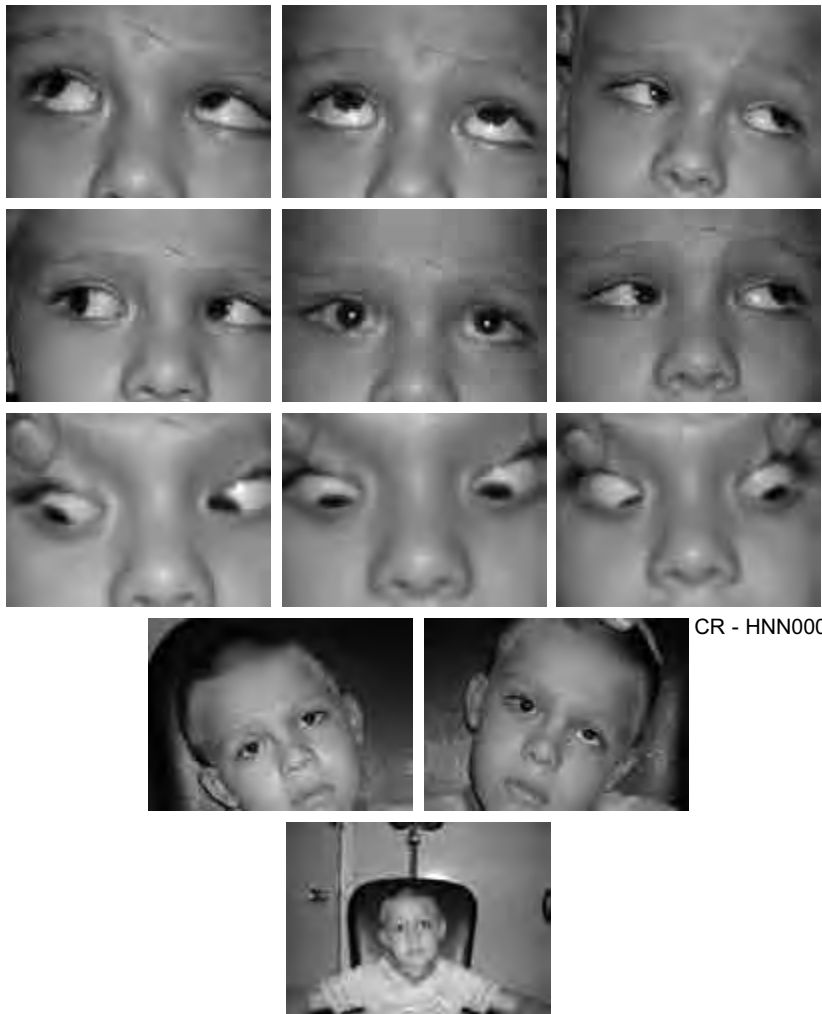
Right Tilt 5 LHT
Left Tilt 20 LHT

Head posture: right tilt
 Fusion: stereo acuity 3000 seconds
 Double maddox rod: no torsion

Comment

With maximum deviation greater than 25 prism diopters and the larger deviations in the field of both the paretic superior oblique and the antagonist inferior oblique this patient has a class III superior oblique palsy requiring two muscle surgery. The left inferior oblique would be weakened along with a tuck of the left superior oblique if the tendon were found to be loose on traction testing or right inferior rectus weakening if the left superior traction test were normal.

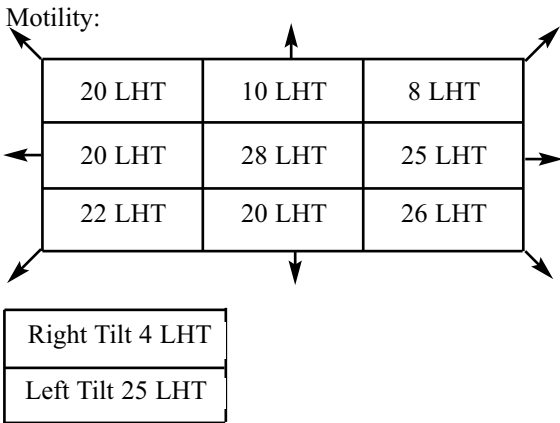
CASE 40: Class IV superior oblique palsy



CR - HNN0004

History

6 year old male
 Vision: OD 20/30, OS 20/30
 Refraction: OD +1.00 +.50 x 90
 OS +1.00 +.50 x 90 (no glasses worn)

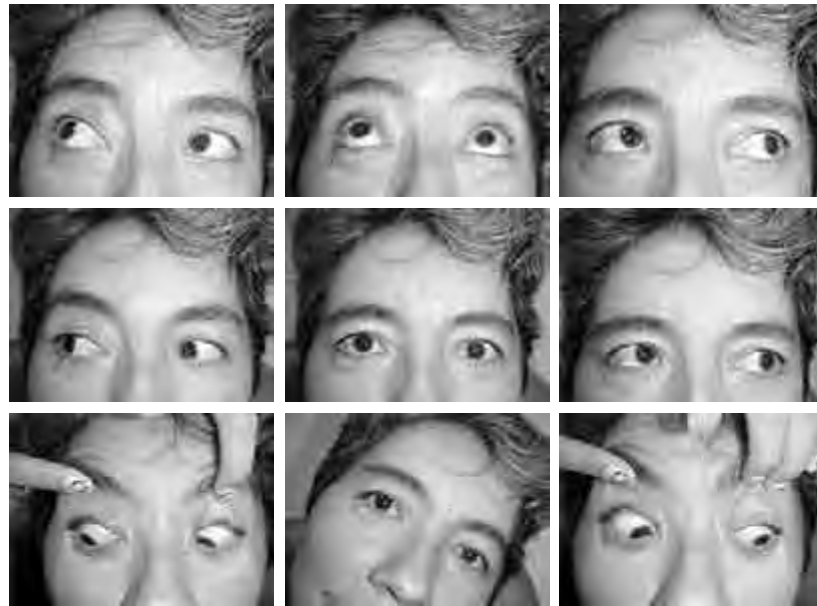

Comment

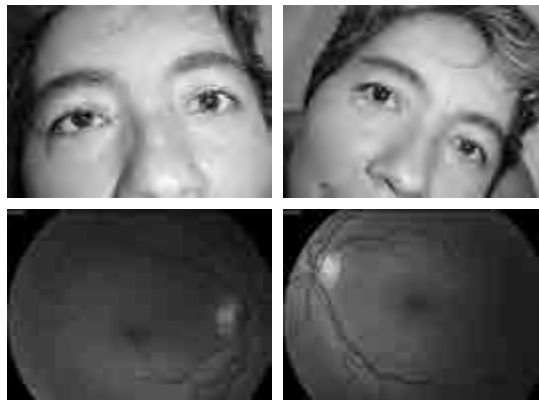
The pattern of this deviation is that the larger left hyper is in the entire right field plus a large deviation is present in down left gaze. This latter is due to contraction of the left superior rectus which is the yoke of the right inferior oblique which is the antagonist to the paretic right superior oblique. In this case the deviation is treated by weakening the left inferior oblique to treat the deviation in right gaze plus a recession of the left superior rectus to deal with the hyperdeviation in the down left field. This pattern of superior oblique palsy was first described by Jampolsky who pointed out that the contracted superior rectus created 'fixation duress' in the antagonist ipsilateral inferior rectus which by Hering's law influences the normal superior oblique to overact. The important thing to remember in this pattern of superior oblique palsy is that the 'overacting' superior oblique should not be weakened!

Head posture: right head tilt
 Fusion: stereo acuity 400 seconds
 Double maddox rod: no torsion

CASE 41: Class V superior oblique palsy



ECA0017



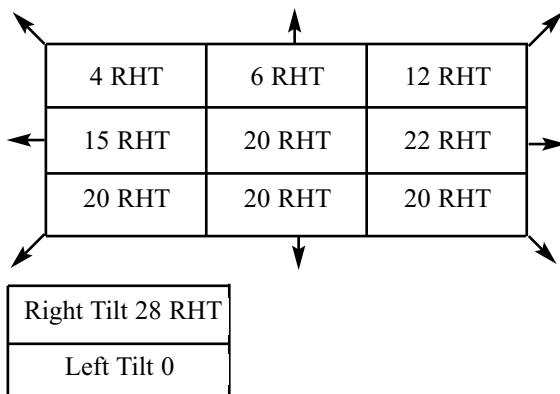
OD

OS - extorted globe

History

45 year old female
 Vision: OD 20/20, OS 20/25
 Refraction: OD $-0.25 +0.25 \times 95$ degrees
 OS $-0.50 +0.25 \times 75$ (no glasses worn)

Motility:

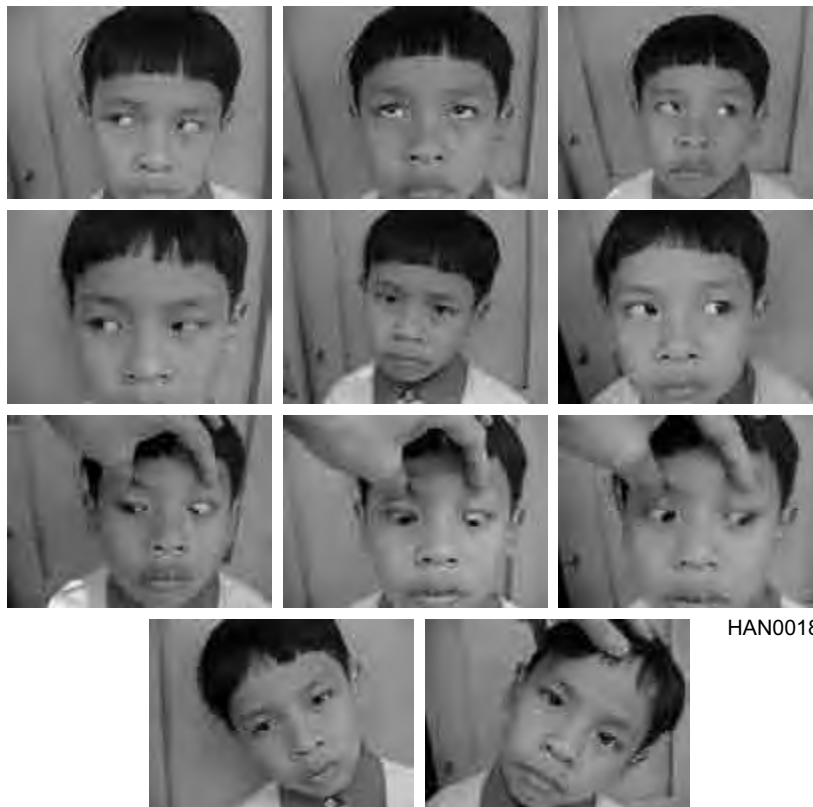


Head posture: left head tilt
 Fusion: stereo acuity 40 seconds
 Double maddox rod: 12° excyclo OS

Comment

This patient began noticing occasional diplopia over the past two years. She also has developed a chronic left head tilt. She fixates with her paretic right eye. This appears to be producing fundus torsion expressed as excyclotorsion of the left fundus. With the greater vertical deviation in the lower fields, this is closest to a Class V superior oblique palsy. It could be treated with a right superior rectus recession and a recession of the left inferior rectus could be added. As an alternative, an anterior and lateral shift of the the anterior fibers of the right superior oblique could be done with a right superior rectus recession. Treatment is aimed at dealing with a hypertropia in both the right and left fields of down gaze. Also with no hypertropia in left head tilt and significant torsion it is a good idea to be watching for a 'masked' bilateral superior oblique palsy.

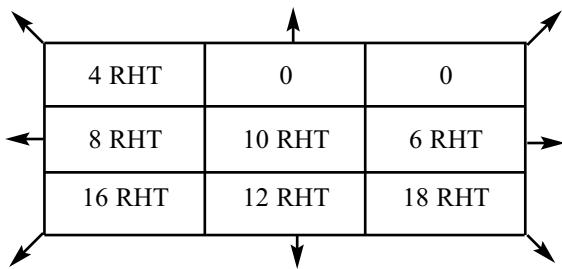
CASE 42: Class V superior oblique palsy



HAN0018

History

9 year old male
 Vision: OD 20/20, OS 20/50
 Refraction: OD -.75
 OS -5.00 +3.50 x 65 degrees
 Motility:



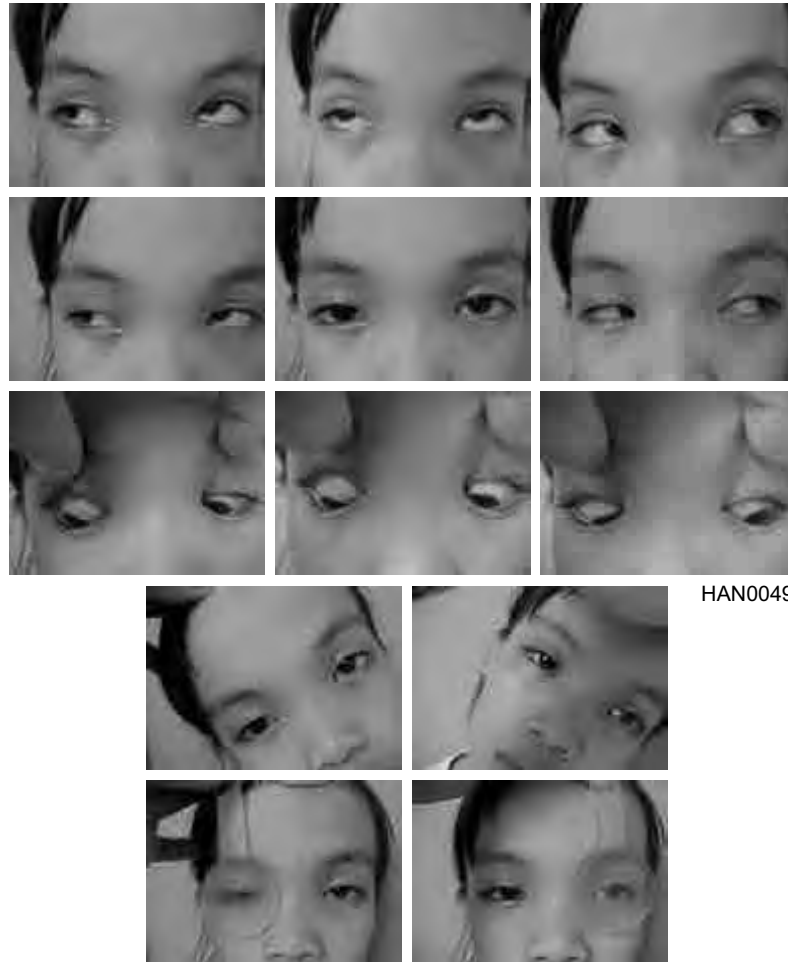Right Tilt 18 RHT
Left Tilt 0

Head posture: left head tilt
 Fusion: stereo acuity 100 seconds
 Double maddox rod: no torsion

Comment

This patient demonstrates a pattern of hyperopia with the largest deviation measured on down gaze or as it has been referred to ‘across the bottom’. This is called a Class V superior oblique palsy. Effective treatment of this class of deviation starts with recession of the ipsilateral superior rectus that in this case is the right superior rectus. Then either tuck of a loose superior oblique tendon, on the right in this case, or if the paretic superior oblique has a normal tendon, a recession of the yoke left inferior rectus.

CASE 43: Class III superior oblique palsy with pseudo ptosis (inhibitional palsy of the contralateral antagonist)



HAN0049

History

14 year old female
 Vision: OD 20/20, OS 20/20
 Refraction: OD plano
 OS plano
 Motility:

	↖	↑	↗
	20 LHT	20 LHT	10 LHT
←	18 LHT	16 LHT	6 LHT
	16 LHT	8 LHT	4 LHT
	↘	↓	↙
	Right Tilt 0		
	Left Tilt 12 LHT		

Head posture: right head tilt
 Fusion: nil
 Double maddox rod: 5° Right excyclo

Comment

The special feature of this case is that the patient appears to prefer the left eye or the eye with the paretic superior oblique for fixation. This results in more innervation to the paretic left superior oblique and by Hering's law the same robust innervation to the normal yoke, the right inferior rectus. This in turn causes excess inhibition to the antagonist of this yoke muscle which is the right superior rectus. This innervation level also dictates the innervation to the right levator palpebrae. Since this antagonist gets less innervation, a ptosis (or more correctly a pseudo ptosis) is present. This is called *inhibitional palsy of the contralateral antagonist*. The important lesson to remember is that fixing the motility defect automatically fixes the ptosis.

CASE 44: Superior oblique palsy - head posture normalized by successful surgery



HAN0085



HAN0114

History

9 year old male
 Vision: OD 20/25, OS 20/25
 Refraction: OD plano
 OS plano
 Fusion: stereo acuity 40 seconds
 Motility:

Pre-operative


	20 RHT	

Comment

The preoperative motility points to a right superior oblique palsy with a rather pronounced left head tilt as would be expected. In addition some facial asymmetry is present with the fuller face on the side of the paretic superior oblique, a finding 'with the rule'. Before the patient underwent surgery a question about the role of tight neck muscles on the head posture was discussed and correctly dismissed. A weakening procedure of the right inferior oblique was done.

The postoperative appearance of the patient shows essentially normal alignment. Only a slightly positive Bielschowsky test remains as evidenced by a small residual right hypertropia in right head tilt. But most important, the head posture is now normal. This confirms that the anomalous head posture was due to the vertical deviation and not due to a tight neck muscle.

CASE 45: Congenital superior oblique without facial asymmetry



History

10 year old female
 Vision: OD 20/20, OS 20/20
 Refraction: OD +1.00
 OS +1.00
 Fusion: stereo acuity 40 seconds
 Motility:

↖	25 LHT	10 LHT	5 LHT	↗
←	25 LHT	15 LHT	4 LHT	→
↙	20 LHT	5 LHT	0	↘

Comment

This girl demonstrates a typical class III left superior oblique palsy with the expected right head tilt. Her parents state that she has always demonstrated this head tilt. Her general health is excellent and her eye examination is otherwise normal. This is apparently a congenital superior oblique palsy, but this girl does not demonstrate facial asymmetry. She does on direct questioning admit to occasionally seeing images doubled vertically, but she can fuse the images readily. In a case like this with a hypertropia measuring 25 prism diopters at the maximum, that is in up right gaze, the patient can be treated effectively with a weakening of the left inferior oblique. A second surgery could be needed for an undercorrection many years in the future.

CASE 46: Congenital superior oblique with facial asymmetry and esotropia



ROL0006

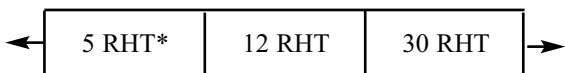History

4 year old female

Vision: Fixes and follows OU, no cooperation for optotypes

Refraction: OD +3.00 +1.00 x 10 degrees
 OS +3.50 +.75 x 90 degrees (wearing glasses)

Motility:



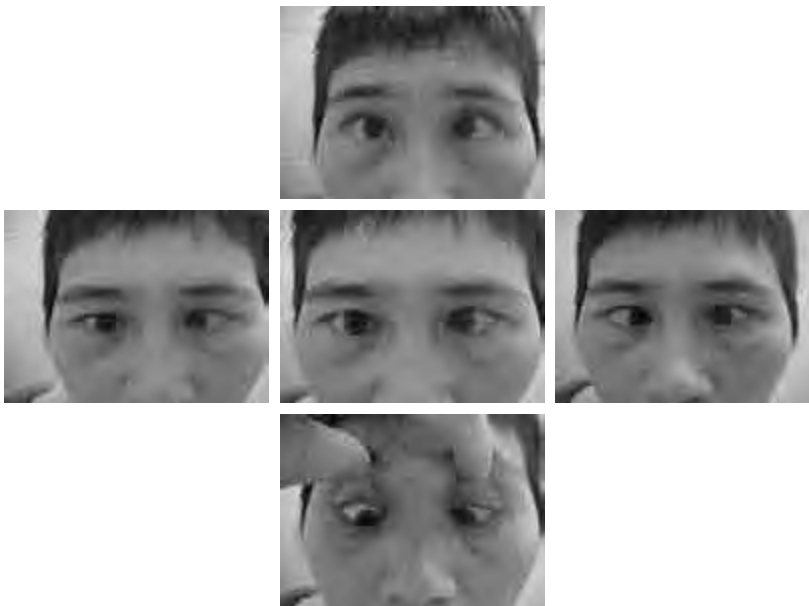
* A variable esotropia +/- 12

Double maddox rod: unable

Comment

A striking feature in this child is the facial asymmetry with a much larger cheek on the right side, the side of the paretic superior oblique. The esotropia suggests that this child does not have fusion and although a moderate left head tilt is present, it does not compare to the facial asymmetry. In a case like this it is especially important to determine the status of the superior oblique tendon. This is the type of patient where the tendon may be absent or extremely loose. This can be determined by a careful superior oblique traction test and confirmed by exploration of the superior oblique tendon at the time of surgery. Note in picture 3 the right hypertropia is manifested as a left hypotropia because the right eye is fixing.

CASE 47: Bilateral sixth nerve palsy



HAN0111

Measurements

70 pd ET - up
80 pd ET - primary
90 pd ET - down

History

46 year old female
Vision: OD 20/25, OS 20/40
Refraction: OD plano
OS plano

This is an example of complete bilateral sixth nerve palsy occurring after severe head trauma. This happened 18 months ago. The eyes have remained like this since the accident. The eyes are 'stuck' in convergence, (actually bilateral adduction) with no abduction. The eyes elevate and depress reasonably well indicating functioning of the vertical recti and obliques. The man has constant diplopia.

Comment

Treatment in this case would consist of:

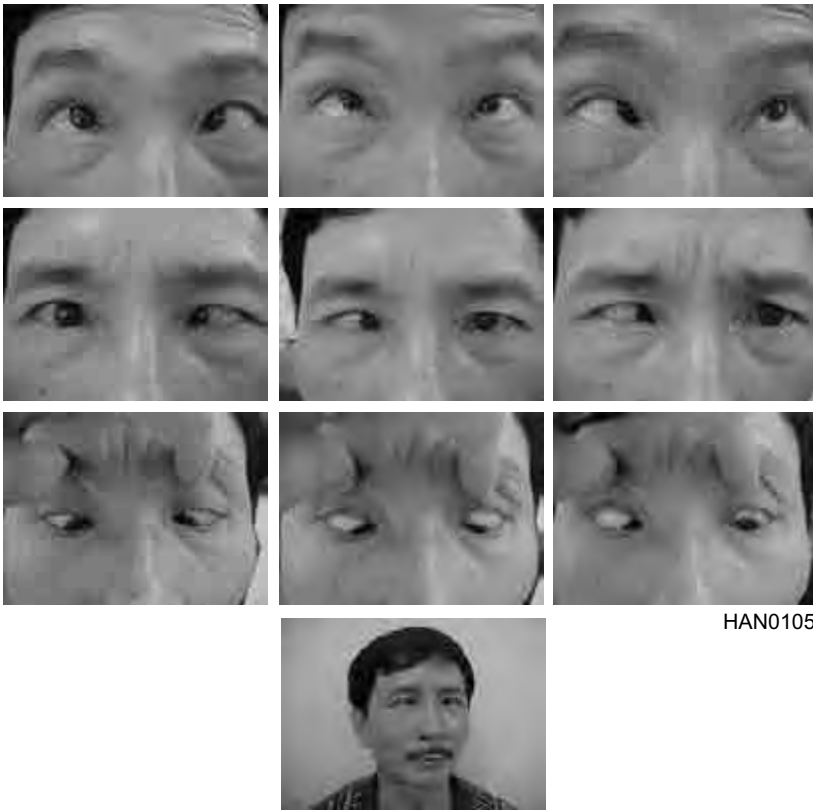
1) Bilateral transfer of the vertical rectus muscles to the lateral rectus muscle. The question would be, full tendon or half tendon? With or without augmentation?

2) Weakening of both medial rectus muscles.

The question would be, recession or Botox.

My choice would be large recession of both medial rectus muscles plus a half tendon transfer shifting the lateral half of the superior and inferior rectus muscles (or the full tendon) to the lateral rectus muscle. Augmentation as suggested by Foster could be done at the discretion of the surgeon. Bilateral sixth nerve palsy patients have diplopia even with otherwise good results from surgery. Because of both eyes being affected, a secondary deviation can occur in any field of gaze. At best a small field of single binocular vision can be gained. Suppression is a comfort for these patients. The decision to do a full tendon or a half tendon transfer would depend on the surgeon's concerns about anterior segment ischemia occurring since only one anterior ciliary artery, that in the lateral rectus, would remain.

CASE 48: Bilateral sixth nerve palsy



Measurements
60 pd ET primary

History

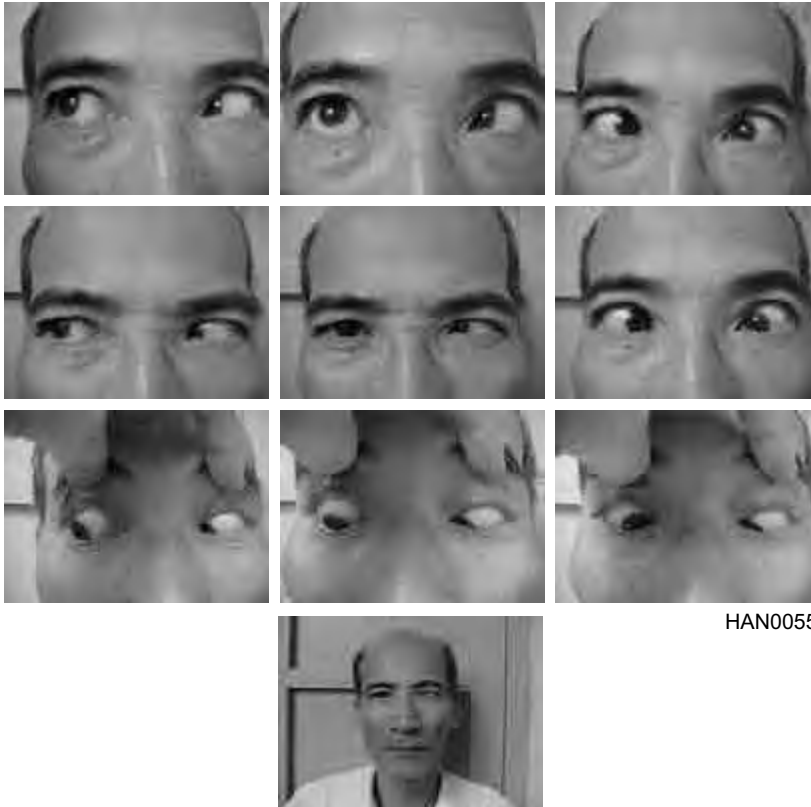46 year old male
Vision: OD 20/25, OS 20/20
Refraction: OD +0.75
OS +1.00

This man sustained bilateral sixth nerve palsy after closed head trauma. The right eye is more severely affected than the left. Trauma occurred more than a year ago. The condition of the eyes has remained stable for nearly a year. The right eye remains in the adducted position even in full dextroversion. In contrast, the left eye is able to move out at least to the midline. Testing with saccadic velocity shows slightly brisker outward movement of the left eye in attempted abduction compared to the right. Generated force is nil to abduction in the right eye and a slight tug is felt in the left eye on attempted abduction.

Comment

This man could be treated with a muscle transfer of the right eye moving the lateral half of the superior and inferior rectus muscles (or the full tendon) to the insertion of the right lateral rectus muscle with or without augmentation. The right medial rectus would be recessed. In the left eye, because some lateral rectus function remains, a large recession of the medial rectus and resection of the lateral rectus could be done. This man has a chance of having a slightly bigger 'window' of single binocular vision compared to a patient with bilateral total sixth nerve palsy. The decision to do a full tendon or a half tendon transfer would depend on the surgeons concerns about anterior segment ischemia occurring since only one anterior ciliary artery, that in the lateral rectus, would remain.

CASE 49: Right sixth nerve palsy



HAN0055

Measurements

RT ortho right
P 60 pd ET primary
LT 100 pd ET left

History

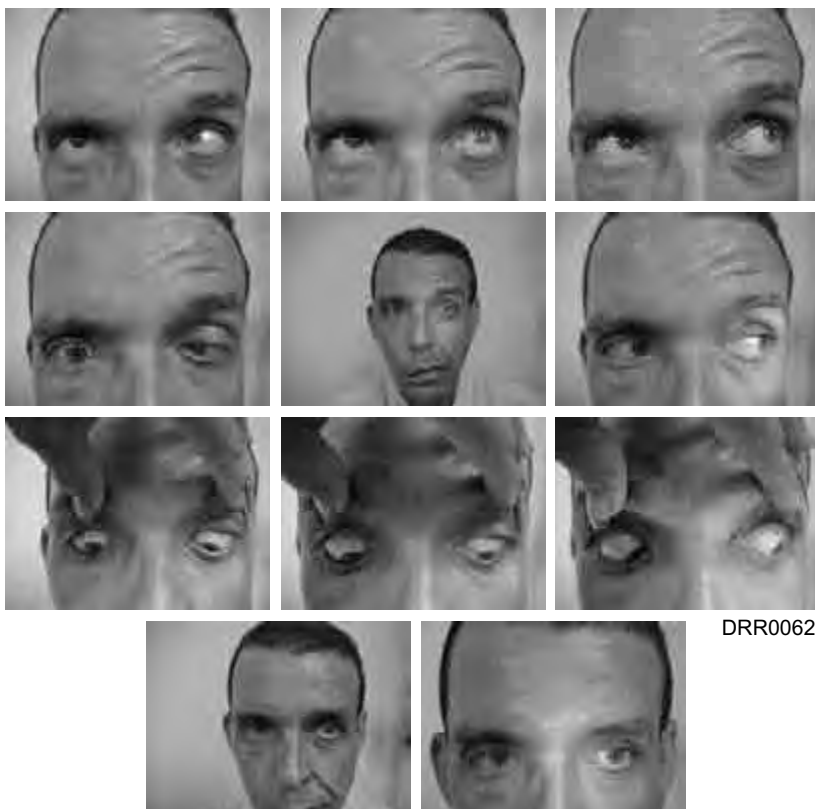This man suffered a carotid-cavernous sinus fistula three years ago. He was successfully treated but has a residual complete left sixth nerve palsy. He is eager to have his eyes realigned.

Comment

The chance of achieving a useful area of single binocular vision is greater in the case of unilateral palsy compared to one with bilateral involvement. In a case like this, a question that often arises is: should the antagonist medial rectus be injected with Botox in the acute stage to prevent contraction? While this has not been shown to contribute to better results for the treatment of sixth nerve palsy in the long run, I think that it is a treatment that should be considered if Botox is readily available.

Surgical treatment of this case would be transfer of the lateral half of the superior and inferior rectus muscles (or the full tendon) to the lateral rectus muscle with or without augmentation and recession of the left medial rectus muscle. The decision to do a full tendon or a half tendon transfer would depend on the surgeon's concern about anterior segment ischemia occurring since only one anterior ciliary artery, that in the lateral rectus, would remain.

CASE 50: Sixth and seventh nerve palsy



DRR0062

Measurements

20 pd ET primary

History

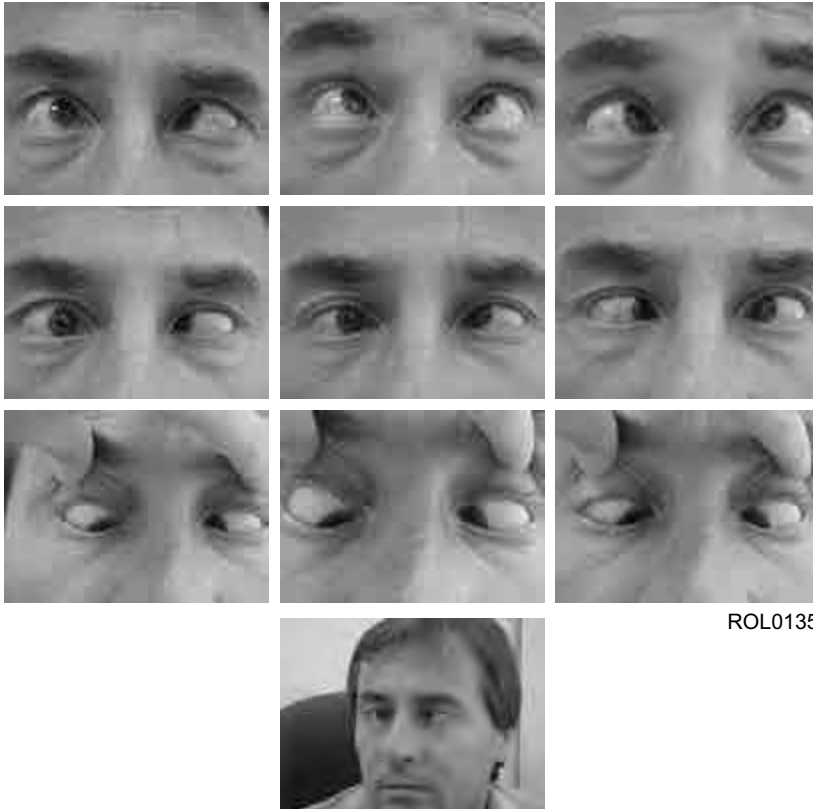42 year old male
Vision: OD 20/20, OS 20/40
Refraction: OD +1.00
OS +1.00

This man had removal of a benign brain tumor four months ago. He is recovering well but has had since surgery a right esotropia with inability to abduct the eye, and a drooping of his right face. This right sixth and seventh nerve palsy is improving slowly.

Comment

In a case like this it necessary to wait a sufficient time to determine how much recovery will occur. In the meantime precautions should be taken to protect the right cornea from exposure caused by the paralysis of the facial muscles responsible for closing the right eye and innervated by the seventh nerve. The right medial rectus could have been injected with Botox earlier to prevent right medial rectus contracture. After eight months to a year the condition can be considered stable and surgery can be done. The type of surgery would depend on results of forced ductions. If they are free, then a full tendon transfer shifting the right vertical recti to the right lateral rectus would be a good choice. If the medial rectus were found tight on passive duction testing, then this muscle would be recessed and a decision would be made to do a full or a half tendon shift depending on concerns regarding anterior segment ischemia. The right lid lag could be helped with a partial tarsorrhaphy or a more extensive facial muscle procedure by an oculo-plastic surgeon.

CASE 51: Bilateral sixth nerve palsy



Measurements

100 pd ET primary

History

44 year old male

Vision: OD 20/20, OS 20/30

Refraction: OD + 0.50

OS + 0.50 +0.75 x 80 degrees

This man suffered severe head trauma one year ago in an auto accident. His eyes have been crossed since the accident. He is not able to abduct the eyes even to the midline. He has diplopia but the images are so far apart that he is not particularly bothered. He turns his head to cross fixate because the eyes remain in full adduction.

Comment

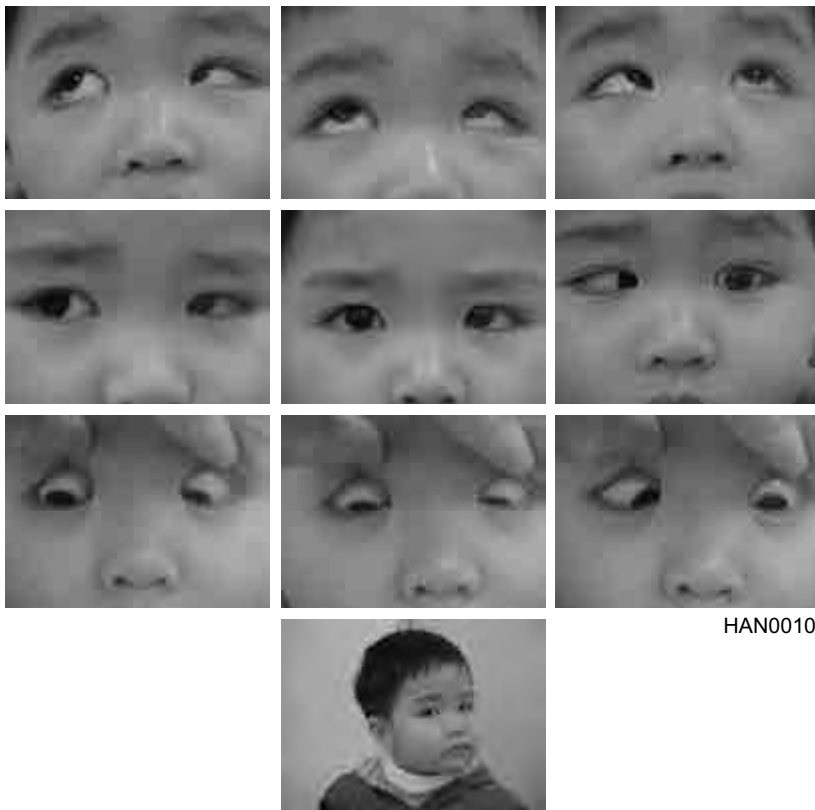Treatment in this case would consist of:

- 1) Bilateral transfer of the vertical rectus muscles to the lateral rectus muscle. The question would be, full tendon or half tendon? With or without augmentation?

- 2) Weakening of both medial rectus muscles. The question would be, recession or Botox.

My choice would be large recession of both medial rectus muscles plus a half tendon transfer shifting the lateral half of the superior and inferior rectus muscles (or the full tendon) to the lateral rectus muscle. Augmentation as suggested by Foster could be done at the discretion of the surgeon. Bilateral sixth nerve palsy patients have diplopia even with otherwise good results from surgery. Because of both eyes being affected, a secondary deviation can occur in any field of gaze. At best a small field of single binocular vision can be gained. Suppression is a comfort for these patients. The decision to do a full tendon or a half tendon transfer would depend on the surgeon's concerns about anterior segment ischemia occurring since only one anterior ciliary artery, the one in the lateral rectus, would remain.

CASE 52: Duane class I



HAN0010

Measurements

40 pd ET

History

2 year old girl

Vision: fixes and follows well with either eye

Refraction: OD +2.50
OS +3.00

This girl was noted by her parents to have in-turning of the left eye from shortly after birth. As she began sitting up and walking they noted that she turns her head to the left and assumes right gaze. The child is healthy and there is no family history of strabismus.

Comment

This is an example of Class I Duane syndrome. There is a left esotropia in the primary position, limited abduction in the left eye, and narrowing of the left palpebral fissure on dextroversion. The girl assumes left face turn and right gaze to achieve aligned eyes presumably with fusion. This may be treated surgically with a recession of the left medial rectus muscle and possibly with a posterior fixation suture on the right medial rectus to limit excursion in left gaze making the eyes more nearly 'matched' in that gaze position. In a case like this, it is always necessary to rule out a left sixth nerve palsy. The narrowing of the left palpebral fissure with enophthalmos helps confirm Duane. This would not occur in a sixth nerve palsy. At surgery, resistance to forced abduction in the right eye would also be seen in Duane, but could also be seen, probably to a lesser degree, in sixth nerve palsy.

CASE 53: Duane syndrome class II



Measurements

20 pd XT primary

History

8 year old girl

Vision: OD 20/20, OS 20/20

Refraction: OD +1.00
OS +1.25

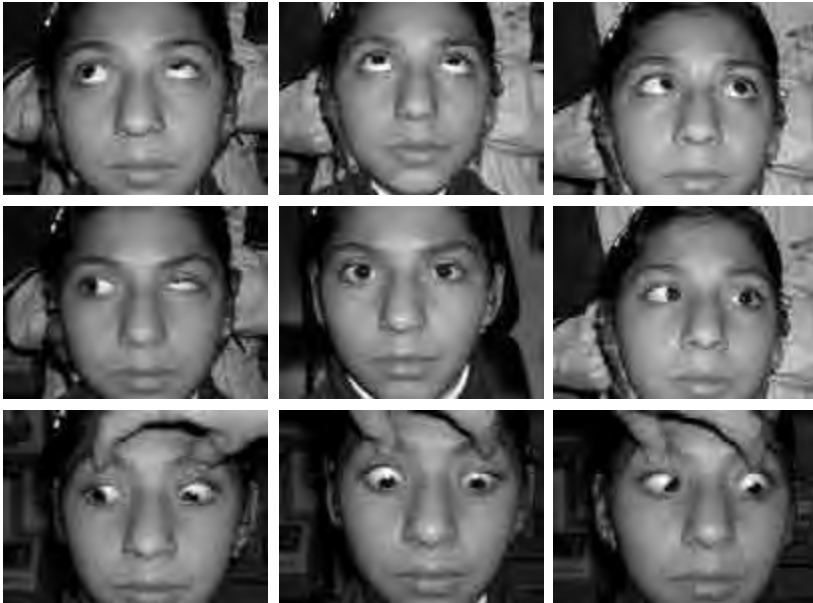Stereo: fly (3000 sec)

This girl has been noted by her parents to have a face turn to the right. They do not notice anything else about her eyes. She is otherwise healthy and has no complaints.

Comment

This is a class II or exotropic Duane affecting the left eye. Abduction in the left eye is quite good. This girl turns her face to the right (toward the normal eye) and assumes left gaze where she has single binocular vision and where she can fuse at least the stereo fly (3000 sec). Note in picture 3 that the inferior orbital septum pushes out making the lower lid fuller. This occurs because the enophthalmos caused by the co-contraction of the medial and lateral recti displaces orbital fat. This class II Duane affecting the left eye is treated by recession of the left lateral rectus muscle. If the enophthalmos were more severe, both the medial and lateral rectus of the involved eye could be recessed and then the lateral rectus of the sound eye could be recessed to treat the extra exodeviation caused by the medial rectus recession in the affected eye.

CASE 54: Duane syndrome class III



Measurements

ortho

RO - CHB0011

History

9 year old girl

Vision: OD 20/20, OS 20/25

Refraction: OD +0.50

OS +0.50

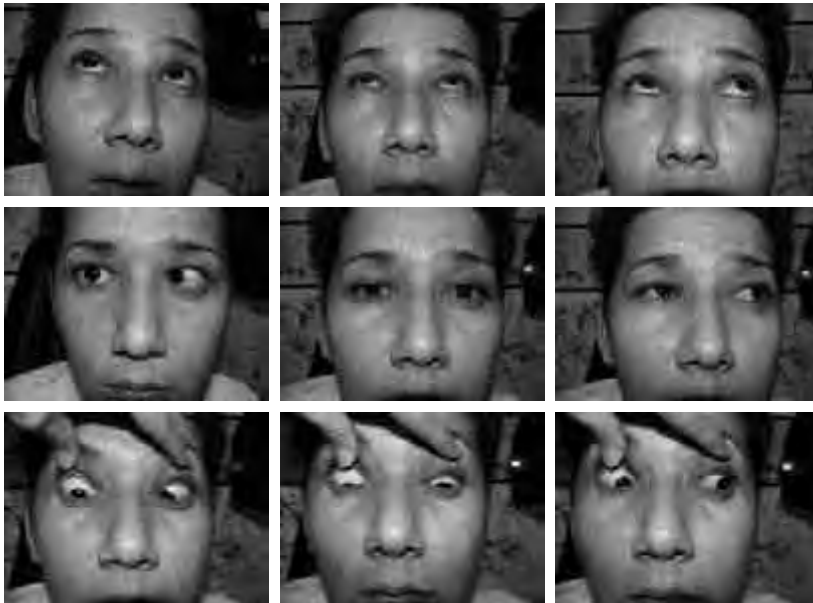Stereo: 9/9 (40 sec.)

This girl is reported by her parents to have a smaller eye on the left and that some times it 'disappears'. She is doing well in school and has no complaints.

Comment

This girl has a class III or 'straight eye' Duane with a prominent upshot in adduction. Because she has excellent stereopsis and no complaints, any surgical treatment should take these two facts into consideration. If the enophthalmos and upshoot become enough of a problem, surgery on the left eye could be done consisting of a recession of the left lateral rectus with a 'Y' split and recession of the left medial rectus. Note that the main problem with this girl's appearance is in far right gaze seen in picture 4. This position is easy for her to avoid. This girl can find double vision as can virtually all Duane patients both before and after even successful surgery. Patients with Duane can be made better but not 'perfect'.

CASE 55: Duane class III



GUM0057

Measurements

ortho primary

History

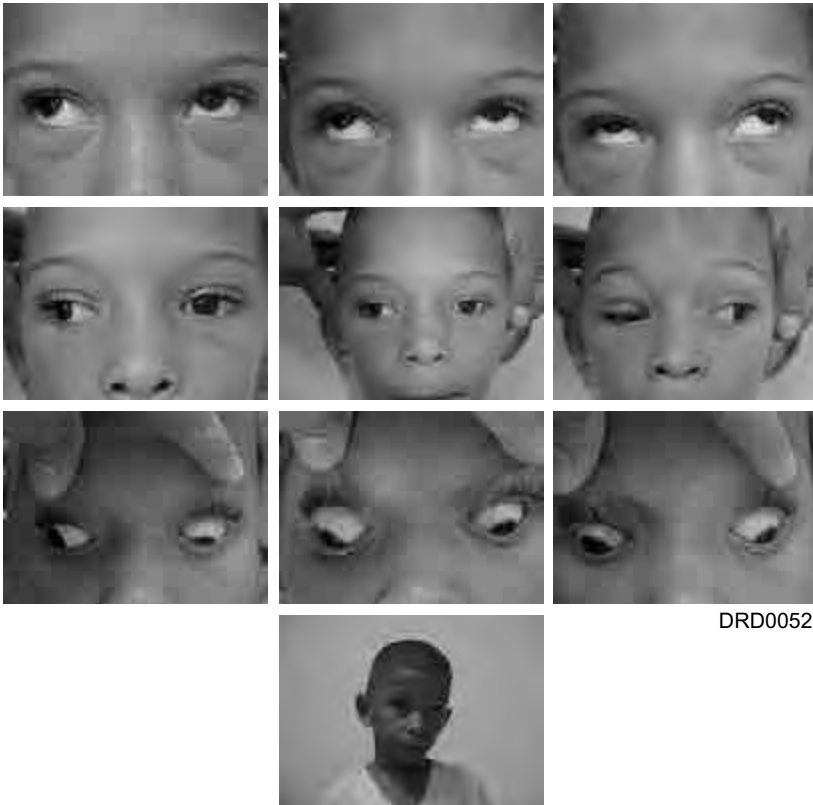
40 year old female
 Vision: OD 20/40, OS 20/20
 Refraction: OD +0.25 -1.25 x 180 degrees
 OS +0.25
 Stereo: fly (3000 sec.)

This woman is becoming increasingly uncomfortable about the way she looks. She complains that her eyes just don't 'look like they should'. Specifically she states that her right eye looks smaller and that it does not go all the way to the right. She also experiences double vision when she looks to the right.

Comment

It has been my experience that children with Duane syndrome seldom if ever complain and that adults almost always complain. In other words, Duane syndrome becomes more symptomatic with age without necessarily any change in the eye movement behavior. It is well understood that Duane cannot be 'cured' only made some better. This is achieved by normalizing head posture, reducing or eliminating the primary position deviation, and increasing the field of single binocular vision. However these patients will always be able to find double vision and will continue to experience some over and/or under action of selected extraocular muscles. For this reason it would be unwise in my opinion to offer surgery to this patient. She is probably as well off as she can be. Surgery at best would offer no significant improvement and at worst would create a new problem.

CASE 56: Duane class II



DRD0052

Measurements

40 pd XT - up
 60 pd XT - primary
 80 pd XT - down

History

6 year old boy
 Vision: OD 20/20, OS 20/20
 Refraction: OD +0.50
 OS +0.50
 Stereo: fly (3000 sec.)

This boy has had a face turn according to his parents since the time the child sat up and walked. At times they see his eyes deviated outward and sometimes the right eye looks 'small'. This boy does not complain about his eyes.

Comment

A large right exotropia is present in the primary position. The patient deals with this by turning his head to the left. With this posture he demonstrates stereo acuity. Abduction in the right eye is nearly normal, but adduction is limited. During levoversion the right eye becomes enophthalmic, and it 'shoots' up or down. An 'A' pattern is present. To treat this case surgically the following could be done:

- 1) Large recession of the right lateral rectus with 'Y' split
- 2) Moderate recession of the right medial rectus
- 3) Recession of the right lateral rectus

The amounts of surgery must be determined at the time of surgery and would depend, at least in part on the tightness of the muscles.

CASE 57: Duane class II



Measurements

25 pd XT primary

History

13 year old girl

Vision: OD 20/20 OS 20/20

Refraction OD +0.50 OS + 0.75

Stereo: 6/9 dots (80 sec.)

This girl has a moderate right exotropia in the primary position. She assumes a left face turn to keep her eyes in right gaze where she has excellent fusion. There is moderate limitation of abduction in the right eye, narrowing of the right palpebral fissure on levoversion, enophthalmos of the left eye and both up and down shoot of the right eye in levoversion depending on whether the right eye is slightly above or below the midline. This girl does not complain of diplopia. Her parents are concerned about the face turn.

Comment

This class II Duane is unusual because abduction seems more affected than adduction in the involved eye. But the exotropia and upshoot make this more of a class II than anything else.

Surgery for this patient could consist of:

1) A moderate right lateral rectus recession with one muscle width upshift.

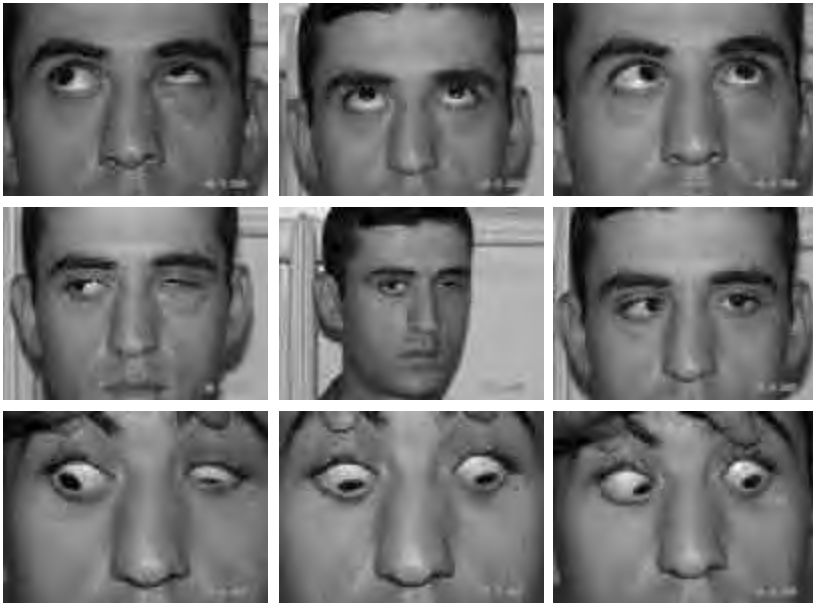Since this could further limit the already slightly limited abduction in this eye. Another alternative would be:

2) Recession of both the lateral and the medial rectus in the right eye and a recession of the lateral rectus in the left eye. The right lateral rectus would be shifted up one muscle width.

In addition, the patient could have:

3) Posterior fixation suture of the left medial rectus to help balance alignment in right gaze

CASE 58: Duane class I (or II)



TRK0005

Measurements

20 pd ET distance
8 pd XT near primary

History

20 year old male
Vision: OD 20/25, OS 20/25
Refraction: OD +1.00 +0.25 x 90
OS +1.50
Stereo: fly (3000 sec.)

This man's alignment goes from an esotropia to an exotropia in the primary position comparing distance and near. He has severe limitation of abduction and adduction in the left eye with enophthalmos and mostly upshoot of the left eye in adduction. He is most concerned with his face turn and the hyperdeviation of the left eye. He also complains of frequent diplopia when he is driving a car.

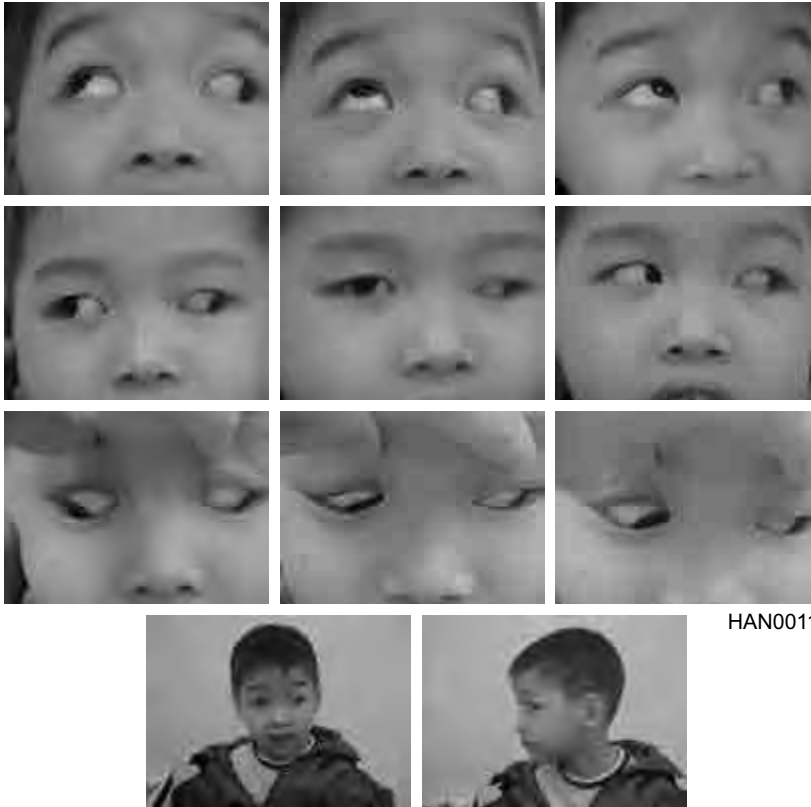Comment

Surgery for the enophthalmos and upshoot in this patient could include:

- 1) Small recession of the left lateral rectus with 'Y' split
- 2) Moderate recession of the left medial rectus

This could also benefit the exotropia in downgaze

CASE 59: Duane class IV



Measurements

60 pd XT primary

History

5 year old boy
 Vision: OD 20/60, OS 20/30
 Refraction: OD -1.00
 OS -2.00

This boy according to his parents has had a large exotropia since birth. He has always turned his face to the right and looked at them with the eyes in left gaze. The child is otherwise healthy and is developing normally.

Comment

This boy demonstrates another striking ocular motility finding that the parents did not observe. When he looks far to the right the left eye diverges or goes to the left! This had been called 'perversion of the extra ocular muscles'. It is also called 'simultaneous abduction'. I believe it is a very extreme example of class II Duane. In these patients the eyes are so exotropic that when co-contraction occurs in the affected eye, the mechanical advantage of the involved eye is so great because of the eye position in exodeviation that the eye undergoes abduction rather than retraction. I call this class IV Duane.

Surgical treatment of this could be:

- 1) Large bilateral lateral rectus recession
- 2) Left medial rectus resection

This 'breaks' the rule of not resecting muscles in cases in Duane. However, the exodeviation is so great that I believe resection is advisable. I have seen and treated only a few of these cases. They are rare. I believe this is a type of Duane that deserve a class of its own

CASE 60: Brown syndrome



AL0040

History

12 year old boy
 Vision: OD 20/25, OS 20/25
 Refraction: OD plano
 OS plano

This boy is noted by his parents to tilt his head to the right. He has no specific complaints but does say he can see double at times. His general health is good and he is doing satisfactory work in school.

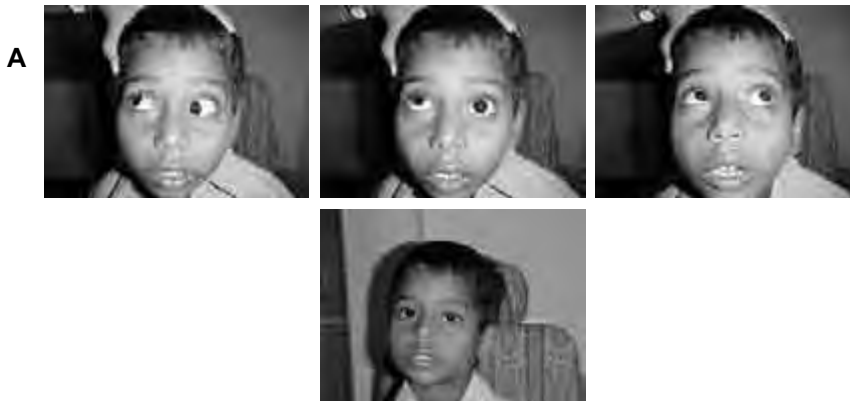Comment

This is a typical case of Brown syndrome. Of course, this must be confirmed by demonstrating restricted forced ductions to elevation of the right eye in adduction. Based on the typical appearance, it is safe to schedule surgery with confidence that the diagnosis of Brown will be confirmed. The choice of surgical procedure depends on the experience and the preference of the surgeon. There are several approaches suggesting that none is 'perfect.'

- 1) My choice is to do the following: a) expose the entire superior oblique tendon after a 'cuffed' superior limbal incision, usually with detachment of the superior rectus; b) explore the superior oblique tendon from the trochlear cuff to the tendon's insertion freeing any obvious restrictions; c) repeat forced duction testing the tightness of the superior oblique tendon and if resistance to elevation of the eye persists proceed with disinsertion or tenectomy as needed but starting with the lesser weakening procedure and proceeding as indicated by the forced ductions d) replace the superior rectus and close. I do not routinely place a traction suture.
- 2) Some would do a medial approach to the superior oblique tendon and place a silicone spacer to lengthen the tendon.
- 3) Still others would do a superior oblique tenectomy.

All of these procedures can succeed and I suspect all can fail!

CASE 61: Brown syndrome (three examples)



IN0047

Measurements

Primary ortho
with head tilt



AL0029



AL0025

Measurements

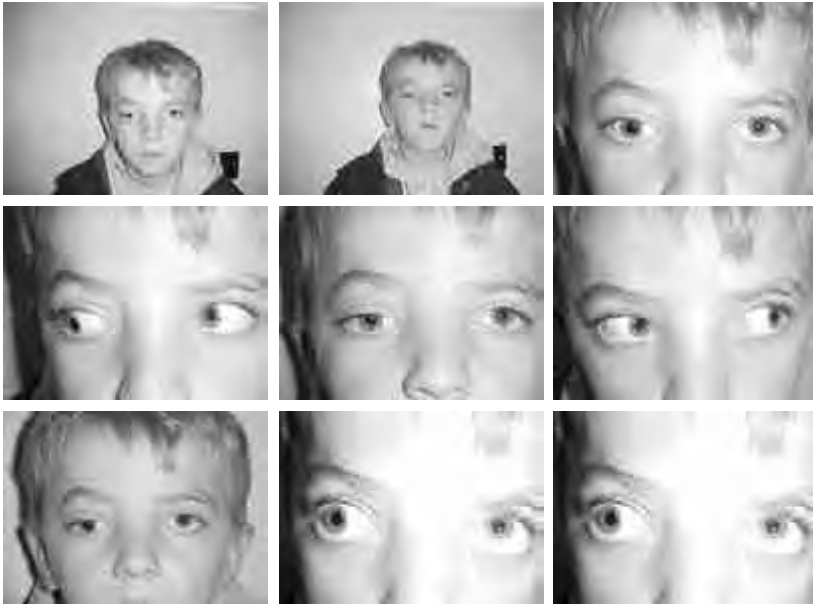
25 pd ET 10 pd
right hypo primary

A, Typical Brown with chin up head posture; **B**, Typical Brown; **C**, Brown and esotropia - the boy does not assume a chin up head posture

Comment

These three patients demonstrate the similarities of findings in patients with Brown syndrome. These findings are for the most part like those of case 60 and treatment would be similar. However note that in the third patient there is a large angle esotropia in the primary position. This would require at least a medial rectus recession along with the surgical treatment of the Brown. The patient with esotropia and Brown does not assume a chin up head posture because he has suppression. A head posture in this case is not needed to avoid of diplopia and achieve fusion.

CASE 62: Right hypotropia (trauma)



Measurements

20 pd R hypo

AL0018

History

9 year old boy

Vision: OD 20/20 OS 20/20

Refraction: OD plano OS plano

This boy was stuck above the right eye with a pointed stick about one year ago. His right eye has been lower since that time. He holds his chin up and reports seeing double. A CT of the orbit shows the superior rectus in place and there is no evidence of a blow out fracture.

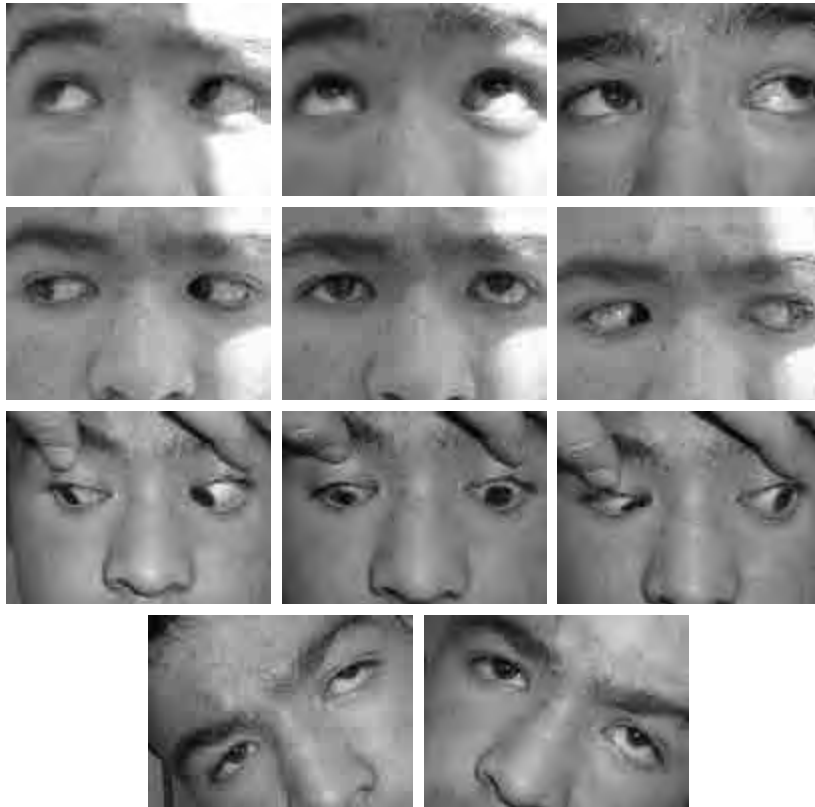Comment

Any time trauma around the eye causes a hypotropia a blowout fracture must be suspected. This was not shown on the CT. I suspect that the problem is with the right superior rectus in spite of the CT findings suggesting a normal muscle. My recommendations for treatment are the following:

- 1) At surgery confirm the presence of free forced elevation of the right eye
- 2) Explore the right superior rectus area and advance/repair a lacerated muscle or resect an intact muscle
- 3) If passive ductions are restricted, the reason must be found and the restrictions freed. A decision must then be made regarding recession of the muscle associated with the restriction

Trauma cases must be dealt with on an individual basis with surgery done in response to the unique findings of each case.

CASE 63: Traumatic disinsertion of the inferior rectus



Measurements
 5 pd L hyper up
 25 pd L hyper primary
 35 pd L hyper down

AFT-kbl0007

History

16 year old boy
 Vision: OD 20/20 OS 20/20
 Refraction: OD plano OS plano

This boy was struck in the left eye one year ago with a carpet hook. He was treated surgically for a lacerated left inferior rectus, but the left hypertropia, limited depression of the left eye and diplopia remain.

Comment

The inferior rectus is the muscle most frequently involved in trauma like this. This may be due to the fact that the protective Bell phenomenon places the inferior rectus in harms way as the eye rotates upward. The first attempt at repair was unsuccessful. The significant lower lid ptosis suggests that the muscle is there but was not properly reattached.

Surgery for this patient would consist of:

- 1) Exploration of the left inferior rectus
- 2) Advancement of the inferior rectus to the original insertion. A tandem adjustable suture could be used.

The presence of lower lid ptosis and the fact that some depression of the left eye remains suggests that the inferior rectus continues to act and that if it is reattached, the lid will come up and the eye will go down!

CASE 64: Third nerve palsy with aberrant regeneration




HA0004

Comment

This case may well be treated best by avoiding surgery.

CASE 65: Traumatic subconjunctival hemorrhage



GUM0036

Comment

A trauma case like this deserves a thorough eye examination in addition to evaluation of motility. In this patient both were normal except for the extensive ecchymosis and subconjunctival hemorrhage. In cases like this the hemorrhage is said to resolve in fourteen days with treatment and in two weeks without!

CASE 66: Conjunctival laceration



GUM0068

Comment

This small conjunctival laceration can be closed with one suture or it can be allowed to heal on its own. In a case like this be sure to rule out lateral rectus damage and perforation of the globe. With an injury like this a thorough eye examination should be done.

CASE 67: Dissociated vertical deviation (two examples)



DRD0066

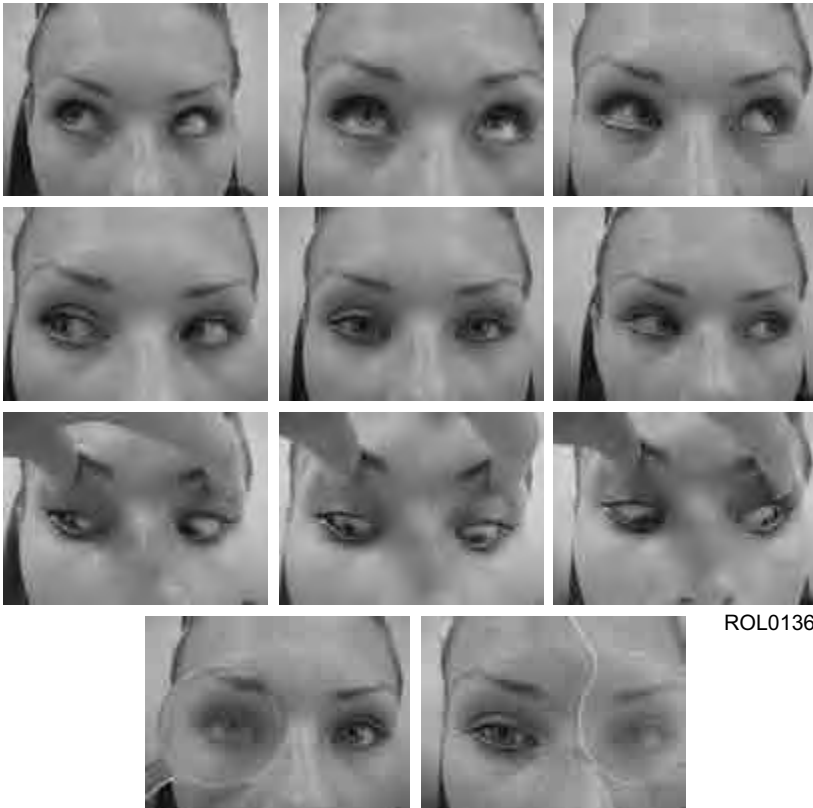

DRD0085

Comment

These two patients are excellent examples of the value of the Speilmann translucent occluder for demonstrating dissociated vertical deviation in a way suitable for photographic documentation.

CASE 68: Heimann-Bielschowsky phenomenon



Measurements
15 pd R hypo primary

History

16 year old girl
Vision: OD 20/400 OS 20/20
Refraction: OD +3.00 OS +1.25

This girl started with congenital esotropia and has undergone three surgeries. She has had no treatment for amblyopia. She notes that her right eye is lower than the left and that it sometimes moves up and down.

Comment

Hypotropia in a poorly seeing eye which also 'bobs' up and down with nystagmoid movements is characteristic of the Heimann-Bielschowsky phenomenon. This patient also demonstrates a DVD response when the right eye is covered. Behavior of this sort can occur in a poorly seeing eye of long standing. I have seen similar behavior in more than a dozen such cases. The best treatment for this patient in my experience is recession of the inferior rectus of the hypotropic right eye. In cases like this that I have treated, there has been no exacerbation of the hyper response of the DVD.

16

Strabismus case management

- CASE 1** Congenital esotropia without nystagmus, 363
- CASE 2** Congenital esotropia with nystagmus, limited abduction, and face turn (Ciancia syndrome), 365
- CASE 3** Nystagmus blockage syndrome, 366
- CASE 4** Residual esotropia, 367
- CASE 5** Exotropia after surgery for esotropia (with normal or nearly normal adduction), 368
- CASE 6** Exotropia after a slipped medial rectus muscle, 369
- CASE 7** Exotropia caused by a 'lost' medial rectus muscle, 370
- CASE 8** 'V' pattern exotropia with overaction of the inferior obliques, 371
- CASE 9** Dissociated vertical deviation (DVD), 373
- CASE 10** 'A' esotropia after bimedial rectus recession, 375
- CASE 11** 'A' exotropia after bimedial rectus recession, 376
- CASE 12** Basic pattern intermittent exotropia, 377
- CASE 13** Divergence excess intermittent exotropia, 378
- CASE 14** Convergence insufficiency intermittent exotropia, 379
- CASE 15** Persistent diplopia after surgery for intermittent exotropia, 380
- CASE 16** Congenital Brown syndrome, 381
- CASE 17** Acquired Brown syndrome, 383
- CASE 18** Iatrogenic Brown syndrome, 384
- CASE 19** Duane syndrome with esotropia (class I), 385
- CASE 20** Duane syndrome with limited adduction (class II), 386
- CASE 21** Duane syndrome with straight eyes and limited abduction and adduction (class III), 387
- CASE 22** Duane syndrome with simultaneous abduction (class IV), 389
- CASE 23** Class I superior oblique palsy, 390
- CASE 24** Class II acquired superior oblique palsy, 392
- CASE 25** Large-angle class III congenital superior oblique palsy 393
- CASE 26** Large class IV acquired superior oblique palsy, 395
- CASE 27** Bilateral superior oblique palsy, 397
- CASE 28** Canine tooth syndrome: 'class VII' superior oblique palsy, 399
- CASE 29** Congenital absence of the superior oblique tendon, 401
- CASE 30** Thyroid ophthalmopathy (Graves' ophthalmology), 402
- CASE 31** Thyroid ophthalmopathy (Graves' ophthalmology) with postoperative slippage of the recessed inferior rectus, 403
- CASE 32** Thyroid ophthalmopathy (Graves' ophthalmology) involving multiple muscles, 405
- CASE 33** Unilateral sixth nerve palsy, 406

- CASE 34** Bilateral sixth nerve palsy, 408
- CASE 35** Bilateral sixth nerve palsy with persistent diplopia after successful treatment, 409
- CASE 36** Right sixth nerve palsy from intracranial aneurysm, 411
- CASE 37** Acquired third nerve palsy, 412
- CASE 38** Traumatic third nerve palsy with misdirection after successful horizontal alignment, 414
- CASE 39** Congenital third nerve palsy, 416
- CASE 40** Severe bilateral congenital third nerve palsy, 417
- CASE 41** Sensory exotropia, 418
- CASE 42** Residual sensory esotropia, 419
- CASE 43** Dissociated vertical deviation with true hypotropia (falling eye), 420
- CASE 44** Double elevator palsy, 422
- CASE 45** Blowout fracture of the orbit, 423
- CASE 46** Acute blowout fracture of the orbit, 424
- CASE 47** Congenital fibrosis syndrome, 425
- CASE 48** Möbius syndrome, 426
- CASE 49** Skew deviation with symptomatic diplopia, 427
- CASE 50** Acquired esotropia, 428
- CASE 51** Chronic progressive external ophthalmoplegia, 430
- CASE 52** Ocular myasthenia, 431
- CASE 53** Absence of the medial rectus muscle, 432
- CASE 54** Traumatic disinsertion of the inferior rectus muscle, 433
- CASE 55** Diplopia after cataract extraction from left inferior rectus restriction, 435
- CASE 56** Diplopia after repair of retinal detachment, 437
- CASE 57** Diplopia after repair of retinal detachment, 438
- CASE 58** 'V' pattern esotropia with overaction of the inferior oblique muscles, 439
- CASE 59** 'A' exotropia, bilateral overaction of the superior obliques, dissociated vertical deviation, 441
- CASE 60** Parinaud's paralysis of elevation, 443
- CASE 61** Null point nystagmus, 444
- CASE 62** Congenital nystagmus with decreased vision, 446
- CASE 63** Nystagmus after brain stem stroke, 449
- CASE 64** Superior oblique myokymia, 450
- CASE 65** Typical refractive esotropia, 451
- CASE 66** Refractive/ accommodative esotropia (high AC/A), 452
- CASE 67** Refractive esotropia with dissociated vertical deviation, 453

Case presentations

The layout of the patient presentations in this section includes the following:

1. A clinical photograph of the patient emphasizing the most informative characteristic(s).
2. A brief clinical history highlighting pertinent facts about this patient. These historical items will be typical of the class of patient presented.
3. Pertinent clinical measurements including those motor and sensory findings important in diagnosis and treatment planning. Although the complete motility examination as described previously (see chapter 4) has been completed for all patients up to the level of the patients ability to cooperate only selected findings will be described.
4. Diagnosis
5. Nonsurgical treatment
6. Surgical treatment
7. Comments

The management of strabismus starts with recognition of the entity; a diagnosis must be made. After thinking about how this is actually done, a fairly unlikely solution occurred to me. The diagnosis of strabismus in most cases is made by first recognizing the *qualitative* findings and then assigning a diagnostic label. Third nerve palsy looks like third nerve palsy because the eye is down and out with ptosis and frequently a large pupil. Congenital esotropia looks like congenital esotropia because the eyes are crossed in an infant who can abduct either eye. The diagnosis of strabismus is made by simply knowing and recognizing this condition in a patient. Although a thorough understanding of mechanisms of strabismus and a thorough knowledge of the diagnostic routine are essential, the diagnosis is made more on the basis of observation than by the deductive process. Each strabismus has its gestalt, and awareness of this is the foundation of strabismus diagnosis. Once the diagnosis is made, it is necessary to work more or less backward from the diagnosis by determining size or amount (quantification), the sensory status, and finally, the etiology of the strabismus. The ability to carry out this process beforehand is essential to the ultimate effective treatment of strabismus.

A key to the *understanding* of strabismus starts with etiology. The concept can be demonstrated in an algorithm (p.24). The first branching of this algorithm separates all of strabismus into those patients with *inborn errors in motor fusion mechanism*, the basic cause of congenital esotropia, and those born with *motor fusion potential*. The former category extends linearly to include the broad spectrum of ocular motility disturbances, which can be placed under

the large heading ‘congenital esotropia syndrome.’ The latter includes all patients born with the *potential* for motor fusion and comprises the remainder of strabismus in its many and varied forms.

The algorithm of etiology recognizes five principal causes for strabismus or misalignment of the eyes:

1. Congenital absence of *motor fusion*, leading to congenital esotropia and its sequelae
2. Congenital or acquired *mechanical* strabismus
3. Congenital or acquired supranuclear, nuclear, and fascicular *neural* strabismus including intermittent exotropia
4. Congenital or acquired *sensory* deficit leading to strabismus
5. Refractive-accommodative esotropia

In the first category with absence of the motor fusion mechanism in the occipital cortex, the eyes are not guided gently and inexorably to alignment during the formative months of life. In the absence of this central guide, called motor fusion, the peripheral motor elements (extraocular muscles guided by supranuclear vergence mechanisms and activated through motor nerves) tend to “go their own way.” Since the most exuberant infantile oculomotor response is convergence, esotropia is the result of a lack of central motor fusion. Later, this lack of motor fusion control has its effect on some subtle and not so subtle brainstem oculomotor control functions and produces dissociated vertical deviation (DVD), oblique dysfunction, asymmetric optokinetic nystagmus (OKN), torticollis, and latent nystagmus.

Now for the rest of strabismus! It may seem to be painting with too broad a brush to assign the remainder of strabismus to a single branch, those born with motor fusion who develop strabismus on the basis of mechanical or neural factors. I hope I can convince you that this is logical. While all of these patients in the second branch of the classification have in common the capacity for motor fusion, some retain normal sensory fusion at least part of the time, some lose it (acquired strabismus with suppression), and others may never have been able to realize the potential (Mobius syndrome, congenital third nerve palsy). Depending on time of onset of the strabismus, inability (ability) of the eyes to attain alignment with vergence response or by assumption of an appropriate head posture, and providing there is equal sensory input, fusion potential can be salvaged. On the other hand, in the absence of these factors it can be lost. In a similar way, sensory fusion (stereopsis) may be retained if favorable factors prevail or it may be lost. Diplopia from defective motor fusion may be either constant or intermittent. Finally, suppression—either intermittent and reversible, as in intermittent

exotropia, or constant with anomalous correspondence and with or without amblyopia--may be the sensory adaptation to the ocular misalignment.

The eyes may be free to move individually in all directions or they may not. If free movement is not achieved, the cause of the strabismus may be mechanical or neurologic or combined mechanical/ neurologic. Only testing of passive ductions and generated force can differentiate these classes of strabismus.

This array may seem to be getting long and complicated and even out of hand, but it should not be so construed. A little thought and a little practice will lead even the neophyte through the initial steps. This approach provides an alternative to the traditional scheme of categorizing that, in my opinion, is really not the most useful way to tackle the management of strabismus.

After observation, an accurate history and employing appropriate physical examination techniques, the proper diagnosis of strabismus can be made in nearly every case. This strabismus workup has been described in detail (chapter 4). In outline form it is as follows:

History

When

What

Symptoms

Prior treatment

Vision

Stereo acuity

Motor fusion amplitudes

Diplopia fields

Ductions--versions--forced ductions--saccadic velocity--generated force

Nystagmus

External

Pupils

Head posture

Prism and cover test--double Maddox rod test (torsion)--head tilt test (Bielschowsky)

Retinoscopy after cycloplegia

Fundus examination--'retinal torsion'

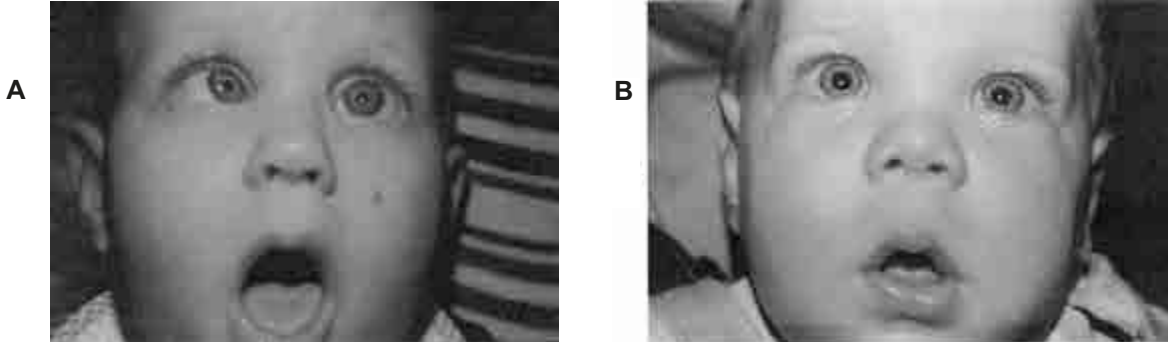
Diagnosis

Treatment plan

The patient workup scheme, surgical options, surgical techniques, aphorisms, and possible complications (and ways to avoid them) are described elsewhere in the book. It should always be understood that all aspects of the nonsurgical management of the strabismus patient -- including treatment of amblyopia, and appropriate orthoptic, pharmacologic, optical, and prismatic therapy -- should be considered before embarking on a course of surgical treatment.

CASE 1: Congenital esotropia without nystagmus

Clinical picture



A 6 month-old boy with 40 prism diopters of congenital esotropia **A**, before and **B**, 1 day after bimedial rectus recession to 9.5 mm from the limbus with a limbal approach.

History

This patient with congenital esotropia was brought in for examination at 6 months of age; similar infants are usually seen initially between 4 and 12 months of age. Parents often state that the eyes are crossed or that they do not 'track' together. The infant's general health, especially neurologic status, is normal. Older children, up to 2 or 3 years old or more, may be examined for the first time with a similar picture and be diagnosed as probably congenital esotropia based on the history. In either case, parents tend to report that the eyes have been crossed since birth. However, after specific questioning about the timing and duration of the crossing, they may admit that the esotropia was intermittent at first and constant later. One or both parents, a sibling, or another relative may have strabismus, but the family history may be negative for strabismus.

Examination

An infant must be approached gently, with quiet reassuring movements, in order to maintain some semblance of cooperation. The child is observed for fixation and following behavior of each eye, using an interesting object and employing a nonthreatening cover test. Lateral versions should be observed to confirm full abduction. If full abduction is not accomplished while the infant is following an interesting object, the 'doll's head' or oculocephalic maneuver should be done to rule out limited abduction as the cause of the esotropia. Prism and cover testing is difficult in the infant. The deviation can be measured with sufficient accuracy using the Krimsky prism test or the Hirschberg light reflex test with the infant looking across the room. The average deviation is 30 to 45 prism diopters (this infant had 40

prism diopters esotropia), with a range of 10 to 90 prism diopters. No 'A' or 'V' pattern is observed in the straightforward case, although these findings and DVD may be seen at the initial examination of the older child with congenital esotropia. Throughout the examination one should closely observe for both manifest and latent nystagmus, including fine manifest rotary movements. The patient shown here did not have nystagmus. This is a very important finding, since in my experience patients without nystagmus have better surgical results. Refraction is done 40 minutes after 1 drop of Cyclogyl has been instilled in each eye (1/2% in infants under 1 year and 1% in children over 1 year). Retinoscopy findings are typically between plano and less than +3.00 diopters. This infant had retinoscopy of +1.00 diopter in each eye. The examination is completed with evaluation of the anterior segment, media, and retina (posterior pole), including evaluation of the optic nerve and macula.

Diagnosis

Congenital esotropia without nystagmus,* 40 prism diopters, alternating.

Treatment

If amblyopia is diagnosed by noting fixation preference, occlusion therapy is started following one of these two techniques:

- Patch preferred eye all waking hours. Check in 1 week for infants under 1 year of age, in 2 weeks for children over 1 year of age, and in suitably short intervals in any older child to accurately monitor the fixation behavior while avoiding occlusion amblyopia. Continue occlusion until alternation is achieved or no

*This type of congenital esotropia can demonstrate latent nystagmus with DVD later in its course, after surgical treatment

improvement is noted after 3 months of patching with compliance. Before discontinuing attempts at patching, a thorough reassessment of the physical status of the eye should be carried out.

- Patch preferred eye 3 or 4 days, then patch the amblyopic eye 1 day in continuing cycles (one eye is always patched), and follow the routine described above. This technique provides a 'safer' program to avoid occlusion amblyopia, especially in cases where close follow-up is not possible.

If +3.00 D hyperopia or greater is found at cycloplegic refraction in a patient similar to the one shown here, spectacles are usually prescribed. If the eyes are aligned with spectacle correction, refractive esotropia is confirmed and the treatment is continued glasses wear. If the eyes are not aligned with the glasses, congenital esotropia is confirmed. In my experience this is the usual case in infants under 1 year. Since 'low plus' correction of +3.00 or +4.00 diopters rarely results in alignment, loaner glasses may be provided to cut down on the expense for parents.

Surgery

An infant 4 months of age or older with esotropia without amblyopia and without a refractive component is a candidate for eye muscle surgery. My choice of surgical treatment for congenital esotropia without nystagmus is bimedial rectus recession of between 8.5 and 11.5 mm measuring from the limbus, with the amount of surgery depending on the age and the angle. Deviations are divided into small, medium, and large and bimedial rectus recessions are likewise divided.

Deviation	<i>Bimedial rectus recession</i>			
	(mm)	<1 yr	>1 yr	>5 yr
Small	20-30 diopters	8.5	9.0	9.0
Medium	30-45 diopters	9.5	10.0	10.5
Large	45+ diopters	10.5	11.0	11.5

10.0 mm is the maximum between 4 and 6 months

In practice, there is a significant overlap in the preceding table. The inconsistencies can only be described as the 'art' of strabismus surgery. In my opinion, any surgeon who adheres doggedly to a 'formula' will produce inferior results. Minor adjustments should be made based on subtleties of each patient's strabismus. In addition to bimedial rectus recession, conjunctival recession after limbal incision may be done in patients with an angle over 70 prism diopters and in cases where passive abduction is found to be restricted at the time of surgery.

Comment

With appropriate surgery 80% to 85% of eyes will be aligned with less than 10 prism diopters of residual strabismus, which is in most cases an

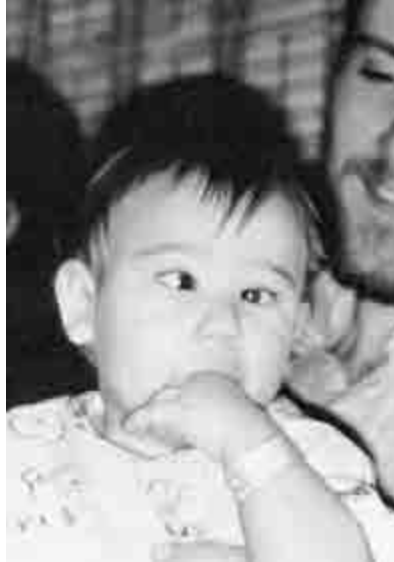esotropia. I estimate that 10% of patients will need a second surgery, usually for residual esotropia, in the first year. Seven of 10 will require a second or third surgery before their teens. Parents are told that a child treated surgically for congenital esotropia has a likelihood of needing additional surgical procedures for an early over- or undercorrection and/or for 'new' strabismus occurring after a period of alignment. These additional surgical procedures are required for DVD, oblique overaction with 'V' or 'A' pattern, residual esotropia, and secondary exotropia. It must be emphasized that the patient with congenital esotropia has an abnormal central nervous system subserving motor fusion. Surgery on the extraocular muscles combined with amblyopia treatment when indicated improves alignment and maximizes sensory function, but this does not eliminate the original and underlying neurologic problem. The best result obtainable from treatment for congenital esotropia is subnormal binocular vision.

Patients treated surgically for congenital esotropia require close follow-up until their teen years. It is especially important to monitor amblyopia in the first few years after the eyes are aligned because it is more difficult to assess fixation behavior and therefore amblyopia in the preverbal child after successful surgery. Other sequelae such as DVD, oblique dysfunction, and exotropia must also be watched for. I tell families of infants treated surgically for congenital esotropia that they need an ophthalmologist for a 'friend' at least until the child receives a driver's licence (that is, until the mid-teens).

For any type of congenital esotropia, some strabismologists use injection of Botox into one medial rectus muscle in doses up to 5 units. This has been reported to produce alignment of 10 dipoters or less esotropia in just over 60% of patients with an average of 1.7 injections. Newer studies by Campos report 88% 'alignment' in congenital esotropia patients after injection of 5 units of Botox in each medial rectus under direct observation with the patient under general anesthesia. This compares to similar alignment in just over 80% of patients after bimedial rectus recession. Some surgeons prefer three or four horizontal rectus muscle surgery for larger angle esotropia, adding one lateral rectus resection for esotropia greater than 70 diopters. I do bimedial rectus recession as the first surgical procedure for all patients with congenital esotropia. We produce hard to explain undercorrection with some small angles and overcorrection with some larger preoperative esotropia in patterns that suggest that factors other than just the angle of deviation predict the response to surgery.

CASE 2: Congenital esotropia with nystagmus, limited abduction, and face turn (Ciancia syndrome)

Clinical picture



A 10-month-old boy with esotropia, face turn, and manifest latent nystagmus (Ciancia syndrome).

History

This 10-month-old boy presented with a typical congenital esotropia history: the eye crossing from birth or shortly after in an otherwise normal infant. This patient differs in that his parents say he appears to have *both* eyes crossed and usually turns his head.

Examination

Abduction is apparently limited, but with effort it is full with nystagmus increasing in abduction. Nystagmus (manifest latent nystagmus) is present in the primary position with the slow phase toward the nonfixing eye.

The strabismus angle is measured with the Krimsky prism test or the Hirschberg light reflex test. In this patient 60 prism diopters of esotropia is measured. Prism and cover testing is more difficult to perform than in congenital esotropia without nystagmus. The angle is usually larger than congenital esotropia without nystagmus by 10 prism diopters or more. The remainder of the examination is normal. Retinoscopy after 1/2% Cyclogyl is OD +1.50, OS +1.50.

Diagnosis

Congenital esotropia with nystagmus (Ciancia syndrome).

Treatment

Amblyopia and hyperopia (refractive component) if present are treated in the usual manner.

Surgery

Bimedial rectus recession is performed according to the angle. A slightly larger bimedial rectus recession is indicated compared to congenital esotropia without nystagmus. As a guideline, I add 0.5 mm to 1.0 mm to each medial rectus recession, according to age. The maximum for this child is 10.5 mm from the limbus. Some surgeons would add a lateral rectus recession in one eye.

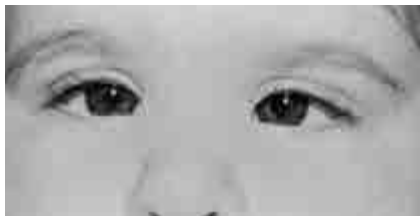Comment

Congenital esotropia with nystagmus is more likely to result in postoperative undercorrection when a similar amount of surgery is done compared to congenital esotropia without nystagmus. This means that close follow-up is needed. Repeat surgery for a significant residual angle is needed about twice as often as in congenital esotropia without nystagmus.

The ultimate in manifest latent nystagmus occurs in infants who have no vision in one eye or have undergone enucleation of one eye. These patients may develop pronounced manifest latent nystagmus with the slow phase toward the non-seeing eye and face turn toward the seeing eye. Improved head posture results after recession of the medial rectus and resection of the lateral rectus of the sound eye.

CASE 3: Nystagmus blockage syndrome

Clinical picture



An 18-month-old girl with 40 prism diopters esotropia and *both* eyes crossed. This patient has a variable angle, often large, esotropia with stable eyes while the eyes are crossed (converged) because of the stabilizing effect of convergence.

History

Early onset variable angle esotropia with dancing movements of the eyes is reported by this child's parents, who state she is an otherwise healthy 18-month-old girl.

Examination

Since the deviation is inversely related to the nystagmus, the larger the esotropia, the less nystagmus and vice versa. It is difficult to measure the angle of deviation with any more precision than can be obtained with observation and estimation or by the light reflex (Hirschberg). This patient has a maximum esodeviation of 40 prism diopters. Versions and ductions are full, but some effort may be required to record full abduction in patients like this. Retinoscopy after 1% Cyclogyl is OD +2.50, OS +2.75.

Diagnosis

Nystagmus blockage syndrome.

Treatment/ Surgery

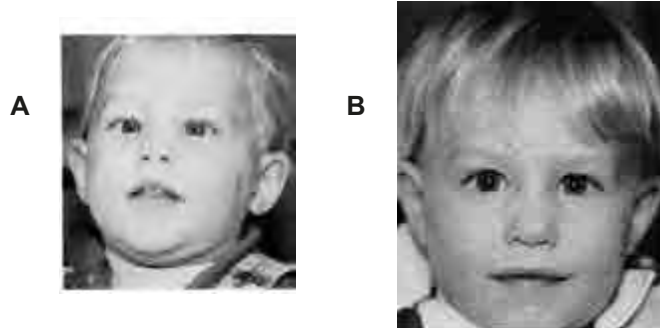
My choice for surgery in this case is a bimedial rectus recession according to the maximum angle. In this case I would recess each medial rectus 11.0 mm from the limbus. A smaller bimedial rectus recession may be combined with a posterior fixation suture. Others might do a posterior fixation suture alone.

Comment

Nystagmus blockage syndrome (NBS), more than Ciancia syndrome, is an esotropia without totally agreed upon characteristics or incidence. Ciancia syndrome probably represents about 10% of congenital esotropia in my experience. NBS represents only about 1% to 3%. Some patients with congenital esotropia have a variable angle with manifest pendular and jerk horizontal, vertical, and *rotary* small amplitude nystagmus. This curious type of esotropia (or nystagmus) I have called *ocular instability syndrome*. As with other congenital esotropia patients with nystagmus, ocular instability patients are prone to undercorrection and are the esotropia patients who in my experience are most likely to receive *little*, if any, apparent effect from surgery.

CASE 4: Residual esotropia

Clinical picture



A, Patient after bimedial recession 9.5 mm from the limbus;
B, after re-recession of the medial recti to 11.5 mm from the limbus.

History

This 14-month-old boy had a bimedial recession to 9.5 mm from the limbus (equivalent 4.5 mm from the insertion) at 4 months of age for 35 prism diopters of esotropia. The eyes were never aligned postoperatively and now 25 prism diopters of residual esotropia remains.

Examination

A stable angle of 25 prism diopters esotropia is measured with the Krimsky test. Ductions are full. No oblique dysfunction or vertical incomitance is seen. No nystagmus is noted.

Diagnosis

Residual esotropia after bimedial rectus recession.

Treatment/Surgery

Re-recession of the medial recti to 11.5 mm.

Comment

The choice of surgery depends in large part on what was done at the first surgery. If the bimedial rectus recession was less than maximum, the medial recti may be re-recessed to a maximum of 11.5 mm. Since this case was undercorrected, a slightly larger recession was done in this 1-year-old, exceeding the

11.0 mm limit for initial surgery. If less than 2.0 mm of re-recession can be done; that is, if more than 9.5 mm bimedial rectus recession or equivalent had been done at the initial surgery; less effect would be gained from re-recession and I would consider lateral rectus resection. In a young child with residual esotropia, I would rarely elect to operate on just one muscle. Another choice for surgery would be re-recession of one medial rectus and resection of the lateral rectus of the same eye.

Repeat surgery for residual esotropia is indicated for the same reason that surgery is done originally. An acceptable residual angle is ± 10 prism diopters; greater than this can be reason for reoperation. However, some residual angles greater than 10 diopters are not noticeable. If that is the case, I do not think that a second surgery is necessary. After surgery this type of undercorrected patient may be noted to have manifest nystagmus (manifest latent nystagmus) and what I call *ocular instability* with small amplitude horizontal, vertical, and rotary nystagmus not seen before the initial surgery. Surgical treatment for residual esotropia is based primarily on how the patient looks. In contrast to young patients, some teenagers and adults with residual esotropia can benefit from a single medial rectus weakening procedure for an angle of ± 15 prism diopters.

CASE 5: Exotropia after surgery for esotropia (with normal or nearly normal adduction)

Clinical picture



A 22-year-old man with 35 prism diopters exotropia after bimedial rectus recession at age 3.

History

This 22-year-old man had bimedial rectus recession to 10.0mm from the limbus (5.0 mm equivalent measured from the insertion) at 3 years of age. His eyes were aligned for 3 years then they gradually began to drift out. For the past several years he has had a 'lazy eye,' according to his parents and friends.

Examination

Visual acuity is 20/20 in each eye without correction. The exotropia measures 35 prism diopters distance and near with prism and cover testing. Ductions are essentially full in either eye, except for a trace of reduced adduction bilaterally. No vertical incomitance, oblique dysfunction, or nystagmus is seen. This patient usually fixed with the left eye but would take up and hold fixation with the right eye when asked.

Diagnosis

Secondary exotropia.

Treatment/Surgery

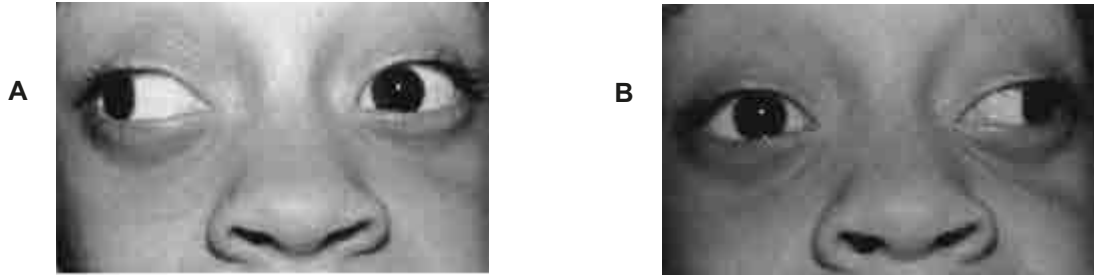
Advancement and resection of both medial recti, including 4.0 mm of advancement and 2.0 mm of resection.

Comment

The most important physical finding is the nearly full adduction, that suggests the medial recti have not slipped. In this type of patient, some surgeons would prefer to do a moderate bilateral lateral rectus recession. In my hands recessing both lateral recti 5.0 to 6.0 mm would be appropriate. Another alternative surgery is resection and advancement of the medial rectus and recession of the lateral rectus in the non-preferred eye.

CASE 6: Exotropia after a slipped medial rectus muscle

Clinical picture



Limited adduction, more pronounced in the left eye in a 14-year-old boy with slipped medial recti after bimedial rectus recession done at age 1 year for congenital esotropia. **A**, dextroversion; **B**, levoversion

History

This 14-year-old boy had bimedial rectus recession for congenital esotropia at age 1 year. The eyes turned out a few months after surgery and he has had a gradually increasing exotropia for the past 10 years. He now comments that his friends notice his eye being out. This has been a concern to both the patient and his parents for the past several years.

Examination

An exotropia of 45 prism diopters is measured in the distance, and this increases to 55 prism diopters at near in the primary position. Visual acuity is 20/20 in the right eye and 20/40 in the left with the visual reduction due to slight amblyopia. The salient feature in this case is reduced adduction in both eyes. Even with maximum attempts at adduction, a prominent rim of sclera shows medially, indicating that the medial recti are underacting.

Diagnosis

Secondary exotropia after surgery for esotropia, and in addition a suspicion that the medial recti have slipped backward from their point of reinsertion.

Treatment/Surgery

Advancement and resection of both medial recti based on the findings at surgery.

Comment

This type of reoperation cannot be subject to a 'cookbook' type of answer. The type and amount of surgery required depend on the findings at surgery. In cases such as this the passive ductions are usually

free, but this must always be confirmed at surgery. When exploring these medial recti, their intended point of reinsertion, if known, should be inspected meticulously. If the medial rectus is where it belongs at the intended or at least at a reasonable recessed position, muscle tissue should be seen at this point. In the case of a slipped muscle, muscle tissue will not be seen here. Instead an 'empty' muscle capsule will firmly adhere to the globe. With careful dissection this can be followed posteriorly to the muscle tissue which is often found excessively recessed to a point at or posterior to the equator. At surgery this muscle must be engaged on a muscle hook, secured with a suture, and brought forward to a point at or near the original muscle insertion. In most cases it is difficult to bring the muscle up to a point 5.5 mm from the limbus (the usual original insertion.) Instead, the muscle is reinserted 6 to 7 mm from the limbus, having been advanced usually 5.0 mm or more. To achieve sufficient effect, I usually include a resection of the muscle with the advancement. For example, I would do a 5.0 mm advancement and a 3.0 mm resection in this case. The final placement of the muscle on the sclera is a matter of intraoperative judgement. Slipped medial recti may be unilateral as well as bilateral. In the case of a unilateral slipped medial rectus, the exodeviation will be incommittant and adduction will be deficient only on the side of the slipped muscle. Slipped muscles happen, in my opinion, because the surgeon places the suture too close to the rectus muscle insertion before disinsertion. With a slipped muscle, the suture is more likely to slip out of the muscle than it is to break loose from sclera.

CASE 7: Exotropia caused by a 'lost' medial rectus muscle

Clinical picture



75 prism diopters right exotropia after a 'lost' right medial rectus muscle following bimedial rectus recession at age 3 years.

History

This 27-year-old man had a bimedial rectus recession for congenital esotropia at age 3 years. Immediately after surgery the right eye became exotropic and he was unable to move his right eye toward his nose. Two subsequent surgeries at ages 4 and 10 were unsuccessful in aligning his eyes.

Examination

Visual acuity is 20/400 in the right eye and 20/20 in the left eye. The right eye is densely amblyopic. The exotropia measures 75 prism diopters in the primary position, but prism and cover testing is difficult because of poor fixation with the right eye. Ductions are normal in the left eye but adduction is severely deficient in the right eye. Saccadic velocity in the right eye during saccade to the left is reduced and generated force is weaker on attempted adduction of the right eye compared to the left. In left gaze the exotropia is 90 prism diopters; it is only 30 in right gaze.

Diagnosis

Presumed 'lost' right medial rectus muscle.

Treatment/Surgery

Passive duction testing to confirm free adduction is followed by exploration of the medial globe, searching for the medial rectus muscle. If the medial rectus is found, it should be reattached to sclera at an appropriate point, depending on the stiffness of the muscle and the alignment produced by reattachment

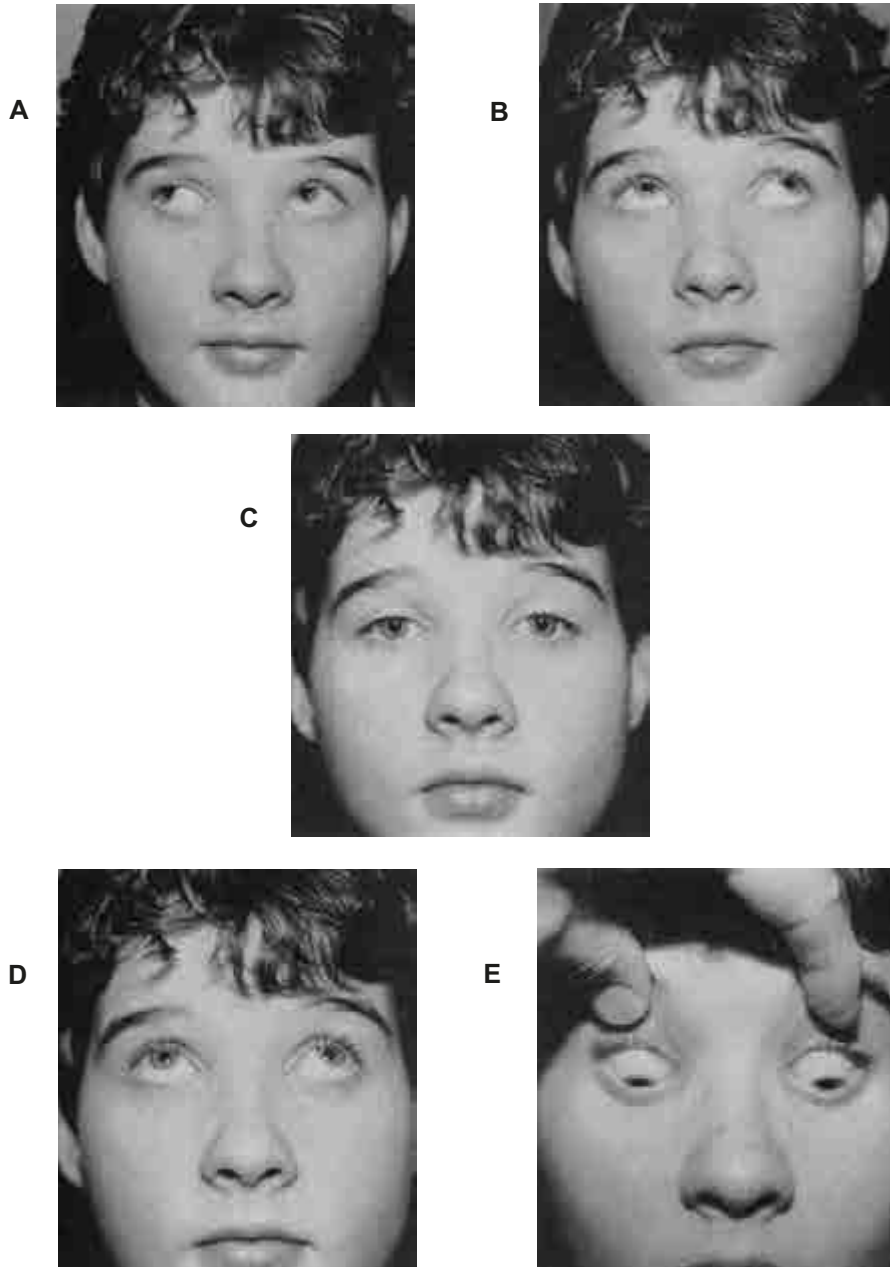
of the muscle. If the medial rectus muscle cannot be found after a reasonable search, a rectus muscle transfer procedure may be done. If the lateral rectus muscle has not been detached at previous surgery (as in this patient), a full tendon transfer of the superior and inferior rectus muscles to the medial rectus insertion site can be done. If the lateral rectus has been detached at a prior procedure, half of the superior and inferior rectus muscle insertion can be shifted to the medial rectus insertion (Hummelsheim procedure). Another option is the 'empty Jensen' procedure, which uses a suture reinforced strip of sclera to join the medial half of the superior and inferior rectus muscles near the medial rectus insertion site (see chapter 13).

Comment

The 'lost muscle' is obviously not lost. It has merely lost its attachment to sclera. The medial rectus muscle is most prone to this complication because it has no association with an oblique muscle as do the other three rectus muscles. This oblique muscle attachment of the other rectus muscles prevents them from slipping behind posterior Tenon's capsule into the orbital fat space. When the medial rectus muscle loses its attachment to the globe, it may retract into the fat space outside of the posterior Tenon's capsule. This is more likely to happen when extensive dissection of the intermuscular membrane has been carried out. A 'lost' medial rectus muscle can be seen on an orbital CT scan or MRI. This can show where the muscle is in the orbit and if (where) it attaches to the globe. The main requirement for approaching this type of surgery is experience and patience on the part of the surgeon. If the lateral rectus muscle is shown to be contracted, as demonstrated by restricted passive adduction, it should be recessed before the 'lost' medial rectus is reattached or the appropriate muscle transfer has been done. If a muscle transfer must be done with a lateral rectus recession, the two lateral anterior ciliary vessels of the vertical recti should be spared. In one very special case of a 'lost' medial rectus surgery done with local anesthesia, I noted a dimple in posterior Tenon's capsule when the patient was asked to adduct the eye. Dissection over this 'dimple' revealed the medial rectus, which was then reattached to the globe. This produced alignment and full adduction!

CASE 8: 'V' pattern exotropia with overaction of the inferior obliques

Clinical picture



V pattern exotropia with bilateral overaction of the inferior obliques. A, up right gaze; B, up left gaze; C, primary position; D, upgaze; E, downgaze

History

This 10-year-old girl had bimedial rectus recession for congenital esotropia at 1 year of age. Both medial recti were recessed 10.0 mm from the limbus for 45 prism diopters of esotropia. She did well for several years but now the family notices that one of her eyes goes “out of sight” at times. They could not be any more specific or explain precisely when or how they notice this.

Examination

Visual acuity is 20/30 in each eye while wearing a low hyperopic-astigmatic correction. The principal positive finding is marked elevation of each eye in adduction (strabismus sursoadductorius) with overaction of the inferior obliques. In addition, a ‘V’ pattern is present with 30 prism diopters of esotropia in downgaze. Cover-uncover testing of each eye in the primary position demonstrates only the slightest trace of DVD. While the patient fixates with either eye in adduction, the abducted fellow eye does not become hyperdeviated under cover (as it would if DVD were a major factor) but instead is hypodeviated. There is minimal apparent underaction of the superior oblique and ductions are otherwise normal, as is the remainder of the eye examination.

Diagnosis

‘V’ pattern exotropia with bilateral overaction of the inferior obliques after bimedial rectus recession for congenital esotropia.

Treatment/Surgery

Bilateral inferior oblique weakening. My preferred technique for this is bilateral inferior oblique myectomy.

Comment

Overaction of the inferior obliques occurs frequently after bimedial rectus recession, occasionally in congenital esotropia that has not had surgery and also as an isolated primary finding without other strabismus. It is certainly legitimate to ask the question, “Does the inferior oblique truly overact?” In my opinion, the inferior oblique probably does overact but only insofar as its relationships to other structures around the eye allow it. For example, after a bimedial rectus recession, the inferior oblique ‘overacts’ by assuming more presence as an abductor as a result of the altered muscle insertion relationship caused by retroplacement of the medial recti. This, I believe, is the reason for the exotropia in upgaze producing the ‘V’ pattern. Capo and Guyton have shown this convincingly. On the other hand, primary overaction of the inferior obliques in cases without prior bimedial rectus recession is, in my opinion, due to *underchecking* by the superior oblique tendon as occurs with congenital superior oblique palsy caused by an anomalous loose tendon. Other instances of presumed inferior oblique ‘overaction’ are due at least in part to DVD. In cases where ‘overaction’ of the inferior obliques is associated with DVD and a ‘V’ pattern, inferior oblique anterior transposition is the procedure of choice.

CASE 9: Dissociated vertical deviation (DVD)

Clinical picture



Left DVD in a 5-year-old boy 3 years after bimedial rectus recession for congenital esotropia.

History

This 5-year-old boy had bimedial rectus recession for congenital esotropia at age 18 months. His eyes remained aligned for several years, but recently his mother has noticed that the left eye goes “way up,” especially when the boy is tired or inattentive. His mother estimates the left eye is deviated upward more than 50% of the time.

Examination

Visual acuity is 20/20 in the right eye and 20/40 in the left with best correction. A mild amblyopia is present in the left eye. On casual observation the eyes look aligned, but at other times the left eye is up, resulting in approximately 15 prism diopters of hyperdeviation. When the right eye is occluded it is approximately 5 prism diopters hyperdeviated. With the cover removed the eye moves briskly down toward the primary position with incycloduction. When the cover is placed over the eye again the right eye moves slowly upward with excycloduction. A similar but larger hyperdeviation with similar cycloductions occurs when the left eye is occluded. When the occluder is removed the left eye moves slowly to the primary position with incycloduction. Latent nystagmus of very low amplitude can be detected in the fixing eye when either eye is occluded. No ‘A’ or ‘V’ pattern is observed, and none of the oblique muscles overacts.

Diagnosis

Dissociated vertical deviation, left eye greater than right eye, manifest left eye.

Treatment

In cases where DVD is asymmetrical and is never or seldom present with a given eye fixing, fixation with this eye is encouraged and no further treatment may be needed. However, if the DVD is manifest sufficiently often to cause distress to the patient, then surgical treatment is indicated.

Surgery

Asymmetrical large recession of the superior recti. The left superior rectus is recessed 7.0 mm and the right superior rectus is recessed 5.0 mm.

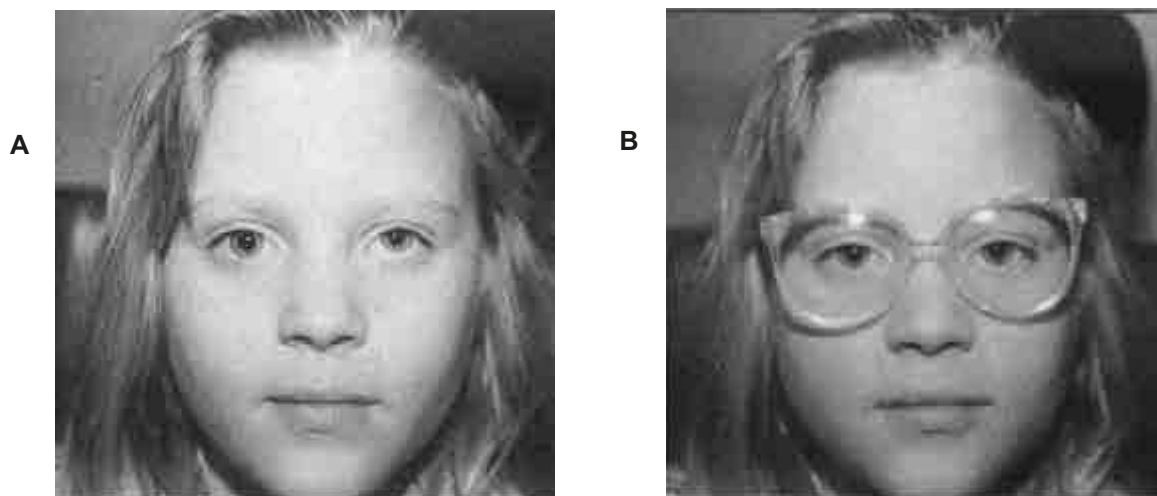
Comment

Because of the peculiar manifestation of DVD as an intermittent vertical vergence occurring in patients with imperfect fusion, the surgical treatment of DVD cannot be expected to be specific, clear cut, or universally effective. On the contrary, surgical treatment is only moderately successful and is definitely not the subject of widespread agreement among strabismologists. Some surgical options include: ‘large’ superior rectus recession, maximal ‘hang back’ superior rectus recession, superior rectus posterior fixation suture with or without recession, inferior

rectus resection, and inferior oblique anterior transposition. Superior rectus recession is the most commonly employed procedure for most patients who have DVD requiring surgery. I rarely do this surgery unilaterally. For persistent DVD after superior rectus recession, I do inferior rectus resection. If a 'V' pattern and inferior oblique overaction are present with DVD, I do bilateral inferior oblique anterior transposition as the first surgical procedure. It must be made perfectly clear that the mere presence of DVD is *not* reason for surgery. More than half of all congenital esotropia patients have some DVD after surgery, including even those with the best results. Surgery

for DVD is indicated only if a hyperdeviation is manifest sufficiently often and the deviation large enough to compromise appearance.

DVD is, in my opinion, a nonspecific manifestation of imperfect binocularity. It occurs most often in the most common manifestation of imperfect binocularity, congenital esotropia. However, DVD can accompany any type of strabismus. It tends to develop in longer standing cases and those with more profound defects in binocularity. In other cases DVD can occur in patients with gross stereopsis. DVD is to strabismus as hyperpyrexia (fever) is to infection.



A, A manifest left hypertropia. Cover/uncover testing shows a typical, unequal (OD<OS) DVD. **B**, When the eyes are uncovered, they are aligned. This 10-year-old girl manifests a 20 prism diopter left hyperdeviation shown immediately after a cover was removed. The girl and her parents see this only rarely, such as when the child is ill with a fever. They never see the right eye up. However, a slight right DVD can be elicited with the cover test. In this case, no surgery is indicated.

CASE 10: 'A' esotropia after bimedial rectus recession

Clinical picture



'A' esotropia
A 25 prism diopters esotropia in primary position
B 35 prism diopters esotropia in upgaze
C Eyes are aligned in downgaze

History

A 10-year-old boy gradually developed a 'lazy eye' according to his mother. The boy had bimedial rectus recession to 9.5 mm from the limbus for 35 prism diopters of congenital esotropia at age 20 months. The deviation is especially bad when he looks up. The boy assumes a chin-up position and always seems to be looking down his nose at people, according to his mother.

Examination

Visual acuity is 20/30 in each eye. The eyes are 35 prism diopters esotropic in upgaze and are aligned in 30 degrees of downgaze at distance measurement. In the primary position, 25 prism diopters of esotropia is measured. There is no overaction of the superior obliques and no underaction of the inferior obliques. The wings seem to stand up on the stereo fly test (gross stereopsis - 3000 sec) with the chin up and eyes in downgaze.

Diagnosis

'A' pattern esotropia without oblique muscle overaction or underaction

Treatment/Surgery

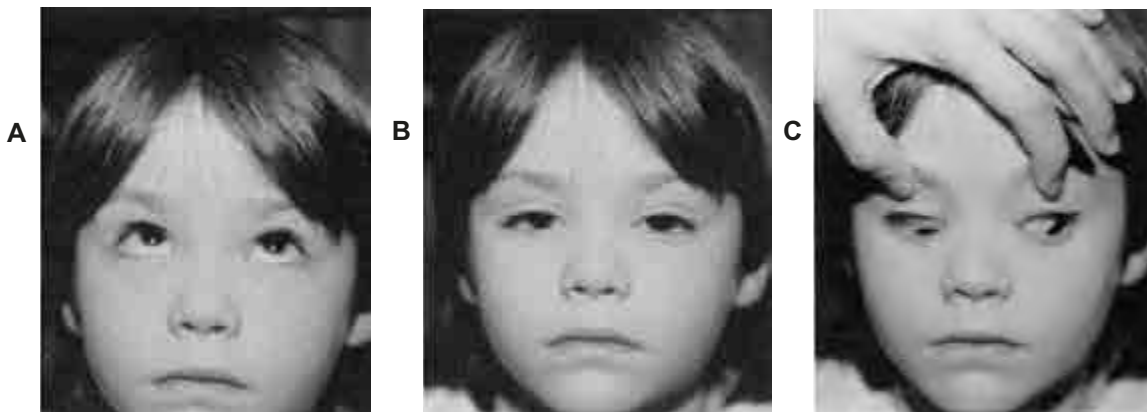
Re-recess both medial recti 2 mm with one half to three quarters muscle width *upshift*.

Comment

An 'A' pattern vertical incomitance may occur with or without apparent superior oblique muscle overaction. On the other hand, 'V' pattern is almost always associated with overaction of the inferior obliques. 'A' pattern without superior oblique overaction occurs in some cases when the medial recti have been recessed. The pattern probably is due to altered mechanics, as is the case in my opinion with most apparent oblique muscle overaction causing greater exodeviation (less esodeviation) in upgaze or downgaze. The principle of vertical displacement of the horizontal recti can be applied in *any* vertical incomitance occurring without oblique dysfunction. The medial recti are moved to the 'closed' end and the lateral recti are moved to the 'open' end. The usual amount of vertical shift is one-half to one muscle width.

CASE 11: 'A' exotropia after bimedial rectus recession

Clinical picture



'A' exotropia after bimedial rectus recession

- A upgaze
- B primary position
- C downgaze.

History

This 4-year-old girl had recession of both medial recti to 9.5 mm from the limbus at age 11 months. Gradually since that time she has been noted by her parents to be "wall eyed" when she looks down to eat or to look at books. Her parents say she holds her chin down "a lot" and tends to look up.

Examination

Visual acuity is 20/40 in each eye with linear E vision testing. Refraction after cycloplegia is OD +1.75 and OS +1.25. The eyes are aligned in the primary position. Five prism diopters of esotropia is measured in upgaze and 60 prism diopters of exotropia is measured in downgaze. The superior obliques are 2+ overacting. Stereo acuity is nil. The remainder of the eye examination is unremarkable.

Diagnosis

'A' exotropia after bimedial rectus recession with overaction of the superior oblique muscles.

Treatment/Surgery

Bilateral superior oblique weakening (tenectomy or recession).

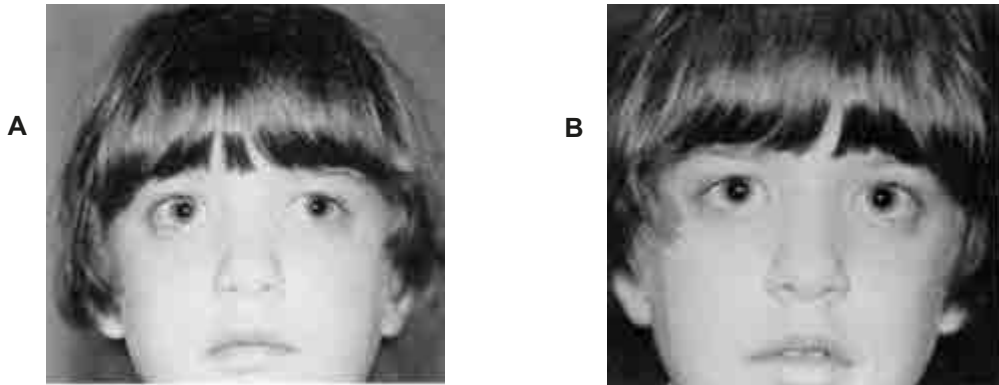
Comment

When instead of an esodeviation in upgaze, as occurs in the preceding case, an exodeviation in downgaze occurs, causing an 'A' pattern, a different surgical approach is indicated. My choice, in this case, would be bilateral weakening of the superior obliques if the eyes were aligned or nearly so, as shown in the case above. If, on the other hand, an exodeviation greater than 10 or 15 prism diopters is present in the primary position, bilateral lateral rectus recession of a small amount (3 to 4 mm) is combined with a one-half to one muscle width *downshift*.

In this case, even though the superior obliques are 'overacting' because of the altered medial rectus insertion, they are weakened. This will balance the muscle forces as they are so as to achieve alignment.

CASE 12: Basic pattern intermittent exotropia

Clinical picture



Cover testing reveals 25 prism diopter intermittent exotropia at near.
A 30 prism diopter exotropia at distance
B straight eyes near

History

This 9-year-old girl was brought in by her parents, who report that their daughter's eye had wandered out occasionally from the time she started walking. They now see the left eye out 30% to 50% of the time.

Examination

Visual acuity is OD 20/30-1 and OS 20/25-1. Cycloplegic refraction is OD + 1.50 and OS + 1.00. She fuses 6/9 stereo dots (80 seconds). The prism and cover test shows exotropia of 30 prism diopters in the distance and 25 prism diopters intermittent exotropia at near. Near point of convergence is to the bridge of the nose (<2 cm). No oblique over- or underaction or 'A' or 'V' pattern is noted. The child has no symptoms, but on direct questioning her parents say she "always" closes the left eye when outdoors in bright sunlight. The remainder of the eye examination is normal.

Diagnosis

Basic pattern intermittent exotropia.

Treatment/Surgery

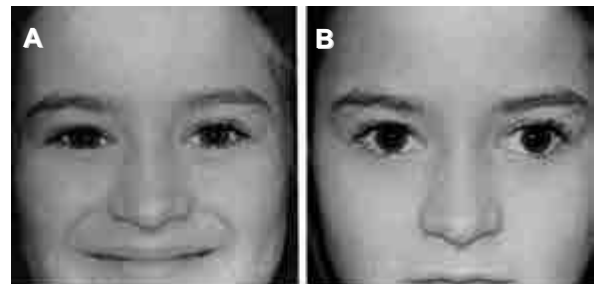
Bilateral lateral rectus recession 6.0 mm.

Comment

This patient presents a typical clinical picture of a child with basic intermittent exotropia. This may be treated with bilateral lateral rectus recessions or with a recession of the lateral rectus and a resection of the medial rectus. I prefer to avoid resecting a muscle if a successful result can be obtained with a

recession. A recession procedure is tissue sparing and causes less redness and tissue heaping in the anterior part of the eye.

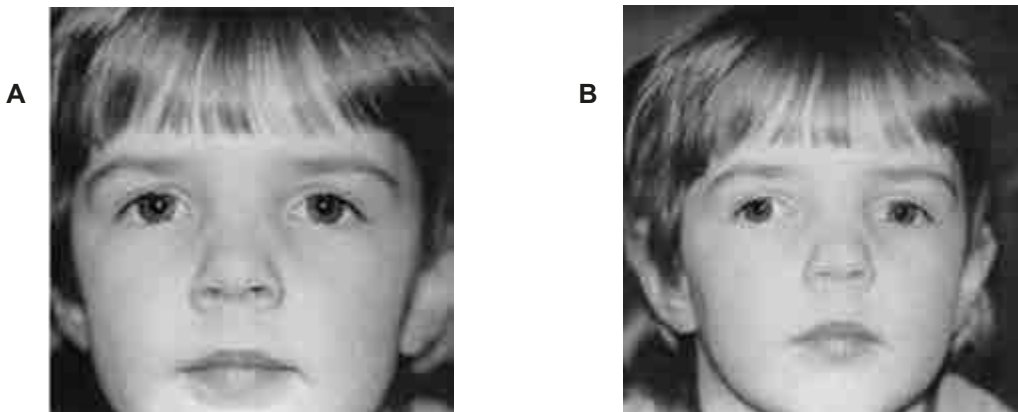
This child has had a long history of intermittent exotropia. It is likely that the deviation had been intermittent at distance but it gradually decompensated to a nearly constant deviation. If this child had been seen at age 3 instead of 9 years, a period of observation would have been appropriate before scheduling surgery. During the observation, parents are instructed to chart their child's deviation. This activity serves the dual purpose of marking the behavior (and progress) of the deviation and ensuring that the parents understand better the aims of surgery. If in a case such as this an 'A' or 'V' pattern is present, suitable oblique muscle weakening could be carried out or, in the absence of oblique overaction, the rectus muscle insertion could be shifted upward or downward according to the pattern.



A A 6-year-old girl is shown orthotropic at near.
B She is exotropic (measuring 30 prism diopters) 90% of the time according to her parents. This moderate angle intermittent exotropia will be adequately treated with a 6.0 mm bilateral lateral rectus recession. The percent of time exodeviated does not influence the amount of surgery.

CASE 13: Divergence excess intermittent exotropia

Clinical picture



- A** The eyes are aligned at near.
B After dissociation with the cover test the eyes are 40 prism diopters exotropic and remain so until the child blinks or is reminded this her eye is “out.”

History

Over the past 2 years, this 4-year-old girl has been noted by her family to have an eye that wanders out when she is tired and when she is looking in the distance. Also, she closes her left eye almost constantly in bright sunlight. The child has been otherwise healthy and is doing well in preschool.

Examination

Visual acuity with correction is 20/25 in each eye. Retinoscopy after 1% Cyclogyl is OD +.50, OS +.75. This patient fused 7/9 stereo dots (60 seconds), and her eyes were aligned throughout the early part of the examination. Cover testing revealed 40 prism diopters of intermittent exotropia at distance. Recovery is fairly brisk, but the left eye does remain exodeviated through a blink and remains exodeviated until the patient changes fixation, usually to near, or her attention is called to the fact that the eye is out. She experiences no diplopia during this manifest phase. At near, prism and cover test measures 15 prism diopters of intermittent exotropia. Near point of convergence is to the nose. The remainder of the eye examination is completely normal. After wearing a patch over the left eye for 1 hour, near cover testing was repeated without allowing any binocular experience, and the near deviation remained 15 prism diopters intermittent exotropia.

Diagnosis

Divergence excess intermittent exotropia.

Treatment/Surgery

Bilateral lateral rectus recessing 7.0 mm.

Comment

This girl has a fairly classic intermittent exotropia, which is classified as a divergence excess intermittent exotropia because the distance deviation is persistently larger than the near. If, after occlusion of one eye for 1 hour cover testing at near carried out without allowing the patient to become binocular had resulted in a near deviation increasing to become equal or nearly equal to the distance deviation, this could be called a pseudo divergence excess intermittent exotropia. If the distance and near deviation had been equal from the outset, basic exotropia would be the diagnosis. Most patients with intermittent exotropia do well with surgery. However, patients with divergence excess intermittent exotropia may have esotropia at near postoperatively, producing bothersome diplopia and requiring base-out prism. Such treatment may be prolonged for a few weeks or months. In a few cases it has been necessary to recess one or both medial recti in older symptomatic patients. This in turn could cause a return of the distance exodeviation. This response is rare. The amount of surgery is dependent on the *angle* of deviation. A smaller angle of exodeviation requires a smaller amount of surgery and vice versa, but the *timing* of intermittent exotropia surgery is done on the basis of how *often* the eye is deviated, not by how *far* the eye is out.

CASE 14: Convergence insufficiency intermittent exotropia

Clinical picture



History

A 35-year-old woman was seen initially with a complaint that her left eye “jumped up and down” and that both eyes turned out. Mild ptosis of the left upper lid was an incidental finding. This had been present for many years, according to the patient, who also stated that she saw double most of the time at near. She particularly had trouble with reading, causing her great difficulty in her job as a secretary.

Examination

Visual acuity with myopic correction showed OD 20/20 and OS 20/20, near 20/20. Her glasses were OD -2.00 +0.50 X 180 degrees and OS -2.00 +0.50 X 180 degrees. Prism and cover measurement at distance was 18 prism diopters of intermittent exotropia and near 30 prism diopters of intermittent exotropia. Near point of convergence was remote. The patient fused 8/9 stereo dots (50 seconds). There was slight overaction of the inferior oblique muscles, producing a small ‘V’ pattern. The remainder of the eye examination was normal.

Diagnosis

Convergence insufficiency intermittent exotropia.

Treatment

Near point of convergence ‘push up’ exercises can be helpful. Base-in prism is a possible short-term treatment.

Surgery

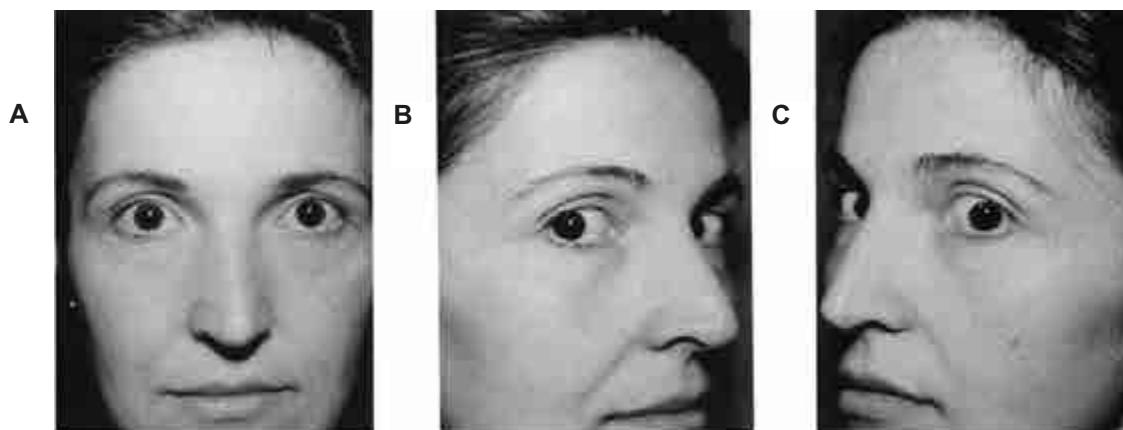
Recession left lateral rectus 5 mm, resection left medial rectus 5 mm, or bimedial rectus resection 5 mm.

Comment

Convergence insufficiency intermittent exotropia usually occurs in adulthood but may be seen in children. Symptoms are usually as noted here; that is, trouble concentrating for a prolonged period of time on near objects with or without diplopia. The near point of convergence is routinely remote. Often, as in this case, Stereo acuity is excellent. However, this excellent potential for binocular vision cannot be sustained comfortably for long periods. Some patients with this type of problem are helped by near point of convergence, ‘pencil push up’ training. This condition may be the one best treated with orthoptic exercises. However, many patients are unable to sustain comfortable near vision even with orthoptic exercises, and surgery is needed in those cases. Surgery may be a recess/resect procedure or a bimedial rectus resection. These patients, especially those having bimedial rectus resection, often have significant overcorrection in the early postoperative course. This requires temporary treatment with base-out Fresnel prism and of course patience and time. The recess/resect procedure has the advantage that it produces incomitance that allows fusion with a slight head turn. This more or less ‘buys time’ while the near overcorrection is resolving. The surgical treatment of convergence insufficiency should be undertaken only with the understanding that the postsurgical treatment course is complicated by varying periods of diplopia. Before deciding on the type of surgery, the surgeon must recognize that a bimedial rectus resection produces a postoperative condition where, in the presence of an overcorrection, no head posture can be assumed to avoid the diplopia. Diplopia after bimedial rectus resection must either be treated early on with prism or by occluding one eye.

CASE 15: Persistent diplopia after surgery for intermittent exotropia

Clinical picture



A, The eyes are aligned in the primary position; **B**, full abduction of the right eye; **C**, limited abduction of the left eye

History

This 35-year-old woman had a resection of the left medial rectus muscle and recession of the left lateral rectus muscle for what she described as an intermittent exotropia. Records from the previous surgery were not available. She complains bitterly of diplopia that is worse when she looks to the left. It is very difficult for her to carry on her work as a bank teller because of the diplopia. In order to maintain single binocular vision she must turn her head to the left and maintain eyes to the right.

Examination

Visual acuity is 20/20 in each eye without correction. The near point of accommodation is satisfactory, and the patient could read 20/20 at near easily. With 20 degrees of left face turn, 9/9 stereo acuity is recorded (40 seconds). Prism and cover testing reveals 5 prism diopters of esotropia in the primary position. The eyes are aligned in right gaze and 20 prism diopters of esotropia is found in left gaze. Abduction of the left eye is moderately restricted. Saccadic velocity to the left is observed to be brisk and equal to saccadic velocity to the right. Passive abduction of the left eye was noted to be moderately stiff. With a red lens over the right eye, the patient observed diplopia starting at 10 degrees of dextroversion and continuing through the primary position to all fields of left gaze. Single vision was present beginning at 10 degrees of dextroversion and continuing to full dextroversion.

Diagnosis

Diplopia after recession-resection for intermittent exotropia, presumably caused by a tight left medial rectus muscle.

Treatment/Surgery

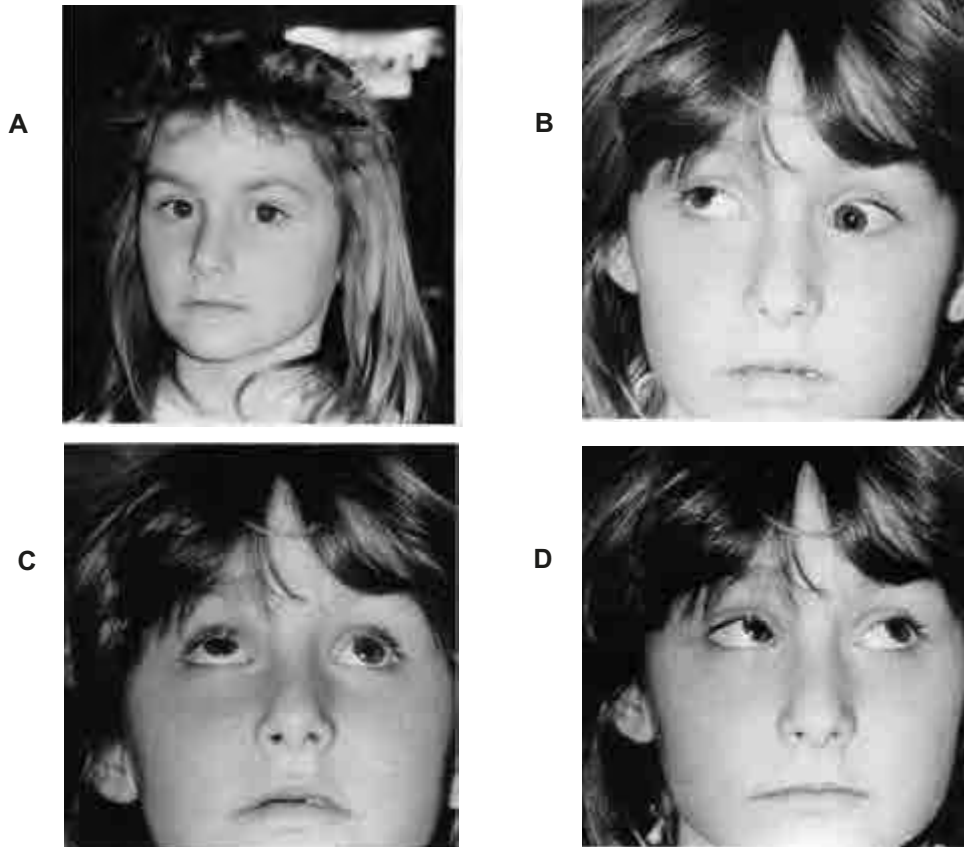
Recession of the left medial rectus muscle after forced duction testing to confirm restriction of abduction.

Comment

In a case of diplopia after surgery for intermittent exotropia such as this where ductions are definitely limited either because of mechanical restriction or muscle weakness, prompt repeat surgery is indicated. This is in sharp contrast to the overcorrected intermittent exotropia patient with perfectly free ductions who should be treated conservatively, often for periods of months, with prism for the diplopia. The precise amount of surgery to be done in a case like this cannot be determined arbitrarily on the basis of the deviation. In most cases a small recession of the previously resected muscle will suffice. This type of case is ideally suited for an adjustable suture recession. Even after successful surgery such a patient may be able to 'find' diplopia by looking far to the left. In cases like this, I stress to the patient that the surgery is a success and that they should remain satisfied as long as they must "find" the diplopia and the diplopia does not "find" them!

CASE 16: Congenital Brown syndrome

Clinical picture



Congenital Brown syndrome in left eye. **A**, The chin is up and pointing to the right; **B**, downshoot of the left eye while attempting to look up and to the right; **C**, moderate limitation of elevation left eye in upgaze; **D**, no limitation of elevation of the left eye in abduction

History

Shortly after she started to walk, this 7-year-old girl was noted by her parents to persistently keep her chin up. The family also noticed that the left eye looked “different” at times. This child has otherwise been perfectly healthy with no ocular problems or systemic complaints.

Examination

During casual observation of this patient while obtaining this history she assumes a head posture with her chin pointing slightly up and to the right. Visual acuity is 20/20 in each eye. Stereo acuity is measured to 40 seconds (9/9 dots). During versions, the left eye did not elevate in adduction. The left eye actually dips down below midline in dextroversion. Elevation is moderately limited in straight upgaze

and is not limited in gaze up and to the left. The remainder of the eye examination is normal. The neck is supple with no apparent orthopedic cause for the head posture. Because of the young patient’s lack of cooperation, it is impossible to do forced duction testing in the clinic. Finding a restriction on attempted passive elevation of the left eye in adduction would have confirmed the diagnosis of Brown syndrome and would have differentiated it from left inferior oblique palsy. However, given the rarity of inferior oblique palsy compared to Brown syndrome and the degree of limitation to elevation in straight up gaze, the presumptive diagnosis of Brown syndrome can be made with confidence. Of course, this must be confirmed by passive duction testing done in the operating room before surgery.

Diagnosis

Congenital Brown syndrome.

Treatment/Surgery

Exploration of the left superior oblique tendon, find and treat any restriction

Comment

Brown syndrome is best thought of as a mechanical restriction to the full separation of the trochlea and the superior oblique insertion in elevation and adduction. It must be recognized that it can have many causes and if it is to be cured, it will require different treatments. Brown believed that an abnormally restrictive sheath around the superior oblique tendon, the principal structure connecting the trochlea and the insertion of the superior oblique tendon into sclera was the cause of Brown syndrome. Cutting the superior oblique tendon remains the most effective way to relieve the restriction. In most cases this would solve the problem if the restriction is caused by a tendon or trochlear anomaly. The closer to the trochlea the superior oblique tendon is cut, the more likely the restriction is to be eliminated. Postoperative superior oblique palsy occurs for the same reason as the Brown is cured! About one-third of patients having superior oblique tenectomy for Brown syndrome have superior oblique underaction postoperatively and need inferior oblique weakening as a second procedure. For this reason, I do not recommend inferior oblique weakening at the same procedure as superior oblique tenectomy in treating Brown syndrome. Use of a silicone expander to lengthen the superior oblique tendon has been sug-

gested by Wright and is being done by many surgeons with success.

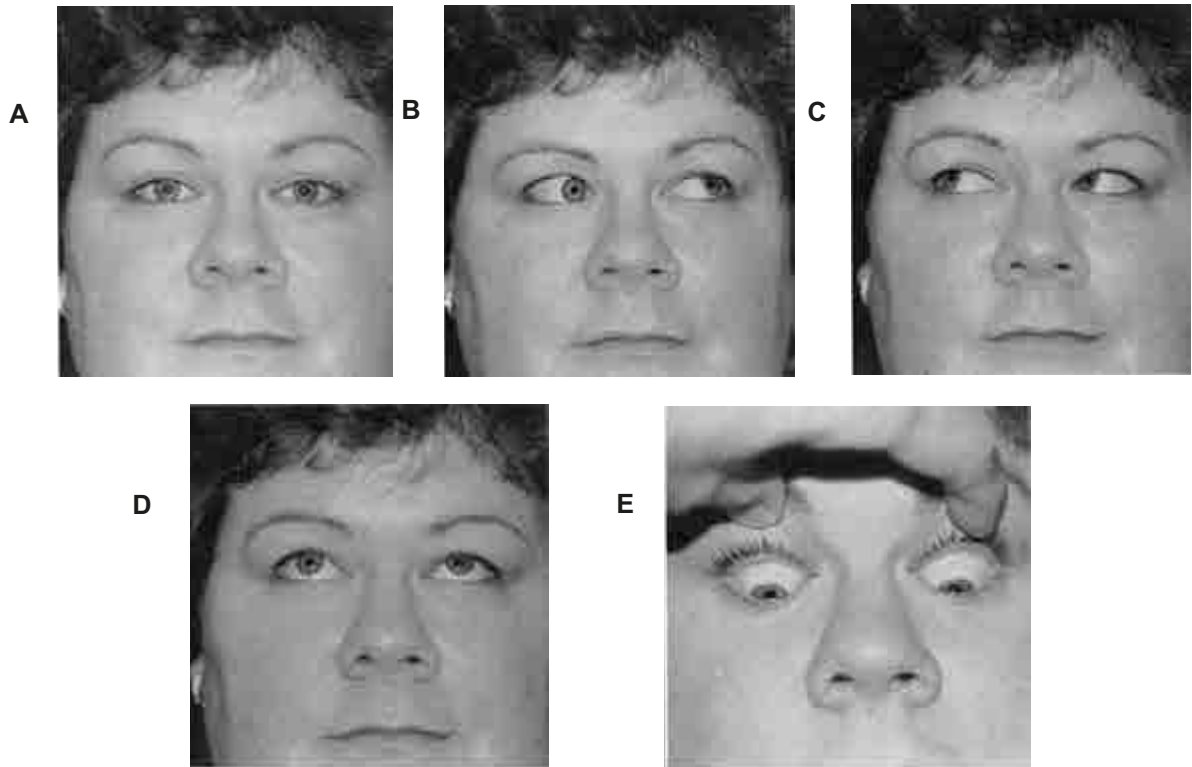A major frustration in the surgical management of Brown syndrome is that passive ductions may be freed at the time of surgery only to become severely restricted again in the postoperative period. Because of this, the eye may be sutured in the adducted elevated position with a traction suture for several days postoperatively. This apparently logical maneuver is not done often. In rare cases of Brown syndrome, disinsertion of the posterior seven-eighths of the superior oblique tendon insertion has been effective. This only underscores the fact that this condition, which is really a physical sign rather than a disease process, has multiple etiologies and should be expected to have multiple remedies.

I now prefer to treat Brown syndrome after securing exposure of the entire tendon after a cuffed superior limbal incision. This offers a good view of the anatomy and enables specific treatment of the cause of the Brown (see chapter 6).

In young children with Brown syndrome, an indirect technique for performing the equivalent of passive ductions is the differential intraocular pressure test. A tonometer is used to record intraocular pressure in the primary position and also during attempts at elevating the left eye in adduction. A pressure rise of 5 to 10 mm Hg on attempted elevation indicates that the inferior oblique is contracting in the face of a nonyielding antagonist, implying a mechanical restriction to elevation. If no pressure rise occurs, a paresis of the inferior oblique is inferred (see p.103).

CASE 17: Acquired Brown syndrome

Clinical picture



Acquired Brown syndrome of the right eye with limitation of elevation in adduction.

- A** primary position, eyes are aligned
B elevation of the right eye limited in gaze up to the left
C normal motility up and to the right
D normal upgaze
E normal downgaze

History

This 36-year-old woman noted the sudden onset of diplopia only when looking up 4 months ago. The diplopia typically lasted for a few hours and then went away. It recurred on a daily basis and now happens several times a day. The double vision is associated with a full feeling in the corner of the right eye, and she has heard a “click” and felt a “rub” in the corner of the right eye during these episodes of double vision. No other health problems are evident.

Examination

The initial eye examination was normal: 20/20 vision in each eye, stereoacuity at 9/9 dots (40 seconds), and orthophoria is seen in the primary position. After several minutes of testing versions, the

right eye suddenly became “stuck” and would not elevate in adduction. At this time a soft nontender mass could be felt just below the trochlear area at the inner aspect of the junction of the medial and superior orbital rim.

Diagnosis

Acquired Brown syndrome, probably cyst of superior oblique tendon.

Treatment/Surgery

Exploration of the superior oblique tendon after a cuffed limbal incision with excision of the cyst.

Comment

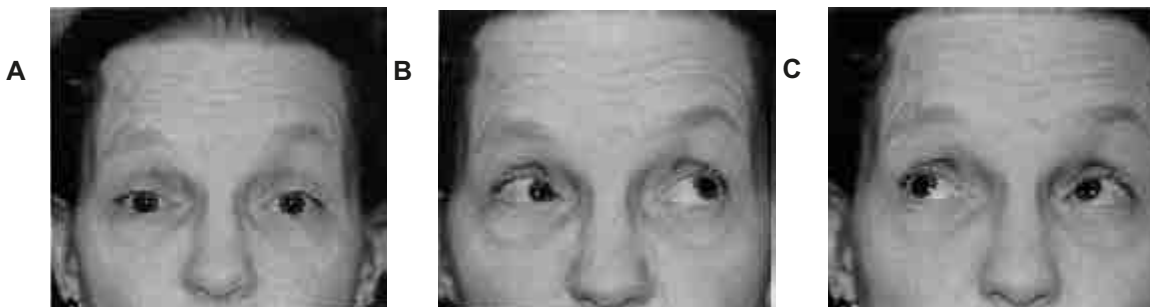This case describes just one of many causes of acquired Brown syndrome (see chapter 9) Other somewhat similar cases that I have seen have been associated with a painful or at least tender spot in the area of the trochlea with a constant or intermittent limitation of elevation. Tenderness associated with a feeling of induration on palpation suggests inflammation. I have treated several such patients with injection of soluble steroid in the area of the trochlear cuff but not into the trochlea itself. Several patients have required repeated injections, but all cases have resolved.

Acquired Brown syndrome from trauma to the area of the trochlea and the superior oblique tendon presents a formidable therapeutic challenge. Because results of treatment of this and what has been called canine tooth syndrome or Class VII superior oblique

palsy are so disappointing, it is better to leave these patients untreated, provided the symptoms are not too great. The Brown syndrome caused by trauma to the trochlear area tends to recur after surgery, producing poor surgical results. Iatrogenic Brown syndrome also occurs after too large a tuck or resection of the superior oblique tendon. At reoperation to take down a tuck or recess a previously resected tendon, the amount of adhesions and therefore the difficulty of exposure will depend largely on the care and precision of the original surgery. If the surgery had been done primarily on the temporal side, near the superior oblique insertion, the reoperation is much easier. However, when significant scar and reaction is found in the area of the tuck, a tenectomy can be done with good results. It is best to avoid tucking the superior oblique tendon medial to the superior rectus.

CASE 18: Iatrogenic Brown syndrome

Clinical picture



A 55-year-old woman with iatrogenic Brown syndrome of the right eye after superior oblique resection for right superior oblique palsy. **A**, Eyes are aligned in primary position; **B**, right eye shows limited elevation in adduction; **C**, normal motility up and to the right.

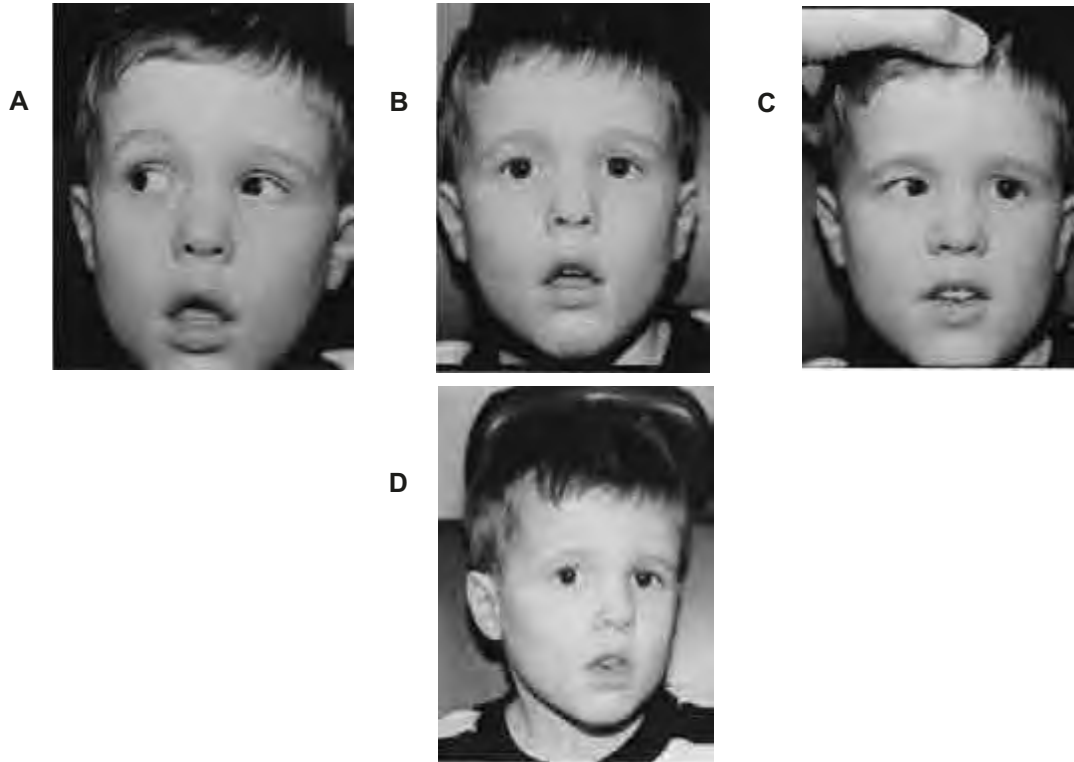
Comment

This 55-year-old woman had right superior oblique resection and right superior rectus recession for class IV acquired superior oblique palsy (see p. 155). In spite of a small (6.0 mm) superior oblique tuck, iatrogenic Brown syndrome of the right eye is evident. Before the superior oblique resection, this patient had 30 prism diopters of right hypertropia in left gaze and slightly less in down right gaze. After surgery the eyes were aligned in the primary position and less than 5 prism diopters of intermittent right hypertropia was measured in downgaze. The patient is extremely pleased with the results of surgery and is

able to carry out her work as a cashier in a school cafeteria symptom free. She is able to notice diplopia looking up and to the left, but she has no difficulty avoiding this field. Other patients with less Brown syndrome after superior oblique shortening have complained bitterly to the point of being inconsolable. This points out the fact that tolerance of patients to minor inconveniences in the postoperative period varies greatly. For this reason, all of these patients should be counselled thoroughly before surgery. Iatrogenic Brown syndrome like this also tends to lessen with time (see p. 395).

CASE 19: Duane syndrome with esotropia (class I)

Clinical picture



A, Minimal narrowing of left palpebral fissure on right gaze; **B**, slight left esotropia in primary position; **C**, limited abduction of the left eye; **D**, left face turn and right gaze to achieve comfortable single binocular vision.

History

This 7-year-old boy was presented for examination by his parents because his first grade teacher said that the boy turned his head constantly. In retrospect, the parents realized that they had also noted this behavior but had not thought it to be significant.

Examination

The patient's slight left face turn presents a typical picture that can be diagnosed at once by the experienced observer. With the head straightened, the left eye becomes slightly esotropic. The left palpebral fissure narrows somewhat on dextroversion and the left eye fails to abduct fully on levoversion. The remainder of the eye examination is normal. Visual acuity is 20/20 in each eye, retinoscopy after 1% Cyclogyl is OD +1.00, OS +1.00, and Stereo acuity, with left face turn and eyes right, is at 9/9 dots (40 seconds).

Diagnosis

Duane syndrome with esotropia (class I).

Treatment/Surgery

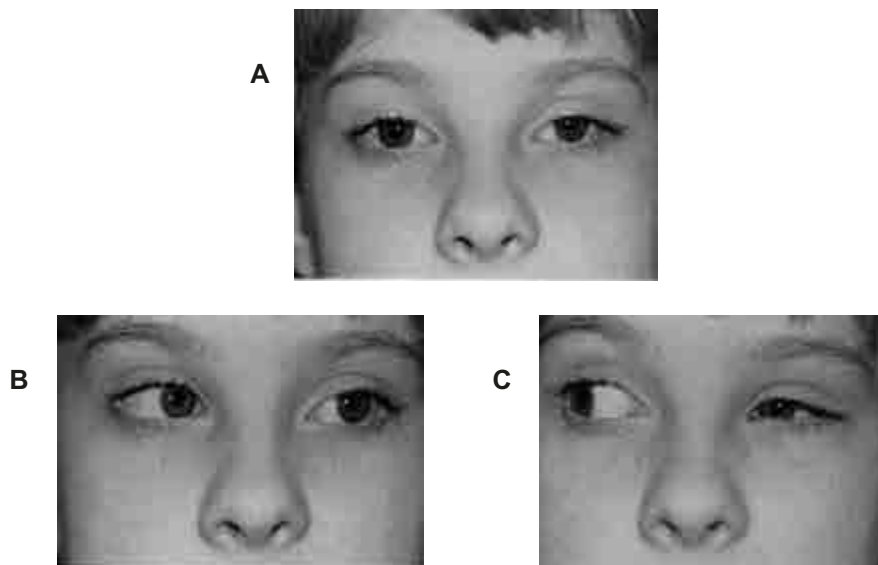
Recession of the left medial rectus.

Comment

These patients can do well with surgery. However, it is necessary to tell the patient and/or the family that the main reason for the surgery is to improve head posture and allow the patient to have straight eyes in the primary position with a straight head. Abduction will *not* be improved. For this reason, some surgeons suggest placing a posterior fixation suture on the contralateral (right in this case) medial rectus. In mild esotropic Duane syndrome (class I), some surgeons have recommended transferring the superior an inferior recti to the lateral rectus. I have not done this and do not recommend it because of the risk of producing an exotropic Duane (class II) with severe enophthalmos on attempted adduction postoperatively and also the possibility of creating a vertical deviation in the primary position. Class I Duane syndrome and any of the types discussed subsequently can be bilateral. In the case of bilateral involvement, appropriate surgery is done on both eyes.

CASE 20: Exotropic Duane syndrome with limited adduction (class II)

Clinical picture



A, Primary position eyes are slightly exotropic; B, slightly limited abduction; C, limited adduction with narrowing of the left palpebral fissure

History

This 10-year-old girl had no trouble with her eyes, but her parents noted that at times her eyes did not seem to work together and that she turned her face to the right when reading. The left eye is also seen to “shoot up.”

Examination

Observing this girl it is evident that she has a 10-degree right face turn. Testing of versions confirms reduced adduction of the left eye with narrowing of the palpebral fissure and enophthalmos. Upshoot of the left eye on adduction was observed. Visual acuity is 20/20 in each eye. Retinoscopy after 1% Cyclogyl is OD +1.50 and OS +1.00 +.50 X 80 degrees. The remainder of the eye examination was unremarkable. The stereo fly test indicated gross stereopsis (3000 sec).

Diagnosis

Duane syndrome with exotropia and limited adduction left eye (class II).

Treatment/Surgery

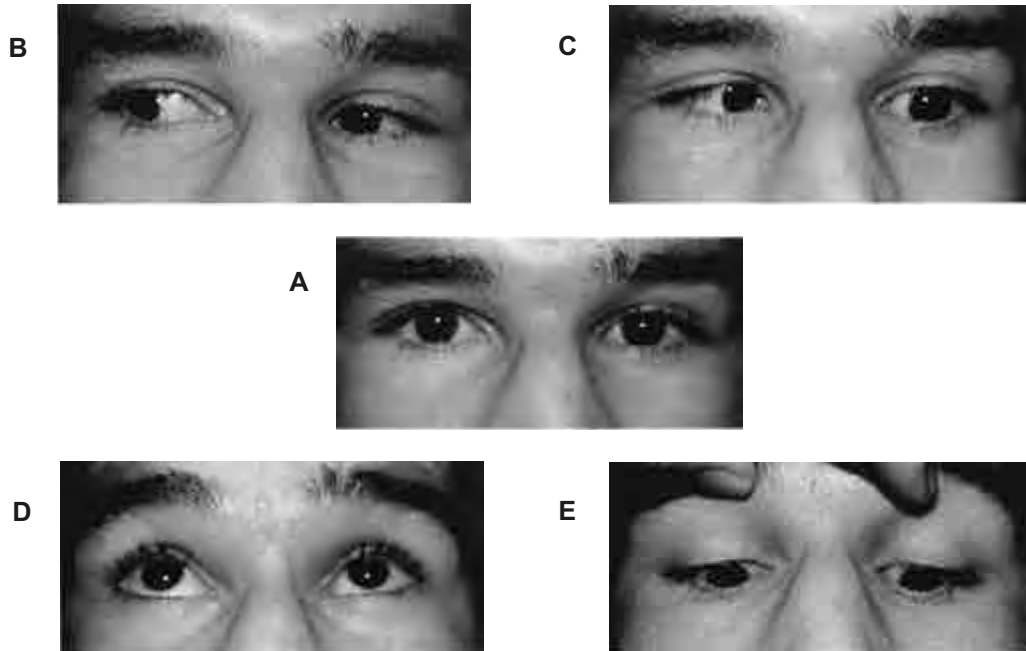
This patient may benefit from a right lateral rectus recession alone. If the upshoot is a problem, both the medial and lateral recti may be recessed. If it is believed that this will produce too much exodeviation, the lateral rectus of the sound eye may be recessed.

Comment

The principal aim of this surgery is to achieve normal head posture, maintain aligned eyes in the primary position, and reduce upshoots and downshoots without disrupting fusion. Success can be measured as a factor of how well these goals are met.

CASE 21: Duane syndrome with straight eyes and limited abduction and adduction (class III)

Clinical picture



A, In primary position, the eyes are aligned; **B**, left eye adduction is slightly limited with mild fissure narrowing on the left; **C**, left eye abduction is moderately limited; **D**, elevation is intact; **E**, depression is intact.

History

This 15-year old boy's left eye has always "looked funny," according to the family. He reports frequent double vision. At times the left eye seems to go "out of sight."

Examination

Visual acuity is 20/20 in each eye and stereoacuity is 6/9 dots (80 seconds). Both abduction and adduction are moderately limited. On extreme attempts to *adduct* the left eye, it shoots up under the upper lid and the pupil cannot be seen. If the eye attempts to adduct while looking slightly below midline, the eye shoots down but the cornea is less obscured by the lower lid.* The eyes are aligned in the primary position as the patient assumes a slight right face turn.

Diagnosis

Duane syndrome with straight eyes and limited abduction and adduction (class III).

Treatment/Surgery

Recession of the left medial and left lateral rectus muscles, or no surgery.

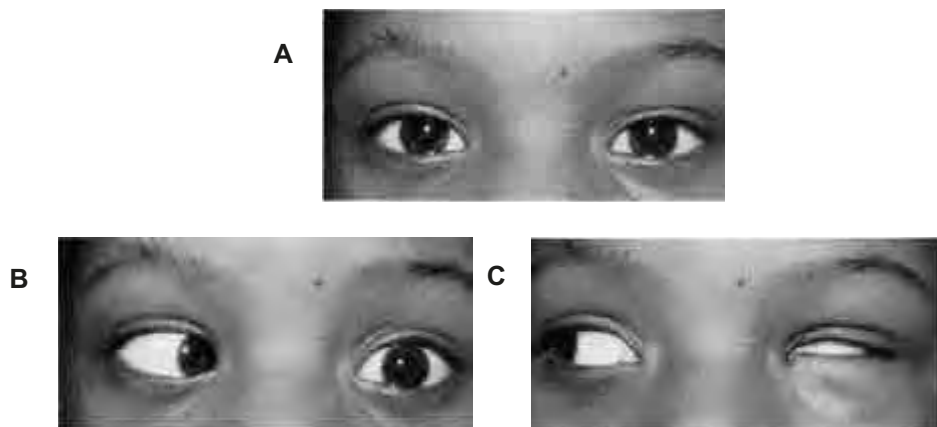
*The up and down shoot are not shown in the clinical photographs. Actually this never occurs unless the patient makes it happen. The patient's main complaint is a feeling of "tightness" of the left eye.

Comment

The principal reason for doing this surgery is to reduce the enophthalmos and the upshoot (and downshoot). Weakening the two opposing rectus muscles of the involved eye is designed to accomplish this without adversely affecting the primary position alignment. This type of Duane syndrome with severe enophthalmos and up- and downshoots can also have an esotropia in the primary position. If this is the case, recessing the opposing horizontal recti will mean that the esodeviation in the primary position persists. When this type of patient is encountered, in addition to recessing both horizontal recti in the involved eye, the medial rectus of the uninvolved eye

is also recessed. The three recession procedure is not commonly done but with this rare indication it is effective.

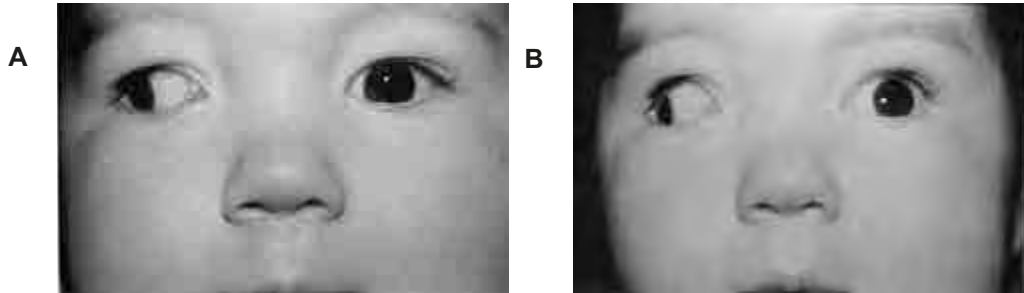
To lessen the up- and downshoot associated with this type of Duane syndrome, 'Y' splitting of the insertion of the lateral rectus muscle of the involved eye may be done, with or without recession. Another surgical treatment is to do a posterior fixation suture on the lateral rectus of the involved eye. Both this and the 'Y' split are intended to keep the lateral rectus from slipping above or below the horizontal plane of the lateral rectus where it becomes either an elevator or depressor.



This 6-year-old girl has a more severe manifestation of "straight-eyed" Duane syndrome or class III according to the Huber classification. She demonstrates the 'disappearing eye' or the 'pumpkin seed' sign where the eye disappears usually beneath the upper lid on adduction. **A**, The eyes are aligned in the primary position; **B**, abduction in the left eye is limited; **C**, during adduction the palpebral fissure narrows markedly and the left eye "shoots up" under the lid because of the "knife edge" created by the nonyielding left lateral rectus in response to the vigorous contraction of the left medial rectus.

CASE 22: Duane syndrome with simultaneous abduction (class IV)

Clinical picture



A, Large exotropia; B, the left eye abducts on dextroversion.

History

This 18-month-old boy was noted by his parents to have widely divergent eyes that never worked together from birth. The child was also diagnosed as having arthrogyriposis multiplex congenita at age 1 year.

Examination

This child had stiff joints, especially in the hands. Vision appeared to be normal in each eye. An exotropia of 50 prism diopters was present in the primary position with left eye fixation. On gaze to the left the exotropia reduced to approximately 40 prism diopters. On *right* gaze the exotropia increased to more than 100 prism diopters because the *left eye abducted* at the same time the right eye *abducted* in the way it was expected to while looking to the right.

Diagnosis

Duane syndrome with simultaneous abduction (perversion of the extraocular muscles) (class IV).

Treatment/Surgery

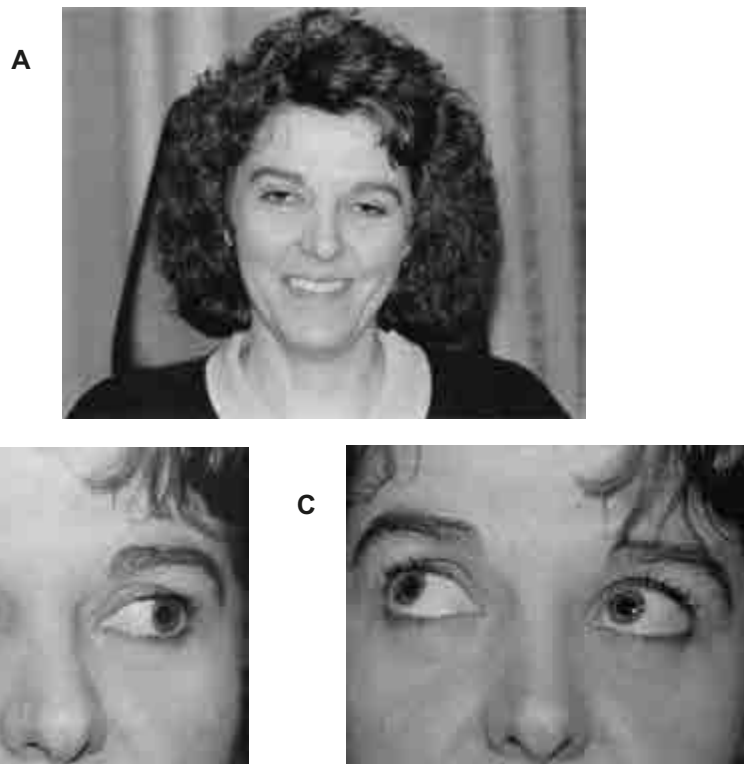Recession of both lateral recti greater on the left with resection of the left medial rectus.

Comment

This type of patient is very unusual; I have seen only a handful in the past 40 years. The reason for the simultaneous abduction seems to be misdirection of the third nerve fibers from the medial rectus, which innervate the lateral rectus, as is known to occur in other Duane syndrome patients. Added to this condition is the fact that the involved eye is so far in abduction that when the co-contraction is initiated, the balance of forces is tipped over toward the lateral rectus, which overcomes the opposing effort of the medial rectus contraction. Repositioning the muscles at surgery has no effect on the innervation pattern, meaning that after alignment is obtained, if indeed this is even possible, the problems of the co-contraction will remain. However, if the exotropia is reduced substantially, simultaneous abduction should not occur simply because of alteration of the mechanical lever arm that is taken away in this case from the left lateral rectus. This type of Duane syndrome with simultaneous abduction could be confused with congenital third nerve palsy on the basis of the large exotropia. Several points of difference include absence of ptosis and normal pupil response. In addition, simultaneous abduction is not a part of third nerve palsy, even with misdirected regeneration of the third nerve fibers.

CASE 23: Class I superior oblique palsy

Clinical picture



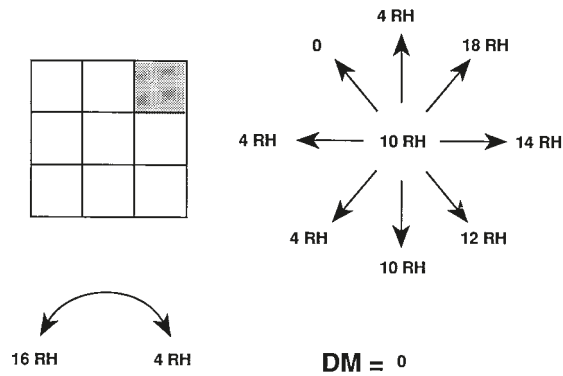
A, The head is tilted left with slight chin depression. **B**, On upgaze to the left, moderate overaction of the right inferior oblique can be seen. **C**, Motility is normal on gaze up and to the right. Moderate facial asymmetry is characterized by a fuller face on the right.

History

This 34-year-old woman complained of vertical diplopia that was better if she tilted her head to the left and tipped her chin down. She is now concerned because it is becoming more difficult for her to work for long periods at a computer, a task that her job requires.

Examination

Visual acuity is right eye 20/30-2 and left eye 20/40 corrected to 20/20 in each eye with -0.75 sphere. Versions show 2+ overaction of the right inferior oblique with normal action of all other muscles. Stereo acuity was 9/9 dots (40 seconds). Prism and cover testing shows 10 prism diopters of right hypertropia in the primary position, increasing to 14 prism diopters of right hypertropia in left gaze. A small right hypertropia is measured in right and downgaze, while 4 prism diopters of right hypertropia is noted in upgaze. With the Bielschowsky head tilt, the right hypertropia increases to 16 prism diopters on right head tilt and decreases to 4 prism diopters right hypertropia on head tilt to the left. No cyclotropia is noted with double Maddox rod test. The remainder of the eye examination is normal.



Diagnosis

Class I right superior oblique palsy.

Treatment/Surgery

Right inferior oblique myectomy.


Comment

This woman demonstrates a class I superior oblique palsy producing a moderate-sized, incomitant right hypertropia manifesting principally as overaction of the right inferior oblique. Traction testing of the superior oblique at surgery demonstrated a lax superior oblique tendon on the right and a normal tendon on the left. Because of the small angle and minimal superior oblique findings as well as the fact that the superior oblique had normal function and the inferior oblique overaction was the main motility problem, this patient was best treated with a right inferior

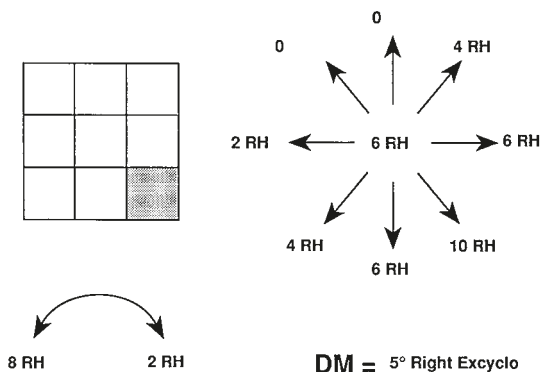
oblique myectomy. Although it is likely that this is a congenital superior oblique palsy because of the lax superior oblique traction test and absence of history for trauma, this type of picture, but with a normal superior oblique tendon on traction testing, is seen very commonly in acquired superior oblique palsy. It should be strongly emphasized here that the safest surgical procedure for patients with superior oblique palsy is a weakening procedure of the antagonist inferior oblique. It is difficult to go wrong when this procedure is done properly. Treatment other than an inferior oblique weakening in superior oblique palsy should be undertaken only after carefully analysis of all measurements. These include especially the diagnostic position prism and cover measurements and the intraoperative superior oblique traction test findings.

CASE 24: Class II acquired oblique palsy

Clinical picture



This patient's appearance is normal but he complains of vertical diplopia.



History

This 87-year-old man began to note double vision 6 weeks earlier. Images were separated vertically, causing him difficulty in reading the newspaper and in watching television. He also stopped driving his automobile, which he used only for short daytime trips in a familiar area. He states that he takes some blood pressure medication prescribed by his internist and that his blood pressure is satisfactorily controlled. When the double vision started, this man was referred to a neurologist by his internist. A CT scan and MRI of the head were said to be normal. Lumbar puncture findings, blood sugar testing, and EEG were also within normal limits for a man of his age. When all of these tests were found to be in the range of normal, the man was referred to a general ophthalmologist, who then referred the patient to me.

Examination

Visual acuity with correction is OD 20/40 and OS 20/30. Slight lens opacities were thought to account for the decrease in vision. Prism and cover measurements were 6 prism diopters right hypertropia in the primary position, 4 prism diopters in up left gaze, and 10 prism diopters hypertropia in down left gaze. Slight underaction of the right superior oblique is noted on testing of versions. The right inferior oblique did not overact. Five degrees of exocycloptropia of the right eye is seen on testing with the double Maddox rod. Blood pressure in the left arm was 134/88.

Diagnosis

Class II acquired right superior oblique palsy.

Treatment

Fresnel prism, 6 diopters base-down, right eye.

Surgery

None.

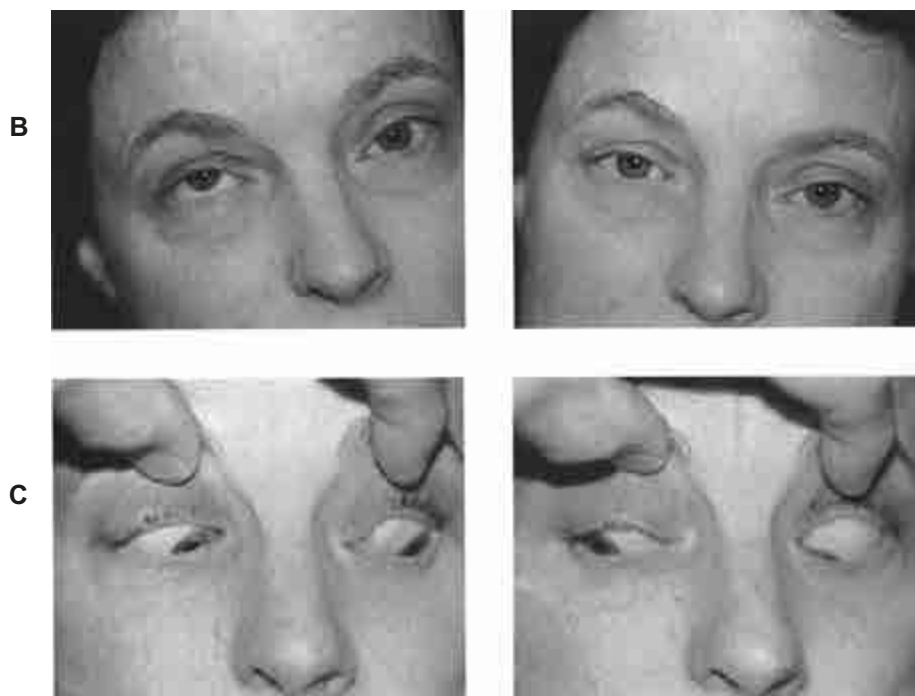
Comment

This is a typical pattern for acquired superior oblique palsy resulting from a presumed microvascular accident. These patients usually do very well with temporary prism. The deviation often resolves completely and prism therapy can be discontinued. If this does not happen, permanent prism can be given. The extensive work-up in this case was not necessary. Such an exercise should be avoided on the basis of the unnecessary expense and the inconvenience to the patient. A curious thing happened when the patient's son was told that his father had superior oblique palsy. "Is that like a trochlear palsy?" the son asked. This man's son had looked up the symptoms his father complained of in the Merck Manual* and had arrived at the proper diagnosis. A similar level of clinical acumen on the part of the patient's internist and neurologist would have spared the patient a great deal of expense and inconvenience.

*Berkow R, editor: The Merck Manual of Diagnosis and Therapy, ed 15, Rathway, NJ, 1987, Merck Sharp & Dohme. Today, the son would have obtained this kind of information on the Internet.

CASE 25: Large-angle class III congenital superior oblique palsy

Clinical picture



A, Abnormal head posture with the head tilted to the left and the chin depressed. The face is fuller on the right. **B**, The Bielschowsky head tilt test is positive for a right superior oblique palsy, as indicated by increased right hypertropia on right head tilt when compared to left head tilt. **C**, There is moderate underaction of the right superior oblique compared to the left superior oblique which appears to overact with slight underaction of the right inferior rectus.

History

This 36-year-old woman has been bothered by a deviating right eye since early childhood. She has had diplopia for as long as she can remember but was able to tilt her head to relieve it. She has worn prism glasses for many years. Her friends and associates at work comment on the fact that she tilts her head constantly.

Examination

Visual acuity with correction is OD 20/30-2 and OS 20/20. Glasses are OD -1.00 +0.50 X 60 degrees and OS -1.00 X 100 degrees with 3 diopters of base-down prism in the right lens. Prism and cover measurements are 20 prism diopters of right hypertropia in the primary position, increasing to a maximum of 35 prism diopters in up left gaze and 38 prism diopters right hypertropia in down left gaze. Five degrees of exocycloptropia is measured with the double Maddox rod. With the Bielschowsky head tilt test, there is right hypertropia of 40 on right tilt and 15 on left head tilt. There is 2+ overaction of the right inferior oblique and 2+ underaction of the right superior oblique. Stereoacuity is nil. The remainder of the examination is normal.

Diagnosis

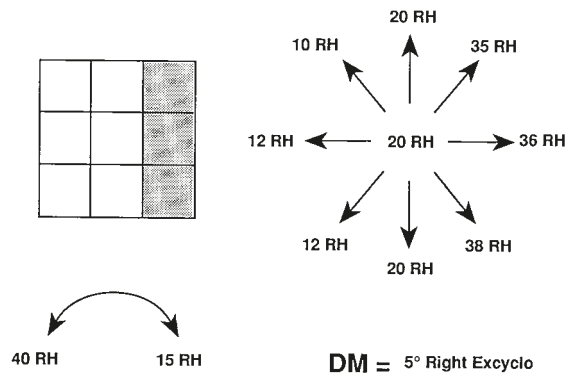
Superior oblique palsy, class III, probably congenital.

Treatment/Surgery

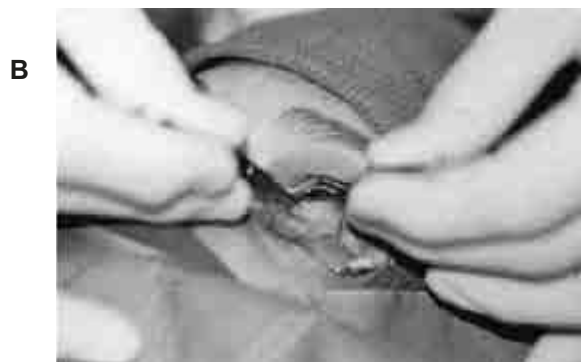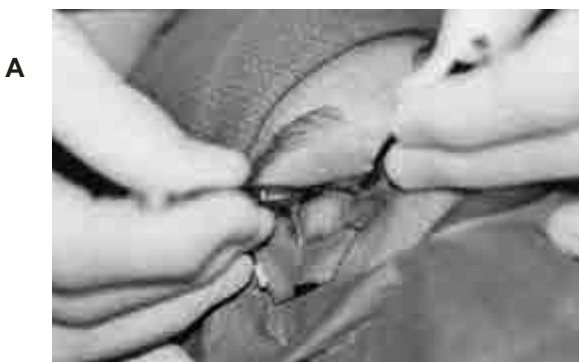Right superior oblique resection, right inferior oblique myectomy.

Comment

This patient has a classic congenital superior oblique palsy persisting into adulthood. At surgery, a



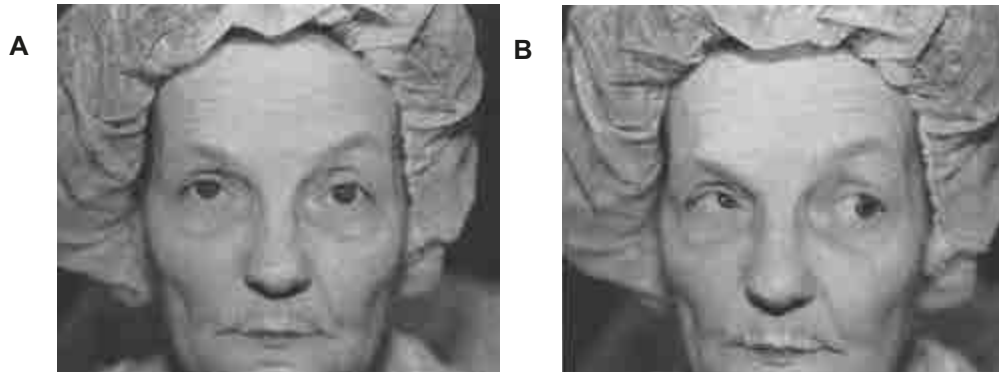
long redundant right superior oblique tendon was found. This was associated with a -4 (loose) superior oblique traction test on the right compared with a normal superior oblique traction test on the left. This type of patient does well with a tuck or resection of the superior oblique tendon. This is in contrast to the usual acquired superior oblique palsy patient who, because of an anatomically normal superior oblique tendon is much more likely to have a Brown syndrome after tuck or resection of the superior oblique tendon. I avoid tuck or resection of the superior oblique tendon in an acquired superior oblique palsy. This patient postoperatively had a moderate limitation of elevation in adduction in the right eye (Brown syndrome), but it did not bother her except when looking up and to the left, a field of gaze that she can easily avoid. Her stereoacuity was nil preoperatively. It improved to fusion of the stereo fly (3000 seconds) after surgery. The patient had a small residual intermittent right hypertropia measuring 6 to 8 prism diopters in the primary position, but she controlled this easily and without symptoms.



A, Viewed from below, the superior oblique traction test of the right eye is -4; that is, the globe is pushed back in the orbit with only a faint tactile evidence of the band formed by the superior oblique tendon between the trochlea and the insertion. **B**, In contrast, the left superior oblique traction test is normal. A band of superior oblique tendon could be felt. Note that the cornea is still visible on the normal left side (see p. 97).

CASE 26: Large class IV acquired superior oblique palsy

Clinical picture



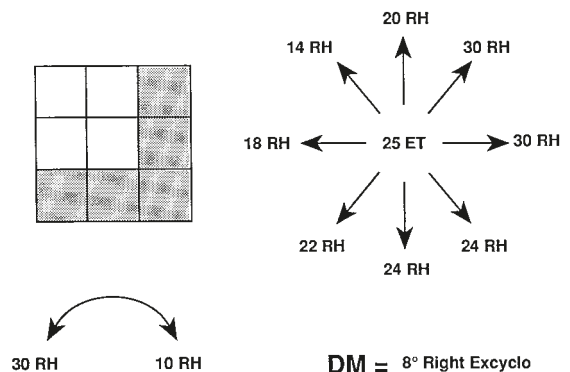
A, Right hypertropia; B, overaction of the right inferior oblique.

History

This 52-year-old woman sustained closed head trauma 24 months earlier in a motor vehicle accident. Since that time, she has been bothered by constant vertical diplopia. She is wearing heavy prism in her glasses. She wants to be rid of the prism and seeks treatment for her vertical diplopia.

Examination

Visual acuity with correction is right eye 20/20 and left eye 20/20 while wearing OD +2.00+1.50 X 22 degrees and OS +1.00+2.00 X 165 degrees. There is 9 diopters of base down prism in the right lens and 8 diopters of base-up prism in the left lens. The glasses are physically very heavy. Prism and cover testing shows 25 prism diopters of right hypertropia in the primary position increasing to 30 in left gaze and decreasing to 18 in right gaze. The right hypertropia is 24 in down left gaze and 22 in down right gaze. Eight degrees of right excyclotropia is measured. The right hypertropia increases with right head tilt. Two plus overaction of the right inferior oblique and 1+ underaction of the right superior oblique are noted. The patient fuses 6/9 stereo dots (80 seconds) with her prism glasses.



Diagnosis

Class IV acquired right superior oblique palsy.

Treatment/Surgery

Right superior oblique resection, right superior rectus recession.

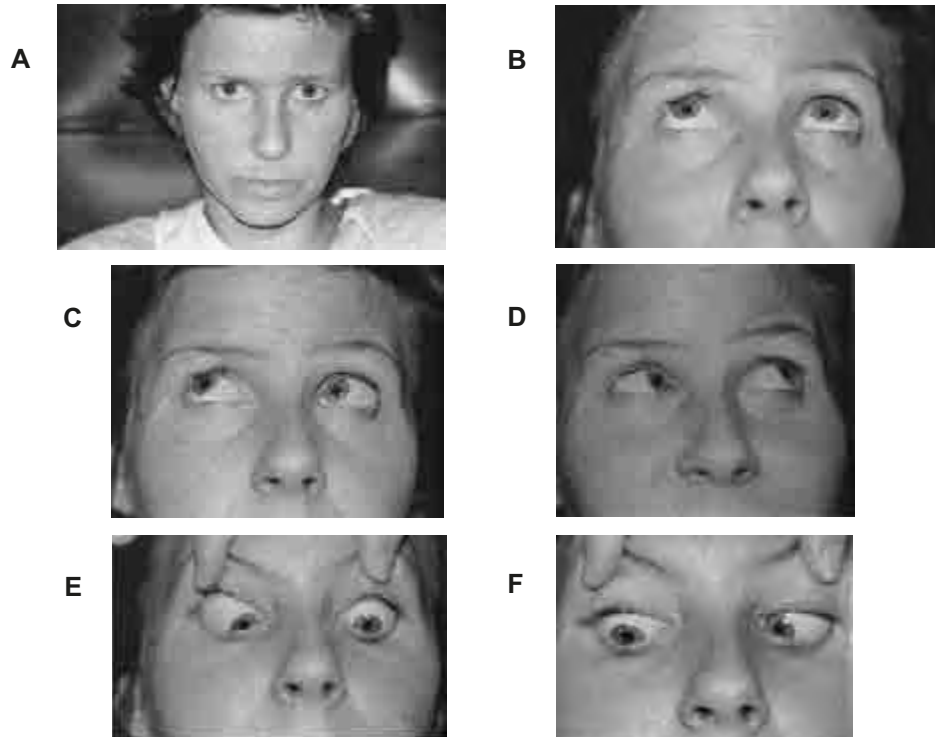
Comment

This patient had a spread of comitance because she had contracture of the right superior rectus muscle. This caused the right eye to “hang up” in down right gaze. The surgery done on this patient was aimed at decreasing the hypertropia in left gaze by resecting the right superior oblique tendon and decreasing the hypertropia in right gaze by recessing the presumably tight right superior rectus. A small, 6.0 mm resection of the right superior oblique tendon was done. This muscle was chosen for resection instead of weakening the right inferior oblique because strengthening the superior oblique would be more likely to eliminate the 8 degrees of excyclotorsion. However, weakening the antagonist inferior oblique would be a reasonable choice. The incyclotorsion effect of strengthening the right superior oblique is greater than the excyclotorsion that would be produced by recessing the superior rectus. This case stresses the importance of carefully assessing the diagnostic position measurements in a superior oblique palsy in order to design a surgical procedure to create postoperative comitance. Postoperatively this patient had a mild iatrogenic Brown syndrome but she was not bothered by it. This case was done

before I recognized the value of the preoperative superior oblique traction test. Now I would avoid even a small superior oblique resection with a normal tendon weakening the ipsilateral inferior oblique instead. Another significant postoperative event occurred with this patient. Two days after surgery the patient called the office distraught, saying that her eyes were worse than before surgery and that she was sorry she had the operation. The patient was, of course, seen immediately. We were reminded to our chagrin of the 17 diopters of prism (to correct the right hypertropia) in her glasses, which she had to wear in order to see! Since the surgery had reduced the vertical deviation to a small intermittent right hypertropia, the preoperative prisms were creating diplopia! Our policy now is to send such patients home from surgery with Fresnel prism to temporarily offset permanent prism in the glasses that were appropriate preoperatively. In this patient, we were guilty of an oversight. The surgeon and staff should be sure to make provisions to nullify the unneeded prism by adding to the patient’s present glasses offsetting Fresnel prism for wear in the immediate postoperative period (see p. 384).

CASE 27: Bilateral superior oblique palsy

Clinical picture



With her chin down and looking up, this patient is able to “nearly” fuse. A slight horizontal diplopia persists. A definite ‘V’ pattern is present. Both superior obliques underact but more so on the left. **A**, Chin down in primary position; **B**, exotropia in upgaze; **C**, normal up-right gaze; **D**, normal up left gaze; **E**, esotropia in downgaze (‘V’ pattern); **F**, underaction of the left superior oblique.

History

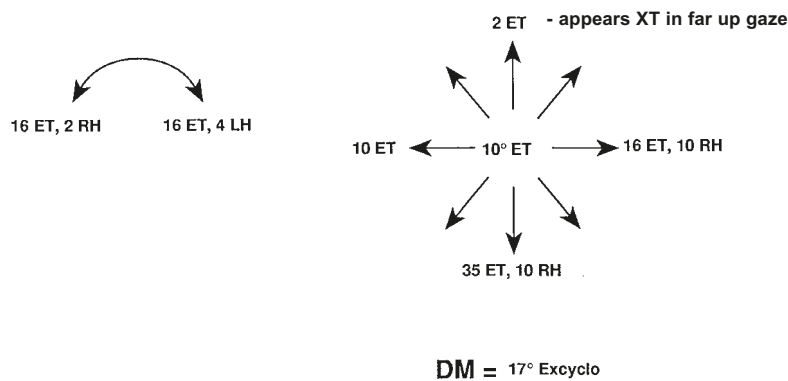
This 28-year-old woman was involved in a motor vehicle accident 3 1/2 years before being seen by us. She had been comatose for 3 days after the accident. Since the time she regained consciousness, she has had diplopia. The only relief for the diplopia is to patch one eye. The images are closer together when she puts her chin down and looks upward, but even then some horizontal diplopia persists. At times, images appear tilted.

Examination

Visual acuity without correction is right eye 20/25-2 and left eye 20/20. Prism and cover test in the primary position shows 10 prism diopters of esotropia in the distance and 12 prism diopters of esotropia at near. In right gaze the esotropia is 10 prism diopters and in left gaze it is 16 prism diopters with 10 prism diopters of right hypertropia. With

right head tilt 16 prism diopters of esotropia and 2 prism diopters of right hypertropia is noted. On left head tilt, 16 prism diopters of esotropia and 4 prism diopters of left hypertropia is noted. With a double Maddox rod, 17 degrees of excyclotropia is measured in the primary position. Versions show moderate underaction of the right superior oblique and marked underaction of the left superior oblique with no overaction of the inferior obliques. The remainder of the eye examination is unremarkable.

Prism and cover testing in the nine diagnostic positions is very difficult in bilateral superior oblique palsy and is actually unnecessary either for diagnosis or for planning treatment. The measurements shown above are sufficient.



Diagnosis

Bilateral superior oblique palsy.

Treatment/Surgery

Bilateral inferior rectus recession 5.0 to 6.0 mm combined with anterior and temporal transposition of the anterior half of the superior oblique insertion is a first choice for treatment. Do not tuck the superior oblique tendons; this will cause a bilateral Brown. Some would weaken both inferior obliques. The medial recti could be shifted down without recession.

Comment

This patient demonstrates the typical clinical findings of bilateral superior oblique palsy. These include a history of closed head trauma, spontaneous torsional diplopia, ‘V’ pattern, and reversing Bielschowsky test. Bilateral superior oblique palsy represents a serious therapeutic challenge. The safest initial procedure is to do a bilateral inferior rectus recession. This will help to “open up” the ‘V’ and should have some beneficial effect on the cyclotropia. However, in this patient, with no overaction of the inferior obliques, the result of inferior oblique weakening might be disappointing. Tucking of a superior oblique in an acquired case presents the risk of producing a Brown syndrome. A bilateral anterior and temporal shift of the anterior fibers of the superior oblique may be the best treatment in that it gives the patient the opportunity to be free of cyclodeviation with only minimal risk of a postoperative Brown. In this patient’s case, since there is esotropia even in upgaze, she has no place to fuse! Some cases of bilateral superior oblique palsy are able to fuse in far upgaze, which tends to give a better starting point for obtaining a bifoveal fusion result in a useful field.

Bilateral superior oblique palsy, like bilateral sixth nerve and third nerve palsy, presents a special

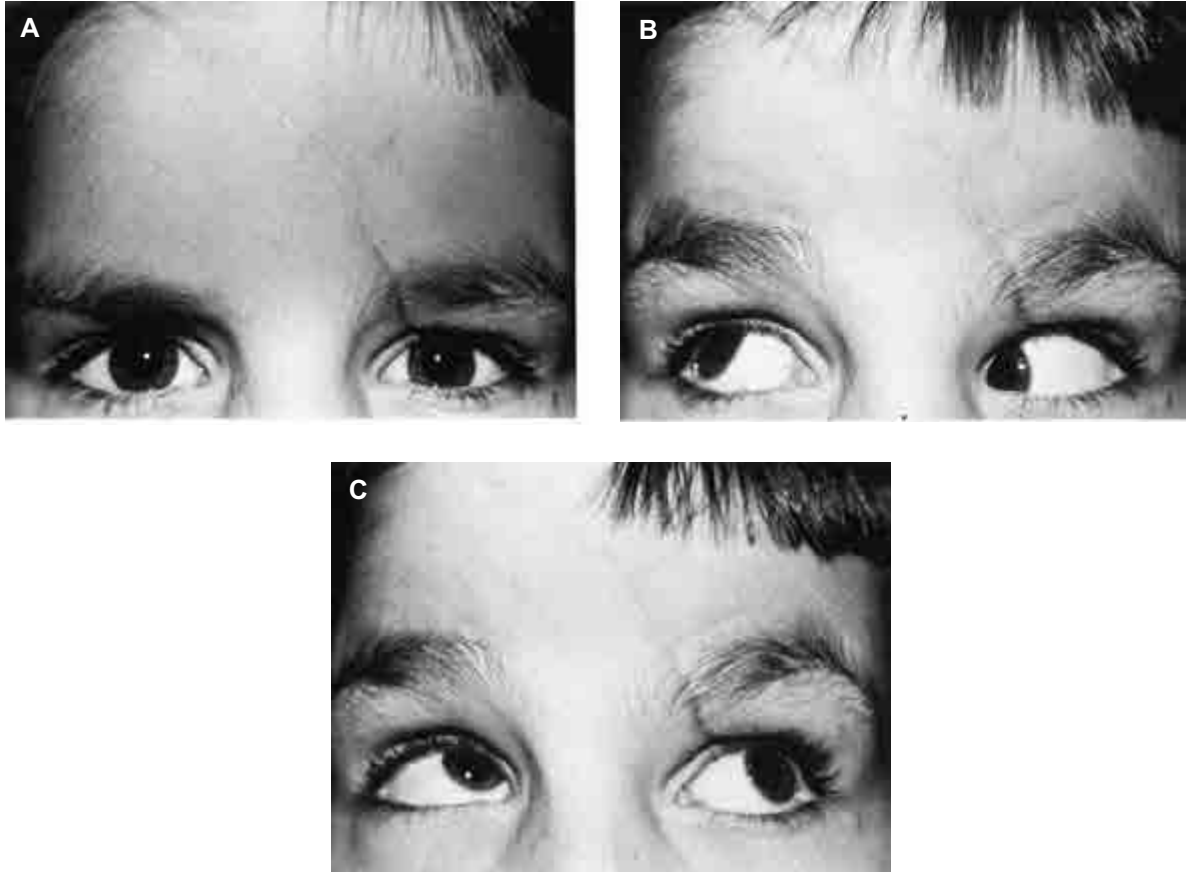
therapeutic challenge since these conditions are often associated with severe head trauma, which in turn can lead to central disruption of fusion and produce a situation where the patient may have a secondary deviation in all fields of gaze.

Strengthening of the superior oblique has its own unique problems related to the special anatomy of the superior oblique tendon. I recently did a bilateral superior oblique tuck in a 4-year-old girl with a ‘V’ pattern, a chin-down posture, and 4+ bilateral inferior oblique overaction. The usual diagnosis in this type of case is “primary” overaction of the inferior obliques. At surgery, this child had bilateral -4 (very loose) superior oblique traction tests. Postoperatively she continued to manifest a fairly large ‘V’ pattern and bilateral inferior oblique weakening was required. As a contrast in other cases of bilateral superior oblique palsy after trauma, small bilateral superior oblique tucks have caused troublesome Brown syndrome and have resulted in only a small window of single binocular vision.

In some patients with bilateral superior oblique palsy one side can be ‘masked’ by a greater deviation on the other side. Patients who have atypical unilateral superior oblique palsy findings, including a head tilt test that shows a moderate hyperdeviation on tilt toward the involved side and no or almost no deviation on tilt toward the other side, with a history of head trauma and cyclodiplopia should be suspect for ‘masked’ bilateral superior oblique palsy. If bilateral “masked” superior oblique palsy is suspected, surgery may be done as for bilateral superior oblique palsy, with the provision that more surgery per muscle or more muscles be treated on the more affected side. As an alternative, the more involved side can be treated at the initial procedure and the less involved side treated appropriately at a second procedure.

CASE 28: Canine tooth syndrome: “class VII” superior oblique palsy

Clinical picture



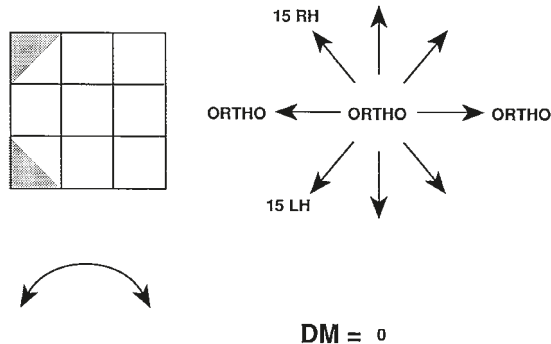
This patient has canine tooth syndrome **A**, the eyes are aligned in the primary position, note the diagonal scar across the forehead ending at the trochlea. **B**, limited elevation of the left eye in adduction. **C**, normal elevation of the left eye in abduction

History

This 11-year-old boy was attacked by a large German Shepherd dog. He was bitten around the left eye. Repair of the skin was carried out immediately after the injury. When the swelling around the left eye subsided, the boy noted that things looked double when he looked up or down.

Examination

Visual acuity is 20/20 in each eye. Cycloplegic retinoscopy is plano. With slight chin depression stereo acuity is 9/9 (40 seconds). On testing of versions, movement of the left eye is limited in both elevation and depression in adduction. In addition, the intraocular pressure in the left eye is more than 10 mm Hg elevated in the left eye compared to the right eye on attempts to elevate and depress the eye, implying restriction of eye rotation in the face of normal generated force. The remainder of the eye examination is normal.



Diagnosis

Canine tooth syndrome: “class VII” superior oblique palsy.

Treatment/Surgery

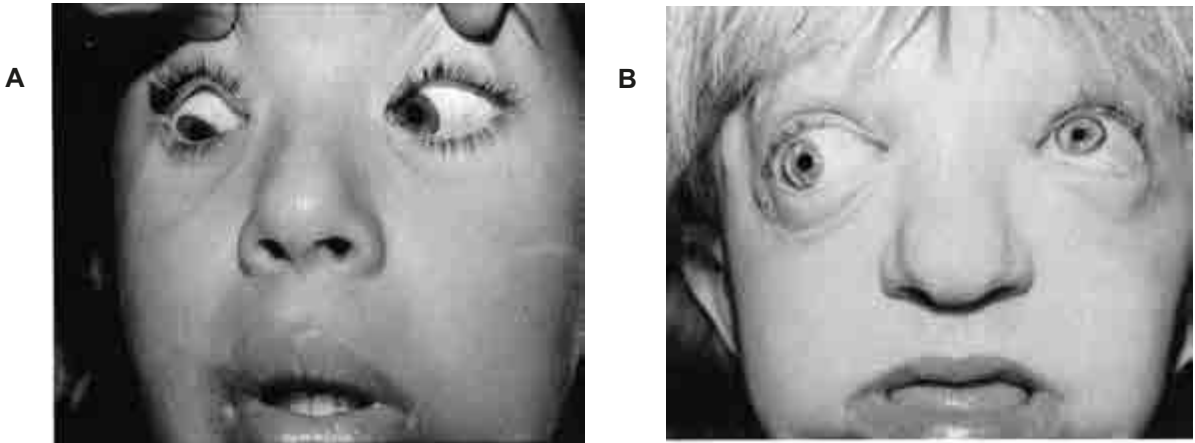
Surgery could be done depending on the patient’s symptoms. If surgery is elected, an attempt could be made to free the adhesions around the superior oblique tendon. A tenectomy of the superior oblique near the trochlea (producing superior oblique palsy) and a weakening of the antagonist inferior oblique (treating superior oblique palsy) is a treatment option. If this does not treat the palsy completely, a recession of the yoke inferior rectus could be added. If the patient does well in the primary position, no treatment may be indicated.

Comment

This condition, first described by Philip Knapp, can occur after trauma in the area of the superior oblique tendon and trochlea and affect eye movement on a strictly mechanical basis. In other cases it can be associated with superior oblique palsy, plus mechanical limitation of elevation from iatrogenic causes or from the trauma that directly or indirectly caused the superior oblique palsy. The mechanical limitation to elevation in adduction (Brown syndrome) is easiest to eliminate when it has occurred after a tuck or resection of the superior oblique (iatrogenic Brown syndrome). In the case described here, the patient retained excellent fusion in the primary position and did not want surgery. Attempts at improving motility by means of surgery could make such a patient worse and should therefore be avoided unless a very troublesome head posture is adopted or if diplopia is troublesome.

CASE 29: Congenital absence of the superior oblique tendon

Clinical picture



A, Pronounced underaction of the left superior oblique on testing versions in a patient who at surgery was found to have no left superior oblique tendon. **B**, A patient with Crouzon anomaly demonstrating marked overaction of the left inferior oblique had bilateral absence of the superior oblique tendons confirmed at surgery.

History

Both of the patients shown were known to have extreme vertical deviations which were variable. They were brought for examination by their parents because of this.

Examination

When a patient with presumed congenital superior oblique palsy is seen with pronounced underaction of the superior oblique, this should raise suspicion that the superior oblique tendon could be absent. Two signs that point to the possibility of this occurring in a patient with congenital superior oblique palsy are: horizontal strabismus, and amblyopia. Facial asymmetry is a nearly constant finding in patients with congenital superior oblique palsy with an anomalous tendon. Patients with severe craniofacial anomalies such as patients with Crouzon anomaly shown here, are more likely to have absence of the superior oblique tendon if they manifest superior oblique palsy signs. As is so often the case, absence of the superior oblique tendon was encountered initially in this type of “worst case” scenario. Later, absence of the superior oblique tendon was noted in less severely affected patients. In addition to being more likely to have a superior oblique tendon anomaly, patients with congenital superior oblique palsy frequently have facial asymmetry. The fuller face is on the involved side. This occurrence is not fully explained, but it seems the facial asymmetry is caused by postural factors; i.e., the chronic head tilt.

Treatment/Surgery

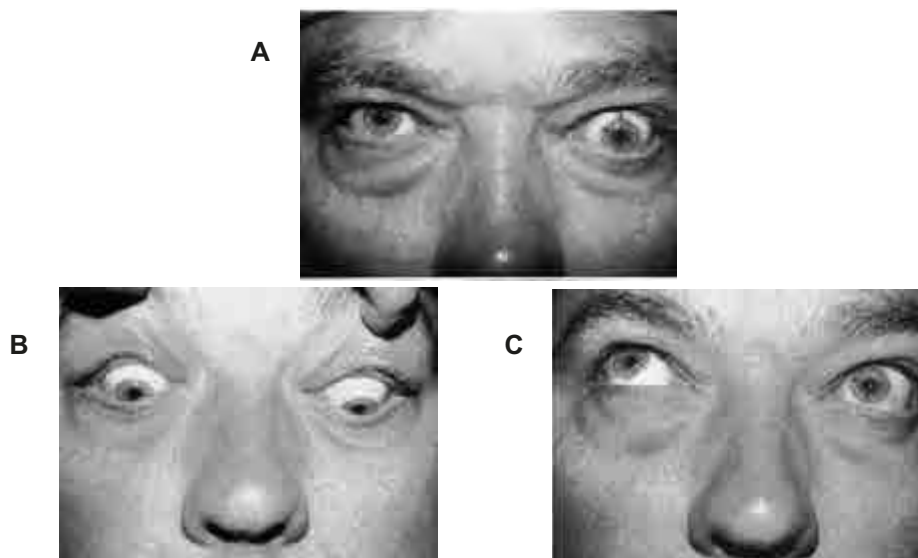When no superior oblique tendon is found at surgery, it is necessary to weaken and “strengthen” available vertically acting muscles to produce the most favorable alignment. The following sequence for extraocular muscle surgery is logical: (1) Weaken the antagonist inferior oblique, (2) weaken the yoke of the absent superior oblique (contralateral inferior rectus), (3) weaken the ipsilateral superior rectus, and (4) “strengthen” the contralateral superior rectus. To this scheme could be added horizontal rectus surgery of sufficient amount to treat any horizontal strabismus. It is usually sufficient to operate on only two vertical muscles at the first procedure.

Comment

Patients with absence of one or both superior oblique tendons usually do not have normal bifoveal fusion even with head tilt. This is in contrast to most acquired and those less severely affected congenital superior oblique palsy patients, who usually have bifoveal fusion when they assume appropriate head posture.

CASE 30: Thyroid ophthalmopathy (Graves' ophthalmopathy)

Clinical picture



Left hypotropia greater in upgaze also with retraction of the left upper lid, Graefe's sign. **A**, Left hypotropia fixing with the right eye. **B**, The left eye depresses more than the right eye on downgaze. **C**, Elevation of the left eye is limited.

History

This 36-year-old airplane mechanic began noticing vertical diplopia 6 months ago. At the beginning, he was able to see one object by raising his chin to look downward. This strategy is no longer effective and his double vision is constant. He is otherwise in good health except for exogenous obesity (67 inches tall, 280 pounds). He has no signs of hyperthyroidism, and none were found earlier during routine laboratory tests obtained by his internist.

Examination

Visual acuity is 20/20 in each eye without correction. Vertical diplopia is experienced in all fields. The left eye is hypodeviated approximately 20 prism diopters in the primary position. This appears to be a larger deviation because of contraction of the left upper lid. When attempting to look up, the left eye lags behind the right eye. The left hypotropia persists in downgaze but is of lesser magnitude. Ductions are normal in the right eye.

After the conjunctiva of the left eye was anesthetized with proparacaine hydrochloride, passive ductions were done and found to be severely restricted to elevation in the left eye. Intraocular pressure was 17 mm Hg in both eyes in downgaze. The pressure in the left eye rose to 40 mm Hg on attempted upgaze, while the pressure in the right eye rose only slightly (to 20 mm Hg in upgaze.)

Diagnosis

Euthyroid Graves' (thyroid) ophthalmopathy involving the left inferior rectus.

Treatment/Surgery

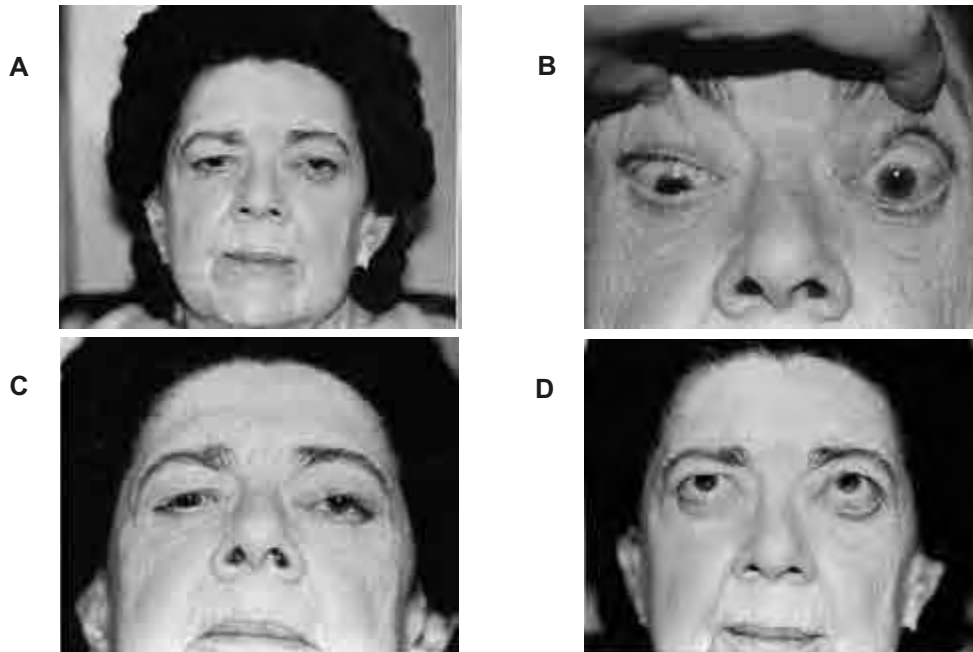Recession of the left inferior rectus muscle with (or without) an adjustable suture with smaller recession of the right inferior rectus if any restriction is felt at the time of surgery.

Comment

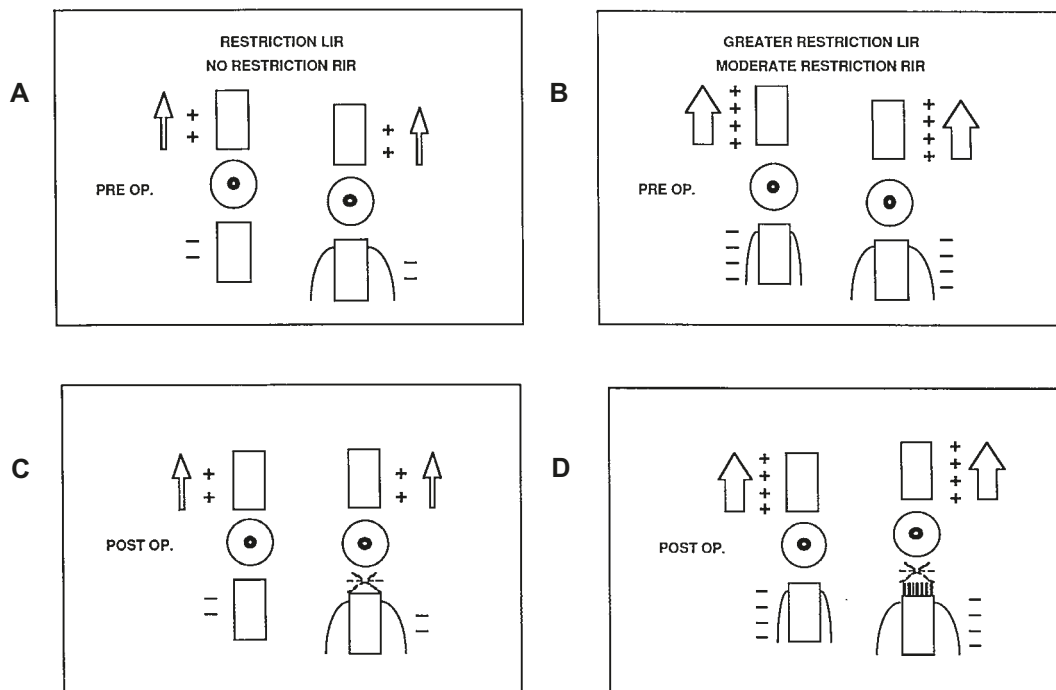
In a patient like this, who has Graves' (thyroid) ophthalmopathy with the fellow eye apparently uninvolved, recession of a single inferior rectus muscle can be very effective. On the other hand, if the fellow inferior rectus is restricted, even minimally, and only the more involved inferior rectus is recessed, the operated eye may become hypertropic postoperatively with weakness of depression. This occurs because the eye with the recessed inferior rectus is subjected to the efforts of a secondary deviation when the patient fixes with the unoperated but mildly restricted fellow eye. When thyroid ophthalmopathy is bilateral, even though the involvement is minimal in the less involved eye, recession should be done in both eyes to avoid progressive overcorrection after inferior rectus recession.

CASE 31: Thyroid ophthalmopathy (Graves' ophthalmopathy) with postoperative slippage of the recessed inferior rectus

Clinical picture



Postoperative slippage of the left inferior rectus. **A**, Ten diopters left hypertropia in primary position with ptosis of the left lower lid; **B**, limited depression of the left eye. **C**, Reading is difficult because of increasing vertical diplopia from left hypertropia in downgaze. **D**, Single binocular vision is possible in upgaze.



Schematic representation of the mechanism of progressive overcorrection after inferior rectus recession in a patient with unequal bilateral inferior rectus thyroid ophthalmopathy. The + and - signs represent innervation (+) and relaxation (-). **A**, Unilateral inferior rectus restriction (left eye) preoperatively. **B**, Corrected with recession of the restricted inferior rectus. **C**, Bilateral unequal inferior rectus restriction preoperatively. **D**, Postoperative slippage of the recessed left inferior rectus caused in part by excess innervation to its antagonist, the left superior rectus by Herings law.

History

When first seen, this 72-year-old woman had swelling around the eyes, redness, slight prominence of her eyes, and diplopia that had been gradually increasing for the past year. When she watched television or rode in a car, images were separated vertically. She closed one eye to read or she placed an occluder over the lens of her glasses. She stopped driving because of the diplopia. She had been treated with ablation of the thyroid by her internist, who states that her condition is now stable, requiring only maintenance thyroid supplement. Visual acuity with pseudophakic correction is 20/30 in each eye. Prism and cover testing in the primary position revealed 16 prism diopters of left hypotropia (right hypertropia). This decreased slightly on downgaze and increased slightly on upgaze. Intraocular pressure in the left eye was 16 mm Hg in the primary position and increased to 30 mm Hg on attempted upgaze. In the right eye only a 4 mm Hg pressure rise was recorded in upgaze. With a 10-diopter prism held base up in front of the left eye, the patient could see 4/9 stereo dots on the Titmus test (140 seconds). Observed saccadic velocity during elevation of the left eye was equal to that of the right. She was diagnosed as having stable thyroid ophthalmopathy, and an adjustable left inferior rectus recession was done. The eyes were aligned for 6 weeks. After this time, the patient noted double vision with vertical displacement of the images, especially when looking down.

Examination

After the adjustable left inferior rectus recession, this patient had deficient depression of the left eye resulting in a variable left hypertropia as well as ptosis of the left lower lid. The left hypertropia is 10 prism diopters in primary position. With this prism held in front of the left eye, single binocular vision is attained, but diplopia reappears when the patient looks down into the reading position.

Diagnosis

Slipped left inferior rectus after recession for thyroid ophthalmopathy.

Treatment/Surgery

Advancement of the slipped left inferior rectus, recession of the right inferior rectus, and recession of the left superior rectus. Either or both of the recessions may be done with adjustable suture.

Comment

On the surface, this seemed like a fairly straightforward case where an acquired mechanical restriction could be freed in a patient who already enjoyed good fusion. Unfortunately, in dysthyroid

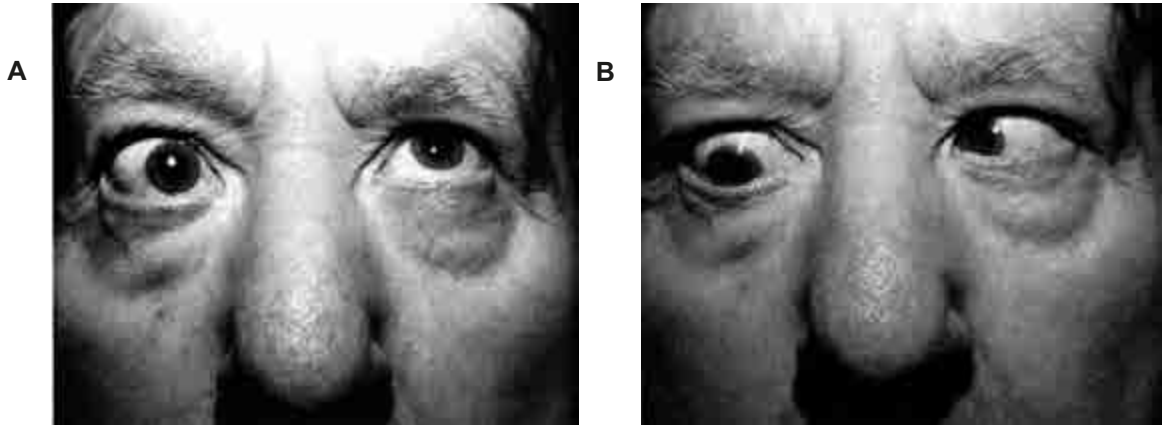
ophthalmopathy this is not always the case. Several obstacles to the ideal treatment occur. First and most important is the fact that the muscle operated on is not the only muscle involved. It is merely the most involved muscle. This autoimmune disease undoubtedly involves all of the extraocular muscles but to a different degree. A CT scan or an MRI of the orbit routinely shows thickening of all of the muscles, not just one or two. This means that if one muscle is weakened, it may be transformed from being the stiffest muscle to the most lax, with another taking its place as the stiffest muscle. As in the case described, it is often the other inferior rectus that becomes the stiffest muscle. If that eye then takes up fixation after the other inferior rectus has been recessed, the basis for a secondary deviation may be present when the superior rectus, the antagonist of the surgically weakened left inferior rectus, receives extra innervation. It is being stimulated equally with the superior rectus of the fellow eye, which now has as its antagonist a stiff inferior rectus muscle. This in turn destabilizes the newly reattached inferior rectus. This sequence of events leads to an overcorrection (hypertropia), especially if an adjustable suture has been used. For this reason it is important to balance forces when weakening a muscle, especially the inferior rectus, in treatment of thyroid ophthalmopathy.

Because of its unique relationship with the inferior oblique, the inferior rectus is prone to destabilization and subsequent slippage after any recession, but especially after an adjustable recession for a dysthyroid ophthalmopathy. Any of the rectus muscles can be involved in dysthyroid ophthalmopathy singly or in combination. The most commonly involved muscle is the inferior rectus followed by medial, superior, and lateral rectus. I have on numerous occasions weakened both the inferior and the medial rectus for dysthyroid ophthalmopathy.

I have never had an occasion to resect a muscle in dysthyroid ophthalmopathy because the motility problem is invariably one of restriction, not weakness. Surgery in this condition should be held off until the patient's thyroid status has been stabilized. However, Coats advocates surgery in some active cases if symptoms demand. I am skeptical of glowing reports of success with adjustable recession of a single inferior rectus, and because of this I warn the reader not to be lulled into a complacent attitude when dealing with this very challenging type of strabismus. In some cases of stable small-angle strabismus and diplopia from thyroid ophthalmopathy, prism therapy may be the best treatment. In some cases after surgery for a larger restrictive component, it is necessary to use prisms to treat a smaller residual vertical or horizontal deviation.

CASE 32: Thyroid ophthalmopathy (Graves' ophthalmopathy) involving multiple muscles

Clinical picture



Bilateral thyroid ophthalmopathy involving multiple muscles. **A**, Fixing OD, looking slightly upward, demonstrating esotropia and left hypertropia. **B**, Looking to the right, demonstrating esotropia and right hypotropia.

History

This 62-year-old man has been troubled by double vision for the past several years. Images are separated both vertically and horizontally. In order to function, he must occlude one eye. He had been treated by his internist for a hyperthyroid condition. He is now stable after medical ablation of the thyroid and is in satisfactory systemic control treated with thyroid supplement. He is also being treated for hypertension and diabetes.

Examination

Visual acuity is OD 20/25 and OS 20/30 while wearing the correction: OD +1.00+1.75 X 20 degrees, OS +1.00+1.00 X 160 degrees add +2.75. In the primary position, the right eye is 20 prism diopters hypodeviated and 15 prism diopters esodeviated. Elevation and abduction of the right eye are severely limited. The left eye has moderate limitation to abduction. Horizontal and vertical diplopia are present to varying degrees in all fields. The separation of images is greatest on attempts to look up and to the right. Passive duction testing after anesthetizing conjunctiva with proparacaine hydrochloride reveals severely limited elevation and abduction in the right eye and moderate limitation to abduction in the left eye. The remainder of the eye examination is unremarkable.

Diagnosis

Thyroid ophthalmopathy (Graves' ophthalmopathy) involving multiple muscles, specifically the right inferior and medial rectus and the left medial rectus.

Treatment/Surgery

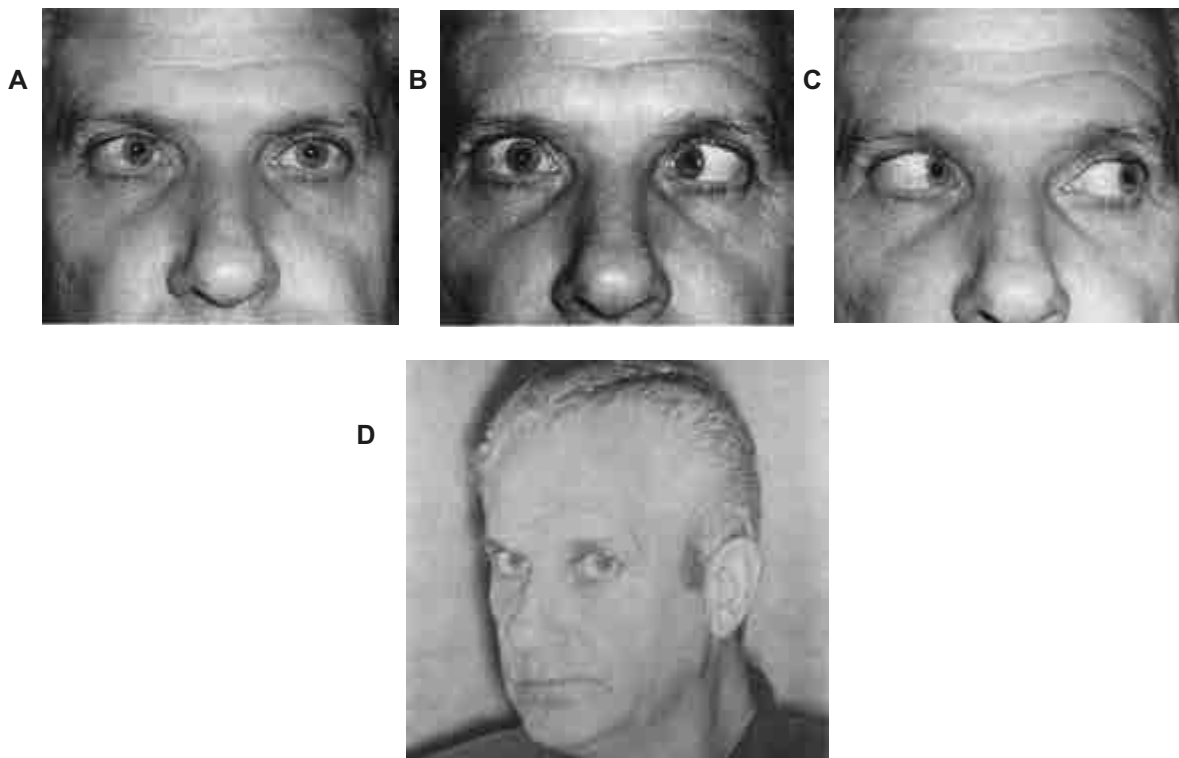
Recession of the medial recti and recession of the right inferior rectus (one medial rectus and the inferior rectus muscle could be recessed with an adjustable suture).

Comment

It is common for thyroid ophthalmopathy to involve multiple muscles. In this patient, care was taken to evaluate the relative stiffness of the left inferior rectus muscle. Had it shown any restriction at all, it would have been appropriate to recess this muscle also. Placing one medial rectus and the inferior rectus of the right eye on an adjustable suture enables fine tuning of the alignment the day after surgery. However, the potential problems associated with adjustable inferior rectus recession; that is, early or late slippage should always be kept in mind.

CASE 33: Unilateral sixth nerve palsy

Clinical picture



Right sixth nerve palsy. **A**, Primary position fixing with the left eye. **B**, Fixing with the paretic right eye; **C**, left gaze; **D**, right face turn and left gaze enables single binocular vision.

History

This 62-year-old man sustained closed head trauma in a motor vehicle accident 1 year ago. After a brief period of unconsciousness, he noted double vision. This has persisted in all fields except in extreme left gaze, where he has single binocular vision. In order to drive, watch television, and read with comfort, he must cover one eye. There were no other injuries from the accident, and this man's health is otherwise excellent.

Examination

Visual acuity with correction is 20/20 in each eye. With the left eye fixing, approximately 20 prism diopters of right esotropia is noted. When fixing with the right eye, the left eye is esodeviated 60 prism diopters. The right eye cannot abduct to the midline. Versions are normal in left gaze. The right eye "floats" to just short of the midline during a saccade to the right. The velocity of this saccade is approximately one-fourth the speed of the abduction saccade of the left eye. Passive duction testing after the con-

junctiva is anesthetized with proparacaine hydrochloride shows *no* restriction to full abduction of the right eye. With extreme right face turn and left gaze, single binocular vision is achieved and stereoacuity of 9/9 (40 seconds) is recorded. The remainder of the eye examination is normal for a person of this age.

Diagnosis

Traumatic right sixth nerve paralysis.

Treatment/Surgery

Full tendon transfer of the superior and inferior rectus muscles of the right eye adjacent to the insertion of the right lateral rectus.

Comment

Unilateral sixth nerve palsy can present in several slightly different patterns, and these different patterns require different types of treatment. In the case described, no right lateral rectus function was pres-

ent. In addition, there was no significant restriction to passive abduction. This means that a full tendon transfer procedure alone can be effective. On the other hand, if restriction of the antagonist right medial rectus had been present, it would have been necessary to deal with this by weakening this muscle. If a recession is done, then an additional full tendon transfer of the vertical recti would leave only one anterior ciliary artery intact (that in the paretic lateral rectus). This can be done, but it increases the risk of producing anterior segment ischemia, especially in an older patient. Since the vertical recti have no long posterior ciliary artery, detachment of these muscles with no "backup" arterial blood supply introduces a greater risk of anterior segment ischemia when compared to detachment of the horizontal recti.

When passive abduction is restricted in a patient with sixth nerve palsy, Botox can be injected into the antagonist medial rectus to weaken it either at the time of surgery or from 7 to 14 days before or after surgery. In a case of sixth nerve palsy with sufficient lateral rectus function remaining so that the paretic eye moves beyond the midline combined with only slightly reduced saccadic velocity during abduction, a recession of the medial rectus and resection of the lateral rectus can be effective. In the case of an acute sixth nerve palsy, Botox injection into the antagonist medial rectus muscle can be effective in forestalling contracture of this muscle, thereby providing a better chance for effective rehabilitation of the reinnervated paretic lateral rectus muscle. At least this makes sense, but the benefit from this 'prophylactic' use of Botox has not been established. In surgical treatment of sixth nerve palsy, favorable factors are unilateral involvement, residual lateral rectus function (paresis), and absence of mechanical restriction. When a medial rectus recession and lateral rectus resection can be done, postoperative results are better than if a muscle transfer is required. Unfavorable factors in surgical treatment of sixth

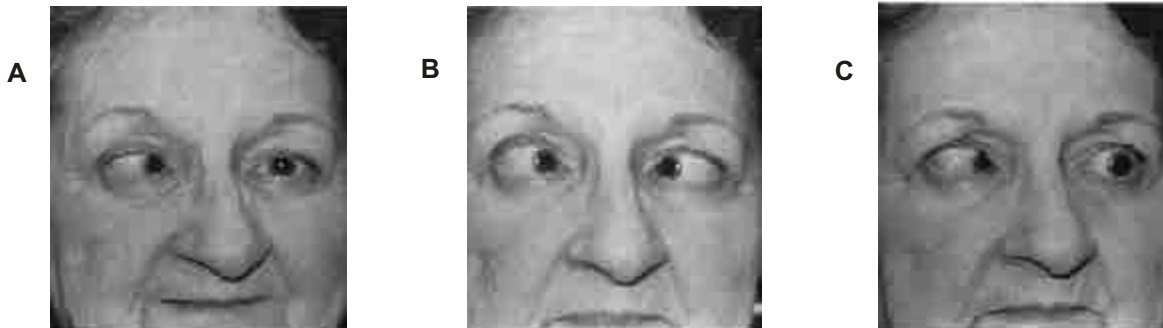nerve palsy are bilateral involvement, absence of lateral rectus function (paralysis), and mechanical restriction.

Before doing an extraocular muscle transfer procedure to treat a paralyzed muscle, the surgeon should emphasize to the patient that a muscle transfer does not restore full ocular rotations. The surgeon should also emphasize to the patient with bilateral sixth nerve palsy that diplopia will persist postoperatively even when primary position alignment is achieved because abduction is never full and a secondary deviation occurs in gaze to the right or left, creating horizontal and sometimes vertical strabismus and diplopia. An induced vertical deviation is more likely to occur after full tendon transfer. The occurrence of vertical strabismus after full tendon transfer has prompted Rosenbaum et al. to suggest that adjustable sutures be used on the transferred vertical recti. In any case of strabismus from cranial nerve palsy, suppression of the second image is advantageous if fusion is unattainable. In the case of unilateral sixth nerve palsy I do not recess the sound medial rectus of the fellow eye because the field of single binocular vision can be reduced in the field opposite the paralyzed lateral rectus. Instead of recessing the normal medial rectus a posterior fixation suture may be used.

A diplopia field plotted with an arc perimeter or a bowl perimeter is a useful way to follow the progress of sixth nerve palsy, either after surgical treatment or as it spontaneously resolves. Results can be important for medicolegal reasons. The fields are recorded quickly and easily by determining how many degrees away from primary position an object can be moved before it is seen doubled. To do this test, the head must be centered in the head support (not to the right or left, as is done during visual field testing of each eye) and the head should remain fixed while only the eyes move.

CASE 34: Bilateral sixth nerve palsy

Clinical picture



Bilateral sixth nerve palsy greater in the right eye. **A**, Primary position with left eye fixing. **B**, dextroversion; **C**, levoversion

History

This 66-year-old woman sustained closed head injury in a car accident 14 months earlier. She also sustained multiple lower limb fractures and uses a walker. Since the accident, her eyes have crossed and she is bothered by constant diplopia.

Examination

Visual acuity with correction is OS 20/25-2 and OS 20/20-1. Glasses are OD +2.00+0.50 X 180 degrees and OS +2.00+0.50 X 10 degrees with a +2.50 add. Adduction is normal in both eyes. Abduction is slightly limited (-1) in the left eye. The right eye does not abduct even to the midline. Approximately 60 prism diopters of right esotropia is present in the primary position while fixing with the left eye. The esotropia increases when fixing with the right eye and in right gaze. The esodeviation is less in left gaze. Saccadic velocity is moderately brisk to the left in the left eye. A floating saccade is present in attempted abduction in the right eye as the eye moves from the adducted position to just short of the midline.

Diagnosis

Bilateral traumatic sixth nerve palsy more severe in the right eye.

Treatment/Surgery

Full tendon transfer shifting the right superior rectus and right inferior rectus to the right lateral rectus was performed. At surgery this patient was noted to have a flaccid right lateral rectus muscle. Because of this, in addition to the full tendon transfer, a 10 mm plication-tuck was done on the right lateral rectus, sparing the anterior artery. Five units of Botox were then injected into the right medial rectus muscle

because passive adduction of the right eye was moderately restricted.

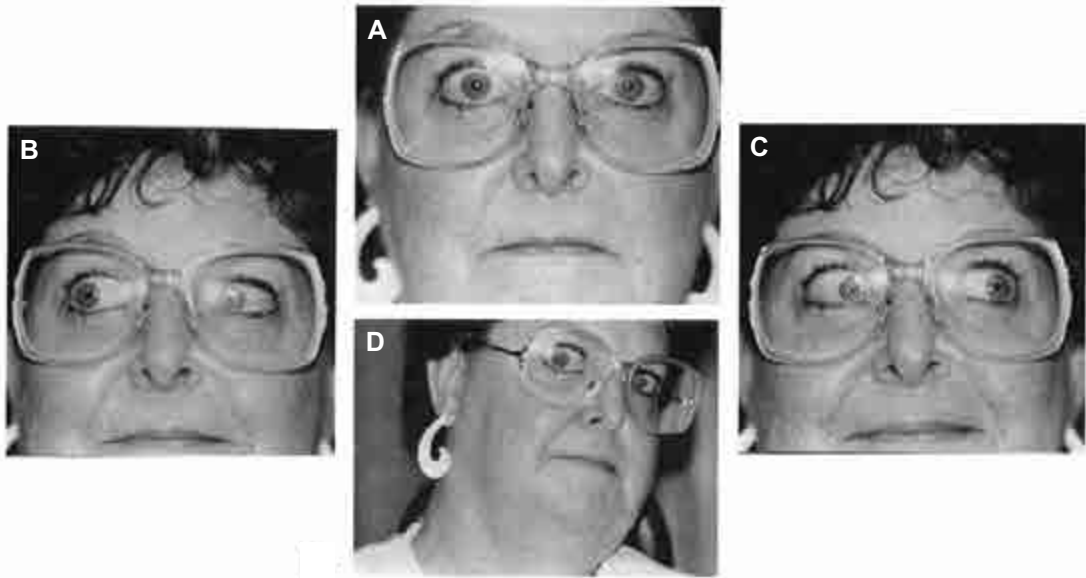
Comment

Posteratively the patient had anterior segment ischemia of the right eye characterized by flare and cell, keratic precipitates, and a dilated fixed pupil. This resolved for the most part after intense topical steroid therapy consisting of 1 drop of 1% prednisolone in the right cul-de-sac every 2 hours while awake. This was reduced gradually over the next 4 weeks to 2 drops a day as the anterior chamber flare and cell reaction subsided. Atrophy of the iris stroma persists from the 9 to 12 o'clock meridians. The pupil is also eccentrically dilated to approximately 6 mm with a reduced reaction to light. In addition, during this period, the patient developed cystoid macular edema with visual acuity reduced to 20/200 in the right eye. The retinal lesion was not treated. After 6 weeks, vision improved to 20/30, but the residual pigmentary changes in the macula and a slight increase in the cataract indicate that visual acuity may not improve beyond this level. Primary position alignment is 10 prism diopters of exotropia, and the patient has single binocular vision with a slight left face turn.

This case may demonstrate the vulnerability of an eye in an older patient to anterior segment ischemia after detachment of the vertical recti. It is not clear what role the Botox injection in the medial rectus or for that matter the lateral rectus plication played in the anterior segment ischemia. However, I have seen two other cases of anterior segment ischemia occurring after Botox injection in similar cases where we thought sufficient anterior ciliary circulation remained.

CASE 35: Bilateral sixth nerve palsy with persistent diplopia after realignment

Clinical picture



Head posture to achieve single binocular vision after surgery on both eyes. **A**, Primary position; **B**, dextroversion; **C**, levoversion; **D**, a chin up left tilt head posture is needed to obtain single binocular vision

History

This 52-year-old woman was involved in a motor vehicle accident 4 1/2 years ago, sustaining bilateral sixth nerve palsy. Since sufficient lateral rectus function remained, she was treated with recession of the medial recti and resection of the lateral recti for esotropia of each eye, with the surgeries done 1 month apart. She now complains of double vision. This is helped some by using base-out prism, by turning her eyes to the right, or by occluding one eye.

Examination

Visual acuity with correction is right eye 20/25 and left eye 20/30. The patient is wearing the following myopic correction: right eye - 4.25 and left eye - 3.50 + 0.75 X 35 degrees. Prism and cover testing in the primary position reveals 20 prism diopters of esotropia. This decreases to 10 prism diopters esotropia in far right gaze and increases to 25 prism diopters in far left gaze. No significant 'A' or 'V' pattern or other vertical deviation is noted. There is moderate limitation of abduction more in the left eye than the right. Saccadic velocity is brisk to abduction to either side. Adduction is full and vertical versions

are full. This woman has double vision in all fields of gaze with the images separated horizontally. She is wearing 15 diopters of permanent prism divided 8 prism diopters base out in the right lens and 7 prism diopters base out in the left lens. With this prism she is able to see objects singly with her head turned to the left and her chin slightly elevated. If she moves her head even a few degrees or if the object of regard moves even slightly she experiences double vision but can regain single vision fairly easily

Diagnosis

Residual esotropia with diplopia after treatment for bilateral sixth nerve palsy.

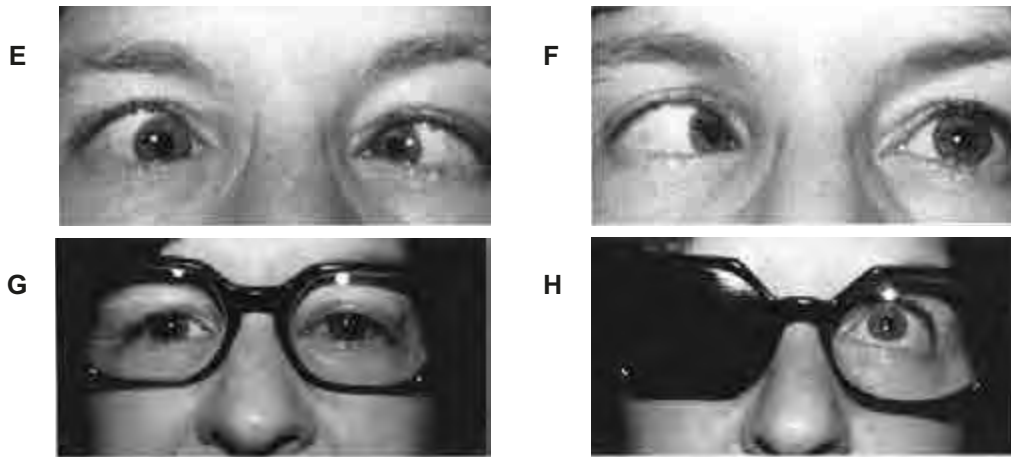
Surgery

Consider re-resection of the left lateral rectus muscle and re-recession of the left medial rectus muscle.

Comment

This patient is happy with the small area of single binocular vision and is willing to try to have this limited field enlarged by additional surgery. When considering a further attempt at gaining a wider range of single binocular vision several things must be considered. First, does the patient have central disruption of fusion* The answer is most likely no. If she had central disruption of fusion she would not be able to gain and regain single binocular vision as she does. Does she have horror fusionis? Again the answer is

no. If this were present, the two foveas would repel each other making any single binocular vision impossible. In this condition the two fovea act as though they were similar magnetic poles as they are driven apart. Will the 'relentless secondary deviation' of bilateral sixth nerve palsy keep the eyes from working together? The answer is maybe, but maybe not. If the patient is willing to have realistic expectations, further surgery is worth a chance.

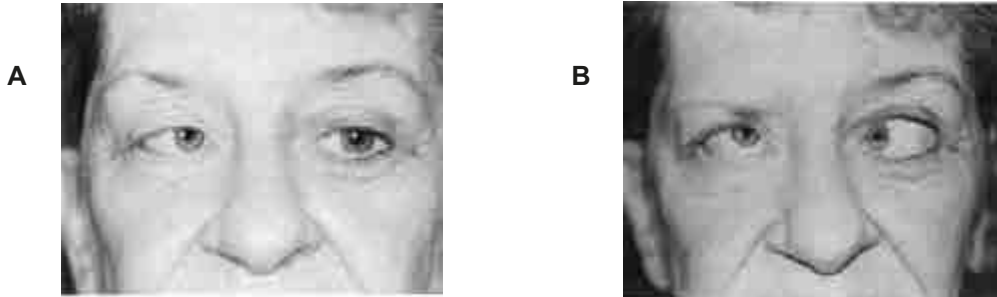

Bilateral sixth nerve palsy in a 45-year-old woman. **E**, Dextroversion preoperatively; **F**, levoversion preoperatively; **G**, primary position alignment after surgery; **H**, One eye patched to avoid diplopia.

Pratt-Johnson JA, Tillson G: The loss of fusion in adults with intractable diplopia (central disruption of fusion), Aust NZ J Ophthalmol 16:81-85, 1988.

CASE 36: Right sixth nerve palsy from intracranial aneurysm

Clinical picture



A, Right esotropia when fixing with the left eye. **B**, In dextroversion the right eye has *no* abduction but is esodeviated and hyperdeviated.

History

This 43-year-old woman had an intracranial aneurysm clipped 6 weeks earlier. Her right eye crossed moderately before the surgery. After surgery, the right eye crossed completely. The images are so far apart that they are not very bothersome.

Examination

Visual acuity is OD 20/40 and OS 20/20 without correction. Motility testing shows 70 prism diopters of right esotropia with *no* right lateral rectus function. The remainder of the eye examination is normal.

Diagnosis

Acute right sixth nerve paralysis.

Treatment/Surgery

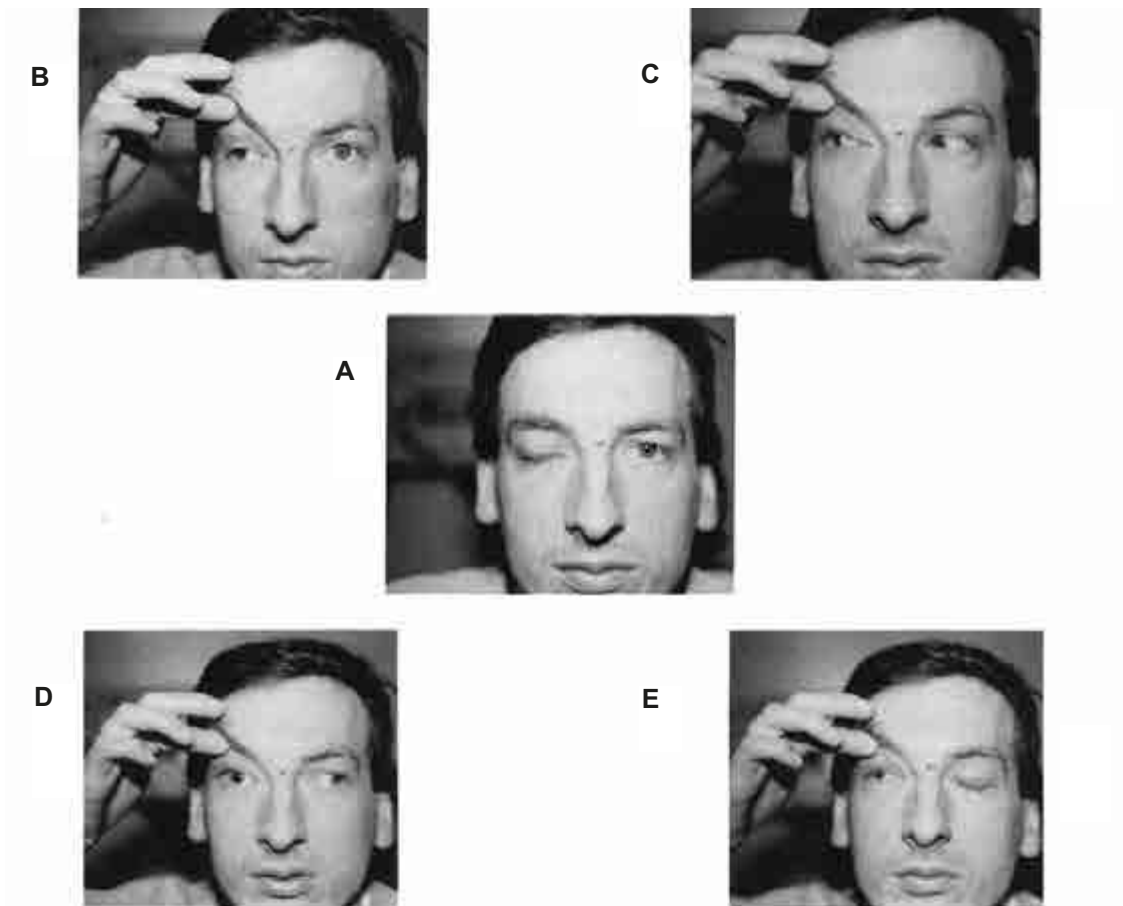
Botox, 5 units to the right medial rectus muscle.

Comment

This patient with acute sixth nerve palsy may recover some or all of her sixth nerve function in the right eye over a period of up to 6 months. To prevent spastic contracture of the unopposed right medial rectus muscle with additional development of restriction during the convalescent period, Botox is injected into this muscle. This patient represents an extreme case of sixth nerve palsy where the nerve may have been transected at surgery. Other milder cases of unilateral and bilateral acute sixth nerve palsy can also benefit from Botox injection. There is no clear-cut evidence that the Botox enables or even hastens recovery of sixth nerve function, but it does make sense and there is little downside. The mechanism of action of Botox in similar cases is to paralyze the medial rectus muscle for a period of weeks to months. Ptosis of the upper lid often occurs when the lateral rectus muscle is injected. To help avoid this, the patient should sit up immediately after injection and should remain upright for at least 2 hours. The toxin is less likely to diffuse in the area of the levator palpebri when this precaution is observed.

CASE 37: Acquired third nerve palsy

Clinical picture



This patient has an acute right third nerve palsy. **A**, In the primary position, ptosis of the right upper lid is complete. **B**, With the right upper lid held up by the right patient's finger, the right eye is exodeviated approximately 40 prism diopters and is slightly hypodeviated. **C**, Abduction of the right eye is full. **D**, The right eye cannot adduct even to the midline. **E**, On downgaze the right eye intorts slightly, suggesting unopposed superior oblique function.

History

This 28-year-old man sustained closed head trauma in a motor vehicle accident 13 months earlier. He is concerned because his right eye is closed. When he raises his right upper lid, he notes that his eye is deviated outward, and he sees double. He would like to have the right eye straightened and his right lid raised.

Examination

Complete ptosis of the right upper lid is present. With maximum attempt at elevation using the frontalis muscle, the right upper lid moves upward about 3 mm. Forty prism diopters of exotropia and 15 prism diopters of right hypotropia are present in the primary position. The right pupil is dilated to 6 mm and does not react to light or accommodative effort. Visual acuity is OD 20/30 and OS 20/20. This patient understands that if his eye is made straighter and his lid raised, he will continue to have double vision and that this double vision may be more bothersome because the images are closer. In spite of this, he would like to have surgery to improve alignment of his eyes.

Diagnosis

Traumatic right third nerve palsy.

Treatment/Surgery

Maximum recession of the right lateral rectus 10+ mm, right superior oblique tendon transfer without trochlea fracture or maximum recession of the right lateral rectus and 10+ mm resection of the right medial rectus with 1/2 to 3/4 muscle width upshift of both muscles.

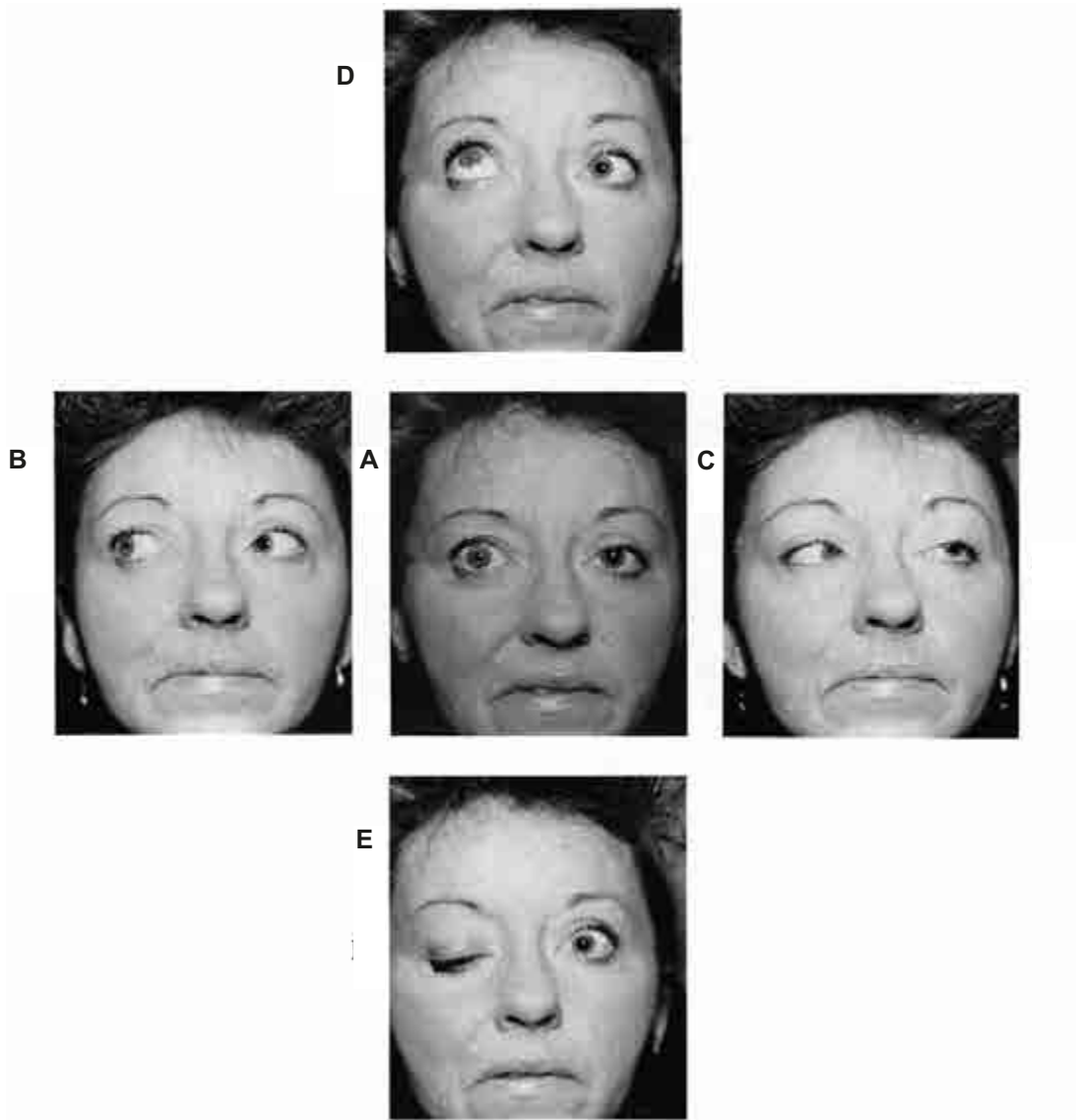Comment

The appropriate extraocular procedure, when successful, can align or nearly align the eye with third nerve palsy, but motility is always limited. When the lid is raised, postoperatively the involved eye during fixation in the primary position is usually slightly exotropic. Frontalis suspension of the upper lid can be performed at the same time as the extraocular muscle surgery or it can be done at a second procedure. Whenever it is done, the ptosis should be undercorrected to lessen the adverse effect of corneal exposure

which is the rule after frontalis lid suspension and limited upward protective movement (Bell phenomenon) of the eye. In a patient such as this, who lacks effective suppression, diplopia can be extremely bothersome. Actually, some of the most agitated and distraught patients I have treated have been of this category. This problem is especially severe when the patient with third nerve palsy is emotionally liable from brain injury. Patients with acquired third nerve palsy should be counseled thoroughly before surgery, telling them about the problems associated with postoperative diplopia. In several successfully aligned cases, it has been necessary to fit the patient with an occluding contact lens or to give glasses with an occluder lens to eliminate the diplopia. On the other hand, if suppression is present for any reason or if vision is poor in one eye alignment can be achieved and the patient is pleased. In some cases of complete acquired third nerve palsy it may be best to refrain from surgery and simply allow the ptosis to “treat” diplopia.

CASE 38: Traumatic third nerve palsy with misdirection after successful horizontal alignment

Clinical picture



A, Primary position alignment with 3 mm ptosis of the left upper lid. **B**, The left palpebral fissure widens on right gaze. **C**, The left palpebral fissure narrows on left gaze. **D**, The left eye does not elevate. **E**, The left eye does not depress and the left upper lid retracts from aberrant regeneration during attempted downgaze.

History

This 36-year-old woman was involved in a motor vehicle accident 2 years earlier. She was comatose for 14 days. When she regained consciousness, she had constant double vision. She is also bothered by generalized left-side weakness. She has difficulty walking, has slurred speech, cries easily, and has difficulty with memory. A left lateral rectus recession of 9 mm and a left medial rectus resection of 10 mm with one-half muscle width upshift was done 4 months ago.

Examination

The patient has visual acuity of OD 20/30 and OS 20/20. The 30 prism diopters of left exotropia and 15 prism diopters of left hypotropia that had been present in the primary position before recent surgery has been nearly eliminated, leaving 5 prism diopters of exotropia resulting in satisfactory appearance. The left pupil is dilated to 6 mm and is nonreactive to light or accommodation. The left eye has nearly full adduction but neither elevates nor depresses more than a few degrees. During dextroversion of the left eye, the left upper lid elevates. This lid is photic on gaze to the left. On attempted downgaze, the left eye remains near the primary position but the left upper lid retracts. The remainder of the eye examination is unremarkable.

Diagnosis

Traumatic third nerve palsy with aberrant regeneration after recess-resect of the horizontal recti with upshift.

Treatment/Surgery

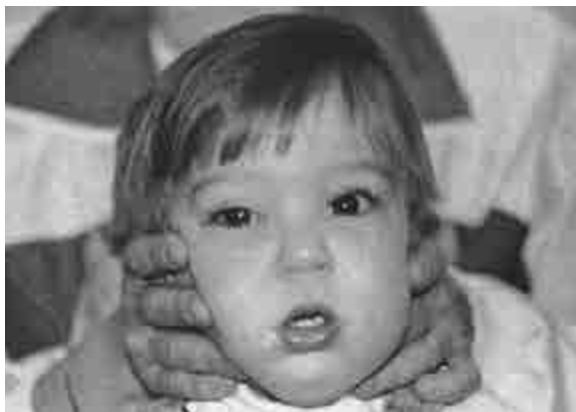Recession of the left lateral rectus 9 mm, resection of the left medial rectus 10 mm with upshift of the insertion of both horizontal recti one half muscle width.

Comment

In cases of unilateral palsy of the third nerve with aberrant regeneration, such as this, a recession/resection procedure with upshift of both muscles can be effective in straightening the eyes in the primary position. There is *no* effective way to deal surgically with the aberrant regeneration. Since the ptosis in this patient is only moderate, possibly a result of the effects of the aberrant regeneration, no treatment is required. Patients with third nerve palsy will always see double in nearly every direction unless they are successful in suppressing one image, usually from the paretic eye. Aberrant regeneration occurs in approximately two-thirds of patients with third nerve palsy, congenital or traumatic.

CASE 39: Congenital third nerve palsy

Clinical picture



Congenital right third nerve palsy aligned surgically. A small residual right exotropia and ptosis of the right upper lid remain.

History

This 14-month-old boy was brought by his parents for examination because his right eye deviated outward and downward. This had been present and unchanging since birth. They also thought the right upper lid “drooped.” The child is otherwise healthy and is developing normally, with all milestones reached on time or early.

Examination

This patient fixed and followed well with *either* eye. While fixing with the left eye, the right eye was down and out and a mild right ptosis was present. When fixing with the right eye, a large left hypertropia with exotropia was present. With the left eye fixing, the right eye was 20 prism diopters exotropic and 15 prism diopters hypotropic. With the right eye fixing, the left eye was 30 prism diopters exotropic and 25 prism diopters hypertropic. Levator function in the right eye was only mildly limited. The right pupil responded *normally*. The remainder of the eye examination was normal.

Diagnosis

Congenital incomplete right third nerve palsy.

Treatment/Surgery

First procedure (14 months of age): recession of the right lateral rectus 8 mm, resection of the right medial rectus 8 mm with 1/2 muscle width upshift of both muscles. Second procedure (18 months of age): resection of right superior rectus 6.0 mm, recession of left superior rectus 4.0 mm.

Comment

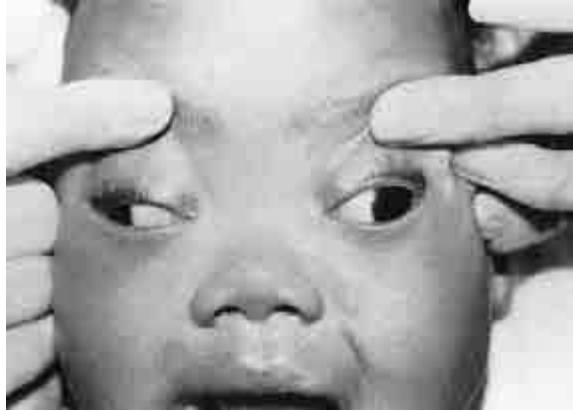After the first surgical procedure, the child's eyes were aligned horizontally but he persisted with a large right hypotropia. After the second procedure, the patient has only a small right hypotropia or left hypertropia and slight ptosis of the right upper lid. This patient was treated initially with a recess/resect procedure of the right eye with upshift because adduction was only moderately limited. There was no limitation to passive ductions in either eye.

Congenital third nerve palsy has many expressions. This patient had fairly mild congenital third nerve palsy that was treatable with a recession/resection and did not require a muscle transfer procedure. Since the ptosis in this case is mild, no treatment is indicated now. Before school-age, it may be appropriate to do a small right levator resection.

Free alternation in this patient rules out amblyopia. I have treated several infants with congenital third nerve palsy who preferred fixation with the paretic eye because vision was better in this eye. If vision is equal in patients with congenital third nerve palsy, they frequently alternate fixation having a large secondary deviation when fixing with the paretic eye. The potential for amblyopia in the patients with congenital third nerve palsy should not be ignored while focusing on the strabismus alone. If fixation preference is noted and the non-preferred eye appears normal, occlusion therapy should be carried out. However, it should be closely monitored. I saw a patient with third nerve palsy who developed intractable occlusion amblyopia after several weeks of full-time occlusion at six months of age. In addition to the amblyopia, a grotesque secondary deviation was created by fixing with the paretic eye. I believe that imaging studies with CT scan or MRI should be done in all cases of congenital third nerve palsy to rule out structural brain abnormalities.

CASE 40: Severe bilateral congenital third nerve palsy

Clinical picture



A sixth-month-old girl has 100 prism diopters exotropia and bilateral complete ptosis from bilateral congenital third nerve paralysis. The lids must be manually elevated to clear the visual axes.

History

This 6-month-old patient had both eyes markedly deviating outward and bilateral ptosis. In order to see, the child habitually used her left forefinger to elevate the left upper lid.

Examination

Both eyes are deviated downward and outward. There is little movement toward elevation or adduction. Both lids are photic and there is no detectable levator function. Both pupils are mid-dilated and react sluggishly to light. The infant appears to have moderate psychomotor retardation. The role of the visual deficit in causing this delay cannot be determined fully at this time. The eyes are otherwise normal.

Diagnosis

Bilateral complete congenital third nerve palsy.

Treatment/Surgery

First procedure (age 8 months): recession of both lateral recti, bilateral superior oblique tendon transfer with trochlear fracture. Second procedure (age 10 months): bilateral (temporary) frontalis suspension of the upper lids using heavy nylon suture.

Comment

Severe congenital third nerve palsy requires more than a recession/resection procedure because adduction is absent. In this case a superior oblique tendon transfer with fracture of the trochlea was done. Recession of the lateral rectus provides additional help toward centering the eye. The ptosis procedure done later should aim at undercorrection because the cornea is at risk for exposure. A review of our patients revealed that approximately two-thirds of children with congenital third nerve palsy have some evidence of aberrant regeneration, suggesting that trauma to the nerve has occurred. Patients with congenital third nerve palsy do not have diplopia because of effective suppression. This patient is one of the very few who in my experience had successful fracture of the trochlea. I have abandoned this technique because of difficulty with the fracture and/or unintended transection of the tendon making transfer impossible, especially in older patients.

CASE 41: Sensory exotropia

Clinical picture



A, Left exotropia; B, limited adduction in the left eye; C, normal adduction in the right eye.

History

This 26-year-old man sustained an injury to the left eye at age 7 when he was struck with a nail. The corneal laceration was repaired and the damaged lens removed. No optical or other treatment was given to the eye. His left eye has gradually drifted outward. He would now like to have his eyes straightened in order to have improved eye contact. He feels uncomfortable talking to people, and he states that he is not sure if people know where he is looking when he is talking to them or trying to get their attention.

Examination

Visual acuity in the right eye is 20/20 without correction, and in the left eye it is 'counts fingers' at 3 feet not improved with lenses. Fifty prism diopters of left exotropia is present in the primary position measured with the prism and light reflex test (Krimsky). Ductions of the right eye are normal. Adduction in the left eye is limited slightly at -1. During extremes of upgaze and downgaze, the exotropia increases to 70 prism diopters, creating an X pattern.

Diagnosis

Sensory left exotropia with X pattern.

Treatment/Surgery

Recession of left lateral rectus 9 mm, resection of left medial rectus 8 mm.

Comment

This patient with a long-standing left sensory exotropia is bothered socially and in business dealings by a feeling that he describes as "people don't know where I am looking." Justification for treatment of this patient may be under the heading "all humans have the right to look like a human." The only normal human ocular alignment is to have orthotropic or aligned eyes. Therefore, "straightening" the left eye in this patient with visual acuity of "counts fingers" in that eye is a functional procedure.

Patients like this are extremely grateful for any improvement in their appearance. Many patients with large-angle exotropia deny that a problem exists and are reluctant to seek help. Compared to those with a similar size esodeviation, the patient with large-angle exotropia is typically more willing to endure strabismus and not seek treatment or will seek it later. Several character actors have actually capitalized on a large angle exotropia to create a sinister or devious image. On the other hand, an esotropia imparts a "foolish" image and an affected patient is more likely to seek treatment. Any adult patient with manifest exotropia who also retains vision in the deviated eye has an enlarged field of peripheral binocular vision. These patients should be warned that they will have a decrease in their binocular field of vision after the eyes are straightened. This can be disturbing to patients at first. They often report a sensation of having "tunnel vision" after surgery. This sensation *always* goes away, with the result that patients report normal vision in weeks or months.

CASE 42: Residual sensory exotropia

Clinical picture



A, Thirty diopters of left esotropia. B, Normal adduction OS. C, Limited abduction OD

History

This 43-year-old woman had eye muscle surgery on the left eye at age 5 for esotropia that had begun during the first year of life. Vision has been very poor in the left eye because of what the patient described as a “hole in the retina.” The patient teaches fourth grade and complains that her students do not know where she is looking. She would like to have her eyes straightened.

Examination

Visual acuity with correction is OD 20/20 and OS counts fingers at 4 feet. Her refraction is OD -6.50+2.75 X 75 degrees and OS -3.75+2.75 X 35 degrees. In the primary position, the left esotropia measures 30 prism diopters. There is also 5 prism diopters of left hypotropia. Abduction is moderately limited in the left eye and a roughened, raised red conjunctival scar is noted medially in the left eye. An inactive chorioretinal scar involving the macula of the left eye accounts for the poor vision in that eye.

Diagnosis

Residual sensory esotropia OS, with conjunctival scar.

Treatment/Surgery

Exploration of the left medial rectus, with plicaplasty and re-recession of the left medial rectus if possible or marginal myotomy of a fully recessed left medial rectus and resection of the left lateral rectus. The amount of surgery is determined at the time of surgery. One or both of the muscles may be placed on an adjustable suture.

Comment

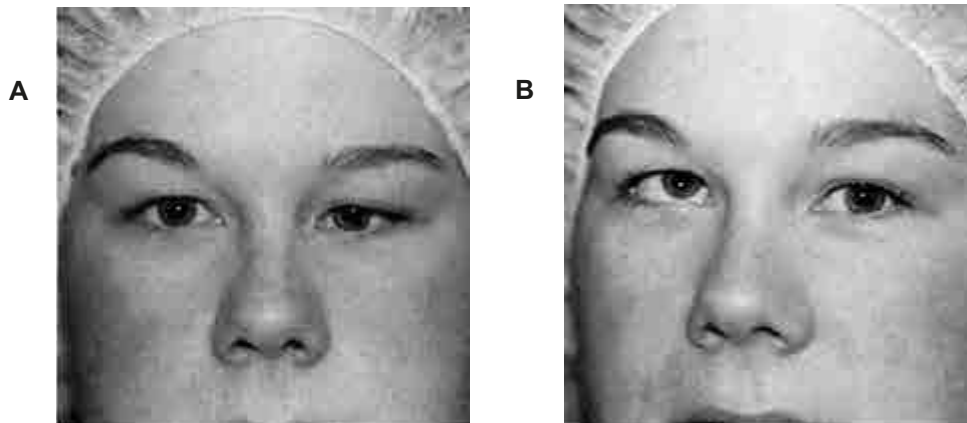
This patient is typical of many patients who have had eye muscle surgery done in the 1950's. She had a transconjunctival incision over the insertion of the left medial rectus. As often occurs when this incision is used, the conjunctiva is scarred with a roughened, red mass over the entire medial conjunctiva. At surgery the medial rectus was found 11.0 mm from the limbus. Because the conjunctiva was rough and red, it was excised to the plica, which had been pulled closer to the nasal limbus by scarring from the previous surgery. The plica was sutured down to sclera and resection of the left lateral rectus was done.

It is a good idea to slightly undercorrect patients like this with esotropia. Postoperatively, they would be more likely to notice and be dissatisfied with 5 prism diopters of exotropia than 5 prism diopters of residual esotropia. This woman has become accustomed to (if not happy with) the esodeviation and will be very grateful for a significant reduction but may be unhappy with even a small overcorrection. Justification for straightening a deeply amblyopic eye such as this are (1) normalization of the oculo-facial relationship with improved interpersonal relations and (2) increase in the peripheral binocular field.

Coats and Paysse have shown that applicants who have had digitally altered photos showing strabismus receive lower evaluations on applications compared to when their pictures are unaltered and show straight eyes. This demonstrated that strabismus can be a handicap when it comes to making a favorable impression.

CASE 43: Dissociated vertical deviation with true hypotropia (falling eye)

Clinical picture



A, Right eye fixation showing 10 prism diopters of left hypotropia. **B**, Left eye fixation with 15 prism diopters of right hypertropia.

History

This 21-year-old woman had eye muscle surgery done on both eyes in Germany between ages 3 and 5 years. Since that time, she has had some crossing of her eyes. More recently, she observed that the left eye appears to be lower than the right most of the time. This patient wishes to have the alignment improved by surgery if it is possible.

Examination

Visual acuity with correction is OD 20/20 and OS 20/30. The patient wears contact lenses with the following correction: OD -6.50, OS -7.00. She prefers to fix with the right eye. While fixing with the right eye in the primary position, the left eye is esodeviated 15 prism diopters and is approximately 10 prism diopters hypotropic. When the nonfixing left eye is occluded, it drifts upward *above* the midline approximately 10 prism diopters with an excycloduction. This left eye sursumduction and excycloduction movement is slow and vergence-like, making it a DVD-type response. When the cover is removed from the left eye, the eye drifts down (deorsumduction) to 10 prism diopters of hypodeviation while the right maintains fixation. When the left eye takes up fixation but the right remains uncovered, the right eye assumes 15 prism diopters of hypertropia. While fixation continues with the left eye and the right eye is occluded, it moves up 10 prism diopters more with a slow vergence movement and excycloduction. No latent nystagmus is noted. Ductions are full in both eyes. The remainder of the eye examination is unremarkable.

Diagnosis

Residual esotropia, asymmetric DVD with small true left hypotropia and “falling” left eye.

Surgery

Recession of right superior rectus 7 mm, re-recession of the left medial rectus.

Comment

This patient demonstrates the combination of true right hypertropia (left hypotropia) along with dissociated vertical deviation. The left medial rectus muscle was selected for re-recession because there was a slight limitation of passive abduction in this eye noted at surgery. The left medial rectus was found approximately 9 mm from the limbus. It was re-recessed to 11.5 mm from the limbus and the scarred overlying conjunctiva was recessed approximately 5 mm. The right superior rectus was recessed 7 mm, which is more than would be done ordinarily for 15 prism diopters of hypotropia. This larger recession was done because of the additional DVD response. In cases of “falling eye” with poor vision in the hypodeviated eye, it is more appropriate to recess the inferior rectus of the hypodeviated eye. However, in this patient, the superior rectus recession made more sense despite the fact that this eye was habitually used for fixation, because a larger recession can be done safely on the superior rectus in contrast to the inferior rectus without correction for lid fissure changes.



This 46-year-old man has poor vision in the left eye that over a period of many years has become hypodeviated. The hypodeviated eye has a pulsating vertical nystagmoid movement. When the nonfixing hypodeviated left eye is occluded, it undergoes a sursumduction in a DVD-type response, moving several prism diopters *above* the midline. When the occluder is removed, the eye returns to a position below the midline. This patient is more typical of the "falling eye" syndrome, which has also been called the Heimann-Bielschowsky phenomenon. In this case, the inferior rectus muscle was recessed 5 mm, resulting in improvement in the primary position alignment.

CASE 44: Double elevator palsy

Clinical picture



With maximum effort, the right eye is able to elevate to a point not even to the midline.

History

This 9-year-old girl has been noted by her parent to have a droopy right upper lid and a right eye that is chronically deviated downward. This has been present since birth. Her health is otherwise normal.

Examination

Visual acuity is 20/20 in each eye. Cycloplegic refraction in both eyes is +0.75. In the primary position, 20 prism diopters of right hypotropia is measured. On maximum attempt at looking up, the left eye reaches just a few degrees short of the midline. With forced lid closure, the eye moves up only a few degrees more but is well short of full elevation, indicating a weak Bell phenomenon.

Diagnosis

Double elevator palsy of right eye.

Treatment/Surgery

Full tendon transfer of the right lateral and right medial recti to a point adjacent to the insertion of the right superior rectus (after confirming free passive elevation of the right eye).

Comment

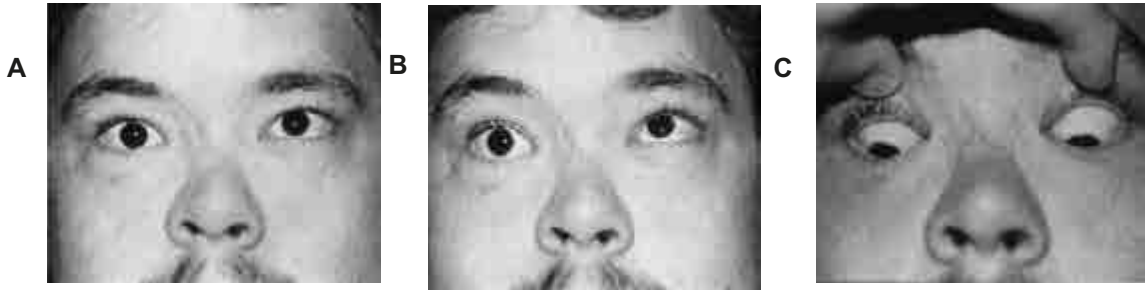Double elevator palsy is a relatively rare and enigmatic strabismus. In some cases, the involved eye can elevate fully with forced lid closure (Bell phenomenon). At other times, such as in this case, the eye does not elevate. In cases with intact Bell's phenomenon, a supranuclear palsy is confirmed. In other

cases, without elevation of the eye on forced closure of the lid, it is necessary to determine if there is a restriction to passive elevation. When restriction is encountered it must be freed before further surgery is done to recess or resect the vertical recti or transfer the horizontal muscles. In the case described here, since there was no restriction to passive elevation a full tendon transfer was done. In other cases with similar clinical characteristics but that differ slightly in that the eye can elevate well above the midline, along with evidence of vertical rectus function, a vertical rectus recession/resection procedure can be done.

In some cases, a full tendon transfer will produce a new horizontal strabismus. When this occurs, it is usually an exodeviation. The method that has been suggested to avoid this complication is use of an adjustable suture, but young children in need of surgical treatment for double elevator palsy are not ordinarily suited for an adjustable suture procedure on a transferred muscle. In cases of double elevator palsy with postoperative horizontal strabismus, the vertically transposed recti can be recessed or resected appropriately or the horizontal recti of the fellow eye can be recessed/resected or both. Children with double elevator palsy may have excellent stereoacuity in downgaze. This can be compromised after the eyes are treated surgically. Double elevator palsy in its several forms is a difficult and frustrating, but fortunately rare, type of strabismus to manage surgically.

CASE 45: Blowout fracture of the orbit

Clinical picture



A, Left hypertropia fixing with the right eye; **B**, The right eye elevates only a few degrees above the midline; **C**, Both eyes depress fully.

History

This 22-year-old had repair of a blowout fracture and associated facial trauma that resulted from injury incurred in a motor vehicle accident 8 months ago. Since the surgery, the right eye on the side of repair has been “down” or at times the left eye has been “up.” The patient reports that he sees everything double except when he looks in far downgaze.

Examination

Visual acuity is 20/20 in each eye. Prism and cover testing shows 14 prism diopters of right hypotropia when fixing with the left eye and 20 prism diopters of left hypertropia fixing with the right eye. Elevation of the right eye is limited to only a few degrees above the midline, even with maximum effort. Numbness of the right infraorbital area is present. In downgaze the stereo fly can be fused (gross stereopsis 3000 seconds). The remainder of the eye examination is normal.

Diagnosis

Right inferior rectus restriction after blowout fracture of the orbit.

Treatment/Surgery

Inferior rectus recession of right eye using adjustable suture.

Comment

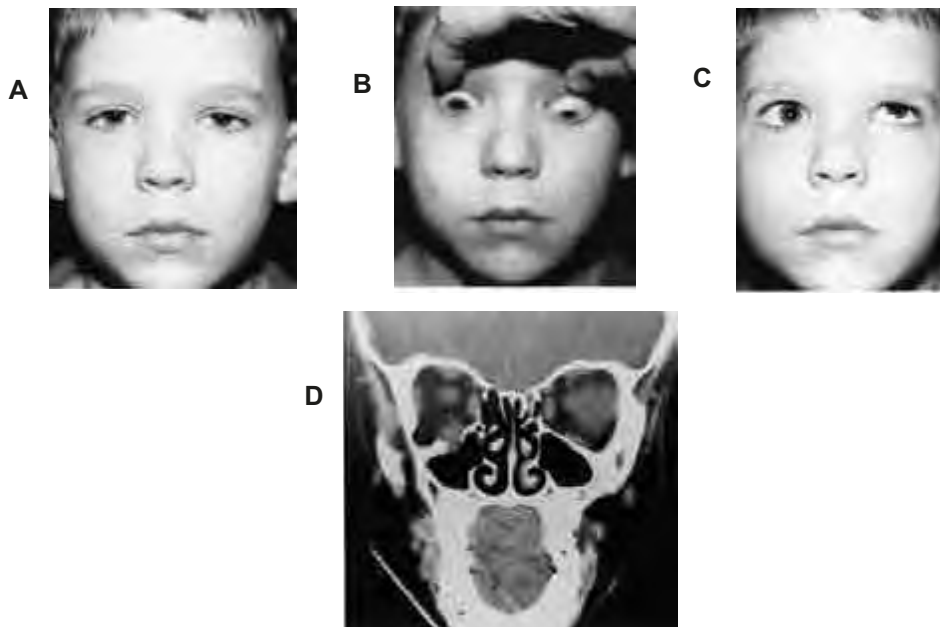
As with any type of strabismus after trauma, blowout fracture presents a complex and varied clinical picture. The acute stage of blowout fracture with prolapse of orbital contents into the maxillary sinus is usually repaired after the swelling has subsided,

which usually occurs about a week after the injury. This fracture repair is done with direct visualization of the orbital floor. Exposure is obtained through a subciliary lid skin incision or by means of an incision behind the lid through the inferior fornix. The prolapsed orbital contents are then ‘teased’ out of the bony defect and the defect in the orbital floor is covered with a splint made of thin plastic material. Unfortunately this is not always the end of the story. Even if all of the incarcerated tissue has been removed from the fracture, trauma to soft tissue—including the inferior rectus and surrounding fascia and fat can cause restrictions that limit elevation and produce a hypotropia of that eye, resulting in diplopia. In some cases the inferior rectus sustains nerve damage. In this case, after repair either a hypertropia results or a persistent restrictive hypotropia is present masking a paretic inferior rectus, that may be recognized only after restriction to elevation has been freed. When this is accomplished in such a case, limitation in both upgaze and downgaze can result.

A wide variety of traumatic strabismus entities can result from direct trauma to the muscles, orbital fascia, and bones around the orbit. In this type of case, the motility repair can be complicated and therefore must be planned and executed based on the unique motility findings. Recession, resection, and transfer are dictated by the residual function of the muscles and use of these procedures depends on both innervational and mechanical factors. In most cases of traumatic motility disturbance that I have treated, it has been possible at best to find a limited area of comfortable single binocular vision with residual areas of diplopia.

CASE 46: Acute blowout fracture

Clinical picture



Acute blowout fracture of the right orbit. **A**, Primary position; **B**, limited downgaze in right eye (reverse leash effect); **C**, severely limited upgaze of the right eye (leash effect). **D**, Coronal CT shows defect in right orbital floor with orbital contents prolapsed into the maxillary sinus.

History

This 6-year-old boy was struck in the right eye by the heel of a playmate's shoe while wrestling at play 6 days ago. The right eye was moderately swollen immediately after the injury. The child saw double after he was struck, and he continues to see double at all times.

Examination

Visual acuity is OD 20/30 and OS 20/20. No significant refractive error is present. The eyes are straight in the primary position and 6/9 stereo dots (80 seconds) are seen. Depression of the right eye is moderately limited and elevation of this eye is severely limited. There is numbness over the medial aspect of the right inferior orbital rim. CT scan of the orbits shows a bony defect of the right orbital floor with prolapse into the maxillary sinus of the orbital contents, possibly including the right inferior rectus muscle.

Diagnosis

Acute blowout fracture of right orbital floor.

Treatment/Surgery

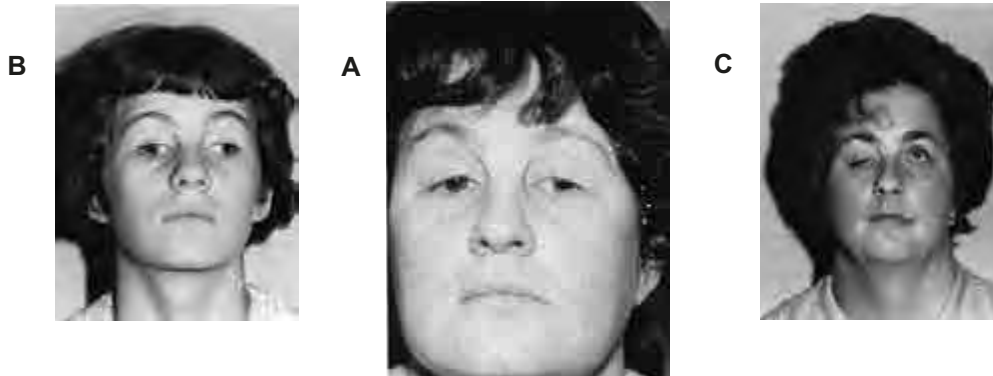Removal of orbital contents from the maxillary sinus and repair of the fracture defect with a splint.

Comment

Acute blowout fracture of the orbit wall (usually the floor) is now treated in most cases by the oculoplastic surgeon. The surgical approach to the orbital floor is through a subciliary incision made in the skin of the lower lid or through an inferior fornix incision. With either incision, inferior orbital rim periosteum is incised below the inferior orbital septum, and the periosteum is elevated to expose the orbital floor defect. Prolapsed orbital contents are carefully extracted from the maxillary sinus, and a thin plastic sheet, either preformed or cut and shaped to size, is placed over the defect. Unfortunately, adhesions in and around the orbital soft tissue, including the inferior rectus, can cause restricted eye movement even when freeing of the prolapsed material has been complete. If motility continues to be limited after surgical repair of a blowout fracture, appropriate eye muscle surgery, usually inferior rectus recession, on the involved side can be carried out. However, if paresis of the inferior rectus is present, freeing of restriction to elevation must be followed by an inferior rectus resection, or, if the inferior rectus is non-functioning, muscle transfer must be done by shifting the horizontal recti to the inferior rectus insertion.

CASE 47: Congenital fibrosis syndrome

Clinical picture



A, This patient has bilateral ptosis, chin elevation, and gaze downward with exotropia; **B**, The patient's sister; **C**, The patient's mother has only the right eye affected

History

This 16-year-old girl has had chin elevation and exotropia in downgaze all of her life. She also complains that both her upper lids droop. Her sister, mother, maternal uncle, and maternal grandfather are also affected.

Examination

The most striking feature of this patient (and all other similarly affected patients) is the chin-up position with bilateral ptosis. No levator function is present. On attempted upgaze (actually attempting to lift the eyes to the primary position), the frontalis is used to raise the lids, but with this effort only a few millimeters of lid elevation is accomplished. Also, when the patient attempts to look up, the eyes converge. Visual acuity is 20/30 in each eye.

Diagnosis

Congenital fibrosis syndrome.

Treatment/Surgery

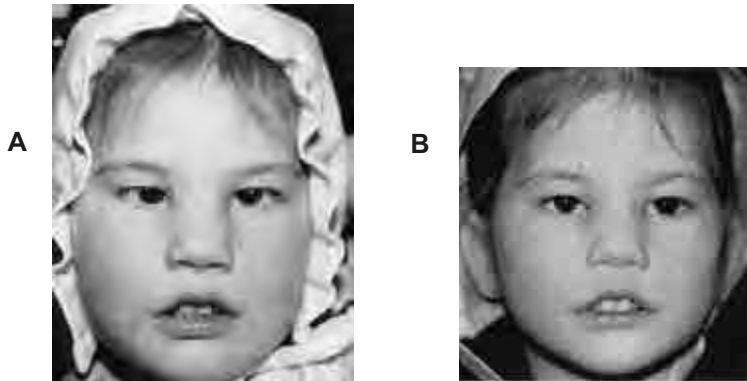Bilateral inferior rectus recession with frontalis suspension of the upper lids done at the same procedure with the extraocular muscles or at a second procedure. If esotropia is a problem the medial recti can be recessed

Comment

Congenital fibrosis syndrome is inherited as autosomal dominant with nearly complete penetrance, although involvement may vary. The inferior and medial rectus muscles are often thin tight bands in this condition. The medial rectus muscle also tends to course upward to the insertion, suggesting an origin in the orbit lower than is usually seen. Results of surgery for fibrosis syndrome are frequently disappointing because of residual restriction to elevation and continued convergence on upgaze. However, after surgery some patients are able to assume a nearly normal head posture. Treatment of congenital fibrosis syndrome, though difficult and not producing excellent results, is certainly worth doing. Most patients appreciate any improvement, even though minimal. The degree of involvement varies from patient to patient. In general the less severe the fibrosis, the better the result from surgery.

CASE 48: Möbius syndrome

Clinical picture



A, Esotropia and a “dull” facial expression are typical features of Möbius syndrome. **B**, After surgery, the eyes are aligned by bimedial rectus recession but the eyes cannot abduct.

History

This 6-year-old girl has a blank look and both eyes are crossed. Shortly after birth and throughout infancy she had some difficulty feeding. Now she is healthy and eats without difficulty.

Examination

Simply observing this child provides sufficient information to make a diagnosis of Möbius syndrome. The eyes are moderately crossed, and the nasolabial fold is absent bilaterally. This gives a dull facial expression. Neither eye can abduct beyond the midline. When adduction is attempted with either eye, there is a convergence response in the fellow eye. The eyes elevate and depress normally. Visual acuity is 20/30 in each eye. Cycloplegic refraction is OD +1.00+0.50 X 30 degrees, OS +1.00 sphere. The distal third of the tongue appears to be atrophic (looked for specifically because this is a typical feature of Möbius syndrome).

Diagnosis

Möbius syndrome.

Treatment/Surgery

Bimedial rectus recession to 10.5 mm.

Comment

Children with Möbius syndrome or bilateral congenital paresis of the sixth and seventh cranial nerves present a typical clinical picture, as demonstrated by this child. Surgery consisting of bimedial rectus recession can at best achieve alignment in the primary position. Postoperatively, abduction will not be restored. Parents must be warned before surgery that they should have limited and realistic expectations about results. I have not done muscle transfer procedures in these patients. Diplopia is not a troublesome symptom in such patients because the strabismus is present from birth with suppression. In my experience Möbius syndrome is a true congenital esotropia along with Duane I, and both also happen to be *conatal*.

CASE 49: Skew deviation with symptomatic diplopia

Clinical picture



This patient is shown 1 day after 3 mm recession of the right superior rectus. Except for slight reaction around the right superior rectus (and right upper lid), the patient looked the same before surgery.

History

This 81-year-old man complained of vertical diplopia that has bothered him for 3 years. He is otherwise healthy for a man of his age. Images are separated vertically by about the height of his television screen. He had a slight stroke 3 years ago. This has left him with no apparent residual problem other than double vision.

Examination

Visual acuity is OD 20/25-1 and OS 20/40+1 with correction of OD -1.50+0.50 X 80 degrees and OS -1.75+0.75 X 100 degrees and a +2.75 add. There is 4 diopters of base-down prism in the right lens and 3 diopters of base-up prism in the left lens. Prism and cover testing with the patient's distance correction in a trial frame shows a *comitant* 10 prism diopter right hypertropia. This vertical deviation does not change in right or left head tilt. No torsion is measured with the double Maddox rod. The remainder of the eye examination is unremarkable except for incipient cataracts slightly greater in the left eye. The patient is unhappy with wearing prism because he can see well at near without glasses, but he has diplopia when he takes them off to read the newspaper. He would like to have eye muscle surgery if this would allow him to get rid of his need for prism.

Diagnosis

Skew deviation (comitant right hypertropia).

Treatment/Surgery

3.0 mm right superior rectus recession.

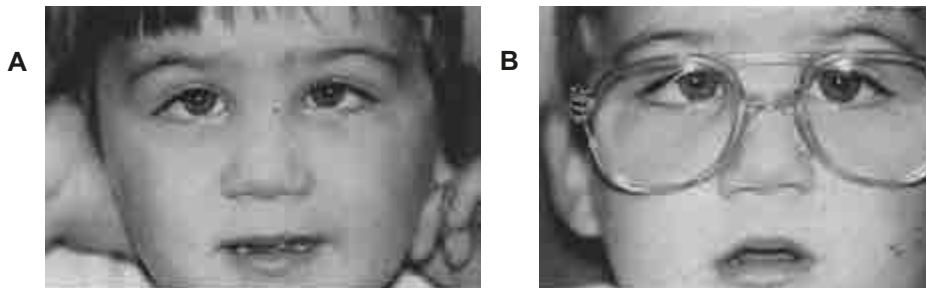
Comment

Vertical diplopia occurring suddenly in an older person, as it did in this case, is usually caused by fourth nerve palsy, presumably a microvascular insult. In a slightly younger patient it may result from thyroid ophthalmopathy. However, there appears to be another cause in this patient. The key to the different etiology is that this is a comitant vertical deviation. An acquired comitant vertical strabismus is called skew deviation. It is believed that this is a supranuclear motility disturbance caused by minor brain stem insult, usually a microvascular accident. Prism therapy is adequate for most patients like this. However, if the patient is not happy with prism for any reason, a surgical procedure involving recession of a single vertical rectus muscle can be successful. Skew deviation; that is, *without* a paretic muscle is usually seen in older patients, is supranuclear, and has a presumed vascular cause that is not usually identified specifically.

Some strabismologists discourage use of the term *skew* because it might presume etiology but not describe the strabismus. In place of the term "skew deviation" it may be more useful to say that this patient has an acquired comitant right hypertropia. The presumed supranuclear microvascular cause is inferred. In my opinion, this type of strabismus does not require extensive workup. Evaluation of blood pressure and blood sugar is indicated, but further evaluation should be based on the patient's other health considerations. Patients like this are often subjected to needless, expensive imaging studies before they are seen by an ophthalmologist.

CASE 50: Acquired esotropia

Clinical picture



A, Left esotropia (30 diopters) without glasses. B, Right esotropia (20 diopters) with glasses.

History

The 4-year-old boy was examined and treated initially by an optometrist at age 2 years. Six months before, at age 1 1/2 years, his parents noted that his eyes were turning in. This in-turning was intermittent at first, but after a few months it was constant. At his initial examination the child was given glasses to correct farsightedness and to help straighten his eyes. He has worn these glasses faithfully for 2 years. Several interim checkups indicated no need to change the prescription of the glasses but the esotropia remained. The child was referred for further evaluation and possible treatment.

Examination

The patient is able to fix and follow with either eye, takes up fixation freely with either eye, and appears to be at ease wearing his glasses, which measure OD +2.00, OS +2.50. With these, he is able to see 20/40 in each eye tested with pictures. His esotropia with glasses measures 20 diopters at distance and at near. Ductions are full and no 'A' or 'V' pattern is present. The esotropia without correction increases to 35 diopters at distance and 30 diopters at near. Cycloplegic refraction is OD +2.00 and OS +2.50, indicating no need to change prescription in the glasses. To perform prism adaptation, fully correcting base-out Fresnel prisms (20 prism diopters) were placed on his spectacles. After 2 weeks, 15 prism diopters of esotropia was measured while the Fresnel prisms were in place. After wearing 35 diopters of base out prism for another two weeks, cover testing showed 2 prism diopters of esotropia and the patient fused the Worth four lights at near. This indicated a total deviation of 35 prism diopters of esotropia while wearing full hyperopic correction in this prism adaptation responder.

Diagnosis

Acquired esotropia, partially accommodative, increasing with prism adaptation in a prism adaptation responder.

Treatment/Surgery

Bimedial rectus recession to 10 mm from the limbus for 35 prism diopters of residual esotropia.

Comment

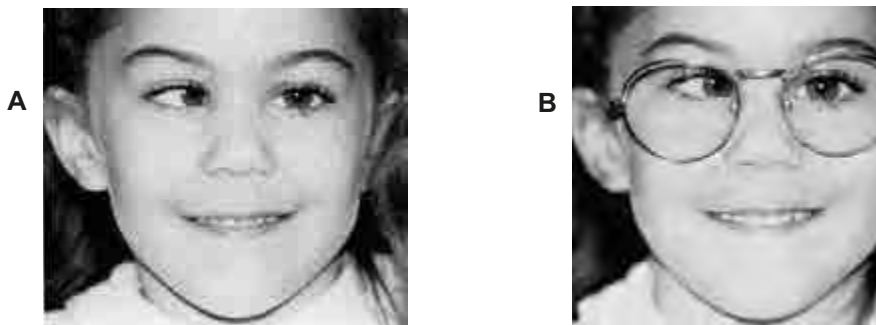Acquired esotropia, which frequently has a refractive component, presents a clinical challenge in that the proper amount of surgery can be difficult to determine. Surgery done for the residual angle while wearing full hyperopic correction could result in undercorrection. To avoid this, the prism adaptation test may be used to uncover a patient's true or maximum esodeviation. For this test, Fresnel prism of sufficient strength to fully correct residual esotropia is placed on the patient's glasses. After a period of adaptation, which may be hours, days, or weeks, the deviation is re-measured.

In some cases, the initially placed prisms continue to fully correct the angle. In this case, the patient is said to *not* respond to the prism adaptation. If Worth four light fusion is measured, surgery is done in an appropriate full amount for the residual angle; that is, the amount corrected by the prism. In other cases, the angle increases or 'builds' after the initial full correction with prism, and more prism must be added to neutralize the esotropia. Such patients are said to respond. More surgery is indicated for patients who increase their angle of deviation after wearing prisms that initially fully correct the deviation.

For practical purposes, a maximum of 60 prism diopters of Fresnel prisms is used for the prism adaptation test. If more esotropia builds, no more prism is added and maximum esotropia surgery is done. In the case presented here, a large amount of surgery was done for what appeared to be only a 20 prism diopter residual esotropia. Because the esotropia increased to at least 35 prism diopters after adaptation, more surgery was justified. This patient will wear his glasses after surgery as long as they are necessary to maintain alignment.

We could have elected to do surgery in this case after one session of prism adaptation, selecting an amount of bimedial rectus recession appropriate

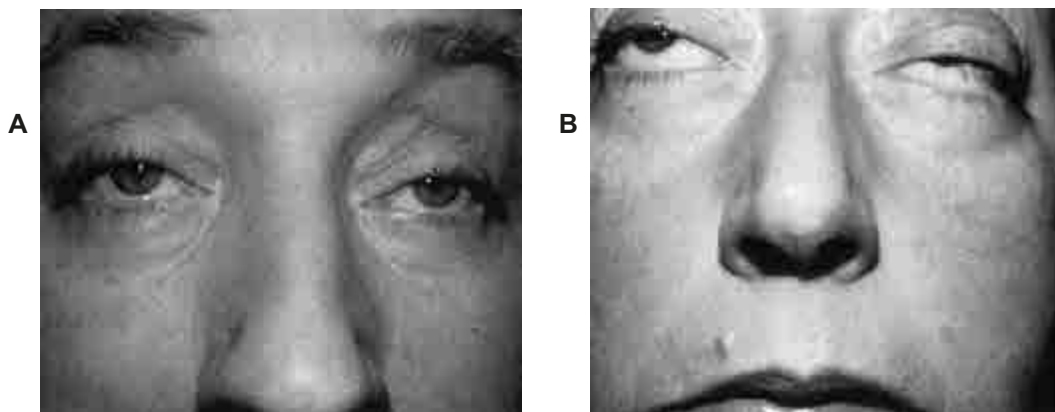for the initially adapted angle; that is, a bimedial recession 10.0 mm from the limbus for 35 prism diopters of esotropia. In the study protocol of the prism adaptation test, prism would have been added if the patient's angle continued to 'build' up to a maximum of 60 prism diopters before discontinuing adaptation. I believe that sufficient information can be gleaned in most cases from one session of adaptation. Those patients who adapt by increasing their esotropia while wearing fully correcting prisms should have an appropriate amount of surgery, but it is probably impractical to attempt to titrate the amount too finely.



A, Another typical acquired esotropia; **B**, residual esotropia while wearing fully correcting plus lenses. She is a candidate for prism adaptation. With prism adaptation, surgery is done either for the residual angle (as shown in **B**) or for the adapted angle, which means that *more* surgery will be done if the esotropia increases while wearing prism that corrects the deviation initially.

CASE 51: Chronic progressive external ophthalmoplegia

Clinical picture



A 47-year-old woman with limited motility and ptosis. **A**, Primary position **B**, upgaze.

History

For more than 20 years, this 47-year-old woman has had diplopia associated with a known diagnosis of chronic progressive external ophthalmoplegia (CPEO). She has no other systemic disease and specifically has no heart problems indicative of Kerns-Sayre syndrome which includes CPEO, pigmentary retinopathy, and complete heart block. She is annoyed by constant double vision and ptosis. She has chronic exposure of the right cornea that requires frequent instillation of topical lubricating drops. She would like to have treatment that would enable some single binocular vision, even if it were only a small area.

Examination

Visual acuity is OD 20/40 and OS 20/30 with correction as follows: OD -2.00+1.75 X 90 degrees and OS -3.25+2.00 X 100 degrees. Ocular motility is severely limited in all fields. The patient can move her eyes only slightly away from the primary position in any direction. In primary gaze, she has vertical diplopia. Images are fused after placing a 15 diopters base-down prism in front of the right eye. The remainder of the eye examination is unremarkable.

Diagnosis

Chronic progressive external ophthalmoplegia (CPEO).

Treatment/Surgery

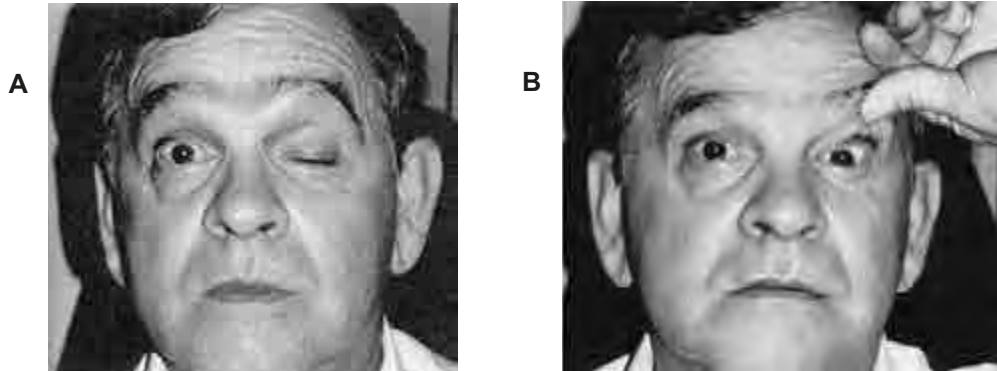Recession of the right superior rectus with appropriate prism postoperatively for residual deviation; bilateral frontalis suspension aimed at some undercorrection.

Comment

Patients such as this pose a challenge to the strabismus surgeon. Obviously, eye muscle surgery will not restore normal or even near normal movement. Prism therapy is appropriate in some cases, but in others, the deviation is so great that prisms are heavy, cumbersome, and therefore impractical. In that case, appropriate recessions and resections of the rectus muscles can be carried out in an attempt to align the eyes at least in the primary position. A smaller residual deviation, either horizontal or vertical (or both), can then be treated with prism. It is also frequently necessary to treat these patients with temporary Fresnel prism because the deviation tends to be variable. Because of the possibility of Kern-Sayre syndrome, CPEO, retinitis pigmentosa, and heart block, all patients with CPEO should have an electrocardiogram and a careful retinal examination, including in some cases an electroretinogram. As a final resort, a patch or an occluding lens may be used to eliminate diplopia.

CASE 52: Ocular myasthenia

Clinical picture



A, Ptosis of the left upper lid. **B**, Left hypertropia apparent when the lid is lifted.

History

This 46-year-old has a 10-year history of recurring visual complaints secondary to ocular myasthenia gravis. These are characterized by episodes of horizontal and vertical diplopia and by ptosis. He is being treated with Mestinon under the supervision of a neurologist. He is also using oral prednisone intermittently in doses up to 80 mg every other day, with the dosage titrated depending on his visual symptoms.

Examination

Visual acuity is 20/20 in each eye with the following correction: OD -1.00 and OS -0.75. At the time the above photograph was taken the patient was obviously having no difficulty with diplopia because of the complete ptosis of the left upper lid. However, 2 months later, the ptosis resolved completely and 15 prism diopters of left hypotropia remained. The deviation was nearly comitant at this time, and there was a slight limitation of elevation of the left eye.

Diagnosis

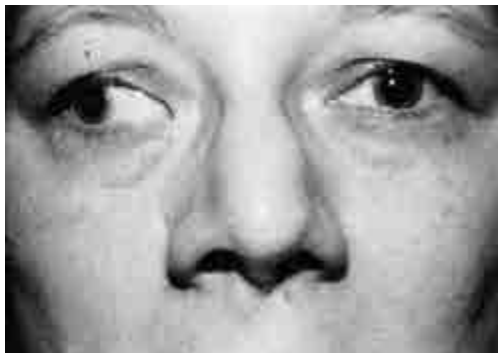Myasthenia gravis with ocular manifestations.

Treatment

While Mestinon can be very effective for treatment of the systemic manifestations of myasthenia gravis, this medication is not very useful for the treatment of diplopia. Instead, prednisone taken in doses of 10 to 80 mg every other day can help eliminate or reduce the double vision. Since the diplopia from ocular myasthenia is variable and responsive to treatment with oral corticosteroids, surgery is rarely indicated. However, in a few cases where the diplopia has been long-standing and refractory to steroid treatment, we have done surgery. If, for example, the left hypotropia in this man remained for several months in spite of maximum steroid dosage, we would consider doing strabismus surgery. In this patient I would do a left superior rectus resection or possibly, but less likely, a left inferior rectus recession. For a deviation larger than 15 diopters, a recession of the right superior rectus could be added. In cases like this, recession is actually an attractive choice because the procedure is tissue sparing and potentially reversible. When contemplating surgery in a case of ocular myasthenia gravis such as this, it is necessary to weigh all of the variables and to be sure that the specific needs of the patient are kept at the forefront. If the surgery must be “undone” it is always easier and more effective in my hands to advance a previously recessed muscle than to recess a previous resected muscle.

CASE 53: Absence of the medial rectus muscle

Clinical picture



Ninety prism diopters of right exotropia in a patient subsequently determined to have absence of the right medial rectus muscle.

History

This 54-year-old woman stated that her right eye has been “way out” for as long as she can remember. She had repair of a cleft lip and palate as a child. She would like to have the right eye straightened if possible.

Examination

Visual acuity in the left eye is 20/20 and the right eye is 20/400. A morning-glory disc anomaly is present in the right eye. The left disc is normal. Ductions are full in the left eye. The right eye cannot adduct even to the midline. The right eye elevates and depresses normally, but the exotropia increases in up- and downgaze, creating an X pattern. The remainder of the eye examination is unremarkable.

Diagnosis

Apparent sensory exotropia of the right eye. Actual diagnosis: Congenital absence of the right medial rectus with morning-glory disc anomaly of the right eye.

Treatment/Surgery

Presurgical plan: recession of right lateral rectus 10 mm, resection of right medial rectus 10.0 mm.

Comment

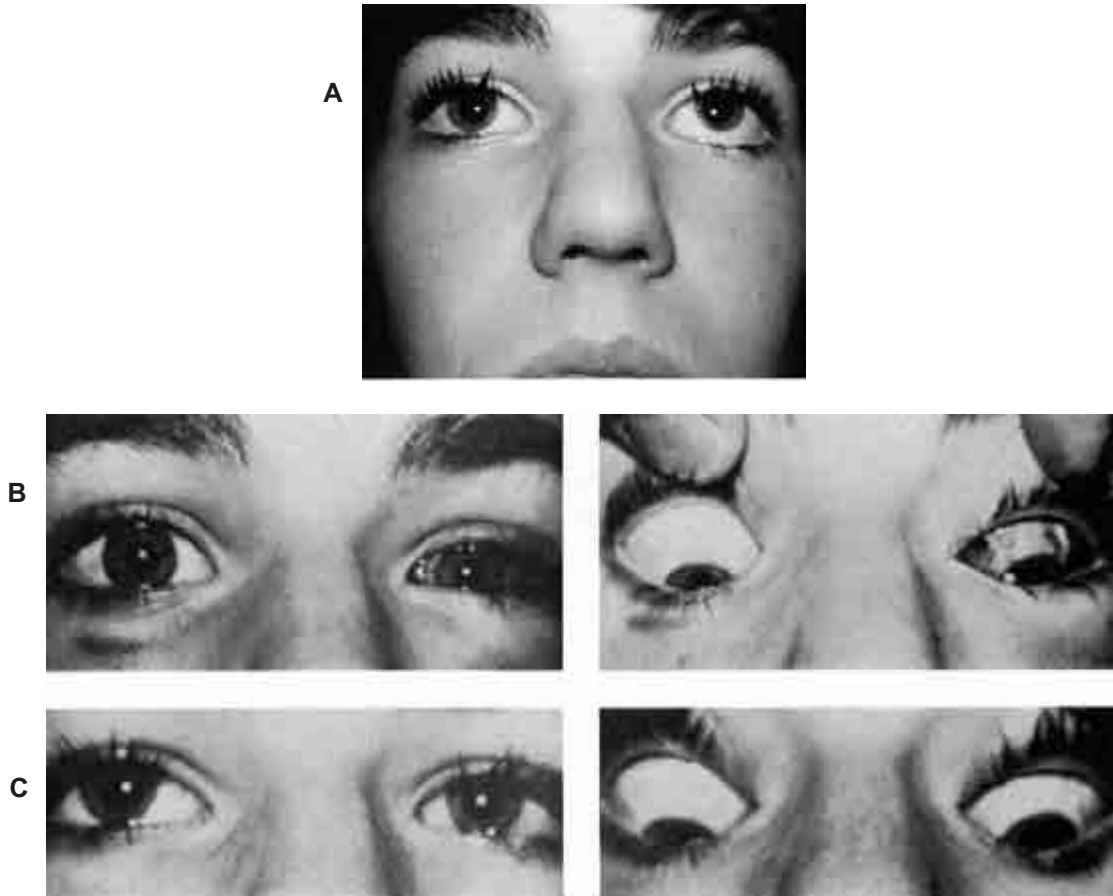
At surgery, passive adduction in the right eye was moderately restricted. The right lateral rectus was found to be normal in appearance but was stiff and nonyielding during attempts to passively adduct this eye. After the right lateral rectus was detached, the right eye could be adducted freely. The right lateral rectus muscle was recessed 10 mm from its original insertion. After extensive exploration of the entire medial aspect of the globe, no evidence of the right medial rectus could be found. Since no prior surgery had been done and the patient denied trauma, congenital absence of the right medial rectus was diagnosed. The right superior and right inferior rectus muscles were then identified and split for approximately 20 mm along the long axis. A strip of banked sclera approximately 3 mm wide and 50 mm long was prepared by cutting it in a spiral fashion from an intact sclera shell, and 5-0 Merseline suture was woven through this scleral strip. The center of the strip was sutured to the patient's sclera where the medial rectus would have inserted. The strips were then placed through the split superior and inferior recti and the ends of the suture-reinforced sclera strip were pulled together over the site where bank sclera had been sutured to host sclera. When the muscle slips of the superior and inferior rectus were almost touching, the bank sclera was sutured to itself. This pulled the right eye nearly straight in the primary position. Postoperatively, the patient had approximately 15 prism diopters of right exotropia with a vastly improved appearance (see chapter 13).

Though any of the extraocular muscles can be missing, the most commonly absent muscle-tendon is the reflected tendon of the superior oblique. I have also seen absence of the inferior rectus and, as shown in this case, the medial rectus. I have not personally encountered congenital absence of either the lateral or superior rectus; however, the latter has been reported in cases with craniofacial anomalies where the superior oblique tendon was also missing.

After surgery, a CT scan of the head was obtained and basal encephalocele was found. It is well known that morning-glory disc is associated with midline defects, including basal encephalocele and midline clefting of the lip and palate. I believe that the absent medial rectus muscle in this case is part of an overall failure of normal development of midline facial structures. In retrospect, a preoperative imaging of the orbit would have provided information about the missing medial rectus.

CASE 54: Traumatic disinsertion of the inferior rectus muscle

Clinical picture



A, Left hypertropia in a patient with traumatic disinsertion of the left inferior rectus; **B**, early postoperative normal depression of left eye after reattachment of a traumatically disinserted left inferior rectus muscle; **C**, normal appearance several months after surgery.

History

This 16-year-old girl hit her face on a screen door 4 months earlier. Immediately afterward she noted double vision, with images being vertically separated. The double vision was worse in downgaze. She stated that she saw a single image in upgaze. A CT scan of the orbit done elsewhere was said to be normal. She was then referred for evaluation of this traumatic left hypertropia, which was thought by her referring physician to be caused by a blowout fracture in spite of normal radiographic findings.

Examination

Visual acuity is corrected to 20/20 in each eye with contact lenses: OD -2.50 sphere, OS -3.00 sphere. In primary position, 16 prism diopters of left hypertropia is present with the right eye fixing. A large right hypotropia measuring 30 prism diopters is present in the primary position while the left eye is fixing. Ductions were normal in the right eye. Depression of the left eye was limited more in abduction than adduction. On attempts to look down with the left eye, an asymmetric skin crease developed in the left lower lid approximately 12 mm below the lid margin.

Diagnosis

Traumatic disinsertion of the left inferior rectus muscle.

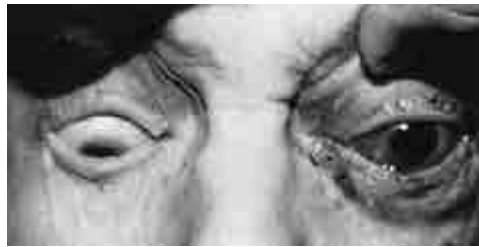Treatment/Surgery

Reattachment of the left inferior rectus muscle.

Comment

The inferior rectus is the muscle most commonly affected by traumatic disinsertion.* This may be due to the fact that this muscle is the least well protected of the extraocular muscles, especially during forced lid closure and upward movement of the eye with the Bell phenomenon. Any of the extraocular muscles could be injured and subsequently weakened by trauma, depending on the unique nature of a given injury. We have seen several patients who sustained foreign body penetration of the orbit with objects such as a store display hook, doorstop, pencil,

penknife, and tree branch, causing trauma to the superior oblique tendon, trochlea, superior rectus, and medial rectus. When treated in a timely manner, reattachment of the traumatically detached rectus muscle is effective in restoring normal function. In long-standing cases or in cases with disturbance of the orbital fascia, it may be necessary to recess the contracted antagonist to free local restrictions in addition to reattaching the detached muscle. If an extraocular muscle has been lacerated posterior to the insertion, the cut ends should be simply reapproximated muscle to muscle with repair of the muscle capsule and intermuscular fascia. However, the more posterior the laceration, the more likely the patient is to have cicatricial restriction and persistent strabismus.

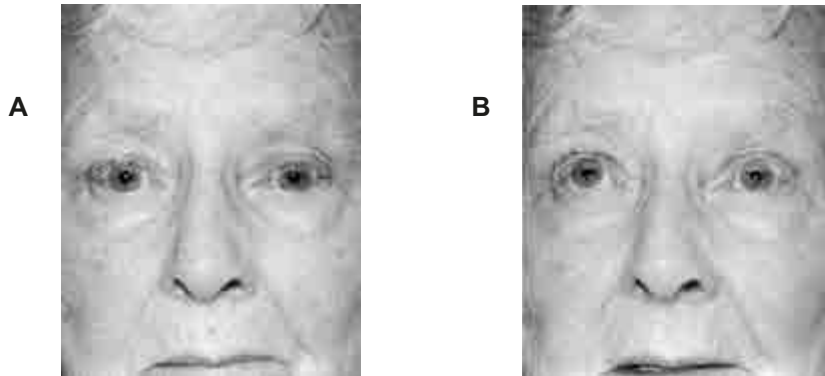


This 77-year-old man was struck in the left eye by the blade of a mowing machine. Miraculously, the large blade cleanly disinserted his left inferior rectus without causing any other damage except a slight contusion of the right lower lid. This patient was seen approximately 3 hours after the accident. Two hours later, with the patient under local anesthesia, the inferior rectus was reattached. The patient was immediately restored to single binocular vision.

*Helveston, EM, Grossman, RD; Extraocular muscle lacerations, *Am J Ophthalmol* 81(6):754-760, 1976.

CASE 55: Diplopia after cataract extraction from left inferior rectus restriction

Clinical picture



A, Left hypotropia--18 prism diopters. B, Restricted upgaze.

History

This 79-year-old woman has had vertical diplopia for the past 1 1/2 years. It began immediately after her second (left eye) cataract was removed and an intraocular lens implanted. She has been wearing Fresnel prisms, which eliminate the diplopia but cause annoying blurring of vision.

Examination

Visual acuity with correction is OD 20/25-2 and OS 20/40-2. A 12 diopter base-up Fresnel prism is on the left lens. Prism cover testing shows 18 prism diopters of right hypertropia (left hypotropia) at distance fixation in the primary position. This increases in upgaze. There is moderate limitation of elevation of the right eye and more pronounced limitation of elevation of the left eye. Passive ductions were restricted to elevation in the left eye.

Diagnosis

Left hypotropia with diplopia after cataract extraction from left inferior rectus restriction.

Treatment/Surgery

Adjustable left inferior rectus recession.

Comment

This woman gives a typical history of diplopia after cataract extraction. The cause of her problem

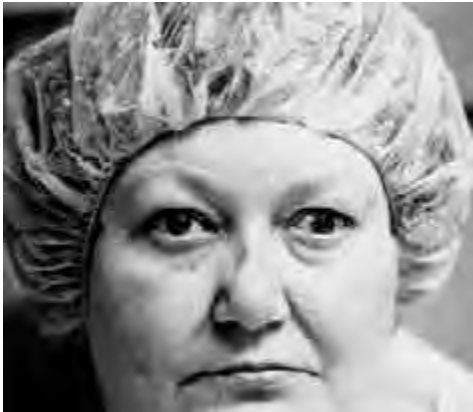was a mechanical restriction to elevation associated with the left inferior rectus confirmed at surgery. Although the Fresnel press-on prism was successful in eliminating her diplopia, it caused blurring of vision in the left eye. Glass prism would have been an alternative, but at 12 prism diopters glass prism creates a wide edge on the spectacle lens. Prisms are heavy; the total weight is similar (but the edge reduced) if the prism strength is divided between the lenses. At surgery, 2 ml of 1% xylocaine was injected for 360 degrees subconjunctivally near the limbus to provide anesthesia in the left eye.(see p 69). The left inferior rectus was recessed using an adjustable suture. After the inferior rectus was detached and reattached to the globe with the suture, the patient was asked to respond to visual targets overhead while she was supine on the operating table. In addition to this subjective testing, during which she observed horizontal and vertical ceiling tiles, cover testing was also done. The inferior rectus was secured with a bow knot when the patient reported single vision and when no shift was noted on the cover test. An hour later in the recovery room, prism cover testing was repeated. When the patient continued to show no shift with the cover test, the knot was "tied off" into a surgeon's knot. The presumed cause of the inferior rectus restriction was myopathic change of the left inferior rectus secondary to the retrobulbar injection of anesthetic agent at the time of the cataract surgery.

Conditions leading to diplopia after cataract extraction	
Condition	No. of patients (N = 38)
Superior oblique palsy diagnosed before cataract surgery	2
Superior oblique palsy diagnosed after cataract surgery	5
Sensory deviations noted before cataract surgery	4
Childhood esotropia	3
Childhood exotropia	1
Skew deviation	2
Superior rectus muscle paresis	2
Choroidal neovascular membrane involving the macula	1
Decentered intraocular lens	2
Idiopathic (presumed myopathy from local anesthetic)	16

From Hamed LM, Helveston EM, Ellis FD: Am J Ophthalmol 6(6):741-744, 1987

CASE 56: Diplopia after repair of retinal detachment

Clinical picture



Left hypotropia and exotropia after repair of a retinal detachment in the left eye.

History

This 56-year-old woman had repair of a retinal detachment in the left eye 1 year ago. She has obtained an excellent recovery of visual acuity in that eye, but since surgery she has been bothered by horizontal and vertical diplopia. She would like to have her eyes straightened and be rid of the diplopia.

Examination

Visual acuity is OD 20/20 and OS 20/50. The patient is wearing the following glasses: OD -3.50, OS -7.50. Ductions are entirely free in the right eye. The left eye has moderate limitation of adduction and elevation. The conjunctiva of the left eye has moderately reddened and scarred from her previous retinal detachment surgery. The left eye has a high buckle with a chorioretinal scar where the retinal hole was treated.

Diagnosis

Left hypotropia and exotropia secondary to her retinal detachment repair.

Treatment/Surgery

Recession of the left lateral rectus, resection of the left superior rectus.

Comment

The more successful the retina surgeon is in restoring useful vision, the more likely it is that the patient fortunate to have good vision restored will be at risk for the complication of diplopia. This patient is an example. While most visually rehabilitated retinal detachment patients are free of diplopia, the few who have it are usually disturbed by it. Double vision can be related to side effects of the detachment or its repair and may actually be *monocular* diplopia or binocular triplopia. Patients like this should always be evaluated for monocular diplopia. This is diagnosed if diplopia persists with one eye closed. If it is eliminated when the patient looks through a pinhole, the diplopia is caused by conditions in the ocular media. Monocular diplopia that persists when looking through a pinhole is of retinal or of central nervous system origin. However, the most common diplopia after repair of retinal detachment is binocular diplopia caused by adhesions of the peribulbar fascia and/or the extraocular muscles, from paresis of an extraocular muscle, or from restriction caused by an encircling band or other support element.

In the case described here, the left superior rectus muscle apparently had been detached and then reattached approximately 7 mm from the limbus resulting in what amounted to a recession of this muscle. Passive ductions were free before detaching the muscle. An encircling element was found just posterior to the superior rectus insertion. Resection and advancement of the left superior rectus muscle totaling 5 mm was done without disturbing this encircling band. The left lateral rectus was then recessed 5 mm with the muscle's final position remaining anterior to the encircling band. Postoperatively the patient's eyes were aligned in the primary position, and she was free of diplopia in all useful fields of gaze. Frequently, in cases of diplopia after retinal detachment surgery, it is necessary to remove supporting elements. This can be done safely a year or more after the detachment surgery. After this time, the various elements no longer provide support to the retina. However, if there is ever a question about the safety of removal of retinal 'hardware,' the retinal surgeon should be consulted before taking the patient to surgery. In my experience, when strabismus surgery is required in a post retinal detachment repair patient who has an encircling band the surgery is more effective if the band is removed.

CASE 57: Diplopia after repair of retinal detachment

Clinical picture



Right hypertropia in a patient who is wearing 4 diopters base-down prism OD and 4 diopters base-up OS.

History

This 60-year-old man had retinal detachment repair done on the right eye one year ago. Six months ago, he underwent vitrectomy in that eye because of multiple large floaters in the vitreous. Since the second surgery, he has had constant diplopia. He is unable to drive at night, especially in the rain. His right eye myopia increased after surgery, but he wears undercorrecting glasses to lessen the effect of his diplopia.

Examination

Visual acuity with his present glasses is OD 20/300- and OS 20/25. He is wearing glasses as follows: OD -4.75+0.75 X 150 degrees 4 diopters of prism base-down, and OS -2.50+0.50 X 35 degrees 4 diopter of prism base-up. Prism and cover testing in the distance shows 3 prism diopters of exotropia and 10 prism diopters of right hypertropia. At near, measurements increased to 5 prism diopters of exotropia and 12 prism diopters of right hypertropia with left head tilt. There is slight limitation of depression OD. Refraction of the right eye is -7.00+0.75 X 115 degrees. With this, visual acuity improves to 20/60.

Diagnosis

Right hypertropia producing diplopia after retinal detachment repair and vitrectomy of the right eye.

Treatment

The patient was given new glasses with the proper myopic correction and a total of 10 diopters base-down prism OD and 3 diopters base-in prism OS. He was also told that surgery could be done if he was not satisfied with prism treatment.

Surgery

The patient later decided to have surgical correction because he was more comfortable with his new glasses. An adjustable right superior rectus recession was done.

Comment

Passive duction testing at surgery demonstrated restriction to depression of the right eye. This confirmed the need to explore the area of the right superior rectus. Scarring of the intermuscular membrane and anterior Tenon's capsule was found in conjunction with an encircling band and a sponge that were immediately behind the superior rectus insertion. The sponge and the band were removed and the superior rectus muscle was recessed using an adjustable suture. Although this patient's eyes were aligned postoperatively, he complains of a "strain" while wearing his fully correcting spectacles. It is possible that the patient is actually having symptoms from the aniseikonia, in which case treatment may be aimed at intentionally blurring the right eye by undercorrecting the myopia as was done before surgery. In some cases with unequal visual inputs acquired in adulthood, comfortable binocular vision is not attainable. This may be such a case.

CASE 58: 'V' pattern esotropia with overaction of the inferior oblique muscles

Clinical picture



A, Chin depression with straight eyes; B, esotropia in downgaze; C, overaction of the right inferior oblique; D, overaction of the left inferior oblique; E, eyes aligned in upgaze.

History

This 4-year-old girl was brought in for examination by her parents because they observed that she holds her chin down when she looks at things and that one eye seems to “shoot up” when she looks to the side.

Examination

Marked chin depression was the most obvious sign when observing this child. She had 20/40 vision in each eye with pictures. Cycloplegic refraction was OD +1.75 and OS +1.50. Versions demonstrated

marked (3+) overaction of both inferior obliques. A ‘V’ pattern was present with straight eyes when looking up and 35 prism diopters of esotropia when looking down. The remainder of the examination was unremarkable.

Diagnosis

'V' pattern esotropia with bilateral overaction of the inferior oblique muscles.

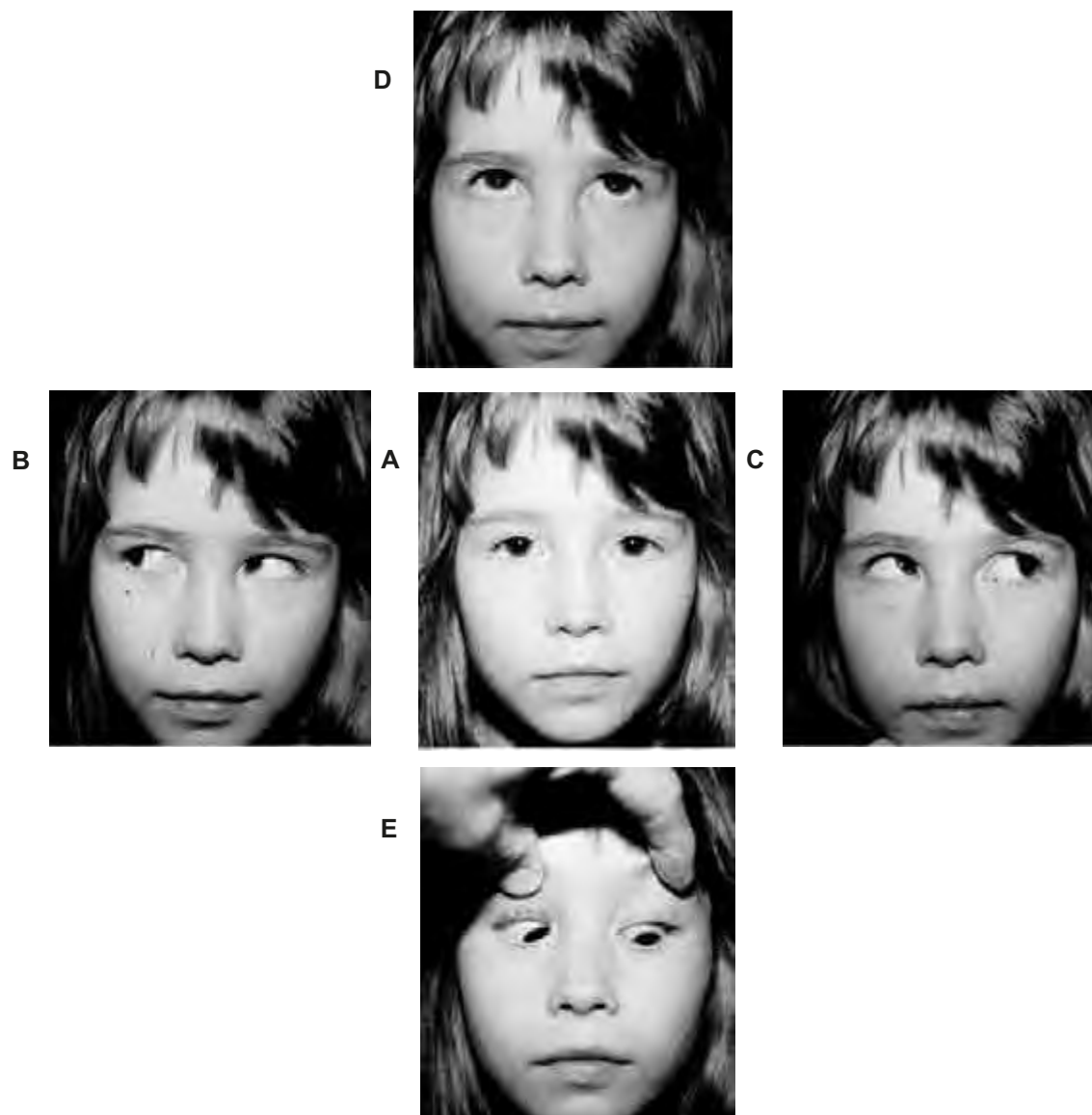Treatment/Surgery

Bilateral inferior oblique weakening.

Comment

This is a case of so-called primary overaction of the inferior obliques. Such a case could be called bilateral congenital superior oblique palsy. However, in this case, at surgery the superior oblique traction test was normal bilaterally, as indicated by finding a definite “knife-edge” response. The true cause for this so-called primary inferior oblique overaction is unknown to me. In a case like this, bilateral inferior oblique weakening is effective in opening up the ‘V’

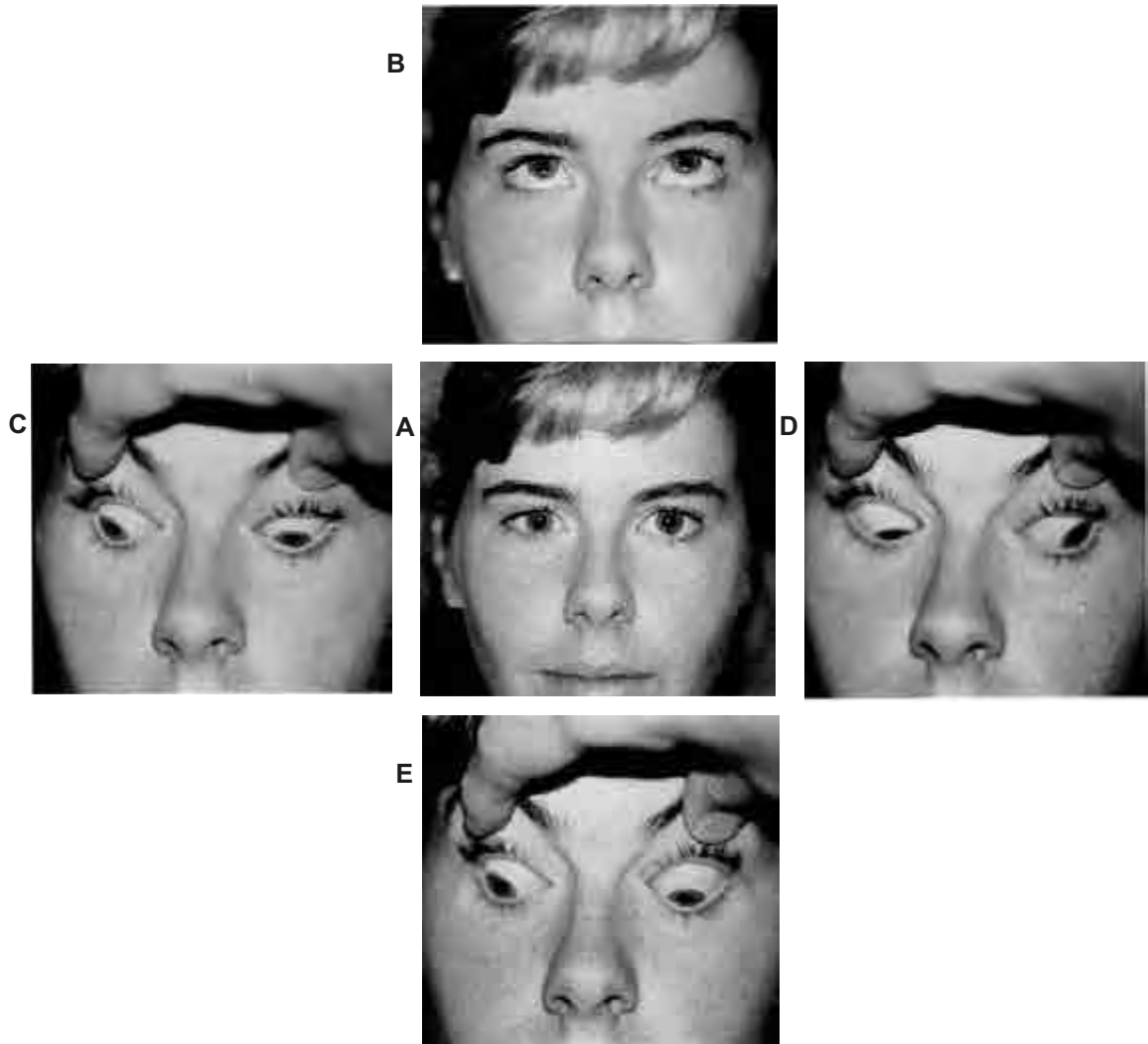
pattern by decreasing the esotropia in downgaze. As an alternative, the medial recti could be shifted downward to treat the ‘V’, but this would be more reasonable if there were anti-mongoloid fissures or other evidence of pulley heterotopy. In case of a bilateral congenital superior oblique palsy confirmed by finding a loose superior oblique tendon on superior oblique traction testing, the superior oblique weakening procedure could be done. This procedure is more difficult. Most surgeons prefer to weaken the inferior obliques.



This patient is similar to the previous patient with a ‘V’ pattern except that **A**, the head posture is normal; **B**, and **C**, the inferior obliques do not overact; and **D**, a small exotropia is present in upgaze and **E**, Esotropia is present in downgaze. This patient would benefit from downward shift of the insertion of the medial rectus muscles.

CASE 59: 'A' exotropia, bilateral overaction of the superior obliques, dissociated vertical deviation (DVD)

Clinical picture



A, In the primary position the eyes are aligned with the chin slightly depressed. **B,** A small esotropia is seen in upgaze. **C,** The left superior oblique overacts. **D,** The right superior oblique overacts. **E,** Fifty diopters of exotropia is seen in downgrade.

History

This 19-year-old college freshman has had difficulty in concentrating on her schoolwork. She has difficulty especially when required to read for long periods. She is also concerned because her friends often say that there is something “funny” about her eyes. Neither the patient nor her parents had any apparent further insight into the problem in that they were not aware of any “crossing” or misalignment of the eyes.

Examination

Visual acuity without correction is 20/20. The eyes are straight in the primary position, but the patient appeared to dip her chin down slightly and to look upward as an unconscious gesture. Six of nine stereo dots (80 seconds) were fused. Ductions were full in either eye. On testing of versions, a significant ‘A’ pattern was observed with bilateral overaction of the superior oblique muscles. Cover and uncover testing revealed 1+ dissociated vertical deviation in each eye in the primary position. Five prism diopters

of esotropia was present in upgaze and 50 prism diopters of exotropia was present in downgaze, confirming that a large 'A' pattern was present. These motility findings were demonstrated to the girl's parents. They exclaimed that they had never seen the eyes do this!

Diagnosis

The triad-'A' exotropia, bilateral overaction of the superior obliques, dissociated vertical deviation.*

Treatment

None now -- see comment.

Surgery

None now -- see comment.

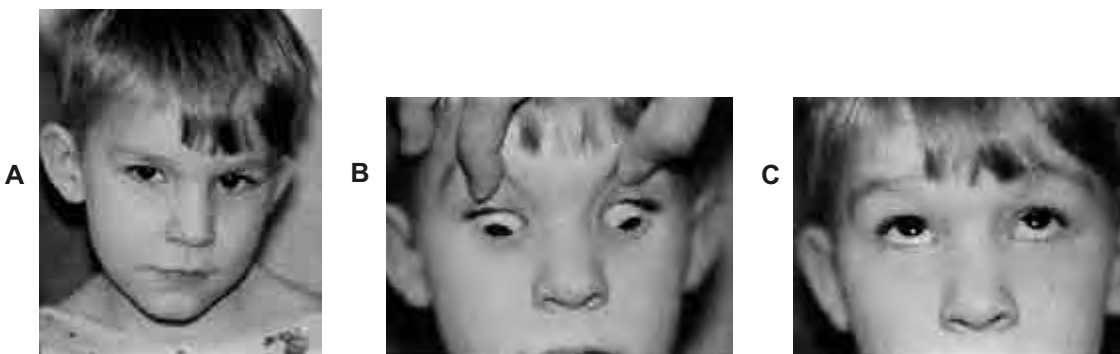Comment

This patient demonstrates an ocular motility triad that is not uncommon but which must be looked for carefully and with awareness that such a pattern of motility disturbance exists. This triad can occur primarily or as a secondary strabismus. It can occur in a patient who has excellent fusion or in one without fusion. The degree of involvement can be mild or marked. In this case, the patient had only minimal DVD but had a rather marked 'A' pattern. She was able to compensate for this effectively by assuming a slight chin depression. In cases like this, it is often necessary to point out the findings to the family. For this patient, I recommend *no* surgery for several reasons. First, neither the patient nor her family knew that there was any specific motility problem when they came for this examination. They only were

aware that "something was wrong." In addition, this patient is doing satisfactory schoolwork with only minimal symptoms. However, if in the future, she has more difficulty with either her schoolwork or with the comments of her friends, surgery could be done. The fact that both the patient and her family will have some insight into the nature of the strabismus makes it more reasonable to consider surgery some time in the future. It is not a good idea to perform surgery for a strabismus that neither the patient nor the family noticed!

If surgery were to be done for this patient, it would consist of bilateral weakening of the superior oblique tendons. It should be understood that weakening of the superior oblique tendons in a fusing patient should be done symmetrically and with full consideration for the consequences; that is, loss of fusion and creation of vertical strabismus with diplopia. In other cases of this triad where the dissociated vertical deviation is also a significant problem, bilateral superior rectus recession can be combined with bilateral superior oblique weakening. As an alternative procedure in this case, the lateral rectus muscles could be shifted downward one-half to three-quarters muscle width. This procedure is "safer" and it is certainly easier to reoperate if the need should arise. It would treat the superior oblique overaction if the lateral pulleys were displaced upward as in a mongoloid fissure.

The 5-year-old boy shown below was examined because he habitually kept his chin down and looked up. Because this was becoming a problem, according to his parents, and since they were aware of the strabismus and the implications of treatment, he was treated with bilateral superior oblique recession.



A, With his chin down and looking up, this patient's eyes were aligned. **B**, Exotropia measuring 40 diopters in downgaze. **C**, Aligned eyes in upgaze.

* Helveston, EM: A-exotropia, alternating sursumduction and superior oblique overaction, Am J Ophthalmol 67:3, March 1969.

CASE 60: Parinaud's paralysis of elevation

Clinical picture



Downgaze in a 28-year-old woman with Parinaud's syndrome.

History

This 28-year-old woman was treated for a pituitary tumor at age 5 years. Since that time, she has been unable to look up. In order to see, she chronically elevates her chin and looks down. She is also bothered by intermittent diplopia. Her biggest problem now is pain and stiffness in her neck, presumably secondary to chronically elevating her chin. She frequently seeks professional help for the neck pain.

Examination

Visual acuity is OD 20/25 and OS 20/40 while wearing the following correction: OD +1.25+0.75 X 135 degrees, and OS +1.75+0.50 X 45 degrees. The patient assumes approximately 20 degrees of chin elevation while looking downward chronically. She cannot elevate her eyes even to the midline. The eyes are approximately 15 prism diopters exodeviated in downgaze and approximately 15 prism diopters esotropic with maximum attempt of upgaze.

Diagnosis

Parinaud syndrome--paralysis of upgaze.

Treatment/Surgery

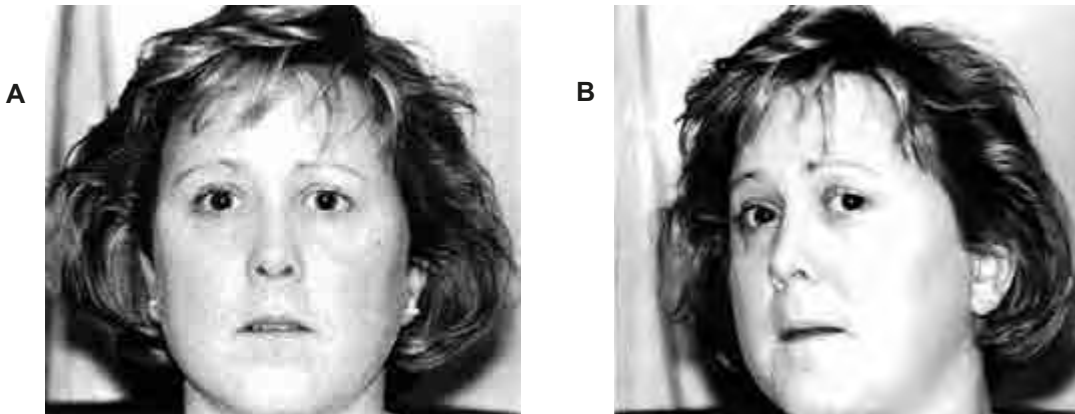
Recession of both inferior recti 5.0 mm, resection both of superior recti 6.0 mm, with advancement of Lockwood's ligament 5.0 mm.

Comment

This patient has no realistic hope of fusion, but she can be helped by simply bringing her eyes up to the primary position to enable comfortable vision without elevating her chin and arching her neck. In this type of case, expectations are limited, but any help that the patient can obtain is usually greatly appreciated. After surgery, this patient had no need to lift her chin, but she was slightly more aware of diplopia. She considered this a more than adequate trade off for the improved head and neck posture.

CASE 61: Null point nystagmus

Clinical picture



A, With the head straight acuity is diminished and nystagmus is present (vision 20/80); **B**, With right face turn and levoversion nystagmus is dampened (acuity 20/40).

History

This 29-year-old woman complains that her eyes dance and her vision is poor. The only way she can improve her visual acuity is to turn her face to the right and look far to the left. She is employed as a technician in an ophthalmologist's office.

Examination

With the head straight and the eyes in primary position, visual acuity is 20/80 in each eye and with both eyes open. A large amplitude right-beating nystagmus is present. When the patient attempts to improve her visual acuity, she turns her face 40 degrees to the right and assumes maximum levoversion. Visual acuity then is 20/40 with both eyes open. Visual acuity in levoversion reduces to 20/60 with either eye occluded, because of latent nystagmus. After repeated checks of visual acuity, the patient always assumes the same head posture with right face turn and left gaze. The remainder of the eye examination is unremarkable.

Diagnosis

Null point nystagmus.

Treatment/Surgery

Anderson procedure: Recession of the left lateral rectus, and recession of the right medial rectus. As an alternative this patient could have recession of the four horizontal recti to the equator.

Comment

Since the description more than a half century ago, the surgical procedure of choice for null point nystagmus has been based on the principle of the Kestenbaum-Anderson procedure. This procedure attempts to shift the null point of nystagmus to the straight-ahead position. To accomplish this, using as an example the patient shown here, the left lateral and right medial rectus muscles are recessed and left medial and right lateral rectus muscles are resected. This means that the neural output for levoversion required preoperatively will put the eyes in the primary position with the head straight or nearly straight after surgery. In the years since its inception, this type of surgery has been only moderately successful. Actually, a few years after surgery, most patients note that the head posture gradually returns or they find that they can achieve comfortable vision by turning their head just as far as before but in the opposite

direction! In the beginning, Kestenbaum recommended recessions and resections limited to 5 mm. Anderson recessed only the two yoke muscles a distance of 5 mm. Since this null point nystagmus surgery tended to be unsuccessful, the surgical amounts were gradually increased proportionally by frustrated surgeons. Finally, Pratt-Johnson described doing 10 mm recessions and resections in both eyes. I suspect that even this maximum surgery will over time fail in many cases. There is something decidedly nonphysiologic about this null point nystagmus surgery, because after this surgical procedure is done, patients must chronically exert effort to hold their eyes and head straight, whereas in the normal state this posture should require the *least* effort! This may be the reason why some patients assume a head posture in just the opposite direction in order to sustain comfortable vision.

I have begun to do recession of the four horizontal recti instead of the modified Kestenbaum-Anderson procedure for most null point nystagmus. By relaxing all of the horizontal rectus muscles, the

amplitude of nystagmus diminishes by about 50%. If the null point nystagmus improves and then later reverts to preoperative findings or if no improvement results from large recession of the four horizontal recti, the yoked rectus muscles opposite the preferred version (the same side as the direction of the face turn) are advanced to their original insertion. This procedure(s) appears to be more physiologic and definitely is tissue sparing. Actually it is a larger, staged Anderson procedure. At the present time, this approach to null point nystagmus is unproven. However, since the Kestenbaum-Anderson procedure is proven, but proven *lacking* for the most part, any logical alternative for this surgery seems reasonable.

In some cases of null point nystagmus, a primary Anderson procedure can be done using larger numbers than originally described. For example, with null point achieved by dextroversion the right lateral rectus would be recessed 8.0 to 10.0 mm and the left medial rectus recessed 12.5 mm from the limbus.

CASE 62: Congenital nystagmus with decreased vision

Clinical picture



A 16-year-old boy with congenital nystagmus (shown here after surgery).

History

This 16-year-old boy has been followed for congenital nystagmus since age 5 years. He and his mother say that he has had “dancing eyes” all of his life. Visual acuity had been recorded on repeated occasions with the letter chart at no better than 20/80 at distance with both eyes. He has always been able to read newspaper size print and he has made satisfactory progress in school. However, because of reduced visual acuity, he was unable to obtain a learner’s permit and enroll in driver’s education. The boy and his mother returned for an annual examination at age 14 years to find out if anything could be done to help this boy’s acuity level that would allow him to obtain his learner’s permit. He drives a motorbike without difficulty and has driven an automobile under supervision with his family.

Examination

Before surgery, visual acuity with correction is OD 20/80 and OS 20/100, both eyes 20/80 without glasses. Cycloplegic retinoscopy is OD and OS +0.75. A rapid, moderate amplitude pendular nystagmus is present in the primary position. This becomes a right-beating nystagmus on right gaze and a left-beating nystagmus on left gaze. The nystagmus amplitude increases slightly in each eye when the fellow eye is occluded. Near vision is 20/40, and the nystagmus is damped significantly by convergence. Both optic nerves are small, but no double rings sign is noted and a clear cut diagnosis of bilateral optic nerve hypoplasia cannot be made. The remainder of the eye examination is unremarkable.

Diagnosis

Congenital motor nystagmus with decreased visual acuity.

Treatment/Surgery

Recession of the four horizontal rectus muscles.

Comment

Nystagmus has two important connections with visual acuity. First, poor vision causes nystagmus, if the poor vision has onset at a young age. The 2-4-6 rule of Cogan states that poor vision occurring before 2 years of age *always* produces nystagmus, poor vision before 4 years of age *can* result in nystagmus, and poor vision after 6 years of age *does not* produce nystagmus. The second important relationship is that *nystagmus causes reduction in vision*. These two can be combined. That is, nystagmus can cause a reduction in visual acuity in an otherwise normal eye or in an eye with some reduction in vision because of the motion of the retinal image. In a case where suitable retinal potential exists, stabilizing the retinal image results in improved visual acuity. A common strategy for stabilizing the retinal image and improving visual acuity is the head turn adopted in null point nystagmus. In another strategy, nystagmus can be reduced and visual acuity improved by convergence. Most patients with congenital motor nystagmus and with nystagmus having its origins in relative visual deficits will see better at near because of reduced amplitude of nystagmus and because the retinal image is larger.

Nystagmus can also be damped by induced convergence stimulated by the use of base-out prism,

*Speilmann A, Dahan A: Double torticollis and surgical artificial divergence in nystagmus, ACTA Strabol, 1985 p 187.

by overcorrecting minus lenses and by surgery to produce 'artificial divergence' as recommended by Spielmann*. However, this treatment technique has not become widespread. Surgery to shift the null point of nystagmus (Kestenbaum-Anderson procedure) does not improve vision; it simply attempts to improve head posture in a patient who has already developed a strategy to improve vision.

The four-muscle recession procedure is a unique strategy for damping nystagmus and in turn improving visual acuity. This was originally done 40 years ago by Bietti and Bagolini. They discarded the technique because it did not retain its effectiveness. Later, Limon of Mexico City revived the procedure and reported significant success. von Noorden and Sprunger reported successful results in three patients, and we later reported successful results.

The principle of the four-muscle recession is to more or less diminish the power of the rectus muscles by reducing the length tension and the lever arm in a balanced way so as to not induce strabismus. This technique is designed to reduce the exuberance of the contraction of the muscle, the factor ultimately responsible for the eye movement.

The technique for recession of the four horizontal recti for treatment of nystagmus was originally to move the muscles back to a point approximately 2 mm behind the equator. Some surgeons moved the medial and lateral rectus muscles a nearly equal amount meaning that the relative recession of the medial rectus was actually greater. As would be expected, this produced exotropia pointing out the need to recess the recti a *proportional* amount meaning that the medial recti should be recessed 2 or 3 mm less than the lateral recti. Later it was suggested that since the functional origin of the rectus muscles could be at their pulley, recession behind the equator was not necessary. In response, I began recessing the horizontal only to the equator with no change in results from surgery.

Indications for four-muscle surgery for nystagmus are the following:

1. Reduced visual acuity and nystagmus, preferably, but not necessarily, with vision improved with the nystagmus damped.
2. Difficult eye contact because of nystagmus
3. Understanding on the part of the patient that improvement will be incremental and not necessarily dramatic
4. No contradiction to surgery

My experience with four muscle recession for the treatment of nystagmus can be summarized in the following:

1. Less than 10% of nystagmus patients fit the criteria for surgery.
2. Patients who are candidates for surgery should be expected to benefit from the reduc-

tion of nystagmus amplitude with or without improvement in visual acuity.

3. If visual acuity improves at all after surgery, it is on the order of *one line!*
4. Recession of the four horizontal recti is carried out to or slightly in front of the equator.
5. After surgery, nystagmus *amplitude* is reduced about 50% while frequency remains unchanged.
6. As pointed out by Sprunger, et. al., recognition time improves after four muscle recession. This means that a patient can recognize the smallest optotype in *less* time. The functional value is that a person can enter a new and possibly confusing environment and become oriented faster.
7. After surgery, ductions are reduced, but symmetrically and to a minimal degree.
8. New strabismus after four muscle recession is rare and is easily managed at a second procedure.
9. Patients are pleased with the results in nearly every case and state that they would do it again.
10. On three occasions, a second family member underwent the surgery after observing results in a parent, a sibling,, and a grandparent. A woman who had surgery for her nystagmus brought her son a year later; she was so pleased with the results. In another case it was sisters with universal albinism. The second sister, observing the results of surgery, accompanied her sister at a one year follow up and requested surgery for herself. In a third case, a grandfather with nystagmus had the surgery to "see if it was effective." After the results of surgery were evident, he brought into the clinic two grandchildren to have four muscle recession.

Recently, Hertle and Dell'Osso reported that simply detaching and reattaching the four horizontal rectus muscles has a beneficial effect on nystagmus. This would rely on the disruption of proprioceptive response of the rectus muscles.


The four muscle recession for treatment of nystagmus is said to rely on 'soft' evidence and anecdotal endorsement, making it difficult to defend on a purely scientific basis. In addition, it was subject to criticism and even warnings against what could be a "wholesale" approach to the treatment of nystagmus. This has not happened. Instead, a relatively small number of patients have received a modest but appreciated improvement in both their visual function and appearance.

Patients should be thoroughly counseled before this surgical procedure is done. The small average improvement of visual acuity should be emphasized.

Patients should be told that the nystagmus will not go away. At best, the amplitude is reduced by approximately 50% but the frequency remains unchanged. Patients are also told that between 10% and 20% of patients need additional surgery for a new horizontal strabismus, usually an exotropia. In our practice, 6.5% of 396 consecutive patients seen over a 5-year period with a principal diagnosis of nystagmus had this type of surgery. This means that because of stringent selection criteria, relatively few patients are considered suitable candidates for four-muscle recession for the treatment of nystagmus. When comparing four-muscle recession, a tissue-sparing operation, with the bilateral 10 mm recession/resection or similar procedures, for treatment of null point nystag-

mus, it is clear that the four-muscle recession is less radical than other methods for surgical treatment of nystagmus, some of which have been more or less accepted as standard and routine.

Immediately after the recession of the four horizontal recti, visual acuity in the patient described in this case improved to 20/60 with both eyes open. On the basis of this improvement, he was able to obtain a driver's license with driving privileges limited to the daylight hours. Two years later, vision remained at 20/60 tested binocularly, but 20 diopters of left exotropia developed. This was treated with a 6.0 mm advancement of the left medial rectus, which resulted in alignment.



A, Primary position alignment after four horizontal rectus recession posterior to the equator followed by 6.0 mm advancement of the left medial rectus for secondary exotropia. **B**, Dextroversion is full. **C**, Levoversion is full.

CASE 63: Nystagmus after brain stem stroke

Clinical picture



The right eye has vertical, horizontal, and rotary nystagmus with oscillopsia after a brain stem stroke. The left eye vision is hand motion from a corneal scar. A left seventh nerve palsy persists. A lateral tarsorrhaphy has been done.

History

This 55-year-old woman complained of reduced vision because of constant movement of her environment (oscillopsia). She had a brain stem stroke 2 years previously, and in addition to her visual difficulties, she is confined to a wheelchair because of hemiparesis. Her left eye has only hand motion vision because of a corneal scar following an ulcer that occurred secondary to exposure, which in turn was caused by lagophthalmos from seventh nerve palsy on the left. This patient wanted some relief from oscillopsia to be able to read and to watch television.

Examination

Visual acuity in the right eye with correction of $-0.50+1.50 \times 90$ degrees is 20/100 and in the left eye it is hand motion. A large amplitude pendular horizontal vertical and to a lesser extent rotary nystagmus is present in both eyes. The left eye is 30 prism diopters esotropic, with a dense corneal scar obscuring the visual axis. A facial paralysis is present on the left as well as sixth nerve palsy on this side. The right eye is normal except for the nystagmus.

Diagnosis

Oscillopsia and reduced visual acuity from nystagmus secondary to brain stem stroke.

Treatment/Surgery

Retrobulbar Botox.

Comment

This is the second patient ever to be treated with retrobulbar Botox. I treated the first patient with toxin injected into the four rectus muscles. This had no beneficial effect. As a second attempt in this patient, 25 units of Botox was injected into the retrobulbar space. This patient had improvement of visual acuity from less than 20/100 to 20/30 in 2 days. The improved vision resulting from decreased movement of the eye lasted for about 3 months. After that, the Botox injection had to be repeated, fortunately producing similar results. After three injections, this patient asked to be followed by an ophthalmologist closer to her home to continue this form of treatment.

The patient described here, the second patient so treated, had the same response as the patient described in the preceding paragraph. She has had a total of more than 30 retrobulbar Botox injections, each remaining effective for approximately five months. After each injection, visual acuity improves to between 20/30 and 20/40 within 24 to 48 hours. No complication from this treatment has been noted. At first we were curious that this patient never had ptosis after any treatments, nor did the first patient after three treatments. We later learned that this was because we had the patients sit up immediately after the injection. This prevented the toxin from pooling at the apex and affecting the nerve to the levator palpebri. Because of presbyopia in both of these patients, requiring reading glasses, any effect on accommodation is not significant.

More than two dozen patients have been treated successfully in our clinic. The relief is temporary, but is appreciated by the patients.

Retrobulbar Botox provides significant temporary improvement in vision for the few who qualify for this type of treatment.

CASE 64: Superior oblique myokymia

Clinical picture



History

This 47-year-old teacher complains that several times a day he sees things double and moving. The second image moves with a pulsating torsional pattern. Without warning, objects seen by the left eye tilt upward and outward. He can stop the sensation only by closing this eye. It disappears spontaneously and comes on without warning.

Examination

The patient has 20/20 visual acuity in each eye. The remainder of the eye examination is completely normal, and he fuses 9/9 stereo dots (40 seconds). Refraction is plano in each eye. After observing this patient for several minutes and after repeated testing of versions, especially having him look up and to the right, a rhythmic incyclodeviation and depression of the right eye began. This is a motion typical of superior oblique myokymia and nothing else. While I observed these motions, the patient described the excyclo-oscillopsia.

Treatment

Just wait. It may go away! Possible medical treatment includes carbamazepine initially. Also, clonazepam, phenytoin, and baclofen have been used.

Surgery

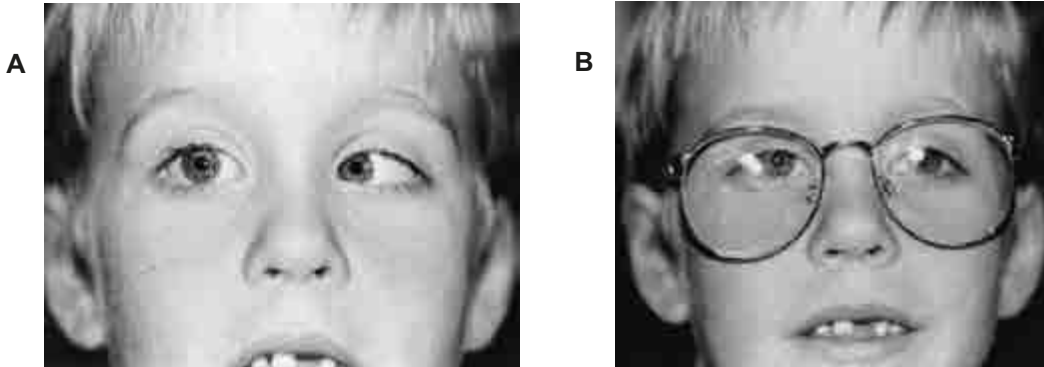
Right superior oblique weakening plus ipsilateral inferior oblique weakening

Comment

Superior oblique myokymia is a rare ocular motility disorder. In the handful of cases that I have seen, patients are extremely disturbed by the oscillopsia. Medical treatment may not be successful and can have serious side effects. I do not endorse it. Superior oblique weakening can be successful in alleviating these symptoms. I prefer to do this by means of disinsertion of the tendon. Superior oblique palsy occurs frequently in cases treated this way. When this occurs, a weakening procedure of the antagonist inferior oblique is done. I have treated one case of superior oblique myokymia with injection of Botox into the superior oblique muscle. This also produced a marked ptosis. When the ptosis resolved, the myokymia returned. A repeat injection did the same, but the myokymia was greatly improved after the second injection. Whether this is only due to the Botox treatment is open to question.

CASE 65: Typical refractive esotropia

Clinical picture



A, Esotropia of 45 prism diopters. B, Eyes are aligned wearing +3.00 diopters spectacles.

Comment

This boy, who is now 5 years old, developed esotropia at age 3 years. He was found to have a hyperopia of +3.00 diopters and given glasses to fully correct this. While wearing these glasses, he is aligned with 9/9 stereoacuity (40 seconds) and has essentially normal motility. This represents a typical pattern for a patient with refractive esotropia. After initial success, these patients typically continue to do well with glasses wear. Some patients are even able to revert to part-time wearing of glasses during the teen years and later, but because of asthenopia and/or blurred vision related to the hyperopia, they always return to wearing glasses during adulthood and well before the usual age of presbyopia. These patients have a normal to slightly high accommodative convergence--accommodation ration (AC/A), and the deviation is the same at distance and near.

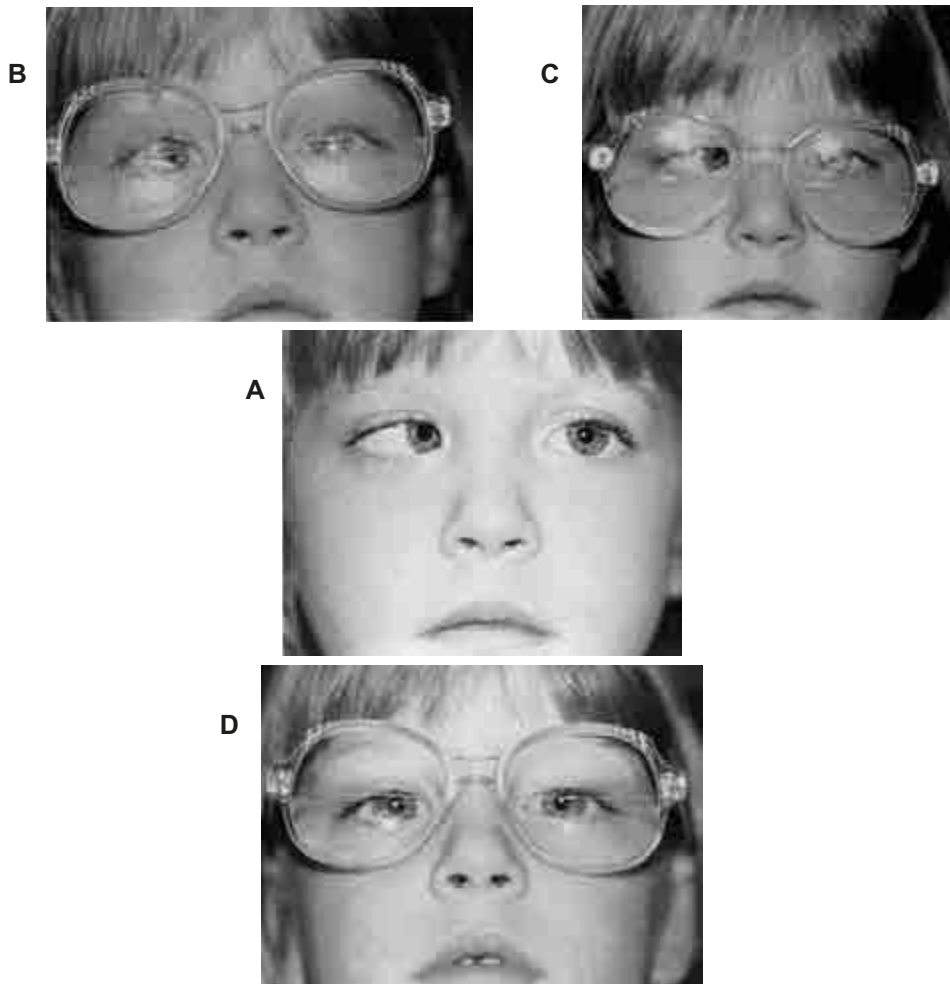
A disquieting movement advocating surgery instead of optical correction for refractive esotropia has begun among some strabismologists, primarily in Europe.* Substituting surgery for optical correction for refractive esotropia flies in the face of all that we know about the nature of this condition. Patients undergoing surgery for refractive esotropia continue to require correction for hypertropia and are therefore asthenopic or simply have blurred vision without optical aid, particularly in the teens and later years. In addition, patients treated with bimedial rectus recession or equivalent for refractive esotropia are very likely to develop exotropia with or without reinstitution of glasses. Surgery in place of hyperopic correction for treatment of refractive esotropia should be condemned!

*A roundtable discussion on the management of fully accommodative esotropia can be found in Campos E, Editor: Strabismus and oculomotility disorders, Proceedings of the Sixth Meeting of the International Strabismological Association, London, 1991, Macmillan, pp 269-305.

**Jampolsky A, von Noorden GK, Spiritus M: Unnecessary surgery in fully refractive accommodative esotropia Australian-New Zealand. J Ophthalmol Nov 1991 (19)4 p 370-373.

CASE 66: Refractive/accommodative esotropia (high AC/A)

Clinical picture



A, Without correction, this patient has esotropia at distance (in some cases of pure accommodative esotropia [high AC/A] the eyes may be aligned in the distance) and crossing at near. Her refraction after cycloplegia is OD and OS +2.50. **B**, Fixing in the distance through the carrier and wearing full correction, the eyes are aligned. **C**, Fixing at near through the carrier, the patient has a large esotropia. **D**, Fixing at near through the +3.00 add (bifocals are usually from +1.50 to +3.50), the eyes are aligned.

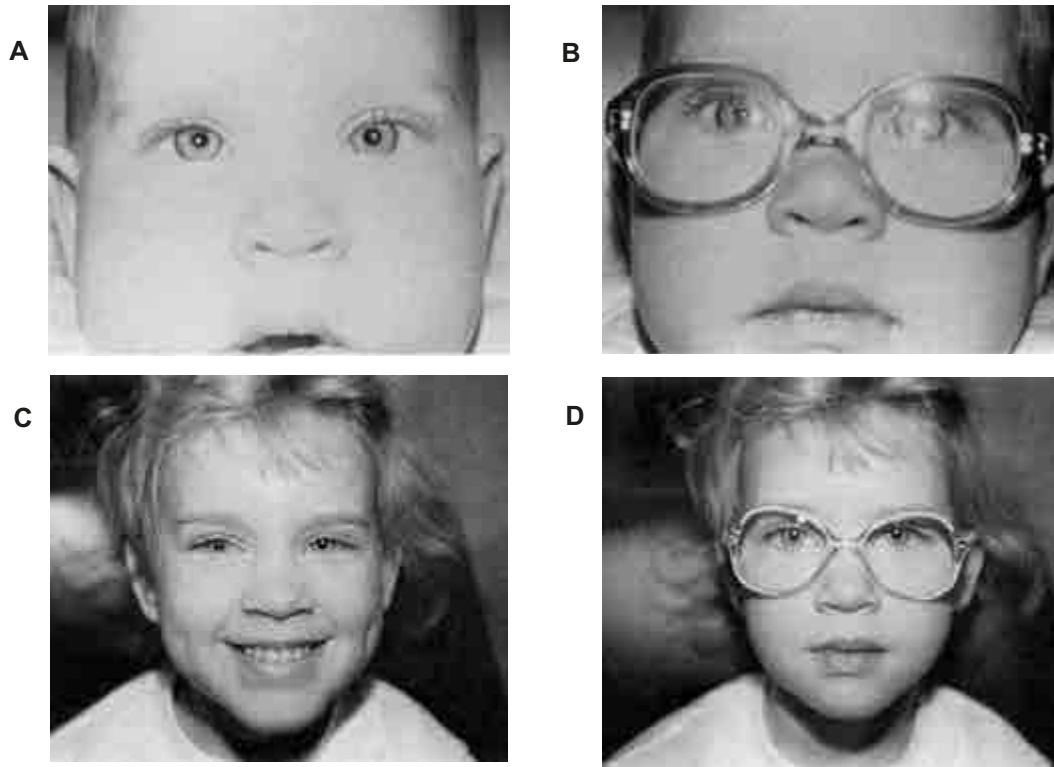
Comment

Refractive/accommodative esotropia can be difficult to manage. These patients may be plano, hyperopic, or even myopic, but they all have in common a high accommodative convergence/ accommodation (AC/A) producing an esotropia at near. The philosophy of treatment varies according to the strabismologist's experience. I use bifocals if the eyes are aligned at near while looking through them, but not if the angle of deviation is only reduced. Patients may be continued with bifocals as long as they are necessary to maintain fusion. Some strabismologists attempt to wean patients from bifocal wear gradually, while others stop bifocals abruptly at a certain age or at a certain reduced near deviation. Some do not use

bifocals at all. In selected cases, bimedial rectus recession with or without posterior fixation suture may be done for patients whose eyes are straight in the distance but who reach their teen years and cannot be weaned from bifocals without developing esotropia at near. There is no universally agreed upon way to deal with this type of strabismus. Prolonged wearing of bifocals has been said to contribute to premature presbyopia. This could be a reason for discontinuing them in favor of surgery or even allowing the child to be esotropic at near. In such a case, the distance alignment can have an effect on the near contributing eventually to near alignment.

CASE 67: Refractive esotropia with dissociated vertical deviation

Clinical picture



A, Esotropia in a 6-month-old girl. **B**, Eyes aligned with +3.00 diopter glasses. **C**, Without correction, the esotropia remains at age 6 years. **D**, With glasses, the eyes are aligned but DVD is present in each eye.

Comment

This infant was brought in for examination at 6 months of age with 30 diopters of esotropia that had its onset at 3 months of age. Full correction of 3.00 diopters of hyperopia in each eye resulted in straight eyes. This is early for refractive esotropia. By age 4 years, this patient, who retained alignment while wearing her glasses demonstrated gross stereopsis, but also had DVD! This case blurs the distinction between refractive and congenital esotropia. I believe that this child has congenital esotropia

straightened with glasses instead of surgery. The best treatment for this child is the continued use of her glasses. She was later found to have asymmetric optokinetic nystagmus suggesting that the basic problem is a congenital fusion deficit. To further complicate this case, the girl was eventually found to have overaction of the superior obliques causing an 'A' pattern. This case may be an example of very early onset refractive esotropia actually being a milder form of congenital esotropia

Summary

The 67 case histories included here are a sample of the clinical spectrum of strabismus. Because of its unlimited potential for variation, strabismus could never be comprehensively described. This list instead offers a glimpse of the larger clinical picture. There will undoubtedly be omissions noted. For example, I have not discussed inferior oblique palsy, a condition seen one or two times a year in a busy strabismus practice. In order to avoid overlooking this entirely I would simply suggest recession of the yoke, the contralateral superior rectus, in this case. A tuck (or resection and advancement) of the paretic inferior oblique would make sense, but this procedure is rarely done.

Another case not described in this list of cases is the 'heavy eye' hypotropia and esotropia that occurs in some patients with very high myopia on the order of approximately -15.00 and above. Such a patient was seen early in the telemedicine program when patients were submitted via e-mail. Pictures of this patient were given to Dr. von Noorden for the sixth edition of *Binocular Vision and Ocular Motility* and can be found on page 474 with an excellent description of this condition. My advice to the referring doctors in 1999 was to recess the medial and

inferior rectus muscles. Since that time, imaging of the orbit has shown that this deviation could be caused by a migration of the lateral rectus inferiorly secondary to a dehiscence of the superior temporal intermuscular membrane due to the enlarging globe. This makes the inferior rectus a depressor. In this case, elevating the lateral rectus and even connecting it to the superior rectus muscle has been suggested along with medial rectus recession. I have had no experience with this treatment

A strabismus surgeon will encounter clinical problems that differ from those presented here in detail but not necessarily in kind. Because each case is unique, you will be required to provide your own personal solution for the management of each strabismus patient. In doing this, you should always strive to manage each problem by using tested principles and by adhering to sound surgical technique. You should apply the tools, skills, and insights of a professional challenged with the need to solve a wide array of complex problems.

If this book has any value, I hope the value is that it challenges the strabismus surgeon to arrive at the proper approach to a strabismus problem through the application of sound principles rather than by adherence to dogma.

Complications of strabismus surgery

Complications of strabismus surgery

In the performance of surgery for strabismus or any other indication, complications will occur if surgery is performed in a sufficient number of cases. This means that surgical complications can be eliminated, at least on a statistical basis, only by not doing surgery. Therefore, it is a truism that if a surgeon performs surgery enough times, a complication will occur. However, whether or not a complication is said to occur depends in part on the surgeon's definition. The only certain way to avoid complications other than to avoid surgery is to deny that a complication exists. This self-serving strategy on the part of the surgeon is seldom tolerated by the patient.

For our purposes, a complication is defined as a factor or event developing in the course of treating a primary condition that appears unexpectedly and changes existing plans and/or outcome. Just what specifically constitutes a complication varies from surgeon to surgeon. The following are criteria established from my personal experience.

Complications range from minor and annoying to severe and threatening. The latter challenge the well-being of the patient and create extra concern on the part of the surgeon. Complications occur in three categories. (1) Unacceptable results are complications that relate directly to the reason for the surgery. The results are unsatisfactory because the alignment is not cosmetically acceptable, diplopia, persists, the conjunctiva is scarred and unsightly, or similar reasons. The surgeon is not happy with the effects of surgery because he thinks he could have produced a better result. (2) A second category of complications is a new problem related to the reason for surgery. Although the problem may be related to the general area of strabismus surgery, it is not necessarily related to the condition being treated surgically in the first

place. An example of this type of complication is lower lid lag with widened palpebral fissure after inferior rectus recession. (3) The third category of complication is characterized by a new problem that is unrelated to the reason for the planned strabismus surgery. This type of complication would occur, for example, if the patient is burned by an anesthesia-heating device or if a retinal detachment or endophthalmitis occur.

The results of strabismus surgery are unique because they are clearly evident for all to see. They are neither covered by clothing nor internally located (although dark glasses may be used). After strabismus surgery patients can, and do, study their alignment by looking in the mirror and by testing themselves for diplopia. They also react to how others seem to relate to them ("people don't know where I'm looking"). The patient also evaluates the results of surgery on a functional basis reporting, for example, diplopia or asthenopia.

Criteria for success after strabismus surgery

To establish a better foundation for evaluation of complications, it is appropriate to discuss criteria for success. A perfect result from strabismus surgery could include the following: (1) minimum immediate postoperative discomfort, (2) no apparent conjunctival scars, (3) normal palpebral fissures, (4) normal versions and ductions, (5) orthotropia, (6) equal and normal visual acuity, and (7) normal stereo acuity. Only rarely is the 'perfect' result attainable because the patient who requires strabismus surgery rarely has the motor and sensory potential for attaining such a result, except perhaps for the patient who has inter-

mittent exotropia and normal stereo acuity. In practice, although the intermittent exotropia patient potentially may be the one most likely to attain perfect results, often these results are not achieved. This may be for the same reason that the patient develops intermittent exotropia in the first place.

If a 'perfect' result is not attainable after strabismus surgery, what then? A reasonable goal for strabismus surgery should be established to determine a basis for what could be termed an acceptable result. For example, an acceptable long-term result could provide the patient with improved function and/or appearance without the introduction of other complicating factors. Some acceptable results could include small undercorrection, small overcorrection, minimal dissociated vertical deviation, a slight or barely perceptible lid fissure anomaly, slight incomitance, minimal conjunctival redness, diplopia only in extreme gaze, and mild Brown syndrome, to name a few. Early postoperative phenomena that are self-limited and should not be considered complications include: transient suture reaction, benign subconjunctival hemorrhage, minimal lid edema, corneal abrasion with prompt healing, and a delle with prompt healing. An acceptable result can include a variety of less than perfect results and even some transient 'complications' that end in the best result that can be hoped for given the presenting condition.

The above lists are relatively minor inconveniences or discomforts that may or may not be avoidable. Since they are completely reversible, they may not be considered a complication. The status of stereo acuity, fusional amplitudes, and vision are preoperative modifying factors. They can affect the outcome of surgery but are neither ordinarily affected, nor enhanced by, proper surgery.

In assessing the results of strabismus surgery, a very important axiom should be remembered: nothing gets better with litigation pending. The person who is involved in an accident and who is seeking compensation or other type of relief may depend either consciously or unconsciously on pain and suffering to achieve a perhaps deserved amount of compensation. It can be more difficult for such a patient to maintain a positive attitude toward obtaining a good result from a surgery. The surgeon must be patient, supportive, appropriate, and above all, understanding in such cases.

Complications after strabismus surgery can include constant diplopia, unsightly conjunctival scars often with limitation of ductions, overcorrection of a significant amount according to the criteria of the patient and surgeon, undercorrection of a like amount, significant lid fissure anomalies, and severe Brown syndrome. Some of these problems can occur in spite of properly performed surgery. In the case of an overcorrection, the strabismus surgeon could say: "Mrs. Jones, your surgery went fine, but you overre-

acted to the right amount of surgery." Although this is said primarily in jest, there is a grain of truth present. A case in point is iatrogenic Brown syndrome that can occur after a tucking or other 'strengthening' procedure carried out on the superior oblique tendon. The patient may achieve an excellent effect in the primary position but develop diplopia in the field of action of the antagonist inferior oblique muscle because of a non-yielding superior oblique tendon. The question is, "Was the surgery performed properly?" From the patient's point of view, the answer might be no. From the surgeon's point of view, however, the surgery may have been performed exactly as planned, but too much of the tendon was tucked. Although preoperative superior oblique tendon testing leading to titrated superior oblique tuck makes this condition less frequent, it still occurs. In either case, the patient has a problem and relief is needed. Late-occurring exotropia or dissociated vertical deviation (DVD) after initially successful surgery for esotropia should not be considered a complication, but rather an unstable result in a patient who does not have bifoveal fusion potential. It is a manifestation of the natural history of the strabismus.

Some new problems related to strabismus surgery could include the following: 'lost' muscle, inferior oblique adherence or inclusion syndrome, scleral perforation, retinal detachment, orbital hemorrhage, cellulitis, operation on the wrong muscle, proptosis, symblepharon, conjunctival cyst, Tenon's prolapse, endophthalmitis, surgical procedure on the wrong eye, or surgical procedure on the wrong patient.

New problems appearing after strabismus surgery that are unrelated to the original surgery can be the most serious of all complications and include prolonged apnea, hyperthermia, gastric bleeding, and even death. It should be noted that the unrelated or new problems associated with strabismus surgery are commonly anesthesia-related. Prolonged apnea may occur in patients who have received a depolarizing relaxant such as succinylcholine in the presence of reduced blood pseudocholinesterase levels, such as would occur after treatment with phospholine iodine. Unplanned admission of an outpatient, usually related to an anesthetic complication, or vomiting, may be reported as a 'complication' by the hospital's quality assurance committee.

Malignant hyperthermia is a familial condition but is difficult to anticipate unless a positive family history is noted. Most operating rooms are now supplied with dantrolene, which is administered immediately when malignant hyperthermia is encountered.

I encountered an unusual complication of surgery, severe postoperative gastric bleeding. This occurred in a patient who apparently had an aberrant artery at the esophageal-gastric junction. Bleeding developed after this artery ruptured with postoperative suctioning of the stomach. An overnight admis-

sion was required, but the bleeding stopped without specific treatment. A skin burn from a heating blanket and one case in which a heated tube on the anesthesia machine caused a second-degree thermal burn of the arm are other examples of complications unrelated to strabismus surgery.

Because complications or the potential for complications are an unavoidable part of strabismus surgery, guidelines for treating and/or avoiding these complications should be established. Each surgeon should acquire and maintain sufficient skills. This is a 'must.' The surgeon should have sufficient knowledge of his patient, the reason for doing the surgery, and should prepare both himself and the patient preoperatively in light of the patient's specific needs. The surgeon and his patient should then maintain realistic expectations with regard to the outcome of the proposed strabismus surgery.

Informed consent

Preoperative informed consent obtained for strabismus surgery should include these potential complications: loss of vision, diplopia, and need for reoperation. A long list of complications which could include bleeding, infection, and anesthetic problems need not be mentioned specifically. All are implied by the three warnings given.

When a complication is encountered, it is essential to deal with the patient with candor and compassion, maintaining a healthy doctor-patient relationship. Denial of a complication by the surgeon is guaranteed to exacerbate the problem in the patient's mind. This is understandable. If the patient is having a problem and the surgeon does not recognize its existence, the patient might magnify the problem until the surgeon or some other physician (or attorney) does recognize a problem, either real or imagined. The best way to deal with a complication is to recognize that it exists, convey this awareness to the patient, and implement a plan to remedy the situation.

Diplopia

Bothersome diplopia after surgery is a problem that can be treated successfully temporarily and in most cases, permanently. The immediate remedy for diplopia is obvious: patch one eye constantly or alternate the patch between the two eyes. This type of treatment is often appropriate for the patient who has an early postoperative overcorrection such as esotropia after surgical treatment for an intermittent exotropia. Diplopia persisting more than a few days may require treatment with prisms, either temporary Fresnel prisms or permanent prisms ground into the spectacles. If time and these remedies fail, reoperation to relieve the diplopia may be necessary.

A few patients may have a type of diplopia that is not a complication of surgery but is the patient's own problem. This type of diplopia has been termed central disruption of fusion that can occur after closed head trauma. Other patients have foveas that repel rather than attract with a condition called horror fusionis. Another relentless form of diplopia is caused by bilateral cranial nerve palsies producing secondary deviations in all fields of gaze and making comfortable fusion impossible. Further active treatment may only worsen that problem and the patient should be counseled appropriately. Patching one eye or use of an opaque contact lens or, best of all, establishing the patient's own suppression mechanism could be the only real remedy. Some of the most unfortunate diplopia-plagued patients that I have encountered are those with acquired third cranial nerve palsy, usually with aberrant regeneration, who have their eyes fairly well straightened by surgery but who have constant and incapacitating double vision. Unless these patients can develop suppression, which they often cannot, they may be better off unoperated retaining a larger angle of strabismus or as an alternative, with some form of occlusion.

Some postoperative patients will literally look for diplopia and in the process become agitated. These patients may complain of double vision when reading while lying on their back in bed or while assuming some other extreme position or when looking in extremes of gaze. I tell these patients to assume a more 'hygienic' posture for reading and television viewing. It is useful to differentiate diplopia that must be 'looked for' and 'found' from diplopia that 'looks for' and 'finds' the patient and in the process disrupts the normal flow of events. The former is an unavoidable part of much strabismus. It can be dealt with by the patient in most cases. The latter may be dealt with by surgical or nonsurgical means but in some cases could be intractable. For the most part, patients seem satisfied by and benefit from this explanation of double vision. Further, it is valuable to tell patients that anyone with two eyes, even those with perfectly normal motility, can experience double vision in certain circumstances. Some patients with longstanding horizontal strabismus and no preoperative fusion potential experience diplopia after their eyes are aligned by surgery. When these patients complain about diplopia, you can offer to put the eyes back in the preoperative state at no charge if the diplopia is more of a detriment than the alignment is beneficial. This would be said with 'tongue in cheek' and with the assurance that in nearly every case the diplopia goes away with onset of suppression provided the patient will give the process sufficient time. I know of no patient to date who has exercised this option.

Reoperation

As part of the preoperative discussion about what can be expected during and after surgery, the patient can be given some estimate of how often repeat surgery may be required both in the immediate postoperative period and long term, based on experience. For example, in cases of congenital esotropia without manifest nystagmus (including manifest latent nystagmus) I tell parents that between 80% and 85% of postoperative alignment will be between orthotropia and 10 prism diopters of residual esotropia and that motor alignment will be considered satisfactory both by us and by the parents about 90% of the time. They are also told that most children will need one or more additional surgical procedures months to years later for new problems such as secondary exotropia, oblique dysfunction, 'A' or 'V' pattern, dissociated vertical deviation, or recurrent esotropia, even though alignment is excellent after the initial surgery. Finally, parents are told that children treated for congenital esotropia should be followed by an ophthalmologist regularly until their teen years.

Other more complicated cases are given different but realistic estimates. In cases of congenital esotropia with manifest nystagmus, I tell families that repeat surgery for residual esotropia must be performed more often than in cases without nystagmus. In other cases, appropriate estimations are given. However, in each case families are told that we will make a 100% effort to make the present operation the last one that is needed. The realities are that we cannot meet these ideals and that some reoperations are inevitable, but we try nonetheless. In the past, surgeons were likely to overestimate the need for repeat operations, possibly as a hedge against not obtaining the desired results the first time. This type of preoperative information would tend to make the surgeon seem extra proficient if he happened to achieve alignment the first time. I believe this approach is an unfair burden to place on the family and is not entirely honest. Another small but important point to emphasize is that statistics are more for the benefit of the surgeon than the family. In a given case, the need for reoperation, if it is needed, will be 100% in the patient's experience even if it is only one out of the last 10 patients the surgeon has treated. The other nine patients will be dealing with a surgeon who is successful 100% of the time.

Loss of vision

Loss of vision is a rare complication of strabismus surgery. Causes include retinal detachment, vitreous hemorrhage, endophthalmitis, posterior chamber hemorrhage, cataract, lens subluxation, hyphema, corneal opacity, optic nerve damage including transection, and glaucoma. These complications are caused by the mechanical or microbial consequences of inadvertent perforation of the retina at the time of dissection or needle placement or by disruption of blood vessels. The best way to avoid these complications is to adhere to proper technique and the surest way to encounter these complications is to stray from this practice. Even with meticulous technique, scleral and retinal perforation can occur especially in patients who have the predisposing factor of extremely thin sclera. Transection of the optic nerve has occurred during the course of strabismus surgery, but to my knowledge such cases have not been reported in the strabismus literature. Before this dreadful complication occurred, the surgeon must have thought that something unusual in the anatomy was being encountered. Whenever I am confronted with such a thought during strabismus surgery, I remind myself that there are more 'anomalous surgeons' than anomalous anatomy!

Postoperative nausea and vomiting

Postoperative nausea and vomiting with strabismus surgery has been common. Traction on the extraocular muscles and the depth of anesthesia required for eye muscle surgery contribute to this postoperative nausea and vomiting. However, with outpatient surgery, the incidence of this complication, at least in our institution, has decreased dramatically. The principal change in the patient's routine and quite likely the reason for the reduced nausea and vomiting is the withholding of preoperative narcotics. These medicines, useful to the anesthesiologists, contribute to vomiting after surgery. With the present routine, anxious toddlers and younger school-aged children receive midazolam (Versed) preoperatively, a calming drug that does not seem to produce vomiting. This reduction notwithstanding, the occasional patient must be admitted for this complication but it occurs in less than 1% of cases and therefore is no longer a significant problem. In addition, the use of propofol as an anesthetic agent during surgery has reduced the incidence of postoperative nausea and vomiting.

Acute, allergic suture reaction

Acute, allergic suture reaction occurred with varying severity in approximately 10% and possibly even 20% of patients who had strabismus surgery with organic suture material (catgut or collagen). This allergic reaction initially looks like a dull red, smooth mass beneath the conjunctiva at the site of the muscle reattachment. The usual postoperative course with uncomplicated strabismus surgery is for the erythema associated with surgery to gradually recede, becoming minimal after the first week. In patients who experience a suture reaction, the operated eye shows a significant and fairly sudden increase in redness beginning 10 to 14 days postoperatively. This redness coincides with the beginning of disintegration and absorption of the gut or collagen suture. Clinically, apparent acute suture reaction is more frequently associated with resections than recessions because more suture material is used and the sutures are placed near the limbus. Acute, allergic suture

reaction is not a serious complication. This reaction does not alter the outcome of surgery and is self-limiting, subsiding in 2 to 4 weeks if untreated (Figure 1).

Prevention

With the nearly universal use of synthetic absorbable suture, allergic suture reaction has been virtually eliminated. Rare cases have been reported and I have seen a few patients who appeared to react to synthetic absorbable suture. Prevention when using gut or collagen may be impossible.

Treatment

Treatment consists of nothing or of topically applied steroids. When treatment is used, I prefer prednisolone 0.12% twice a day for 7 to 10 days.

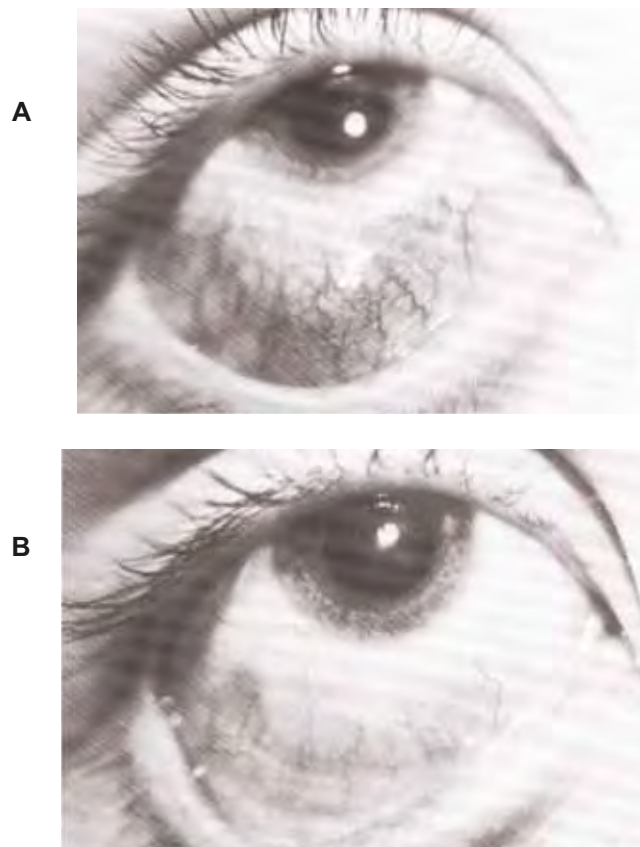


Figure 1

- A** Acute allergic suture reaction occurred 12 days after inferior rectus resection.
- B** After application of prednisolone 0.12% twice a day for 10 days, the reaction disappeared.

Chronic suture granuloma

Chronic suture granuloma is fortunately a rare occurrence in strabismus surgery. It appears in less than 0.5% of cases. This reaction is characterized by a solid, red, protruding mass over the site of the muscle reattachment. It usually occurs about a week after surgery, beginning before the usual erythema associated with surgery begins to clear. The granuloma is composed of chronic inflammatory cells and fibrous tissue. It may diminish with time but does so slowly and incompletely. It occurs with gut or collagen suture. I have not seen chronic suture granuloma with synthetic absorbable sutures (Figure 2)

Prevention

Prevention is the same as for acute allergic suture reaction.

Treatment

Treatment consists of topically applied steroids; I prefer prednisolone 0.12% twice a day for 2 weeks. If the mass persists it must be surgically excised. Repeat strabismus surgery may be required at this time.

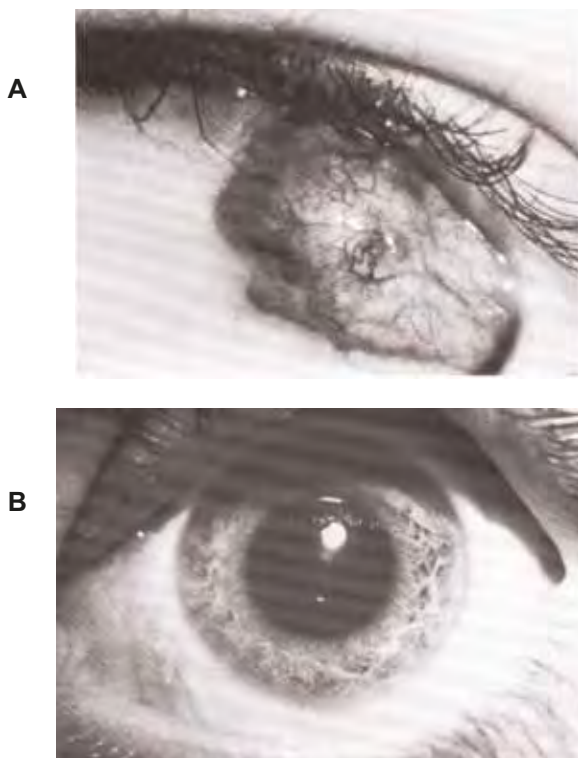


Figure 2
A Chronic suture granuloma persisted 6 months after resection of the lateral rectus.
B The eye looks white and the lateral conjunctiva smooth after excision of the granuloma.

Reaction to synthetic absorbable suture

With the advent of synthetic absorbable suture material polyglactin 910 (Vicryl) and polyglycolic acid (Dexon), acute allergic suture reaction and chronic granuloma formation after strabismus surgery are virtually nonexistent. However, in rare cases (less than 1%) the appearance of an acute allergic reaction after eye muscle surgery using Vicryl has occurred. We have not challenged these patients with a second exposure to these sutures and it is not possible to rule out other causes for the reaction. Treatment is the same as the preceding allergic reactions. I have not encountered any adverse effect on results of surgery (Figure 3).

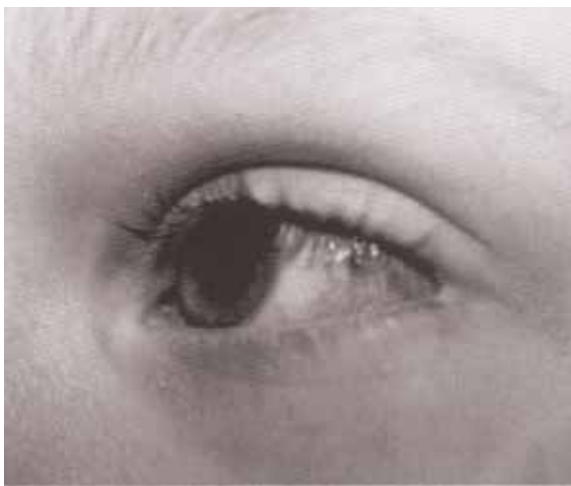

Figure 3
 Mild, acute suture reaction, presumed allergic, after muscle reattachment with 6-0 Vicryl suture. This occurs rarely.

Subconjunctival cysts

A subconjunctival cyst may occur when small segments of the conjunctival epithelium are buried at the time of the conjunctival wound closure. The cysts are usually 2 to 3 mm in diameter and are filled with a clear fluid. They are cosmetically objectionable but do not ordinarily compromise the results of strabismus surgery. Rarely the cysts will be very large and extend back into the orbit for 10 mm or more, occasionally affecting motility (Figure 4).

Prevention

Careful closure of the conjunctiva at the time of surgery will prevent cysts.

Treatment

Small anterior subconjunctival cysts may be removed in the office under topical or subconjunctival 1% lidocaine (Xylocaine) anesthesia. I prefer total excision of these cysts intact, if possible. If the cyst ruptures during dissection, an attempt should be

made to excise the entire epithelial lining. Larger, orbital cysts are removed in the operating room. In my experience, these cysts are always outside the muscle cone and therefore can be approached without disrupting important orbital contents.

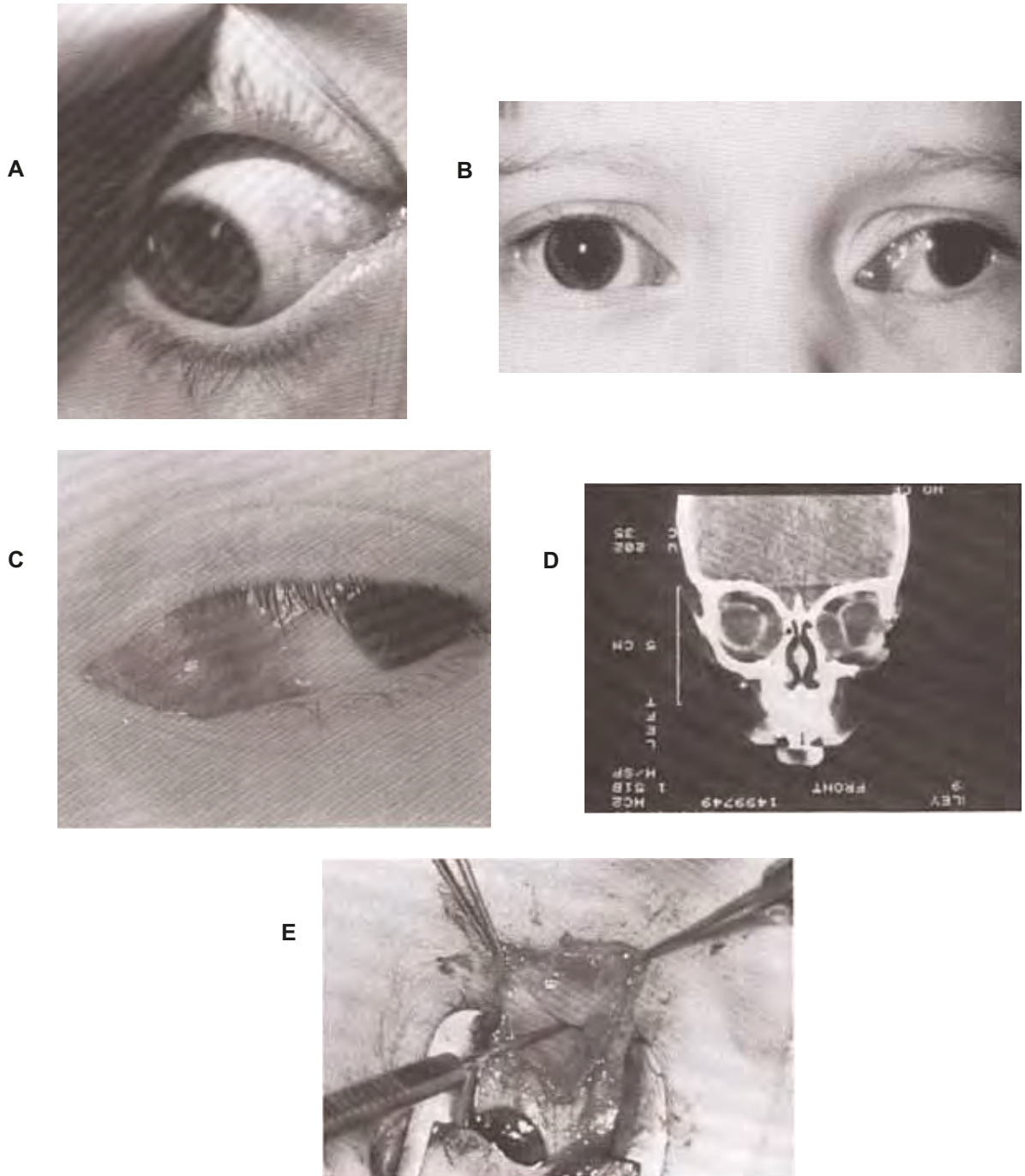


Figure 4

- A A subconjunctival cyst after medial rectus recession.
- B Large subconjunctival-orbital cyst over the left medial rectus
- C Close up view of cyst, left eye.

- D CT scan demonstrating bilateral cysts over the medial recti extending deeply into the orbit.
- E The subconjunctival-orbital cyst over the left medial rectus, seen at the time of surgery for its removal.

Photos Figure 4 B-E courtesy of Hiram Hardesty, M.D., Cleveland, Ohio

Prolapse of Tenon's capsule

Prolapse of Tenon's capsule through the conjunctival incision causes the eye to have an unsightly appearance in the immediate postoperative period. This prolapse is usually caused by incomplete conjunctival closure and is made worse by excess irrigation at the time of surgery. Tenon's capsule under these circumstances tends to imbibe the irrigation solution, thus increasing its bulk.

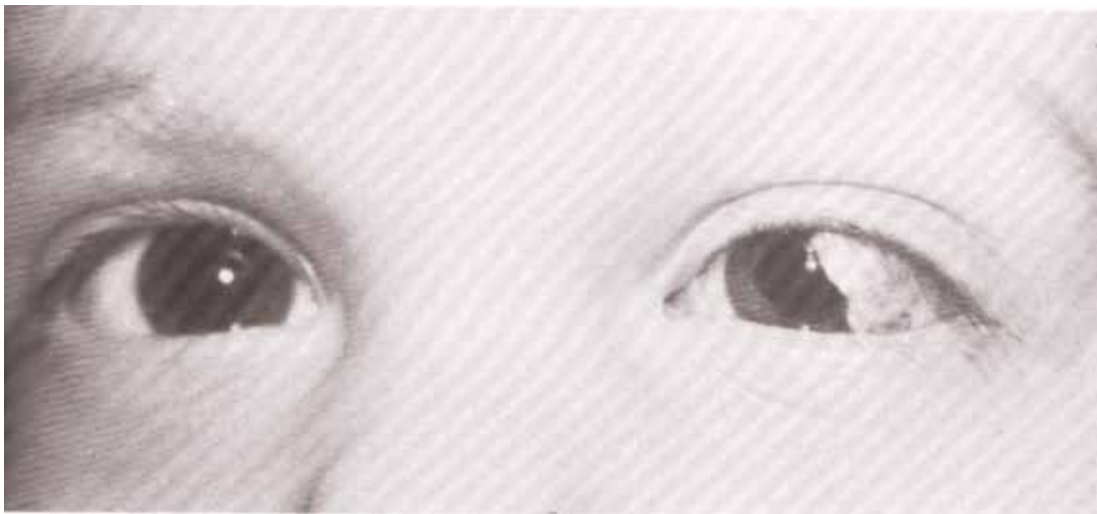
Prevention

Careful wound closure and limited irrigation of the operative site diminishes possible prolapse of Tenon's capsule. If Tenon's capsule is bulky and prolapses in spite of this, any excess may be excised at the time of the initial surgery.

Treatment

Prolapsed Tenon's capsule will usually shrink back into the conjunctival wound without active treatment. If the prolapse is excessive and the wound gaping, excess Tenon's capsule should be excised and the conjunctival wound re-sutured.

A



B



Figure 5

A Prolapsed Tenon's capsule persisted 2 weeks postoperatively.

B Tenon's capsule has retracted without treatment three months after surgery.

Suture abscess

A suture abscess appears as a yellowish elevation over the suture placement site. It usually occurs within the first week postoperatively. The eye is deeply injected and a purulent drainage may be present. An abscess occurs more often when a nonabsorbable suture such as Merseline has been used. This complication is rare.

Prevention

Aseptic technique at the time of surgery and routine use of antibiotics postoperatively will prevent suture abscess.

Treatment

Treatment includes drainage of the abscess under topical, local, or general anesthesia, removal of the suture nidus if present, and appropriate topical antibiotic treatment after a culture has been obtained.

Delle

A delle is a small area of corneal stromal thinning caused by localized drying of the cornea. This corneal thinning does not represent melting away of tissue, but rather shrinkage of tissue as a result of local dehydration. The corneal epithelium is intact and does not stain, but fluorescein will pool in the area giving the appearance of staining. The intact epithelium along with stromal thinning makes the

delle different from an ulcer or corneal melt. The localized drying leading to delle formation is usually caused by elevation of the conjunctiva at the limbus. Delle were found in 8% of 100 consecutive patients who had extraocular muscle surgery with the limbal approach. Most were subtle actually subclinical seen only with the slit lamp for this study. Delle are usually benign complications that do not affect the outcome of strabismus surgery. Clinically significant delle are rare.

Prevention

Smooth closure of the conjunctiva, especially adjacent to the limbus, will prevent delle formation. If decreased tear formation is found preoperatively, the operated eye should be patched and/or artificial tears used after surgery.

Treatment

Occlusion of the eye for 1 or 2 days will result in rehydration of the cornea and disappearance of the delle. Frequent instillation of lubricating drops may be used in lieu of a patch. If the conjunctival elevation causing the dellen persists, the conjunctiva is smoothed surgically or the offending conjunctiva can be excised with conjunctival recession and bare sclera closure.

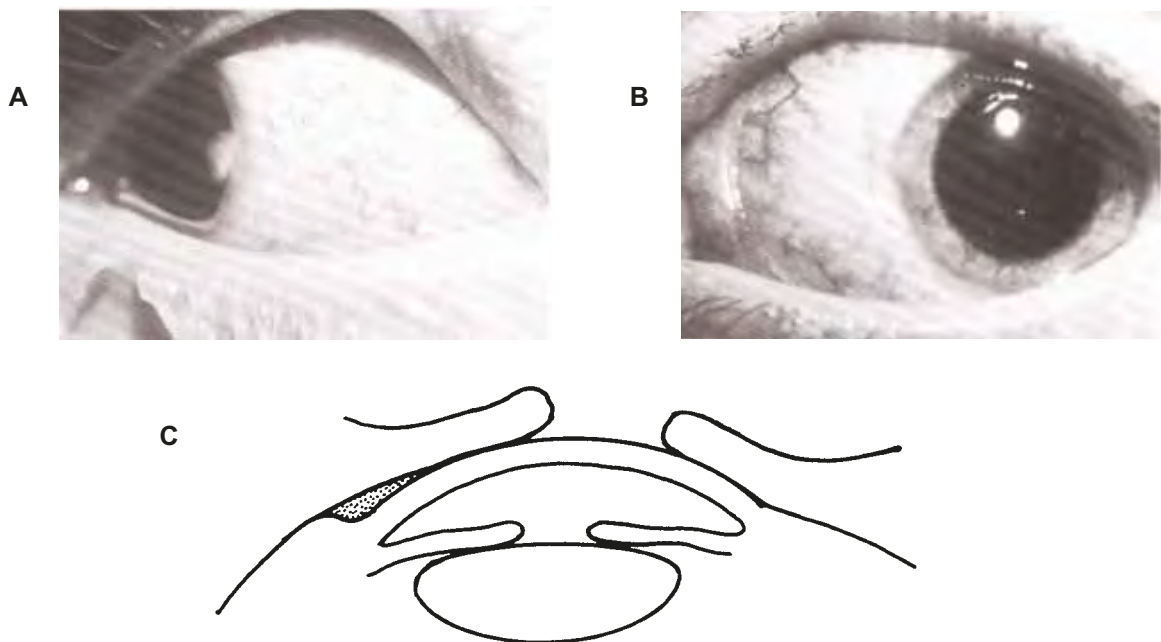


Figure 6

A Rather large delle with associated stromal clouding. This clouding is reversible.
B A less obvious delle adjacent to an area of elevated conjunctiva.

C The cause of a delle is localized corneal stromal dehydration caused by a mound of conjunctiva at the limbus, disrupting lid-cornea apposition.

Lid fissure anomalies

Changes in the vertical dimension of the palpebral opening may occur after recession and resection procedures on the vertical rectus muscles. Lid displacement after vertical rectus surgery occurs in the same direction as the shift in the insertion of the vertical rectus muscle. Ptosis of the upper lid can occur after resection of the superior rectus. Retraction of the upper lid can occur after recession of the superior rectus. Elevation of the lower lid occurs after large resection of the inferior rectus. This means that excessive resection of either the superior or inferior rectus can cause a narrowing of the palpebral fissure and excessive recession of either the superior rectus or the inferior rectus can cause widening of the palpebral fissure. Recession of the caruncle and widening of the medial aspect of the palpebral fissure occur after a slipped or 'lost' medial rectus muscle (Figure 7).

Prevention

Recession and resection of the inferior rectus is usually limited to 5 mm, except in special cases when these numbers may be exceeded if careful dissection of the rectus muscle from its surrounding structures is carried out. After a large recession of the inferior rectus is performed, the ligament of Lockwood may be brought forward and sutured to the outer surface of the inferior rectus muscle (see Chapter 6). Very large recession of the superior rectus of 10 mm or more for the treatment of dissociated vertical deviation has essentially no effect on upper lid height. But these are usually 'hang back' and the recession may not be as large as planned.

Treatment

Plastic lid repair may be performed to treat a cosmetically objectionable lid position which has been produced by excessive recession or resection of the vertical recti if the ocular alignment is satisfactory. In the case of a lacerated or slipped muscle, reattachment of the slipped muscle will usually improve the lid position.

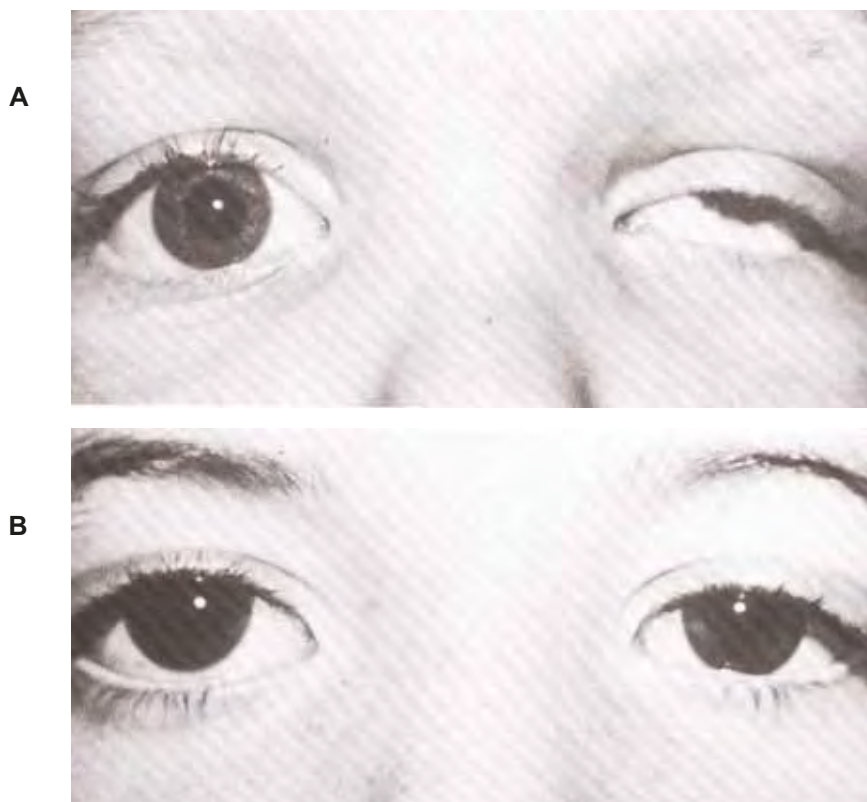

Figure 7

A Ptosis of the left upper lid occurred after excessive resection of the left superior rectus. The surgeon actually intended to resect the left lateral rectus.

B Ptosis of the right lower lid occurred after a 5 mm recession of the right inferior rectus without sufficient freeing of the inferior rectus from its surrounding structures.

continued.

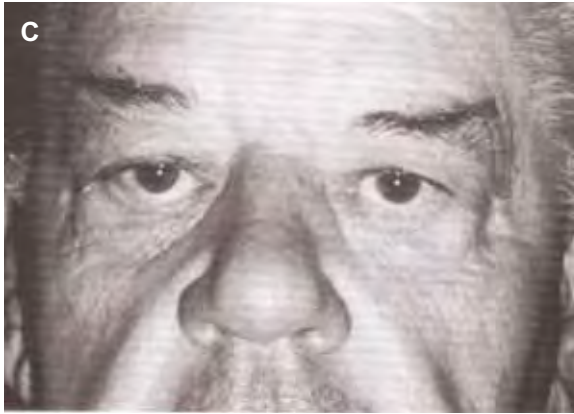

Figure 7, cont'd

C Ptosis of the right lower lid after recession of the right inferior rectus for thyroid ophthalmopathy.

Ptosis of the upper lid

Ptosis of the medial aspect of the upper lid can occur if the medial part of Whitnall's ligament or the medial horn of the levator muscle of the upper eyelid is torn. This complication is most likely to occur when the superior oblique tendon is hooked medial to the superior rectus using the 'blind' technique (see chapter 2).

Prevention

Expose and hook the superior oblique tendon under direct vision.

Treatment

Repair of the medial horn of the levator aponeurosis is made after a skin incision.

Scleral perforation

The true incidence of inadvertent scleral perforation occurring during extraocular muscle surgery is unknown. However, it has been estimated to occur in from 8% to 12% of patients in series reported before the advent of smaller caliber needles. In a recent prospective series where the retina at the site of muscle reattachment was examined before and after muscle surgery, one scleral perforation was identified in 194 procedures done in 144 eyes. This was noted at the time of surgery as a small retinal hemorrhage observed with the indirect ophthalmoscope in the retinal periphery at a point corresponding to the muscle reattachment. No treatment was given. Six months later a small chorioretinal scar was noted. I have confirmed a retinal perforation at the time of surgery six times. Twice I observed a small 'bead' of vitreous on the sclera at the site of needle placement in the sclera. Observation of the retina in the operating room revealed a dot hemorrhage. No treatment was given for these cases or the other four. A small chorioreti-

nal scar persisted and remained unchanged over a follow-up period of seven years in one case. In two more serious cases of scleral rupture, a large area of uvea was exposed during reoperation of the medial rectus muscle. In both cases, a scleral graft was sutured over the exposed uvea and surgery completed successfully by anchoring the muscle to the scleral patch. In neither case was the retina disturbed and no further treatment was needed. We assumed that scleral necrosis occurred in association with the earlier surgery.

My guess is that simple perforation of the retina occurs in approximately 1% to 2% of strabismus procedures. I suspect that most of these go unconfirmed, untreated, and are without sequelae. It is necessary to engage only superficial scleral fibers at a depth of 0.2 mm with a 1.5 mm tunnel to achieve a secure muscle-scleral union. Longer, deeper bites are not necessary (Figure 8).

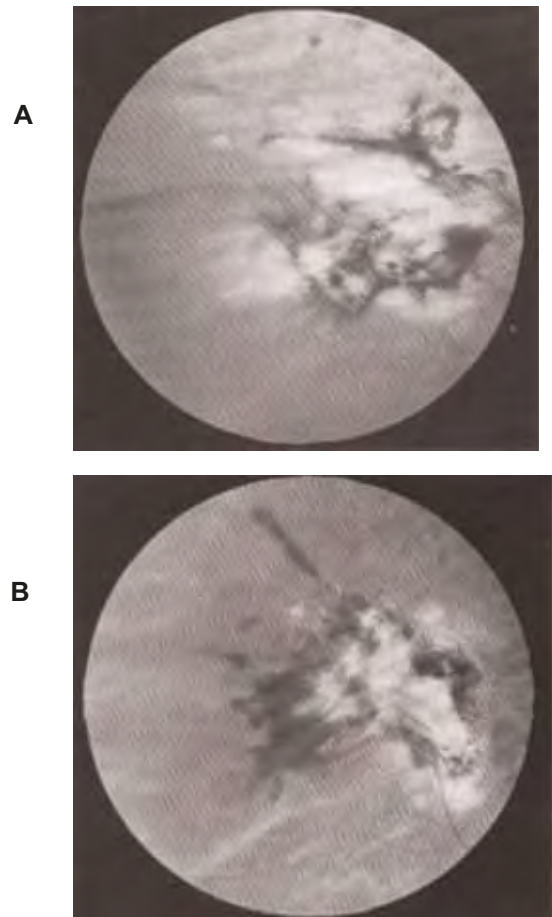


Figure 8

- A** The peripheral retina of the right and left eyes of a 35-year-old patient who had bilateral lateral rectus recession 25 years before.
- B** These retinal scars are adjacent to the presumed site of muscle reattachment and are thought to be caused by scleral and retinal perforation at the time of surgery. No treatment for this was given at the time. Visual acuity is 20/20 in each eye. The patient was not aware of any problem with her eyes.

Prevention

Needles should be placed in sclera with a short shallow track with the widest dimension of the needle parallel to sclera. If a needle is put in sclera at an angle or on edge, scleral perforation could occur. In cases of reoperations with adhesions and the case of thin sclera, careful sharp dissection should be used. In cases where thin sclera is suspected because of systemic connective tissue disease or high myopia, marginal myotomy may be performed as a primary weakening procedure to avoid the risk of scleral perforation associated with needle placement for recession. A resection may be carried out safely in such cases by leaving a slightly longer stump at the insertion and using it for muscle reattachment. The muscle stump may also be used as a safe anchor for a 'hang-back' recession.

Treatment

Any time scleral perforation is suspected at the time of surgery, the patient's pupil should be dilated and the retina over the site of suspected perforation should be examined using an indirect ophthalmoscope. Some surgeons prefer to treat inadvertent scleral perforations with prophylactic application of cryotherapy, diathermy, or even a scleral buckle for support. I strongly disagree with this approach.

In my opinion, simple perforation without prolapse of vitreous or uvea should be left untreated. If uvea or vitreous prolapses or if the defect is large, it should be closed with sutures, with or without a scleral graft, and further prophylactic treatment to the retina should be considered and performed by a retina specialist. If further manipulation of the eye muscle would create a hazardous situation for the eye, the extraocular muscle procedure should be suspended at that time. I suspect that in cases of retinal perforation more harm has resulted from over-treatment than from under-treatment. Sprunger treated scleral-retinal perforation created in a rabbit with cryo and laser treatment. The amount of reaction with cryo was significantly more than that created by a ring of diode laser. However, experience tells us that no treatment is the safest and most effective.

Slipped or lost muscle

There is a significant difference between a slipped muscle and a so-called lost muscle. A 'lost' muscle is not really lost. It simply is no longer connected to sclera and has disappeared from view. The surgeon knows where the muscle is. It is in the orbit, but it cannot be seen! The events surrounding a lost muscle usually occur at the time of surgery and represent an intraoperative complication. In contrast, a slipped muscle tends to occur gradually over time in

the postoperative period. The slipped muscle remains attached to sclera but it slips back, usually in its capsule. This phenomenon has been called 'stretched scar' by Ludwig.

A lost muscle is most likely to occur with the medial rectus muscle because this muscle is not associated with other muscles or orbital structures. 'Loss' of the medial rectus muscle can occur when extensive dissection of the intermuscular membrane has been done and the surgeon simply loses hold of the muscle and it retracts behind Tenon's into the fat compartment. This could also happen if the sutures attaching the muscle to sclera fail immediately after surgery and before tissue union takes place. I have not experienced this so can only guess what takes place intra-operatively. Given the relationship of the lateral rectus to the inferior oblique, the inferior rectus to Lockwood's, and the superior rectus to the superior oblique tendon, it is unlikely that these muscles would be 'lost' from view at the time of surgery. In the event a lost muscle is not detected at the time of surgery, it will become obvious in the immediate post operative period after the suture breaks, unties, or the attachment to the muscle or sclera fails. The eye in this case will not move in the field of the 'lost' muscle.

Slipped muscles are not at all uncommon. They tend to occur in the weeks, months, or years after surgery. This is accompanied by a gradual over-correction in the case of a slipped recessed muscle or a gradual under correction in the case of a slipped resected muscle. There will also be diminished ductions in the case of a slipped muscle.

Prevention

The preventing of slipped or lost muscles demands proper technique, requiring the surgeon to do the following:

1. Place sutures securely into muscle or tendon tissue. This is best accomplished by placing the suture 0.5 mm to 1.0 mm behind the insertion of the muscle during recession and a like amount behind the muscle clamp or crimped line during resection. This 'resection effect' is inconsequential in my experience because the surgeon who pays careful attention to the results of his/her surgery will adjust surgical 'numbers' to the technique employed.
2. Place the needle into sclera producing a track that is at least 1.5 mm long, including superficial scleral fibers and at least 0.2 mm deep.
3. Use at least 6-0 synthetic absorbable suture tied with a double overhand knot with a square knot on top (surgeon's knot).

4. Before securing the muscle to sclera after recession or resection, limit the dissection of intermuscular membrane to a point anterior to the emergence of the muscle through posterior Tenon's capsule, thereby limiting the extent of potential posterior slippage of the muscle and ensuring that the muscle's cut end will stay visible even if attachment to the globe by suture is lost.

Treatment

Treatment of a 'lost' muscle in the operating room has been discussed above. Apparent detachment of a muscle occurring immediately after the patient has left the operating room is an indication for immediate return to the operating room. At this time, careful search for the muscle should be carried out. This can be aided by finding the disrupted suture. If the muscle is found, it is re-sutured at the intended point. Several drops of Neo-Synepherine 2.5% placed on the operative site will blanch Tenon's and episclera and will make the red muscle tissue more evident.

When a 'lost' muscle is later suspected, a useful diagnostic technique is computerized tomography or MRI. If the muscle is seen behind posterior Tenon's capsule, careful dissection can be carried out to identify the muscle that can then be reattached to the sclera. I have retrieved a medial rectus muscle that had been 'lost' many years before by asking the patient during a procedure done with local anesthesia to adduct the eye while I explored the medial sub-Tenon's space. A dimple in Tenon's that appeared during attempted adduction led to the muscle which was identified, dissected free, and reattached to the globe successfully. However, the surgeon should be cautioned against carrying out extensive 'blind' exploration and grasping in search of a 'lost' muscle, if this dissection produces fat herniation and excessive bleeding. This can cause irreparable damage, affecting alignment and conjunctival appearance. If considerable difficulty is anticipated in finding a 'lost' muscle, it may be better to carry out a suitable extraocular muscle transfer, or stop and seek immediate help or refer the patient.

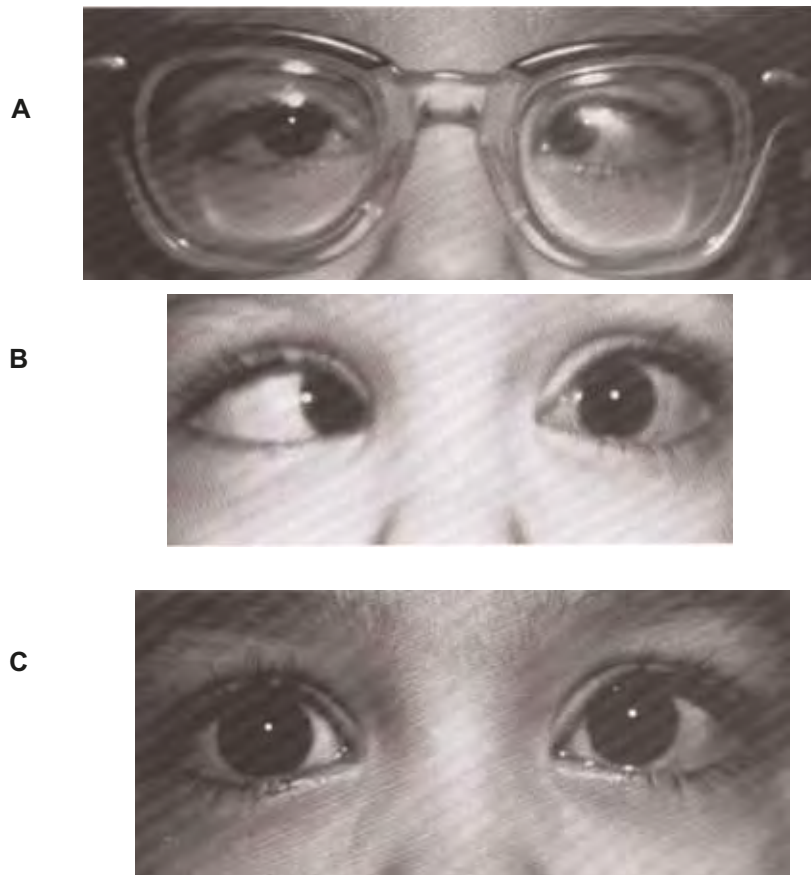


Figure 9

A A 6-year-old boy after having undergone a recession of the left medial rectus muscle and a resection of the left lateral rectus muscle. A diagnosis of a 'lost' left lateral rectus muscle was made.

B The left eye fails to reach the midline in levoversion.
C The same patient after reattachment of the left lateral rectus.

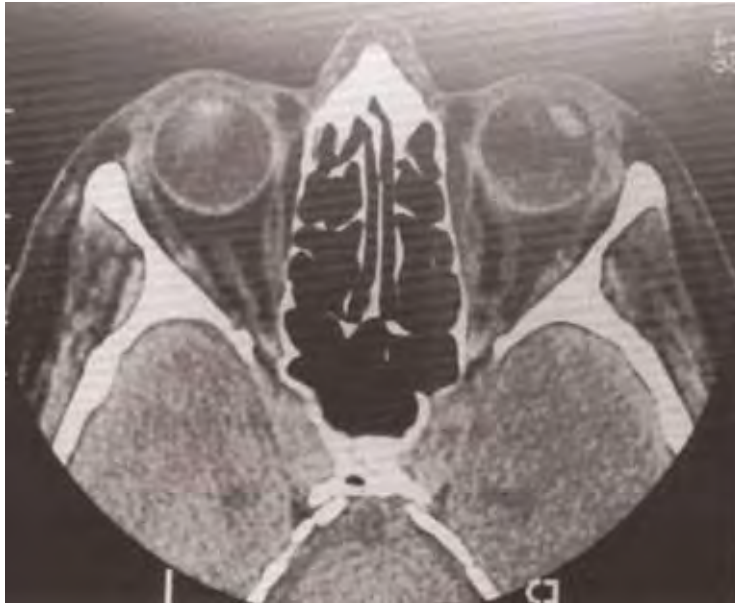

Figure 10
The CT scan of the right medial rectus muscle that has slipped in its capsule.
Note by the position of the lens that the right eye is exotropic.

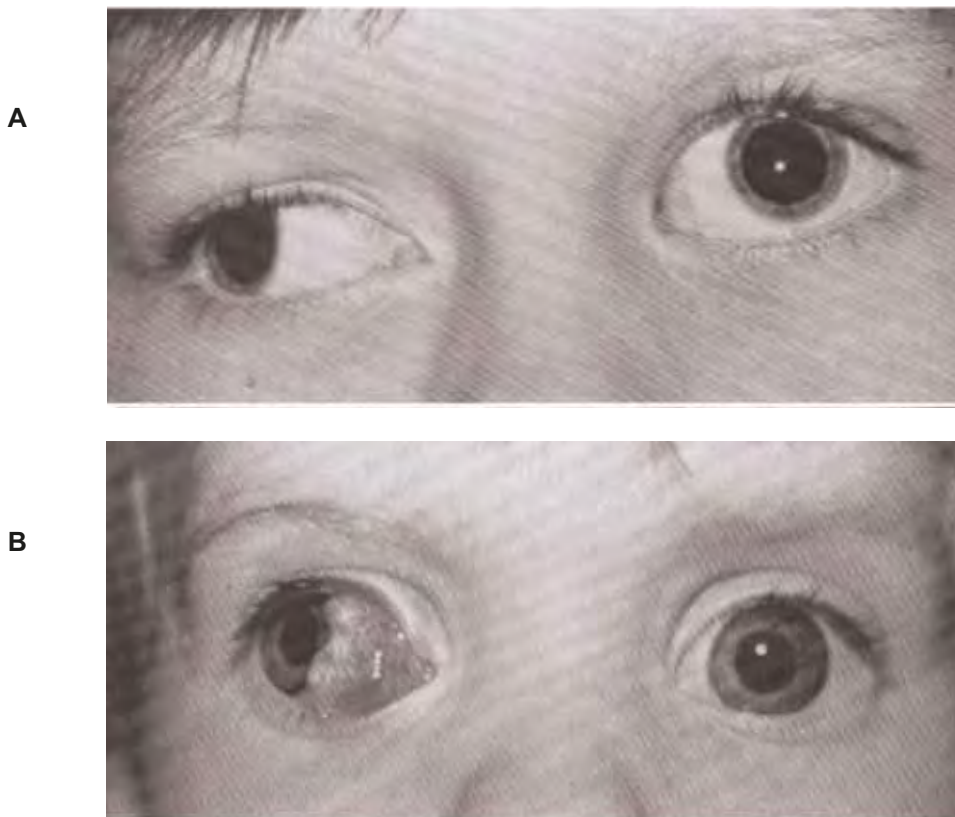


Figure 11
A This patient has a slipped left medial rectus muscle after bimodal rectus recession. Note the widened palpebral fissure on the left side during attempted adduction.
B The right medial rectus was 'lost' when it slipped off a resection clamp. Prolonged 'blind' search for the muscle was unsuccessful and produced a large prolapse of orbital fat.

Anterior segment ischemia

Reduced blood supply to the anterior segment, anterior segment ischemia, occurs in most cases of strabismus surgery if looked for carefully, especially after vertical rectus muscle surgery or surgery on adjacent muscles. Olver and Lee grade anterior segment ischemia as follows: I decreased iris perfusion, II + pupil signs, III + uveitis, and IV + keratopathy. Most patients recover iris circulation to the preoperative level two weeks after surgery, although a few take up to 12 weeks. Re-perfusion takes place through deep collateral circulation and never by recanalization of the anterior ciliary vessels from the detached muscle. Although minor pupil changes may persist, the first three grades of anterior segment ischemia are not important clinically. Grade IV anterior segment ischemia is characterized by corneal edema, often with deep folds, heavy flare, and cells sometimes with hypopyon, pupillary irregularity, and sometimes cataract. All of this occurs with hypotony. Grade IV anterior segment ischemia can cause permanent damage to the eye with reduction of vision from cataract, corneal scarring, and retinal (macular) changes.

Prevention

The surgeon should avoid detaching four rectus muscles even if the procedures are performed many years apart. Instead, when possible, at least one rectus muscle should be left attached with its competent anterior ciliary circulation. I have performed a strengthening procedure when necessary on the fourth rectus muscle with tuck, preserving the anterior ciliary arteries. In other cases, which were considered 'desperate,' I have detached the remaining rectus muscle more than 10 years after the initial eye muscle surgery without adverse results. However, no matter how long the time interval, serious anterior segment ischemia can occur if all anterior ciliary arteries are severed. Rectus muscle recession with sparing of the anterior ciliary arteries can be performed to preserve anterior segment circulation, thereby allowing surgery on a rectus muscle while retaining the integrity of the anterior ciliary vessels. When performing a muscle splitting muscle transfer procedure care should be taken to ensure that both of the anterior ciliary vessels are not inadvertently included in the transferred slip of muscle. As a practical guide the following applies to anterior segment ischemia: (1) vertical recti have more anterior ciliary vessels, but are not backed up by posterior ciliary arteries; (2) older or vascular compromised patients are more susceptible; (3) mild anterior segment ischemia is common and is clinically insignificant; (4) it is possible to 'get away' with detachment of four rectus muscles, but the time interval between surgeries does not necessarily make this a safe procedure; (5) it is not

practical or perhaps possible to predict accurately which patients will have clinically significant anterior segment ischemia; and (6) if surgery is limited to two rectus muscles per procedure per eye and if no more than three rectus muscles per eye are detached in a lifetime, the chance of a patient developing clinically significant anterior segment ischemia is remote.

Exceptions do occur. I did full tendon transfer on two patients on the same day leaving the lateral rectus attached but severing the other six ciliary arteries. Both patients had sixth nerve palsy, were in their 40's and were otherwise healthy. Both developed grade IV anterior segment ischemia. After treatment, each had residual iris atrophy and mild cataract with loss of two lines of vision (Figure 12).

Treatment

Topical and systemic steroids with dilation of the pupil is the treatment of choice for anterior segment ischemia. The topical steroid can be given as 1% prednisolone up to three or four times a day combined with prednisone orally every other day, 50 to 100 mg, with careful monitoring of the response and tapering of the drug as soon as possible. The pupil may be dilated with daily installation of homatropine 5%.

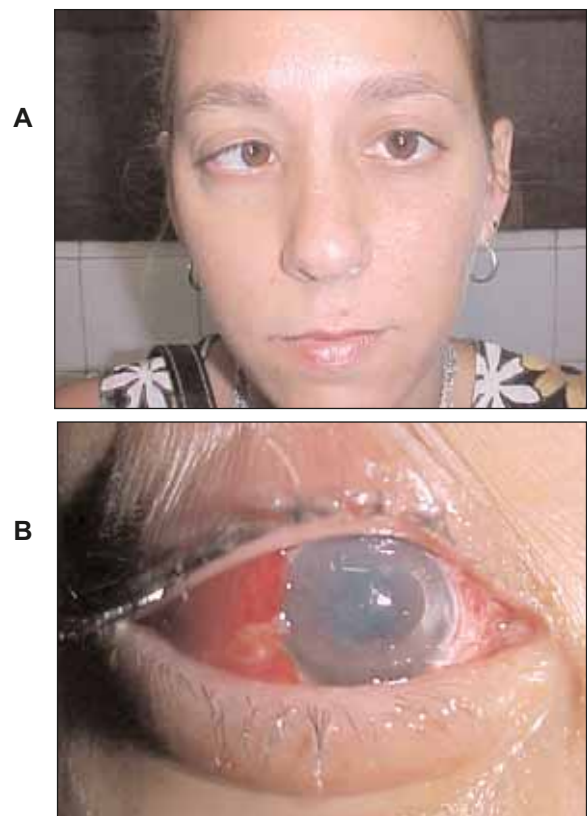


Figure 12

A Right sixth nerve palsy, preoperatively
B Corneal edema

continued.

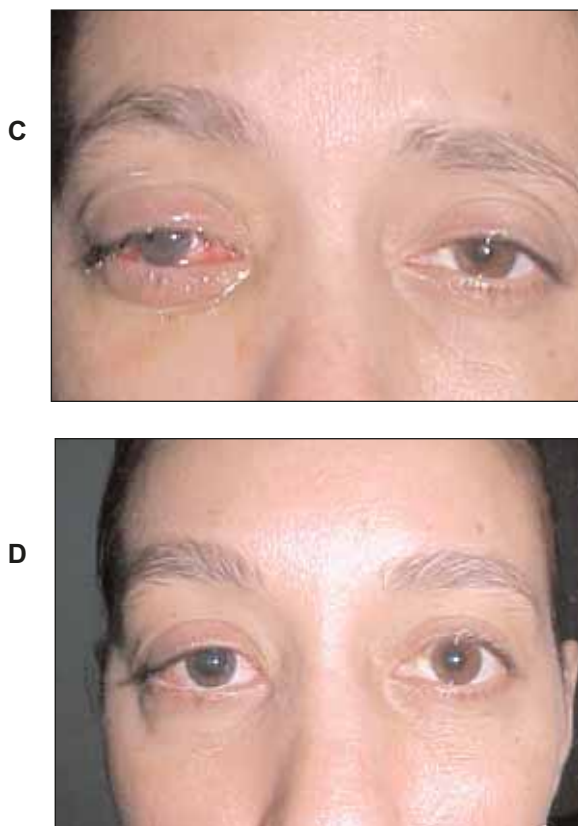

Figure 12, cont'd

- C** Eyes aligned with anterior segment ischemia, right eye
D Good alignment postoperatively with dilated pupil, segmental iris atrophy, and slight cataract; visual acuity reduced to 20/40

Persistent overaction of the inferior oblique muscle

Persistent overaction of the inferior oblique muscle may occur if some of the inferior oblique fibers have been left intact. It may also occur if the severed ends of a myectomized muscle rejoin by muscle or fibrous tissue. In other cases, the proximal end of the inferior oblique can attach to sclera, so as to allow considerable inferior oblique function.

Prevention

Careful exposure of the posterior aspect of the inferior oblique muscle should be carried out routinely. Any remaining fibers should then be transected. This technique must be applied for both myectomy and recession. It has been said that the inferior oblique muscle can have two or three heads. However, this possible anatomic variation is of no significance in the case of myectomy performed in the inferior temporal quadrant. When a myectomy is

performed, the proximal end can be tucked into the opening in Tenon's capsule toward Lockwood's ligament. After carrying out this maneuver, the small defect in posterior Tenon's capsule may be closed with one or two 8-0 Vicryl sutures.

Treatment

The inferior oblique muscle must be explored and re-weakened using the surgeon's preferred technique. The inferior oblique traction test is a useful means for confirming persistent inferior oblique connections (see chapter 4).

Inferior oblique adherence syndrome

Inferior oblique adherence syndrome is characterized by a hypotropia in the primary position and limitation of elevation in adduction in an eye that has undergone inferior oblique weakening. There is always a mechanical restriction to elevation in adduction that can be confirmed with testing of passive ductions. When this condition was described initially, it was stated that it was more likely to occur after myectomy of the inferior oblique and that it was much less likely to occur after recession. Experience has confirmed that inferior oblique adherence syndrome could occur after any inferior oblique weakening that had been complicated by rupture of Tenon's capsule (intermuscular membrane) and prolapse of fat accompanied by hemorrhage. Dense scarring in the inferior temporal quadrant is the cause of inferior oblique adherence syndrome (Figure 13).

Prevention

Inferior oblique adherence syndrome can be avoided if care is taken at the time of surgery. The inferior oblique muscle should be engaged under direct visualization. A small muscle hook should be placed carefully behind the inferior oblique muscle and not simply thrust deeply into the orbit. The intermuscular membrane (posterior Tenon's capsule) should be left intact and any bleeding should be controlled with carefully applied cautery. If any orbital fat is encountered, it should be repositioned behind the intermuscular membrane (posterior Tenon's capsule) and the defect closed with several 8-0 Vicryl sutures.

Treatment

The treatment of inferior oblique adherence syndrome presents a challenge. The surgical area should be dissected carefully and adhesions lysed until passive ductions are free. Appropriate yoke muscle surgery may be performed but persistence of some restriction is the rule, in spite of treatment.

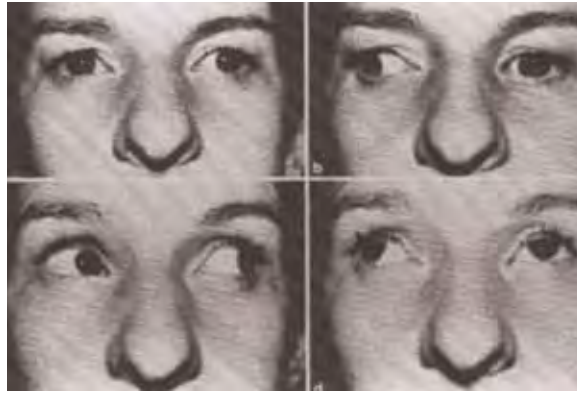

Figure 13
Inferior oblique adherence, left eye. The left eye has limited elevation, depression, and adduction. The latter leads to the increased abduction in elevation creating a 'V' pattern.

Inclusion of the inferior oblique in the lateral rectus insertion

In more than one-third of lateral rectus muscles that we reoperate after either previous lateral rectus recession or resection, the inferior oblique is found attached to the inferior insertion of the lateral rectus. Price called this the J-shaped anomaly. Patients with this complication may have a hyperdeviation or hypodeviation of that eye in the primary position but usually have limited elevation and sometimes depression. There may also be limitation of adduction. The clinical picture is similar to but not as severe as inferior oblique adherence syndrome.

Prevention

When operating on the lateral rectus muscle, always make sure that the lateral rectus has been carefully freed from any connection to the inferior oblique.

Treatment

The inferior oblique muscle must be dissected free from the inferior border of the lateral rectus and allowed to fall back. Unfortunately, even when the inferior oblique is freed and repositioned, a residual vertical and horizontal deviation persists. For this reason, I now advise doing an inferior oblique myectomy or recession in cases with inferior oblique inclusion. This treats the acquired vertical deviation and inferior oblique underaction.

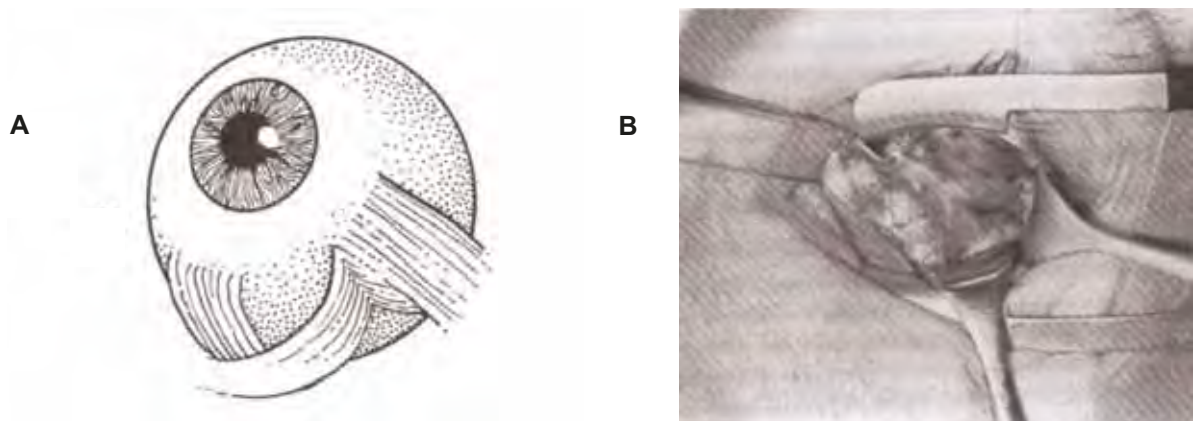
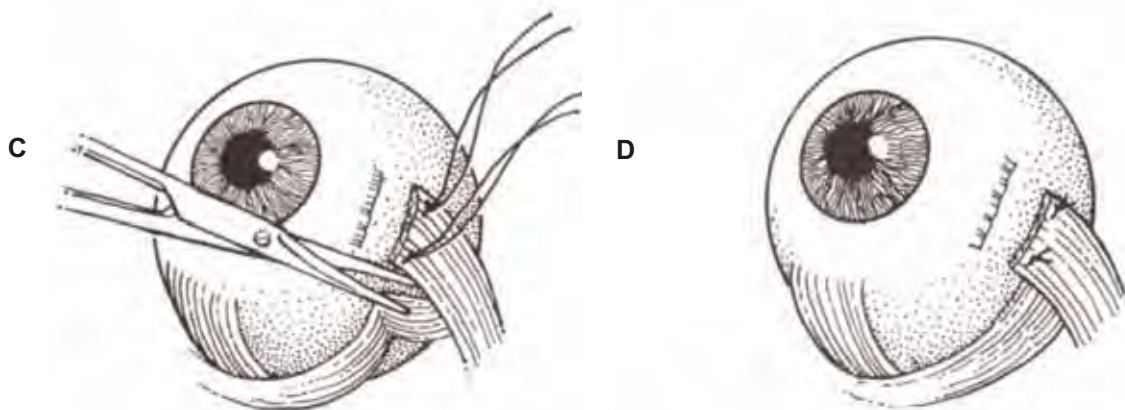


Figure 14
A J anomaly with the inferior oblique attached to the lateral rectus at the insertion of the lateral rectus. This complication produces various expressions of an acquired vertical strabismus after surgery on the lateral rectus muscle.

B The inferior oblique is inserted at the inferior aspect of the insertion of the lateral rectus that had been resected at the previous surgery.

continued.

**Figure 14, cont'd**

C This anomaly is treated by dissecting the inferior oblique free from the lateral rectus muscle with or without lateral rectus recession.

D After the inferior oblique has been dissected, it is allowed to fall back in its usual place. However, in my experience, this is not often successful so inferior oblique myectomy is done in these cases as shown in chapter 9.

Muscle-tendon rupture

During the course of extraocular muscle surgery, a muscle or tendon can rupture. This may be caused by excessive force applied to the normal muscle while handling it on a muscle hook or because the muscle or tendon is abnormally thin or atrophic. Greenwald has reported rupture in several patients. I observed rupture of the inferior oblique while an assistant was holding the muscle with two muscle hooks before I was to have placed hemostats before cutting out a 5 mm segment of muscle. The assistant could not explain why this happened to the healthy muscle. We believed that the inexperienced assistant simply pulled too hard. A minor amount of bleeding was controlled and the distal end of the muscle was trimmed. The proximal muscle disappeared behind Tenon's. Unfortunately, this patient had limited elevation in adduction on a mechanical basis which was refractory to treatment. Bleeding with tissue damage in the area of Lockwood's ligament was the suspected cause. In another case, the superior oblique tendon was pulled from the globe while the tendon was being tucked. The tuck was then converted to a resection without complication. In cases where excessive force is the reason for rupture, as occurred with the inferior oblique described earlier, trauma to associated structures may lead to an adherence syndrome. If the horizontal recti are ruptured resulting in retraction of the proximal portion into the posterior fat compartment, excessive search should be avoided to prevent further trauma leading to restrictive strabismus. Declaring

the muscle 'lost' and carrying out a muscle transfer could be the best course in case of such a 'lost' horizontal rectus muscle, especially the medial.

Prevention

Rupture of an extraocular muscle or tendon can be avoided by limiting the force applied to an extraocular muscle or tendon during manipulation in the course of strabismus surgery. In case an abnormally thin or atrophic muscle is suspected or observed, extra caution must be exercised.

Hyphema

I encountered hyphema one time during strabismus surgery. This complication occurred after tucking a superior oblique tendon. The patient had undergone cataract surgery one year earlier. It was thought that an abnormal iris vessel in the superior anterior chamber angle associated with the cataract incision had been ruptured during manipulation of the globe. The hyphema cleared in 24 hours without complication.

Prevention

There is probably no sure way to prevent the development of hyphema. However, when performing eye muscle surgery on a patient who has had prior cataract surgery, I exercise great care while manipulating the muscles and globe.

Posterior chamber hemorrhage

Greenberg, et. al., reported one patient with posterior chamber hemorrhage. This was associated with choroidal effusion, presumably caused by a perforation of the retina involving a retinal vessel. After a re-bleed one week after surgery that was treated with bed rest and aminocaproic acid, the patient did well. One year later, an atrophic scar was noted in the area of the hemorrhage, where a traction suture had been placed at the time of surgery.

Prevention

Posterior chamber hemorrhage due to retinal perforation is prevented by taking appropriately shallow scleral bites during surgery. This technique also, or perhaps especially, should be applied to traction sutures which are usually placed with larger needles.

Motility disturbance after nonmotility procedures

Under certain circumstances, cosmetic blepharoplasty can result in damage to the inferior rectus, inferior oblique, and/or superior oblique muscles leading to diplopia. This complication occurs when dissection in the fat extends beyond the appropriate area, resulting in denervation or more likely mechanical restriction of the extraocular muscle or tendon. As with any motility disturbance due to mechanical causes, that occurring after cosmetic blepharoplasty is particularly difficult to manage and tends to persist in spite of attempts to surgically relieve the restriction.

Superior oblique muscle palsy has occurred after anterior ethmoidal artery ligation for epistaxis. Superior oblique palsy can occur after the Lynch incision for exposure of the ethmoid sinus. This subperiosteal incision displaces the trochlea which may not return to its normal preoperative position.

The medial rectus can be literally chewed up when ethmoid sinus surgery results in fracture of the medial wall of the orbit, lamina paparecya, allowing the instrument into the orbit. I have seen two cases like this. There is no medial rectus function in these cases. Imaging of the orbit confirms the medial rectus defect. Treatment is by full tendon transfer.

Various diplopia patterns can occur after successful cataract surgery from a variety of causes including presumed myotoxicity from the injection of local anesthetic.

Postoperative Brown syndrome

Inability to fully elevate the eye in adduction because of mechanical restriction around the superior oblique tendon and the trochlea is the broad definition of Brown syndrome. This definition includes a wider array of etiologies than originally described by Brown, but is a logical extension of the limited condition he described as the superior oblique tendon sheath syndrome. A common cause of Brown syndrome is tuck or some other shortening procedure to the superior oblique tendon. The unique anatomy of the superior oblique muscle - trochlea - reflected tendon causes each of the components to function somewhat independently. For example, the superior oblique tendon has a 16-mm potential total excursion through the trochlea from maximum upgaze to maximum downgaze. When a tuck is taken in the tendon or when it is shortened by resection, the amount of tendon available to move in the trochlea may be reduced to the point where the trochlear - superior oblique tendon insertion distance required for full elevation in adduction cannot be achieved and Brown syndrome results.

Surgeons have disagreed on the incidence of postoperative Brown syndrome, probably because many surgeons avoid operating on the superior oblique when treating patients for superior oblique palsy. These surgeons will not encounter (produce) iatrogenic Brown syndrome! Others are very careful when doing a tuck of the superior oblique and avoid producing Brown syndrome by doing intraoperative forced duction testing and by titrating the amount of tuck to a point just short of limiting elevation in adduction. Perhaps the most enlightened way to look at this condition is to recognize that the superior oblique tendon anatomy varies greatly. In congenital superior oblique palsy, the tendon is frequently anomalous ranging from absence to misdirection to redundancy. In contrast, the superior oblique tendon in acquired cases is almost always of normal length, position, and consistency. Thus, patients with congenital superior oblique palsy can and in many cases should undergo shortening of the superior oblique tendon that can be accomplished without producing Brown syndrome. In contrast, acquired superior oblique palsy which is much more susceptible to postoperative Brown syndrome is best treated in most cases by surgery on appropriate muscles other than the paretic superior oblique. This includes the antagonist inferior oblique, ipsilateral superior rectus, and yoke inferior rectus (Figure 15).

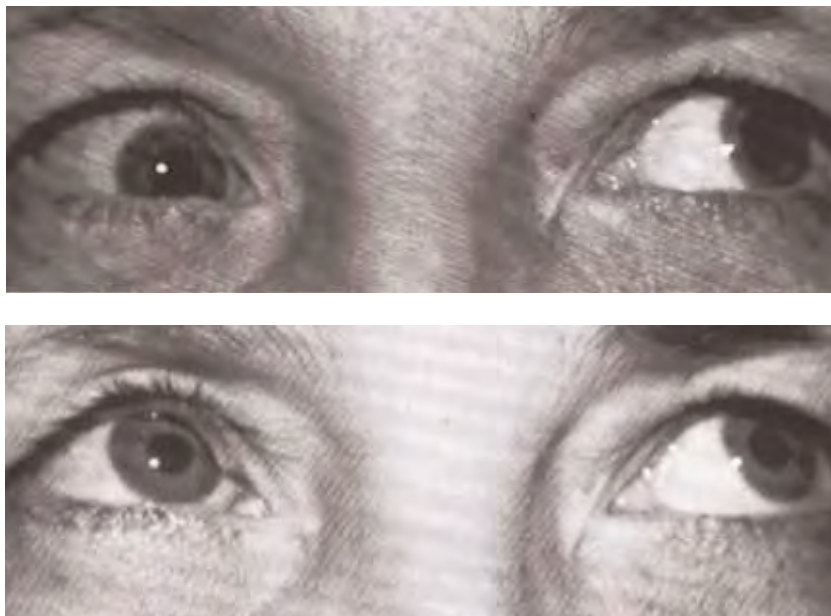

Figure 15
Brown syndrome after superior oblique tuck before and after take down.

Prevention

The surest way to prevent Brown syndrome postoperatively is to avoid surgery to shorten the superior oblique tendon. The next best way is to evaluate the superior oblique tendon carefully before shortening it. This is done by means of forced ductions comparing the two sides and by inspection of the tendon for location of the insertion and for redundancy of the tendon. It is a good idea to observe the normal superior oblique tendon when enucleating an eye. Knowledge of what the normal superior oblique tendon looks and feels like provides a useful background for evaluating and grading the abnormal tendon. Of course, excess manipulation should be avoided when enucleating an eye with malignancy. If a superior oblique tendon shortening procedure is performed, repeat intraoperative forced ductions should also be performed. At the conclusion of the procedure a successfully tucked tendon will allow full or nearly full elevation in adduction with very little increase in resistance.

Early in my career, I tucked a superior oblique tendon 22 mm. This produced a 'perfect' result. Subsequently, I produced a severe Brown syndrome in 17 of 59 patients undergoing superior oblique shortening. Nine of these patients required surgical 'take down' of the tuck. As a result of this experience, I began to look more critically at the differences in the superior oblique tendon. This was the genesis

of my attempt to classify superior oblique palsy into congenital palsy with an abnormal tendon and acquired with a normal tendon.

Treatment

When Brown syndrome is encountered postoperatively, time is the first consideration. The patient is advised to look up in adduction with the involved eye. If after several weeks to months the restriction persists and annoys the patient, the tuck can be taken down or the resected tendon can be disinserted or recessed. In most cases, this second procedure will correct the problem without seriously compromising the results of the original surgery.

Symblepharon

Symblepharon may occur with improperly placed conjunctival incisions (Figure 16).

Prevention

Careful conjunctival incision and closure will prevent symblepharon.

Treatment

Conjunctival recession with bare sclera closure should be carried out if ocular motility is restricted or if the conjunctiva is reddened and unsightly.

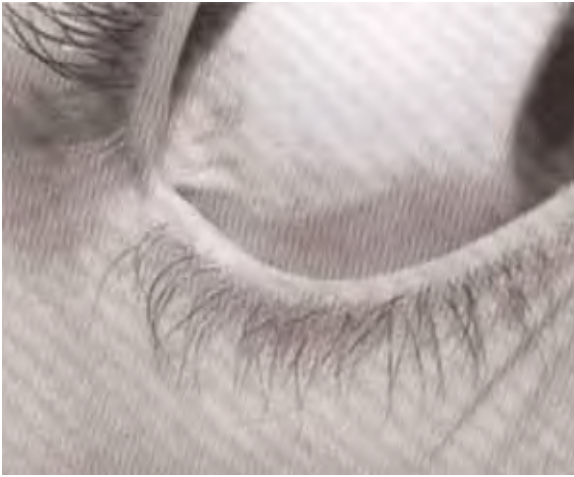

Figure 16 Symblepharon

Treatment

A severed vortex vein should be controlled with local pressure over the bleeding site. Cautery may be used. The treatment of diffuse orbital hemorrhage from blood dyscrasia depends on the surgeon's success at maintaining a reasonable intraocular pressure during the acute period. Assistance from a hematologist is useful and should be sought. Fortunately, children and young adults can withstand brief periods (up to several hours) of very high intraocular pressure without sustaining damage. If such a hemorrhage occurs, osmotic agents and digital massage along with careful monitoring of the intraocular pressure are indicated. Such hemorrhage occurring after extraocular muscle surgery should not be treated with paracentesis.

Orbital hemorrhage

Orbital hemorrhage may occur after a vortex vein is cut or when a patient has an unrecognized blood dyscrasia. Cutting a vortex vein causes a large, usually anterior, hematoma with dark blood that results in unsightly lid swelling and discoloration. Blood dyscrasias cause a far more serious generalized oozing into all orbital tissue. In one operation I did which resulted in generalized orbital hemorrhage, 8 mm of proptosis occurred in both eyes along with intraocular pressure elevation to 50 mm Hg, corneal edema, and easily induced retinal artery pulsations (Figure 17).

Prevention

Careful dissection coupled with awareness of the location of the vortex veins can reduce, if not eliminate, hemorrhage. Blood dyscrasias should be uncovered preoperatively in the course of securing an adequate history. In any case where a bleeding tendency is suspected, hematologic evaluation should be obtained. Preoperative use of aspirin can cause a decrease in platelets which in turn will promote bleeding during and after surgery. Patients should stop taking aspirin for 1 or 2 weeks before surgery. If a patient is on anticoagulant medication, stopping or reducing this medication should be discussed with the primary care physician. I have operated safely on many patients using anticoagulants without complication. In these cases special attention was given to hemostasis with meticulous application of wet field cautery.

I have also operated successfully on an adult patient with hemophilia after he was prepared with preserved globulin by his hematologist.




Figure 17

A A 28-year-old man with 70+ prism diopters of exotropia underwent a 7-mm recession of both lateral rectus muscles and an 8-mm resection of both medial rectus muscles.

continued.

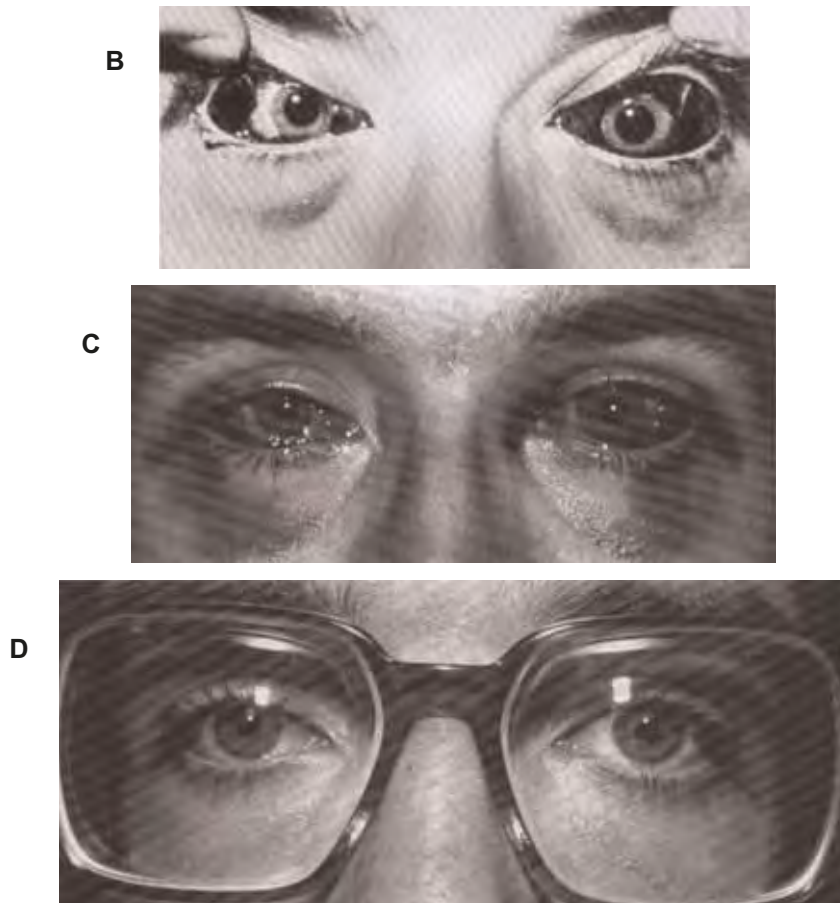


Figure 17, cont'd

B This photo was taken 24 hours after surgery. The intraocular pressure which had been near 50 mm Hg in each eye in the immediate post operative period had by this time reduced to approximately 25 mm Hg. Proptosis had diminished from 8 to 2 mm and the corneas had cleared.

C The eyes were extremely red for weeks.

D The patient had a total recovery and obtained an excellent surgical result which has persisted for 32 years.

Orbital cellulitis

Orbital cellulitis is a rare but most unfortunate complication after extraocular muscle surgery. Proptosis, extreme redness, chemosis, and pain with lid swelling characterize this complication that can occur during the first week to 10 days postoperatively.

Prevention

Using aseptic technique prevents orbital cellulitis.

Treatment

Culture and sensitivity determination should be performed and the proper systemic and topical antibiotic treatment carried out. A broad-spectrum antibiotic may be used before receiving the laboratory results that would lead to choosing the appropriate antibiotic. It is probably best to treat such patients in the hospital with the help of a specialist in infectious disease.

Endophthalmitis

Endophthalmitis is fortunately an extremely rare occurrence after extraocular muscle surgery. It is recognized by the usual signs of conjunctival injection, lid swelling with pain and erythema, anterior chamber reaction including hypopyon and vitreous cellular reaction. It occurs during the first week postoperatively.

Prevention

Using careful sterile technique while avoiding introduction of organisms into the eye by not sticking a needle through the retina into the vitreous will prevent endophthalmitis.

Treatment

Treatment consists of appropriate topical and systemic antibiotics, including intravitreal antibiotic therapy with steroids. This treatment can be combined with vitrectomy and is best accomplished by a retina specialist.

Postoperative communication

Office personnel who handle patient telephone communication must be aware of the significance of patients' complaints. These include increased redness, discharge, and increased pain with lid swelling or vision loss in the early postoperative period of any eye surgery including eye muscle surgery. Any of these signs and symptoms are cause for immediate examination by the surgeon. No patient calling with these complaints should be put off. These complaints signal the onset of a potentially serious postoperative complication. In some cases, early appropriate treatment can mean the difference between a good result and a lost eye. A good rule is that the surgeon or a responsible associate should be informed in a timely manner every time a patient or family member calls especially during the first week after eye surgery.

Operation on the wrong muscle

Prevention

The surgeon should confirm preoperatively which muscle(s) are to be operated and what procedure is to be performed on each muscle. This regimen should be followed while examining the patient in a preoperative holding area with the records of the most recent office visit in hand. In cases with a comitant horizontal deviation, it usually makes little difference which eye is to be operated provided the proper procedure is performed on the muscles. In most cases I tell the parents or the patient that either or both eyes may be operated and permission is obtained for surgery on both eyes. This approach is especially important because even if both eyes do not undergo eye muscle surgery, forced ductions are performed on both eyes and this maneuver can sometimes cause a subconjunctival hemorrhage that must be explained if permission had been given strictly for surgery on one eye.

In other instances, problems can arise from operating on the wrong muscle or from performing the wrong procedure on the 'right' muscle. For example, I have seen two cases where the superior rectus muscle was resected when the surgeon intended to resect the lateral rectus muscle. In both cases the patient had a large hypertropia in the operated eye, a definite surprise to the surgeon at the first postoperative visit. In one case, the procedure had been done well, but on the wrong muscle. Reoperation in this case produced an excellent result. In the other case, the procedure had not been performed well and the patient required several additional surgical procedures including ptosis surgery.

Treatment

If the patient underwent a horizontal recession-resection in the wrong eye, the surgeon would probably not need to perform another procedure. If vertical surgery has been performed on the wrong eye, the deviation will be made worse. If the error is discovered in the operating room, the surgery should be reversed and the proper procedure undertaken. If the error is discovered postoperatively, the patient should be treated as a new case and reoperated according to the findings.

A homily

I believe that it is better to do the wrong procedure well than the correct procedure poorly. This is not to suggest that the surgeon should be any less diligent. Obviously, it is best to do the correct procedure and do it well! On the contrary, it is meant to emphasize the importance of technical competence in the performance of strabismus surgery. It is obvious that this admonition does not apply to procedures where tissue is discarded such as with myectomy or tenectomy, but this admonition does apply to the majority of recession and resection procedures. A poorly executed but properly planned bimedial rectus recession can produce results that can never be overcome such as fat prolapse and conjunctival scarring. On the other hand, a bilateral inferior rectus resection performed (for DVD) on a patient who was scheduled for and needed a bilateral lateral rectus recession was rectified by a skilled but temporarily misguided surgeon without harm to the patient. The resected inferior recti were recessed and the lateral recti were recessed as intended.

Operation on the wrong patient

Prevention

The surgeon should know the patient. In addition, the patient's hospital identification should be checked by nursing personnel to make sure the patient matches the records. It should be a personal rule for the surgeon to see and talk to the patient immediately before surgery. If this is not possible, a person who knows the patient and can verify that the patient and the records match should be on hand.

Treatment

If operation on the wrong patient does occur, the patient should be treated as a new patient.

Unacceptable overcorrections and undercorrections

Undesirable overcorrections and undercorrections are an inevitable accompaniment of strabismus surgery.

Prevention

A careful, accurate workup, correct choice of surgery, and proper execution of surgery will reduce a surgeon's unacceptable overcorrections and undercorrections. The percentage of cases corrected to within ± 10 prism diopters of the intended postoperative angle will depend on multiple factors covered in this book and also on the surgeon's ability to learn from experience. Because similar types of patients react in similar ways, the surgeon should not make the same mistake repeatedly, but instead learn from his patients. It should also be emphasized that by over-

correction or undercorrection I mean more or less correction than the surgeon intended. This is significant because some categories of patients should be undercorrected relative to ortho position and others should be overcorrected.

Treatment

Overcorrections or undercorrections should be treated according to Cooper's dictum; that is, as though they were new cases with appropriate medical, optical, orthoptic, or surgical remedies instituted. In addition, the surgeon should rely on careful measurements, force and velocity studies, and on findings at surgery when doing secondary surgery.

Reading list

General reading list

- Allen JH, editor: Strabismus ophthalmic symposium I. St Louis, 1950, Mosby.
- Allen JH, editor: Strabismus ophthalmic symposium II. St. Louis, 1958, Mosby.
- Bedrossian EH: The surgical and nonsurgical management of strabismus. Springfield, Ill 1969, Charles C Thomas.
- Calhoun JH, Nelson LB, Harley RD: Atlas of pediatric ophthalmic surgery. Philadelphia, 1987, Saunders.
- Del Monte MA, Archer SM. Atlas of pediatric ophthalmology and strabismus surgery. New York, 1993, Churchill Livingstone.
- Dyer JA: Atlas of extraocular muscle surgery. Philadelphia, 1970, Saunders.
- Ellis ED, Helveston EM, editors: Strabismus surgery international ophthalmology clinics. Boston, Fall 1976, Little, Brown & Co., vol. 16, no. 3.
- Gonzalez C: Strabismus and ocular motility. Baltimore, 1983, Williams & Wilkins.
- Hurt J, Rasicovici A, Windsor CE: Comprehensive review of orthoptics and ocular motility—theory, therapy, and surgery. St Louis, 1972, Mosby.
- Lang JD: Strabismus. Thorofare, NJ, 1984, Charles B Slack. New Orleans Academy of Ophthalmology, Strabismus, St Louis, 1962, Mosby.
- New Orleans Academy of Ophthalmology, Symposium on strabismus. St Louis, 1978, Mosby.
- Parks MM: Atlas of strabismus surgery. New York, 1983, Harper & Row.
- Plager DA, editor: Strabismus surgery. Basic and advanced strategies. New York, 2004, Oxford.
- Pratt-Johnson JA, Tillson G: Management of strabismus and amblyopia: a practical guide, ed. 2. New York, 2001, Thieme.
- Prieto-Díaz J, Souza-Dias C: Strabismus, ed. 4. Boston, 1999, Butterworth Heinemann.
- Richards R: A text and atlas of strabismus surgery. Baltimore, 1991, Williams & Wilkins.
- Rosenbaum AL, Santiago AP: Clinical strabismus management. Philadelphia, 1999, Saunders.
- Scobee RG: The oculorotary muscles, ed 2. St Louis, 1952, Mosby.
- von Noorden GK: Atlas of strabismus, ed 4. St Louis, 1983, Mosby.
- von Noorden GK, Campos EC: Binocular vision and ocular motility, ed. 6. St. Louis, 2002, Mosby.
- von Noorden GK, Helveston EM: Strabismus. A decision making approach. St. Louis, 1994, Mosby.
- Wright KW: Color atlas of strabismus surgery. Strabismus. Irvine, CA, 2000, Wright.

Chapter 1

- Duane A, editor: Fuchs' textbook of ophthalmology. Philadelphia, 1908, Lippincott, p 1008.
- Duke-Elder S: System of ophthalmology, vol VI. St Louis, 1973, Mosby, p 223.
- Fink WH: Surgery of the oblique muscles of the eye. St Louis, 1951, Mosby.
- Fink WH: Surgery of the vertical muscles of the eye, ed 2. Springfield, Ill, 1962, Charles C Thomas.
- Lyle TK: Worth and Chavasse's squint — the binocular reflexes and the treatment of strabismus, ed 8. Philadelphia, 1950, Blakiston.
- Peter LC: The extra-ocular muscles—a clinical study of normal and abnormal ocular motility, ed 3. Philadelphia, 1941, Lea & Febiger.
- Sorsby A: A short history of ophthalmology. Mandeville, London, 1933, Staples Press, p 63.
- Spaeth EB: The principles and practice of ophthalmic surgery. Philadelphia, 1944, Lea & Febiger.
- von Noorden GK, editor: History of strabismology. Belgium, 2002, J. P. Wayenborgh.
- Wheeler JM: The collected papers of John Martin Wheeler, MD on ophthalmic subjects. Published by the staff of the Institute of Ophthalmology of the Columbia-Presbyterian Medical Center, New York, 1939.

- Wiener M: Surgery of the eye, ed 2. New York, 1949, Grune & Stratton.
- Wiener M: Surgery of the eye, ed 3. New York, 1952, Grune & Stratton.
- Wiener M, and Alvin B: Surgery of the eye. Philadelphia, 1940, Saunders.
- Worth C: Squint: its causes, pathology and treatment, ed 5. Philadelphia, 1921, Blakiston.

Chapter 2

- Barsoum-Homsy M: Medial rectus insertion site in congenital esotropia. *Can J Ophthalmol* 16:181-185, Oct 1981.
- Clark RA, Miller JM, Demer JL: Location and stability of rectus muscle pulleys. Muscle paths as function of gaze. *Invest Ophthalmol Vis Sci* 38:227, 1997.
- Clark RA, Rosenbaum AL, Demer JL: Magnetic resonance imaging after surgical transposition defines the anteroposterior location of the rectus muscle pulleys. *J AAPOS* 3:9, 1999.
- Cornell E: Innervational anomalies of the extraocular muscles. *Aust J Ophthalmol* 2(1):35-37, 1974.
- Demer JL, Miller JM, Poukens V: Surgical implications of the rectus extraocular muscle pulleys. *Pediatr Ophthalmol Strabismus* 33:208, 1996.
- Demer JL, Miller JM, Poukens V, et al: Evidence for fibromuscular pulleys of the recti extraocular muscles. *Invest Ophthalmol Vis Sci* 36:1125, 1995.
- Demer JL, Oh SY, Poukens V: Evidence for active control of rectus extraocular muscle pulleys. *Invest Ophthalmol Vis Sci* 41:1280, 2000.
- Demer JL, Poukens V, Miller JM, Mircevyeh P: Innervation of extraocular pulley smooth muscle in monkeys and humans. *Invest Ophthalmol Vis Sci* 38:1774, 1997.
- Duane TD, Jaeger EA, editors: Biomedical foundations of ophthalmology, vol 1. New York, 1982, Harper & Row.
- Duke-Elder S, Wybar KC: The anatomy of the visual system. In: *System of Ophthalmology*, vol. 2. St. Louis, 1961, Mosby-Year Book.
- Fink WH: Surgery of the vertical muscles of the eyes, ed. 2. Springfield, Ill, 1962, Charles C. Thomas.
- Gillies WE, Brooks AM: Strabismus surgery landmarks and axial length (letter). *Ophthalmology* 98(12):1755, 1991.
- Helveston EM: A new two step method for the diagnosis of isolated cyclovertical muscle palsies. *Am J Ophthalmol* 64(5):914-915, 1967.
- Helveston EM: The influence of superior oblique anatomy on function and treatment. *Bin Vis Strabismus Q* 14:16, 1999.
- Helveston EM, Merriam WW, Ellis FD, et al: The trochlea: A study of the anatomy and physiology. *Ophthalmology* 89:124, 1982.

- Jones LT: A new concept of the orbital fascia and its surgical implications. *Trans Am Acad Ophthalmol Otolaryngol* 72(5):755-764, 1968.
- Keech RV, Scott WE, Baker JD: The medial rectus muscle insertion site in infantile esotropia. *Am J Ophthalmol* 109(1):79-84, 1990.
- Metz HS, Aquavilla JV, Sgabelloni E: A model for eye muscle surgery. *Arch Ophthalmol* 98:1117, June 1980.
- Miller JM: Functional anatomy of human rectus muscles. *Vision Res* 29:223, 1989.
- Parks MM: The superior oblique tendon - 33rd Doyne Memorial Lecture. *Trans Ophthalmol Soc UK* 97:288, 1977.
- Sandall GS, Morrison JW: Congenital absence of lateral rectus muscle. *J Pediatr Ophthalmol Strabismus* 16(1):35-39, 1979.
- Saunders RA, Bluestein EC, Wilson ME, Berland JE: Anterior segment ischemia after strabismus surgery. *Surv Ophthalmol* 38:456, 1994.
- Sawa M: Absence of the right superior oblique muscle: a case report. *Jpn J Ophthalmol* 22:178-183, 1978.
- Sevel P: The origins and insertions of the extraocular muscles: Development, histologic features, and clinical significance. *Trans Am Ophthalmol Soc* 84:488, 1986.
- Stager DR: The neovascular bundle of the inferior oblique muscle as the ancillary origin of that muscle. *J Am Assoc Pediatr Ophthalmol Strabismus* 4:216, 1997.
- Swan KC, Wilkins JH: Extraocular muscle surgery in early infancy—anatomical factors. *J Pediatr Ophthalmol Strabismus* 21(2):44, 1984.
- Urrets-Zavalía A Jr, Solares-Zamora J, Olmos HR: Anthropological studies on the nature of cyclovertical squint. *Br J Ophthalmol* 45:578-596, 1961.
- Wilson RS, Landers JH: Anomalous duplication of inferior oblique muscle. *Am J Ophthalmol* 93:521-522, 1982.

Chapter 3

- Alexander JP: Reflex disturbances of cardiac rhythm during ophthalmic surgery. *Br J Ophthalmol* 59:518-523, 1975.
- Apt L, Isenberg S: Eye position of strabismus patients under general anesthesia. *Am J Ophthalmol* 84:574-579, 1977.
- Apt L, Isenberg S, Gaffney WL: The oculocardiac reflex in strabismus surgery. *Am J Ophthalmol* 76:533-536, 1973.
- Apt L, et al: Cat gut allergy in eye muscle surgery. *Arch Ophthalmol* 65:474-480, 1961.
- Biesner DH: Extraocular muscle recession utilizing silicone tendon prosthesis. *Arch Ophthalmol* 83:195-204, 1970.

- Blau RP, Greenburg S, Lorfel R, Sugar HS: Polyglycolic acid suture in strabismus surgery. *Arch Ophthalmol* 93:538, July 1975.
- Brown DR, Pacheco EM, Repka MX: Recovery of extraocular muscle function after adjustable suture strabismus surgery under local anesthesia. *J Pediatr Ophthalmol Strabismus* 29(1):16-20, 1992.
- Brown RE Jr, James DJ, Weaver RG, et al: Low-dose droperidol versus standard-dose droperidol for prevention of postoperative vomiting after pediatric strabismus surgery. *J Clin Anesth* 3(4):306-309, 1991.
- Brueggemann WG, Helveston EM: Ketamine anesthesia. *Ophthalmic Surg* 2(6):243-245, 1971.
- Capo H, Munoz M: Sub-Tenon's lidocaine irrigation for strabismus surgery (letter). *Ophthalmic Surg* 23(2):145, 1992.
- Dunlap EA: Survey of sutures used in strabismus surgery. *Am J Ophthalmol* 74(4):625-626, 1972.
- France NK, France TD, Woodburn JD Jr, et al: Succinylcholine alteration of the forced duction test. *Ophthalmology* 87:1282-1287, 1980.
- Hamed LM, Ellis FD, Boudreault G, et al: Hibiclen keratitis. *Am J Ophthalmol* 104:50-56, 1987.
- Helveston EM: A new disposable headrest for surgery. *Am J Ophthalmol* 64(3):468-469, 1967.
- Helveston EM, Callahan MA: Synthetic absorbable suture for strabismus surgery. *Am J Ophthalmol* 82(2): 1976.
- Hessemer V: Anesthesia effects on ocular circulation. Synopsis of a study. *Fortschr Ophthalmol* 88(5):577-587, 1991.
- Isenberg SJ, Apt L, Yamada S: Overnight admission of outpatient strabismus patients. *Ophthalmic Surg* 21(8):540-543, 1990.
- Kearns PP, Cullen JF: Fucithalamic, chloramphenicol or no treatment after squint surgery in children. A single blind randomised study. *Acta Ophthalmol (Copenh)* 70(1):132-134, 1992.
- Klockgether-Radke A, Feldmann M, Braun U, Muhlendyck H: Droperidol versus metoclopramide. Prevention of emesis following strabismus surgery in children. *Anaesthesist* 41(5):254-259, 1992.
- Knapp P: Diagnosis and surgical treatment of hyperopia. *Am Orthopt J* 21:29-37, 1971.
- Klyve P, Nicolaisen B: Surgery of strabismus performed during topical anesthesia using adjustable sutures. *Tidsskr Nor Laegeforen* 112(6): 774-775, 1992.
- Kraus GB, Giebner M, Palackal R: The prevention of postoperative vomiting following strabismus surgery in children. *Anaesthetist* 40(2):92-95, 1991.
- Larsson S, Asgeirsson B, Magnusson J: Propofol-fentanyl anesthesia compared to thiopental-halothane with special reference to recovery and vomiting after pediatric strabismus surgery. *Acta Anaesthesiol Scand* 36(2): 182-186, 1992.
- Larsson S, Jonmarker C: Postoperative emesis after pediatric strabismus surgery: the effect of dixyrazine compared to droperidol. *Acta Anaesthesiol Scand* 34(3):227-280, 1990.
- Lin DM, Furst SR, Rodarte A: A double-blinded comparison of metoclopramide and droperidol for prevention of emesis following strabismus surgery. *Anesthesiology* 76(3):357-361, 1992.
- Merritt IC, Chapman L, Rabb M: Polyglycolic acid suture in strabismus surgery. *Arch Ophthalmol* 91:439, June 1974.
- Milot J, Jacob JL, Blanc VF, Hardy JF. The oculocardial reflex in strabismus surgery. *Can J Ophthalmol* 18:314, 1983.
- Misurya VK, Singh SP, Kulshrestha VK: Prevention of oculocardiac reflex (O.C.R.) during extraocular muscle surgery. *Indian J Ophthalmol* 38(2): 85-87, 1990.
- Rolle L, Belluomo-Anello C, Viglietto A, D'Arì G: Propofol in the anesthesia of patients at risk of malignant hyperthermia in pediatric ophthalmic surgery. *Minerva Anestesiol* 57(9):602-603, 1991.
- Sanders RJ, Nelson LB, Deutsch JA: Peribulbar anesthesia for strabismus surgery. *Am J Ophthalmol* 109(6): 705-708, 1990.
- Solizski SE, Awner S, Reynolds JD: Perioperative care of the strabismus patient. *J Pediatr Ophthalmol Strabismus* 34:1256, 1997.
- Steele MA, Lavrich JB, Nelson LB, Koller HP: Sub-Tenon's infusion of local anesthetic for strabismus surgery. *Ophthalmic Surg* 23(1):40-43, 1992.
- Weinstock SM, Flynn JT: Brief hospital admissions for pediatric strabismus surgery. *Am J Ophthalmol* 80:525-529, 1975.
- Yentis SM, Bissonnette B: Ineffectiveness of acupuncture and droperidol in preventing vomiting following strabismus repair in children. *Can J Anaesth* 39(2):151-154, 1992.

Chapter 4

- Apt L, Azelrod RN: Generalized fibrosis of the extraocular muscles. *Am J Ophthalmol* 85:822-829, 1978.
- Bateman JB, et al: Quantitative analysis of spring forces in esotropia during surgery. *J Pediatr Ophthalmol Strabismus* 19:7-11, Jan/Feb 1982.
- Collins CC, Jampolsky A, Alden AB, et al: Length-tension recording system for strabismus surgery. *IEEE Trans Biomed Eng* 38(3):230-237, 1991.
- Helveston EM: A new two step method for the diagnosis of isolated cyclovertical muscle palsies. *Am J Ophthalmol* 64(5):914-915, 1967.
- Metz HS, Ford GP: The surgical approach to strabismus with tight extraocular muscles. *Ann Ophthalmol* 6:1237-1241, 1974.
- Metz HS, et al: Ocular saccades in lateral rectus palsy. *Arch Ophthalmol* 84:453-460, 1970.

- Paris V, Saya H: The use of Healon in surgery with adjustable sutures for strabismus. *Bull Soc Beige Ophthalmol* 239:37-41, 1990.
- Parks MM: Isolated cyclovertical muscle palsy. *Arch Ophthalmol* 60:1027-1035, 1958.
- Paysse EA, Coats DK, Plager DA: Facial asymmetry and tendon laxity in superior oblique palsy. *J Pediatr Ophthalmol Strabismus* 32:158-161, 1995.
- Plager DA: Superior oblique palsy and superior oblique myokymia. In: Rosenbaum AL, Santiago AP, eds, *Clinical strabismus management: Principles and surgical techniques*. Philadelphia, 1999, WB Saunders Co, pp 219-229.
- Plager DA: Tendon laxity in superior oblique palsy. *Ophthalmology* 99:1032-1038, 1992.
- Plager DA: Traction testing in superior oblique palsy. *J Pediatr Ophthalmol Strabismus* 27(3): 136-140, 1990.
- Prism Adaptation Study Research Group: Efficacy of prism adaptation in the surgical management of acquired esotropia. *Arch Ophthalmol* 108:1248, 1990.
- Repka MX, Connet JE, Scott WE: The one-year surgical outcome after prism adaptation for the management of acquired esotropia. *Ophthalmology* 103:922, 1996.
- Rosenbaum AL, Metz HS: Diagnosis of lost or slipped muscle by saccadic velocity measurements. *Am J Ophthalmol* 77:215-222, 1974.
- Scott AB: Active force tests in lateral rectus paralysis. *Arch Ophthalmol* 85:397-404, 1971.
- Scott AB, Collins CC, O'Meara DM: A forceps to measure strabismus forces. *Arch Ophthalmol* 88(3):330-333, 1972.
- Scott WE: Horizontal saccadic velocities in Duane's syndrome. *Am J Ophthalmol* 80:901-906, 1975.
- Scott WE, Thalacker A: Preoperative prism adaptation in acquired esotropia. *Ophthalmologica* 189:49, 1984.
- Cooper J, Medow N: Major review: intermittent exotropia; basic and divergence excess type. *Bin Vis Eye Muscle Surg Q* 8:185-216, 1993.
- Crone RA: *Diplopia*. Amsterdam, 1973, Excerpta Medica.
- Freeman RS, Isenberg SJ: The use of part-time occlusion for early onset unilateral exotropia. *J Pediatr Ophthalmol Strabismus*, 26:94-96, 1989.
- Gordon YJ, Bachar E: Multiple regression analysis predictor models in exotropia surgery. *Am J Ophthalmol* 90:687-691, 1980.
- Havertape SA, Cruz OA, Chu FC: Sensory strabismus - eso or exo? *J Pediatr Ophthalmol Strabismus* 38:327-330, 2001.
- Helveston EM, Birchler C: Class VII superior oblique palsy: subclassification and treatment suggestions. *Am Orthopt J* 32:104-110, 1982.
- Helveston EM, von Noorden GK: Microtropia: a newly defined entity. *Arch Ophthalmol* 78:272-281, 1967.
- Helveston EM, Neely DE, Stidham DB, et al: Results of early alignment of congenital esotropia. *Ophthalmology* 106:1716-1726, 1999.
- Hermann JS: Masked bilateral superior oblique paresis. *J Pediatr Ophthalmol Strabismus* 18(2):43-48, 1981.
- Hoyt CS: Abnormalities of the vestibulo-ocular response in congenital esotropia. *Am J Ophthalmol* 93:704-708, 1982.
- Hunter DG, Ellis FJ: Prevalence of systemic and ocular disease in infantile exotropia: comparison with infantile esotropia. *Ophthalmology* 106:1951-1956, 1999.
- Iacobucci IL, Archer SM, Giles CL: Children with exotropia responsive to spectacle correction of hyperopia. *Am J Ophthalmol* 116:79-83, 1993.
- Knapp P: Vertically incomitant horizontal strabismus: the so-called "A" and "V" syndromes. *Trans Am Ophthalmol Soc* 57:666-669, 1959.
- Kusher BJ: Exotropic deviations: a functional classification and approach to treatment. *Am Orthopt J* 38:81-93, 1998.
- Kushner BJ: Selective surgery for intermittent exotropia based on distance/near differences. *Arch Ophthalmol* 116:324-328, 1998.
- Kushner BJ, Morton GV: Diagnostic occlusion in strabismus management. *J Ocular Ther Surg*, pp 194-200, July-Aug. 1983.
- Moore S: The prognostic value of lateral gaze measurements in intermittent exotropia. *Am Orthopt J* 19:69-71, 1969.
- Moore S, Mein J, Stockbridge L, editors: *Orthoptics: past, present, future*. Miami, 1976, Symposium Specialists.
- Nemet P, Godel U, Baruch E, Lazar M: Pitfall of acquired ocular torticollis. *J Pediatr Ophthalmol Strabismus* 17(5):310-311, 1980.

Chapter 5

- Bixenman WW: Diagnosis of superior oblique palsy. *J Clin Neuro Ophthalmol* 1:199, 1981.
- Breinin GM: Accommodative strabismus and the AC/A ratio. *Am J Ophthalmol* 71:303-311, 1971.
- Burian HM: Normal and anomalous correspondence. In Allen JH, editor: *Strabismus ophthalmic symposium II*. St Louis, 1958, Mosby.
- Burian HM: Exodeviations: their classification, diagnosis, and treatment. *Am J Ophthalmol* 62:1161-1166, 1966.
- Caltrider N, Jampolsky A: Overcorrecting minus lens therapy for treatment of intermittent exotropia. *Ophthalmology* 90:1160-1165, 1983.
- Coffey B, Wick B, Cotter S, et al: Treatment options in intermittent exotropia: a critical appraisal. *Optom Vis Sci* 69:386-404, 1992.

- Parks MM: Ocular motility and strabismus. New York, 1975, Harper & Row.
- Pediatric Eye Disease Investigator Group: The clinical spectrum of early-onset esotropia: experience of the Congenital Esotropia Observational Study. *Am J Ophthalmol* 133:102-108, 2002.
- Pediatric Eye Disease Investigator Group: Spontaneous resolution of early-onset esotropia: experience of the Congenital Esotropia Observational Study. *Am J Ophthalmol* 133:109-118, 2002.
- Prism Adaptation Research Group: Efficacy of prism adaptation in the surgical management of acquired esotropia. *Arch Ophthalmol* 108:1248-1256, 1990.
- Repka MX, Arnoldi KA: Lateral incomitance in exotropia: fact or artifact? *J Pediatr Ophthalmol Strabismus* 28:125-128, discussion 129-130, 1991.
- Romano PE, von Noorden GK: Atypical responses to the four-diopter prism test. *Am J Ophthalmol* 67:935-941, 1969.
- Rosenbaum AL: Evaluation and management of intermittent exotropia. *Am Orthopt J* 46:94-98, 1996.
- Ruttum M, von Noorden GK: Adaptation to tilting of the visual environment in cyclotropia. *Am J Ophthalmol* 96:229-237, Aug. 1983.
- Saunders RA, Wilson ME, Bluestein EC, et al: Surgery on the normal eye in Duane retraction syndrome. *J Pediatr Ophthalmol Strabismus* 31:162-169, discussion 170-171, 1994.
- Scott AB, Mash AJ, Jampolsky A: Quantitative guidelines for exotropia surgery. *Invest Ophthalmol* 14:428, 1974.
- Scott AB, Wong GY: Duane's syndrome. *Arch Ophthalmol* 87(2):140-147, 1972.
- Swan KC: The blind spot mechanism in strabismus. In Allen JH, editor: *Strabismus ophthalmic symposium II*. St Louis, 1958, Mosby.
- Urist MJ: A lateral version light reflex test. *Am J Ophthalmol* 63:808-815, 1967.
- von Noorden GK: Nystagmus compensation syndrome. *Am J Ophthalmol* 82(2):283-290, 1976.
- von Noorden GK: *Atlas of strabismus*, ed 4. St Louis, 1983, Mosby.
- Wiggins RE, von Noorden GK: Monocular eye closure in sunlight. *J Pediatr Ophthalmol Strabismus* 27:16-20, discussion 21-22, 1990.
- Wilcox LM, Gittinger JW, Breinin GM: Congenital adduction palsy and synergistic divergence. *Am J Ophthalmol* 91(1):1-7, 1981.
- Wilson ME, Parks MM: Primary inferior oblique overaction in congenital esotropia, accommodative esotropia, and intermittent exotropia. *Ophthalmology* 96:950-955, discussion 956-957, 1989.
- Wright KW: Brown's syndrome: Diagnosis and management. *Trans Am Ophthalmol Soc* 97:1023, 1999.
- Wright KW, Edelman PM, McVey JH, et al: High-grade stereo acuity after early surgery for congenital esotropia. *Arch Ophthalmol* 112:913-919, 1994.

Chapter 6

- Mazow ML: Conjunctiva and the creeping muscle. *J Pediatr Ophthalmol* 10:267-270, Nov. 1973.
- Parks MM: Fornix incision for horizontal rectus muscle surgery. *Am J Ophthalmol* 65(6):907-915, 1968.
- Swan KC and Talbot T: Recession under Tenon's capsule. *Arch Ophthalmol* 51:32-41, 1954.
- von Noorden GK: The limbal approach to surgery of the rectus muscles. *Arch Ophthalmol* 80:94-97, 1968.
- von Noorden GK: Modification of the limbal approach to the rectus muscles. *Arch Ophthalmol* 82:349-350, 1969.
- Wright KW, McVey JH: Conjunctival retraction suture for fornix adjustable strabismus surgery. *Arch Ophthalmol* 109(1):138-141, 1991.

Chapter 7

- Abraham SV, Silverman JJ: A new weakening operation for strabismus: progress report. *J Pediatr Ophthalmol Strabismus* 16:55-61, Jan./Feb. 1979.
- Call NB, Apt L: Inferior oblique muscle recession. *Am J Ophthalmol* 85:95-100, Jan.-Jun 1978.
- Chamberlain W: The single medial rectus recession operation. *J Pediatr Ophthalmol* 7(4):208-211, 1970.
- Folk ER, Mittelman D: The surgical treatment of undercorrected esotropia: an evaluation of the effect of recession of the medial rectus muscle 13.5 mm from the limbus. *Trans Am Acad Ophthalmol Otolaryngol* 79:738-744, 1975.
- Freedman HL, Waltman DD, Patterson JH: Preservation of anterior ciliary vessels during strabismus surgery: a nonmicroscopic technique. *J Pediatr Ophthalmol Strabismus* 29(1):38-43, 1992.
- Friendly DS, Parelhoff ES, McKeown CA: Effect of severing the check ligaments and intermuscular membranes on medial rectus recessions in infantile esotropia. *Ophthalmology* 100:945, 1993.
- Helveston EM, Patterson JH, Ellis FD, Weber JC: En-bloc recession of the medial recti for concomitant esotropia. In: *Symposium on Strabismus*, *Trans New Orleans Acad Ophthalmol*. St. Louis, 1978, Mosby-Year Book, pp. 230.
- Klein RM, Muchnich RS, Roskind RH: Measured tendon lengthening. *Arch Ophthalmol* 92:309, Oct 1974.
- Kowal L: Tendon lengthening procedures (letter). *Aust NZ J Ophthalmol* 19(2):162-164, 1991.
- Kushner BJ: A surgical procedure to minimize lower eyelid retraction with inferior rectus recession. *Arch Ophthalmol* 110:1011, 1992.

- Lang RM, Pearce WG: Muscle recession with a suture loop in rabbits. *Can J Ophthalmol* 15:84-86, April 1980.
- Lee DA, Dyer JA: Bilateral medial rectus muscle recession and lateral rectus muscle resection in the treatment of congenital esotropia. *Am J Ophthalmol* 95:528-535, April 1983.
- Magoon E, Cruciger M, Jampolsky A: Dissociated vertical deviation: an asymmetric condition treated with large bilateral superior rectus recession. *J Pediatr Ophthalmol Strabismus* 19:152-156, May/June 1982.
- McKeown CA, Lamber HM, Shore JW: Preservation of the anterior ciliary vessels during extraocular muscle surgery. *Ophthalmology* 96:498, 1989.
- Metz HS, Schwartz C: The treatment of "A" and "V" pattern by monocular surgery. *Arch Ophthalmol* 95:251, Feb. 1977.
- Miller JE: Vertical recti transplantation in the A and V syndromes. *Arch Ophthalmol* 64:175-179, 1960.
- Nemet P, Stolovitch C: Biased resection of the medial recti: A new surgical approach to convergence insufficiency. *Bin Vis Strabismus Q* 5:213, 1990.
- Paque JT, Mumma JV: Vertical offsets of the horizontal recti. *J Pediatr Ophthalmol* 15:205-209, July/Aug. 1978.
- Peart DA, Moltano AC: Effectiveness and predictability of tendon lengthening procedures. *Aust NZ J Ophthalmol* 18(4):401-408, 1990.
- Potter WS III, Nelson LB, Handa JT: Hemihang-back recession: description of the technique and review of the literature. *Ophthalmic Surg* 21(10):711-715, 1990.
- Prieto-Diaz J: Correspondence: fate of the superior rectus in "Hang-Loose" suspension-recession operations. *Binoc Vision Q* 5 (I): 8-9, 1990.
- Pollard ZF, Manley D: Unilateral medial rectus recession for small angle esotropia. *Arch J Ophthalmol* 94:780, May 1976.
- Raab EL, Parks MM: Recession of the lateral recti. *Arch Ophthalmol* 93:584, Aug. 1975.
- Repka MX, Fishman PJ, Guyton DL: The site of reattachment of the extraocular muscles following hang-back recession. *J Pediatr Ophthalmol Strabismus* 27:286, 1990.
- Repka MX, Guyton DL: Comparison of hang back medial rectus recession with conventional recession. *Ophthalmology* 96:782, 1988.
- Spielmann A: The "oblique Kestenbaum" procedure revisited (sloped recessions of the recti). In: Lenk-Schafer M, ed.: *Orthoptic Horizons*. Trans Sixth International Orthoptic Congress, Harrogate, UK, 1987, p. 433.
- Vila-Coro AA: Vascular microdissection in strabismus surgery (published erratum appears in *Arch Ophthalmol* 1990 Oct; 108[10]:1407). *Arch Ophthalmol* 108(7):1034-1036, 1990.

Chapter 8

- Hamtil LW: A study of tucking extraocular muscles to correct strabismus. *Ann Ophthalmol* 15:136-137, Feb. 1983.
- Pacheco EM, Guyton DL, Repka MX: Changes in eyelid position accompanying vertical rectus muscle surgery and prevention of lower lid retraction with adjustable surgery. *J Pediatr Ophthalmol Strabismus* 29:265, 1992.
- Reinecke RD: The figure eight suture for eye surgery. *Ophthalmol Dig* 34:22-27, 1972.
- Shen IL: Lock suture for strabismus surgery. *Ophthalmic Surg* 13:117-118, Feb 1982.
- Repka MX, Fishman PJ, Guyton DL: The site of reattachment of the extraocular muscle following hang-back recession. *J Pediatr Ophthalmol Strabismus* 27(6):286-290, 1990.

Chapter 9

- Anderson LS, German CJ, Luton JP: Superior oblique strengthening procedures in hypertropia I and II. *J Pediatr Ophthalmol Strabismus* 16:43-48, Jan/Feb 1979.
- Berke RN: Tenotomy of the superior oblique for hypertropia. *Trans Am Ophthalmol Soc* 44:304-342, 1946.
- Brown HW: Congenital structural muscle anomalies. In Allen JH, editor: *Strabismus ophthalmic symposium I*. St Louis, 1950, Mosby, pp 205-236.
- Brown HW: True and simulated superior oblique tendon sheath syndromes. *Aust J Ophthalm* 2(1):12-19, 1974.
- Buckley EG, Flynn JT: Superior oblique recession versus tenotomy: A comparison of surgical results. *J Pediatr Ophthalmol Strabismus* 20:112, 1983.
- Byung-Moo M, Ju-Hee P, Seung-Young K, Seong-Bok L: Comparison of inferior oblique muscle weakening by anterior transposition or myectomy: A prospective study of 20 cases. *Br J Ophthalmol* 83:206, 1999.
- Caldeira JA: Graduated recession of the superior oblique muscle. *Br J Ophthalmol* 59:553-559, 1975.
- Caldeira JA: Bilateral recession of the superior oblique in "A" pattern tropia. *J Pediatr Ophthalmol* 15:306-311, Sept/Oct 1978.
- Cooper EL, Sandall GS: Recession versus free myotomy at the insertion of the inferior oblique muscle. Comparative analysis of the surgical correction of overaction of the inferior oblique. *J Pediatr Ophthalmol Strabismus* 6:6, 1969.
- Crawford JS: Surgical treatment of true Brown's syndrome. *Am J Ophthalmol* 82:289-295, July-Dec. 1976.
- Crawford JS, Orton RB, Labow-Daily L: Late results of superior oblique muscle tenotomy in true Brown's syndrome. *Am J Ophthalmol* 89:824-829, Jan-June 1980.

- Diamond GR, Parks MM: The effect of superior oblique weakening procedures on primary position horizontal alignment. *J Pediatr Ophthalmol Strabismus* 18:35-38, Jan/Feb 1981.
- Diorio PC, et al: The effect of bilateral superior oblique tenotomy on horizontal deviation in A-pattern strabismus. *J Pediatr Ophthalmol Strabismus* 17:364-371, Nov/Dec 1980.
- Drummond GT, Pearce WG, Astle WF: Recession of the superior oblique tendon in A-pattern strabismus. *Can J Ophthalmol* 25(6): 301-305, 1990.
- Dyer JA: Tenotomy of the inferior oblique muscle at its scleral insertion. *Arch Ophthalmol* 68:176-181, 1962.
- Edwards WC, Hess JB: Inferior oblique surgery. *Ann Ophthalmol* 14:831-834, Sept 1982.
- Elliott RL, Nankin SJ: Anterior transposition of the inferior oblique. *J Pediatr Ophthalmol Strabismus* 18:35-38, May/June 1981.
- Flynn JT, Buckley EG: Superior oblique recession versus tenotomy: A comparison of surgical results. *J Pediatr Ophthalmol Strabismus* 20(3):112-117, 1983.
- Girard LM: Pseudoparalysis of the inferior oblique muscle. *South Med J* 49:342-346, 1956.
- Goldstein IG: Temporal approach to superior oblique surgery. *Arch Ophthalmol* 92:227, Sept 1974.
- Goldstein JH: Modification of temporal approach to superior oblique tenotomy. *J Pediatr Ophthalmol Strabismus* 17:108, March/April 1980.
- Gonzalez C: Denervation of the inferior oblique: current status and long-term results. *Trans Am Acad Ophthalmol* 81:899-906, 1970.
- Gonzalez C, Klein B: Myectomy and anterior transposition of the inferior oblique muscle: A new surgical procedure and its results in 49 operations. *Bin Vis Strabismus Q* 8:249, 1993.
- Hardesty, HH: Superior oblique tenotomy. *Arch Ophthalmol* 88(2): 181-184, 1972.
- Harada M, Ito Y: Surgical correction of cyclotropia. *Jpn J Ophthalmol* 8:88, 1964.
- Helveston EM, Birchler C: Class VII superior oblique palsy: subclassification and treatment suggestions. *Am Orthopt J* 32:104-111, 1982.
- Helveston EM: Giangiamoco JG, Ellis FD: Congenital absence of the superior oblique tendon. *Trans Am Ophthalmol Soc* 79:123, 1981.
- Jampolsky A: Vertical strabismus surgery. In *Transactions of the New Orleans Academy of Ophthalmology: Symposium on strabismus*. St Louis, 1971, Mosby, pp 366-385.
- McLean JM: Direct surgery of underacting oblique muscles. *Trans Am Ophthalmol Soc* 46:633-651, 1948.
- Mims JL, Woods RC: Bilateral anterior transposition of the inferior oblique muscles. *Arch Ophthalmol* 107:41, 1989.
- Mullough DH, Strominger MB: Comparison of anterior transposition and recession of the inferior oblique muscle in unilateral superior oblique paresis. *Am Assoc Pediatr Ophthalmol Strabismus* 2:340, 1998.
- Mulvihill A, Murphy M, Lew JP: Disinsertion of the inferior oblique muscle for treatment of superior oblique paresis. *J Pediatr Ophthalmol Strabismus* 37:279, 2000.
- Mumma JV: Surgical procedure for congenital absence of the superior oblique. *Arch Ophthalmol* 92:Sept 1974.
- Parks MM: The overacting inferior oblique muscle. *Am J Ophthalmol* 77:787, 1974.
- Parks MM: The weakening surgical procedures for eliminating overaction of the inferior oblique muscle. *Am J Ophthalmol* 73(1):107-122, 1972.
- Parks MM, Brown M: Superior oblique tendon sheath syndrome of Brown. *Am J Ophthalmol* 79:82-86, Jan-June 1975.
- Parks MM, Helveston EM: Direct visualization of the superior oblique tendon. *Arch Ophthalmol* 84:491-494, 1970.
- Pollard ZF: Superior oblique tenectomy in A pattern strabismus. *Ann Ophthalmol* 10:211-215, Feb 1978.
- Pollard ZF, Greenberg MF: Results and complications in 66 cases using a silicone tendon expander on overacting superior obliques with A pattern anisotropias. *Bin Vis Strabismus Q* 15:113, 2000.
- Prieto-Diaz J: Posterior tenectomy of the superior oblique. *J Pediatr Ophthalmol* 16:321-323, Sept/Oct 1979.
- Romano P, Roholt P: Measured graduated recession of the superior oblique muscle. *20:134-140, July/Aug 1983.*
- Scott AB, Knapp PK: Surgical treatment of superior oblique tendon sheath syndrome. *Arch Ophthalmol* 88(3):282-286, 1972.
- Scott WE, et al: Superior oblique tenotomy, indications and complications. In Ellis FD, Helveston EM, editors: *Strabismus surgery*. Boston, 1976, Little, Brown.
- Seawright AA, Gole GA: Results of treatment of superior oblique overaction by silicone tendon-expander techniques. *J Pediatr Ophthalmol Strabismus* 35:33, 1998.
- Selm JL: Superior oblique plication in the management of infantile onset convergent squint. *J Ocular Ther Surg* 209-211, July-Aug 1983.
- Shin GS, Elliott RL, Rosenbaum AL: Posterior superior oblique tenotomy at the scleral insertion for collapse of A-pattern strabismus. *J Pediatr Ophthalmol Strabismus* 33:211, 1996.
- Sousa-Dias C, Vesugui CF: Effects of different techniques of superior oblique weakening in correction of "A" esotropia. *J Pediatr Ophthalmol Strabismus* 23:82-86, 1986.

- Stager DR, Parks MM: Inferior oblique weakening procedures. Effect on primary position horizontal alignment. *Arch Ophthalmol* 90:15, 1973.
- Stager DR, Parks MM, Stager DR Jr, Pesheva M: Long-term results of silicone expander for moderate and severe Brown syndrome (Brown syndrome "plus"). *J Am Assoc Pediatr Ophthalmol Strabismus* 3:328, 1999.
- Stager DR, Weakley DR, Stager D: Anterior transposition of the inferior oblique - anatomic assessment of the neurovascular bundle. *Arch Ophthalmol* 110:360, 1992.
- Stark N, Fries U: Tenotomy of the superior oblique muscle in treatment of A-pattern strabismus and Brown syndrome. *Klin Monatsbl Augenheilkd* 199(5):337-343, 1991.
- Stein LA, Ellis FJ: Apparent contralateral inferior oblique muscle overaction after unilateral inferior oblique muscle weakening procedures. *J Am Assoc Pediatr Ophthalmol Strabismus* 1:2, 1997.
- Toosi SH, von Noorden GK: Effect of isolated inferior oblique muscle myectomy in the management of superior oblique muscle palsy. *Am J Ophthalmol* 88:602-608, July-Dec 1979.
- Vempali YMR, Lee JP: Results of superior oblique posterior tenotomy. *J Am Assoc Pediatr Ophthalmol Strabismus* 2:147, 1998.
- Wesson M: Fourteen patients with bilateral superior oblique defect and convergence excess corrected by sagittalization. *Aust Orthopt J* 18:23-25, 1980-1981.
- Wilson ME, Sinatra AB, Saunders RA: Downgaze restriction after placement of the superior tendon spacer for Brown syndrome. *J Pediatr Ophthalmol Strabismus* 32:29, 1995.
- Wright K: Superior oblique silicone expander for Brown's syndrome and superior oblique overaction. *J Pediatr Ophthalmol Strabismus* 28:101, 1991.
- Wright KW, Min BM, Park C: Comparison of superior oblique tendon expander to superior oblique tenotomy. *J Pediatr Ophthalmol Strabismus* 29(2):92-97, 1992.

Chapter 10

- de Faber JT, von Noorden GK: Medial rectus muscle marginal myotomies for persistent esotropia. *Am J Ophthalmol* 112(6):702-705, 1991.
- Helveston EM, Cofield DD: Indications for marginal myotomy and technique. *Am J Ophthalmol* 70:574-578, 1970.
- Kroczek SE, Heyde EL, Helveston EM: Quantifying the marginal myotomy. *Am J Ophthalmol* 70:204-209, 1970.
- Romero-Apis D, Martinez-Oropeza S: Strabismus surgery by means of marginal myotomy combined with lineal tucking. *Am Orthopt J* 33:74-77, 1983.

- von Noorden GK: An alternative to marginal myotomy. *Am J Ophthalmol* 94:285, 1982.
- Yim Bin Hye, Biglan A, Cronin TH: Graded partial tenotomy of the vertical rectus muscles for treatment of hypertropia. *Trans Amer Ophthalmol Soc*, Vol. 102, 2004.
- Zak TA, Morin JD: Surgery of infantile esotropia: a critical evaluation of marginal myotomy of the medial recti as a primary and secondary procedure. *J Pediatr Ophthalmol Strabismus* 20(2):52-57, 1983.

Chapter 11

- Buckley EG: Faden operation (posterior fixation suture). In: Rosenbaum AL, Santiago AP, eds., Chapter 37, Clinical strabismus management: Principles and surgical techniques. Philadelphia, 1999, WB Saunders Co, pp. 491-505.
- Buckley EG, Meekins BB: Faden operation for the management of complicated incomitant vertical strabismus. *Am J Ophthalmol* 105:304-312, 1988.
- Clark RA, Isenberg SJ, Rosenbaum AL, Demer JL: Posterior fixation sutures: A revised mechanical explanation for the faden operation based on rectus extraocular muscle pulleys. *Am J Ophthalmol* 128:702, 1999.
- Cuppers C: The so-called "faden operation" (surgical correction by well-defined changes in the arc of contact). In Fells P, editor: Second Congress of the International Strabismological Association. Marseilles, 1976, Diffusion Generale de Librairie, pp 395-400.
- Klainguti G, Chamero J, Deller M: Short- and intermediate-term angular results of Cuppers retro-equatorial myopexy, with or without additional simultaneous recession. *Klin Monatsbl Augenheilkd* 198(5):382-385, 1991.
- Kushner BJ: Evaluation of the posterior fixation suture plus recession operation with saccadic velocities. *J Pediatr Ophthalmol Strabismus* 20(5):202, 1983.
- Leitch RJ, Burke JP, Strachan IM: Convergence excess esotropia treated surgically with faden operation and medial rectus muscle recessions. *Br J Ophthalmol* 74(5):278-279, 1990.
- Muhlendych H: Diagnosis of convergent strabismus with nystagmus and its treatment with Cuppers faden operation. In Moore S, Mein J, Stockbridge L, editors: Orthoptics: past, present, future. Miami, 1976, Symposium Specialists, pp 143-154.
- Paliaga GP, Braga M: Passive limitation of adduction after Cupper's "Faden operation" on medial recti. *Br J Ophthalmol* 73:633, 1989.
- Schuckett EP, et al: Posterior fixation suture operation (faden operation). *Ophthalmic Surg* 12:578-584, 1981.
- Scott AB: The faden operation: mechanical effects. *Am Orthopt J* 27:44-47, 1977.

- Scott AB: Posterior fixation: Adjustable and without posterior sutures. In: Lennerstrand G, ed: Update on strabismus and pediatric ophthalmology. Boca Raton, FL, 194, CRC Press, p. 399.
- Sprague JB: Dissociated vertical deviation. *Arch Ophthalmol* 98:465-468, 1980.
- von Noorden GK: Indications of the posterior fixation operation in strabismus. *Ophthalmology* 85:512-520, 1978.
- von Noorden GK: An alternative to marginal myotomy. *Am J Ophthalmol* 94(3):285-289, 1982.
- von Noorden GK: Posterior fixation suture in strabismus surgery. In: Symposium on strabismus. *Trans New Orleans Acad Ophthalmol*. St. Louis, 1978, Mosby-Year Book, p. 307.
- ## Chapter 12
- Jampolsky A: Adjustable strabismus surgical procedures. In: Symposium on strabismus. *Trans New Orleans Acad Ophthalmol*. St. Louis, 1978, osby-Year Book, p. 321.
- Knapp P: The increased certainty and the increased correction of the bare sclera closure with bimedial recession. In: Moore S, Mein J, Stockbridge L, eds. *Orthoptics: Past, present, future*. *Trans Third International Orthoptic Congress*. New York, 1976, Stratton Intercontinental.
- Kraft SP, Jacobson ME: Techniques of adjustable suture strabismus surgery. *Ophthalmic Surg* 21(9):633-640, 1990.
- Kushner BJ, Gloeckner E, Larson C: A technique for measuring adjustable suture recessions. *J Ocular Ther Surg* 283, 1983.
- Rosenbaum AL: Adjustable vertical rectus muscle transposition surgery. *Arch Ophthalmol* 109:1346-1352, 1991.
- Weston B, Enzenauer RW, Kraft SP, Gayowsky GR: Stability of the postoperative alignment in adjustable-suture strabismus surgery. *J Pediatr Ophthalmol Strabismus* 28(4):206-211, 1991.
- Wisnicki HJ, Repka MX, Guyton DC: Reoperation rate in adjustable strabismus surgery. *J Pediatr Ophthalmol Strabismus* 25(3):112-114, 1988.
- ## Chapter 13
- Bicas HE: A surgical implanted elastic band to restore paralyzed ocular rotations. *J Pediatr Ophthalmol Strabismus* 28(1):10-13, 1991.
- Buckley EG, Townshend LM: A simple transposition procedure for complicated strabismus. *Am J Ophthalmol* 111(3):302-306, 1991.
- Buncic JR: Sixth nerve palsy. In: Good WV, Hoyt CS, eds. *Strabismus Management*. Boston, 1996, Butterworth-Heinemann, pp. 271-276.
- Burke JP, Ruben JB, Scott WE: Vertical transposition of the horizontal recti (Knapp procedure) for the treatment of double elevator palsy: effectiveness and long term stability. *Br J Ophthalmol* 76:734-737, 1992.
- Conrad HG, de Decker W: Torsional Kestenbaum procedure: Evolution of a surgical concept. In: Reinecke RD, ed. *Strabismus II*. Orlando, FL, 1984, Grune & Stratton, p. 301.
- Diamond GR: True transposition procedures. *J Pediatr Ophthalmol Strabismus* 27(3):153-156, 1990.
- Fells P: Management of paralytic strabismus. *Br J Ophthalmol* 58:255, 1974.
- Fells P: Vertical rectus muscle transplantation to restore abduction. In: Mein J, Bierlaagh JJM, Brummelkamp-Dons TEA, eds, *Orthoptics: Proceedings of the Second International Orthoptic Congress*. Amsterdam, Excerpta Medica, 1972.
- Foster SR: Vertical muscle transposition augmented with lateral fixation. *J Am Assoc Pediatr Ophthalmol Strabismus* 1:20, 1997.
- Frueh BR, Henderson JW: Rectus muscle union in sixth nerve paralysis. *Arch Ophthalmol* 85:191, 1971.
- Gobin MH: Surgical management of Duane's syndrome. *Br J Ophthalmol* 58:301-306, 1974.
- Goldstein JH: Modification of the Jensen procedure. *J Pediatr Ophthalmol* 15:321-322, Sept/Oct 1978.
- Helveston EM: Muscle transposition procedures. *Surv Ophthalmol* 16(2):92-97, 1972.
- Hiatt RL: Extraocular muscle transplantation. *J Pediatr Ophthalmol* 14:79-92, Mar/Apr 1977.
- Jensen CDF: Rectus muscle union: a new operation for paralysis of the rectus muscles. *Trans Pac Coast Otoophthalmol Soc* 45:359-384, 1964.
- Metz HS: Muscle transposition surgery (20th Annual Frank Costenbader Lecture). *J Pediatr Ophthalmol Strabismus* 30:346, 1993.
- Metz HS: Rectus muscle transposition surgery. *J Pediatr Ophthalmol Strabismus* 18:51-54, Nov/Dec 1981.
- Metz HS: The use of vertical offsets with horizontal strabismus surgery. *Ophthalmology* 95:1094, 1988.
- Scott AB, Miller JM, Collins CC: Eye muscle prosthesis. *J Pediatr Ophthalmol Strabismus* 29(4):216-218, 1992.
- Scott WE: Vertical rectus muscle transposition surgery modified (letter). *Arch Ophthalmol* 109(10):1345-1346, 1991.
- Selezinka W, Sandall GS, Henderson JW: Rectus muscle union in sixth nerve paralysis, Jensen rectus muscle union. *Arch Ophthalmol* 92:882, 1974.
- von Noorden GK, Jenkins RH, Rosenbaum AL: Horizontal transposition of the vertical rectus muscles for treatment of ocular torticollis. *J Pediatr Ophthalmol Strabismus* 30:8, 1993.

Zehl DN, Snell AC: Extraocular muscle surgery in the presence of complete paralysis of the fifth, sixth and seventh cranial nerves. *J Pediatr Ophthalmol* 14:76-78, Mar/Apr 1977.

Chapter 14

Abbasoglu OE, Sener EC, Sanac AS: Factors influencing success and dose-effect relation of botulinum A treatment. *Eye* 10:385, 1996.

Acheson JF, Bentley CR, Shallo-Hoffmann J, Gresty MA: Dissociated effects of botulinum toxin chemodenervation on ocular deviation and saccade dynamics in chronic lateral rectus palsy. *Br J Ophthalmol* 82:67, 1998.

Ad Hoc Committee on Ophthalmic Procedures: Botulinum toxin therapy of eye muscle disorders. American Academy of Ophthalmology Instrument and Book Issue, 1989, pp 37-41.

Balkan RJ, Poole T: A five-year analysis of botulinum toxin type A injections: some unusual features. *Ann Ophthalmol* 23:326-333, 1991.

Biglan AW, et al: Management of strabismus with botulinum A toxin. *Ophthalmology* 96(7):935-943, 1989.

Campos EC: New indications for botulinum toxin A in strabismus and in medical treatment of amblyopia. Editorial review. *Curr Opin Ophthalmol* 4:34, 1992.

Campos EC: Pharmacological treatment of strabismus. In: Lennerstrand G, Ygge J, eds. *Advances in strabismus research: Basic and clinical aspects*. Wnner Gren International Series. London, Portland Press 78:167, 2000.

Campos EC, Schiavi C, Scorolli L: Botulinum toxin A in essential infantile esotropia. In: Louly N, ed. *Trans of the Eighth International Orthoptic Congress*. Kyoto, Japan, 1995, p. 229.

Carruthers JDA: Ophthalmic use of botulinum A toxin. *Can J Ophthalmol* 20:135-141, 1985.

Carruthers JDA, Kennedy RA, Bargaric D: Botulinum vs adjustable sutures in the treatment of horizontal misalignment in adult patients lacking fusion. *Arch Ophthalmol* 108:1432-1435, 1990.

Dawson EL, Marshman WE, Adams GGW: The role of botulinum toxin A in acute-onset esotropia. *Ophthalmology* 106:1727, 1999.

Dennehy PJ: *Succinylcholine-stimulated muscle tensions following botulinum injection in the domestic cat*. New York, 1991, Academic Press, pp 445-449.

Dunlop D, Pittar G, Dunlop C: Botulinum toxin in ophthalmology. *Aust NZ J Ophthalmol* 16:15-20, 1988.

Flynn JT, Bachynski B: Botulinum toxin injections in strabismus. *Trans New Orleans Acad Ophthalmol*, 1986, pp 526-536.

Hakin KN, Lee JP: Binocular diplopia in unilateral aphakia: the role of botulinum toxin. *Eye* 5:447-450, 1991.

Helveston EM, Pogrebniak AE: Treatment of acquired nystagmus with botulinum A toxin. *Am J Ophthalmol* 106:584, 1988.

Hoffman RO, Archer SM, Zirkerlbach SL, Helveston EM: The effect of intravitreal botulinum toxin on rabbit visual evoked potential. *Ophthalmic Surg* 18:118-119, 1987.

Hoffman RO, Helveston EM: Botulinum in the treatment of adult motility disorders. *IOC* 26(4):241-250, 1986.

Ing MR: Botulinum alignment for congenital esotropia. *Ophthalmology* 100:318, 1993.

Kowal L: Botulinum toxin (letter). *Aust NZ J Ophthalmol* 16:264, 1988.

Lee J, et al: Botulinum toxin therapy for squint. *Eye* 2:24-28, 1988.

Lee JP, Harris S, Cohen J, et al: Results of a prospective randomised trial of botulinum toxin therapy in acute sixth nerve palsy. *J Pediatr Ophthalmol Strabismus* 31:283, 1994.

Lee JP, Page B, Lipton J: Treatment of strabismus after retinal detachment surgery with botulinum neurotoxin A. *Eye* 5:451-455, 1991.

Lyons CJ, Vickers SF, Lee JP: Botulinum toxin therapy in dysthyroid strabismus. *Eye* 4:538-540, 1990.

Magoon EH: Chemodenervation of strabismic children. *Ophthalmology* 96(7):931-934, 1989.

Magoon E, Scott AB: Botulinum toxin chemodenervation in infants and children: an alternative to incisional surgery. *J Pediatr* 10(5):719-722, 1987.

McNeer KW: Botulinum toxin injection into the superior rectus muscle of the nondominant eye in dissociated vertical deviation. *J Pediatr Ophthalmol Strabismus* 26(4): 162-164, 1989.

McNeer KW: An investigation of the clinical use of botulinum A toxin. *J Pediatr Ophthalmol Strabismus* 27(1):3-9, 1990.

McNeer KW, Spencer RF, Tucker MG: Observations on bilateral simultaneous botulinum toxin injection in infantile esotropia. *J Pediatr Ophthalmol Strabismus* 31:214, 1994.

McNeer KW, Tucker MG, Spencer RF: Botulinum toxin management of essential infantile esotropia in children. *Arch Ophthalmol* 115:1411, 1997.

Metz HS, Mazow M: Botulinum treatment for acute sixth and third nerve palsy. *Graefes Arch Clin Exp Ophthalmol* 226:141-144, 1988.

Perman KI, Baylis HI, Rosenbaum AL, et al: The use of botulinum toxin in the medical management of benign essential blepharospasm. *Ophthalmology* 93:1-3, 1986.

Pittar G, Dunlop DB, Dunlop C: Who needs botulinum toxin? *Med J Aust* 149:265-266, 1988.

- Rayner SA, Hollick EJ, Lee JP: Botulinum toxin in childhood strabismus. *Strabismus* 7:103, 1999.
- Renier S, Magoon EH: The role of the office nurse in botulinum injection as an alternative to strabismus surgery. *J Ophthalmic Nursing Technol* 9:138-140, 1990.
- Ruben ST, Lee JP, O'Neill D, et al: The use of botulinum toxin for treatment of acquired nystagmus and oscillopsia. *Ophthalmology* 101:783, 1994.
- Schiavi C, Benedetti P, Campos EC: Botulinum toxin in essential infantile esotropia and in Lang's normosensorial strabismus. In: Kaufmann H, ed. *Trans 20th Meeting European Strabismological Assoc. Brussels, 1992*, p. 179.
- Schiavi C, Scorolli L, Campos EC: Long term follow-up of botulinum toxin treatment in essential infantile esotropia and in late-onset normosensorial esotropia. In: Spiritus M, ed. *Trans 22nd Meeting European Strabismological Assoc. Cambridge, UK, The Hague, Aeolus Press, 1995*, p. 159.
- Scott AB: Antitoxin reduces botulinum side effects. *Eye* 2:29-32, 1988.
- Scott AB: Botulinum injection treatment of congenital esotropia. In: Lenk-Schaefer M, ed. *Trans 6th International Orthoptic Congress. Harrogate, UK, 1987*, p. 294.
- Scott AB: Botulinum injection treatment for endocrine orbital myopathy. *Doc Ophthalmol* 58:141, 1984.
- Scott AB: Botulinum toxin A injections in the treatment of strabismus. In Wolff S, editor: *Questions and answers. Arch Ophthalmol* 109:1510, 991.
- Scott AB: Botulinum toxin injection into extraocular muscles as an alternative to strabismus surgery. *Ophthalmol* 87:1044, 1980.
- Scott AB: Botulinum toxin injection of eye muscles to correct strabismus. *Trans Am Ophthalmol Soc* 79:734, 1981.
- Scott AB: Botulinum toxin treatment of strabismus and blepharospasm: a multiple investigator study. In Campos E, editor: *Proceedings of the fifth meeting of the International Strabismological Association. Modena, Italy, Scientific Distributors, 1986*, pp 483-485.
- Scott AB: Botulinum treatment of strabismus following retinal detachment surgery. *Arch Ophthalmol* 108:509-510, 1990.
- Scott AB, et al: Botulinum treatment of childhood strabismus. *Ophthalmology* 97(11):1434-1438, 1990.
- Scott AB, et al: Botulinum treatment of children. *Trans Am Ophthalmol Soc* 87:174-183, 1989.
- Scott AB, et al: Diagnostic injection of xylocaine into extraocular muscles. *Ophthalmology* 89:489-491, 1982.
- Scott AB, Kraft SP: Botulinum toxin injection in the management of lateral rectus paresis. *Ophthalmology* 92:676, 1985.
- Scott AB, Magoon E, Stager D, McNeer K: Botulinum treatment of strabismus in children. *Trans Am Ophthalmol Soc* 87:1, 1989.
- Scott AB, Rosenbaum AL, Collins CC: Pharmacologic weakening of extraocular muscles. *Invest Ophthalmol* 12:924, 1973.
- Siatowski RM, Tyutyunikov A, Biglan AW: Serum antibody production to botulinum A toxin. *Ophthalmology* 100:1861, 1993.
- Spencer RF, McNeer KW: Botulinum toxin paralysis of adult monkey extraocular muscle. Structural alterations in orbital, singly innervated muscle fibers. *Arch Ophthalmol* 105:1703, 1987.
- Tsoy EA, Buckley EG, Dutton JJ: Treatment of blepharospasm with botulinum toxins. *Am J Ophthalmol* 99:176, 1985.
- Weinkers IC, Helveston EM, Ellis FD, Cadera W: Botulinum injection into the rabbit vitreous. *Ophthalmic Surg* 15(4):310-314, 1984.

Chapter 15 and 16

- Arnoult JB, Yeshurun O, Mazow ML: Comparative study of the surgical management of congenital esotropia of 50 diopters or less. *J Pediatr Ophthalmol* 13:129-131, May 1976.
- Aylward GW, Lawson J, McCarry B, et al: The surgical treatment of traumatic brown syndrome. *J Pediatr Ophthalmol Strabismus* 29(5):265-272, 1992.
- Biedner B, Yassur Y, David R: Medial rectus re-recession in undercorrected esotropia. *J Pediatr Ophthalmol Strabismus* 29(2):89-91, 1992.
- Capo H, Guyton DL: Ipsilateral hypertropia after cataract surgery. *Ophthalmology* 103:721-730, 1996.
- Christmann LM, Wilson ME: Motility disturbances after Molteno implants. *J Pediatr Ophthalmol Strabismus* 29:44-48, 1992.
- Cooper EL: The surgical management of secondary exotropia. *Trans Am Acad Ophthalmol Otolaryngol* 65:595-608, 1961.
- Cruz OA: Restricted motility for vertical strabismus in Graves' ophthalmopathy. *Ophthalmology* 108:242-243, 2001.
- de Faber JT, von Noorden GK: Inferior rectus muscle palsy after retrobulbar anesthesia for cataract surgery. *Am J Ophthalmol* 112:209-211, 1991.
- de Molina AC, Munoz LG: Brown syndrome associated with contralateral superior oblique palsy: a case report. *J Pediatr Ophthalmol Strabismus* 28:310-313, 1991.
- de Molina AC, Munoz LG: Ocular alignment under general anesthesia in congenital esotropia. *J Pediatr Ophthalmol Strabismus* 28(5):278-282, 1991.
- Delisle P, Strasfeld M, Pelletier D: The prism adaptation test in the preoperative evaluation of esodeviations. *Can J Ophthalmol* 23(5):208-212, 1988.

- Deutsch JA, Nelson LB, Sheppard RW, Burke MJ: Unilateral lateral rectus recession for the treatment of exotropia. *Ann Ophthalmol* 24(3):111-113, 1992.
- Edwards WC, Hess JB: Surgical correction of small-angle esotropia. Part I. *J Ocular Ther Surg* pp 279-282, Nov-Dec 1983.
- Elsas FJ: Occult Duane syndrome: co-contraction revealed following strabismus surgery. *J Pediatr Ophthalmol Strabismus* 28(6):328-332, 1991.
- Enke ES, Stewart SA, Scott WE, et al: The prevalence of dissociated horizontal deviations in congenital esotropia. *Am Orthopt J* 44:109-111, 1994.
- Enright JT: Unexpected role of the oblique muscles in human vertical fusional reflex. *J Physiol* 451:279-293, 1992.
- Esswein MB, von Noorden GK, Coburn A: Comparison of surgical methods in the treatment of dissociated vertical deviation. *Am J Ophthalmol* 113(3):287-290, 1992.
- Farr AK, Guyton DL: Strabismus after retinal detachment surgery. *Curr Opin Ophthalmol* 11:207-210, 2000.
- Fellows R, et al: Strabismus surgery and its effect upon infant development in congenital esotropia. *Ophthalmology* 89:479-483, Jan.-June 1982.
- Fells P: Management of paralytic strabismus. *Br J Ophthalmol* 58:255-265, 1974.
- Feretis D, Mela E, Vasilopoulos G: Excessive single lateral rectus muscle recession in the treatment of intermittent exotropia. *J Pediatr Ophthalmol Strabismus* 27(6):315-316, 1990.
- Forster RC, Paul OT, Jampolsky A: Infantile esotropia. *Am J Ophthalmol* 82(2):291-299, 1976.
- Frankel CA, Juengst ET: Cosmetic surgery for a fatally ill infant. *J Pediatr Ophthalmol Strabismus* 28(5):250-254, 1991.
- Gardner TA, Kennerdell JS: Treatment of dysthyroid myopathy with adjustable suture recession. *Ophthalmic Surg* 21(7):519-521, 1990.
- Giangiaco J: Efficacy of prism adaptation in the surgical management of acquired esotropia (letter). *Arch Ophthalmol* 109(6):765, 1991.
- Goldstein, JH, Freeman J: Management of large angle exotropia. *Ann Ophthalmol* 10:1739-1744, Dec. 1978.
- Goldstein JH, Sacks DB: Bilateral Duane's syndrome. *J Pediatr Ophthalmol* 14:12-17 Jan/Feb 1977.
- Guyton DL: Dissociated vertical deviation: etiology, mechanism, and associated phenomena. *J Am Assoc Pediatr Ophthalmol Strabismus* 4:131-144, 2000.
- Guyton DL, Cheeseman EW Jr, Ellis FJ, et al: Dissociated vertical deviation: an exaggerated normal eye movement used to damp cyclovertical latent nystagmus. *Trans Am Ophthalmol Soc* 96:389-424, discussion 424-429.
- Hamed LM: Bilateral Brown syndrome in three siblings. *J Pediatr Ophthalmol Strabismus* 28:306-309, 1991.
- Hamed LM, Lingua RW: Thyroid eye disease presenting after cataract surgery. *J Pediatr Ophthalmol Strabismus* 27(1):10-15, 1990.
- Hamed LM, Silbiger J: Periodic alternating esotropia. *J Pediatr Ophthalmol Strabismus* 29(4):240-242, 1992.
- Hardesty HH: Treatment of intermittent exotropia. *Arch Ophthalmol* 96:268-274, 1978.
- Hardesty HH: Management of intermittent exotropia. *Binoc Vision Q* 5(3):145-152, 1990.
- Helveston EM: "A" exotropia, bilateral overaction of the superior obliques and alternating sursumduction. *Am J Ophthalmol* 67:377-380, 1969.
- Helveston EM: Dissociated vertical deviation—a clinical and laboratory study. *Trans Am Ophthalmol Soc* 78:734-779, 1981.
- Helveston EM: The value of strabismus surgery. *Ophthalmic Surg* 21(5):311-317, 1991.
- Helveston EM, Ellis ED, Plager DA: A new classification of superior oblique palsy based on congenital variations in the tendon. *Ophthalmology* 99(10): 1609-1615, 1992.
- Helveston, EM, Ellis ED, Plager DA: Large recession of the horizontal recti for treatment of nystagmus. *Ophthalmology* 98(8): 1302-1305, 1991.
- Helveston EM, Ellis ED, Plager DA, Miller KK: Early surgery for essential infantile esotropia. *J Pediatr Ophthalmol Strabismus* 27(3):115-118, 119, 1990.
- Helveston EM, Grossman RD: Extraocular muscle lacerations. *Am J Ophthalmol* 81(6): 300-302, 1976.
- Hertle RW, Maldonado VK, Maybodi M, et al: Clinical and ocular motor analysis of the infantile nystagmus syndrome in the first 6 months of life. *Br J Ophthalmol* 86:670-675, 2002.
- Hess JB, Calhoun JH: A new rationale for the management of large angle esotropia. *J Pediatr Ophthalmol Strabismus* 16:345-348, 1979.
- Hiles DA, Davies GT, Costenbader ED: Long-term observations on unoperated intermittent exotropia. *Arch Ophthalmol* 80:436-442, 1968.
- Holbach HT, von Noorden GK, Avilla CW: Changes in esotropia after occlusion therapy in patients with strabismic amblyopia. *J Pediatr Ophthalmol Strabismus* 28(1):6-9, 1991.
- Holmes JM, Cronin CM: Duane syndrome associated with oculocutaneous albinism. *J Pediatr Ophthalmol Strabismus* 28(1):32-34, 1991.
- Hunter LR, Parks MM: Response of coexisting underacting superior oblique and overacting inferior oblique muscles to inferior oblique weakening. *J Pediatr Ophthalmol Strabismus* 27(2):74-79, 1990.

- Ing MR: Early surgical alignment for congenital esotropia. *Ophthalmology* 90(2):132-135, 1983.
- Jaafar MS, Traboulsi EI: Congenital fibrosis of the extraocular muscles. In: Rosenbaum AL, Santiago AP, eds. *Clinical strabismus management: Principles and surgical techniques*. Philadelphia, 1999, WB Saunders Co, pp. 363-370.
- Jampolsky A, von Noorden GK, Spiritus M: Unnecessary surgery in cases of fully accommodative esotropia (letter). *J Fr Ophtalmol* 14(3):201-202, 1991.
- Jampolsky A, von Noorden GK, Spiritus M: Unnecessary surgery in fully refractive accommodative esotropia (letter). *Aust NZ J Ophthalmol* 19(4):370-373, 1991.
- Jampolsky A, von Noorden GK, Spiritus M: Unnecessary surgery in fully refractive accommodative esotropia. *Int Ophthalmol* 16(2):129-131, 1992.
- Keech RV, Stewart SA: The surgical overcorrection of intermittent exotropia. *J Pediatr Ophthalmol Strabismus* 27(4):218-220, 1990.
- Keenan JM, Willshaw HE: Outcome of strabismus surgery in congenital esotropia. *Br J Ophthalmol* 76(6): 342-345, 1992.
- Kirkali P, Topaloglu R, Kansu T, Bakkaloglu A: Third nerve palsy and internuclear ophthalmoplegia in periarteritis nodosa. *J Pediatr Ophthalmol Strabismus* 28(1):45-46, 1991.
- Kishore K, Kumar H: Congenital ocular fibrosis with musculoskeletal abnormality: a new association. *J Pediatr Ophthalmol Strabismus* 28(5):283-286, 1991.
- Knapp P: The surgical treatment of double-elevator paralysis. *Trans Am Ophthalmol Soc* 67:304-323, 1969.
- Kraft SP: Outcome criteria in strabismus surgery. *Can J Ophthalmol* 33:237, 1998.
- Kraft SP, Scott WE: Surgery for congenital esotropia—an age comparison study. *J Pediatr Ophthalmol Strabismus* 21(2):57, 1984.
- Kushner BJ: Paresis and restriction of the inferior rectus muscle after orbital floor fracture. *Am J Ophthalmol* 94:81-86, 1982.
- Kushner BJ, Morton GV: Postoperative binocularity in adults with longstanding strabismus. *Ophthalmology* 99(3):316-319, 1992.
- Kwitko S, Feldon S, McDonnell PJ: Corneal topographic changes following strabismus surgery in Graves' disease. *Cornea* 11 (1):36-40, 1992.
- Lee J: Surgical management of nystagmus. *J R Soc Med* 95:238-241, 2002.
- Legge RH, Hedges TR, Anderson M, Reese PD: Hypertropia following trochlear trauma. *J Pediatr Ophthalmol Strabismus* 29(3):163-166, 1992.
- Leigh RJ, Zee DS: *The neurology of eye movements*. Philadelphia, 1991, FA Davis.
- Lorenz B, Raab I, Boergen KP: Dissociated vertical deviation: what is the most effective surgical approach? *J Pediatr Ophthalmol Strabismus* 29(1):21-29, 1992.
- Ludwig IH, Parks MM, Getson PR: Long-term results of bifocal therapy for accommodative esotropia. *J Pediatr Ophthalmol Strabismus* 26:264-270, 1989.
- Magrann I, Schlossman A: Strabismus in patients over the age of 60 years. *J Pediatr Ophthalmol Strabismus* 28(1):28-31, 1991.
- Manley RD, Hughes RM: Surgical management of A pattern esotropia. *Ann Ophthalmol* 3(10):1067-1078, 1971.
- Manson DN, IliffN, Putterman AM: Management of blow-out fracture of the orbital floor. In Dutton JJ, editor: *Viewpoints*. *Surv Ophthalmol* 5(4):279-298, 1991.
- Mims JL III, Wood RC: Is prism adaptation helpful for children with acquired esotropia? (letter: comment). *Arch Ophthalmol*, 109(4):466-467, 1991.
- Mitchell PR, Parks MM: Surgery for bilateral superior oblique palsy. *Ophthalmology* 89:484-488, 1982.
- Molarte AB, Rosenbaum AL: Vertical rectus muscle transposition surgery for Duane's syndrome. *J Pediatr Ophthalmol Strabismus* 27(4):171-177, 1990.
- Molarte AB, Rosenbaum AL: Clinical characteristics and surgical treatment of intermittent esotropia. *J Pediatr Ophthalmol Strabismus* 28(3):137-142, 1991.
- O'Hara MA, Calhoun JH: Surgical correction of excess esotropia at near. *J Pediatr Ophthalmol Strabismus* 27(3): 120-125, 1990.
- Pratt-Johnson JA: The surgery of congenital nystagmus. *Can J Ophthalmol* 6(4):268-277, 1971.
- Prieto-Diaz, J: Large bilateral medial rectus recession in early esotropia with bilateral limitation of abduction. *J Pediatr Ophthalmol* 17(2):101-105, 1980.
- Procyanoy E, Justo DM: Results of unilateral medial rectus recession in high AC/A ratio esotropia. *J Pediatr Ophthalmol Strabismus* 28(4):212-214, 1991.
- Raab EL: Unilateral four-muscle surgery for large-angle exotropia. *Ophthalmology* 86:1441-1446, 1979.
- Raab EL: Outcome of deteriorated accommodative esotropia. *Trans Am Ophthalmol Soc* 87:185-196, 1990.
- Raab EL: The accommodative portion of mixed esotropia. *J Pediatr Ophthalmol Strabismus* 28(2):73-76, 1991.

- Repka MX: Nystagmus: clinical evaluation and surgical management. In: Rosenbaum AL, Santiago AP, eds. *Clinical strabismus management: Principles and surgical techniques*. Philadelphia, 1999, WB Saunders Co, pp. 404-420.
- Repka MX, Arnold KA: Lateral incomitance in exotropia: fact or artifact? *J Pediatr Ophthalmol Strabismus* 28(3):125-128, 1991.
- Repka MX, Savino PJ, Reinecke RD: Treatment of acquired nystagmus with botulinum neurotoxin A. *Arch Ophthalmol* 112:1320-1324, 1994.
- Repka MX, Wentworth D, Prism Adaptation Study Research Group: Predictors of prism response during prism adaptation. *J Pediatr Ophthalmol Strabismus* 28(4):202-205, 1991.
- Robb RM: Idiopathic superior oblique palsies in children. *J Pediatr Ophthalmol Strabismus* 27(2):66-69, 1990.
- Rubin SE, Slavin ML: Head nodding associated with intermittent esotropia. *J Pediatr Ophthalmol Strabismus* 27(5):250-251, 1990.
- Schwartz T, Scott W: Unilateral superior rectus recession for the treatment of dissociated vertical deviation. *J Pediatr Ophthalmol Strabismus* 28(4):219-222, 1991.
- Seaber JH, Buckley EG: Strabismus after retinal detachment surgery: etiology, diagnosis, and treatment. *Semin Ophthalmol* 10:61-73, 1995.
- Sharma P, Gupta NK, Arora R, Prakash P: Strabismus fixus convergens secondary to amyloidosis. *J Pediatr Ophthalmol Strabismus* 8(4):236-237, 1991.
- Shuey TF, Parks MM, Friendly DS: Results of combined surgery on the superior oblique and horizontal rectus muscles for A-pattern horizontal strabismus. *J Pediatr Ophthalmol Strabismus* 29(4):199-201, 1992.
- Small RG: Functional vs cosmetic ophthalmologic defects (letter). *Arch Ophthalmol* 109(9):1194-1195, 1991.
- Smoot CN, Simon JW, Nelson LB: Binocularity following surgery for secondary esotropia in childhood. *Br J Ophthalmol* 74(3):155-157, 1990.
- Sprunger DT, von Noorden GK, Helveston EM: Surgical results in Brown syndrome. *J Pediatr Ophthalmol Strabismus* 28(3):164-167, 1991.
- Toosi SH, von Noorden GK: Effect of isolated inferior oblique myectomy in management of superior oblique palsy. *Am J Ophthalmol* 88:602, 1979.
- Traboulsi EI, Jaafar MS, Hasan M, Kattan, et al: Congenital fibrosis of the extraocular muscles: report of 24 cases illustrating the clinical spectrum and surgical management. *Am Orthopt J* 43:45-53, 1993.
- von Noorden, GK: Oculomotor effects on vision: clinical aspects. In: Lennerstrand G, Bachy-Rita P, editors: *Basic mechanisms of ocular motility and their clinical implications*. New York, 1975, Pergamon Press.
- von Noorden GK: The nystagmus compensation (blockage) syndrome. *Am J Ophthalmol* 82:283, 1976.
- von Noorden GK: A reassessment of infantile esotropia. *Am J Ophthalmol* 105:1, 1988.
- von Noorden GK, Avilla CW: Nystagmus blockage syndrome: revisited. In Reinecke RD, editor: *Strabismus II*. New York, 1984, Grune & Stratton.
- von Noorden GK, Avilla CW: Refractive accommodative esotropia: a surgical problem? *Int Ophthalmol* 16(1):45-48, 1992.
- von Noorden GK, LaRoche R: Visual acuity and motor characteristics in congenital nystagmus. *Am J Ophthalmol* 95:748, 1983.
- von Noorden GK, Munoz M, Wong SY: Compensatory mechanisms in congenital nystagmus. *Am J Ophthalmol* 104:387, 1987.
- von Noorden GK, Wong SY: Surgical results in nystagmus blockage syndrome. *Ophthalmology* 93:1028, 1986.
- Wallace DK, Sprunger DT, Helveston EM, et al: Surgical management of strabismus associated with chronic progressive external ophthalmoplegia. *Ophthalmology* 104:695-700, 1997.
- Weakley DR, Stager DR, Everett ME: Seven-millimeter bilateral medial rectus recessions in infantile esotropia. *J Pediatr Ophthalmol Strabismus* 28(3):113-115, 1991.
- Weeston B, Enzenauer RW, Kraft SP, Gayowsky GR: Stability of the postoperative alignment in adjustable-suture strabismus surgery. *J Pediatr Ophthalmol Strabismus* 28(4):206-211, 1991.
- Wiggins RE, von Noorden GK: Monocular eye closure in sunlight. *J Pediatr Ophthalmol Strabismus* 27(1):16-20, 1990.
- Willshaw HE, Keenan J: Strabismus surgery in children: the prospects for binocular single vision. *Eye* 5(Pt 3):338-343, 1991.
- Wilson ME, Hutchinson AK, Saunders RA: Outcomes from surgical treatment for dissociated horizontal deviation. *J Am Assoc Pediatr Ophthalmol Strabismus* 4:94-101, 2000.
- Wilson ME, McClatchey SK: Axial length and the response to strabismus surgery (letter:comment). *Arch Ophthalmol* 108(4):476-477, 1990.
- Wilson ME, McClatchey SK: Dissociated horizontal deviation. *J Pediatr Ophthalmol Strabismus* 28:90-95, 1991.
- Zanoni D, Rosenbaum AL: A new method for evaluating distance stereo acuity. *J Pediatr Ophthalmol Strabismus* 28(5):255-260, 1991.
- Zubcov AA, Reinecke RD, Calhoun JH: Asymmetric horizontal tropias, DVD and manifest latent nystagmus: an explanation of dissociated horizontal deviation. *J Pediatr Ophthalmol Strabismus* 27(2):59-64, 1990.

Chapter 17

- Arnold RW: Pseudo-slipped muscle due to perioperative inflammatory palsy. *J Pediatr Ophthalmol Strabismus* 29(3):189-190, 1992.
- Bajart AM: Internal ophthalmoplegia following inferior oblique myectomy; a report of three cases. *Ophthalmology* 86:1401-1404, 1979.
- Bartley GB, Buller CR, Campbell RJ, Bullock JD: Pigmented episcleral mass from argyrosis following strabismus surgery (letter). *Arch Ophthalmol* 109(6): 775-776, 1991.
- Basmadjian G, Labelle P, Dumas J: Retinal detachment after strabismus surgery. *Am J Ophthalmol* 79:305-309, 1975.
- Bleik JH, Cherfan GM: Anterior segment ischemia after the Jensen procedure in a 10-year-old patient. *Am J Ophthalmol* 119:524, 1995.
- Cibis GW: Incidence of inadvertent perforation in strabismus surgery. *Ophthalmic Surg* 23(5):360-361, 1992.
- Eitzen JP, Elsas FJ: Strabismus following endoscopic intranasal sinus surgery. *J Pediatr Ophthalmol Strabismus* 28(3):168-170, 1991.
- Ellis FD, Wasserman BN, Hidaji F: Selected surgical complications. In: Rosenbaum AL, Santiago AP, eds. *Clinical strabismus management: Principles and surgical techniques*. Philadelphia, 1999, WB Saunders, pp. 539-551.
- Gottlieb F, Castro JL: Perforation of the globe during strabismus surgery. *Arch Ophthalmol* 84:151-157, 1970.
- Gross SA, von Noorden GK, Jones DB: Necrotizing scleritis and transient myopia following strabismus surgery. *Ophthalmic Surg* 24:839, 1993.
- Helveston EM, Alcorn DM, Ellis FD: Inferior oblique inclusion after lateral rectus surgery. *Graefes Arch Clin Exp Ophthalmol* 226:102-105, 1988.
- Helveston EM, Beams R, Cofield DD, Rohn RJ: Strabismus surgery in hemophilia. *J Pediatr Ophthalmol* 7:116-117, 1970.
- Ing MR: Infection following strabismus surgery. *Ophthalmic Surg* 22(1):41-43, 1991.
- Kushner BJ: Paresis and restriction of the inferior rectus muscle after orbital floor fracture. *Am J Ophthalmol* 94:81-86, July 1983.
- Kushner BJ: Restriction of elevation in adduction after inferior oblique anteriorization. *J Am Assoc Pediatr Ophthalmol Strabismus* 1:55, 1997.
- Lyons CJ, Lee JP: Bilateral consecutive superior oblique palsy following fronto-ethmoidal sinusitis. *J Pediatr Ophthalmol Strabismus* 27(5):233-236, 1990.
- MacEwen CJ, Lee JP, Fells P: Aetiology and management of the 'detached' rectus muscle (editorial). *Br J Ophthalmol* 76(3):131-136, 1992.
- McLean JM, Galin MA, Baras I: Retinal perforation during strabismus surgery. *Am J Ophthalmol* 50:1167-1169, 1960.
- Morris RJ, Rosen PH, Fells P: Incidence of inadvertent globe perforation during strabismus surgery. *Br J Ophthalmol* 74(8):490-493, 1990.
- Murray ADN: Slipped and lost muscles and other tales unexpected (Philip Knapp Lecture). *J Am Assoc Pediatr Ophthalmol Strabismus* 2:133, 1998.
- Pacheco EM, Guyton DL, Repka MX: Changes in eyelid position accompanying vertical rectus muscle surgery and prevention of lower lid retraction with adjustable surgery. *J Pediatr Ophthalmol Strabismus* 29(5):265-272, 1992.
- Plager DA, Parks MM: Recognition and repair of the "lost" rectus muscle. *Ophthalmology* 97:131, 1990.
- Recchia FM, Baumal Cr, Sivalingam A, et al: Endophthalmitis after pediatric strabismus surgery. *Arch Ophthalmol* 118:939, 2000.
- Salamon SM, Friberg TR, Luxenberg MN: Endophthalmitis after strabismus surgery. *Am J Ophthalmol* 93:39-41, 1982.
- Saunders RA, Sandall GS: Anterior segment ischemia syndrome following rectus muscle transposition. *Am J Ophthalmol* 93:43, 1982.
- Sharma P, Arya AV, Prakash P: Scleral dellen in strabismus surgery. *Acta Ophthalmol (Copenh)* 68(4):493-494, 1990.
- Simon JW, Lininger LL, Scheraga JL: Recognized scleral perforation during eye muscle surgery. *J Pediatr Ophthalmol Strabismus* 29(5):265-272, 1992.
- von Noorden GK: Orbital cellulitis following extraocular muscle surgery. *Am J Ophthalmol* 74(4):627-629, 1972.
- von Noorden GK: Anterior segment ischemia following the Jensen procedure. *Arch Ophthalmol* 94:845-847, 1976.
- Weakley DR: Orbital cellulitis complicating strabismus surgery: a case report and review of the literature. *Ann Ophthalmol* 23(12):454-457, 1991.

A

A esotropia. See Esotropia, A
 A exotropia. See Exotropia, A
 'A' pattern explanation, 108
 Abduction, limited, congenital esotropia and, 365
 Abscess, suture, as complication of strabismus surgery, 463
 Absorbable suture, synthetic, reaction to, as complication of strabismus surgery, 460
 Accommodative convergence/accommodation ratio (AC/A), 89
 Adduction, normal or nearly normal, exotropia after surgery for esotropia with, 368
 Adjustable suture, 116-117
 Adjustable suture considerations, 260
 Afterimage test, strabismus surgery and, 87
 Amblyopia, 120
 Anesthesia, 59, 60, 67, 68, 69, 70, 72, 75, 76
 dissociative, 69
 general, 68
 insufflation, 59
 local, 69
 retrobulbar, 70
 topical, 70
 Anesthetic apparatus, layout of, in operating room, 72
 Aneurysm, intracranial, right sixth nerve palsy from, 411
 Angiography, 48
 Angle kappa, 22
 Anterior arteries, sparing of, recession of rectus muscle, 194-195
 Anterior ciliary arteries, 48, 50
 anatomy of, 48
 sparing of, 50
 Anterior segment ischemia, 48
 Anterior Tenon's capsule, anatomy of, 15, 20, 23, 24, 25, 26, 27, 28, 30, 32, 38
 Anterior transposition of the inferior oblique, 222-225
 Antibiotics, postoperative, 76
 Antimongoloid palpebral fissure, 21
 Arc perimeter, 89
 A-scan biometer, 54
 Atropine, 68, 89
 Axial length, 17, 55

B

Bagolini striated glasses, strabismus surgery and, 87
 Barbie retractor, 63
 Barbiturates, 68
 Bielschowsky test, 107
 Bielschowsky head tilt test in superior oblique palsy, 152
 Bilateral lateral rectus recession for exotropia, 112
 Bilateral lateral rectus resection for esotropia, 110
 Bilateral sixth nerve palsy. See Sixth nerve palsy, bilateral
 Bimedial rectus recession
 A esotropia after, 375
 A exotropia after, 376
 and lateral rectus resection for esotropia, 111
 measured from the limbus for esotropia, 109
 Bimedial rectus recession-bilateral lateral rectus resection for esotropia, 111
 Bimedial rectus resection, 112
 Binocular function, 84
 Bagolini glasses, 87

Binocular function - cont'd

 first-degree fusion, 86
 haploscope examination, 85
 screen comitance, 85
 second-degree fusion, 86
 stereo acuity, 86
 Worth four-dot, 86
 Biometer, A-scan, 54
 Biomicroscopic examination, strabismus surgery and, 90
 Bishop tucking instrument, 8
 Blepharophimosis, epicanthus inversus and, 23
 Blood supply to anterior segment of eye, 15, 23, 31, 35, 38, 48, 49
 useful guidelines, 48
 Blowout fracture of orbit, 423
 acute, 424
 Botox, 275-282
 for treatment of benign essential blepharospasm, 277
 for treatment of strabismus, 276
 indications for, 276
 injection techniques, 277
 for blepharospasm and facial spasm, 281
 retrobulbar Botox for treatment of nystagmus, 277
 the drug, 275-282
 Botulinum A-toxin (Oculinum)
 technique for injection of, into extraocular muscle, 80
 Bradycardia, 68
 Brain stem stroke, nystagmus after, 449
 Brown syndrome, 147, 156, 216, 232, 234, 235, 263
 acquired, 383
 canine tooth, 148
 classification of, 149
 congenital, 381
 cyst at exit of trochlea, 233
 directed treatment, 233
 iatrogenic, 148, 384
 iatrogenic, 235
 idiopathic, 147
 inflammation, swelling restriction in trochlea, 233
 intra-trochlear adhesions, 232
 postoperative, as complication of strabismus surgery, 473-474
 restriction at entry of tendon to trochlea, 232
 surgery for, 148
 tendon shortness - restriction, 232
 trauma to trochlea - 'canine tooth', 233
 traumatic, 148
 with superior oblique underaction, 156
 Brown's superior oblique tendon sheath syndrome, tendon sheath stripping for treatment of, 232-233
 Bulbar conjunctiva, anatomy of, 23, 24

C

Canine tooth syndrome, 399
 Caruncle, anatomy of, 23, 24
 Cataract extraction from left inferior rectus restriction, diplopia after, 435
 Ceiling-mounted microscope, 74
 Cellulitis, orbital, as complication of strabismus surgery, 476
 Check ligaments, 18, 20, 33
 Chin depression in superior oblique palsy, 152

- Ciancia syndrome, 140, 365
 Ciliary arteries, anterior, 48, 50
 Cocaine hydrochloride, 70
 Complications in strabismus surgery. See Strabismus surgery, complications in
 Congenital absence
 of inferior rectus muscle, 9
 of superior oblique tendon, 401
 Congenital Brown syndrome, 381
 Congenital esotropia, 125. See Esotropia, congenital
 cause of, 135
 characteristics, 126, 140, 141
 differential diagnosis, 140
 large-angle esotropia/exotropia, 128
 microtropia, 127
 monofixation, 127
 results of early surgery, 128
 small-angle esotropia/exotropia, 127
 subnormal binocular vision, 127
 terminology, 125
 treatment, 127
 Congenital fibrosis syndrome, 425
 Congenital large-angle class III superior oblique palsy, 393
 Congenital nystagmus with decreased vision, 446
 Congenital superior oblique palsy, 153, 215, 216, 235
 Congenital third nerve palsy. See Third nerve palsy, congenital
 Conjunctiva, anatomy of, 15, 22, 23, 24, 25, 27, 28, 29, 30, 32
 Conjunctival incision, 163
 for exposing oblique muscles, 166
 Conjunctival recession, 261
 Consent, informed, 60, 457
 Convergence insufficiency intermittent exotropia, 146, 379
 Convergence, movement of eye during, 32, 34
 cover-uncover test, 87
 Cul-de-sac incision, 24, 48, 168
 Cyclodiplopia in superior oblique palsy, 152
 Cyclopentolate hydrochloride (Cyclogyl), 120, 121
 Cyclopropane, 68
 Cyst, subconjunctival, as complication of strabismus surgery, 460-461
- D**
- Dantrolene, 67, 68
 Decreased vision, congenital nystagmus with, 446
 Delle, as complication of strabismus surgery, 463
 Depth of focus, magnification and, 74
 Detachment, retinal. See Retinal detachment
 Diazepam, 70
 Differential intraocular pressure test, 98
 Diplopia
 after cataract extraction from left inferior rectus restriction, 435
 after repair of retinal detachment, 437
 after surgery, 457
 in superior oblique palsy, 152
 persistent
 after surgery for intermittent exotropia, 380
 bilateral sixth nerve palsy with, after successful treatment, 409
 symptomatic, skew deviations with, 427
- Displacement
 horizontal, of vertical rectus muscles, 190
 of horizontal rectus muscles with resection for A and V patterns, 211
 vertical, of horizontal rectus muscles, 190
 Dissociated vertical deviation (DVD), 88, 373
 A exotropia, bilateral overaction of superior obliques and, 441
 refractive esotropia with, 453
 with true hypotropia, 420
 Dissociative anesthesia, 69
 Divergence excess intermittent exotropia, 146, 378
 Divergence, movement of eyes during, 32
 Doll's head, 85
 Double elevator palsy, 422
 Double Maddox rod test, 89
 Double-arm suture technique for rectus muscle resection, 205-206
 Droperidol, 68
 Duane syndrome, 149-151, 385
 class I, 385
 class II, 386
 class III, 387
 class IV, 389
 classification of, 150-152
 common findings, 151
 exotropic, 150
 Huber classification, 150
 simultaneous abduction, 151
 treatment guidelines, 151
 with esotropia, 149-151, 385
 with limited adduction, 386
 with simultaneous abduction, 389
 with straight eyes and limited abduction and adduction, 150, 387
 Ductions, evaluation of, strabismus surgery and, 85
 DVD. See Dissociated vertical deviation
- E**
- E chart, visual acuity testing and, 83
 Echothiophate iodide (Phospholine), 67, 80, 89, 90
 Education, preoperative, outpatient strabismus surgery and, 59
 Elevation, Parinaud's paralysis of, 443
 Endophthalmitis, as complication of strabismus surgery, 476
 Epicanthal folds, pseudoesotropia and, 22, 23
 Epicanthus, 22, 23
 pseudoesotropia of, 22
 true telecanthus and, 22
 Epicanthus inversus, 22, 23
 Epinephrine, lidocaine with, 69
 Esotropia
 A pattern
 antimongoloid palpebral fissure and, 21
 vertically incomitant strabismus in, 21
 after bimedial rectus recession, 375
 bilateral lateral rectus resection for, 110
 bimedial rectus recession and lateral rectus resection for, 111
 bimedial rectus recession measured from the limbus for, 109
 bimedial rectus recession-bilateral lateral rectus

- Esotropia - cont'd
- resection for, 111
 - congenital, 2, 16, 17, 29, 46, 54, 56
 - with manifest latent nystagmus, limited abduction, and face turn, 365
 - without nystagmus, 363
 - exotropia after surgery for, with normal or nearly normal adduction, 368
 - four muscle surgery for, 111
 - horizontal rectus surgery for, 108-111
 - infantile
 - essential, 2
 - myectomy of medial rectus for, 2
 - recession of medial rectus-resection of lateral rectus for, 111
 - refractive/accommodative, 452
 - residual, 367
 - sensory, 418
 - residual, 419
 - single muscle procedures for, 108-109
 - three muscle surgery for, 111
 - two muscle surgery for, 109-111
 - V pattern, 21
 - antimongoloid palpebral fissure and, 21
 - with overaction of inferior oblique muscles, 439
 - with nystagmus, 458
- Essential infantile esotropia, 2
- Ether, open-drop, 68
- Exodeviations in intermittent exotropia, 143
- Exotropia
- A pattern
 - after bimedral rectus recession, 376
 - bilateral overaction of superior obliques, and dissociated vertical deviation, 441
 - intermittent, 143-148
 - after slipped medial rectus muscle, 369
 - after surgery for esotropia with normal or nearly normal adduction, 368
 - bilateral lateral rectus recession for, 112
 - bimedral rectus resection for, 112
 - caused by a "lost" medial rectus muscle, 370
 - constant, progression of intermittent exotropia to, 146-150
 - four muscle surgery for, 112
 - horizontal rectus surgery for, 111
 - intermittent, 142-148
 - A and V pattern with, 143-144
 - classification of, 143
 - combined horizontal and vertical deviation with, 144
 - convergence insufficiency, 146, 379
 - divergence excess, 146, 378
 - exodeviation in, in newborn, 143
 - nonsurgical treatment of, 144-145
 - parental observation in, 144
 - pathophysiology of, 143
 - pattern of deviation in, in young, 142
 - persistent diplopia after surgery for, 380
 - progression of, to constant esotropia, 146-150
 - racial predilection in, 143
 - refractive error in, 142
 - surgical treatment of, 145
- Exotropia - cont'd
- intermittent - cont'd
 - choice of muscles and amount of surgery in, 145-146
 - results of surgery for, 146
 - timing of surgery for, 145
 - work-up of patient with, 144
 - lateral rectus recession-medial rectus resection for, 112
 - sensory, 418
 - single lateral rectus recession-single medial rectus resection for, 111
 - single muscle surgery for, 111
 - three muscle surgery for, 112
 - two muscle surgery for, 112
 - V pattern
 - with overaction of the inferior obliques, 371
- External ophthalmoplegia, progressive, 430
- Extirpation of inferior oblique, 222-223
- Extraocular muscles
- anatomy of, 28
 - imaging of, 52
 - incisions in surgery of, 24
 - innervation of, 15, 29, 31, 32, 34, 35, 36
 - lengthing of, 14
 - maximum isometric contraction of, 32
 - movement of eye and, 32
 - origin of, 18
 - overaction of, 34
 - resting tension of, 32
 - shortening of, 14
 - static tension of, 32
 - Tenon's capsule and surgery of, 24
 - transfer of, 13
 - underaction of, 34
- Eye(s)
- anterior segment of, blood supply to, 48
 - center of rotation of, 31
 - falling, 420
 - growth of, from birth through childhood, 54
 - movement of, 31
- F**
- Face turn, congenital esotropia with, 365
 - Faden operation, 116, 247-254
 - Falling eye, 420
 - Fat pad, 24, 25, 30, 37
 - Fat, orbital, 14, 15
 - Fentanyl citrate, 70
 - Fibrosis syndrome
 - congenital, 425
 - Fick's axes, 31, 103
 - Finder hook, 63
 - Finer hook, 63
 - First-degree fusion, 86
 - Fixation OD, 84
 - Fixation OS, 84
 - Floor-mounted microscope, 74
 - Fluoromar. See Fluroxene
 - Fluothane. See Halothane
 - Fluroxene (Fluoromar), 68
 - Follow-up of the surgical patient, 120
 - Fornix incision, 24

- Fracture, blowout, of the orbit, 423
Fundus examination, 89-90
Fundus torsion in superior oblique palsy, 152
Fusion, 84
 central disruption of, 457
 first-degree, strabismus surgery and, 86
 range of, strabismus surgery and, 86
 second-degree, strabismus surgery and, 86-90
- G**
- Gastric bleeding, postoperative, 456
General anesthesia, 59, 67, 68, 70, 76
Generated muscle force, 98
Glasses
 Bagolini striated, 87
 telescopes mounted on, 74
Gold buttons as bolsters, resection of rectus muscle and, 8
Goldmann perimeter, 89
Granuloma, chronic suture, as complication of strabismus surgery, 460
Graves' ophthalmopathy, 402
 involving multiple muscles, 405
 with postoperative slippage of recessed inferior rectus, 403
Guidelines for application of surgical options, 117
- H**
- Halothane (Fluothane), 68
Handle suture, 257
Hang-back recession, 178, 193
Head posture, 138
 evaluation of, strabismus surgery and, 85
 in superior oblique palsy, 152
Headband, telescopes mounted on, 74
Helmeston two-step test, 107
Hemorrhage
 Orbital, as complication of strabismus surgery, 475
 Posterior chamber, as complication of strabismus surgery, 473
Hering's law, 105-108
Hess screen, 89
High AC/A. See Refractive/accommodative esotropia
High myopia, 54
Hirschberg test, 88
History of strabismus surgery, 1-14
Homatropine, 76
Horizontal displacement of vertical rectus muscles, 190
Horizontal rectus muscle
 displacement of, with resection for A and V patterns, 211-212
 resection of, 199
 management of check ligaments and intermuscular membrane in, 200-202
 surgery on
 for esotropia, 108-111
 for exotropia, 111-113
 vertical displacement of, 190
Hyperthermia, malignant, 60, 67, 68
Hyphema, as complication of strabismus surgery, 472
- I**
- Imaging, 52
- Incision
 cuffed superior limbal, 176
 cul-de-sac, 48
 for exposing obliques, 174
 fornix, 24
 in extraocular muscle surgery, 24
 limbal incision, 28
 Parks cul-de-sac, 168
 transconjunctival, 24
Infection after strabismus surgery, 76
Inferior oblique (IO) muscle
 anatomy of, 35
 anterior transposition of, 222-225
 extirpation of, 222-223
 Inclusion of, in lateral rectus insertion, as complication of strabismus surgery, 471
 overaction of, V pattern esotropia with, 439
 recession of, 12
 resection and advancement of, 225
 strengthening of, 115-PB 121, 225-233
 V pattern exotropia with overaction of, 371
 weakening of, 115
 common complication of, 220
 disinsertion and, 220
 recession and, 220
Inferior oblique adherence syndrome, as complication of strabismus surgery, 470
Inferior oblique myectomy, 216-220
Inferior oblique traction test, 95
Inferior oblique tuck, 225-226
Inferior rectus (IR) muscle
 anatomy of, 29
 congenital absence of, 9
 left, restriction of, diplopia after cataract extraction from, 435
 Lockwood's ligament and the lower lid, 185
 recession of, 177
 resection of, technique of, 207
 traumatic disinsertion of, 433
Informed consent, 60, 457
Instruments used in strabismus surgery, 63
Insufflation anesthesia, 59
Intermittent exotropia, 142. See Exotropia, intermittent
 'A' and 'V' pattern in, 143
 age of onset, 142
 choice of muscles, 145
 classification of, 143
 combined horizontal and vertical deviation in, 144
 convergence insufficiency, 146
 divergence excess, 146
 in the newborn, 143
 nonsurgical treatment of, 144
 parental observation, 144
 pathophysiology, 143
 pattern of deviation in, 142
 refractive error in, 142
 results of surgery, 146
 surgical treatment of, 145
 timing of surgery, 145
 work-up, 144
Intermuscular membrane, management of, in horizontal rectus resection, 200-202
intracranial aneurysm, right sixth nerve palsy, 411
IO muscle. See Inferior oblique muscle

- IR muscle. See Inferior rectus muscle
 Iris angiography, 48
 Ischemia, anterior segment, 469
 Isometric contraction of extraocular muscles, maximum, 32
- J**
- Jampolsky, spring back balance test of, 32
 Jensen tendon-muscle splitting transfer, 50
 J-shaped anomaly, 471
- K**
- Ketamine, 69
 Knapp procedure, 272
 Krinsky test, 88
- L**
- Lancaster screen, 89
 Lateral gaze prism and cover testing, 88
 Lateral rectus (LR) muscle
 anatomy of, 28
 insertion of, inclusion of inferior oblique in, as complication of strabismus surgery, 471
 recession of, 178
 medial rectus-resection of, for esotropia, 111
 resection of, 199-200
 bilateral, for esotropia, 110
 lateral rectus recession-medial rectus resection for exotropia, 112
 Lees screen, 89
 Left inferior rectus restriction, diplopia after cataract extraction from, 435
 Lid fissure anomalies as complication of strabismus surgery, 464
 Lid, upper, ptosis of, as complication of strabismus surgery, 465
 Lidocaine (Xylocaine), 68, 69, 70
 with epinephrine, 69
 Limbal incision, 28, 168, 171, 174
 Limbus, bimedial rectus recession measured from, for esotropia, 109
 Listing's plane, 31
 Local anesthesia, 69-70
 Lockwood's ligament, 15, 18, 20, 35, 36, 37, 51
 Loss of vision, as complication of strabismus surgery, 458
 Lost muscle, as complication of strabismus surgery, 466-467
 LR muscle. See Lateral rectus muscle
- M**
- Maddox rod test, 89
 Magnification in strabismus surgery, 74
 Malignant hyperthermia, 60, 67, 68
 Marginal myotomy, 241-246
 indications for, 245
 partial disinsertion, 246
 quantifying, 242
 Measuring from the limbus, 179
 Mechanics of surgery, 163-176
 Medial anterior segment circulation, 48
 Medial rectus (MR) muscle
 absence of, 432
 anatomy of, 16
 myectomy of, for esotropia, 2
 recession of, 178
 resection of, 199-200
 slipped, exotropia after, 369
 Medial rectus-resection of lateral rectus, recession of, for esotropia, 111
 Methoxyflurane (Penthrane), 68
 Microscope, floor- or ceiling-mounted, 74
 Moebius syndrome, 426
 Mongoloid palpebral fissure, 21
 Motility
 in superior oblique palsy, 152
 Motility disturbance after nonmotility procedures, as complication of strabismus surgery, 473
 Motor physiology, 103
 Motor physiology, anatomy of, 31
 MR muscle. See Medial rectus muscle
 Muscle
 slipped or lost as complication of strabismus surgery, 466-467
 Muscle transposition procedures, 265-274
 Muscle-tendon rupture, as complication of strabismus surgery, 472
 Myasthenia, ocular, 431
 Myectomy
 inferior oblique, 216-220
 of medial rectus for esotropia, 2
 Myelomeningocele, mongoloid slant of palpebral fissure and, 21, 22
 Myokymia
 superior oblique, 450
 Myopexy, retroequatorial, 14
 Myopia, high, 35, 54
 Myotomized muscles, use of sutures to reapproximate, in avoidance of overcorrection, 5
 Myotomy, marginal. See Marginal myotomy
- N**
- Naloxone (Narcan), 68
 Nanophthalmos, 54
 Narcan. See Naloxone
 Narcotics, 68
 Nasal shift, horizontal displacement of vertical rectus and, 190
 Needle, 7, 56, 66
 design, 57
 placement in sclera, 66
 placement of, 188
 in sclera, 56
 variations in, in recession of rectus muscle, 188
 Neo-Synephrine. See Phenylephrine
 Newborn visual sensory system, 135
 Next-day examination, outpatient strabismus surgery and, 60
 Nitrous oxide, 68
 Nonmotility procedures, motility disturbance after, as complication of strabismus surgery, 473
 Null point nystagmus, 444
 Nystagmus, 84

after brain stem stroke, 449
 congenital esotropia and, 365, 458
 congenital esotropia without, 363
 congenital, with decreased vision, 446
 manifest latent, congenital esotropia with, 365
 null point, 444
 vertical with retraction, 85
 Nystagmus blockage syndrome, 140, 366

O

O'Connor cinch, shortening of rectus muscle and, 9
 Oblique muscles
 exposure of, 174
 inferior. See Inferior oblique muscle
 superior. See Superior oblique muscle
 Ocular motility studies in the newborn, 133
 Ocular motor apraxia, 84
 Ocular myasthenia, 431
 Oculinum. See Botulinum A-toxin
 Operating room
 layout of, 72
 patient preparation in, 70
 Ophthalmic needle. See Needle
 Ophthalmopathy
 Graves'. See Graves' ophthalmopathy
 thyroid. See Thyroid ophthalmopathy
 Ophthalmoplegia, progressive external, 430
 Orbit, blowout fracture of, 423
 Orbital cellulitis, as complication of strabismus surgery, 476
 Orbital fat, 14, 15, 20, 26, 30, 37
 Orbital hemorrhage, as complication of strabismus surgery, 475
 Orthotropization curve, 134
 Outpatient surgery, 59, 60, 68, 75, 76
 Overaction
 of extraocular muscles, 35
 persistent, of inferior oblique muscle, as complication of strabismus surgery, 470

P

Palpebral fissure
 anatomy of, 15
 antimongoloid, 20, 21
 level of, 21
 mongoloid, 21
 Palsy, 47
 double elevator, 422
 right superior oblique, 47
 sixth nerve. See Sixth nerve palsy
 superior oblique. See Superior oblique palsy
 third nerve. See Third nerve palsy
 Pancuronium, 67
 Paralysis, Parinaud's, of elevation, 443
 Paretic muscle, speed of saccade in, 32
 Parinaud's paralysis of elevation, 443
 Parks 3-step test, 107
 Parks cul-de-sac incision, 168
 Partial disinsertion for torticollis, 194
 Patch, postoperative, 59, 76, 457
 Patient
 postoperative care of, 76
 preparation of in the operating room, 70-72

Patient - cont'd
 under endotracheal anesthesia, monitoring of, 72
 Perilimbal anesthesia, 69
 Peter's whip stitch, 7
 Phenylephrine (Neo-Synephrine), 80, 89
 Phenylketopyruvate, 67
 Physical examination, preoperative, 60
 Plica semilunaris, 23, 24
 Plication of a rectus muscle, 210
 Posterior chamber hemorrhage, as complication of strabismus surgery, 473
 Posterior fixation suture, 116, 247
 adjustable faden, 252
 combined with recession, 252
 laudable secondary deviation, 247
 placement of after detaching muscle, 251
 placement of without detaching muscle, 251
 reduced lever arm, 249
 reinforced, 252
 Posterior Tenon's capsule, anatomy of, 24
 Postoperative examination, outpatient strabismus surgery, 76
 Postoperative gastric bleeding, 456
 Postoperative nausea and vomiting as complication of strabismus surgery, 68
 Postoperative nausea and vomiting, as complication of strabismus surgery, 458
 Prednisolone, 76
 Preoperative education, outpatient strabismus surgery and, 59
 Preoperative medication, 68
 Prism cover testing, 87-89
 Progressive external ophthalmoplegia, 430
 Prolapse of Tenon's capsule, as complication of strabismus surgery, 462
 Pseudocholinesterase, echothophate iodide and, 67
 Pseudoesotropia, epicanthal folds and, 22
 Pseudostrabismus, 21, 22
 Ptosis
 epicanthus inversus and, 23
 of upper lid, as complication of strabismus surgery, 465
 Pulleys, 18

R

Recession
 bimedial rectus
 and lateral rectus resection, for esotropia, 111
 measured from the limbus, for esotropia, 109
 hang-back, 193
 horizontal rectus, vertical effect from, 212
 of inferior oblique muscle, 12
 of inferior rectus muscle, 193
 of lateral rectus muscle, 178
 of medial rectus muscle, 179-181
 of superior oblique muscle, 230
 of superior rectus muscle, 182
 Rectus muscle transfer, 268
 Rectus muscles
 anatomy of, 28
 gold buttons as bolsters and, 8
 horizontal
 displacement of, with resection for A and V patterns, 211-212

- Rectus muscles - cont'd
 vertical displacement of, 190
 inferior. See Inferior rectus muscle
 insertion of, 29
 medial. See Medial rectus muscle
 plication of, 210
 recession of
 bimedial. See Bimedial rectus recession
 resection effect of suture placement posterior to the muscle hook, 192-193
 technique of, 186-190
 variations in suture and needle placement in, 188-190
 with sparing of anterior arteries, 194-195
 resection of, 199-214
 double-arm suture technique for, 205-206
 horizontal. See Horizontal rectus resection
 resection clamp technique for, 201-205
 tandem suture technique for, 208-210
 surgery of, horizontal, for exotropia, 111-113
 vertical, horizontal displacement of, 190
- Red lens test, 89
- Refraction, 89, 120-121
- Refractive error in intermittent exotropia, 142
- Refractive esotropia
 typical, 451
 with dissociated vertical deviation, 453
- Refractive/accommodative esotropia (high AC/A), 452
- Reoperation, complications in strabismus surgery and, 458
- Resection
 bilateral lateral rectus, for esotropia, 110
 horizontal rectus, vertical effect from, 212
 of inferior rectus muscle, technique of, 207-208
 of superior rectus muscle, 206
- Resection clamp technique for rectus muscle resection, 201-205
- Resection effect of suture placement posterior to muscle hook, recession of rectus muscle and, 192
- Residual esotropia, 367
- Resting tension of extraocular muscles, 32
- Restrictions, 90
 fixing with the paretic eye, 92
 fixing with the sound eye, 92
 forced ductions, 94-95
 saccadic velocity analysis, 91
- Retina, examination of, 89
- Retinal detachment
 diplopia after repair of, 437
 surgery for, Tenon's capsule and, 25
- Retinoblastoma, 89, 90
- Retrobulbar anesthesia, 70
- Retrobulbar Botox for treatment of nystagmus, 277
- Retroequatorial myopexy, 14, 247
- Review of muscle transposition procedures, 265-274
- S**
- Saccade, 32, 34
- Sagittalization of superior oblique muscle, 231-232
- Sclera
 anatomy of, 56
 placement of needle into, 56
 suturing of the tendon to, 5
 thickness of, 56
- Scleral augmented muscle-tendon transfer, 270
- Scleral perforation, as complication of strabismus surgery, 465-466
- Scleral ruler, 64, 187
- Screen comitance, evaluation of, strabismus surgery and, 85
- Second-degree fusion, strabismus surgery and, 86
- Sensory evaluation, strabismus surgery and, 85
- Sensory exotropia, 418
- Sensory fixation, evaluation of, strabismus surgery and, 87
- Sensory testing, implications of, strabismus surgery and, 87
- Simultaneous prism and cover testing (SPC), 88
- Single lateral rectus-single medial rectus recession for exotropia, 111
- Sixth nerve palsy
 bilateral, 408
 with persistent diplopia after successful treatment, 409
 right, from intracranial aneurysm, 411
 unilateral, 406
- Skew deviation with symptomatic diplopia, 427
- Slanted recession, 196
- Slipped muscle, as complication of strabismus surgery, 466-467
- SO muscle. See Superior oblique muscle
- Spectacle prescription, 121
- Speculum, 16
- Spiral of Tillaux, 24, 29
- Spring back balance test of Jampolsky, 32
- SR muscle. See Superior rectus muscle
- Static tension of extraocular muscles, 32
- Stereo acuity, strabismus surgery and, 86
- Steroids
 postoperative, 76
- Strabismus case management index, 359-454
- Strabismus surgery
 afterimage test and, 87
 anatomy and, 15-58
 anesthesia for, 67
 Bagolini striated glasses and, 87
 biomicroscopic examination and, 90
 complications of
 acute, allergic suture reaction as, 459
 anterior segment ischemia as, 469
 categories of, 455
 chronic suture granuloma as, 460
 delle as, 463
 diplopia as, 457
 endophthalmitis as, 476
 hyphema as, 472
 inclusion of the inferior oblique in the lateral rectus insertion as, 471
 inferior oblique adherence syndrome as, 470
 informed consent as, 457
 lid fissure anomalies as, 464
 loss of vision as, 458
 motility disturbance after nonmotility procedures as, 473
 muscle-tendon rupture as, 472
 orbital cellulitis as, 476
 orbital hemorrhage as, 475
 persistent overaction of inferior oblique muscle as, 470

- Strabismus surgery - cont'd
- complications of - cont'd
 - posterior chamber hemorrhage as, 473
 - postoperative Brown's syndrome, 473-474
 - postoperative nausea and vomiting as, 458
 - prolapse of Tenon's capsule as, 462
 - ptosis of upper lid, 465
 - reaction to synthetic absorbable suture as, 460
 - reoperation, 458
 - scleral perforation as, 465-466
 - slipped or lost muscle as, 466-467
 - subconjunctival cysts as, 460-461
 - suture abscess as, 463
 - symblepharon as, 474
 - criteria for success after, 455-457
 - design of procedure for, 79-81
 - diagnosis and, 90
 - ductions and, 85
 - first-degree fusion and, 86
 - follow-up of patient after, 120-121
 - fundus examination and, 89-90
 - guidelines for application of surgical options in, 117-120
 - head posture evaluation and, 85
 - infection after, 59
 - instruments used in, 63
 - magnification in, 74
 - patient evaluation and, 81-90
 - prism cover testing and, 87-89
 - range of fusion and, 86
 - refraction, 89
 - results to be expected from, 108-117
 - screen comitance evaluation and, 85
 - second-degree fusion and, 86-90
 - sensory evaluation and, 85-87
 - sensory fixation and, 87
 - stereo acuity and, 86
 - technique of, 120
 - timing of, 121
 - Worth four-dot testing and, 86
- Stroke, brain stem, nystagmus after, 449
- STYCAR chart, visual acuity testing and, 83
- Subconjunctival cysts as complication of strabismus surgery, 460-461
- Succinylcholine, 67
- Sulfacetamide sodium, 76
- Superior oblique (SO) muscle
- anatomy of, 38
 - anterior shift of, 114-115
 - bilateral overaction of, dissociated vertical deviation, and A exotropia, 441
 - recession of, 230
 - sagittalization of, 231-232
 - strengthening of, 114
 - weakening of, 114
- Superior oblique myokymia, 450
- Superior oblique palsy, 151-154
- acquired, 153
 - acquired, 215, 235
 - anatomic congenital, 157
 - Bielschowsky head tilt test in, 152
 - bilateral, 397
 - chin depression in, 152
- Superior oblique palsy - cont'd
- class I, 154, 390
 - class II, 154, 392
 - class III, 155, 393
 - large-angle congenital, 393
 - class IV, 155
 - large acquired, 395
 - class V, 155
 - class VI, 155
 - class VII, 156, 399
 - congenital, 153, 156-157, 215, 216, 235
 - cyclodiplopa in, 152
 - diplopia in, 152
 - double Maddox rod torsion in, 152
 - fundus torsion in, 152
 - head posture in, 152
 - motility in, 152
 - patient demographics, 158
 - patient history in, 152
 - patient presentation in, 152-153
 - scheme for etiology, 154
 - surgical procedures performed, 159
 - torticollis in, 152
 - treatment classification of, 153-154
- Superior oblique resection and advancement, 237
- Superior oblique tendon
- bundles of fibers, 45
 - congenital absence of, 401
 - exposure of, 174
 - resection of, 12
 - scanning electron microscopy of, 45
 - size of fiber, 45
 - strengthening of, 237
 - transcutaneous approach to, 9
 - tucking of, 11
- Superior oblique tendon transfer, 273
- Superior oblique tendon expander, 234
- Superior oblique tenotomy, 226-228
- after temporal approach, 228-230
- Superior oblique traction test, 95, 215-216
- Superior oblique tuck at insertion, 235-237
- Superior rectus (SR) muscle
- anatomy of, 29
- Surgical anatomy, 15-58
- Suture granuloma, chronic, as complication of strabismus surgery, 460
- Suture reaction, acute, allergic, as complication of strabismus surgery, 460
- Suture(s), 64
- animal product absorbable, 64
 - double-arm, technique of, for rectus muscle resection, 205-206
 - nonabsorbable, 64, 66
 - posterior fixation, 116
 - resection effect of placement of, posterior to muscle hook, recession of rectus muscle and, 192-193
 - resection using, 5
 - synthetic absorbable, 65
 - reaction to, as complication of strabismus surgery, 460
 - Vicryl, 65
 - tandem, technique of, for rectus muscle resection, 208-210
 - tenotomy and, 4

- Suture(s) - cont'd
 traction
 in strabismus surgery, 263
 use of, to reapproximate myotomized muscles in
 avoidance of overcorrection, 5
 variations in, in recession of rectus muscle, 188-190
- Symblypharon, 24
- Synthetic absorbable suture
 reaction to, as complication of strabismus surgery,
 460
- T**
- Tandem adjustable suture, 259
- Tandem suture technique for rectus muscle resection, 208-210
- Teaser hook, 63
- Telecanthus, true, epicanthus and, 23
- Telescopes mounted on glasses frames or headband, 74
- Teller acuity cards, visual acuity testing, 83
- Tendon sheath stripping for treatment of Brown's superior oblique tendon sheath syndrome, 232-233
- Tendon, suturing of, to sclera, 5
- Tendon-lengthening procedures, 2, 3
- Tenon's capsule, 24-25
- Tenon's capsule
 prolapse of, as complication of strabismus surgery,
 462
- Tenotomy
 sutures and, 4
- Tetracaine, 70
- Thiopental sodium (Pentothal), 68
- Third nerve palsy, 216
 acquired, 412
 congenital, 416
 severe bilateral, 417
 traumatic, with misdirection after successful horizontal alignment, 414
- Thyroid ophthalmopathy, 402
 involving multiple muscles, 405
 with postoperative slippage of recessed inferior rectus, 403
- Tillaux, spiral of, 24
- Topical anesthesia, 70
- Traction sutures, 164
 in strabismus surgery, 263
- Transconjunctival incision, 24
- Transposition for head tilt without oblique muscle dysfunction, 274
- Traumatic disinsertion of inferior rectus muscle, 433
- Traumatic third nerve palsy with misdirection after successful horizontal alignment, 414
- Trochlea, 42
 absence of, 47
 dimensions of, 44
 exenterated orbit, 42
 trochlear complex, 42
 trochlear components, 44
 cartilage saddle, 44
 trochlear cuff, 44
- True knot, 187
- True telecanthus, epicanthus and, 22
- Tuck
 for muscle-tendon shortening, 8
 inferior oblique, 225
- Tuck - cont'd
 of extraocular muscles, 8
 of rectus muscle, 210
- U**
- Underaction of extraocular muscles, 34
- Unilateral sixth nerve palsy, 406
- Unique characteristics of each extraocular muscle, 166
- Upper lid, ptosis of, as complication of strabismus surgery, 465
- V**
- V esotropia. See Esotropia, V
- V exotropia. See Exotropia, V
- 'V' pattern explanation, 108
- Versed, 68, 75
- Versions, evaluation of, strabismus surgery and, 85
- Vertical displacement of horizontal rectus, 190
- Vertical effect from horizontal rectus resection and recession, 212
- Vertical nystagmus with retraction, 85
- Vertical rectus muscles
 horizontal displacement of, 190-192
 surgery on, 113-114
- Vertically incomitant strabismus
 A pattern in esotropia, 21
 horizontal, surgery for, 115-116
 V pattern in esotropia, 21
- Vision
 decreased, congenital nystagmus with, 446
- Visual testing, 84
 after-image test, 87
 ductions, 85
 fixation, 84
 prism cover testing, 87
 refraction, 89
- Vomiting, postoperative, 59, 68
- Vortex veins, 15, 51, 177, 185, 207
- W**
- Whitnall's ligament, 15, 20, 41
- Worth four-dot testing, strabismus surgery and, 86
- X**
- X-axis of Fick, 31
- Y**
- Y-axis of Fick, 31
- 'Y' split of the lateral rectus, 197
- Yoked extraocular muscles, 106
- Z**
- Z tenotomy, 1, 3
- Z-axis of Fick, 31
- Zinn, ligament of, 18, 34, 38

